



# Review of methods for the detection of *Lawsonia intracellularis* infection in pigs

Marta Campillo,<sup>1</sup> Sionagh H. Smith,  
David L. Gally, Tanja Opriessnig

**Abstract.** *Lawsonia intracellularis* is an obligate intracellular bacterium associated with enteric disease in pigs. Clinical signs include weight loss, diarrhea, and, in some cases, sudden death. The hallmark lesion is the thickening of the intestinal mucosa caused by increased epithelial cell replication, known as proliferative enteropathy. The immune response to *L. intracellularis* is not well defined, and detection of the infection, especially in the early stages, is still a significant challenge. We review here the main approaches used to identify this important but poorly understood pathogen. Detection of *L. intracellularis* infection as the cause of clinical disease is confounded by the high prevalence of the pathogen in many countries and that several other pathogens can produce similar clinical signs. A single *L. intracellularis*-specific ELISA and several amplification assays are available commercially to aid detection and surveillance, although histopathology remains the primary way to reach a conclusive diagnosis. There are major gaps in our understanding of *L. intracellularis* pathogenesis, especially how the host responds to infection and the factors that drive infection toward different clinical outcomes. Knowledge of pathogenesis will increase the predictive value of antemortem tests to guide appropriate interventions, including identification and treatment of subclinically affected pigs in the early stages of disease, given that this important manifestation reduces pig productivity and contributes to the economic burden of *L. intracellularis* worldwide.

**Keywords:** bacteria; detection tools; *Lawsonia intracellularis*; pigs; porcine proliferative enteropathy.

The obligate intracellular bacterium *Lawsonia intracellularis* has been associated with enteric disease in various animal species, but it is of greatest importance in pigs.<sup>17,18,40,42,72,77</sup> In 1931, a clinical presentation in pigs, characterized by diarrhea, weight loss, and, in some cases, sudden death, was described for the first time.<sup>7</sup> In 1953, the disease was given the name *proliferative enteropathy* (PE) to reflect the main pathologic changes (i.e., proliferation of crypt enterocytes).<sup>24</sup> Since then, PE has emerged as a disease of economic significance to the pig industry, causing clinical disease in a wide age range of pigs depending on specific manifestations. Economic impact assessments vary depending on the country of origin and clinical subtype but, overall, they indicate a potential for significant financial impact if *L. intracellularis* infection is highly prevalent.<sup>17,40,72,77</sup>

Detection of *L. intracellularis* infection remains a challenge for swine practitioners and producers. Infection can be subclinical but, even when clinical signs are apparent, diagnosis of PE may be complicated because several pathogens can have similar clinical presentations (e.g., *Brachyspira hyodysenteriae*, *Salmonella enterica* serovar Typhimurium, and porcine circovirus 2 [PCV-2]).<sup>3,9,100</sup> The scarcity of suitably validated detection tools, together with a lack of pathognomonic clinical signs and intermittent shedding of bacteria, can hinder confident and meaningful diagnosis.

Our review focuses on recent advances in the diagnosis of PE. We also compare the value, advantages, and drawbacks of detection tools available to the pig production industry, to date.

## Disease overview

Clinical signs of *L. intracellularis* infection in pigs have been well documented. The disease generally manifests in 1 of 2 ways clinically, acute PE and chronic PE, or the infection may remain subclinical.<sup>21,65,107</sup>

In the most fulminant (and less frequent) *acute form* of PE, *L. intracellularis* infection can be associated with sudden death of pigs > 4 mo old as a result of severe acute hemorrhage into the intestinal tract, variably known as proliferative hemorrhagic enteropathy or acute PE.<sup>60,93</sup> In these severe cases, pigs may exsanguinate prior to the development of diarrhea, and the only other clinical sign may be pallor. However, in more prolonged cases, melena or hematochezia

The Roslin Institute and The Royal (Dick) School of Veterinary Studies, University of Edinburgh, Easter Bush, Midlothian, UK.

<sup>1</sup>Corresponding author: Marta Campillo, Wellcome Centre for Integrative Parasitology, Institute of Infection, Immunity & Inflammation, College of Medical, Veterinary and Life Sciences, University of Glasgow, 120 University Place, Glasgow, G12 8TA, Scotland, UK.  
marta.campillopoveda@glasgow.ac.uk

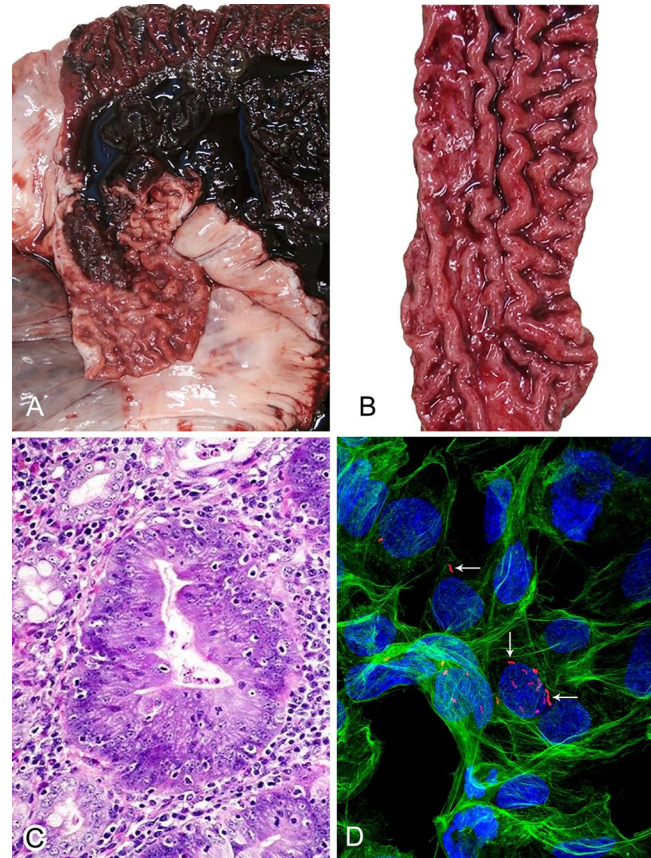are appreciable.<sup>107</sup> The mortality rate for acute PE is 12–50% and is more typical in replacement breeder animals.<sup>31,55,74,106</sup>

The *chronic form* of PE causes non-hemorrhagic diarrhea (i.e., gray-green, semi-solid to liquid feces), weight loss, or reduced rates of weight gain in younger pigs, but clinical signs are often subtle, and diarrhea may not be present.<sup>78</sup> Affected pigs are 6–16 wk old and are often in suboptimal-to-poor body condition, with a normal-to-dull demeanor. Although widely known as chronic PE, this subtype is also termed porcine intestinal adenomatosis, proliferative ileitis, or just ileitis.<sup>24,93,107</sup> Chronic PE is generally not fatal, and recovery within several weeks is the norm.<sup>92,107</sup> The mortality rate is ~2%, and death is generally the result of secondary infections. However, fecal shedding of *L. intracellularis* increases the likelihood of pig-to-pig transmission, negatively impacting morbidity, feed conversion rates, treatment cost, and time to slaughter.<sup>2,17,29,74</sup>

*Subclinical infection* is usually characterized by reduced growth rates and increased feed conversion rates, in the absence of other clinical signs.<sup>21,24,43,84,92,98,106</sup> Although subclinically infected pigs do not usually have diarrhea, they still generally have histologic lesions, shed the bacterium, and may remain a source of infection for other pigs.<sup>11</sup> Studies to account for the dichotomous outcome of *L. intracellularis* infection (i.e., subclinical infection vs. overt clinical signs [including acute or chronic PE]), are lacking to date.

## Lesions

Macroscopic lesions associated with *L. intracellularis* infection can occur at all levels of the intestinal tract. Lesions are typically localized in the terminal ileum from where they may extend distally to the colon and cecum, or proximally to the distal jejunum.<sup>37,45,48</sup> The intestinal mucosa may become thickened by raised islands of the mucosa (originally described as polyps).<sup>7</sup> In more severe or advanced cases, the islands coalesce, resulting in mucosa that has a thickened, corrugated, or cerebriform appearance (Fig. 1A). In some cases, there is focal necrosis, with superimposed yellow or gray deposits of fibrin and cellular debris (Fig. 1B).<sup>57</sup> Secondary infection may lead to necrotic enteritis, characterized by coagulative necrosis and superimposed fibrin. If the pig survives, the necrotic tissue is replaced by granulation tissue. This lesion is known as regional ileitis or, more colloquially, “hosepipe gut.”<sup>94</sup> Mucosal thickening is common to both the acute and chronic forms of PE, but only in acute PE does the intestinal content consist of blood, including blood clots, free blood, and fibrin, the exact origin of which remains unclear. Although highly suggestive of PE, these lesions are not solely indicative of *L. intracellularis*. For example, the gross features of PCV-2 enteritis can be very similar to the necrotizing form of PE.<sup>46</sup> Pigs may also be infected in the absence of macroscopically appreciable lesions, or lesions may be small and focal, and thus are easily overlooked



**Figure 1.** *Lawsonia intracellularis* infection and associated lesions. **A.** Pig ileum from a case of acute proliferative enteropathy (PE). The lumen is filled with clotted blood, and the exposed mucosa is markedly thickened and corrugated. **B.** Pig ileum from a case of acute PE. The blood clot has been removed to expose the highly corrugated mucosa. A severe case of chronic PE would appear similar grossly, lacking only the intraluminal blood clot. **C.** Dramatic enterocyte hyperplasia in an intestinal crypt from a case of PE, in which there is also goblet cell depletion. H&E. 400 $\times$ . **D.** PK15 cells infected with *L. intracellularis*, which is labeled with a specific monoclonal antibody and detected with AlexaFluor594 (red; arrows). PK15 actin is labeled with phalloidin-495 (green), and nuclei are labeled with DAPI (blue). Immunofluorescence with confocal microscopy. 400 $\times$ .

postmortem.<sup>36</sup> Diagnosis may also be hampered if PE is masked or complicated by other diseases, such as salmonellosis or swine dysentery.<sup>78,100</sup>

The microscopic lesions of PE are very characteristic and generally pathognomonic, unless mild, infrequent, or complicated by secondary or concomitant infections. The lesions have been well characterized and, in short, consist of hyperplasia of crypt enterocytes with the formation of elongated, dilated, and branching crypts. The hyperplasia is accompanied by increased mitoses and a reduction in, or complete loss of, goblet cells (Fig. 1C; i.e., loss of differentiation of the mucosal epithelial population).<sup>6,57</sup> Crypt hyperplasia is not specific, however, and can occur as a nonspecific

reactive or regenerative change in the face of mucosal injury or ulceration.<sup>14,86</sup>

### Immunology

Understanding the host immune response against a specific pathogen can help in the development of specific laboratory tests. A review summarizing the current knowledge of the porcine immune response to *L. intracellularis* and the potential applications of this response for diagnostic purposes was published in 2020.<sup>83</sup> We aim to put the timing of these responses into the context of their value for detection of the infection in relation to clinical signs and direct detection of the pathogen (Fig. 2).

Innate immunity is the first line of defense and, in pigs, the first signs of a general inflammatory response are expected 2–3 d post-infection (dpi).<sup>68</sup> In chronic PE, the absence of an inflammatory response including the relative dearth of immune cells in affected areas could be a consequence of bacterial inhibition.<sup>75,91</sup> In contrast, during acute PE, some authors have described an immune response characterized by increased numbers of macrophages in the mucosa, as well as high levels of proinflammatory cytokines.<sup>65,66</sup> The reason for these differences is unknown.<sup>19,30,65,82,91,105</sup>

The cell-mediated immune response to *L. intracellularis* is poorly defined. However, type 1 cytokine levels are often altered; for example, increased levels of interferon-gamma (IFN- $\gamma$ ), IL-6, IL-10, transforming growth factor- $\beta$  (TGF- $\beta$ ), and tumor necrosis factor- $\alpha$  (TNF- $\alpha$ ) have been reported.<sup>82,112</sup> Insights into the *L. intracellularis*-specific IFN- $\gamma$ -producing cell responses have been published using the enzyme-linked immunospot (ELISpot) assay for IFN- $\gamma$  detection, as well as the use of IFN- $\gamma$  receptor knockout mice.<sup>28,30,83,91,95,112</sup> These studies have concluded that IFN- $\gamma$  is elevated in infected pigs from 10 dpi, peaking at 20 dpi, earlier than other cytokines (Fig. 2B). They have also demonstrated that IFN- $\gamma$  plays a role in the control of *L. intracellularis* infection, given that mice lacking IFN- $\gamma$  receptors are unable to control infection.<sup>28,95</sup> These cytokine changes may be of use diagnostically in the future if faster and more inexpensive tools to detect them become available, but defining *L. intracellularis* infection specifically with such readouts alone would be impossible unless unique signatures are demonstrated.<sup>25</sup>

With respect to humoral immunity, specific antibodies have been detected in the sera, intestinal mucosa, and feces of pigs experimentally infected with *L. intracellularis*.<sup>30</sup> Antibodies were also detected in oral fluids in pigs naturally infected with *L. intracellularis*.<sup>4,39,103</sup> Circulating and/or fecal antibodies may have some potential for diagnostic purposes, as they may indicate previous exposure to *L. intracellularis*. Furthermore, in the case of vaccinated and field infections, the main antibody isotypes are IgG, IgM, and IgA and, hence, based on antibody types or levels, differentiation between vaccinated and naturally infected pigs is not

possible.<sup>82</sup> *Lawsonia*-specific IgG and IgM responses can be detected in serum 2 wk after infection (Fig. 2B). They peak at 3–4 wk and remain detectable for up to 13 wk post-infection.<sup>31,82</sup> IgG responses may result from active infection, vaccination, or colostrum intake.<sup>31,33,82,90</sup> On the other hand, although IgA has been observed in feces, the concentration of IgA bears no relationship to the concentration of serum IgG.<sup>19,30,82</sup> The mechanism by which IgA is involved in bacterial clearance is unknown.<sup>30,82</sup>

### In vitro culture of *L. intracellularis*

*L. intracellularis* is an obligate intracellular, straight or curved, gram-negative, non-spore-forming bacillus in the *Desulfovibrionaceae* family.<sup>26</sup> There is a strong correlation between the presence of the organism in the apical cytoplasm of crypt enterocytes and the development of lesions.<sup>57,76,92,93</sup> The diagnosis of many bacterial infections involves bacterial culture,<sup>27</sup> but culture has never been an option for *L. intracellularis*. Even when unadulterated by fecal material or competing gut flora, in vitro propagation of *L. intracellularis* is extremely difficult and remains a primary research hurdle. Only a few laboratories have the required in vitro culture systems available to satisfy the specific growth requirements of this organism. Briefly, the culture method, optimized from the first descriptions, comprises an anaerobic tri-gas mixture (80% nitrogen, 10% hydrogen, 10% carbon dioxide) that is used to generate strict atmospheric requirements.<sup>58</sup> Further optimization resulted in an alternative method using Original Space Bags (Storage Packs) inflated with the gas mixture rather than the use of a conventional anaerobic jar.<sup>108</sup> *L. intracellularis* can be cultured in PK15 cells (porcine kidney epithelial cells) and imaged by immunofluorescence (Fig. 1D).

### Common tools for detection of *L. intracellularis*

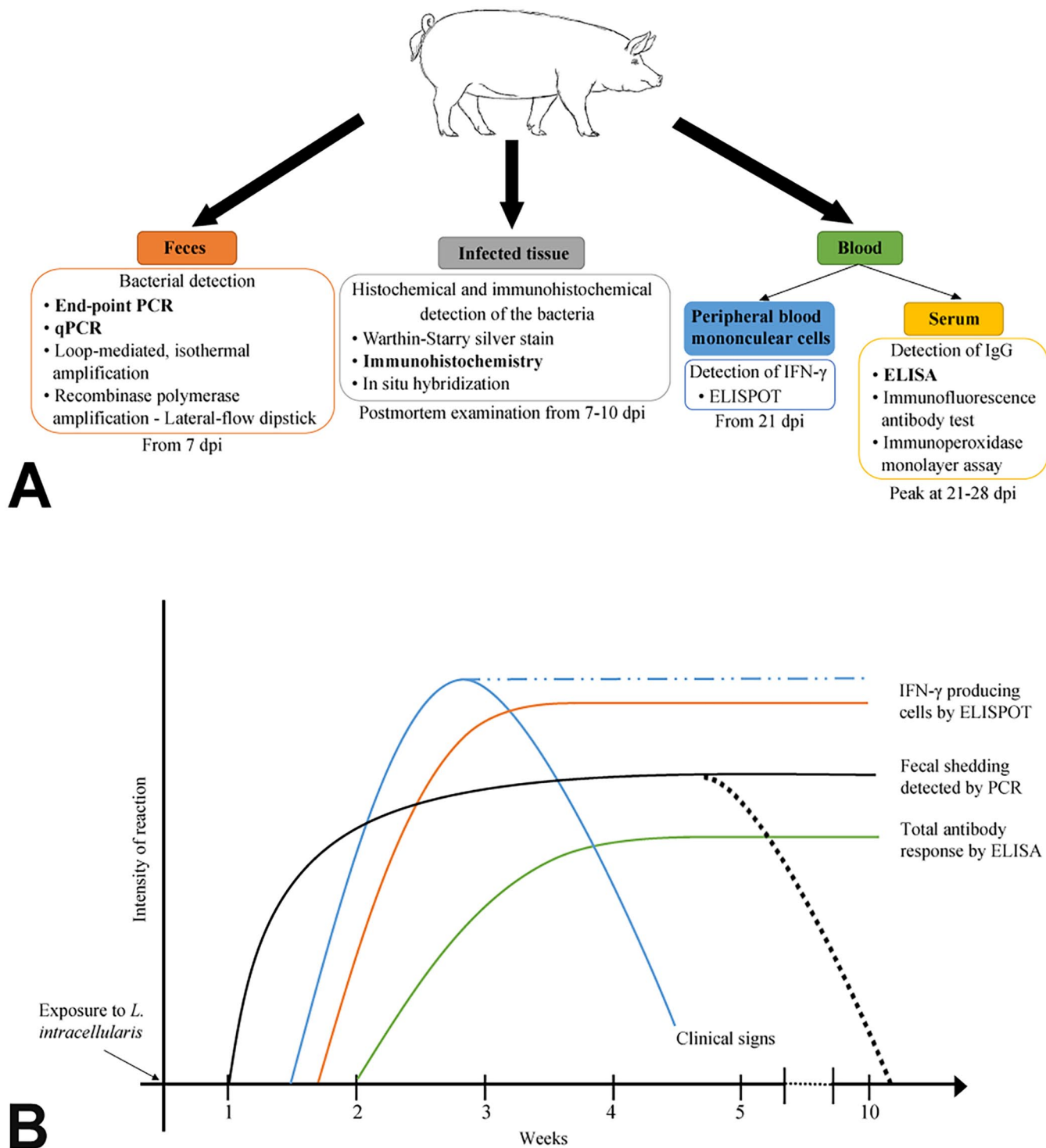
#### Histochemical, immunohistochemical, and in situ hybridization techniques

There are several methods for confirming the presence of *L. intracellularis* bacteria, antigens, or nucleic acids in formalin-fixed or frozen tissue sections (Fig. 2A). Post-infection, up to 5 d of intracellular proliferation may be required for bacteria to reach levels that are detectable using these methods, although antigen can be detected until at least 14 dpi.<sup>10,37,106</sup>

#### Warthin–Starry silver stain

In 1920, a silver nitrate-based stain was first developed for improved detection of spirochetes.<sup>110</sup> The Warthin–Starry (WS) histologic stain works on the ability of spirochetal organisms to absorb silver from solution, given their distinctive





**Figure 2.** Detection of *Lawsonia intracellularis* infection. **A.** Time post-infection of detection of infection by each technique. Boldfaced techniques are those most widely used in veterinary diagnostic laboratories globally. dpi = days post-infection. **B.** Graphic representation of the course of *L. intracellularis* infection, clinical signs, immune reaction, and adaptive immune response. Solid blue line = clinical signs with interventions. Dashed blue line = clinical signs without interventions. Orange line = IFN- $\gamma$  detection. Solid black line = fecal shedding detection without interventions. Dotted black line = fecal shedding detection with interventions. Green line = total antibody response.

double-layered envelope (diderm).<sup>12</sup> By confirming the localization of the bacterium within the intestinal crypt cells, the WS stain is a cost-effective, often frontline, method for

confirming *L. intracellularis* infection. The WS stain is readily available in most veterinary diagnostic laboratories.<sup>12,41</sup> However, the disadvantages of the WS stain include low

**Table 1.** Histochemical and immune-based tests used in the diagnosis of proliferative enteropathy.

Assay	Clinical samples tested	Comments	Reference
WS staining	Tissue	Fails to distinguish <i>Lawsonia intracellularis</i> from <i>Spirochaetes</i> , <i>Campylobacter</i> spp., or other curved rods	Warthin and Starry <sup>110</sup>
IHC	Tissue, fecal smear	Nonspecific, stains several surface proteins	McOrist et al. <sup>73</sup>
	Tissue	Specific against outer membrane antigen	Guedes and Gebhart <sup>32</sup>
Ag ELISA	Tissue	Specific against <i>L. intracellularis</i> surface antigen (LsaA)	McCluskey et al. <sup>70</sup>
	Tissue	Colorimetric reaction; not specific; no longer commercially available	Lebret et al. <sup>61</sup>
IF	Serum	IgG anti LI-N343	Collins et al. <sup>16</sup>
ELISA	Serum	Svanovir <i>L. intracellularis</i> /Ileitis-Ab	Jacobson et al. <sup>44</sup>

Ag = antigen; IF = immunofluorescence (IF) assay; WS = Warthin–Starry.

specificity (e.g., *L. intracellularis* cannot be distinguished from other curved bacilli, such as *Campylobacter* spp.), reproducibility, and repeatability.<sup>41</sup>

### Immunohistochemistry and immunofluorescence

Immunohistochemistry (IHC) and immunofluorescence (IF) are similar tests based on the same principle but using different labeling methods. IHC has been well-reviewed in the general veterinary literature.<sup>15,88,89</sup> IHC detection of *L. intracellularis* antigen is an established research and diagnostic tool.<sup>53,101</sup> The test result can be visualized using a chromogen, most commonly 3,3'-diaminobenzidine, which serves as a substrate for the catalyst horseradish peroxidase. In practice, IHC applies mainly to formalin-fixed, paraffin-embedded tissue. The IF test, which uses a fluorescent label, is less applicable to routine use given the requirement for fluorescence microscopy.<sup>22,88</sup>

IHC was first described for use in PE in 1987, several years before the organism was classified and accepted as a novel genus and species.<sup>73</sup> Specifically, *L. intracellularis* bacteria (“*Campylobacter*-like organisms”) were detected in the intestinal mucosa and fecal smears from infected pigs and hamsters using a mouse monoclonal antibody (mAb) generated by immunizing mice with *L. intracellularis* that had originated from pigs with acute PE. This approach has subsequently formed the basis of what is now a commonly used technique for PE diagnosis; over the years, other groups have generated their own mAbs (Table 1).<sup>32,73</sup> These antibodies can be used to detect organisms in fecal smears, and in formalin-fixed and fresh-frozen tissues, with the major benefit that they facilitate co-location of causative organisms and lesions in tissues. In 2005, a new mAb (Law-1-DK) was developed against a 21-kDa molecule that was resistant to proteinase K digestion, suggesting a non-protein target.<sup>8</sup> This antibody has since been used to detect *L. intracellularis* in feces and infected tissues, and there is also a commercial mAb (Moab a-*Lawsonia intracellularis*; Bio-X Diagnostics)

that improves the accessibility of the technique for diagnostic laboratories.<sup>8,45</sup>

IHC and IF methods have proven to be the most reliable tests for the postmortem diagnosis of PE.<sup>13,41,45,49,56</sup> One study using ileal samples from slaughterhouse pigs reported IF sensitivity of 89% and specificity of 97%, in addition to high agreement compared to PCR.<sup>36</sup> Similarly, another study comparing IHC with Warthin–Starry silver and routine hematoxylin and eosin staining concluded that IHC was superior to both and an excellent test overall, with a sensitivity of almost 87% when compared to PCR, the gold standard in that study.<sup>36</sup> Disadvantages of these antibody-based techniques are that they require specialized equipment and appropriately trained staff to analyze and interpret, contributing further to costs. However, the main advantage of both IF and IHC over PCR is that they can confirm the presence of *Lawsonia* within histologic lesions.

### In situ hybridization

In situ hybridization (ISH) using *L. intracellularis*-specific oligonucleotide probes allows a comparable, if more expensive, approach to IHC,<sup>45</sup> and can be used on fixed tissue samples from infected pigs, similar to IHC. However, one study also found that fluorescent ISH (FISH) was more vulnerable to the effects of autolysis compared to IF when testing formalin-fixed porcine intestinal tissue samples, effectively reducing assay sensitivity.<sup>45</sup> Similarly to IHC, ISH requires specialized equipment and technical knowledge. Nonetheless, both IHC and ISH techniques are considered gold standards in the diagnosis of PE.<sup>45</sup>

### Detection of antibodies against *L. intracellularis*

As noted previously, IgG and IgM antibodies against *L. intracellularis* can be detected from ~14 dpi (Fig. 2B), and IgG has been shown to persist for at least 13 wk post-infection.<sup>31</sup> Demonstration of antibodies against *L. intracellularis* can be interpreted in 3 ways: 1) pigs are actively infected and have

developed a humoral immune response; 2) pigs have received antibodies passively through colostrum; and 3) pigs were vaccinated against *L. intracellularis*. Any combination of these 3 scenarios is also possible, so meaningful interpretation of serology results can be difficult unless samples are compared over time or are collected in a cross-sectional manner from different age groups. To date, serum is the most commonly used sample type, and the only commercial kit (Svanovir *L. intracellularis*/Ileitis-Ab; Boehringer Ingelheim Svanova) that detects total immunoglobulins without differentiation of IgA, IgM, or IgG.

## ELISA

Several ELISAs have been developed for the detection of *L. intracellularis* antibodies in serum.<sup>16,44,54,61</sup> Most are competitive ELISAs, the major advantage of which is their ability to selectively detect the antibody recognized by the plated antigen, even in crude or impure samples. To date, only one commercial kit is available (Svanovir *L. intracellularis*/Ileitis-Ab; Table 1).<sup>44,109</sup> This test is unable to quantify the response against *L. intracellularis*, and sensitivity may vary depending on the value of percent inhibition (PI) selected; at PI = 35, the test sensitivity is 72% and the specificity reaches 93%.<sup>44</sup> *Lawsonia*-specific serum antibody responses, IgG and IgM, can be detected in serum 2 wk after infection (Fig. 2B); they peak at 3–4 wk and remain detectable for up to 13 wk post-infection.<sup>31,82</sup>

## Indirect fluorescent antibody test

The indirect fluorescent antibody test (IFAT) was first described for the detection of IgG antibodies in serum of pigs exposed to *L. intracellularis*.<sup>32,59</sup> Briefly, serum samples are applied to a plate to which *L. intracellularis*-infected McCoy cells have been fixed. Following incubation and a series of washes, a detection antibody labeled with a fluorophore is added to the plate. Serial dilutions of serum samples are used to determine the concentration of antibodies directed against *L. intracellularis*. One disadvantage of IFAT is the need for a specialized fluorescence microscope. Furthermore, the generation of infected culture monolayers in slides for the test can require 5–7 d.<sup>58</sup> The principal advantage of IFAT is that results are measured as titers, which can be considered semi-quantitative.

## Immunoperoxidase monolayer assay

The immunoperoxidase monolayer assay (IPMA) is similar to the IFAT except that a colorimetric change is produced by the breakdown of a chemical substrate by a peroxidase conjugated to the secondary antibody. The major advantage of IPMA is that the resulting brown stain, unlike a fluorescent label, can be evaluated using a more readily available light microscope. Another advantage is that the brown stain is

usually more stable and lasts longer than fluorescent stains, which fade over time and must be protected from light. The principal disadvantages of both IFAT and IPMA are nonspecific staining (IFAT more so than IPMA), low repeatability and reproducibility, and the highly subjective interpretation of results.<sup>34,36,61</sup> Although IPMA and IFAT are considered the most specific techniques for detection of *L. intracellularis* seroconversion compared to the commercial and other research ELISAs, IPMA and IFAT both require a source of infected cells.<sup>20,35,67</sup> Thus, there is the need to culture *L. intracellularis* in vitro, which remains one of the persistent challenges in PE research.<sup>20,35,56,67</sup> Another drawback is that these tests can only detect infection >21 dpi, long after the appearance of clinical signs and establishment of *L. intracellularis* shedding (Fig. 2B).<sup>31</sup>

## Molecular detection

Amplification techniques, such as standard PCR, real-time PCR, and loop-mediated isothermal amplification (LAMP), offer potentially rapid and sensitive ways to demonstrate the presence of *L. intracellularis* DNA or RNA in samples (Fig. 2A). The assays are commonly applied to fecal samples, rectal swabs, or intestinal samples (Table 2, Fig. 2).<sup>50,62,64,81,97,99,111</sup> Pigs experimentally infected with *L. intracellularis* are expected to show *L. intracellularis* shedding in feces by 7 dpi and may sustain shedding of the bacterium for up to 10 wk after infection (Fig. 2B).<sup>31,96</sup> The gene target commonly used is the 16S ribosomal DNA gene (16S rDNA),<sup>64</sup> although *aspA*<sup>99</sup> and *dnaA*<sup>111</sup> have also been used as markers for *L. intracellularis*.<sup>42,64,111</sup> Various primer pairs have been used for detection of *L. intracellularis* (Table 2). “In situ” amplification in tissue samples has also been reported and could potentially be a good candidate to substitute for tissue IHC.<sup>80</sup>

Molecular methods are capable of more rapid and accurate antemortem detection of *L. intracellularis* during the first stages of infection, but their reported sensitivities and specificities span a wide range.<sup>85,87</sup> Two innovative amplification assays have been developed for the detection of *L. intracellularis*. The first is a real-time LAMP assay that allows quantification of bacteria in a single 60-min reaction, targeting a conserved region of the 16S rDNA gene.<sup>62</sup> The second assay, initially described in early 2019, is a detection assay that combines an isothermal recombinase polymerase amplification of the *L. intracellularis dnaA* gene with the visual observation of the results using a lateral-flow dipstick containing streptavidin-coated colloidal gold.<sup>111</sup> These new approaches allow more rapid detection and could potentially be developed as point-of-care tests for use on-farm. Furthermore, a multiplex PCR has been used to simultaneously detect specific combinations of *L. intracellularis*, *B. hyodysenteriae*, *Mycoplasma* spp., and *Salmonella* serovars.<sup>23,78</sup>

Although some complex samples, such as feces, can contain contaminants that can inhibit amplification,<sup>52,79</sup> this can

**Table 2.** Reported PCR techniques used to detect *Lawsonia intracellularis* DNA.

PCR type	Primers	Target gene	Sensitivity/limit of detection	Clinical samples tested (n)	Reference
Conventional	F: 5'-CAGCACTTGCAAACAATAAACT-3'	<i>aspA</i>	94.1%	Feces (18)	Suh et al. <sup>99</sup>
	R: 5'-TTTCCTTTCTCATGTCCCATAA-3'		88.2%		
Conventional and nested	F: 5'-GATGAAAGCCTGCTGCACGGA-3'	<i>ubiE</i>	97.3%	Feces (150)	Nathues et al. <sup>81</sup>
	R: 5'-GTCTTGTGAAGCTATGGAACCTG-3'				
Conventional and nested	F: 5'-TATGGCTGTCAAACACTCCG-3'	<i>aspA</i>	10 <sup>3</sup> –10 <sup>4</sup> LI/g	Feces and mucosal scraps (18)	Jones et al. <sup>51</sup>
	R: 5'-TGAAGGTATTGGTATTCTCC-3'				
	NF: 5'-TTACAGGTGAAGTTATTGGG-3'				
	NR: 5'-CTTTCTCATGTCCCATAAAGC-3'				
Real-time PCR	F: 5'-GCGCGCGTAGGTGGTTATAT-3'	16S		Feces (204)	Lindecrona et al. <sup>64</sup>
	R: 5'-GCCACCCTCTCCGATACTCA-3'				
Real-time PCR	F: 5'-GCGCGCGTAGGTGGTTAT-3'	16S	10 <sup>2</sup> LI/g	Feces (113)	Ståhl et al. <sup>97</sup>
	R: 5'-GCCACCCTCTCCGATACTCA-3'				
RPA-LFD assay	F: 5'-AAATCCAAAAGTCGA GTATCTAACTGCGG-3'	<i>dnaA</i>	10 <sup>4</sup> LI/g	Feces (150)	Wu et al. <sup>111</sup>
Real-time LAMP assay	R: 5'-TAAAAACCCAGAGCAAAATCGTGATACCAGGCG-3'				
	FIP: 5'-GCATTCACCCGAGCATGCTGA-AGTCTGCAAC-3'	16S	10 <sup>1</sup> pg/sample	Feces (136)	Li et al. <sup>62</sup>
	(F1c-F2): 5'-TCGACTCCAT-3'				
	F3: 5'-GCATCTCAGTCCGGATTGG-3'				
	B3: 5'-CTTGTTACGACTTCACCCCA-3'				
	BIP: 5'-GTACACACCGCCCGTCACAC-3'				
(B1c-B2): 5'-GTAGACGACTGCCTCGATTG-3'					

LAMP = loop-mediated isothermal amplification; RPA-LFD = recombinase polymerase amplification–lateral-flow dipstick.

be overcome with careful selection of extraction methods. Indeed, nucleic acid extraction is a critical step to allow the advantages of amplification techniques to be brought to “farm-side” use. New opportunities are emerging and driving the development of innovative techniques for better on-site testing. One example is the use of a cellulose-based filter paper that retains nucleic acids.<sup>69,113</sup> This allows quick and clean on-site nucleic acid purification for amplification methods, such as the ones mentioned above. The next step for a truly on-farm amplification process will be the use of portable amplification systems. During 2020, the improvement in biosensor technology has made this type of system emerge and improve significantly.<sup>38,47,63</sup>

Although these devices will become useful for field veterinarians, there is still a need to improve the systems by better dealing with the various environmental conditions that swine veterinarians encounter in the field, such as highly variable temperatures, moisture, dust, biosecurity issues, availability of suitable facilities, sample processing, or the overall processing time from sample collection to result reading. Aside from the well-recognized and previously mentioned disadvantages of PCR, another issue is the inability to differentiate pathogenic strains of *L. intracellularis* from the live attenuated vaccine strain (Enterisol Ileitis; Boehringer Ingelheim Vetmedica). No such test is yet available, but comparative genomic studies may help define robust differences that can be exploited. Laboratory methods that can differentiate infected from vaccinated animals (DIVA) have been developed for other swine pathogens, such as pseudorabies virus (*Suid alphaherpesvirus 1*), classical swine fever virus (*Pestivirus C*), foot-and-mouth disease

virus, and *Salmonella*.<sup>5,102,104</sup> Some of these methods target specific markers that are added to vaccine formulations at the time of manufacture, ensuring a route for distinguishing vaccinated from naturally infected animals by serology.<sup>1,71</sup> To date, there are no markers in commercial *L. intracellularis* vaccines, but the design of an amplification method based on the genomic differences between the Boehringer Ingelheim Vetmedica vaccine and wild-type strains would be an interesting approach for the development of a *L. intracellularis* DIVA method.

## Summary

*L. intracellularis* remains an important bacterial pathogen in pigs, and PE remains a challenge to diagnose. At a practical level, diagnosis is tightly associated with the possible interventions available for the infection, with antimicrobial treatments used and a commercial vaccine available. Nevertheless, given that the impact of *L. intracellularis* infection varies widely in countries and between farms, it would not necessarily be beneficial to target *L. intracellularis* by blanket use of vaccines. In addition, the global drive toward reducing antimicrobial use will also deter prophylactic use of antibiotics for this infection. Hence, accurate diagnosis of PE remains important to rule out other infections with similar gross presentations and to enable appropriate advice on vaccination and antimicrobial treatment to be given, especially when more serious outbreaks occur.

Histochemical, IHC, and ISH techniques are invaluable for confirming *L. intracellularis* infections, but these require tissue samples at postmortem, extended time to process the



samples, and require specialist skills to interpret the results. In turn, this makes diagnosis exclusive to a limited number of veterinary practices and diagnostic and research centers. By comparison, both serologic and pathogen detection assays can indicate past or current presence of the bacteria, respectively. However, they cannot be used unambiguously to define the etiology of the intestinal disease. Serologic assays for *L. intracellularis* are therefore applied mainly to measure the impact of vaccination treatments, determine when infection takes place, and examine prevalence.<sup>39,103</sup>

Although our review demonstrates that good progress is being made on ways to identify *L. intracellularis* infection antemortem, with the potential for the development of pen-side tests, we still need to understand the interactions that lead to the different clinical presentations in pigs so that diagnosis can quickly predict the likelihood and severity of an outbreak and appropriate action can be taken swiftly. Thus, we highlight the need to develop tools to improve the diagnosis of *L. intracellularis* disease, in relation to pathogen load and the immune response of the pig, as well as improve measurement of the efficacy of disease control actions on farms.

### Acknowledgments

We thank Stephen Fitzgerald, Petra Maass, and Lysan Eppink for suggestions and critical review of the manuscript draft. We also acknowledge Linda Morrison (Easter Bush Pathology, University of Edinburgh) for providing panels A and B of Figure 1.

### Declaration of conflicting interests

The authors declared no potential conflicts of interest with respect to the research, authorship, and/or publication of this article.

### Funding

Funding was provided by Biological Sciences Research Council (BBSRC)–Boehringer Ingelheim Training grant, Industrial CASE CVS (BB/P505006/1). Additional support was received through the BBSRC Institute Strategic Programme Grant awarded to the Roslin Institute (BB/P013740/1; BBS/E/D/20002174).

### ORCID iD

Marta Campillo  <https://orcid.org/0000-0002-2561-5429>

### References

- Avellaneda G, et al. Differentiation of infected and vaccinated animals (DIVA) using the NS1 protein of avian influenza virus. *Avian Dis* 2010;54:278–286.
- Bae JK, et al. Risk factors associated with *Lawsonia intracellularis* in English pig farms. *Vet J* 2013;197:707–711.
- Baro J, et al. Porcine circovirus type 2 (PCV2) enteric disease: an independent condition or part of the systemic disease? *Vet Microbiol* 2015;176:83–87.
- Barrera-Zarate JA, et al. Oral fluid for detection of exposure to *Lawsonia intracellularis* in naturally infected pigs. *Vet J* 2019;244:34–36.
- Bearson BL, et al. *Salmonella* DIVA vaccine reduces disease, colonization and shedding due to virulent *S. Typhimurium* infection in swine. *J Med Microbiol* 2017;66:651–661.
- Bengtsson RJ, et al. *Lawsonia intracellularis* infection of intestinal crypt cells is associated with specific depletion of secreted MUC2 in goblet cells. *Vet Immunol Immunopathol* 2015;168:61–67.
- Biestler HE, et al. Intestinal adenoma in swine. *Am J Pathol* 1931;7:175–185.
- Boesen HT, et al. Development, characterization and diagnostic application of a monoclonal antibody specific for a proteinase K resistant *Lawsonia intracellularis* antigen. *Vet Microbiol* 2005;105:199–206.
- Borewicz KA, et al. Changes in the porcine intestinal microbiome in response to infection with *Salmonella enterica* and *Lawsonia intracellularis*. *PLoS One* 2015;10:e0139106.
- Boutrup TS, et al. Early pathogenesis in porcine proliferative enteropathy caused by *Lawsonia intracellularis*. *J Comp Pathol* 2010;143:101–109.
- Brandt D, et al. Evaluation of *Lawsonia intracellularis* infection in a group of pigs in a subclinically affected herd from weaning to slaughter. *Vet Microbiol* 2010;146:361–365.
- Bridges CH, Luna L. Kerr's improved Warthin-Starry technique; study of the permissible variations. *Lab Invest* 1957;6:357–367.
- Burrough ER, et al. Correlation of *Lawsonia intracellularis* semi-quantitative fecal polymerase chain reaction assay results with the presence of histologic lesions of proliferative enteropathy and positive immunohistochemical staining. *J Swine Health Prod* 2015;23:204–207.
- Chase-Topping ME, et al. Feed-associated colitis of growing pigs and its interaction with enteric infections. *Acta Sci Vet* 2009;37(Suppl 1):S1–S9.
- Chen X, et al. Double staining immunohistochemistry. *N Am J Med Sci* 2010;2:241–245.
- Collins A, et al. Comparison of a commercial ELISA with an indirect fluorescent antibody test to detect antibodies to *Lawsonia intracellularis* in experimentally challenged pigs. *Aust Vet J* 2012;90:97–99.
- Collins AM. Advances in ileitis control, diagnosis, epidemiology and the economic impacts of disease in commercial pig herds. *Agriculture* 2013;3:536–555.
- Cooper DM, et al. Diagnosis of proliferative enteritis in frozen and formalin-fixed, paraffin-embedded tissues from a hamster, horse, deer and ostrich using a *Lawsonia intracellularis*-specific multiplex PCR assay. *Vet Microbiol* 1997;54:47–62.
- Cordes H, et al. Cell-mediated and humoral immune responses in pigs following primary and challenge-exposure to *Lawsonia intracellularis*. *Vet Res* 2012;43:9–20.
- Corzo CA, et al. Comparison of 2 serologic tests for the diagnosis of porcine proliferative enteropathy. *Can J Vet Res* 2005;46:433–435.
- Dodd DC. Adenomatous intestinal hyperplasia (proliferative ileitis) of swine. *Pathol Vet* 1968;5:333–341.
- Donaldson JG. Immunofluorescence staining. *Curr Protoc Cell Biol* 2001;Chapter 4:Unit 4.3.
- Elder RO, et al. Multiplex polymerase chain reaction for simultaneous detection of *Lawsonia intracellularis*, *Serpulina hyodysenteriae*, and salmonellae in porcine intestinal specimens. *J Vet Diagn Invest* 1997;9:281–286.



24. Field HI, et al. Terminal or regional ileitis in pigs. *J Comp Pathol* 1953;63:153–160.
25. Fossum C. Cytokines as markers for infections and their effect on growth performance and well-being in the pig. *Domest Anim Endocrinol* 1998;15:439–444.
26. Gebhart CJ, et al. Ileal symbiont intracellularis, an obligate intracellular bacterium of porcine intestines showing a relationship to *Desulfovibrio* species. *Int J Syst Bacteriol* 1993;43:533–538.
27. Giuliano C, et al. A guide to bacterial culture identification and results interpretation. *Pharm Ther* 2019;44:192–200.
28. Go YY, et al. Experimental reproduction of proliferative enteropathy and the role of IFN-gamma in protective immunity against *Lawsonia intracellularis* in mice. *J Vet Sci* 2005;6:357–359.
29. Gogolewski RP, et al. Suboptimal growth associated with porcine intestinal adenomatosis in pigs in nutritional studies. *Aust Vet J* 1991;68:406–408.
30. Guedes RMC, Gebhart CJ. Evidence of cell-mediated immune response and specific local mucosal immunoglobulin (Ig) A production against *Lawsonia intracellularis* in experimentally infected swine. *Can J Vet Res* 2010;74:97–101.
31. Guedes RMC, Gebhart CJ. Onset and duration of fecal shedding, cell-mediated and humoral immune responses in pigs after challenge with a pathogenic isolate or attenuated vaccine strain of *Lawsonia intracellularis*. *Vet Microbiol* 2003;91:135–145.
32. Guedes RMC, Gebhart CJ. Preparation and characterization of polyclonal and monoclonal antibodies against *Lawsonia intracellularis*. *J Vet Diagn Invest* 2003;15:438–446.
33. Guedes RMC, et al. Serologic follow-up of a repopulated swine herd after an outbreak of proliferative hemorrhagic enteropathy. *Can J Vet Res* 2002;66:258–263.
34. Guedes RMC, et al. Validation of an immunoperoxidase monolayer assay as a serologic test for porcine proliferative enteropathy. *J Vet Diagn Invest* 2002;14:528–530.
35. Guedes RMC, et al. A comparative study of an indirect fluorescent antibody test and an immunoperoxidase monolayer assay for the diagnosis of porcine proliferative enteropathy. *J Vet Diagn Invest* 2002;14:420–423.
36. Guedes RMC, et al. Comparison of different methods for diagnosis of porcine proliferative enteropathy. *Can J Vet Res* 2002;66:99–107.
37. Guedes RMC, et al. *Lawsonia intracellularis* in pigs: progression of lesions and involvement of apoptosis. *Vet Pathol* 2017;54:620–628.
38. He L, et al. Battery-powered portable rotary real-time fluorescent qPCR with low energy consumption, low cost, and high throughput. *Biosensors (Basel)* 2020;10:49.
39. Holyoake PK, et al. Prevalence of antibodies to *Lawsonia intracellularis* in pig herds in Australia. *Aust Vet J* 2010;88:186–188.
40. Holyoake PK, et al. Simulation of the economic impact of proliferative enteritis on pig production in Australia. *Aust Vet J* 1996;73:89–92.
41. Huerta B, et al. Comparison of diagnostic techniques for porcine proliferative enteropathy (*Lawsonia intracellularis* infection). *J Comp Pathol* 2003;129:179–185.
42. Hwang J, et al. *Lawsonia intracellularis* in the feces of wild rodents and stray cats captured around equine farms. *BMC Vet Res* 2017;13:233–233.
43. Jacobson M, et al. Porcine proliferative enteropathy: an important disease with questions remaining to be solved. *Vet J* 2010;184:264–268.
44. Jacobson M, et al. Evaluation of a blocking ELISA for the detection of antibodies against *Lawsonia intracellularis* in pig sera. *Acta Vet Scand* 2011;53:23–29.
45. Jensen TK, et al. Detection of *Lawsonia intracellularis* in formalin-fixed porcine intestinal tissue samples: comparison of immunofluorescence and in-situ hybridization, and evaluation of the effects of controlled autolysis. *J Comp Pathol* 2010;142:1–8.
46. Jensen TK, et al. Distinction between porcine circovirus type 2 enteritis and porcine proliferative enteropathy caused by *Lawsonia intracellularis*. *J Comp Pathol* 2006;135:176–182.
47. Jie J, et al. Portable and battery-powered PCR device for DNA amplification and fluorescence detection. *Sensors* 2020;20:2627.
48. Joens LA, et al. Induction of gross and microscopic lesions of porcine proliferative enteritis by *Lawsonia intracellularis*. *Am J Vet Res* 1997;58:1125–1131.
49. Jones GF, et al. Comparison of techniques for diagnosis of proliferative enteritis of swine. *Am J Vet Res* 1993;54:1980–1985.
50. Jones GF, et al. Use of a DNA probe to detect the intracellular organism of proliferative enteritis in swine feces. *Am J Vet Res* 1993;54:1585–1590.
51. Jones GF, et al. Enhanced detection of intracellular organism of swine proliferative enteritis, ileal symbiont intracellularis, in feces by polymerase chain reaction. *J Clin Microbiol* 1993;31:2611–2615.
52. Khan G, et al. Inhibitory effects of urine on the polymerase chain reaction for cytomegalovirus DNA. *J Clin Pathol* 1991;44:360–365.
53. Kim J, et al. Immunohistochemistry and polymerase chain reaction for the detection of *Lawsonia intracellularis* in porcine intestinal tissues with proliferative enteropathy. *J Vet Med Sci* 2000;62:771–773.
54. Kroll JJ, et al. Lipopolysaccharide-based enzyme-linked immunosorbent assay for experimental use in detection of antibodies to *Lawsonia intracellularis* in pigs. *Clin Diagn Lab Immunol* 2005;12:693–699.
55. Kroll JJ, et al. Proliferative enteropathy: a global enteric disease of pigs caused by *Lawsonia intracellularis*. *Anim Health Res Rev* 2005;6:173–197.
56. Ladinig A, et al. Comparative evaluation of diagnostic methods for *Lawsonia intracellularis* infection in pigs, with emphasis on cases lacking characteristic lesions. *J Comp Pathol* 2009;140:140–148.
57. Lawson GH, Gebhart CJ. Proliferative enteropathy. *J Comp Pathol* 2000;122:77–100.
58. Lawson GH, et al. Intracellular bacteria of porcine proliferative enteropathy: cultivation and maintenance in vitro. *J Clin Microbiol* 1993;31:1136–1142.
59. Lawson GH, et al. Serological diagnosis of the porcine proliferative enteropathies: implications for aetiology and epidemiology. *Vet Rec* 1988;122:554–557.

60. Lawson GH, et al. Proliferative haemorrhagic enteropathy. *Res Vet Sci* 1979;27:46–51.
61. Lebret A, et al. Longitudinal evaluation of three commercial diagnostic assays for *Lawsonia intracellularis* infection in pigs. *Vet Rec* 2013;172:341–343.
62. Li Y, et al. A real-time loop-mediated isothermal amplification method for rapid detection of *Lawsonia intracellularis* in porcine fecal samples. *J Microbiol Methods* 2018;151:62–65.
63. Lim J, et al. Battery-operated portable PCR system with enhanced stability of Pt RTD. *PLoS One* 2019;14:e0218571.
64. Lindecrona RH, et al. Application of a 5' nuclease assay for detection of *Lawsonia intracellularis* in fecal samples from pigs. *J Clin Microbiol* 2002;40:984–987.
65. Love DN, et al. Pathology of proliferative haemorrhagic enteropathy. *Vet Pathol* 1979;16:41–48.
66. MacIntyre N, et al. Immunopathogenesis of experimentally induced proliferative enteropathy in pigs. *Vet Pathol* 2003;40:421–432.
67. Magtoto RL, et al. Evaluation and use of a serological assay for the detection of antibodies to *Lawsonia intracellularis* in swine. *Int J Vet Sci Med* 2014;2:109–113.
68. Mair KH, et al. The porcine innate immune system: an update. *Dev Comp Immunol* 2014;45:321–343.
69. Mason MG, et al. An easy-to-perform, culture-free *Campylobacter* point-of-management assay for processing plant applications. *J Appl Microbiol* 2020;128:620–629.
70. McCluskey J, et al. LsaA, an antigen involved in cell attachment and invasion, is expressed by *Lawsonia intracellularis* during infection in vitro and in vivo. *Infect Immun* 2002;70:2899–2907.
71. McElroy AK, et al. Development of a RVFV ELISA that can distinguish infected from vaccinated animals. *Virology* 2009;6:125.
72. McOrist S. Defining the full costs of endemic porcine proliferative enteropathy. *Vet J* 2005;170:8–9.
73. McOrist S, et al. Monoclonal antibodies to intracellular campylobacter-like organisms of the porcine proliferative enteropathies. *Vet Rec* 1987;121:421–422.
74. McOrist S, et al. Porcine proliferative enteropathies. In: Straw BE, et al., eds. *Diseases of Swine*. 8th ed. Iowa State University Press, 1999:521–534.
75. McOrist S, et al. Immunocytological responses in porcine proliferative enteropathies. *Infect Immun* 1992;60:4184–4191.
76. McOrist S, et al. Developed and resolving lesions in porcine proliferative enteropathy: possible pathogenetic mechanisms. *J Comp Pathol* 1996;115:35–45.
77. McOrist S, et al. Estimate of direct financial losses due to porcine proliferative enteropathy. *Vet Rec* 1997;140:579–581.
78. Moller K, et al. Detection of *Lawsonia intracellularis*, *Serpulina hyodysenteriae*, weakly beta-haemolytic intestinal spirochaetes, *Salmonella enterica*, and haemolytic *Escherichia coli* from swine herds with and without diarrhoea among growing pigs. *Vet Microbiol* 1998;62:59–72.
79. Monteiro L, et al. Complex polysaccharides as PCR inhibitors in feces: *Helicobacter pylori* model. *J Clin Microbiol* 1997;35:995–998.
80. Nathues H, grosse Beilage E. Diagnosis of *Lawsonia intracellularis* infection in pigs after vaccination or antimicrobial treatment. *Dtsch Tierarztl Wochenschr* 2008;115:404–409.
81. Nathues H, et al. Quantification of *Lawsonia intracellularis* in porcine faeces by real-time PCR. *J Appl Microbiol* 2009;107:2009–2016.
82. Nogueira MG, et al. Immunological responses to vaccination following experimental *Lawsonia intracellularis* virulent challenge in pigs. *Vet Microbiol* 2013;164:131–138.
83. Obradovic MR, et al. Immune response and protection against *Lawsonia intracellularis* infections in pigs. *Vet Immunol Immunopathol* 2020;219:109959.
84. Paradis MA, et al. Subclinical ileitis: diagnostic and performance parameters in a multi-dose mucosal homogenate challenge model. *J Swine Health Prod* 2012;20:137–141.
85. Pedersen KS, et al. Diagnostic performance of different fecal *Lawsonia intracellularis*-specific polymerase chain reaction assays as diagnostic tests for proliferative enteropathy in pigs: a review. *J Vet Diagn Invest* 2010;22:487–494.
86. Pedersen KS, et al. Demonstration of non-specific colitis and increased crypt depth in colon of weaned pigs with diarrhea. *Vet Q* 2012;32:45–49.
87. Pedersen KS, et al. Association between faecal load of *Lawsonia intracellularis* and pathological findings of proliferative enteropathy in pigs with diarrhoea. *BMC Vet Res* 2012;8:198.
88. Ramos-Vara JA. Technical aspects of immunohistochemistry. *Vet Pathol* 2005;42:405–426.
89. Ramos-Vara JA, et al. Suggested guidelines for immunohistochemical techniques in veterinary diagnostic laboratories. *J Vet Diagn Invest* 2008;20:393–413.
90. Resende TP, et al. Serological profile, seroprevalence and risk factors related to *Lawsonia intracellularis* infection in swine herds from Minas Gerais State, Brazil. *BMC Vet Res* 2015;11:306.
91. Riber U, et al. Vaccination of pigs with attenuated *Lawsonia intracellularis* induced acute phase protein responses and primed cell-mediated immunity without reduction in bacterial shedding after challenge. *Vaccine* 2015;33:156–162.
92. Rowland AC, et al. Intestinal adenomatosis in the pig: occurrence of a bacterium in affected cells. *Nature* 1973;243:417.
93. Rowland AC, Rowntree PG. A haemorrhagic bowel syndrome associated with intestinal adenomatosis in the pig. *Vet Rec* 1972;91:235–241.
94. Rowland ACL, Lawson GHK. Porcine proliferative enteropathies. In: Leman AP, et al., eds. *Diseases of Swine*. 7th ed. Iowa State University Press, 1992:560–569.
95. Smith DG, et al. Gamma interferon influences intestinal epithelial hyperplasia caused by *Lawsonia intracellularis* infection in mice. *Infect Immun* 2000;68:6737–6743.
96. Smith SH, McOrist S. Development of persistent intestinal infection and excretion of *Lawsonia intracellularis* by piglets. *Res Vet Sci* 1997;62:6–10.
97. Ståhl M, et al. The use of quantitative PCR for identification and quantification of *Brachyspira pilosicoli*, *Lawsonia intracellularis* and *Escherichia coli* fimbrial types F4 and F18 in pig feces. *Vet Microbiol* 2011;151:307–314.
98. Stege H, et al. Infection dynamics of *Lawsonia intracellularis* in pig herds. *Vet Microbiol* 2004;104:197–206.
99. Suh DK, et al. Detection of *Lawsonia intracellularis* in diagnostic specimens by one-step PCR. *J Vet Sci* 2000;1:33–37.

100. Suh DK, Song JC. Prevalence of *Lawsonia intracellularis*, *Brachyspira hyodysenteriae* and *Salmonella* in swine herds. *J Vet Sci* 2005;6:289–293.
101. Szczotka A, et al. Immunohistochemical detection of *Lawsonia intracellularis* in tissue sections from pigs. *Pol J Vet Sci* 2011;14:531–538.
102. Uttenthal A, et al. Strategies for differentiating infection in vaccinated animals (DIVA) for foot-and-mouth disease, classical swine fever and avian influenza. *Expert Rev Vaccines* 2010;9:73–87.
103. van der Heijden HM, et al. Prevalence of exposure and infection of *Lawsonia intracellularis* among slaughter-age pigs. *Res Vet Sci* 2004;77:197–202.
104. van Oirschot JT. DIVA vaccines that reduce virus transmission. *J Biotechnol* 1999;73:195–205.
105. Vannucci FA, et al. Laser microdissection coupled with RNA-seq analysis of porcine enterocytes infected with an obligate intracellular pathogen (*Lawsonia intracellularis*). *BMC Genomics* 2013;14:421.
106. Vannucci FA, Gebhart CJ. Recent advances in understanding the pathogenesis of *Lawsonia intracellularis* infections. *Vet Pathol* 2014;51:465–477.
107. Vannucci FA, et al. Proliferative enteropathy. In: Zimmerman JJ, et al., eds. *Diseases of Swine*. 11th ed. Wiley, 2019: 898–911.
108. Vannucci FA, et al. An alternative method for cultivation of *Lawsonia intracellularis*. *J Clin Microbiol* 2012;50: 1070–1072.
109. Walter D, et al. Serologic profiling and vaccination timing for *Lawsonia intracellularis*. *J Swine Health Prod* 2004;12: 310–313.
110. Warthin AS, Starry AC. A more rapid and improved method of demonstrating spirochetes in tissues (Warthin and Starry's cover-glass method). *Am J Syph Gonorrhea Vener Dis* 1920;4:97–103.
111. Wu Y, et al. Rapid and visual detection of *Lawsonia intracellularis* with an improved recombinase polymerase amplification assay combined with a lateral flow dipstick. *BMC Vet Res* 2019;15:97.
112. Yeh J-Y, Ga A-R. Systemic cytokine response in pigs infected orally with a *Lawsonia intracellularis* isolate of South Korean origin. *J Vet Med Sci* 2018;80:13–19.
113. Zou Y, et al. Nucleic acid purification from plants, animals and microbes in under 30 seconds. *PLoS Biol* 2017;15:e2003916.