

Pericardial Effusion

The **pericardium** is a thin sac that surrounds the heart and the large blood vessels closely associated with the heart. The pericardium has an inner and an outer layer with a small amount of lubricating fluid between them. **Pericarditis** is a condition in which the pericardium becomes **inflamed** (increased blood flow and a protective cell response due to injury). With pericarditis, the amount of fluid increases within the pericardial layers, squeezes the heart, and can restrict the motion of the heart. This is called a **pericardial effusion**. If the onset is rapid or if the volume of the pericardial effusion is large, **cardiac tamponade** can occur. Cardiac tamponade diminishes the force of heart contractions because of compression by the fluid trapped within the pericardial space. Among individuals with a pericardial effusion, 7% to 10% are at risk of developing a cardiac tamponade. The April 25, 2007, issue of JAMA includes an article that discusses the accuracy of the medical history, physical examination, and basic diagnostic tests for the diagnosis of cardiac tamponade.

CAUSES OF PERICARDIAL EFFUSION

- **Idiopathic** (cause is uncertain)
- Infection—bacterial, viral, fungal, or parasitic organisms
- Trauma
- **Hemorrhage** (bleeding) into pericardial space due to chest trauma, heart attack, aortic rupture, or cardiac bypass surgery
- Cancer
- Radiation therapy
- Kidney failure
- Autoimmune disorders (hypothyroidism, inflammatory bowel disease, rheumatoid arthritis)

SIGNS AND SYMPTOMS OF CARDIAC TAMPONADE

- **Dyspnea** (difficulty breathing)
- Chest pain
- **Tachycardia** (abnormally rapid heart rate)
- **Jugular vein distention** (enlargement of the neck veins due to increased pressure in the heart)
- **Pulsus paradoxus** (marked decrease in pulse and blood pressure during inhalation)

DIAGNOSTIC TESTS FOR CARDIAC TAMPONADE

- Medical history
- Physical examination
- Electrocardiogram (assessment of electrical activity of the heart)
- Chest x-ray (identify enlargement of the heart)
- **Echocardiography**—use of sound waves to assess the heart size and to identify a pericardial effusion.

TREATMENT

Most cases can be managed with a combination of drugs. Surgery may be required if the constriction of the heart is severe or persisting.

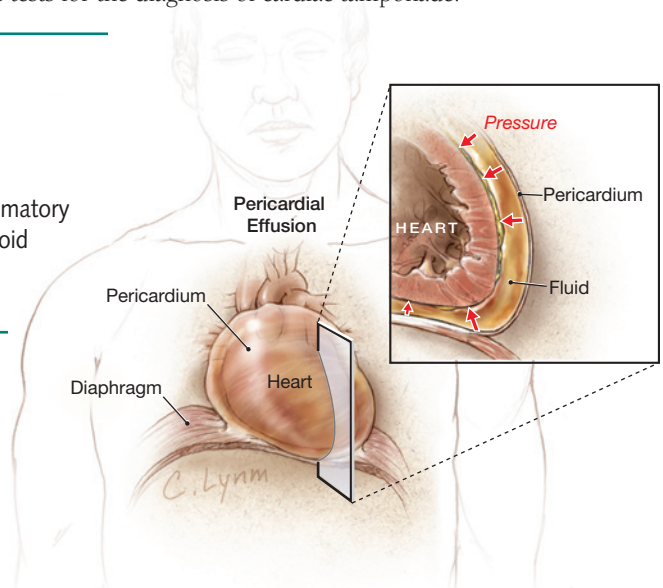
- Drugs (anti-inflammatory drugs, corticosteroids, colchicine, diuretics)
- **Pericardiocentesis** (an aspiration needle is inserted through the skin into the pericardial sac and fluid is removed)
- **Pericardectomy** (a surgical procedure to remove a portion of the pericardial sac)

John L. Zeller, MD, PhD, Writer

Cassio Lynn, MA, Illustrator

Richard M. Glass, MD, Editor

The JAMA Patient Page is a public service of JAMA. The information and recommendations appearing on this page are appropriate in most instances, but they are not a substitute for medical diagnosis. For specific information concerning your personal medical condition, JAMA suggests that you consult your physician. This page may be photocopied noncommercially by physicians and other health care professionals to share with patients. To purchase bulk reprints, call 203/259-8724.



FOR MORE INFORMATION

- American Heart Association
www.americanheart.org
- American College of Cardiology
www.acc.org

INFORM YOURSELF

To find this and previous JAMA Patient Pages, go to the Patient Page link on JAMA's Web site at www.jama.com. Many are available in English and Spanish.

Sources: American Heart Association, American College of Cardiology

