

## Treatment of achalasia: lessons learned with Chagas' disease

F. A. M. Herbella,<sup>1</sup> J. L. B. Aquino,<sup>2</sup> S. Stefani-Nakano,<sup>3</sup> E. L. A. Artifon,<sup>4</sup> P. Sakai,<sup>4</sup> E. Crema,<sup>5</sup>  
N. A. Andreollo,<sup>6</sup> L. R. Lopes,<sup>6</sup> C. de Castro Pochini,<sup>7</sup> P. R. Corsi,<sup>7</sup> D. Gagliardi,<sup>7</sup> J. C. Del Grande<sup>1</sup>

<sup>1</sup>Department of Surgery, Division of Esophagus and Stomach, Federal University of Sao Paulo, Sao Paulo;

<sup>2</sup>Department of Surgery, School of Medicine, Catholic University, Campinas; <sup>3</sup>Santa Casa de Goiânia,

Goiânia; <sup>4</sup>Department of Surgery, Gastrointestinal Endoscopy Unit, University of Sao Paulo Medical School,

Sao Paulo; <sup>5</sup>Department of Surgery, Universidade Federal do Triângulo Mineiro, Uberaba, MG; <sup>6</sup>Department  
of Surgery, Division of Esophagus and Stomach and Gastrocentro, State University of Campinas, Campinas;

<sup>7</sup>Department of Surgery, Santa Casa de Sao Paulo Medical School, Sao Paulo, Brazil

**SUMMARY.** Chagas' disease (CD) is highly prevalent in South America. Brazilian surgeons and gastroenterologists gained valuable experience in the treatment of CD esophagopathy (chagasic achalasia) due to the high number of cases treated. The authors reviewed the lessons learned with the treatment of achalasia by different centers experienced in the treatment of Chagas' disease. Preoperative evaluation, endoscopic treatment (forceful dilatation and botulinum toxin injection), Heller's myotomy, esophagectomy, conservative techniques other than myotomy, and reoperations are discussed in the light of personal experiences and review of International and Brazilian literature. Aspects not frequently adopted by North American and European surgeons are emphasized. The review shows that nonadvanced achalasia is frequently treated by Heller's myotomy. Endoscopic treatment is reserved to limited cases. Treatment for end-stage achalasia is not unanimous. Esophagectomy was a popular treatment in advanced disease; however, the morbidity/mortality associated to the procedure made some authors seek different alternatives, such as Heller's myotomy and cardioplasties. Minimally invasive approach to esophageal resection may change this concept, although few centers perform the procedure routinely.

**KEY WORDS:** achalasia, Chagas' disease, esophagus, surgery.

### INTRODUCTION

Chagas' disease (CD) (American trypanosomiasis) is a common disease in South America. Although the incidence of CD is declining,<sup>1</sup> an impressive number of individuals still suffer from the disease.

CD esophagopathy (CDE) leads to slow esophageal emptying due to nonrelaxation of the lower esophageal sphincter, similar to idiopathic (primary) achalasia.<sup>2</sup>

This article reflects the lessons learned by different Brazilian centers highly experienced in the treatment of CDE. Different treatment options are discussed in the light of personal experiences and review of inter-

national and Brazilian literature. Aspects not frequently adopted by North American and European surgeons are emphasized.

### Chagas' disease

Carlos Chagas' work is unique in the history of medicine – it is the only instance in which a single investigator has described the infection, agent, vector, manifestations, epidemiology and some of the hosts of a pathogenic parasite. Only a year after Chagas' paper was published, a committee of Brazilian medical experts suggested the name CD for American trypanosomiasis.<sup>3</sup>

CD has a wide distribution in Central and South America. It is endemic in 21 countries, with 16–18 million persons infected and 100 million people at risk. It is locally transmitted in Argentina, Belize, Bolivia, Brazil, Colombia, Costa Rica, Ecuador, El Salvador, French Guiana, Guatemala, Guyana, Honduras, Mexico, Nicaragua, Panama, Paraguay,

Address correspondence to: Dr Fernando A. M. Herbella, Division of Esophagus and Stomach, Federal University of Sao Paulo, Rua Napoleao de Barros, 715 2o. andar, Sao Paulo, Brazil 04024-002. Email: herbella.dcir@unifesp.epm.br  
Author's contribution: FAH: conception and design, writing of the final version of the manuscript. All authors: data collection, writing parts of the manuscript, approval of the final version of the manuscript.

Peru, Suriname, and Venezuela. It is sometimes transmitted in the United States as well.<sup>4,5</sup>

The disease is caused by *Trypanosoma cruzi*, a flagellated protozoan which is transmitted to humans by a blood-sucking insect which deposits its infective feces on the skin at the time of biting, or directly by transfusion of infected blood, which is rare nowadays. Humans and a large number of species of domestic and wild animals constitute the reservoir, and the vector insect infests poor housing and thatched roofs.<sup>4</sup>

Commonly, there are no acute clinical manifestations. In about one-third of infected cases, a chronic form develops some 10–20 years later, causing irreversible damage to the heart, esophagus and/or colon. Injury to these organs is characterized by: (i) dilated cardiomyopathy and conduction system abnormalities, most frequently right bundlebranch block or left anterior fascicular block; (ii) achalasia-like esophagopathy with marked esophageal dilatation; and (iii) megacolon, particularly of the sigmoid segment, usually complicated by fecal impaction or sigmoid volvulus.<sup>4,6</sup> The heart is the most commonly affected organ (60%). The colon and the esophagus are affected in approximately 20% of the cases, with 60% of the patients developing concomitant cardiopathy.<sup>6</sup>

There is neither vaccine nor recommended drug available to prevent Chagas' disease. Also specific treatment for the chronic phase of the disease is non-existent.

## TREATMENT OF CHAGAS' DISEASE ESOPHAGOPATHY IN BRAZIL

### Preoperative evaluation

Careful preoperative clinical evaluation is essential in patients with CDE. Most of the individuals are undernourished because of late presentation to medical care. A significant number of patients present with subclinical pulmonary complications of the disease due to chronic aspiration and a major operation may be anticipated. CD may affect, apart from the esophagus, the heart and the colon. For this reason, different from idiopathic achalasia, a cardiac and colonic workup is also necessary.

Barium esophagram is performed in all patients due to the fact that therapy may be guided based on the presence and grade of the esophageal dilatation.<sup>7</sup> Esophageal dilatation is a common feature of CDE, rendering the name megaesophagus, as it is known in Latin America. The esophagus is dilated in 70–100% of the patients with CDE, with massive dilatations (more than 10 cm) in 10–40% of the cases.<sup>2</sup> Timed-barium esophagram is not popular in Brazilian centers.

Upper digestive endoscopy is always performed to rule out malignancy or premalignant lesions of the esophagus and concomitant gastroduodenal disease.

Manometrically, there are no significant differences between CDE and achalasia.<sup>2</sup> In Brazil, esophageal manometry is not performed routinely other than for research or academic purposes. Exceptions to the rule are incipient cases without esophageal dilatation. Some authors; however, perform esophageal manometry routinely in order to define end-stage achalasia based on the presence of simultaneous waves with amplitudes lower than 20 mm Hg.<sup>8</sup>

### Endoscopic treatment

#### Dilatation

Endoscopic forceful balloon dilatation of the lower esophageal sphincter was traditionally indicated as the initial treatment for patients with absent or minimal dilatation of the esophagus. However, a shift to surgical treatment in these patients can be noticed in Brazil as well as in the United States.<sup>9</sup> At the present time, dilatation is rarely used as a primary and definitive treatment. Currently, indications for endoscopic dilatation include: (i) primary treatment in patients unfit or unwilling for surgery; (ii) recurrence of symptoms after myotomy; and (iii) preoperative as a mean to improve nutrition status before a major operation.<sup>10</sup>

Patients are kept on clear fluids for 3 days before the procedure. Cleansing of the esophagus with a large tube may be necessary at the day of the test as well.

Correct placement of the catheter may be challenging in a massive dilated esophagus. At the time of endoscopy, the esophagogastric junction is identified with the aid of air inflation. The endoscope is then advanced with counterclockwise rotation movements and its tip facing up, in an attempt to follow the curvature of the esophagus below the diaphragm. The stomach is accessed and a guide wire is left in place. The balloon is placed at the esophagogastric junction with the aid of the guide wire and fluoroscopy. Interestingly, some groups perform dilatation at the endoscopy suite without the aid of fluoroscopy. In these centers, the balloon is positioned based on the distance from the nares calculated during endoscopy. The correct position of the balloon is assured with direct visualization with the endoscope and the balloon insufflation is done under direct vision. These groups report similar results compared to fluoroscopy guidance. Esophageal perforation rate is also comparable.

Air insufflation is progressive. The balloon is inflated to 5 psi for 1 to 3 minutes and deflated. If the patient is able to tolerate the dilatation new cycles are initiated with 7 and 10 psi. If the patient is not able to tolerate the procedure it is discontinued even if incomplete in order to diminish the risk of esophageal perforation. The procedure is repeated in a latter appointment.

The esophagus and stomach are re-scoped following removal of the balloon. Mucosal tears are frequently observed and they are not clinically important. True perforations are characterized by longitudinal mucosal lacerations where the bottom of lesion is not visualized. Rarely, esophageal perforations are undetected by endoscopy. Less frequent complications associated to the procedure are aspiration, esophageal hematoma and bleeding.

After the dilatation, patients are kept fasting and observed for 4 hours due to the risk of perforation. Diet must be restricted to soft foods at the day of the dilatation. Antibiotics or acid inhibitors are not used. It is important to emphasize that the dilatation may be painful; however, the pain related to an uncomplicated procedure usually subsides in minutes. Persistence or increase in pain and radiation to the back may be seen as signs of alert for perforation.

Good and excellent results are consistently shown in more than 90% of patients, comparable to idiopathic achalasia.<sup>4</sup>

#### *Botulinum toxin*

Botulinum toxin injection is rarely used by Brazilian endoscopists for the treatment of CDE. Also, there is no consensus on which patients would preferably get this therapy rather than dilation or an operative approach.

Brazilians endoscopists follow standard technique described for botulinum toxin injection.<sup>11,12</sup> Echoendoscopic guidance of injection has been tried but did not prove to be a valuable tool.<sup>13</sup>

Only one representative series has been published regarding botulinum toxin in CDE.<sup>14</sup> Twenty-four patients were randomly assigned to botulinum toxin injection or placebo injection. Most patients (58%) had clinical improvement of dysphagia in a 6 months follow-up. Interestingly, gender, age and lower esophageal sphincter pressure did not influence outcomes, contrary to the results obtained in idiopathic achalasia series.<sup>15</sup>

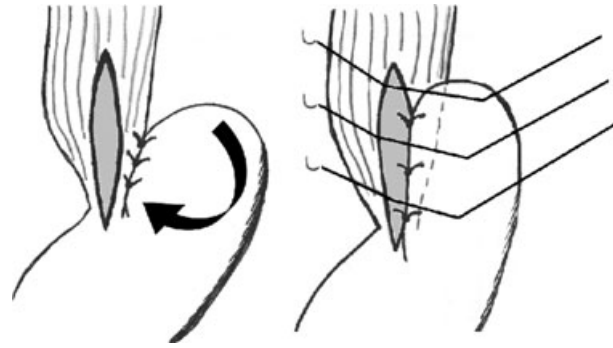
## Surgical treatment

#### *Heller's myotomy*

Heller's myotomy is the most performed operation for idiopathic achalasia and CDE. Excellent and good results exceed 90% in most series.<sup>2</sup>

The procedure is performed following international standards.<sup>16</sup> However, some technical points must be discussed.

A short myotomy was historically considered the standard procedure, especially in the United States. The rationale for this approach was to make the myotomy long enough to relieve dysphagia but short enough to avoid reflux.<sup>17</sup> Brazilian surgeons<sup>18</sup> and some European centers always performed extended



**Fig. 1** Anterolateral fundoplication. The angle of His is accentuated with a row of sutures between the posterior gastric fundus and the posterolateral left wall of the esophagus (left). A Dor fundoplication is performed with a second row of sutures between the gastric fundus and the left border of the myotomy and a third row of sutures between the gastric fundus and the right border of the myotomy (right).

myotomies onto the stomach (2 cm) with better results for dysphagia and similar results for reflux. Not until Oelschlager *et al.*<sup>19</sup> published improved outcome after extended myotomy was the practice widely accepted in North America. Few centers perform a myectomy (resection of a strip of muscular layer) instead of a myotomy.<sup>20</sup> They claim that the technique decreases the risk of healing or scarring of the myotomy.

In Brazil, most surgeons associate a posterior fundoplication to the myotomy. However, an anterolateral fundoplication proposed by Pinotti<sup>21</sup> incorporates the advantages of covering the exposed mucosa and a better reflux control due to a more ample wrapping of the esophagus. It consists of an association of a Lortat-Jacob and a Dor fundoplication (Fig. 1). Some surgeons prefer to start with the posterolateral row of sutures before the myotomy is performed in order to have a better handling of the esophagus. The technique is performed by some groups<sup>22</sup> with good results.

#### *Other conservative techniques*

Some authors propose conservative (esophagus-preserving) techniques other than myotomy as an alternative to esophagectomy in patients with end-stage dilated esophagus or recurrent disease after previous myotomy.

#### *Cardioplasty, vagotomy and Roux-en-Y gastrectomy*

Cardioplasty, vagotomy and Roux-en-Y gastrectomy (CVG) was first described by Holt and Large<sup>23</sup> and popularized in Brazil by Serra Dória, as the operation is known in South America. It consists of a Gröndahl cardioplasty, truncal vagotomy and Roux-en-Y partial gastrectomy (antrectomy) (Fig. 2).

Proposed advantages of CVG are: (i) ample permeability of the esophagogastric junction; (ii) prevention of acid and alkaline reflux; (iii) decreased

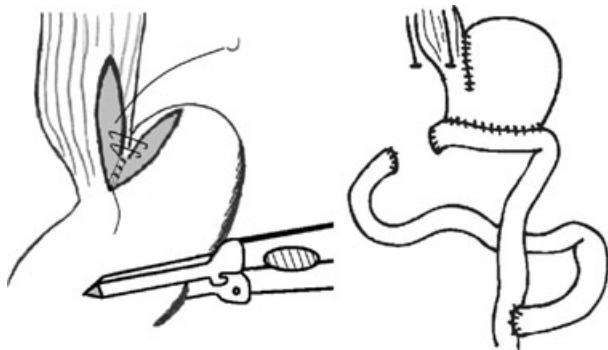


Fig. 2 Cardioplasty, vagotomy and Roux-en-Y gastroectomy.

hospitalization and recovery period compared to esophagectomy; (iv) may be used after previous gastric operations; and (v) decreased morbidity and mortality compared to esophagectomy.

Published series reported low morbidity (0–25%) and low mortality (0–2%) associated to the technique.<sup>24–27</sup>

Ponciano *et al.*<sup>24</sup> studied 20 patients with a median follow-up of 22 months. Symptoms were relieved in 88% of the patients. Gastroectomy-related postoperative symptoms were dumping in 2 (10%) patients and anemia in 1 (5%). Interestingly, reduction of the esophageal diameter was noticed in all cases.

Stefani-Nakano *et al.*<sup>25</sup> reported a comparative study between CVG and esophagectomy. In this retrospective study, long-term results (median follow-up 82 months) of 22 patients submitted to esophagectomy and 22 patients submitted to CVG for recurrent or advanced megaesophagus were analyzed. Quality of life and nutritional status were similar when both procedures were compared. Bloating, diarrhea and weight loss were more incident in the CVG group, while dumping and heartburn were more incident in the esophagectomy group.

#### *Sleeve esophagectomy and myotomy*

Pinotti described in 1999<sup>28</sup> a new technique for the treatment of advanced megaesophagus. The operation consisted in the decrease of the caliber of the esophagus accomplished by a vertical partial (sleeve) esophagectomy associated to Heller's myotomy and fundoplication (Fig. 3). Proposed advantages of the technique are: (i) reduction of the caliber and straightening of the esophagus; (ii) single field surgery; and (iii) decreased morbidity/mortality compared to esophagectomy.

The operative technique follows the principles of Heller's myotomy. It can be accomplished either via laparotomy or laparoscopy. After dissection of the abdominal esophagus and downward traction with a Penrose drain, the diaphragm is incised (Pinotti's approach) allowing dissection of the thoracic esophagus up to the pulmonary veins. The redundant part of

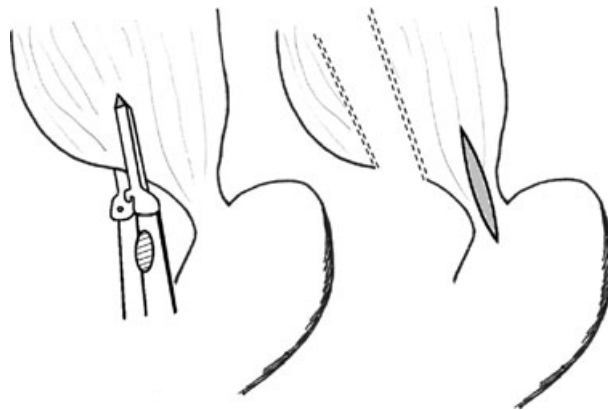


Fig. 3 Sleeve esophagectomy and myotomy.

the esophagus (usually the right side) is resected with the aid of linear staplers with a bougie in place. In cases where the esophageal wall is too thick, a longitudinal myotomy can be performed followed by stapling of the submucosa and mucosa only. The suture line is oversewn. Heller's myotomy and fundoplication are added to the esophagectomy. The diaphragm must be closed at the end of the operation.

The only published series<sup>29</sup> reported early results in 12 patients operated via laparoscopy. Intra-operative complications were: one pleural injury requiring tube thoracostomy and one case of hypoxia. Patients were discharge after 4 days in average (range 2–9). Early results (30 days) showed 2 cases of wound infection and 1 atelectasis. No leaks were observed at the staple line. Late results are still not known.

#### *Esophagectomy*

A significant number of patients with CDE present for the first time to treatment with end-stage disease. Thus, esophagectomy became popular in Brazil in the 1970s and 1980s. A decrease in the number of esophagectomies for achalasia was noticed in the 1990s<sup>30</sup> due to the fact that several groups opted for less invasive procedures, such as Heller's myotomy. Satisfactory results with this approach have been found not only by Brazilians surgeons<sup>22</sup> but also by others.<sup>31,32</sup> Contrary to this tendency, however, minimally invasive approach made esophagectomy more appealing, making the procedure well liked again among some centers.

Currently, the indications for esophageal resection are: (i) end-stage disease, as the initial treatment according to some groups or after failure of conservative operations according to others; (ii) concomitant premalignant or malignant lesions of the esophagus; and (iii) esophageal perforation unsuitable for repair during diagnostic tests, therapeutic endoscopy or intraoperatively.

Brazilian surgeons adopt a transhiatal approach. The stomach is the first choice to replace the esophagus due to the frequent association of chagasic megacolon.

Conventional open esophagectomy is performed following international standards.<sup>33</sup> Medial incision of the diaphragm<sup>34</sup> is routinely used. However, we believe that the extension of the incision up to the xiphoid, as originally described, is not necessary since the pericardium obliterates further mediastinal access. It must be emphasized that esophagectomy for achalasia may be more technically challenging compared to operation for cancer due to the larger diameter of the esophagus and inflammatory adhesions to mediastinal structures.

Outcomes are similar to international series. A series of 16 esophagectomies performed in the last 3 years by the Santa Casa de Sao Paulo shows an operative time of 5 hours, a mean of 0.3 units of blood transfused and no necessity for postoperative intensive care. Pleuropulmonary complications occurred in 31% of the patients, followed by anastomotic leak in 12% and laryngeal nerve injury in 6%. No mortality was reported.

Laparoscopic transhiatal esophagectomy was first described by a Brazilian group in 1995.<sup>35</sup> The largest experience with the technique comes from the Universidade Federal do Triângulo Mineiro, with 60 patients submitted to laparoscopic transhiatal esophagectomy (unpublished data). Earlier experience with 30 patients was previously reported.<sup>36</sup>

The mean operative time in these 60 patients was 160 (range 110–325) minutes. No death or conversion to open surgery occurred. Early complications were observed in 12 patients (20%): 7 (12%) cases of dysphonia/hoarseness due to recurrent laryngeal nerve injury; 5 (8%) cases of anastomotic leak; 4 (7%) cases of hemothorax managed with tube thoracostomy only; and 3 (5%) cases of gastroparesis. Late complications were observed in 7 (12%) patients: 3 cases of dysphonia/hoarseness persistent for 3 months; 2 cases of anastomotic stricture requiring endoscopic dilatation; 2 cases of gastroparesis requiring laparoscopic pyloroplasty; and 1 case of internal hernia through the hiatus. A high incidence of recurrent laryngeal nerve injury has been previously reported in idiopathic achalasia series as well.<sup>37</sup> The authors attributed this fact to the removal of a voluminous surgical specimen through the neck. Postoperative endoscopy at 1 year of follow-up showed esophageal stump esophagitis in 2 cases (3%).

Experience with vagal-sparing esophagectomy is still anecdotal.

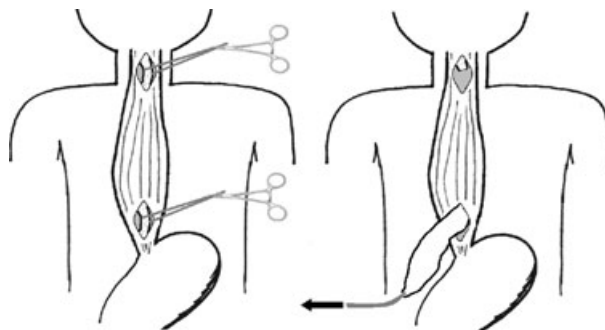
#### *Esophageal mucosectomy and endomuscular pull-through*

Esophageal mucosectomy and endomuscular pull-through is an attractive alternative to conventional

esophagectomy. The technique of resection of the esophageal mucosa with preservation of the muscular layer and transposition of the stomach through the muscular tunnel has the advantages of: (i) decreased bleeding; (ii) decreased pleural lesion; (iii) preservation of mediastinal lymphatic system; and (iv) preservation of vagus nerve if a vagal sparing esophagectomy is indicated.

The operative technique follows the principle of transhiatal esophagectomy. In brief (Fig. 4), it consists of: (i) abdominal and neck incisions; (ii) dissection of the abdominal and cervical esophagus; (iii) opening of the anterior muscular layer at the abdominal and cervical esophagus, similarly to a Heller myotomy; (iv) circumferential dissection of the esophageal mucosa at the areas of myotomy in an extension of 5 cm; (v) small esophagotomy at the level of the abdominal myotomy and passage of a large diameter rectal tube that is exposed in the neck through a esophagotomy at the level of the cervical myotomy; and (vi) the esophageal mucosa at the neck is excised, tied to the tube and removed inverted by downward traction of the tube. Careful inspection of the mucosa must be done, since retained islands of mucosa in the mediastinum preclude the procedure. Reconstruction is performed with the stomach pulled through the muscular tunnel. As yet, there is no report of minimally invasive esophageal mucosectomy and endomuscular pull-through.

The largest experience with esophageal mucosectomy and endomuscular pull-through come from the Catholic University in Campinas, with more than 89 patients operated. The experience with 60 patients was previously reported.<sup>38</sup> The entire procedure was accomplished in 59 (98.3%) patients; in one case resection of the muscular layer was necessary because of incomplete removal of the mucosa. Gastric transposition through the muscular tunnel in the posterior mediastinum was accomplished in 45% of the cases;



**Fig. 4** Esophageal mucosectomy and endomuscular pull-through. A myotomy is performed at the cervical and abdominal esophagus, and the esophageal mucosa is dissected circumferentially (left). A large bore tube is passed through a small esophagotomy at the level of the abdominal myotomy and exposed in the neck through a esophagotomy at the level of the cervical myotomy. The esophageal mucosa is removed inverted by downward traction of the tube tied to the mucosa (right).

**Table 1** Treatment options for end-stage Chagas' disease esophagopathy

	Mortality (%)	Excellent/good results (%)	Reference
Heller's myotomy	0	80	22
Cardioplasty, vagotomy and Roux-en-Y gastrectomy	0–2%	90	24–27
Esophagectomy (conventional)	0–4	N/A	UD, 41
Esophagectomy (minimally invasive)	0	97	36
Esophageal mucosectomy and endomuscular pull-through	3	75	UD, 38
Sleeve esophagectomy and myotomy	0	N/A	29

N/A, not available; UD, unpublished data.

in the other 55% of the patients fear of gastric compression prevented the use of the posterior mediastinum. In the last 30 nonreported patients, however, transposition through the muscular tunnel was accomplished in 93% of the cases.

In-hospital mortality was 3.3% consisting of two cases of myocardial infarction in patients with chagasic cardiopathy. Pulmonary complications were present in 3 cases: 2 pleural effusions and 1 case of pneumonia. Anastomotic leak was observed in 1 case (3.7%) among the patients whose stomach was transposed through the esophageal muscular tunnel. Interestingly, computed tomography scan was routinely performed in 22 patients with the stomach transposed through the esophageal muscular tunnel. Two asymptomatic fluid collections were observed.

Long-term follow-up (6 to 15 years) was available in 50 patients. Dysphagia was relieved in 76% of the patients. Eight (16%) patients persisted with sporadic dysphagia and 4 (8%) with frequent dysphagia. Three (6%) patients lost weight after the procedure. Improvement of quality of life and satisfaction with the operation were referred by 98% of the patients.

## REOPERATIONS

The main causes for reoperative approach to CDE are: (i) incomplete myotomy; (ii) myotomy scarring or healing; (iii) esophagitis due to gastroesophageal reflux; (iv) fundoplication misplacement or migration; and (v) failure of conservative techniques in end-stage cases.<sup>39</sup> The rate of reoperation is obviously dependent on the initial treatment, ranging from 2 to 8% for Heller's myotomy and fundoplication.<sup>22,40</sup>

The patients must be submitted to a complete workup identical to the initial evaluation. pH monitoring must also be performed if gastroesophageal reflux is suspected.

The surgical approach is based on the cause for recurrence. Endoscopic dilatation can be tried in cases of incomplete myotomy or myotomy scarring or healing. If endoscopy therapy fails, a *de novo* myotomy and fundoplication can be performed.<sup>39</sup> We prefer to perform a second myotomy in an area not covered by the fundoplication if the previous fundoplication is intact and well placed and gastroesoph-

ageal reflux is not suspected. Good results are obtained in almost 100% of the patients.<sup>22,39</sup>

Gastroesophageal reflux not controlled by medication may be treated with a redo fundoplication if it is anatomically defective. In cases when the fundoplication is well placed and configured, CVG may be an alternative.

Failure of conservative techniques in end-stage cases is best treated by esophagectomy. Other options in frail patients are cardioplasties, such as CVG, Thal-Hatafuku operation or Merendino operation.

Irrespective of the technique it is important to emphasize that reoperation at the esophagogastric junction may be challenging due to extensive fibrosis. The esophagus can be accessed above the dissected area with opening of the diaphragm.<sup>34</sup>

A large experience with reoperations comes from the State University of Campinas. Forty-five patients were reoperated from 1992 to 2007. The period between the initial treatment and reoperation ranged from 3 to 44 (mean 8.9) years.

Redo-myotomy was the operation of choice in the majority of patients ( $n = 25$ ), especially in nonadvanced cases (esophageal diameter <7 cm). Three patients (12%) had recurrence of symptoms and underwent esophagectomy. End-stage cases (esophageal diameter >7 cm) were managed with transhiatal esophagectomy ( $n = 18$ ), with esophageal mucosectomy and endomuscular pull-through in eight patients. Other techniques were Thal-Hatafuku operation in one case and fundoplication in one case submitted originally to myotomy only.

Follow-up ranged from 1 to 68 (average 25) months. Third-eight (84%) patients reported improvement in symptoms and quality of life, 16% of the patients reported symptoms but without the necessity for a new procedure.

## CONCLUSIONS

South American surgeons and gastroenterologists are able to treat enormous number of patients with CDE yearly, making them natural candidates to conduct clinical studies. However, available literature regarding surgical therapy for CDE is surprisingly limited.

Our review shows that in Brazil nonadvanced achalasia is treated by Heller's myotomy. Endoscopic

treatment is reserved to very limited cases. Treatment for end-stage achalasia is not unanimous. Esophagectomy was a popular treatment for these patients; however, the morbidity/mortality associated to the procedure made some authors seek for different alternatives, such as Heller's myotomy and CVG. Different centers adopted different techniques with similar results achieved (Table 1). Minimally invasive approach to esophageal resection may change this concept, although few centers perform the procedure routinely.

## References

- Prata A. Clinical and epidemiological aspects of Chagas disease. *Lancet Infect Dis* 2001; 1: 92–100.
- Herbella F A, Oliveira D R, Del Grande J C. Are idiopathic and Chagasic achalasia two different diseases? *Dig Dis Sci* 2004; 49: 353–60.
- Herbella F A, Matone J, Del Grande J C. Eponyms in esophageal surgery, part 2. *Dis Esophagus* 2005; 18: 4–16.
- World Health Organization website. <http://www.who.int/ctd/chagas/disease.htm>
- Center for Diseases Control website. [http://www.cdc.gov/ncidod/dpd/parasites/chagasdisease/factsht\\_chagas\\_disease.htm](http://www.cdc.gov/ncidod/dpd/parasites/chagasdisease/factsht_chagas_disease.htm)
- Kamiji M M, de Oliveira R B. [Features of Chagas' disease patients with emphasis on digestive form, in a tertiary hospital of Ribeirão Preto, SP] *Rev Soc Bras Med Trop* 2005; 38: 305–9.
- Rezende J M, Oliveira R, Lauer K N. Aspectos clínicos e radiológicos da aperistalsis do esôfago. *Revista Brasileira de Gastroenterologia* 1960; 12: 247–62.
- Crema E, Cruvinel L A, Werneck A M, de Oliveira R M, Silva A A. [Manometric and radiologic aspects of Chagas' megaesophagus: the importance to its surgical treatment] *Rev Soc Bras Med Trop* 2003; 36: 665–9.
- Patti M G, Fisichella P M, Perretta S, Galvani C, Gorodner M V, Robinson T, Way L W. Impact of minimally invasive surgery on the treatment of esophageal achalasia: a decade of change. *J Am Coll Surg* 2003; 196: 698–703.
- Souza W F, Tornatores K G F, Dantas M S. Estudo radiológico do esôfago e coração em doadores de sangue chagásicos. *Rev Soc Bras Med Trop* 1984; 17(Suppl.): 21.
- Woltman T A, Pellegrini C A, Oelschlager B K. Achalasia. *Surg Clin North Am* 2005; 85: 483–93.
- Pasricha P J, Ravich W J, Hendrix T R, Sostre S, Jones B, Kalloo A N. Intrasphincteric botulinum toxin for the treatment of achalasia. *N Engl J Med* 1995; 332: 774–8.
- Brant C Q, Nakao F, Ardengh J C, Nasi A, Ferrari A P Jr. Echoendoscopic evaluation of botulinum toxin intrasphincteric injections in Chagas' disease achalasia. *Dis Esophagus* 1999; 12: 37–40.
- Brant C, Moraes-Filho J P, Siqueira E *et al.* Intrasphincteric botulinum toxin injection in the treatment of chagasic achalasia. *Dis Esophagus* 2003; 16: 33–8.
- Pasricha P J, Rai R, Ravich W J *et al.* Botulinum toxin for achalasia: long-term outcome and predictors of response. *Gastroenterol* 1996; 110: 1410–5.
- Gorodner M V, Galvani C, Patti M G. Heller myotomy. *Oper Tech Gen Surg* 2004; 6: 23–8.
- Herbella F A, Patti M G. Fundoplication after laparoscopic myotomy for achalasia. In: Ferguson M K (ed). *Difficult Decisions in Thoracic Surgery: An Evidence-Based Approach*. New York: Springer, 2006; 292–7.
- Del Grande J C, Herbella F A, Lourenco L G, Mansur N S, Haddad C M. [Early results of the cardiomyotomy and fundoplication for the treatment of the megaesophagus: analysis of 104 cases]. *GED Gastroenterol. Endosc Dig* 1996; 15: 156–60.
- Oelschlager B K, Chang L, Pellegrini C A. Improved outcome after extended gastric myotomy for achalasia. *Arch Surg* 2003; 138: 490–5.
- Pinotti H W, Felix V N, Zilberstein B, Ceconello I. Surgical complications of Chagas' disease: megaesophagus, achalasia of the pylorus, and cholelithiasis. *World J Surg* 1991; 15: 198–204.
- Pinotti H W, Sakai P, Ishioka S. Cardiomyotomy and fundoplication for esophageal achalasia. *Jpn J Surg* 1983; 13: 399–403.
- Herbella F A, Del Grande J C, Lourenco L G, Mansur N S, Haddad C M. [Late results of Heller operation and fundoplication for the treatment of the megaesophagus: analysis of 83 cases]. *Rev Assoc Med Bras* 1999; 45: 317–22.
- Holt C J, Large A M. Surgical management of reflux esophagitis. *Ann Surg* 1961; 153: 555–62.
- Ponciano H, Ceconello I, Alves L, Ferreira B D, Gama-Rodrigues J. Cardioplasty and Roux-en-Y partial gastrectomy (Serra-Dória procedure) for reoperation of achalasia. *Arq Gastroenterol* 2004; 41: 155–61.
- Stefani-Nakano S M, Faintuch J, Ceconello I, Rocha J M, Gama-Rodrigues J J. Quality of life of patients operated for advanced Chagas' megaesophagus. *ABCD Arq Bras Cir Dig* 2005; 18: 129–32.
- Alves A, Zilberstein B, Trevenzol H P, Penhavel F A S, Neder J. Operação De Serra Doria no tratamento do megaesôfago chagásico avançado: resultados imediatos. *ABCD Arq Bras Cir Dig* 2003; 16: 120–3.
- Tinoco R C, Tinoco A CA, Guimarães L M, El-Kadre L J, Tinoco L A. Cardioplastia com gastrectomia em Y de Roux no megaesôfago avançado ou nas falhas da esofagocardiomiectomia. *Rev Bras Videocir* 2004; 2: 19–22.
- Pinotti, H W. Tratamento cirúrgico do megaesôfago avançado: proposta de novo procedimento técnico – a esofagoplastia redutora vertical com cardiomiectomia. In: Pinotti, H W. *Acesso ao esôfago torácico por transecção mediana do diafragma*. São Paulo: Atheneu, 1999; 173–84.
- Savassi-Rocha, P R, Andrade, M A C. *Megaesôfago Chagásico. Avaliação e Tratamento Clínico e Cirúrgico*. Goiânia: Ed. Da UCG; 2006 358–73.
- Ceneviva R, Ferreira-Santos R, Santos J S, Mente E D, Sankarankutty A K. [Chronological changes of patients profile and of surgical treatment modality of the chagasic megaesophagus]. *Acta Cir Bras* 2002; 17(Suppl 3): 125–8.
- Patti M G, Feo C V, Diener U *et al.* Laparoscopic Heller myotomy relieves dysphagia in achalasia when the esophagus is dilated. *Surg Endosc* 1999; 13: 843–7.
- Mineo T C, Pompeo E. Long-term outcome of Heller myotomy in achalasic sigmoid esophagus. *J Thorac Cardiovasc Surg* 2004; 128: 402–7.
- Orringer M B, Marshall B, Iannettoni M D. Transhiatal esophagectomy: clinical experience and refinements. *Ann Surg* 1999; 230: 392–400.
- Pinotti H W, Zilberstein B, Pollara W, Raia A. Esophagectomy without thoracotomy. *Surg Gynecol Obstet* 1981; 152: 344–6.
- dePaula A L, Hashiba K, Ferreira E A, De Paula R A, Grecco E. Laparoscopic transhiatal esophagectomy with esophagogastroplasty. *Surg Laparosc Endosc* 1995; 5: 1–5.
- Crema E, Ribeiro L B, Terra J A Jr, Silva A A. Laparoscopic transhiatal subtotal esophagectomy for the treatment of advanced megaesophagus. *Ann Thorac Surg* 2005; 80: 1196–201.
- Swanstrom L L, Hanson P. Laparoscopic total esophagectomy. *Arch Surg* 1997; 132: 943–9.
- Aquino J L B, Reis Neto J A, Muraro C L P M, Camargo J G T. [Esophageal mucosectomy in the treatment of the advanced megaesophagus: analysis of 60 cases]. *Rev Col Bras Cir* 2000; 27: 109–16.
- Serra H O, Felix V N, Ceconello I, Pinotti H W. Reapplication of myotomy and fundoplication in the surgical treatment of recurrent dysphagia after incomplete myotomy. *Rev Hosp Clin Fac Med Sao Paulo* 1998; 53: 129–33.
- Martins P, Morais B B, Cunha-Melo J R. Postoperative complications in the treatment of chagasic megaesophagus. *Int Surg* 1993; 78: 99–102.
- Pinotti H W, Ceconello I, Da Rocha J M, Zilberstein B. Resection for achalasia of the esophagus. *Hepatogastroenterol* 1991; 38: 470–3.