

ACG Clinical Guideline: The Diagnosis and Management of Focal Liver Lesions

Jorge A. Marrero, MD¹, Joseph Ahn, MD, FACG² and K. Rajender Reddy, MD, FACG³ on behalf of the Practice Parameters Committee of the American College of Gastroenterology

Focal liver lesions (FLL) have been a common reason for consultation faced by gastroenterologists and hepatologists. The increasing and widespread use of imaging studies has led to an increase in detection of incidental FLL. It is important to consider not only malignant liver lesions, but also benign solid and cystic liver lesions such as hemangioma, focal nodular hyperplasia, hepatocellular adenoma, and hepatic cysts, in the differential diagnosis. In this ACG practice guideline, the authors provide an evidence-based approach to the diagnosis and management of FLL.

Am J Gastroenterol advance online publication, 19 August 2014; doi:10.1038/ajg.2014.213

PREAMBLE

The writing group was invited by the Practice Parameters Committee and the Board of the Trustees of the American College of Gastroenterology to develop a practice guideline regarding the suggested diagnostic approaches and management of focal liver lesions (FLLs). FLLs are solid or cystic masses or areas of tissue that are identified as an abnormal part of the liver. The term “lesion” rather than “mass” was chosen because “lesion” is a term that has a wider application, including solid and cystic masses. This guideline will be limited to primary liver lesions and the management approach to FLLs rather than focusing on the diagnosis and management of metastatic lesions, hepatocellular carcinoma, or cholangiocarcinoma. For specific reading on these lesions, the reader is referred to other recent guidelines (1–3). An evidence-based approach was undertaken to critically review the available diagnostic tests and treatment options of FLLs. The following resources were utilized: (i) a formal review and analysis of the published literature using MEDLINE via the OVID interface up to June 2013 with the search terms “hepatic/liver mass,” “hepatic/liver tumor,” “hepatic/liver cancer,” “hepatic/liver lesion,” “hepatocellular adenoma,” “liver adenomatosis,” “hepatic hemangioma,” “focal nodular hyperplasia,” “nodular regenerative hyperplasia,” “hepatic cyst,” “hepatic cystadenoma,” “hepatic cystadenocarcinoma,” “polycystic liver disease,” and “hydatid cyst,” without language restriction; (ii) hand reviews of articles known to the authors; and (iii) the consensus experiences of the authors and independent reviewers regarding FLLs. The guideline was prepared according to the policies of the American College of Gastroenterology and with the guidance of the Practice Parameters Committee. The GRADE system was used to grade the strength of recommendations and the quality of evidence (4).

Table 1 summarizes the recommendations of this practice guideline on FLLs.

INTRODUCTION

Because of the widespread clinical use of imaging modalities such as ultrasonography (US), computed tomography (CT), and magnetic resonance imaging (MRI), previously unsuspected liver lesions are increasingly being discovered in otherwise asymptomatic patients. A recent study indicated that from 1996 to 2010 the use of CT examinations tripled (52/1,000 patients in 1996 to 149/1,000 in 2010, 7.8% annual growth), MRIs quadrupled (17/1,000 to 65/1,000, 10% annual growth); US approximately doubled (134/1,000 to 230/1,000, 3.9% annual growth), and positron emission tomography (PET) scans increased from 0.24/1,000 patients to 3.6/1,000 patients (57% annual growth) (5). More importantly, the evaluation of liver lesions has taken on greater importance because of the increasing incidence of primary hepatic malignancies, especially hepatocellular carcinoma (HCC) and cholangiocarcinoma (CCA). Therefore, a thorough and systematic approach to the management of focal liver lesions (FLLs) is of utmost importance.

Diagnosis of a liver lesion

The critical components of evaluating an FLL are a detailed history, physical exam, radiological tests, and pathology. For example, a history of oral contraceptive use in the absence of underlying liver disease suggests a diagnosis of hepatocellular adenoma (HCA), whereas an FLL in the setting of chronic liver disease and portal hypertension should lead to a high suspicion of a diagnosis of HCC.

A radiological test is the most important aspect in the evaluation of a liver lesion. Although US is usually the first imaging test obtained

¹University of Texas at Southwestern, Dallas, Texas, USA; ²Oregon Health and Science University, Portland, Oregon, USA; ³University of Pennsylvania, Philadelphia, Pennsylvania, USA. **Correspondence:** K. Rajender Reddy, MD, FACG, University of Pennsylvania, Philadelphia, Pennsylvania 19104, USA. E-mail: rajender.reddy@uphs.upenn.edu

Received 15 November 2013; accepted 22 May 2014

Table 1. Recommendations**The GRADE (Grading of Recommendations Assessment, Development, and Evaluation) system for grading evidence and strength of recommendations***Strength of recommendations*

Strong: the desirable effects of an intervention clearly outweigh the undesirable effects or clearly do not.

Weak: the tradeoffs are less certain between the desirable and undesirable effects of an intervention.

Quality of evidence

High: further research is very unlikely to change our confidence in the estimate of effect.

Moderate: further research is likely to have an important impact on our confidence in the estimate of effect and may change the estimate.

Low: further research is very likely to have an important impact on our confidence in the estimate of effect and is likely to change the estimate.

Very low: any estimate of effect is very uncertain.

Solid FLL

Suspected hepatocellular carcinoma

1. An MRI or triple-phase CT should be obtained in patients with cirrhosis with an ultrasound showing a lesion of > 1 cm (strong recommendation, moderate quality of evidence).
2. Patients with chronic liver disease, especially with cirrhosis, who present with a solid FLL are at a very high risk for having HCC and must be considered to have HCC until otherwise proven (strong recommendation, moderate quality of evidence).
3. A diagnosis of HCC can be made with CT or MRI if the typical characteristics are present: a solid FLL with enhancement in the arterial phase with washout in the delayed venous phase should be considered to have HCC until otherwise proven (strong recommendation, moderate quality of evidence).
4. If an FLL in a patient with cirrhosis does not have typical characteristics of HCC, then a biopsy should be performed in order to make the diagnosis (strong recommendation, moderate quality of evidence).

Suspected cholangiocarcinoma

5. MRI or CT should be obtained if CCA is suspected clinically or by ultrasound (strong recommendation, low quality of evidence).
6. A liver biopsy should be obtained to establish the diagnosis of CCA if the patient is nonoperable (strong recommendation, low quality of evidence).

Suspected hepatocellular adenoma

7. Oral contraceptives, hormone-containing IUDs, and anabolic steroids are to be avoided in patients with hepatocellular adenoma (strong recommendation, moderate quality of evidence).
8. Obtaining a biopsy should be reserved for cases in which imaging is inconclusive and biopsy is deemed necessary to make treatment decisions (strong recommendation, low quality of evidence).
9. Pregnancy is not generally contraindicated in cases of hepatocellular adenoma <5 cm and an individualized approach is advocated for these patients (conditional recommendation, low quality of evidence).
10. In hepatocellular adenoma ≥5 cm, intervention through surgical or nonsurgical modalities is recommended, as there is a risk of rupture and malignancy (conditional recommendation, low quality of evidence).
11. If no therapeutic intervention is pursued, lesions suspected of being hepatocellular adenoma require follow-up CT or MRI at 6- to 12-month intervals. The duration of monitoring is based on the growth patterns and stability of the lesion over time (conditional recommendation, low quality of evidence).

Suspected hemangioma

12. An MRI or CT scan should be obtained to confirm a diagnosis of hemangioma (strong recommendation, moderate quality of evidence).
13. Liver biopsy should be avoided if the radiologic features of a hemangioma are present (strong recommendation, low quality of evidence).
14. Pregnancy and the use of oral contraceptives or anabolic steroids are not contraindicated in patients with a hemangioma (conditional recommendation, low quality of evidence).
15. Regardless of the size, no intervention is required for asymptomatic hepatic hemangiomas. Symptomatic patients with impaired quality of life can be referred for surgical or nonsurgical therapeutic modalities by an experienced team (conditional recommendation, low quality of evidence).

Suspected focal nodular hyperplasia

16. An MRI or CT scan should be obtained to confirm a diagnosis of FNH. A liver biopsy is not routinely indicated to confirm the diagnosis (strong recommendation, low quality of evidence).
17. Pregnancy and the use of oral contraceptives or anabolic steroids are not contraindicated in patients with FNH (conditional recommendation, low quality of evidence).
18. Asymptomatic FNH does not require intervention (strong recommendation, moderate quality of evidence).

Table 1 continued on following page

Table 1. Continued

19.	Annual US for 2–3 years is prudent in women diagnosed with FNH who wish to continue OCP use. Individuals with a firm diagnosis of FNH who are not using OCP do not require follow-up imaging (conditional recommendation, low quality of evidence).
Suspected nodular regenerative hyperplasia	
20.	Liver biopsy is required to confirm the diagnosis of NRH (strong recommendation, moderate quality of evidence).
21.	Pregnancy and the use of oral contraceptives or anabolic steroids are not contraindicated in patients with an NRH (conditional recommendation, low quality of evidence).
22.	Asymptomatic NRH does not require intervention (conditional recommendation, low quality of evidence).
23.	Management of NRH is based on diagnosing and managing any underlying predisposing disease processes (strong recommendation, low quality of evidence).
<i>Cystic FLL</i>	
Suspect simple hepatic cysts	
24.	A hepatic cyst identified on US with septations, fenestrations, calcifications, irregular walls, or daughter cysts should prompt further evaluation with a CT or MRI (strong recommendation, low quality of evidence).
25.	Asymptomatic simple hepatic cysts should be observed with expectant management (strong recommendation, moderate quality of evidence).
26.	Aspiration of asymptomatic, simple hepatic cysts is not recommended (strong recommendation, low quality of evidence).
27.	Symptomatic simple hepatic cysts may be managed with laparoscopic deroofing rather than aspiration and sclerotherapy, dictated based on availability of local expertise (conditional recommendation, low quality of evidence).
Suspected biliary cystadenoma or cystadenocarcinoma	
28.	Routine fluid aspiration is not recommended when BCA is suspected because of limited sensitivity and the risk of malignant dissemination (strong recommendation, low quality of evidence).
29.	Imaging characteristics suggestive of BC or BCA, such as internal septations, fenestrations, calcifications, or irregular walls, should lead to referral for surgical excision (strong recommendation, low quality of evidence).
30.	Complete surgical excision, by an experienced team, is recommended if BC or BCA is suspected (strong recommendation, low quality of evidence).
Suspected polycystic liver disease	
31.	Routine medical therapy with mammalian target of rapamycin inhibitors or somatostatin analogs is not recommended (strong recommendation, low quality of evidence).
32.	Aspiration, deroofing, resection of a dominant cyst(s) can be performed based on the patient's clinical presentation and underlying hepatic reserve (conditional recommendation, low quality of evidence).
33.	Liver transplantation with or without kidney transplantation can be considered in patients with refractory symptoms and significant cyst burden (conditional recommendation, low quality of evidence).
Suspected hydatid cysts	
34.	MRI is preferred over CT for concomitant evaluation of the biliary tree and cystic contents (conditional recommendation, low quality of evidence).
35.	Monotherapy with antihelminthic drugs is not recommended in symptomatic patients who are surgical or percutaneous treatment candidates (strong recommendation, moderate quality of evidence).
36.	Adjunctive therapy with antihelminthic therapy is recommended in patients undergoing PAIR or surgery, and in those with peritoneal rupture or biliary rupture (strong recommendation, low quality of evidence).
37.	Percutaneous treatment with PAIR is recommended for patients with active hydatid cysts who are not surgical candidates, who decline surgery, or who relapse after surgery (strong recommendation, low quality of evidence).
38.	Surgery, either laparoscopic or open, based on available expertise, is recommended in complicated hydatid cysts with multiple vesicles, daughter cysts, fistulas, rupture, hemorrhage, or secondary infection (strong recommendation, low quality of evidence).
BC, biliary cystadenoma; BCA, biliary cystadenocarcinoma; CCA, cholangiocarcinoma; CT, computed tomography; FLL, focal liver lesion; FNH, focal nodular hyperplasia; HCC, hepatocellular carcinoma; IUD, intrauterine device; MRI, magnetic resonance imaging; NRH, nodular regenerative hyperplasia; OCP, oral contraceptive; PAIR, puncture, aspiration, injection, and reaspiration; US, ultrasonography.	

because of its safety and low cost, it lacks the performance characteristics that CT and MRI have to diagnose and characterize hepatic lesions (6). Contrast-enhanced US is an emerging modality that has some utility but is not widely available in the United States. Therefore, we will focus our attention on CT and MRI scans in this guideline.

In the context of HCC and liver transplantation, a recent consensus conference addressed the importance of standardizing the technical specifications for CT and MRI in the diagnosis of HCC (7). Although this report focused on the specifications for diagnosing HCC, the technical aspects for CT or MRI can

also be applied to the evaluation of FLLs as shown in **Table 2**. The most important aspect is the need for a late arterial phase, a portal venous phase, and a delayed venous phase. In the context of a CT scan, this is referred to as a “triple-phase” study, distinct from a standard abdominal CT that includes only a portal venous phase and a delayed phase. A technically appropriate CT or MRI will give the clinician information about the characteristics of the liver lesion, its location and relationship to anatomical structures (such as the gallbladder and hepatic vasculature), and, in the case of malignancy, allow staging of the tumor.

Pathological examination is another important aspect in the evaluation of an FLL. The evolution of CT and MRI technology has improved their diagnostic capability to often permit making an accurate diagnosis without the requirement for a liver biopsy. In fact, HCC can be diagnosed with $\geq 90\%$ accuracy with imaging alone when a lesion is 2 cm, thus obviating the need for liver biopsy in nearly all cases under the right clinical circumstances (8). However, if the diagnosis cannot be reliably made radiologically, a biopsy should be performed. Pathological examination is extremely accurate in making a diagnosis in a patient with an FLL. A well-sampled biopsy specimen has greater diagnostic accuracy and provides more tissue for ancillary testing (i.e., immunohistochemistry) when compared with fine-needle aspiration (9). A consensus conference on pathology for hepatobiliary malignancies also recommended core biopsies over fine-needle aspiration as it allows for the assessment of both architectural and cytological features (10).

MALIGNANT LIVER LESIONS

Hepatocellular carcinoma

Epidemiology of hepatocellular carcinoma. HCC is the third most common tumor worldwide and the second leading cause of cancer-related deaths (11). The incidence of HCC has been rising in the United States to 8 per 100,000, with chronic hepatitis C virus infection as the main driving force behind this increase (12). The age-specific incidence rate of HCC starts increasing in the mid 40s, with those under 60 years of age having the largest increase in incidence, suggesting that this increasing incidence will continue for another 10 to 20 years (13). The overall 5-year survival of patients with HCC is $\sim 15\%$, indicating its generally poor prognosis. However, 40% of patients who are diagnosed with disease localized to the liver have improved 5-year survival rates of 30% (12). This indicates that early detection and accurate diagnosis of HCC localized to the liver may improve overall outcomes.

Risk factors for HCC

In Japan, Europe, and the United States, approximately $\sim 60\%$ of HCC cases are attributed to hepatitis C virus infection, whereas 20% are attributed to hepatitis B virus (HBV) infection and another 20% to cryptogenic and alcoholic liver disease (14). In high HBV prevalence areas such as East Asia, China, and Africa, up to 8% of the population is chronically infected with HBV because of high rates of vertical (mother-to-child) or horizontal (child-to-child) transmission, resulting in nearly 80% of patients

with HCC having underlying chronic HBV infection. The broad traits of the epidemiology of HCC can be traced to the prevalence of these hepatotropic viral infections.

Cirrhosis is the most important risk factor for HCC. More than 80% of the cases of HCC occur in the setting of cirrhosis. The risk for HCC in individuals with HBV increases from asymptomatic inactive carriers and those with chronic hepatitis without cirrhosis, all with an incidence < 1 per 100 person-years, to 2.2–4.3 per 100 person-years in cirrhotics (15). Importantly, $\sim 20\%$ of patients with HCC in the setting of HBV infection present without evidence of cirrhosis. Risk factors for the development of HBV-associated HCC include viral factors such as a high degree of viral replication, viral genotype, as well as the use of alcohol and tobacco (16,17). The risk for HCC among patients with chronic hepatitis C virus infection occurs almost exclusively in the setting of cirrhosis. In the United States and Europe, the incidence rate is 2–3% per year for hepatitis C virus cirrhotics, whereas it is $< 1\%$ for patients with chronic hepatitis C without cirrhosis (18,19). Among patients with cirrhosis, alcohol, tobacco, obesity, diabetes, older age, and male gender are associated with an increase in the risk for the development of HCC (20–23).

Diagnosis of HCC

The diagnosis of HCC based on imaging can be challenging because of the imaging characteristics of a background of liver cirrhosis. Therefore, CT or MRI should be performed using the technical specifications indicated in **Table 2**. A CT or MRI should be performed in cirrhotics with an ultrasound showing a lesion of > 1 cm, an elevated or rising α -fetoprotein in the absence of a liver lesion on US, or when there is a clinical suspicion for the presence of HCC. The choice of MRI versus CT is controversial despite several studies comparing the performance characteristics of one versus the other with explant examination as the gold standard (24). These studies have shown that dynamic MRI has a slightly better performance than CT for the diagnosis of HCC. However, these studies were limited by potential biases such as a high percentage of patients being evaluated for liver transplantation, lack of blinding of the reader, and limiting generalizability to smaller or nontransplant-associated centers (25–29). Therefore, one should utilize the locally available expertise, whether MRI or CT. An essential characteristic of HCC is that it is an arterially hypervascular tumor (30). However, only using hypervascularity on the arterial phase as the sole criterion for the diagnosis of HCC has poor specificity and has led to reports of liver transplantations being performed for a radiologic diagnosis of HCC with an absence of HCC on explant examination (31,32). During the portal venous phase of a patient with HCC, the previously arterially enhanced mass lacks contrast and appears hypodense compared with the rest of the liver that is now enhanced in the portal venous phase, a term labeled “washout.” These characteristic findings of arterial hyperenhancement with “washout” in the portal venous or delayed phase are highly specific and sensitive for a diagnosis of HCC (33). These criteria have been validated and accepted in the guidelines for the diagnosis of HCC (34).

It has been estimated that ~85% of patients with HCC have arterial enhancement and washout (35,36). In those who do not have these characteristic features on radiological examination, a directed biopsy of the mass may be needed in order to confirm a diagnosis of HCC. This strategy of biopsying atypical lesions on imaging has been validated (37). In this study by Forner *et al.* (37), the first biopsy was positive in 42/60 (70%) patients with HCC, and subsequent follow-up biopsies led to the diagnosis in the rest of the patients. The decision to proceed with a directed biopsy must be made weighing the risk of tumor seeding and potential bleeding versus the impact of the results on the patient's treatment options and prognosis. The use of the coaxial biopsy technique, in which the actual needle is introduced percutaneously into the tumor inside a sheath, can mitigate this risk of tumor seeding by insulating the needle inside the sheath (38).

Treatment of HCC

Excellent treatment options exist for HCC, especially if localized to the liver. A detailed review of the treatment for HCC is beyond the scope of this guideline but has been reviewed recently (1). It is important to note that hepatic resection, liver transplantation (in carefully selected individuals), and radiofrequency ablation have a 5-year survival of >50% and are considered curative (39,40). Treatments not considered curative are transarterial chemoembolization, radioembolization, and systemic chemotherapy such as with sorafenib (41,42).

Recommendations

1. An MRI or triple-phase CT should be obtained in patients with cirrhosis with an ultrasound showing a lesion of >1 cm (strong recommendation, moderate quality of evidence).
2. Patients with chronic liver disease, especially with cirrhosis, who present with a solid FLL are at a very high risk for having HCC and must be considered to have HCC until otherwise proven (strong recommendation, moderate quality of evidence).
3. A diagnosis of HCC can be made with CT or MRI if the typical characteristics are present: a solid FLL with enhancement in the arterial phase with washout in the delayed venous phase should be considered to have HCC until otherwise proven (strong recommendation, moderate quality of evidence).
4. If an FLL in a patient with cirrhosis does not have typical characteristics of HCC, then a biopsy should be performed in order to make the diagnosis (strong recommendation, moderate quality of evidence).

CHOLANGIOCARCINOMA

Epidemiology of CCA

CCA can be divided further into intrahepatic CCA (ICCA) or extrahepatic CCA. This guideline will focus on ICCA as a possible diagnosis for an FLL. The incidence of ICCA has been shown to be increasing in Japan, United Kingdom, and the United States, the latter with an incidence of 0.85 per 100,000 in 2005 (43). The

1-year survival for ICCA remains low at 27.6% and the 5-year survival is <10% because of the diagnosis often being made at advanced stages.

Risk factors for CCA

Identifying risk factors for CCA is more challenging than for HCC because for most cases the cause is unknown. In the United States, patients with primary sclerosing cholangitis (PSC) have a risk of developing CCA at ~1.5% per year after diagnosis (44). Among patients with PSC who progress to CCA, ~30% are diagnosed with CCA within 2 years after the initial diagnosis of PSC. Given these risk factors, CCA should be strongly suspected in patients with PSC who present with an FLL. Furthermore, CCA is also associated with smoking and alcohol use (45). Other important risk factors in the development of CCA are older age (>65 years of age), liver fluke infestation, Caroli's disease, choledochal cyst, bile duct adenoma, chronic intrahepatic stones, chemical agents (such as vinyl chloride), and cirrhosis (45). The current evidence does not support routine screening for CCA in patients with underlying PSC, despite the increased incidence of CCA in this population.

Diagnosis of CCA

Patients with ICCA may present with nonspecific symptoms including abdominal pain, diminished appetite, weight loss, malaise, and night sweats. Laboratory tests are usually nonspecific. CT and MRI can greatly assist in the diagnosis of CCA. ICCA takes up contrast agent progressively during the arterial and venous phases of studies—especially if the lesion is >2 cm, because of its extensive desmoplastic reaction. Other associated findings may include hepatic capsular retraction, vascular encasement that may lead to lobar atrophy, and dilatation of peripheral bile ducts. ICCA may be difficult to differentiate from a metastatic lesion (especially a metastasis from a foregut adenocarcinoma) by imaging and histology (45). A diagnosis of CCA cannot be confidently made with radiological imaging alone. If surgery is indicated for a patient with an FLL suspected of having underlying primary hepatic malignancy, a diagnostic biopsy may not be required because its results will not change the management strategy and may lead to seeding (2). In all other cases, a biopsy specimen should be obtained to confirm the diagnosis if CCA is suspected. Either CT or MRI is appropriate for the evaluation of tumor size, the presence of satellite lesions, the status of vascular structures, and for volumetric assessment of potential liver remnants, as these findings can be used to plan further treatment. Multidetector CT may be more accurate than MRI for predicting resectability, with an accuracy of 85% to 100%, and may be better for identifying extrahepatic metastases (46). The utility of PET in the diagnosis of CCA is limited and PET should not be used routinely; PET detects ICCA with sensitivity values ranging from 18% (for infiltrating types) to >80% (for mass-forming types) (47). Carbohydrate antigen 19-9 is a serum marker that can be measured to identify patients with ICCA, with 62% sensitivity and 63% specificity (48).

Table 2. Technical considerations for dynamic contrast-enhanced MRI and dynamic contrast-enhanced computerized tomography of the liver

Feature	Specification
<i>Dynamic contrast-enhanced MRI</i>	
Scanner	1.5-T or greater main magnetic field strength
Coil type	Phased array multichannel torso coil
Gradient types	Current-generation high-speed gradients (providing sufficient coverage)
Injector	Dual-chamber power injector recommended
Contrast injection rate	2–3 ml/s of gadolinium chelate
Minimum sequences	Precontrast and dynamic post-gadolinium T1-weighted gradient echo sequence (3D preferable), T2 (with and without FAT SAT), and T1w in- and out-of-phase imaging
Mandatory dynamic sequences	(i) <i>Arterial phase</i> . Artery fully enhanced, beginning contrast enhancement of portal vein (ii) <i>Portal venous phase</i> . Portal vein enhanced, peak liver parenchymal enhancement, beginning contrast enhancement of hepatic veins (35–55 s after the initiation of a late arterial phase scan) (iii) <i>Delayed phase</i> . > 120 s after the initial injection of contrast
Slice thickness	5 mm for dynamic series, 8 mm for other imaging
Breath holding	Maximum length of series requiring breath hold should be ~20 s with a minimum matrix of 128 _ 256
<i>Dynamic contrast-enhanced computerized tomography of the liver</i>	
Scanner type	Multidetector row scanner
Detector type	Minimum of 8 detector rows
Reconstructed slice thickness	Minimum reconstructed slice thickness of 5 mm
Injector	Power injector, preferably a dual-chamber injector with a saline flush
Contrast injection rate	Not less than 3 ml/s of contrast, 4–6 ml/s better with at least 300 mg I/ml or a higher concentration for a dose of 1.5 ml/kg of body weight
Mandatory dynamic phases on contrast-enhanced MDCT	(i) <i>Late arterial phase</i> . Artery fully enhanced, beginning contrast enhancement of portal vein. (ii) <i>Portal venous phase</i> . Portal vein enhanced, peak liver parenchymal enhancement, beginning contrast enhancement of hepatic veins (iii) <i>Delayed phase</i> . Variable appearance, > 120 s after the initial injection of contrast
FAT SAT, fat saturation; MDCT, multidetector computed tomography; MRI, magnetic resonance imaging. Adapted from Pomfret et al. (7).	

Treatment of CCA

When surgical resection can be offered for ICCA, the median survival time is 36 months, with a recurrence rate of 62.2% after a median of 26 months of follow-up (49). However, even in centers with expertise, <30% of all patients undergo curative resections (50). Liver transplantation is contraindicated in ICCA because of its poor results. For inoperable tumors, combination chemotherapy with gemcitabine plus cisplatin is the standard therapy (51).

Recommendations

- MRI or CT should be obtained if CCA is suspected clinically or by ultrasound (strong recommendation, low quality of evidence).
- A liver biopsy should be obtained to establish the diagnosis of CCA if the patient is nonoperable (strong recommendation, low quality of evidence).

BENIGN LIVER LESIONS

Hepatocellular adenoma

Hepatocellular adenoma is a benign neoplasm that arises *de novo* and may potentially have several risk factors. In select cases it may be stimulated by a metabolic or hormonal abnormality in the individual (52). Hepatocellular adenoma is rare with 0.007–0.012% of the population developing these lesions (53,54).

Risk factors for hepatocellular adenoma

In support of a causal relationship between the development of hepatocellular adenomas and hormonal abnormalities, a marked increase in hepatocellular adenomas has been noted in women taking oral contraceptive (OCP) therapy. The incidence of these lesions in women not taking OCPs is 1–1.3 per million, whereas in those taking OCPs the frequency has been higher at 34 per 1 million (55). Strengthening this causal relationship, hepatocellular adenomas tend to regress after the discontinuation of OCP therapy

(56,57). Along with OCP use, anabolic androgen steroids have also been associated with the development of hepatocellular adenomas (58,59). Males taking androgens are not the only individuals at risk from hormonal abnormalities. Males and females with high levels of endogenous androgens or estrogens are also at risk of developing hepatocellular adenomas (60).

Individuals with glycogen storage disease (GSD) Ia and III are also at an increased risk for hepatocellular adenomas. There is a 2:1 male to female ratio in GSD patients who develop hepatocellular adenomas. In addition, patients >25 years of age with GSD have a dramatic increase in the incidence of hepatocellular adenomas (61). The majority of GSD Ia-related cases are of the inflammatory hepatocellular adenoma subtype (62). Managing hepatocellular adenomas in patients with GSD requires treatment strategies unique to this population. Tumor size has been shown to decrease as a result of continuous nocturnal feeding (63). Despite higher morbidity in GSD patients, surgical resection to prevent tumor progression is a feasible intermediate step until definitive treatment with liver transplantation can be achieved (64).

Obesity and features of the metabolic syndrome such as diabetes mellitus, insulin resistance, hypertension, and dyslipidemia are becoming increasingly recognized in the United States and Europe as risk factors for hepatocellular adenomas (65,66). Obesity and metabolic syndrome are frequently observed in patients with hepatocellular adenomas. In addition to promoting the development of hepatic lesions, obesity and metabolic syndrome are also postulated to increase the risk of hepatocellular adenomas progression (65). Obese patients who use OCP are likely at an increased risk for hepatocellular adenomas, as studies reveal that 70–95% of obese patients who develop these lesions have a history of OCP use (65,66). Although OCP use in combination with metabolic syndrome places women at a greater risk than men for the development of hepatocellular adenomas, the prevalence of transformation of hepatocellular adenomas to HCC is 10 times more likely in males, with metabolic syndrome the most frequently associated condition for this transformation (67).

Clinical variants of hepatocellular adenoma

Liver adenomatosis. Multiple adenomas, defined as between >3 and ≥ 10 lesions, are collectively referred to as liver adenomatosis (68,69). These multiple lesions have identical clinical, histological, and radiographic features as hepatocellular adenomas and are managed in the same manner (52). There is accumulating evidence that the phenotype of hepatic adenomas has changed over the past few years. The lesions encountered in those with the metabolic syndrome tend to be multiple and may have associated hemangioma and focal nodular hyperplasia (FNH) lesions. Their precise pathogenesis is unclear. Of interest, preliminary retrospective analysis has noted stability or regression of these lesions with weight loss (65).

Telangiectatic hepatocellular adenoma

Previously known as telangiectatic focal nodular hyperplasia, telangiectatic hepatocellular adenoma (THCA) has recently been reclassified as a subcategory of inflammatory hepatocellular

adenoma. The aggressive management of THCA as compared with the conservative management of FNH and the resemblance of hepatocellular adenomas to THCA at the molecular level propelled the shift in classification (52). OCP use, hormonal therapy, and obesity are frequently associated with the development of THCA (70–72). In addition, up to 40% of patients with THCA typically present concomitantly with another benign liver lesion (70,72). THCA should be managed as aggressively as hepatocellular adenomas as they are likely to be symptomatic, prone to hemorrhage, and may contain focal areas of necrosis (71,72). The high likelihood of hemorrhage combined with an unknown potential of transformation to HCC makes surgery the recommended treatment (52,72).

Diagnostic characteristics of hepatocellular adenoma

The multiple variants of hepatocellular adenomas are typically symptomatic, with incidental discovery occurring in only 15–25% of cases (55,73). Although CT can be used to diagnose hepatocellular adenomas, recent findings suggest that not only can MRI be used to diagnose hepatocellular adenomas, but it can also identify the subtypes of hepatocellular adenomas based on the imaging patterns, obviating the need for biopsy to distinguish these subtypes (52,74). MRI enhanced with gadobenate dimeglumine or gadoxetate disodium can be very effective in differentiating hepatocellular adenomas from FNH and other lesions, as shown in **Table 3** (52,75).

Liver biopsy can aid in identifying the subtype of hepatocellular adenomas as each category has specific genetic and molecular markers. However, the vascular nature of hepatic lesions coupled with their propensity to hemorrhage can make biopsy risky. Thus, biopsy should be reserved for cases in which imaging is inconclusive and the results will have an impact on treatment decisions (52).

Hepatocellular adenoma and pregnancy

Hepatocellular adenomas have been known to increase in size during pregnancy (52). The infrequency of these lesions has hindered an evidence-based algorithm for the evaluation and management of hepatocellular adenomas in pregnant women. Instead of advocating contraindication to pregnancy in all cases of hepatocellular adenomas, an individualized approach is advocated in which pregnancy is not discouraged when lesions are <5 cm (76). A study being conducted in the Netherlands will evaluate this approach and further elucidate management strategies for pregnant women with hepatocellular adenomas (77).

Management of hepatocellular adenoma

The management of hepatocellular adenomas requires treatment strategies that are more aggressive than that for most other benign hepatic lesions because of the potential for hepatocellular adenomas to hemorrhage or progress to HCC (52). Hemorrhage has been reported in 11–29% of hepatocellular adenomas cases, with nearly all instances of spontaneous rupture occurring in lesions ≥ 5 cm (78–80). Thus, resection should be considered when hepatocellular adenomas are found to be ≥ 5 cm.

Nonsurgical modalities such as embolization can be pursued as an alternative to resection in high surgical risk patients or in patients with lesions in anatomically challenging locations. In cases where hemorrhage does occur, conservative management using blood products is a temporary approach to achieve hemodynamic stability and avoid emergent liver resection (81). Packing the liver, performing an emergency hepatectomy, embolizing the hepatic artery, or even liver transplantation can be used to control hemorrhage (81,82). Hepatocellular adenomas of the β -catenin subtype should be considered for early referral for resection as malignant transformation occurs most frequently in this subtype, occurring in up to 5–10% of cases (52,78,83,84).

Hepatocellular adenomas <5 cm can be managed conservatively as these lesions are rarely observed to rupture or undergo malignant transformation (85). Nevertheless, some hepatocellular adenomas have been reported to increase in size despite the discontinuation of OCP or anabolic steroids, and the development of HCC has been reported despite regression in size (86–88). Thus, follow-up imaging should be conducted once every 6 months for at least 2 years to establish any growth patterns and monitor for malignant transformation. Annual imaging can be performed after this period based on the growth patterns and stability of the lesion (89).

Recommendations

7. Oral contraceptives, hormone-containing intrauterine devices, and anabolic steroids are to be avoided in patients with hepatocellular adenoma (strong recommendation, moderate quality of evidence).
8. Obtaining a biopsy should be reserved for cases in which imaging is inconclusive and biopsy is deemed necessary to make treatment decisions (strong recommendation, low quality of evidence).
9. Pregnancy is not generally contraindicated in cases of hepatocellular adenoma <5 cm and an individualized approach is advocated for these patients (conditional recommendation, low quality of evidence).
10. In hepatocellular adenomas \geq 5 cm, intervention through surgical or nonsurgical modalities is recommended, as there is a risk of rupture and malignancy (conditional recommendation, low quality of evidence).
11. If no therapeutic intervention is pursued, lesions suspected of being hepatocellular adenoma require follow-up CT or MRI at 6- to 12-month intervals. The duration of monitoring is based on the growth patterns and stability of the lesion over time (conditional recommendation, low quality of evidence).

HEPATIC HEMANGIOMA

Hepatic hemangiomas are benign vascular liver lesions of unknown etiology that are thought to arise from congenital hamartomas. Alternatively, hepatic hemangiomas could result from dilation of existing blood vessels in tissues that developed normally. The observed increase in the size of the lesions is thought to result

from progressive ectasia rather than hyperplasia or hypertrophy (52). Hepatic hemangiomas are the most common benign hepatic tumors with a prevalence of 0.4–20% identified during autopsy (53,90). The actual frequency of clinically relevant cases is more likely 0.7–1.5%, as indicated by US studies (91,92).

There is no causal link between hepatic hemangiomas and pregnancy or OCP use. However, hepatic hemangiomas are found earlier, are larger, and are more often found in women than in men, with a 5 to 1 female to male preponderance (93,94). These observations, combined with reports that these lesions grew in size during pregnancy and OCP use, suggested that female sex hormones may have a role in their pathogenesis (52,95,96). However, no direct causal link between OCP use and hepatic hemangioma was found in a case-control study (97). Thus, the relationship between hormonal involvement and the development of hemangioma is unsubstantiated and is not a precondition for development, as hemangiomas are also observed in men, in women with no history of OCP use, and in postmenopausal women (52).

Diagnostic characteristics of hepatic hemangioma

Hepatic hemangiomas can be found in all age groups, although they are typically discovered in those between the ages of 30 and 50 years. Most of these lesions are asymptomatic and are discovered incidentally during imaging studies (52). Hemangiomas occur with symptoms in ~11–14% of all hepatic hemangioma cases (98,99). The most common presentations are right upper quadrant pain or a mass felt in the epigastrium. Both are likely secondary to pressure or displacement of adjacent anatomical structures by the lesions. Other common symptoms include severe pain, nausea, dyspepsia, early satiety, vomiting, weight gain, and hepatomegaly (52). In rare cases, giant hemangiomas may cause consumptive coagulopathy known as Kasabach–Merritt syndrome that manifests as thrombocytopenia, disseminated intravascular coagulation, and systemic bleeding (100).

CT, MRI, and US studies are reliable in establishing a diagnosis of hepatic hemangioma as this lesion displays unique features upon imaging with peripheral nodular enhancement and progressive centripetal fill-in, as outlined in **Table 3**. MRI is preferred in cases where the lesion is <3 cm or found close to the heart or intrahepatic vessels (52). Contrast-enhanced US, if available, can increase both the sensitivity and specificity of US and is effective in diagnosing hepatic hemangioma (101).

Spontaneous bleeding of hemangiomas is rare. However, owing to its highly vascular nature, biopsy should be avoided because of the risk of potential bleeding. Furthermore, the high sensitivity and specificity of radiologic studies in the diagnosis of hepatic hemangioma obviates the need for a biopsy. In cases of smaller lesions where there is uncertainty in the diagnosis, a follow-up imaging study may be more prudent than a biopsy (52).

Management of hepatic hemangioma

The majority of hemangiomas are asymptomatic and remain stable over time (102). Thus, preventing rare complications with

Table 3. Imaging characteristics of solid liver lesions

Lesion	US	CT	MRI
HCA	Heterogeneous; hyperechoic if steatotic but anechoic center if hemorrhage	Well demarcated with peripheral enhancement; homogenous more often than heterogeneous; hypodense if steatotic, hyperdense if hemorrhagic	HNF1 α : signal lost on chemical shift; moderate arterial enhancement without persistent enhancement during delayed phase IHCA: markedly hyperintense on T2 with stronger signal peripherally; persistent enhancement in delayed phase β -Catenin: inflammatory subtype has same appearance as IHCA; noninflammatory is heterogeneous with no signal dropout on chemical shift, isointense of T1 and T2 with strong arterial enhancement and delayed washout
THCA	Variable appearance	Hypo- to isoattenuating	T1: heterogeneous and well-defined iso- to hyperintense mass. Strongly hyperintense with persistent contrast enhancement in delayed phase
Hemangioma	Hyperechoic with well-defined rim and with few intranodular vessels	Discontinuous peripheral nodular enhancement isoattenuating to aorta with progressive centripetal fill-in	T1: hypointense; discontinuous peripheral enhancement with centripetal fill-in T2: hyperintense relative to spleen
FNH	Generally isoechoic	Central scar. Arterial phase shows homogenous hyperdense lesion; returns to precontrast density during portal phase that is hypo- or isodense	T1: isointense or slightly hypointense. Gadolinium produces early enhancement with central scar enhancement during delayed phase T2: slightly hyperintense or isointense
NRH	Isoechoic/hyperechoic	Nonenhancing nodules, sometimes hypodense, with variable sizes (most sub-centimeter)	T1: hyperintense T2: varied intensity (hypo/iso/hyperintense)

CT, computed tomography; FNH, focal nodular hyperplasia; HCA, hepatocellular adenoma; HNF1 α , hepatocyte nuclear factor-1 α ; IHCA, inflammatory hepatocellular adenoma; MRI, magnetic resonance imaging; NRH, nodular regenerative hyperplasia; THCA, telangiectatic hepatocellular adenoma; US, ultrasonography. Adapted from Shaked *et al.* (52).

surgical intervention is not needed, and instead a conservative approach is advocated. Surgical intervention can be considered in cases where the lesion grows very large (> 10 cm) or the patient begins to report symptomatic compression or recurrent pain (52,103). Follow-up imaging is not required in cases of classical hemangioma.

Recommendations

- An MRI or CT scan should be obtained to confirm a diagnosis of hemangioma (strong recommendation, moderate quality of evidence).
- Liver biopsy should be avoided if the radiologic features of a hemangioma are present (strong recommendation, low quality of evidence).
- Pregnancy and the use of oral contraceptives or anabolic steroids are not contraindicated in patients with a hemangioma (conditional recommendation, low quality of evidence).
- Regardless of the size, no intervention is required for asymptomatic hepatic hemangiomas. Symptomatic patients with impaired quality of life can be referred for surgical or non-surgical therapeutic modalities by an experienced team (conditional recommendation, low quality of evidence).

FOCAL NODULAR HYPERPLASIA

FNH is the second most common hepatic lesion and is found at autopsy with a prevalence of 0.3–3% (53,90). Clinically relevant

cases of FNH are rare with a reported prevalence in US studies of 0.03% (54). The development of focal nodular hyperplasia is caused by an injury to the portal tract resulting in the formation and enlargement of arterial to venous shunts (104). This in turn causes hyperperfusion in local arteries resulting in oxidative stress that triggers a response from hepatic stellate cells to produce the central scar typically seen in cases of FNH (52,105).

Diagnostic characteristics of FNH

Although 20–40% of cases of FNH may present with symptoms, most are discovered incidentally (106,107). Up to 20% of cases are associated with a concomitant diagnosis of hepatic hemangioma (108). In addition, other hypervascular tumors such as hepatocellular adenomas and HCC have been observed concurrently with FNH, and this supports the notion that FNH may develop in the background of vascular malformations (52,109,110). FNH is noted primarily in women in their 40s and 50s (111,112). Female sex hormones were suspected to have a role in FNH development as not only is the prevalence higher in women but also women tend to develop larger and earlier lesions compared with men. However, changing OCP use over time has not led to alterations in the prevalence of FNH, and pregnancy has not been associated with an increase in tumor size, making this association less likely (113,114).

Identification of classic FNH by way of its “spoke-wheel” central scar on cross-sectional imaging is relatively straightforward (Table 3). Ambiguous cases that cannot exclude hepatocellular

adenomas must be differentiated accurately as FNH or hepatocellular adenomas as their management differs significantly (52). The diagnostic accuracy of MRI for FNH has improved because of the improvement in hepatobiliary contrast agents, such as gadobenate dimeglumine (115,116). In addition, adherence to the technical specifications of triphasic and multisection spiral CT (Table 2) has been reported to accurately diagnose FNH (117,118). Improvements in imaging have been made with the use of contrast-enhanced US that has been shown to be similarly accurate as MRI and CT in identifying FNH, but its use in the United States has been limited (119). In cases where FNH cannot be distinguished from hepatocellular adenomas, immunohistochemical analysis performed on biopsy specimens can discriminate FNH from hepatocellular adenomas with good performance characteristics (120).

Management of FNH

Most cases of FNH are asymptomatic and stable over time (121). In addition, the occurrence of HCC and spontaneous rupture are rare (122–124). Thus, a conservative approach should be taken when managing FNH. However, further evaluation of symptomatic lesions in which a diagnosis of FNH cannot be firmly established is recommended. Although partial hepatic resection is the most common intervention, embolization and radiofrequency ablation have more recently been utilized as they are associated with fewer complications and lower morbidity (125–127). Follow-up annual US for 2–3 years is prudent in women diagnosed with FNH who wish to continue OCP use. Individuals with a firm diagnosis of FNH who are not using OCP do not require follow-up imaging.

Recommendations

16. An MRI or CT scan should be obtained to confirm a diagnosis of FNH. A liver biopsy is not routinely indicated to confirm the diagnosis (strong recommendation, low quality of evidence).
17. Pregnancy and the use of oral contraceptives or anabolic steroids are not contraindicated in patients with FNH (conditional recommendation, low quality of evidence).
18. Asymptomatic FNH does not require intervention (strong recommendation, moderate quality of evidence).
19. Annual US for 2–3 years is prudent in women diagnosed with FNH who wish to continue OCP use. Individuals with a firm diagnosis of FNH who are not using OCP do not require follow-up imaging (conditional recommendation, low quality of evidence).

NODULAR REGENERATIVE HYPERPLASIA

Nodular regenerative hyperplasia (NRH) is the transformation of normal hepatic parenchyma into small regenerative nodules. NRH is believed to be a secondary consequence of altered blood flow in which obstructive portal venopathy, due to thrombosis or phlebitis, causes ischemia. This, in turn, leads to hyperplasia of hepatic acini to maintain adequate blood flow to compensate for atrophied hepatocytes. This process forms nodules that are sepa-

rated by atrophic areas with little to no fibrosis (52). NRH has a prevalence of over 5.3% in individuals >80 years old (128). The general population presents with NRH at a lower frequency of 2.1–2.6%. No apparent relationship is found between NRH and gender. A number of conditions do seem to be associated with NRH, including immunological and hematological disorders, cardiac and pulmonary disorders, several drugs and toxins, neoplasias, and organ transplantation (128,129).

Diagnostic characteristics of NRH

NRH is most commonly discovered incidentally. Symptomatic cases are rare and most often present with features of portal hypertension, such as ascites, splenomegaly, hepatomegaly, and esophageal varices (128–130). Imaging studies are insufficient in establishing a definitive diagnosis of NRH. The lesions are routinely too small to observe radiographically and, when visualized, too difficult to distinguish from the regenerating nodules of cirrhosis (131). The definitive method for establishing a conclusive diagnosis of NRH is biopsy. Although NRH shares common features with micronodular cirrhosis, three histological criteria—nodules of regenerative hepatocytes separated by atrophic parenchyma, absence of fibrous septa between nodules, and curvilinear compression of the central lobule—can be used to distinguish NRH from cirrhosis (132–134). There are no reliable tumor markers known to be useful for diagnosing NRH.

Management of NRH

Treating NRH requires addressing the underlying etiological condition. The β -blocker prophylaxis and/or endoscopic therapy for esophageal varices, pharmacologic therapy of ascites, and transjugular intrahepatic portosystemic shunts are possible forms of treatment when NRH is complicated by portal hypertension (135). Although very rare, NRH can lead to liver failure that may require treatment with liver transplantation (136). As NRH is commonly associated with other underlying disease processes, follow-up care requires determining and managing the underlying disease. There are no absolute contraindications to pregnancy or the use of OCPs.

Recommendations

20. Liver biopsy is required to confirm the diagnosis of NRH (strong recommendation, moderate quality of evidence).
21. Pregnancy and the use of oral contraceptives or anabolic steroids are not contraindicated in patients with an NRH (conditional recommendation, low quality of evidence).
22. Asymptomatic NRH does not require intervention (conditional recommendation, low quality of evidence).
23. Management of NRH is based on diagnosing and managing any underlying predisposing disease processes (strong recommendation, low quality of evidence).

HEPATIC CYSTS

Hepatic cysts typically present for evaluation upon being found incidentally on imaging studies. Early laparotomy series reported

Table 4. Imaging characteristics of cystic liver lesions

Lesion	US	CT	MRI
Simple hepatic cysts (SHCs)	Anechoic, homogeneous, fluid filled. Smooth margins	Well-demarcated, water-attenuated, smooth lesion without an internal structure. No enhancement with contrast	Well-defined, homogeneous lesion. No enhancement with contrast. T1: hypointense signal intensity T2: hyperintense signal intensity
Biliary cystadenomas (BCs)	Irregular walls, internal septations forming loculi	Heterogeneous septations, internal septations, irregular papillary growths, thickened cyst walls	May appear heterogeneous. T1: Hypointense signal intensity T2: Hyperintense signal intensity
Polycystic liver disease (PCLD)	Multiple hepatic cysts, similar in characteristics to SHC US findings	Multiple hepatic cysts, similar in characteristics to SHC CT findings	Multiple hepatic cysts, similar in characteristics to SHC MRI findings
Hydatid cysts (HCs)	May appear similar to SHC. Progress to develop thick, calcified walls, hyperechoic/hypoechoic contents. Daughter cysts in periphery.	Hypodense lesion with hypervascular pericyst wall, distinct endocyst wall. Calcified walls and septa easily detected. Daughter cysts seen peripherally within mother cyst.	T1: Hypointense signal intensity of cyst contents. T2: Hyperintense signal intensity of cyst contents. Hypointense rim on T2. Daughter cysts seen peripherally within mother cyst. Collapse parasitic membranes seen as floating linear structures within cyst.

CT, computed tomography; MRI, magnetic resonance imaging; US, ultrasonography.

a prevalence of 0.2 to 1% (137). US series have reported a 3–5% prevalence in the population, whereas CT series have reported the prevalence to be as high as 15–18% (138–142). Given the increased use of cross-sectional imaging, hepatic cysts are an increasingly common finding that has led to a growing awareness of their existence. **Table 4** outlines the imaging characteristics of common cystic FLLs. Although the natural history of simple hepatic cysts has not been well elucidated, they are not thought to be premalignant precursors to the development of biliary cystadenomas (BCs) or biliary cystadenocarcinomas (BCAs). Optimal management of incidentally found hepatic cysts is not clear because of the lack of rigorous clinical studies. Nevertheless, it has been observed that the vast majority of hepatic cysts are predominantly benign, and in the absence of characteristic features suggestive of BC, BCA, polycystic liver disease (PCLD), or hydatid cysts they can be managed expectantly. The presence of multiple cysts (>20), large cysts (>4–5 cm), septations, calcifications, fenestrations, loculations, heterogeneity, daughter cysts, or symptoms on presentation are not characteristic of simple hepatic cysts and should prompt further diagnostic evaluation. Suspected biliary cystadenomas and BCAs should be completely resected. The management of PCLD and hydatid cysts is variable, based on the clinical presentation, the size, location, and number of lesions, as well as the experience of the managing team.

Simple hepatic cysts

Simple hepatic cysts are postulated to be congenital exclusions of hyperplastic bile duct rests that lack a communication with biliary ducts (93,143). They are composed of an outer layer of fibrous tissue and are lined by a cuboidal, columnar epithelium that continually produces cystic fluid (137). Simple hepatic cysts are usually <1 cm and can grow up to 30 cm (144,145). Simple hepatic cysts are uncommon before the age of 40 years and have

a female predilection of 1:4 (146,147). However, there is no clear correlation with oral contraceptive use or pregnancy. They are usually asymptomatic and discovered incidentally, although larger lesions may present with abdominal pain, epigastric fullness, or early satiety. Infrequently, internal hemorrhage, infection, or rapid enlargement can lead to symptoms and presentation for clinical evaluation. Thus, the presence of symptoms or a rapid increase in size on follow-up imaging should lead to consideration of alternative diagnosis such as biliary cystadenoma (BC) or BCA (148,149).

Diagnostic characteristics of simple hepatic cysts

Ultrasound typically reveals an anechoic, homogenous, fluid-filled lesion with smooth margins. CT shows a well-demarcated, water-attenuated, smooth lesion without an internal structure, and no enhancement with contrast. Similarly, MRI shows a well-defined, homogeneous lesion with low signal intensity on T1 weighting, and high intensity on T2, without contrast enhancement. The differential diagnosis includes BCA, PCLD, hydatid cysts, cystic metastases from primary cystic tumors, and cystic necrosis of large solid neoplasms. Cysts that have internal septations, fenestrations, calcifications, irregular walls, or daughter cysts on US should be evaluated with CT or MRI for features of BCA or hydatid cysts. Aspiration of fluid contents is not needed to diagnose simple hepatic cysts and is not recommended. However, if done, the findings should show normal fluid carbohydrate antigen 19-9 levels and negative testing for cytology.

Management of simple hepatic cysts

There is a paucity of randomized controlled trials and a lack of long-term follow-up outcome data comparing treatment methods for simple hepatic cysts. These limitations make it difficult to

make evidence-based recommendations with strong support from the literature. Nevertheless, several basic dictums are found in the literature that require strong consideration. First, incidentally identified asymptomatic cysts do not need follow-up or treatment (150). Second, hepatic cysts that are symptomatic because of hemorrhage, rupture, infection, or growth merit intervention. Simple aspiration is not recommended as it leads to universal recurrence. Beyond these basic statements, and once a decision has been made to intervene on a simple hepatic cyst, no definitive, evidence-based recommendations can be made regarding the optimal mode of intervention.

Treatment modality may be determined by the operative candidacy of the patient. Open surgical cyst fenestration, also known as deroofting or marsupialization, which leaves the cysts open to drain into the peritoneal cavity, has been reported to be successful in up to 90% of cases (151–156). Patients who are not surgical operative candidates or who decline surgery can be managed with radiologic cyst aspiration and sclerotherapy with alcohol or other sclerosants (157). Although this approach is associated with a high recurrence rate, it may be appropriate for patients who are not surgical candidates (158–160). Laparoscopic approaches to fenestration were reported beginning in the 1990s, and have been quickly adopted, where available, as the standard approach compared with open laparotomy, because of reported success rates matching open approaches along with reductions in morbidity and length of hospital stay. Laparoscopic deroofting may be the preferred therapeutic strategy where available (157,161–163). Regardless of the approach, the decision to pursue surgical intervention is often driven by the uncertainty of the underlying diagnosis of simple hepatic cysts, and the inability to unequivocally exclude malignancy without a histological evaluation (164). Thus, an important factor in selecting surgical intervention is that it allows histological examination of the cyst to exclude biliary cystadenomas and biliary cystadenocarcinomas. Nevertheless, it is imperative to complete a thorough evaluation for alternative causes of the patient's complaints before proceeding with invasive interventions to avoid diagnostic dilemma and therapeutic frustration of persistence of symptoms despite treatment directed toward the ostensibly symptomatic hepatic cyst. Overall, comparison studies between aspiration, fenestration, and laparoscopic versus open approaches have been limited by heterogeneous methods, variable outcomes reported, small number of patients reported, short follow-up times, and single-center experiences (153). Once intervention has been deemed necessary, the mode of treatment should be dictated by the local availability of surgical and radiologic expertise and patient preference on an individual basis.

Recommendations

24. A hepatic cyst identified on US with septations, fenestrations, calcifications, irregular walls, or daughter cysts should prompt further evaluation with CT or MRI (strong recommendation, low quality of evidence).
25. Asymptomatic simple hepatic cysts should be observed with expectant management (strong recommendation, moderate quality of evidence).

26. Aspiration of asymptomatic, simple hepatic cysts is not recommended (strong recommendation, low quality of evidence).
27. Symptomatic simple hepatic cysts may be managed with laparoscopic deroofting rather than aspiration and sclerotherapy, dictated based on availability of local expertise (conditional recommendation, low quality of evidence).

BILIARY CYSTADENOMAS AND BILIARY CYSTADENOCARCINOMAS

Biliary cystadenomas are congenitally derived, aberrant bile duct remnants composed of three layers of tissue. Early pathophysiologic suppositions regarding an origin from heterotopic ovarian tissue have been disproven by recent immunohistochemistry and electron microscopy studies (165). The outer layer of thick collagen and mixed connective tissue surrounds a middle layer of mesenchymal smooth muscle cells and fibroblasts, and an inner lining of cuboidal/columnar epithelium that typically secretes mucin (134). Grossly, BCs have a heterogeneous interior with septations forming multiple loculations filled with mucinous (95%) or serous (5%) material (144). Some BCs have papillary projections that form thick, compact septa (166–169).

Biliary cystadenomas are reported to constitute up to 1–5% of total hepatic cysts, and up to 10% of cysts >4 cm (161). There are no known associations with the use of oral contraceptives, although the 1:4 female predilection suggests a possible hormonal involvement (170). Although rare, BC is the most common form of a primary hepatic cystic neoplasm. Biliary cystadenomas are thought to be precursors to the development of BCA, although it is difficult to predict progression or clearly identify characteristics that herald such progression (144,166,170,171). Although symptoms are rare, they are often correlated with the increasing size of the lesions leading to mass effect and abdominal discomfort, nausea, early satiety, or anorexia (155,170). Smaller BCs are typically discovered incidentally on imaging. The presence of calcifications along with mixed solid and cystic components on imaging as well as constitutional symptoms has been reported to be associated with BCA.

Diagnostic characteristics of biliary cystadenomas

US typically shows irregular walls and internal septations forming loculi. US is most sensitive in identifying these internal septations. If a complex cyst is found on US, cross-sectional imaging with CT and MRI should be obtained. CT and MRI can help confirm the findings of heterogeneous septations, irregular papillary growths, and thickened cyst walls (172,173). The cysts are typically hyperintense on T2 weighting, although because of mucinous content they may appear heterogeneous (174). Aspiration and biopsy is not recommended for focusing the differential because it has limited sensitivity and can disseminate malignancy if there is underlying BCA (175,176). Although imaging can suggest the possibility of BC or BCA, surgical resection is ultimately necessary to confirm and treat the suspected BC or BCA.

Management of biliary cystadenomas

If BC or BCA is suspected on imaging, referral for surgical consultation should be made. Full surgical excision of any suspected BC is recommended given the high risk of recurrence, difficulty in preoperative differentiation and exclusion, and possible risk of progression to BCA if only partial excision is performed (169,177–179). Because of the presence of pseudocapsules, enucleation may be a feasible alternative (180). There is a dearth of trials comparing laparoscopy versus open laparotomy in managing BC or BCAs. Although data are limited, where available, the laparoscopic approach has gradually replaced open laparotomy as the modality of choice in surgical intervention for BC and BCA based on reported reductions in surgical morbidity and complications. Preference should be given for referral to an experienced surgical team given the challenges of both open and laparoscopic approaches to BC and BCA excision (152,181). If the patient is not a surgical candidate, monitoring with repeat imaging should be performed.

Recommendations

28. Routine fluid aspiration is not recommended when BCA is suspected because of limited sensitivity and the risk of malignant dissemination (strong recommendation, low quality of evidence).
29. Imaging characteristics suggestive of BC or BCA, such as internal septations, fenestrations, calcifications, or irregular walls, should lead to referral for surgical excision (strong recommendation, low quality of evidence).
30. Complete surgical excision, by an experienced team, is recommended if BC or BCA is suspected (strong recommendation, low quality of evidence).

POLYCYSTIC LIVER DISEASE

PCLD is thought to be a part of a clinical spectrum of ciliopathies including congenital hepatic fibrosis, choledochal cysts, microhamartomas, and Caroli's disease that are associated with mutations that impair cholangiocyte ciliary function. PCLD is characterized by the presence of extensive hepatic cysts that are microscopically similar to simple hepatic cysts but more numerous (usually >20) and larger (182). Descriptions of the various types of PCLD are beyond the scope of this guideline, but can be summarized as three main types. The most common is autosomal dominant polycystic kidney disease with PCLD. The majority of these patients have renal failure from renal cysts, and 60% have phenotypic expression of multiple hepatic cysts (183,184). Autosomal dominant PCLD has a more benign prognosis compared with polycystic kidney disease and is mainly asymptomatic (185). The rarest is autosomal recessive polycystic kidney disease that has a high infant mortality and in which hepatic cysts are not a prominent feature.

Diagnostic characteristics of PCLD

PCLD is rare with autopsy series reporting 0.13% and US studies reporting 0.9% prevalence (141,186). There is a female predilec-

tion and a noted increase in the size of hepatic cysts and symptoms with age. Pregnancy and female hormones are also thought to be risk factors for an increase in the size and number of hepatic cysts (147). PCLD tends to be asymptomatic until the size and number of cysts increase to a critical level. Patients are typically more likely to have hepatomegaly and symptoms from mass effect, such as abdominal bloating, pain, fullness, and shortness of breath, when the cyst to hepatic parenchyma ratio becomes >1. Patients may also present with complications such as traumatic rupture, infection, bleeding, extrinsic compression of the biliary tree or gastrointestinal tract, and compression of the inferior vena cava (187). In advanced cases, patients may develop portal hypertension with relatively preserved hepatic synthetic function (188). The diagnosis of PCLD is supported by the presence of multiple hepatic cysts on US, CT, or MRI. CT or MRI may provide additional information to exclude other disease processes and to evaluate for the presence of concomitant renal cysts.

Management of PCLD

Treatment of PCLD is guided by the presence of symptoms that are often directly related to the volume of the liver rather than to specific cysts. Therefore, treatment should be focused on decompressing the liver or reducing the cyst volume as much and as safely as possible. Some recent interest in medical therapy has been stirred by reports of the use of somatostatin analogs and mammalian target of rapamycin inhibitors (189–195). However, despite these promising reports, their use outside of clinical studies cannot be recommended at this point because of uncertainty regarding their long-term efficacy, safety, as well as optimal dosing and duration of treatment.

The data defining the optimal management choice for PCLD between aspiration, fenestration, resection, and transplantation as well as between laparoscopic versus open approaches are limited to small-scale clinical series or case reports. Thus, treatment should be guided by the principle of selecting the least invasive procedure that provides the most effective treatment response and improvement in the quality of life. Aspiration of a large, single cyst or a small number of large cysts may be appropriate, although associated with high recurrence rates. Deroofing or fenestration can provide a less transient response, although it is still associated with a 30–70% recurrence. Growth of multiple hepatic cysts stretches and distorts the anatomy, making it difficult to recognize and avoid damage to bile ducts and vasculature during surgical intervention. Complications such as ascites, hemorrhage, bile leakage, and pleural effusion can occur from such inadvertent damage (162,182,196). In addition to these complications, hepatic resection also carries the risk of hepatic insufficiency if an inadequate hepatic remnant is left. Moreover, resection and surgical treatment can cause adhesions that may complicate possible future procedures such as liver transplantation. Thus, treatment must be tailored to the individual presentation, cyst size and location, vascular patency, and hepatic reserve (197,198). Despite the challenges of these surgical interventions, the laparoscopic approach has been widely adopted, where available (151,152). Finally, liver transplantation with or without concomitant kidney transplantation has been reported for very

symptomatic patients with hepatic failure and/or poor quality of life (162,199–202). Outcomes have been reported to be comparable or superior to other indications for liver transplantation, with 1-year survival of 90% and 5-year survival of 70–80% (203,204). Nevertheless, strong recommendations cannot be made because of the overall limitations of the currently available data.

Recommendations

31. Routine medical therapy with mammalian target of rapamycin inhibitors or somatostatin analogs is not recommended (strong recommendation, low quality of evidence).
32. Aspiration, deroofting, resection of a dominant cyst can be performed based on the patient's clinical presentation and underlying hepatic reserve (conditional recommendation, low quality of evidence).
33. Liver transplantation with or without kidney transplantation can be considered in patients with refractory symptoms and significant cyst burden (conditional recommendation, low quality of evidence).

HYDATID CYSTS

Hydatid cysts, or cystic echinococcosis, are most common in patients from sheep-grazing areas such as the Mediterranean, South America, Australia, and East Africa. Hydatid cysts are due to *Echinococcus granulosus* infection in which humans serve as accidental intermediate hosts when they eat food contaminated with echinococcus eggs or eat organ meat from infected animals such as sheep or cows. The eggs hatch in the human host small intestine and penetrate into the vasculature and then into the liver and lungs. The cysts become visible in the liver at 3 to 4 weeks and grow into a mature cyst that has a germinal layer surrounding a fluid-filled central hydatid cavity. The cysts develop an ectocyst or pericyst in response to the compressive forces of the host's liver parenchyma. The cyst can have high pressure from fluid production that can lead to rupture after trauma or operative manipulation.

Most small cysts, <5 cm, are asymptomatic. Larger cysts can elicit an inflammatory reaction and may lead to abdominal pain. An acute presentation with pain should lead to consideration of rupture or secondary infection of the cyst. The incidental rupture or iatrogenic puncture of the cyst with spillage of its antigenic contents can lead to a severe allergic reaction, leading to ascites, peritonitis, and shock. Rarely, the cysts can extrude into the biliary tree, leading to jaundice and cholangitis.

Diagnostic characteristics of hydatid cysts

On US, small hydatid cysts may appear similar to simple hepatic cysts as a unilocular collection. With progression, the lesions may develop a thick, often calcified wall and daughter cysts in the periphery of the main cyst. A classification system has been proposed by the World Health Organization (WHO) Informal Working Group on Echinococcosis in an attempt to classify hydatid cysts based on US findings correlated to their activity and natural history. This has superseded the Gharbi classification (205). How-

ever, the interobserver variability in classifying the stage as well as uncertainty regarding the natural history of hydatid cysts has led to limitations in the utilization of these classification systems in routine clinical practice. CT and MRI can provide more precise information on the cyst morphology and presence of daughter cysts and should be obtained if hydatid cysts are suspected (206). MRI is preferred for presurgical evaluation to look for cystobiliary communication and evaluate cystic content characteristics.

Management of hydatid cysts

Treatment of hydatid cysts depends on the size, location, and symptoms of the cysts as well as the availability of clinical expertise and patient preferences (207). The evidence level is low regarding treatment modality comparisons in terms of efficacy and safety. Asymptomatic, inactive, calcified hydatid cysts can be managed expectantly. Chemotherapy alone with antihelminthic drugs such as albendazole and mebendazole for symptomatic hydatid cysts is generally not utilized unless the patient is not a candidate for primary percutaneous or surgical treatment, has multiorgan dissemination, or declines other intervention. A systematic review that reported that >40% of hydatid cysts remain active or reactivate after 2 years of monotherapy with chemotherapy has dampened enthusiasm for the approach of expectant management (208). Chemotherapy as an adjunct treatment to other modalities is recommended before and after percutaneous treatment or surgery to prevent relapse (209,210). Nevertheless, strong recommendations regarding the timing of treatment initiation and conclusion, exact duration of treatment, and optimal dosing regimens cannot be made on the basis of currently available data. Traditionally, expert opinion has recommended that chemotherapy be started before the procedure and at least 1 month to 6 months afterward (211).

PAIR (puncture, aspiration, injection, and reaspiration) is a percutaneous treatment alternative to surgery (211–215). Two randomized controlled trials and a meta-analysis based on these trials reported that PAIR with adjunct antihelminthic chemotherapy is as effective as open surgical drainage with fewer complications and lower cost (212,216,217). PAIR is recommended for patients with active hydatid cysts >5 cm who are not candidates for or decline surgery, or who relapse after surgery. PAIR is not recommended in patients with biliary fistulas or communications with the biliary tree because of the risk of biliary sclerosis. PAIR is also contraindicated in patients with inaccessible cysts, or with complicated, multivesiculated cysts, because they may not respond favorably as compared with simple hepatic cysts (218,219). A recent review of studies on hydatid cyst-associated anaphylaxis found that the risk of lethal anaphylaxis related to percutaneous treatment was extremely rare at 0.03% of reported procedures (220).

Surgical treatment, either radical pericystectomy or conservative deroofting, has been reserved for complicated cysts that have fistulas, multiple daughter vesicles, rupture, hemorrhage, or secondary infection. Surgery also remains an option when percutaneous treatment such as PAIR is not available. Laparoscopic approaches have been reported to be effective, but quality data on comparison with open surgical approaches or PAIR are highly limited (214,221–223). Overall, the majority of studies are heterogeneous

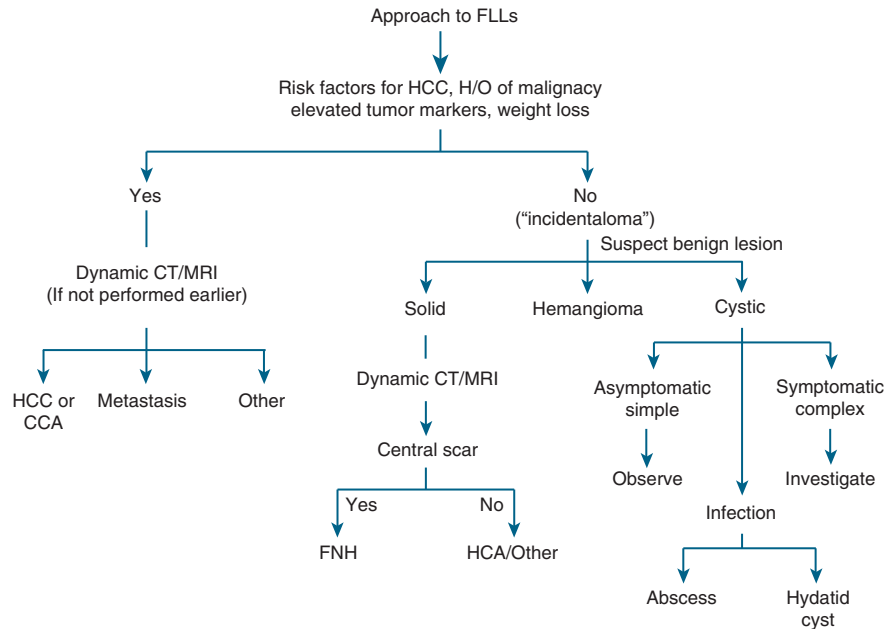


Figure 1. Approach to FLLs. CCA, cholangiocarcinoma; CT, computed tomography; FLL, focal liver lesion; FNH, focal nodular hyperplasia; HCA, hepatocellular adenoma; HCC, hepatocellular carcinoma; H/O, history of; MRI, magnetic resonance imaging.

small series, retrospective reports with overlapping patients, limiting the quality of the evidence on which to make strong recommendations on management (224,225).

Recommendations

34. MRI is preferred over CT for concomitant evaluation of the biliary tree and cystic contents (conditional recommendation, low quality of evidence).
35. Monotherapy with antihelminthic drugs is not recommended in symptomatic patients who are surgical or percutaneous treatment candidates (strong recommendation, moderate quality of evidence).
36. Adjunctive therapy with antihelminthic therapy is recommended in patients undergoing PAIR or surgery, and in those with peritoneal rupture or biliary rupture (strong recommendation, low quality of evidence).
37. Percutaneous treatment with PAIR is recommended for patients with active, hydatid cysts who are not surgical candidates, who decline surgery, or who relapse after surgery (strong recommendation, low quality of evidence).
38. Surgery, either laparoscopic or open, based on available expertise, is recommended in complicated hydatid cysts with multiple vesicles, daughter cysts, fistulas, rupture, hemorrhage, or secondary infection (strong recommendation, low quality of evidence).

CONCLUSION

Imaging modalities for the evaluation of the abdomen are being increasingly utilized, leading to a proliferation in the detection of FLLs. Further technical advances in cross-sectional imaging

have led to identification of ever-smaller FLLs. FLLs frequently pose a diagnostic challenge for clinicians. FLLs of the liver may arise from hepatocytes, biliary epithelium, mesenchymal tissue, or metastases from extrahepatic tumors. Although most incidentally noted FLLs are benign, it may be difficult to differentiate benign lesions from those that are malignant amid the broad differential of FLLs. Furthermore, it is important to remember that some noncancerous lesions such as hepatocellular adenomas and biliary cystadenomas have malignant potential. These lesions may not necessarily present with symptoms attributable to the lesion and are frequently not associated with underlying liver disease. Thus, the clinical circumstance in which an FLL is identified, such as the patient's age, gender, use of oral contraceptives, history of chronic liver disease, and recent travel, may provide vital clues to the etiology. The presence of underlying chronic liver disease, either suspected or proven by clinical and/or laboratory features, as well as the time of detection of the lesion, provides important insight to the nature and relevance of the lesion. For example, an FLL in a patient with hepatitis B or C infection, particularly when associated with features of chronic liver disease or cirrhosis, should lead to a high suspicion for HCC. In addition, the size of the liver lesion is extremely important in guiding the evaluation. Lesions < 1 cm are commonly benign incidental findings.

Radiologically, cystic lesions can be readily differentiated from a solid lesion. In addition, certain solid FLLs such as FNH and hemangiomas can often precisely be diagnosed by a quality imaging modality alone. In many benign lesions such as hemangiomas and hepatocellular adenomas, liver biopsy carries a high risk of bleeding and is not of any additional value to the radiologic diagnosis. A reasonable approach to the diagnosis, follow-up,

and management of liver masses based on the knowledge of their presentation, associated clinical and laboratory features, natural history, and available treatment options is outlined in **Figure 1**. Although malignancy is often the concern with liver masses, most FLLs presenting as “incidentalomas” are benign and require patient reassurance and monitoring.

ACKNOWLEDGMENTS

The writing group thank David Koch (Medical College of South Carolina), Wilscott Naugler (Oregon Health & Science University), Janice Jou (Oregon Health and Science University), Amit Singal (University of Texas at Southwestern), and David Goldberg (University of Pennsylvania) for their helpful comments on the manuscript.

CONFLICT OF INTEREST

Guarantor of the article: K. Rajender Reddy, MD, FACP.

Specific author contributions: All three authors had an equal part in the conception of the outline, literature review, writing, and reviewing the final paper.

Financial support: None.

Potential competing interests: None.

REFERENCES

- Bruix J, Sherman M, American Association for the Study of Liver. Management of hepatocellular carcinoma: an update. *Hepatology* 2011;53:1020–2.
- Khan SA, Davidson BR, Goldin RD *et al.* Guidelines for the diagnosis and treatment of cholangiocarcinoma: an update. *Gut* 2012;61:1657–69.
- European Association For The Study Of The Liver; European Organisation For Research And Treatment Of Cancer. EASL-EORTC clinical practice guidelines: management of hepatocellular carcinoma. *J Hepatol* 2012;56:908–43.
- Guyatt GH, Oxman AD, Vist GE *et al.* GRADE: an emerging consensus on rating quality of evidence and strength of recommendations. *BMJ* 2008;336:924–6.
- Smith-Bindman R, Miglioretti DL, Johnson E *et al.* Use of diagnostic imaging studies and associated radiation exposure for patients enrolled in large integrated health care systems, 1996–2010. *JAMA* 2012;307:2400–9.
- Ros PR, Mortelet KJ. Hepatic imaging. An overview. *Clin Liver Dis* 2002;6:1–16.
- Pomfret EA, Washburn K, Wald C *et al.* Report of a national conference on liver allocation in patients with hepatocellular carcinoma in the United States. *Liver Transpl* 2010;16:262–78.
- Di Martino M, De Filippis G, De Santis A *et al.* Hepatocellular carcinoma in cirrhotic patients: prospective comparison of US CT and MR imaging. *Eur Radiol* 2013;23:887–96.
- Quinn SF, Nelson HA, Demlow TA. Thyroid biopsies: fine-needle aspiration biopsy versus spring-activated core biopsy needle in 102 patients. *J Vasc Interv Radiol* 1994;5:619–23.
- International Consensus Group for Hepatocellular Neoplasia. The International Consensus Group for Hepatocellular Neoplasia. Pathologic diagnosis of early hepatocellular carcinoma: a report of the international consensus group for hepatocellular neoplasia. *Hepatology* 2009;49:658–64.
- WHO. Globocan 2008. <http://globocan.iarc.fr>. [cited 19 October 2013].
- NCL. <http://www.seer.cancer.gov> n.d. [cited 1 June 2013].
- El-Serag HB. Hepatocellular carcinoma. *N Engl J Med* 2011;365:1118–27.
- Bosch FX, Ribes J, Diaz M *et al.* Primary liver cancer: worldwide incidence and trends. *Gastroenterology* 2004;127 (5 Suppl 1): S5–S16.
- Fattovich G, Stroffolini T, Zagni I *et al.* Hepatocellular carcinoma in cirrhosis: incidence and risk factors. *Gastroenterology* 2004;127 (5 Suppl 1): S35–50.
- Donato F, Tagger A, Gelatti U *et al.* Alcohol and hepatocellular carcinoma: the effect of lifetime intake and hepatitis virus infections in men and women. *Am J Epidemiol* 2002;155:323–31.
- Chen ZM, Liu BQ, Boreham J *et al.* Smoking and liver cancer in China: case-control comparison of 36,000 liver cancer deaths vs. 17,000 cirrhosis deaths. *Int J Cancer* 2003;107:106–12.
- Singal AG, Conjeevaram HS, Volk ML *et al.* Effectiveness of hepatocellular carcinoma surveillance in patients with cirrhosis. *Cancer Epidemiol Biomarkers Prev* 2012;21:793–9.
- Lok AS, Seeff LB, Morgan TR *et al.* Incidence of hepatocellular carcinoma and associated risk factors in hepatitis C-related advanced liver disease. *Gastroenterology* 2009;136:138–48.
- Franceschi S, Montella M, Polesel J *et al.* Hepatitis viruses, alcohol, and tobacco in the etiology of hepatocellular carcinoma in Italy. *Cancer Epidemiol Biomarkers Prev* 2006;15:683–9.
- Calle EE, Rodriguez C, Walker-Thurmond K *et al.* Overweight, obesity, and mortality from cancer in a prospectively studied cohort of U.S. adults. *N Engl J Med* 2003;348:1625–38.
- El-Serag HB, Tran T, Everhart JE. Diabetes increases the risk of chronic liver disease and hepatocellular carcinoma. *Gastroenterology* 2004;126:460–8.
- Marrero JA, Fontana RJ, Fu S *et al.* Alcohol, tobacco and obesity are synergistic risk factors for hepatocellular carcinoma. *J Hepatol* 2005;42:218–24.
- Marrero JA, Welling T. Modern diagnosis and management of hepatocellular carcinoma. *Clin Liver Dis* 2009;13:233–47.
- Burrell M, Llovet JM, Ayuso C *et al.* MRI angiography is superior to helical CT for detection of HCC prior to liver transplantation: an explant correlation. *Hepatology* 2003;38:1034–42.
- de Ledinghen V, Laharie D, Lécésne R *et al.* Detection of nodules in liver cirrhosis: spiral computed tomography or magnetic resonance imaging? A prospective study of 88 nodules in 34 patients. *Eur J Gastroenterol Hepatol* 2002;14:159–65.
- Krinsky GA, Lee VS. MR imaging of cirrhotic nodules. *Abdom Imaging* 2000;25:471–82.
- Krinsky GA, Lee VS, Theise ND *et al.* Hepatocellular carcinoma and dysplastic nodules in patients with cirrhosis: prospective diagnosis with MR imaging and explanation correlation. *Radiology* 2001;219:445–54.
- Rode A, Bancel B, Douek P *et al.* Small nodule detection in cirrhotic livers: evaluation with US, spiral CT, and MRI and correlation with pathologic examination of explanted liver. *J Comput Assist Tomogr* 2001;25:327–36.
- Hayashi M, Matsui O, Ueda K *et al.* Progression to hypervascular hepatocellular carcinoma: correlation with intranodular blood supply evaluated with CT during intraarterial injection of contrast material. *Radiology* 2002;225:143–9.
- Hayashi PH, Trotter JF, Forman L *et al.* Impact of pretransplant diagnosis of hepatocellular carcinoma on cadaveric liver allocation in the era of MELD. *Liver Transpl* 2004;10:42–8.
- Bruix J, Sherman M, Llovet JM, *et al.* Clinical management of hepatocellular carcinoma. Conclusions of the Barcelona-2000 EASL conference. European Association for the Study of the Liver. *J Hepatol* 2001;35:421–30.
- Marrero JA, Hussain HK, Nghiem HV *et al.* Improving the prediction of hepatocellular carcinoma in cirrhotic patients with an arterially-enhancing liver mass. *Liver Transpl* 2005;11:281–9.
- Bruix J, Sherman M. Management of hepatocellular carcinoma. *Hepatology* 2005;42:1208–36.
- Bolondi L, Gaiani S, Celli N *et al.* Characterization of small nodules in cirrhosis by assessment of vascularity: the problem of hypovascular hepatocellular carcinoma. *Hepatology* 2005;42:27–34.
- Sangiovanni A, Manini MA, Iavarone M *et al.* The diagnostic and economic impact of contrast imaging techniques in the diagnosis of small hepatocellular carcinoma in cirrhosis. *Gut* 2010;59:638–44.
- Forner A, Vilana R, Ayuso C *et al.* Diagnosis of hepatic nodules 20 mm or smaller in cirrhosis: prospective validation of the noninvasive diagnostic criteria for hepatocellular carcinoma. *Hepatology* 2008;47:97–104.
- Maturen KE, Nghiem HV, Marrero JA *et al.* Lack of tumor seeding of hepatocellular carcinoma after percutaneous needle biopsy using coaxial cutting needle technique. *AJR Am J Roentgenol* 2006;187:1184–7.
- Poon RT, Fan ST, Lo CM *et al.* Long-term survival and pattern of recurrence after resection of small hepatocellular carcinoma in patients with preserved liver function: implications for a strategy of salvage transplantation. *Ann Surg* 2002;235:373–82.
- Mazzaferro V, Regalia E, Doci R *et al.* Liver transplantation for the treatment of small hepatocellular carcinomas in patients with cirrhosis. *N Engl J Med* 1996;334:693–9.
- Llovet JM, Bruix J. Systematic review of randomized trials for unresectable hepatocellular carcinoma: chemoembolization improves survival. *Hepatology* 2003;37:429–42.

42. Llovet JM, Ricci S, Mazzaferro V *et al.* Sorafenib in advanced hepatocellular carcinoma. *N Engl J Med* 2008;359:378–90.
43. Khan SA, Thomas HC, Davidson BR *et al.* Cholangiocarcinoma. *Lancet* 2005;366:1303–14.
44. Razumilava N, Gores GJ, Lindor KD. Cancer surveillance in patients with primary sclerosing cholangitis. *Hepatology* 2011;54:1842–52.
45. Rimola J, Forner A, Reig M *et al.* Cholangiocarcinoma in cirrhosis: absence of contrast washout in delayed phases by magnetic resonance imaging avoids misdiagnosis of hepatocellular carcinoma. *Hepatology* 2009;50:791–8.
46. Vilgrain V. Staging cholangiocarcinoma by imaging studies. *HPB (Oxford)* 2008;10:106–9.
47. Anderson CD, Rice MH, Pinson CW *et al.* Fluorodeoxyglucose PET imaging in the evaluation of gallbladder carcinoma and cholangiocarcinoma. *J Gastrointest Surg* 2004;8:90–7.
48. Blechacz B, Komuta M, Roskams T *et al.* Clinical diagnosis and staging of cholangiocarcinoma. *Nat Rev Gastroenterol Hepatol* 2011;8:512–22.
49. Endo I, Gonen M, Yopp AC *et al.* Intrahepatic cholangiocarcinoma: rising frequency, improved survival, and determinants of outcome after resection. *Ann Surg* 2008;248:84–96.
50. DeOliveira ML, Cunningham SC, Cameron JL *et al.* Cholangiocarcinoma: thirty-one-year experience with 564 patients at a single institution. *Ann Surg* 2007;245:755–62.
51. Valle J, Wasan H, Palmer DH *et al.* Cisplatin plus gemcitabine versus gemcitabine for biliary tract cancer. *N Engl J Med* 2010;362:1273–81.
52. Shaked O, Siegelman ES, Olthoff K *et al.* Biologic and clinical features of benign solid and cystic lesions of the liver. *Clin Gastroenterol Hepatol* 2011;9:547–62 e1–4.
53. Craig JR, Peters RL, Edmondson HA *et al.* Tumors of the liver and intrahepatic bile ducts. *Atlas of Tumor Pathology*, Washington, DC: Armed Forces Institute of Pathology : Supt. of Docs., U.S. G.P.O. For sale by the Armed Forces Institute of Pathology. 280 p 1989.
54. Buscarini L, Fornari F, Civaridi G *et al.* Laparoscopy integrates ultrasound and ultrasound guided biopsy for diagnosis of benign liver tumors. *Acta Endoscopica* 1993;23:27–36.
55. Rooks JB, Ory HW, Ishak KG *et al.* Epidemiology of hepatocellular adenoma. The role of oral contraceptive use. *JAMA* 1979;242:644–8.
56. Edmondson HA, Reynolds TB, Henderson B *et al.* Regression of liver cell adenomas associated with oral contraceptives. *Ann Intern Med* 1977;86:180–2.
57. Buhler H, Pirovino M, Akobiantz A *et al.* Regression of liver cell adenoma. A follow-up study of three consecutive patients after discontinuation of oral contraceptive use. *Gastroenterology* 1982;82:775–82.
58. Hernandez-Nieto L, Bruguera M, Bombi J *et al.* Benign liver-cell adenoma associated with long-term administration of an androgenic-anabolic steroid (methandienone). *Cancer* 1977;40:1761–4.
59. Martin NM, Abu Dayyeh BK, Chung RT. Anabolic steroid abuse causing recurrent hepatic adenomas and hemorrhage. *World J Gastroenterol* 2008;14:4573–5.
60. Triantafyllopoulou M, Whittington PF, Melin-Aldana H *et al.* Hepatic adenoma in an adolescent with elevated androgen levels. *J Pediatr Gastroenterol Nutr* 2007;44:640–2.
61. Labruno P, Trioche P, Duvaltier I *et al.* Hepatocellular adenomas in glycogen storage disease type I and III: a series of 43 patients and review of the literature. *J Pediatr Gastroenterol Nutr* 1997;24:276–9.
62. Sakellariou S, Al-Hussaini H, Scalori A *et al.* Hepatocellular adenoma in glycogen storage disorder type I: a clinicopathological and molecular study. *Histopathology* 2012;60:E58–65.
63. Parker P, Burr I, Slonim A *et al.* Regression of hepatic adenomas in type Ia glycogen storage disease with dietary therapy. *Gastroenterology* 1981;81:534–6.
64. Reddy SK, Kishnani PS, Sullivan JA *et al.* Resection of hepatocellular adenoma in patients with glycogen storage disease type Ia. *J Hepatol* 2007;47:658–63.
65. Bunchorntavakul C, Bahirwani R, Drazek D *et al.* Clinical features and natural history of hepatocellular adenomas: the impact of obesity. *Aliment Pharmacol Ther* 2011;34:664–74.
66. Bioulac-Sage P, Taouji S, Possenti L *et al.* Hepatocellular adenoma subtypes: the impact of overweight and obesity. *Liver Int* 2012;32:1217–21.
67. Farges O, Ferreira N, Dokmak S *et al.* Changing trends in malignant transformation of hepatocellular adenoma. *Gut* 2011;60:85–9.
68. Flejou JF, Barge J, Menu Y *et al.* Liver adenomatosis. An entity distinct from liver adenoma? *Gastroenterology* 1985;89:1132–8.
69. Ribeiro A, Burgart LJ, Nagorney DM *et al.* Management of liver adenomatosis: results with a conservative surgical approach. *Liver Transpl Surg* 1998;4:388–98.
70. Attal P, Vilgrain V, Brancatelli G *et al.* Telangiectatic focal nodular hyperplasia: US, CT, and MR imaging findings with histopathologic correlation in 13 cases. *Radiology* 2003;228:465–72.
71. Bioulac-Sage P, Rebouissou S, Sa Cunha A *et al.* Clinical, morphologic, and molecular features defining so-called telangiectatic focal nodular hyperplasias of the liver. *Gastroenterology* 2005;128:1211–8.
72. Paradis V, Champault A, Ronot M *et al.* Telangiectatic adenoma: an entity associated with increased body mass index and inflammation. *Hepatology* 2007;46:140–6.
73. Vana J, Murphy GP, Aronoff BL *et al.* Primary liver tumors and oral contraceptives. Results of a survey. *JAMA* 1977;238:2154–8.
74. Laumonier H, Bioulac-Sage P, Laurent C *et al.* Hepatocellular adenomas: magnetic resonance imaging features as a function of molecular pathological classification. *Hepatology* 2008;48:808–18.
75. Bieze M, van den Esschert JW, Nio CY *et al.* Diagnostic accuracy of MRI in differentiating hepatocellular adenoma from focal nodular hyperplasia: prospective study of the additional value of gadoxetate disodium. *AJR Am J Roentgenol* 2012;199:26–34.
76. Broker ME, Ijzermans JN, van Aalten SM *et al.* The management of pregnancy in women with hepatocellular adenoma: a plea for an individualized approach. *Int J Hepatol* 2012;2012:725735.
77. van Aalten SM, Bröker ME, Busschbach JJ *et al.* Pregnancy and liver adenoma management: PALM-study. *BMC Gastroenterol* 2012;12:82.
78. Cho SW, Marsh JW, Steel J *et al.* Surgical management of hepatocellular adenoma: take it or leave it? *Ann Surg Oncol* 2008;15:2795–803.
79. Deneve JL, Pawlik TM, Cunningham S *et al.* Liver cell adenoma: a multicenter analysis of risk factors for rupture and malignancy. *Ann Surg Oncol* 2009;16:640–8.
80. Ribeiro Junior MA, Chaib E, Saad WA *et al.* Surgical management of spontaneous ruptured hepatocellular adenoma. *Clinics (Sao Paulo)* 2009;64:775–9.
81. Maoz D, Sharon E, Chen Y *et al.* Spontaneous hepatic rupture: 13-year experience of a single center. *Eur J Gastroenterol Hepatol* 2010;22:997–1000.
82. Papanikolaou V, Giakoustidis D, Patsiaura K *et al.* Management of a giant ruptured hepatocellular adenoma. Report of a case. *Hippokratia* 2007;11:86–8.
83. Bioulac-Sage P, Laumonier H, Couchy G *et al.* Hepatocellular adenoma management and phenotypic classification: the Bordeaux experience. *Hepatology* 2009;50:481–9.
84. Foster JH, Berman MM. The malignant transformation of liver cell adenomas. *Arch Surg* 1994;129:712–7.
85. van der Windt DJ, Kok NF, Hussain SM *et al.* Case-orientated approach to the management of hepatocellular adenoma. *Br J Surg* 2006;93:1495–502.
86. Mariani AF, Livingstone AS, Pereiras RV Jr *et al.* Progressive enlargement of an hepatic cell adenoma. *Gastroenterology* 1979;77:1319–25.
87. Gordon SC, Reddy KR, Livingstone AS *et al.* Resolution of a contraceptive-steroid-induced hepatic adenoma with subsequent evolution into hepatocellular carcinoma. *Ann Intern Med* 1986;105:547–9.
88. Tesluk H, Lawrie J. Hepatocellular adenoma. Its transformation to carcinoma in a user of oral contraceptives. *Arch Pathol Lab Med* 1981;105:296–9.
89. Leese T, Farges O, Bismuth H. Liver cell adenomas. A 12-year surgical experience from a specialist hepato-biliary unit. *Ann Surg* 1988;208:558–64.
90. Karhunen PJ. Benign hepatic tumours and tumour like conditions in men. *J Clin Pathol* 1986;39:183–8.
91. Gibney RG, Hendin AP, Cooperberg PL. Sonographically detected hepatic hemangiomas: absence of change over time. *AJR Am J Roentgenol* 1987;149:953–7.
92. Rungsinaporn K, Phaisakamas T. Frequency of abnormalities detected by upper abdominal ultrasound. *J Med Assoc Thai* 2008;91:1072–5.
93. Mergo PJ, Ros PR. Benign lesions of the liver. *Radiol Clin North Am* 1998;36:319–31.
94. Gandolfi L, Leo P, Solmi L *et al.* Natural history of hepatic haemangiomas: clinical and ultrasound study. *Gut* 1991;32:677–80.
95. Saegusa T, Ito K, Oba N *et al.* Enlargement of multiple cavernous hemangioma of the liver in association with pregnancy. *Intern Med* 1995;34:207–11.
96. Conter RL, Longmire WP Jr. Recurrent hepatic hemangiomas. Possible association with estrogen therapy. *Ann Surg* 1988;207:115–9.
97. Gemer O, Moscovici O, Ben-Horin CL *et al.* Oral contraceptives and liver hemangioma: a case-control study. *Acta Obstet Gynecol Scand* 2004;83:1199–201.
98. Tait N, Richardson AJ, Muguti G *et al.* Hepatic cavernous haemangioma: a 10 year review. *Aust N Z J Surg* 1992;62:521–4.
99. Park WC, Rhillips R. The role of radiation therapy in the management of hemangiomas of the liver. *JAMA* 1970;212:1496–8.

100. Kasabach HH, Merritt KK. Capillary hemangioma with extensive purpura: report of a case. *Am J Dis Children* 1940;59:1063–70.
101. Quaia E, Calliada F, Bertolotto M *et al.* Characterization of focal liver lesions with contrast-specific US modes and a sulfur hexafluoride-filled microbubble contrast agent: diagnostic performance and confidence. *Radiology* 2004;232:420–30.
102. Farges O, Daradkeh S, Bismuth H. Cavernous hemangiomas of the liver: are there any indications for resection? *World J Surg* 1995;19:19–24.
103. Ehrh D, Rothaug K, Herzog P *et al.* ‘Incidentaloma’ of the liver: management of a diagnostic and therapeutic dilemma. *HPB Surg* 2012;2012:891787.
104. Wanless IR, Sapp H, Guindy M *et al.* The pathogenesis of focal nodular hyperplasia: an hypothesis based on histologic review of 20 lesions including 3 occurring in early biliary cirrhosis. *Hepatology* 2006;44:491a–.
105. Sato Y, Harada K, Ikeda H *et al.* Hepatic stellate cells are activated around central scars of focal nodular hyperplasia of the liver—a potential mechanism of central scar formation. *Hum Pathol* 2009;40:181–8.
106. Cherqui D, Rahmouni A, Charlotte F *et al.* Management of focal nodular hyperplasia and hepatocellular adenoma in young women: a series of 41 patients with clinical, radiological, and pathological correlations. *Hepatology* 1995;22:1674–81.
107. Luciani A, Kobeiter H, Maison P *et al.* Focal nodular hyperplasia of the liver in men: is presentation the same in men and women? *Gut* 2002;50:877–80.
108. Mathieu D, Zafrani ES, Anglade MC *et al.* Association of focal nodular hyperplasia and hepatic hemangioma. *Gastroenterology* 1989;97:154–7.
109. Laurent C, Trillaud H, Lepreux S *et al.* Association of adenoma and focal nodular hyperplasia: experience of a single French academic center. *Comp Hepatol* 2003;2:6.
110. Wanless IR, Albrecht S, Bilbao J *et al.* Multiple focal nodular hyperplasia of the liver associated with vascular malformations of various organs and neoplasia of the brain: a new syndrome. *Mod Pathol* 1989;2:456–62.
111. Nguyen BN, Fléjou JF, Terris B *et al.* Focal nodular hyperplasia of the liver: a comprehensive pathologic study of 305 lesions and recognition of new histologic forms. *Am J Surg Pathol* 1999;23:1441–54.
112. Wanless IR, Mawdsley C, Adams R. On the pathogenesis of focal nodular hyperplasia of the liver. *Hepatology* 1985;5:1194–200.
113. Mathieu D, Kobeiter H, Cherqui D *et al.* Oral contraceptive intake in women with focal nodular hyperplasia of the liver. *Lancet* 1998;352:1679–80.
114. Weimann A, Mössinger M, Fronhoff K *et al.* Pregnancy in women with observed focal nodular hyperplasia of the liver. *Lancet* 1998;351:1251–2.
115. Grazioli L, Morana G, Kirchin MA *et al.* Accurate differentiation of focal nodular hyperplasia from hepatic adenoma at gadobenate dimeglumine-enhanced MR imaging: prospective study. *Radiology* 2005;236:166–77.
116. Huppertz A, Haraida S, Kraus A *et al.* Enhancement of focal liver lesions at gadoxetic acid-enhanced MR imaging: correlation with histopathologic findings and spiral CT—initial observations. *Radiology* 2005;234:468–78.
117. Liu YJ, Fan WJ, Yuan ZD *et al.* Research on focal nodular hyperplasia with MSCT and postprocessing. *World J Gastroenterol* 2009;15:4838–43.
118. Lin MC, Tsay PK, Ko SF *et al.* Triphasic dynamic CT findings of 63 hepatic focal nodular hyperplasia in 46 patients: correlation with size and pathological findings. *Abdom Imaging* 2008;33:301–7.
119. Trillaud H, Bruel JM, Valette PJ *et al.* Characterization of focal liver lesions with SonoVue-enhanced sonography: international multicenter-study in comparison to CT and MRI. *World J Gastroenterol* 2009;15:3748–56.
120. Bioulac-Sage P, Cubel G, Taouji S *et al.* Immunohistochemical markers on needle biopsies are helpful for the diagnosis of focal nodular hyperplasia and hepatocellular adenoma subtypes. *Am J Surg Pathol* 2012;36:1691–9.
121. Kuo YH, Wang JH, Lu SN *et al.* Natural course of hepatic focal nodular hyperplasia: a long-term follow-up study with sonography. *J Clin Ultrasound* 2009;37:132–7.
122. Demarco MP, Shen P, Bradley RF *et al.* Intraoperative hemorrhage in a patient with hepatic focal nodular hyperplasia. *Am Surg* 2006;72:555–9.
123. Rahili A, Cai J, Trastour C *et al.* Spontaneous rupture and hemorrhage of hepatic focal nodular hyperplasia in lobus caudatus. *J Hepatobiliary Pancreat Surg* 2005;12:138–42.
124. Haubert L, Yearsley M, Bloomston M. Hepatocellular carcinoma arising within focal nodular hyperplasia. *Am Surg* 2010;76:335–6.
125. Charny CK, Jarnagin WR, Schwartz LH *et al.* Management of 155 patients with benign liver tumours. *Br J Surg* 2001;88:808–13.
126. Amesur N, Hammond JS, Zajko AB *et al.* Management of unresectable symptomatic focal nodular hyperplasia with arterial embolization. *J Vasc Interv Radiol* 2009;20:543–7.
127. Hedayati P, VanSonnenberg E, Shamos R *et al.* Treatment of symptomatic focal nodular hyperplasia with percutaneous radiofrequency ablation. *J Vasc Interv Radiol* 2010;21:582–5.
128. Wanless IR. Micronodular transformation (nodular regenerative hyperplasia) of the liver: a report of 64 cases among 2,500 autopsies and a new classification of benign hepatocellular nodules. *Hepatology* 1990;11:787–97.
129. Nakanuma Y. Nodular regenerative hyperplasia of the liver: retrospective survey in autopsy series. *J Clin Gastroenterol* 1990;12:460–5.
130. Stromeyer FW, Ishak KG. Nodular transformation (nodular “regenerative” hyperplasia) of the liver. A clinicopathologic study of 30 cases. *Hum Pathol* 1981;12:60–71.
131. Laharie D, Vergniol J, Bioulac-Sage P *et al.* Usefulness of noninvasive tests in nodular regenerative hyperplasia of the liver. *Eur J Gastroenterol Hepatol* 2010;22:487–93.
132. Biecker E, Trebicka J, Fischer HP *et al.* Portal hypertension and nodular regenerative hyperplasia in a patient with celiac disease. *Z Gastroenterol* 2006;44:395–8.
133. Ferlitsch A, Teml A, Reinisch W *et al.* 6-thioguanine associated nodular regenerative hyperplasia in patients with inflammatory bowel disease may induce portal hypertension. *Am J Gastroenterol* 2007;102:2495–503.
134. Trotter JF, Everson GT. Benign focal lesions of the liver. *Clin Liver Dis* 2001;5:17–42, v.
135. Boyer TD. Transjugular intrahepatic portosystemic shunt in the management of complications of portal hypertension. *Curr Gastroenterol Rep* 2008;10:30–5.
136. Tateo M, Sebahg M, Bralet MP *et al.* A new indication for liver transplantation: nodular regenerative hyperplasia in human immunodeficiency virus-infected patients. *Liver Transpl* 2008;14:1194–8.
137. Sanfelippo PM, Behars OH, Weiland LH. Cystic disease of the liver. *Ann Surg* 1974;179:922–5.
138. Caremani M, Vincenti A, Benci A *et al.* Ecographic epidemiology of non-parasitic hepatic cysts. *J Clin Ultrasound* 1993;21:115–8.
139. Carrim ZI, Murchison JT. The prevalence of simple renal and hepatic cysts detected by spiral computed tomography. *Clin Radiol* 2003;58:626–9.
140. Gaines PA, Sampson MA. The prevalence and characterization of simple hepatic cysts by ultrasound examination. *Br J Radiol* 1989;62:335–7.
141. Larssen TB, Rørvik J, Hoff SR *et al.* The occurrence of asymptomatic and symptomatic simple hepatic cysts. A prospective, hospital-based study. *Clin Radiol* 2005;60:1026–9.
142. Oto A, Tamm EP, Szklaruk J. Multidetector row CT of the liver. *Radiol Clin North Am* 2005;43:827–48, vii.
143. Ammori BJ, Jenkins BL, Lim PC *et al.* Surgical strategy for cystic diseases of the liver in a western hepatobiliary center. *World J Surg* 2002;26:462–9.
144. Bahirwani R, Reddy KR. Review article: the evaluation of solitary liver masses. *Aliment Pharmacol Ther* 2008;28:953–65.
145. Nisenbaum HL, Rowling SE. Ultrasound of focal hepatic lesions. *Semin Roentgenol* 1995;30:324–46.
146. Charlesworth P, Ade-Ajayi N, Davenport M. Natural history and long-term follow-up of antenatally detected liver cysts. *J Pediatr Surg* 2007;42:494–9.
147. Reid-Lombardo KM, Khan S, Sclabas G. Hepatic cysts and liver abscess. *Surg Clin North Am* 2010;90:679–97.
148. Gadzijev E, Dragan S, Verica FM *et al.* Hepatobiliary cystadenoma protruding into the common bile duct, mimicking complicated hydatid cyst of the liver. Report of a case. *Hepatogastroenterology* 1995;42:1008–10.
149. Taylor BR, Langer B. Current surgical management of hepatic cyst disease. *Adv Surg* 1997;31:127–48.
150. Doty JE, Tompkins RK. Management of cystic disease of the liver. *Surg Clin North Am* 1989;69:285–95.
151. Gall TM, Oniscu GC, Madhavan K *et al.* Surgical management and long-term follow-up of non-parasitic hepatic cysts. *HPB (Oxford)* 2009;11:235–41.
152. Gamblin TC, Holloway SE, Heckman JT *et al.* Laparoscopic resection of benign hepatic cysts: a new standard. *J Am Coll Surg* 2008;207:731–6.
153. Mazza OM, Fernandez DL, Pekolj J *et al.* Management of nonparasitic hepatic cysts. *J Am Coll Surg* 2009;209:733–9.
154. Moorthy K, Mihssin N, Houghton PW. The management of simple hepatic cysts: sclerotherapy or laparoscopic fenestration. *Ann R Coll Surg Engl* 2001;83:409–14.
155. Regev A, Reddy KR, Berho M *et al.* Large cystic lesions of the liver in adults: a 15-year experience in a tertiary center. *J Am Coll Surg* 2001;193:36–45.
156. Wahba R, Kleinert R, Prenzel K *et al.* Laparoscopic deroofting of non-parasitic liver cysts with or without greater omentum flap. *Surg Laparosc Endosc Percutan Tech* 2011;21:54–8.

157. Tocchi A, Mazzoni G, Costa G *et al*. Symptomatic nonparasitic hepatic cysts: options for and results of surgical management. *Arch Surg* 2002;137:154–8.
158. Erdogan D, van Delden OM, Rauws EA *et al*. Results of percutaneous sclerotherapy and surgical treatment in patients with symptomatic simple liver cysts and polycystic liver disease. *World J Gastroenterol* 2007;13:3095–100.
159. Larssen TB, Rørvik J, Horn A *et al*. Biochemical and cytologic analysis of cystic contents in benign non-parasitic symptomatic hepatic cysts before and after ethanol sclerotherapy. *Acta Radiol* 2004;45:504–9.
160. Saini S, Mueller PR, Ferrucci JT Jr *et al*. Percutaneous aspiration of hepatic cysts does not provide definitive therapy. *AJR Am J Roentgenol* 1983;141:559–60.
161. Garcea G, Pattenden CJ, Stephenson J *et al*. Nine-year single-center experience with nonparasitic liver cysts: diagnosis and management. *Dig Dis Sci* 2007;52:185–91.
162. Garcea G, Rajesh A, Dennison AR. Surgical management of cystic lesions in the liver. *ANZ J Surg* 2013;83:516–22.
163. Palanivelu C, Jani K, Malladi V. Laparoscopic management of benign non-parasitic hepatic cysts: a prospective nonrandomized study. *South Med J* 2006;99:1063–7.
164. Fong ZV, Wolf AM, Doria C *et al*. Hemorrhagic hepatic cyst: report of a case and review of the literature with emphasis on clinical approach and management. *J Gastrointest Surg* 2012;16:1782–9.
165. Emre A, Serin KR, Ozden I *et al*. Intrahepatic biliary cystic neoplasms: surgical results of 9 patients and literature review. *World J Gastroenterol* 2011;17:361–5.
166. Devaney K, Goodman ZD, Ishak KG. Hepatobiliary cystadenoma and cystadenocarcinoma. A light microscopic and immunohistochemical study of 70 patients. *Am J Surg Pathol* 1994;18:1078–91.
167. Lam MM, Swanson PE, Upton MP *et al*. Ovarian-type stroma in hepatobiliary cystadenomas and pancreatic mucinous cystic neoplasms: an immunohistochemical study. *Am J Clin Pathol* 2008;129:211–8.
168. Lee JH, Chen DR, Pang SC *et al*. Mucinous biliary cystadenoma with mesenchymal stroma: expressions of CA 19-9 and carcinoembryonic antigen in serum and cystic fluid. *J Gastroenterol* 1996;31:732–6.
169. Lee JH, Lee KG, Park HK *et al*. Biliary cystadenoma and cystadenocarcinoma of the liver: 10 cases of a single center experience. *Hepato-gastroenterology* 2009;56:844–9.
170. Ishak KG, Willis GW, Cummins SD *et al*. Biliary cystadenoma and cystadenocarcinoma: report of 14 cases and review of the literature. *Cancer* 1977;39:322–38.
171. Marsh JL, Dahms B, Longmire WP Jr. Cystadenoma and cystadenocarcinoma of the biliary system. *Arch Surg* 1974;109:41–3.
172. Kim JY, Kim SH, Eun HW *et al*. Differentiation between biliary cystic neoplasms and simple cysts of the liver: accuracy of CT. *AJR Am J Roentgenol* 2010;195:1142–8.
173. Wilson SR, Burns PN, Muradali D *et al*. Harmonic hepatic US with microbubble contrast agent: initial experience showing improved characterization of hemangioma, hepatocellular carcinoma, and metastasis. *Radiology* 2000;215:153–61.
174. Williams DM, Vitellas KM, Sheafor D. Biliary cystadenocarcinoma: seven year follow-up and the role of MRI and MRCP. *Magn Reson Imaging* 2001;19:1203–8.
175. Dixon E, Sutherland FR, Mitchell P *et al*. Cystadenomas of the liver: a spectrum of disease. *Can J Surg* 2001;44:371–6.
176. Hai S, Hirohashi K, Uenishi T *et al*. Surgical management of cystic hepatic neoplasms. *J Gastroenterol* 2003;38:759–64.
177. Hansman MF, Ryan JA Jr, Holmes JH IV *et al*. Management and long-term follow-up of hepatic cysts. *Am J Surg* 2001;181:404–10.
178. Sanchez H, Gagner M, Rossi RL *et al*. Surgical management of nonparasitic cystic liver disease. *Am J Surg* 1991;161:113–8; discussion 118–9.
179. Vogt DP, Henderson JM, Chmielewski E. Cystadenoma and cystadenocarcinoma of the liver: a single center experience. *J Am Coll Surg* 2005;200:727–33.
180. Delis SG, Touloumis Z, Bakoyiannis A *et al*. Intrahepatic biliary cystadenoma: a need for radical resection. *Eur J Gastroenterol Hepatol* 2008;20:10–4.
181. Jain P, Jha AK, Rai RR. Cystic hepatic metastasis from gastrointestinal stromal tumor prior to imatinib mimicking a liver abscess. *J Gastrointest Liver Dis* 2009;18:121–2.
182. Drenth JP, Chrispijn M, Nagorney DM *et al*. Medical and surgical treatment options for polycystic liver disease. *Hepatology* 2010;52:2223–30.
183. Chandok N. Polycystic liver disease: a clinical review. *Ann Hepatol* 2012;11:819–26.
184. Torres VE, Harris PC. Autosomal dominant polycystic kidney disease: the last 3 years. *Kidney Int* 2009;76:149–68.
185. Qian Q. Isolated polycystic liver disease. *Adv Chronic Kidney Dis* 2010;17:181–9.
186. Kwok MK, Lewin KJ. Massive hepatomegaly in adult polycystic liver disease. *Am J Surg Pathol* 1988;12:321–4.
187. Sallee M, Rafat C, Zahar JR *et al*. Cyst infections in patients with autosomal dominant polycystic kidney disease. *Clin J Am Soc Nephrol* 2009;4:1183–9.
188. Chauveau D, Fakhouri F, Grunfeld JP. Liver involvement in autosomal-dominant polycystic kidney disease: therapeutic dilemma. *J Am Soc Nephrol* 2000;11:1767–75.
189. Caroli A, Antiga L, Cafaro M *et al*. Reducing polycystic liver volume in ADPKD: effects of somatostatin analogue octreotide. *Clin J Am Soc Nephrol* 2010;5:783–9.
190. Chrispijn M, Nevens F, Gevers TJ *et al*. The long-term outcome of patients with polycystic liver disease treated with lanreotide. *Aliment Pharmacol Ther* 2012;35:266–74.
191. Hogan MC, Masyuk TV, Page LJ *et al*. Randomized clinical trial of long-acting somatostatin for autosomal dominant polycystic kidney and liver disease. *J Am Soc Nephrol* 2010;21:1052–61.
192. Serra AL, Poster D, Kistler AD *et al*. Sirolimus and kidney growth in autosomal dominant polycystic kidney disease. *N Engl J Med* 2010;363:820–9.
193. Tao Y, Kim J, Schrier RW *et al*. Rapamycin markedly slows disease progression in a rat model of polycystic kidney disease. *J Am Soc Nephrol* 2005;16:46–51.
194. van Keimpema L, Nevens F, Vanslebrouck R *et al*. Lanreotide reduces the volume of polycystic liver: a randomized, double-blind, placebo-controlled trial. *Gastroenterology* 2009;137:1661–8 e1-2.
195. Walz G, Budde K, Mannaa M *et al*. Everolimus in patients with autosomal dominant polycystic kidney disease. *N Engl J Med* 2010;363:830–40.
196. Robinson TN, Stieglmann GV, Everson GT. Laparoscopic palliation of polycystic liver disease. *Surg Endosc* 2005;19:130–2.
197. Aussilhou B, Douflé G, Hubert C *et al*. Extended liver resection for polycystic liver disease can challenge liver transplantation. *Ann Surg* 2010;252:735–43.
198. Que F, Nagorney DM, Gross JB Jr *et al*. Liver resection and cyst fenestration in the treatment of severe polycystic liver disease. *Gastroenterology* 1995;108:487–94.
199. Kirchner GI, Rifai K, Cantz T *et al*. Outcome and quality of life in patients with polycystic liver disease after liver or combined liver-kidney transplantation. *Liver Transpl* 2006;12:1268–77.
200. Morgan DE, Lockhart ME, Canon CL *et al*. Polycystic liver disease: multimodality imaging for complications and transplant evaluation. *Radiographics* 2006;26:1655–1668; quiz 1655.
201. Russell RT, Pinson CW. Surgical management of polycystic liver disease. *World J Gastroenterol* 2007;13:5052–9.
202. Schnelldorfer T, Torres VE, Zakaria S *et al*. Polycystic liver disease: a critical appraisal of hepatic resection, cyst fenestration, and liver transplantation. *Ann Surg* 2009;250:112–8.
203. Chandok N, Uhanova J, Marotta P. Clinical outcomes of liver transplantation for polycystic liver disease: a single center experience. *Ann Hepatol* 2010;9:278–81.
204. van Keimpema L, Nevens F, Adam R *et al*. Excellent survival after liver transplantation for isolated polycystic liver disease: an European Liver Transplant Registry study. *Transpl Int* 2011;24:1239–45.
205. WHO Informal Working Group. International classification of ultrasound images in cystic echinococcosis for application in clinical and field epidemiological settings. *Acta Trop* 2003;85:253–61.
206. von Sinner WN. New diagnostic signs in hydatid disease; radiography, ultrasound CT and MRI correlated to pathology. *Eur J Radiol* 1991;12:150–9.
207. WHO Informal Working Group on Echinococcosis. Guidelines for treatment of cystic and alveolar echinococcosis in humans. *Bull World Health Organ* 1996;74:231–42.
208. Stojkovic M, Zwahlen M, Teggi A *et al*. Treatment response of cystic echinococcosis to benzimidazoles: a systematic review. *PLoS Negl Trop Dis* 2009;3:e524.
209. Kjossev KT, Losanoff JE. Classification of hydatid liver cysts. *J Gastroenterol Hepatol* 2005;20:352–9.
210. Smego RA Jr, Bhatti S, Khaliq AA *et al*. Percutaneous aspiration-injection-reaspiration drainage plus albendazole or mebendazole for hepatic cystic echinococcosis: a meta-analysis. *Clin Infect Dis* 2003;37:1073–83.

211. Brunetti E, Kern P, Vuitton DA *et al.* Expert consensus for the diagnosis and treatment of cystic and alveolar echinococcosis in humans. *Acta Trop* 2010;114:1–16.
212. Nasser Moghaddam S, Abrishami A, Malekzadeh R. Percutaneous needle aspiration, injection, and reaspiration with or without benzimidazole coverage for uncomplicated hepatic hydatid cysts. *Cochrane Database Syst Rev* 2006;1: CD003623.
213. Sahin M, Kartal A, Haykir R *et al.* RF-assisted cystectomy and pericystectomy: a new technique in the treatment of liver hydatid disease. *Eur Surg Res* 2006;38:90–3.
214. Yagci G, Ustunsoz B, Kaymakcioglu N *et al.* Results of surgical, laparoscopic, and percutaneous treatment for hydatid disease of the liver: 10 years experience with 355 patients. *World J Surg* 2005;29:1670–9.
215. Zacharoulis D, Poultsidis A, Roundas C *et al.* Liver hydatid disease: radio-frequency-assisted pericystectomy. *Ann R Coll Surg Engl* 2006;88: 499–500.
216. Khuroo MS, Dar MY, Yattoo GN *et al.* Percutaneous drainage versus albendazole therapy in hepatic hydatidosis: a prospective, randomized study. *Gastroenterology* 1993;104:1452–9.
217. Khuroo MS, Wani NA, Javid G *et al.* Percutaneous drainage compared with surgery for hepatic hydatid cysts. *N Engl J Med* 1997;337:881–7.
218. Giorgio A, Tarantino L, de Stefano G *et al.* Hydatid liver cyst: an 11-year experience of treatment with percutaneous aspiration and ethanol injection. *J Ultrasound Med* 2001;20:729–38.
219. Kabaalioglu A, Ceken K, Alimoglu E *et al.* Percutaneous imaging-guided treatment of hydatid liver cysts: do long-term results make it a first choice? *Eur J Radiol* 2006;59:65–73.
220. Neumayr A, Troia G, de Bernardis C *et al.* Justified concern or exaggerated fear: the risk of anaphylaxis in percutaneous treatment of cystic echinococcosis—a systematic literature review. *PLoS Negl Trop Dis* 2011;5:e1154.
221. Daradkeh S, El-Muhtaseb H, Farah G *et al.* Predictors of morbidity and mortality in the surgical management of hydatid cyst of the liver. *Langenbecks Arch Surg* 2007;392:35–9.
222. Koea JB. Laparoscopic treatment of hepatic hydatid disease. *ANZ J Surg* 2012;82:499–504.
223. Palanivelu C, Jani K, Malladi V *et al.* Laparoscopic management of hepatic hydatid disease. *JLS* 2006;10:56–62.
224. Dziri C, Haouet K, Fingerhut A *et al.* Management of cystic echinococcosis complications and dissemination: where is the evidence? *World J Surg* 2009;33:1266–73.
225. Smego RA Jr, Sebanego P. Treatment options for hepatic cystic echinococcosis. *Int J Infect Dis* 2005;9:69–76.