

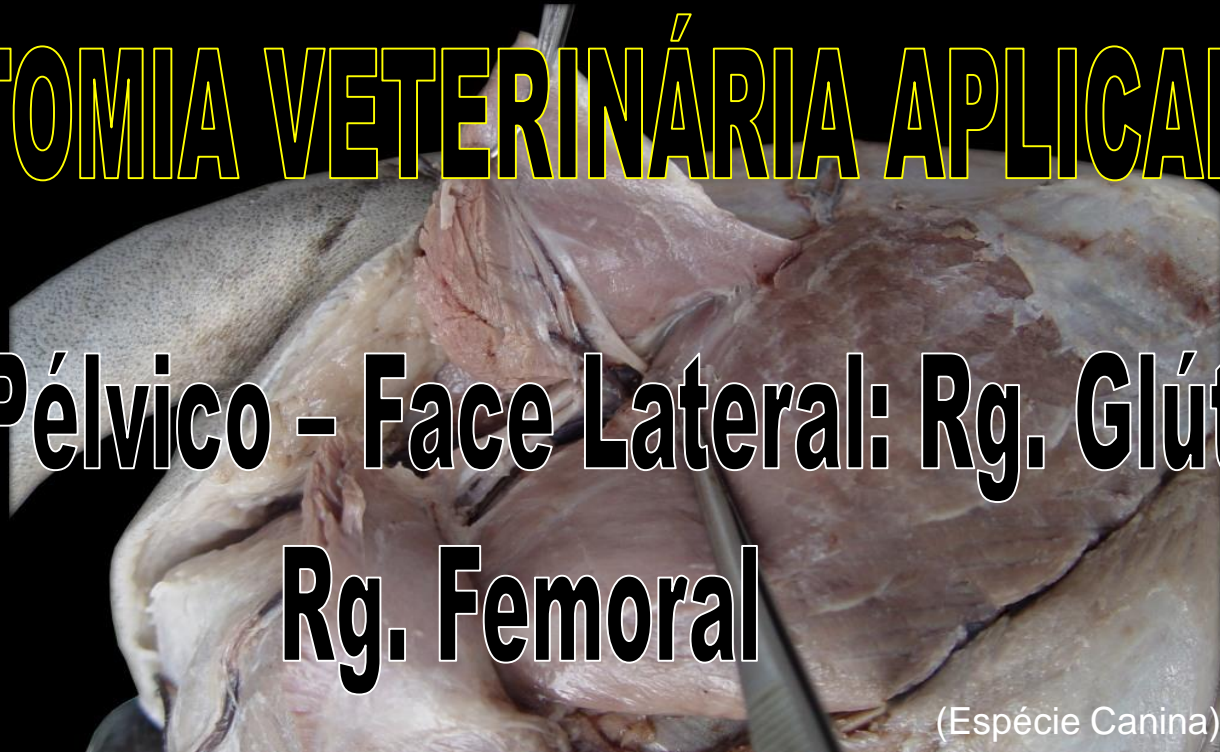

UNIVERSIDADE DE SÃO PAULO
Faculdade de Medicina Veterinária e Zootecnia
Curso de Medicina Veterinária



ANATOMIA VETERINÁRIA APLICADA

**Membro Pélvico - Face Lateral: Rg. Glútea e
Rg. Femoral**

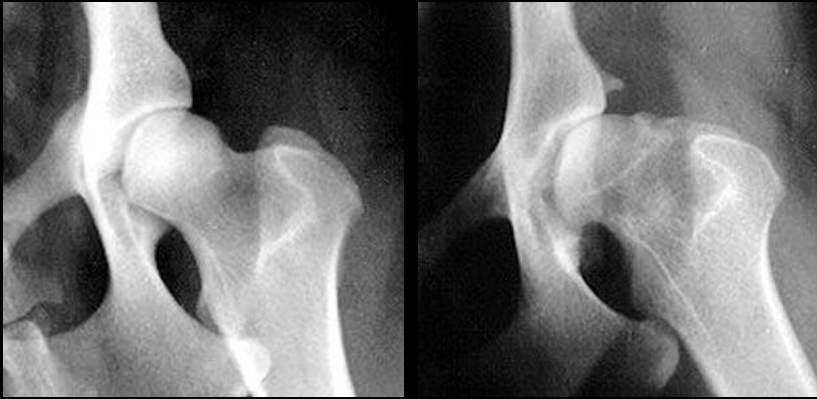

(Espécie Canina)

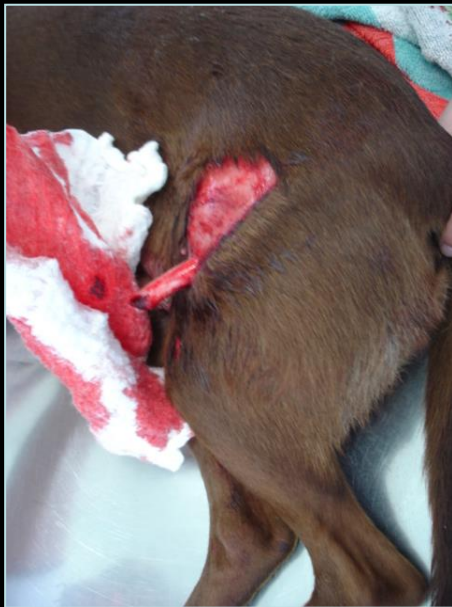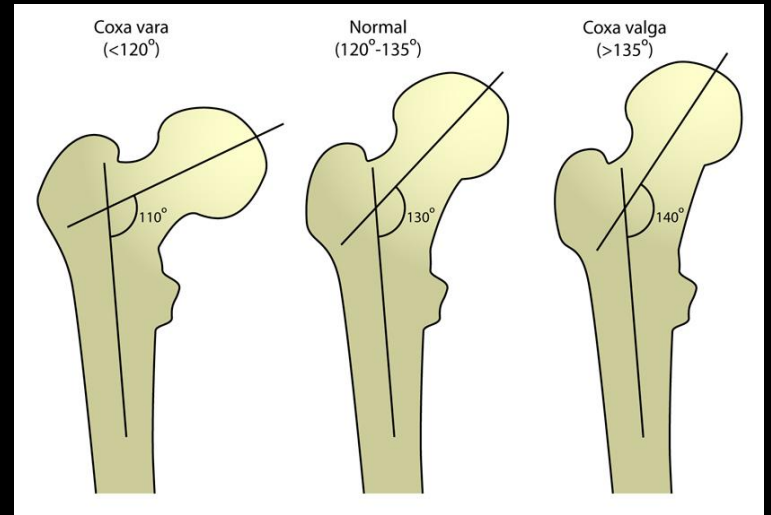
Profs. Tais Sasahara e Silvio Gomes
VCI 5703 - 2022

Importância Clínico-Cirúrgica

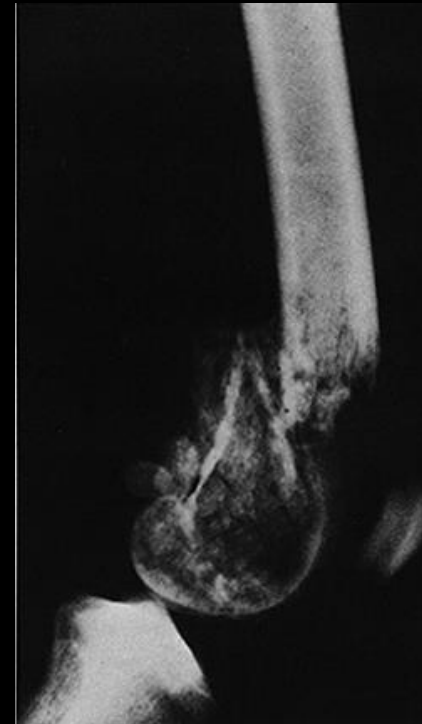
- **Articulação coxofemoral:**
 - Traumas – fraturas do acetábulo, da cabeça ou colo do fêmur; luxação coxofemoral, etc.
 - Congênita ou evolutiva – displasia coxofemoral, osteoartrite;
 - Adquirida: neoplasias, artropatias imune-mediadas, etc.
- **Fêmur:**
 - Traumas – fraturas da cabeça, colo, trocânter maior, diáfise, côndilos, etc;
 - Congênita ou evolutiva – coxa valga (aumento do ângulo entre a cabeça e colo do fêmur em relação ao seu eixo), coxa vara (diminuição), etc.;
 - Adquirida – osteossarcomas.



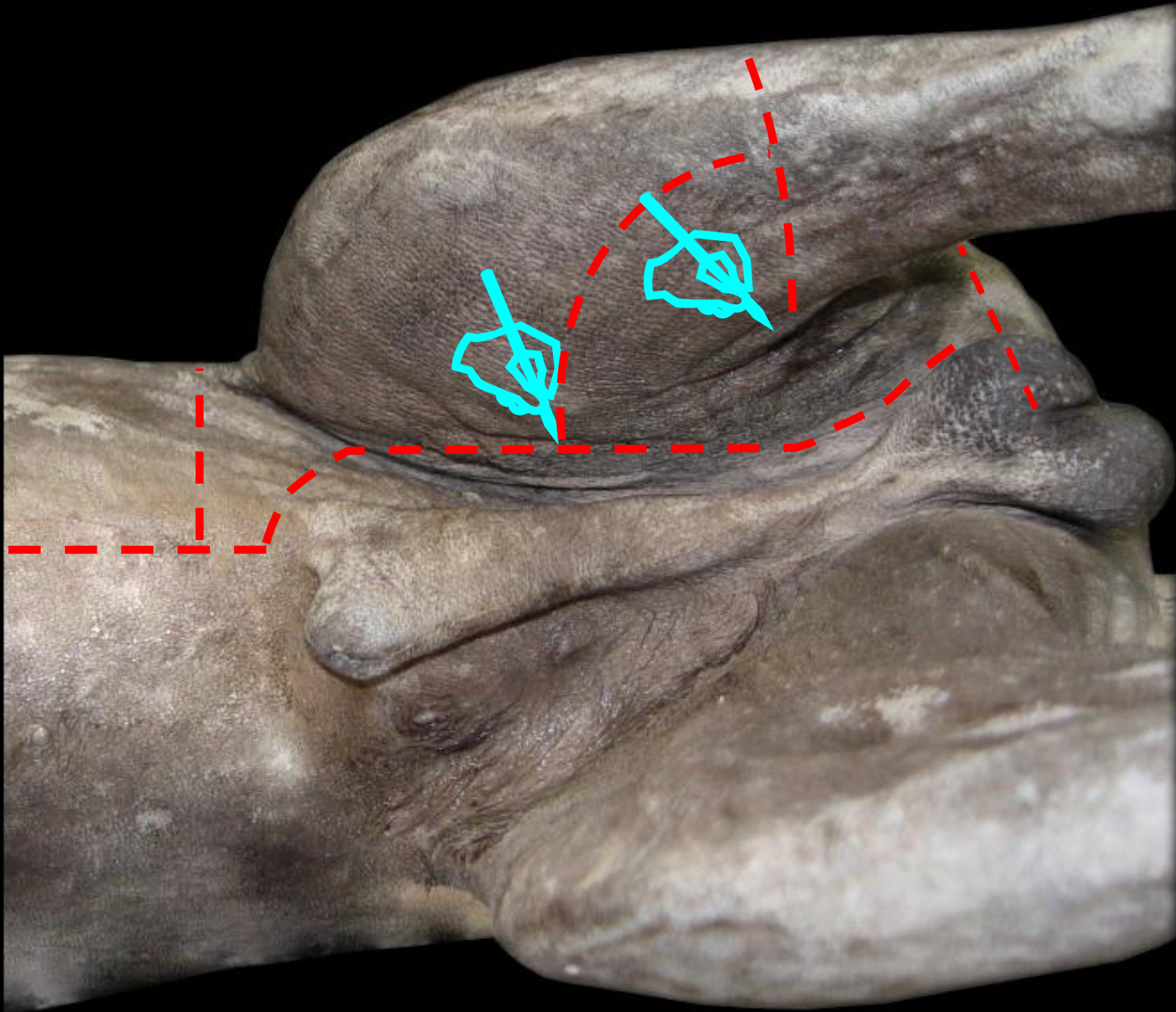
Displasia coxofemoral



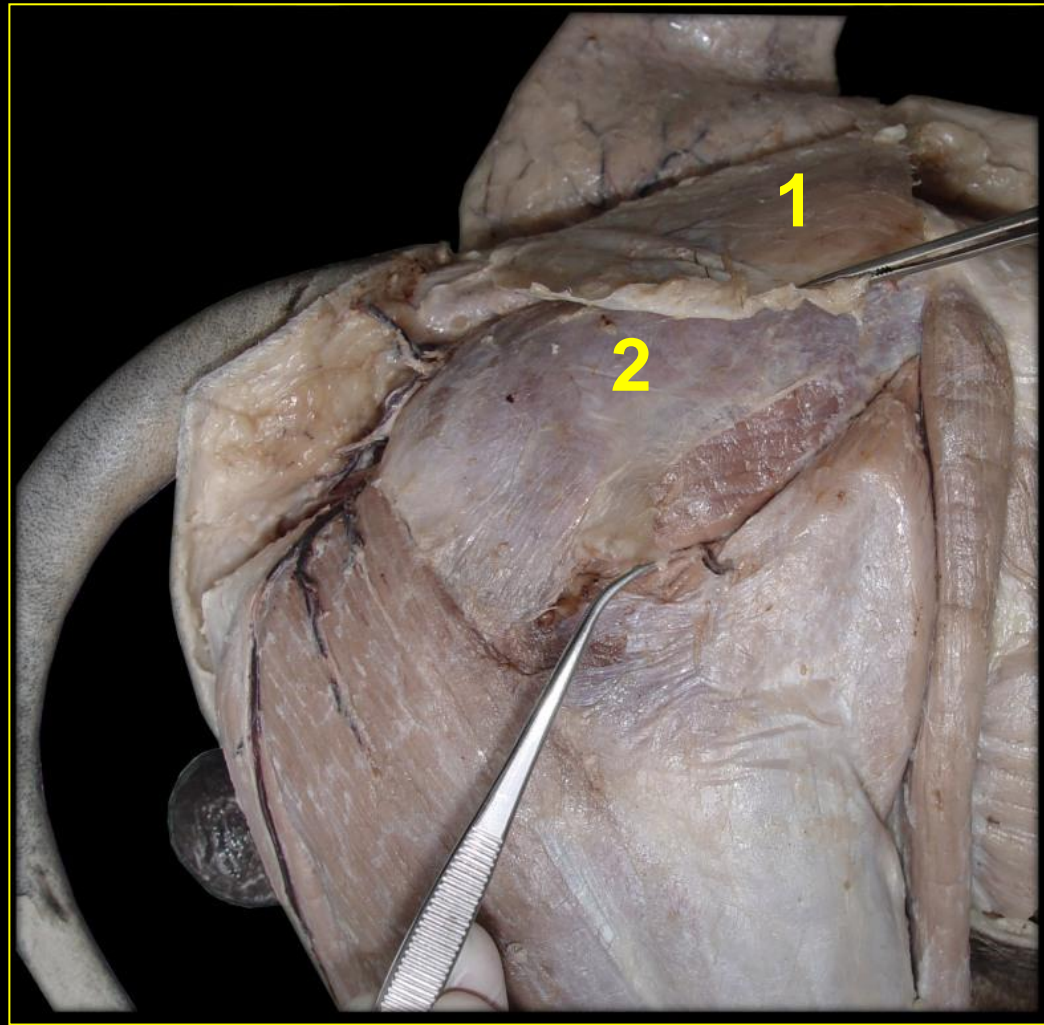
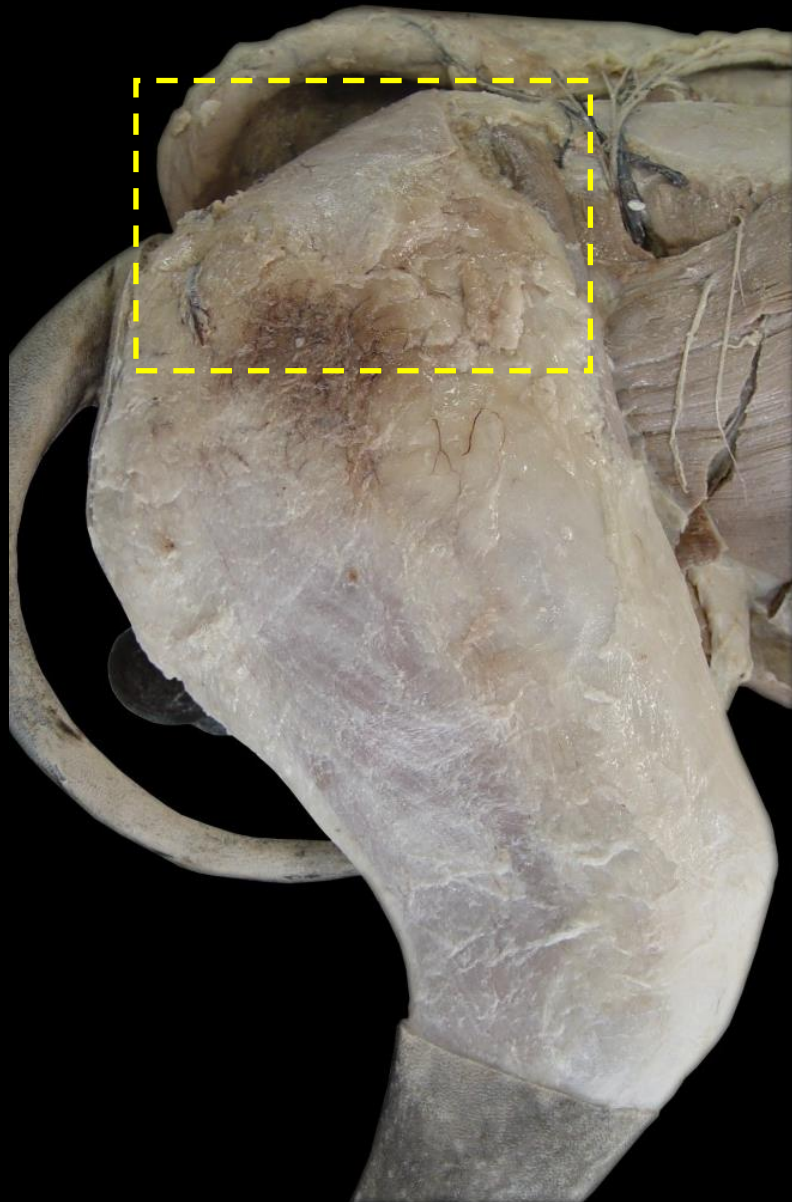
Fratura fêmur - cão



Osteossarcoma - cão



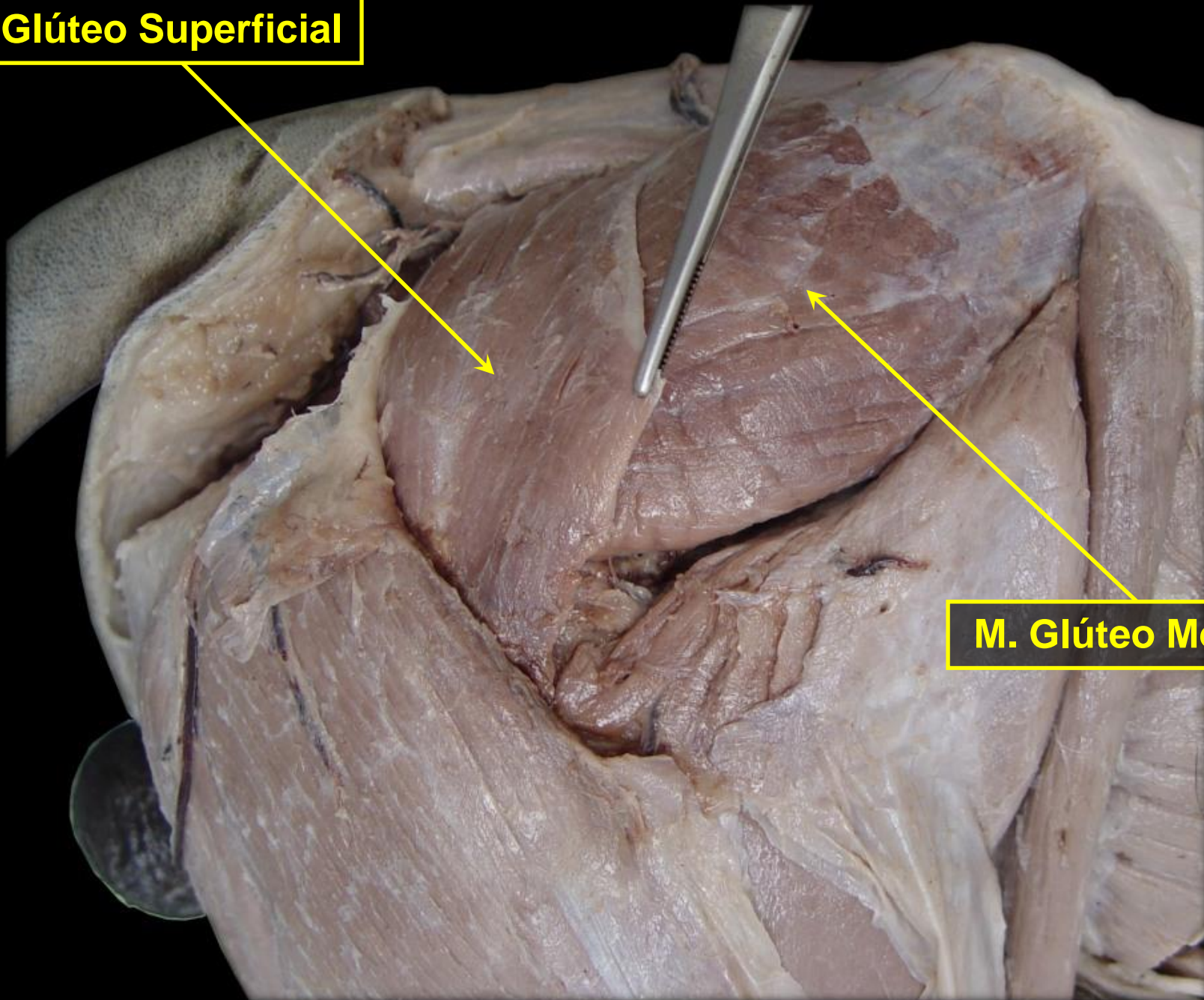
Rg. GLÚTEA - Plano Superficial

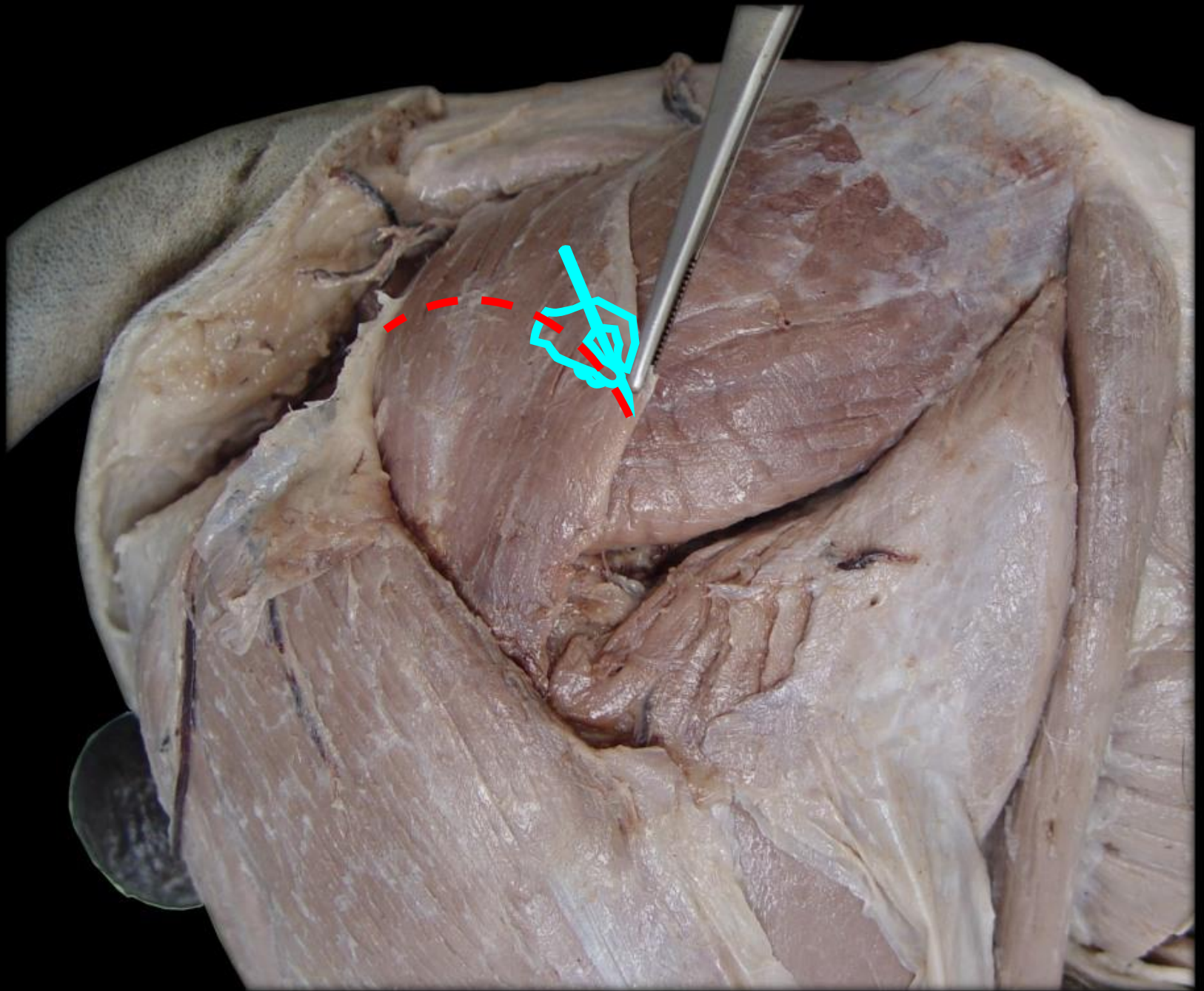


- 1 - M. Cutâneo do Tronco
- 2 - Fáscia Glútea

M. Glúteo Superficial

M. Glúteo Médio





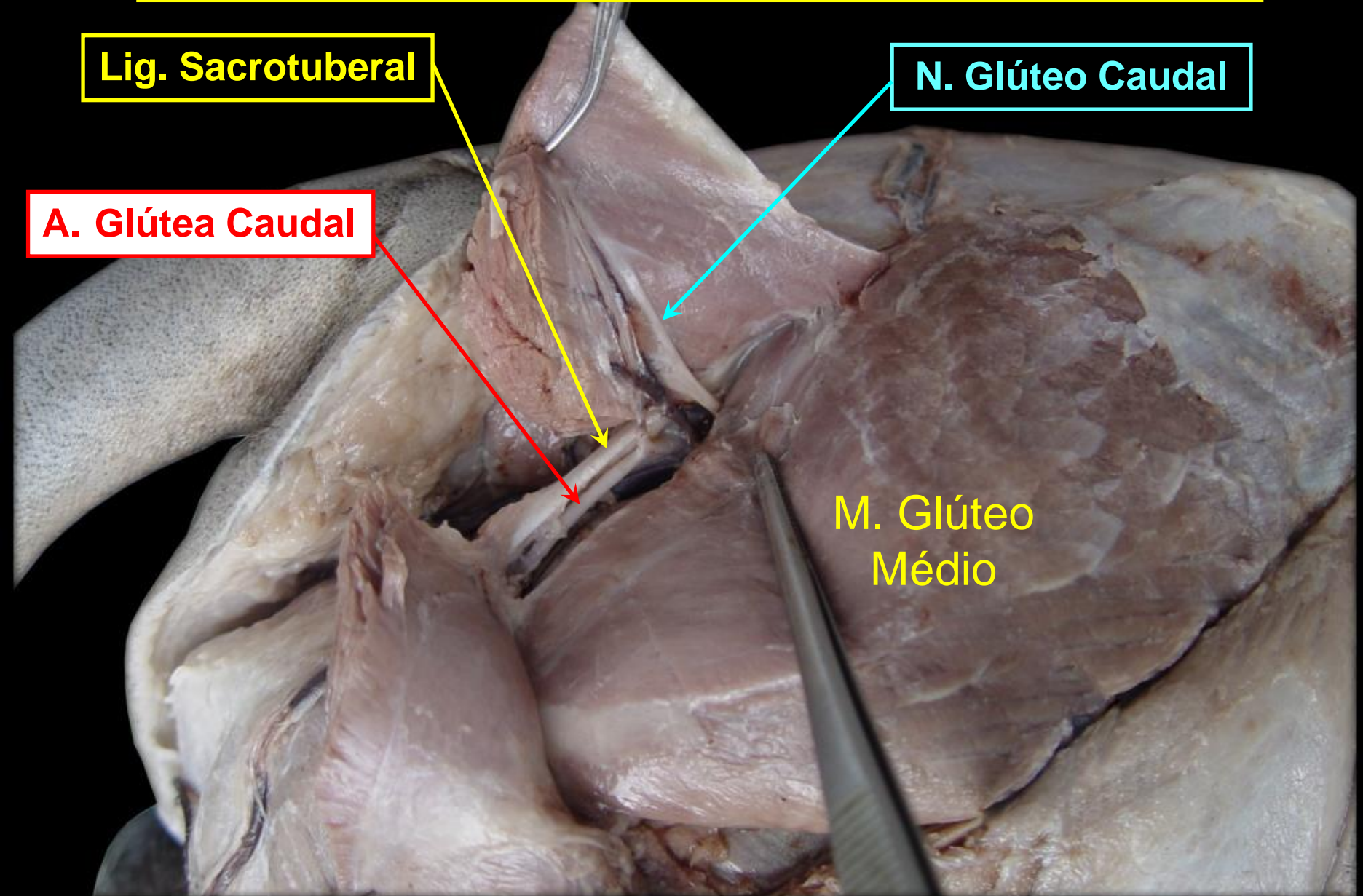
Rg. GLÚTEA - Plano Profundo

Lig. Sacrotuberal

N. Glúteo Caudal

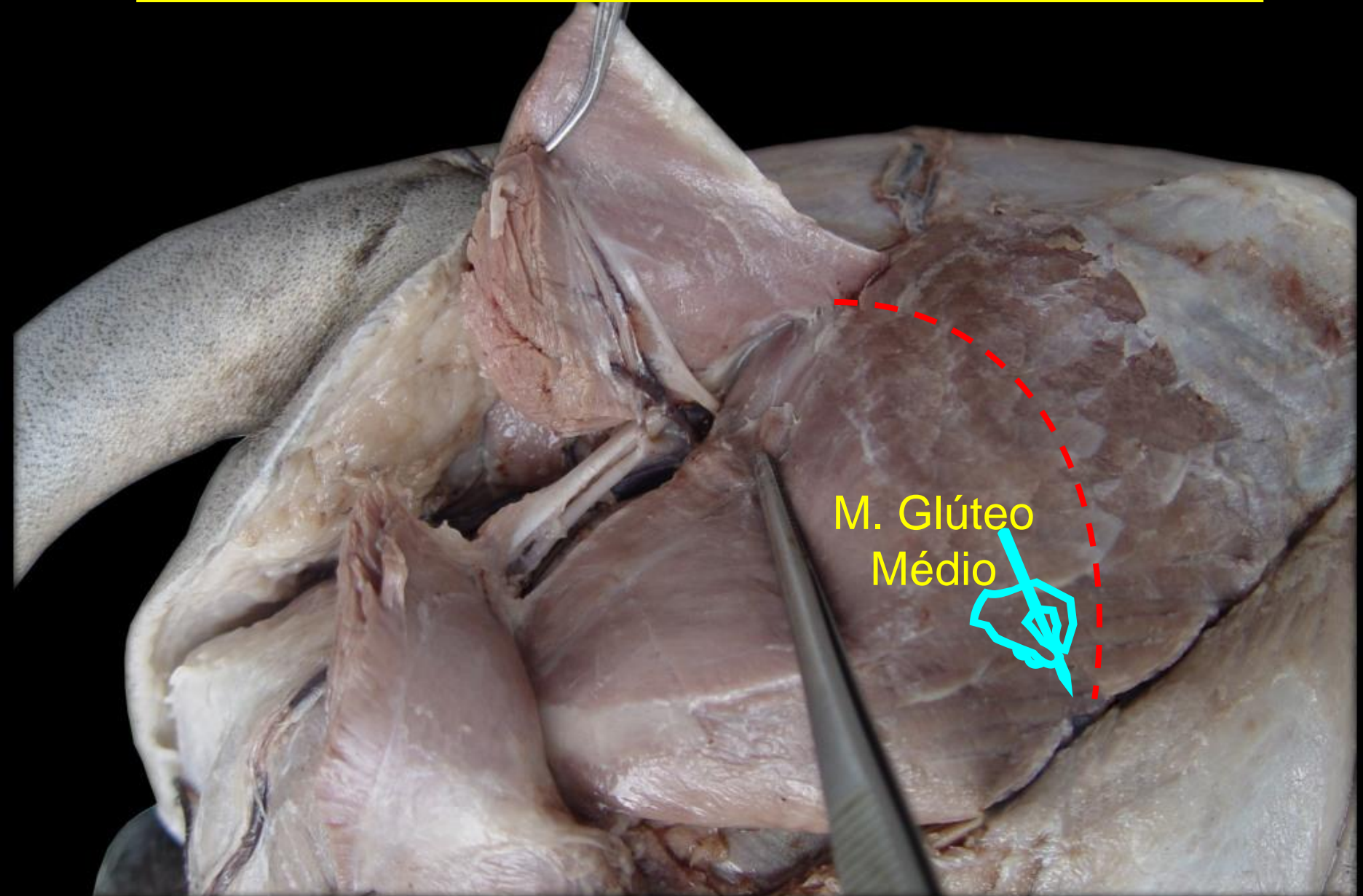
A. Glútea Caudal

M. Glúteo
Médio



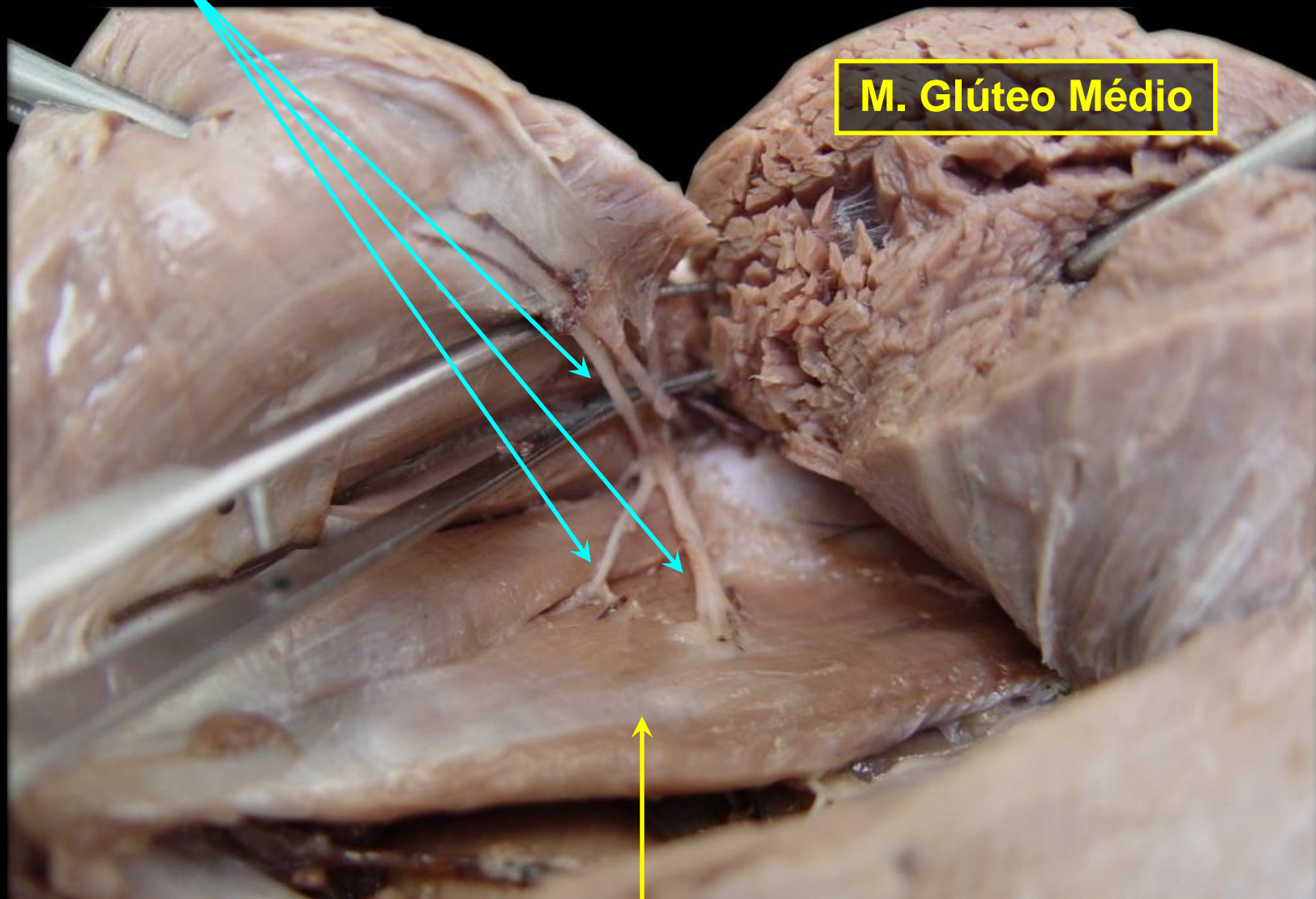
Rg. GLÚTEA - Plano Profundo

M. Glúteo
Médio



Rr. do N. Glúteo Cranial

M. Glúteo Médio

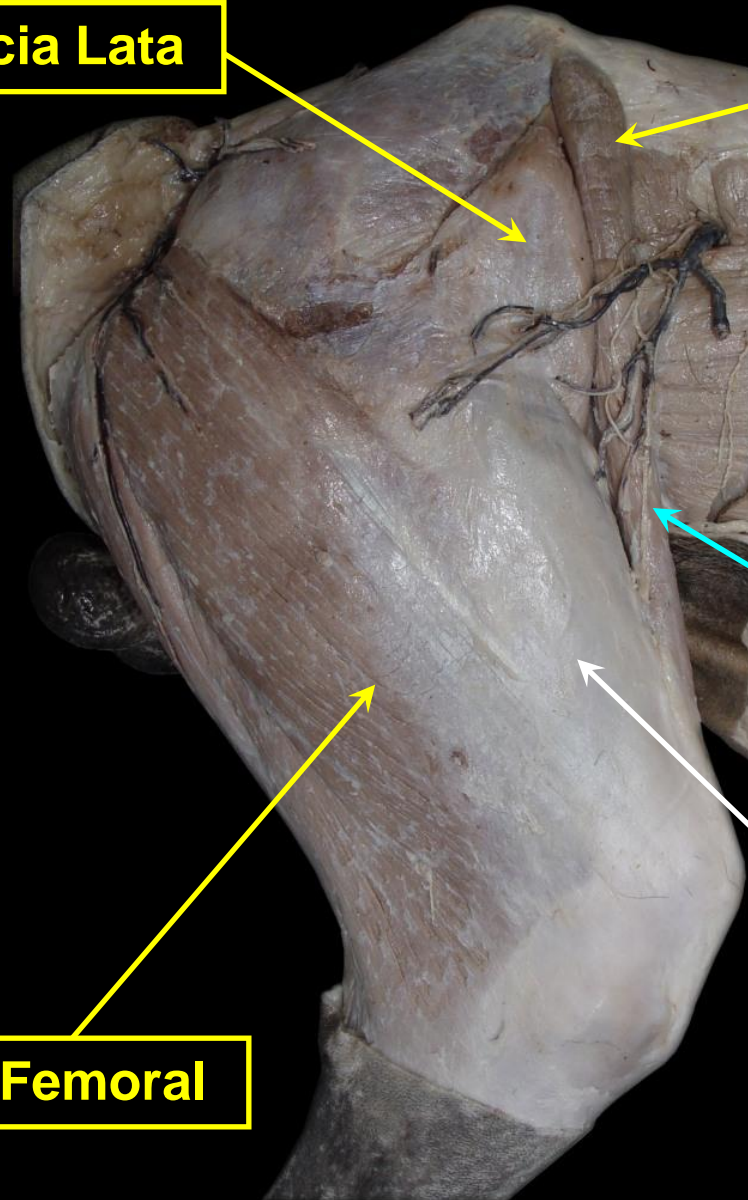
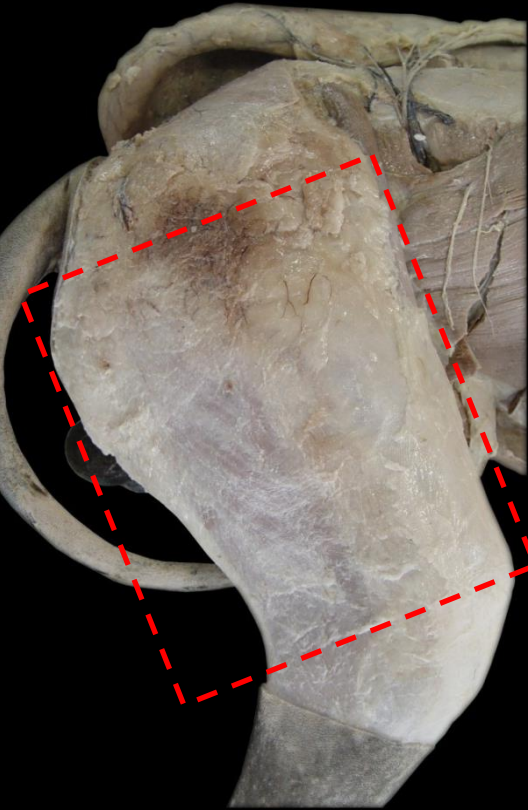

M. Glúteo Profundo

Rg. FEMORAL – Face Lateral

M. Tensor da Fáscia Lata

**M. Sartório
(Parte Cranial)**



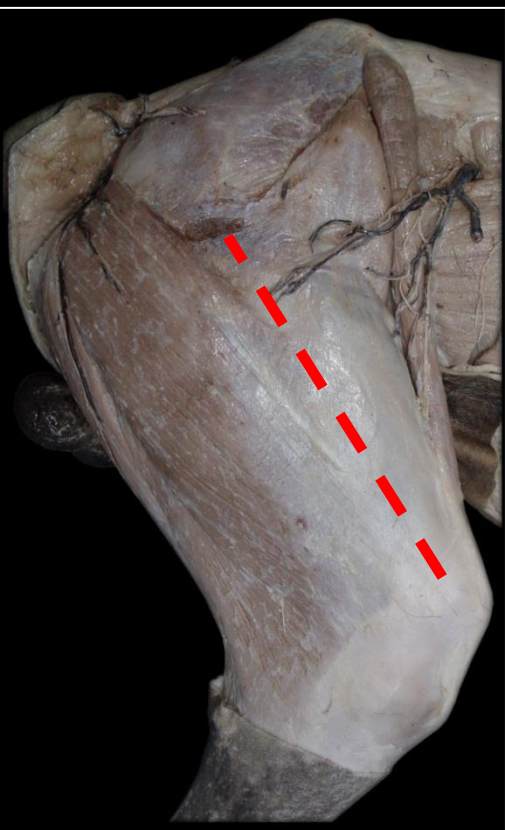
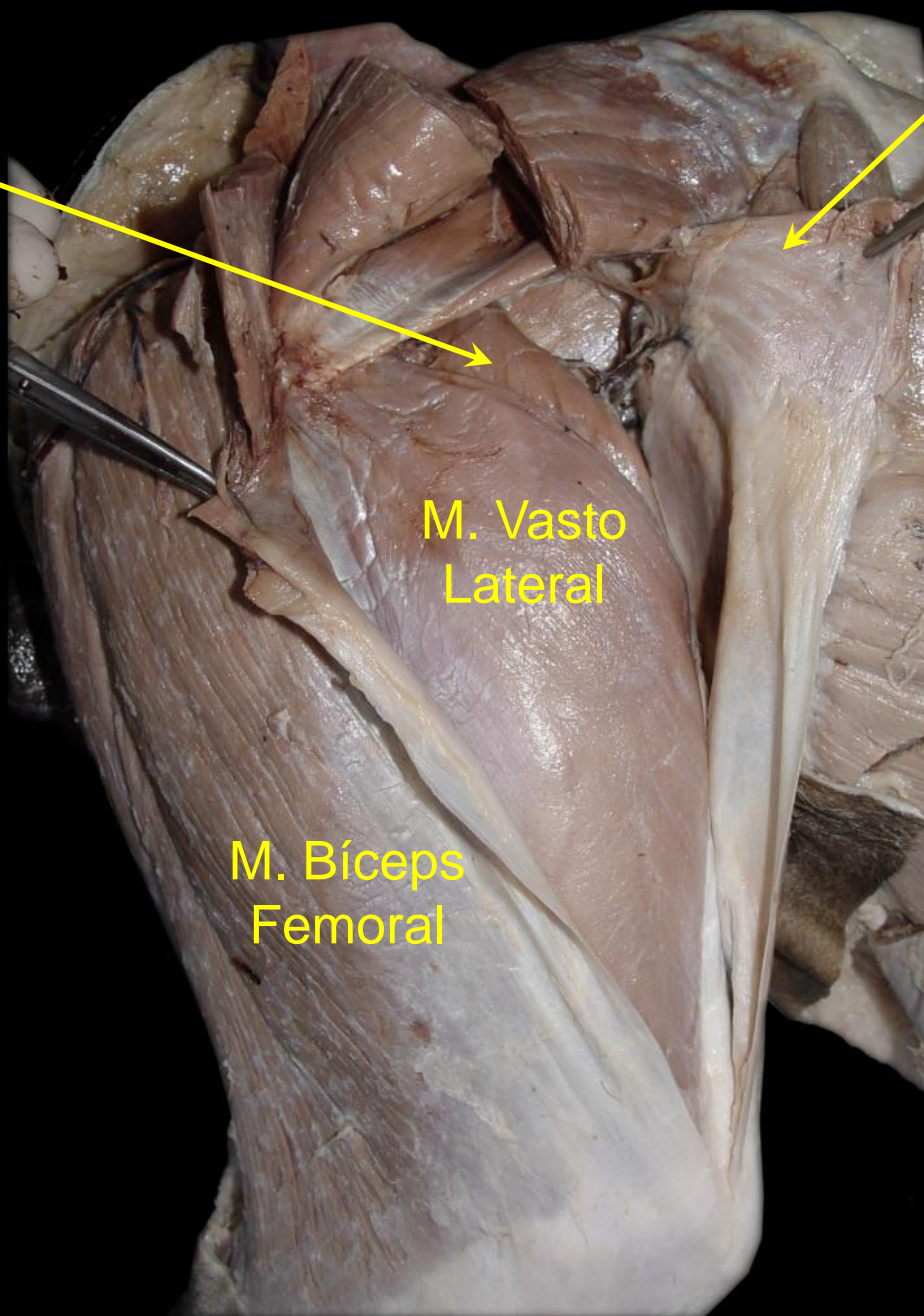
**N. Cutâneo
Femoral
Lateral**

M. Bíceps Femoral

Fáscia Lata

M. Reto Femoral

**M. Tensor
da
Fáscia Lata**



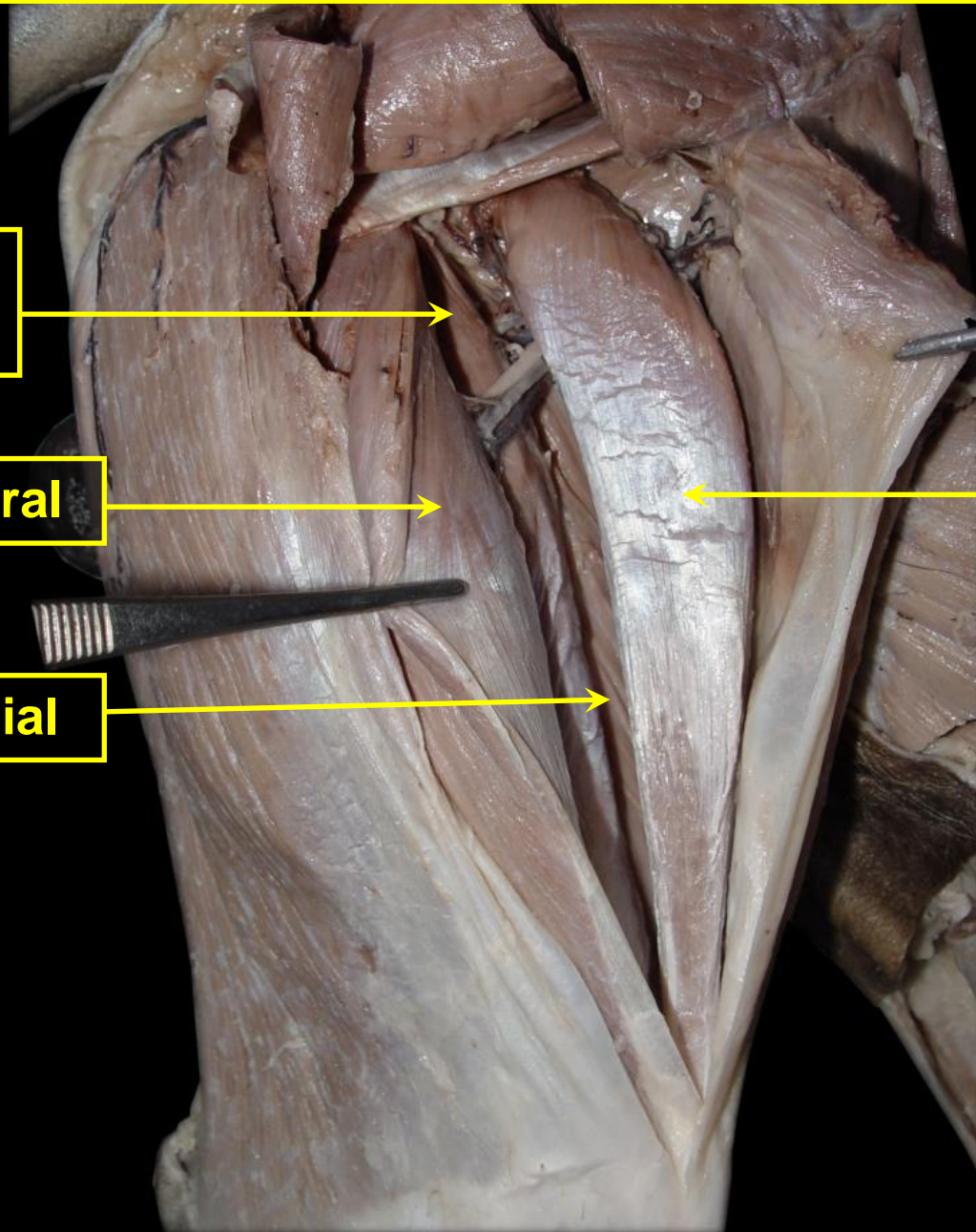
M. QUADRÍCEPS FEMORAL

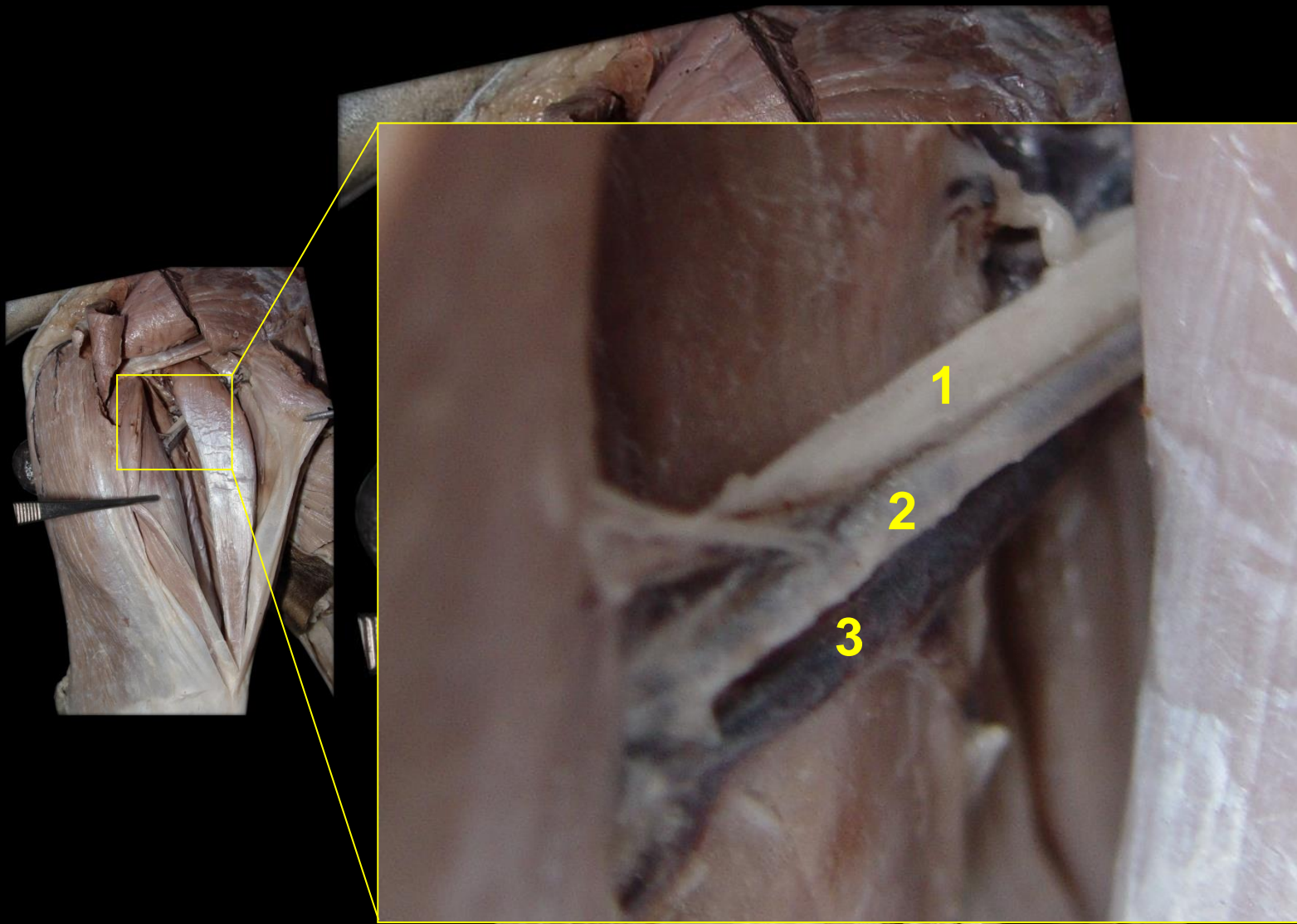
M. Vasto Intermedió

M. Vasto Lateral

M. Vasto Medial

M. Reto Femoral





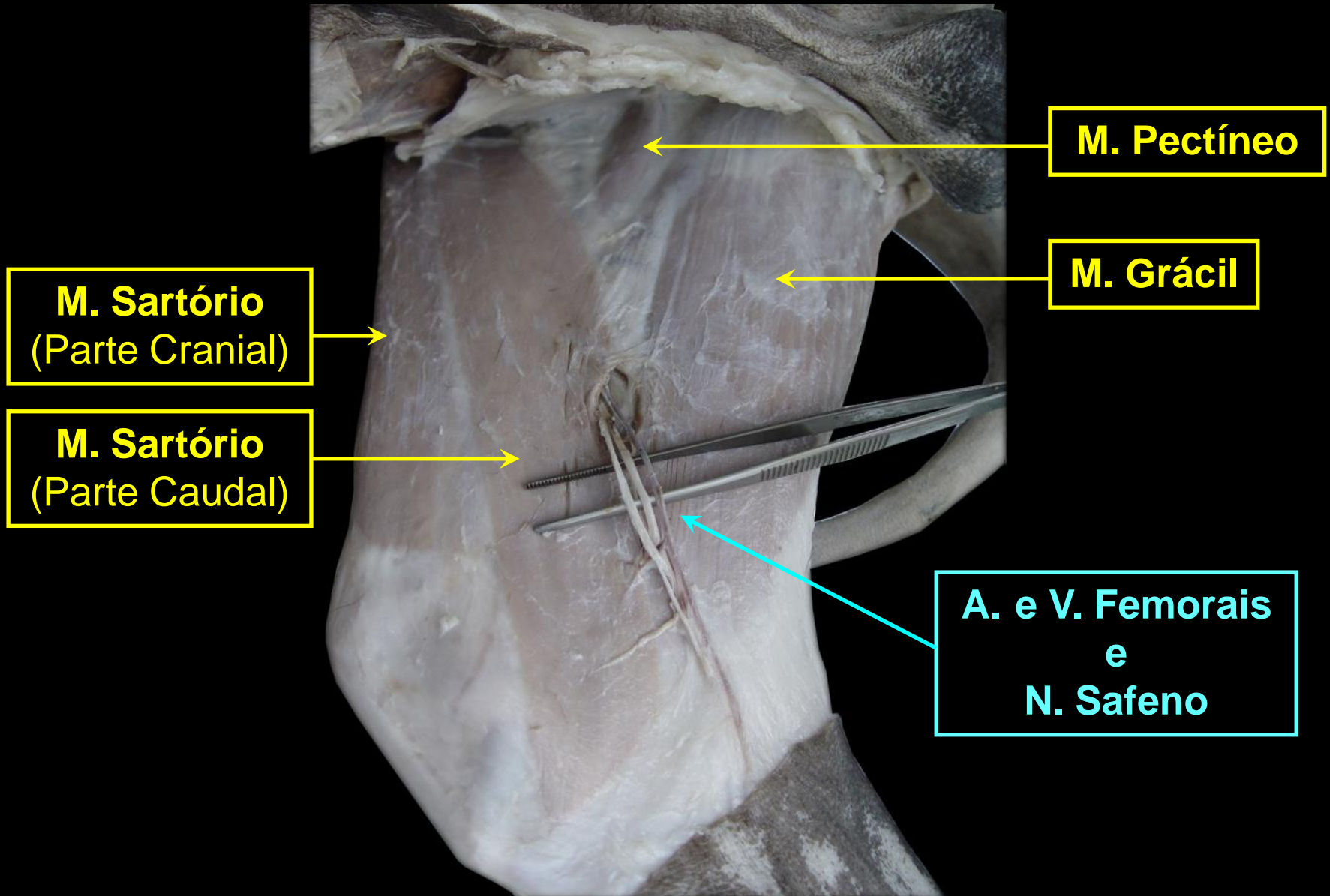
1 – N. Femoral

2 – A. Circunflexa Femoral Lateral

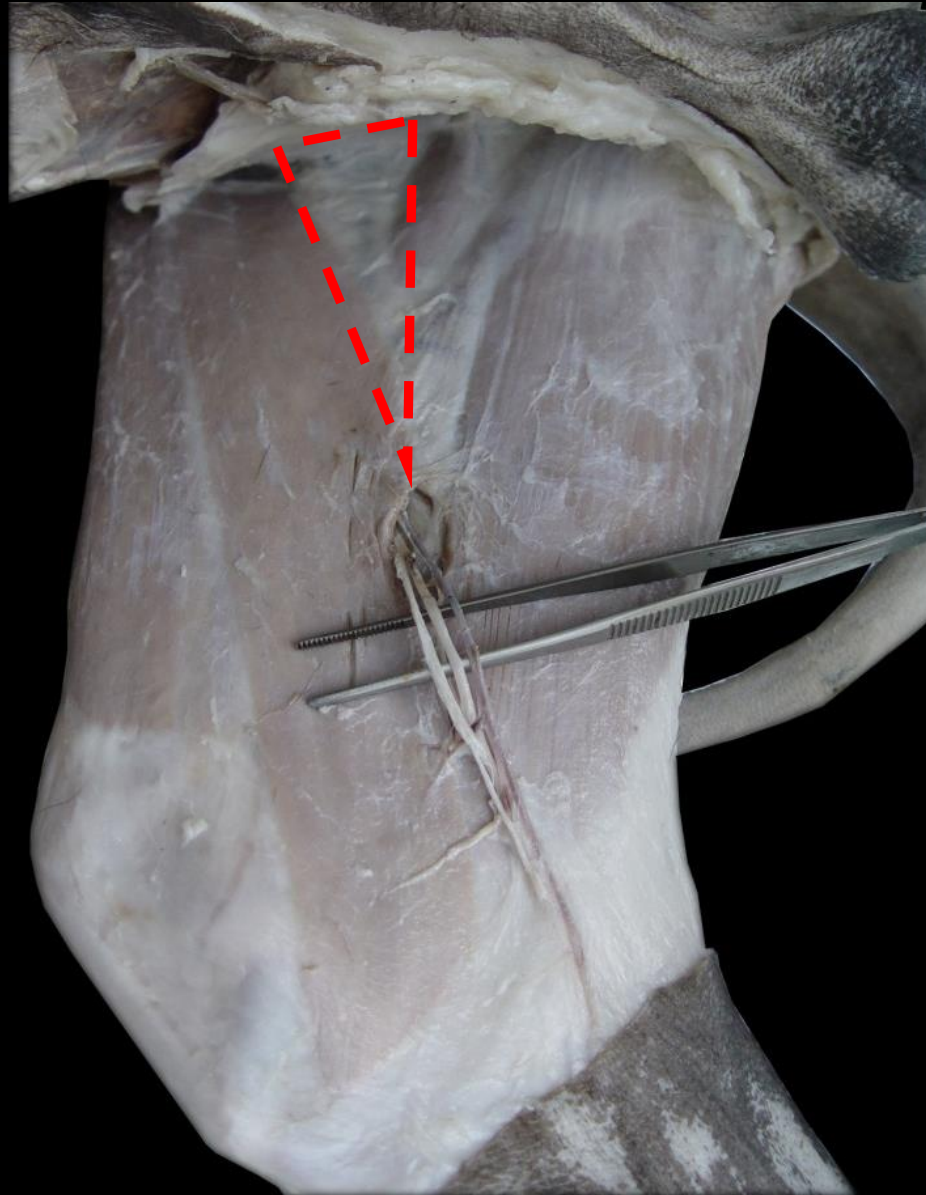
3 – V. Circunflexa Femoral Lateral

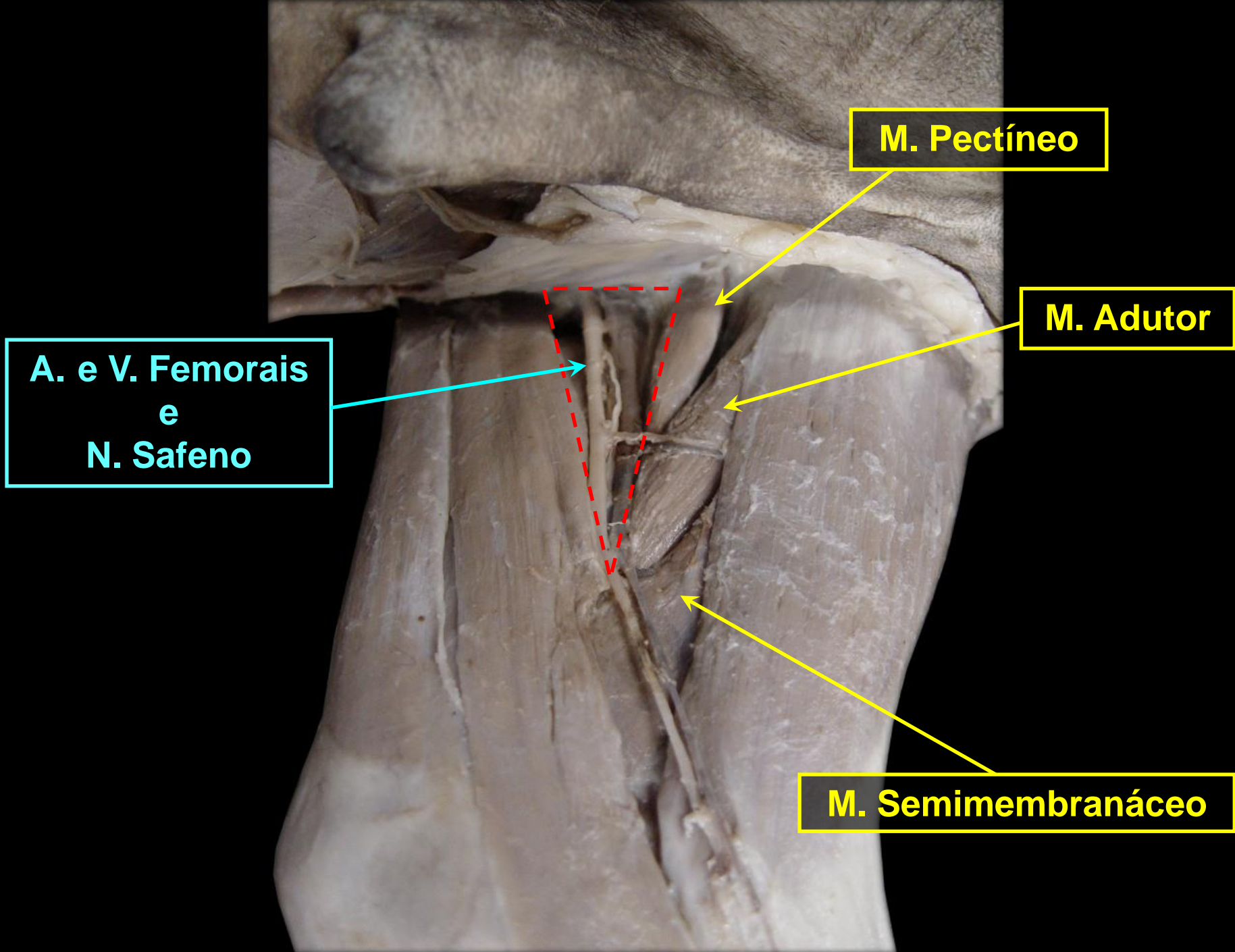
**Rg. FEMORAL – Face
Medial**

Rg. FEMORAL – Face Medial



TRÍGONO FEMORAL



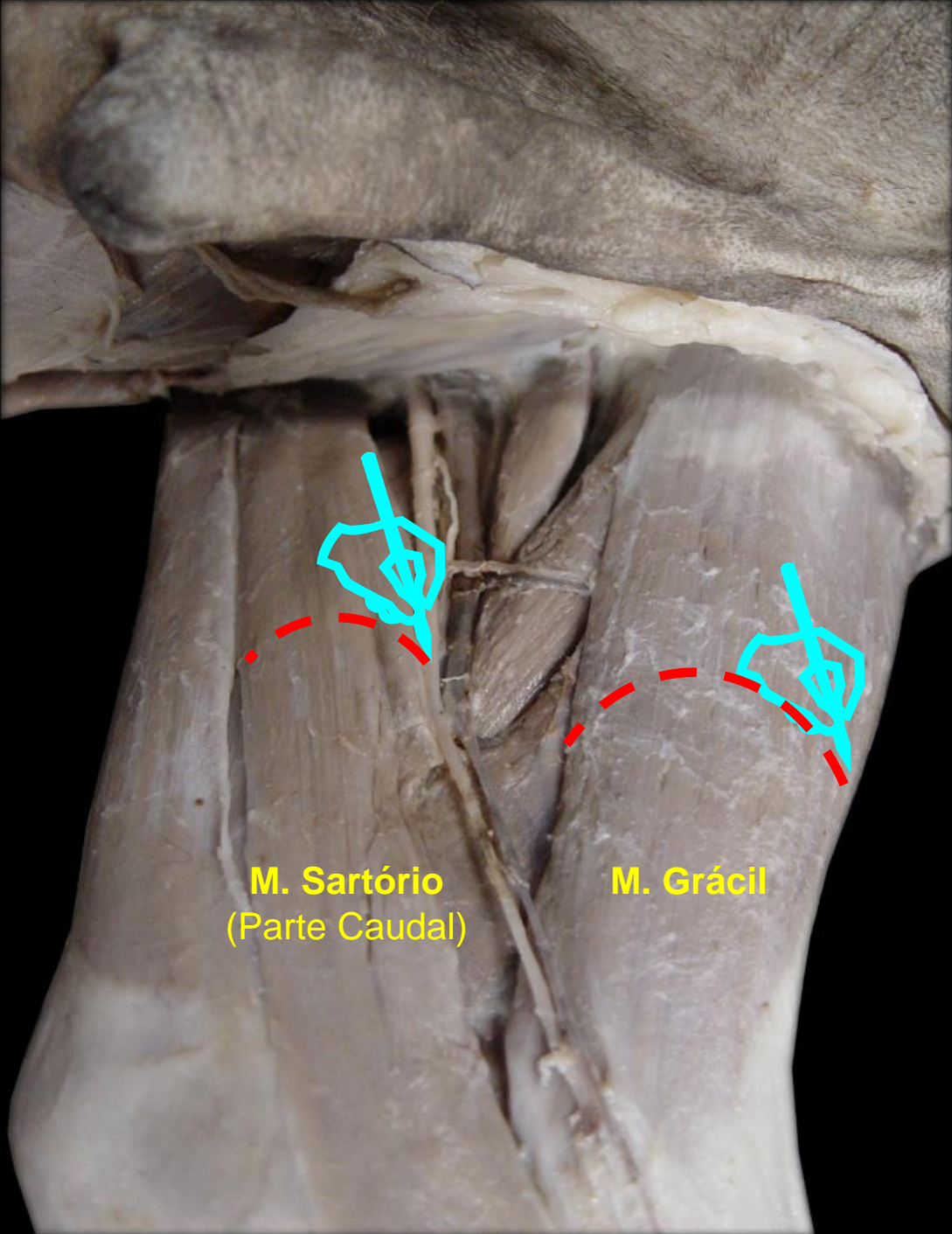


**A. e V. Femorais
e
N. Safeno**

M. Pectíneo

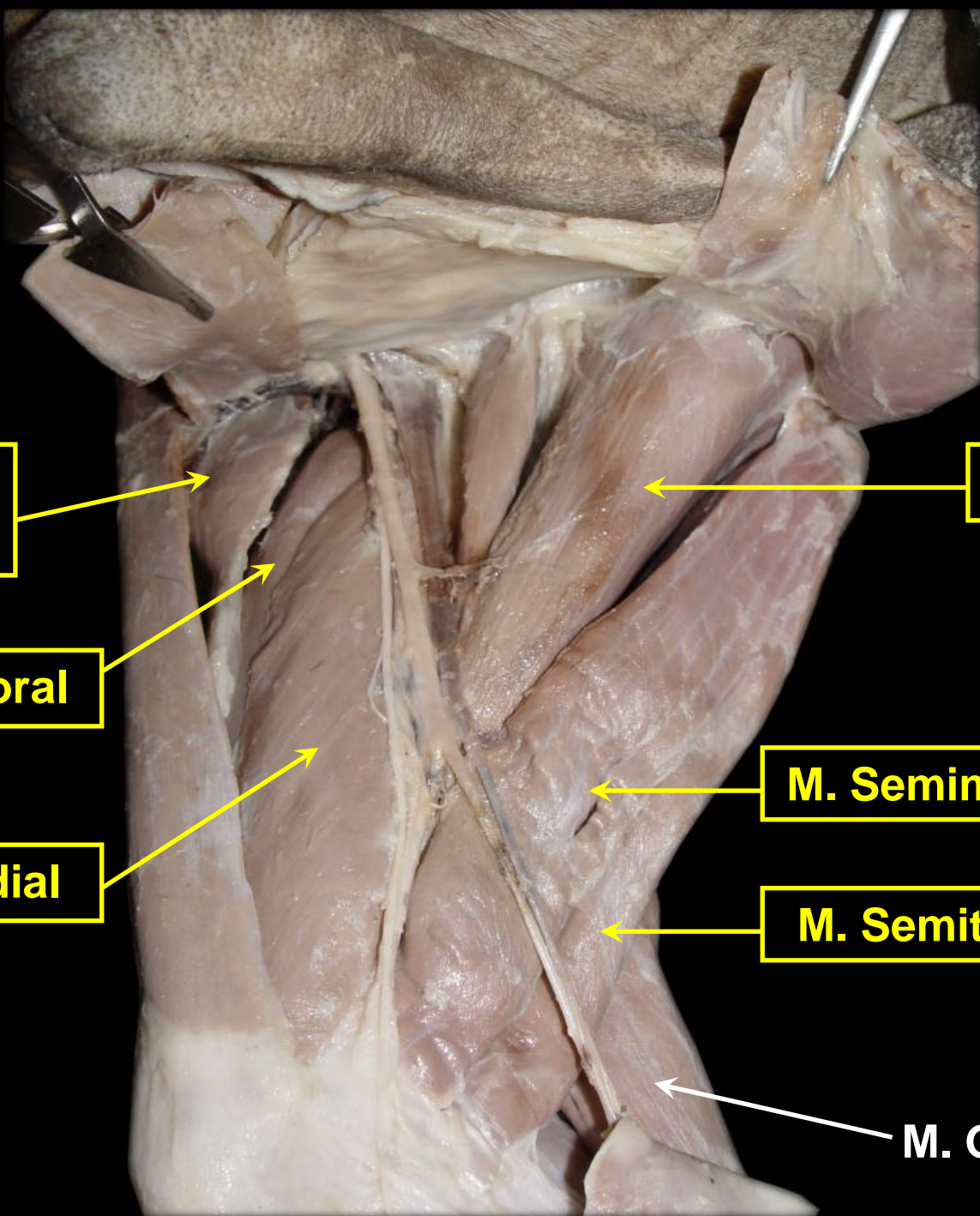
M. Adutor

M. Semimembranáceo



M. Sartorio
(Parte Caudal)

M. Grácil



**M. Tensor da
Fáscia Lata**

M. Reto Femoral

M. Vasto Medial

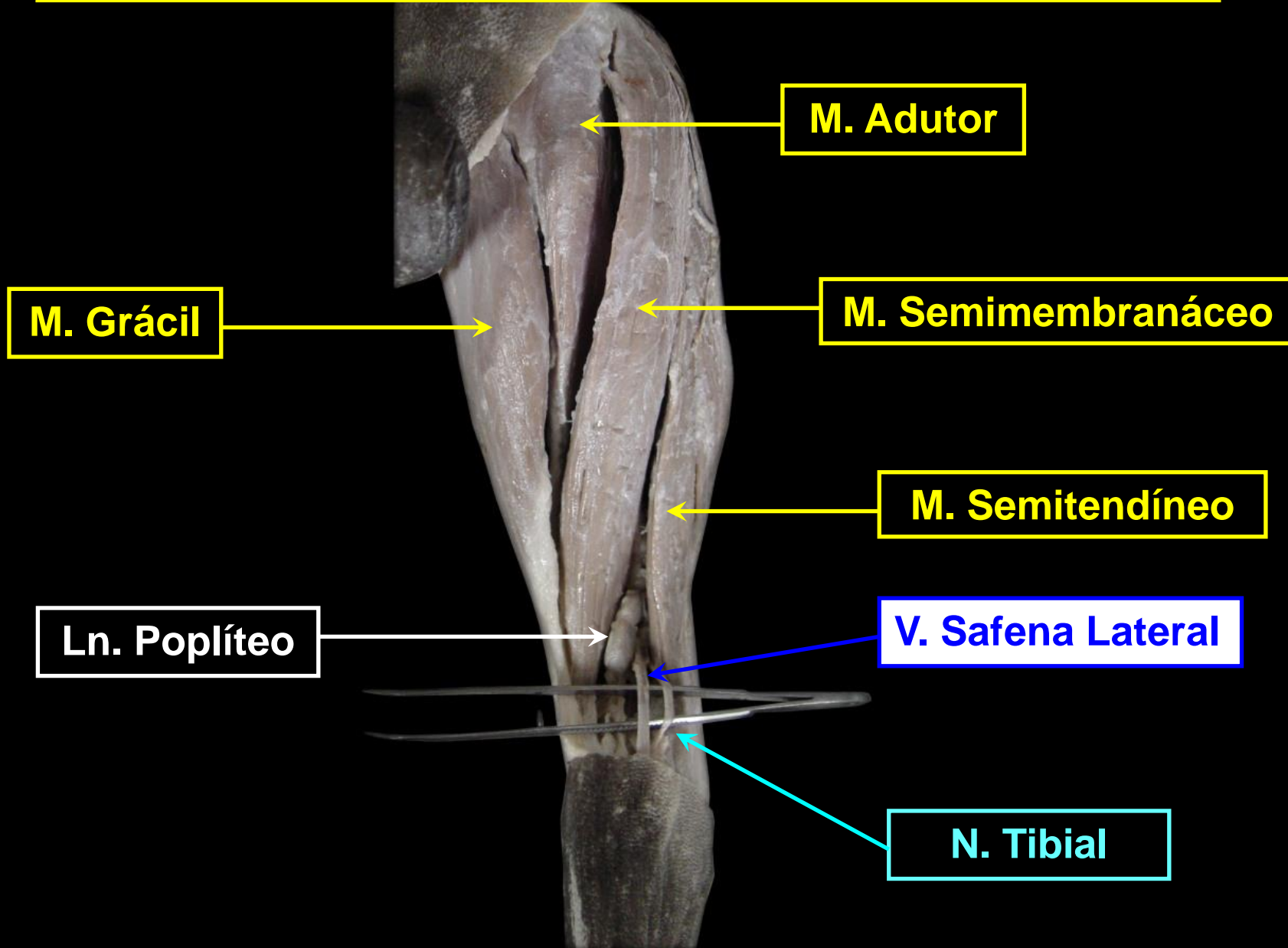
M. Adutor

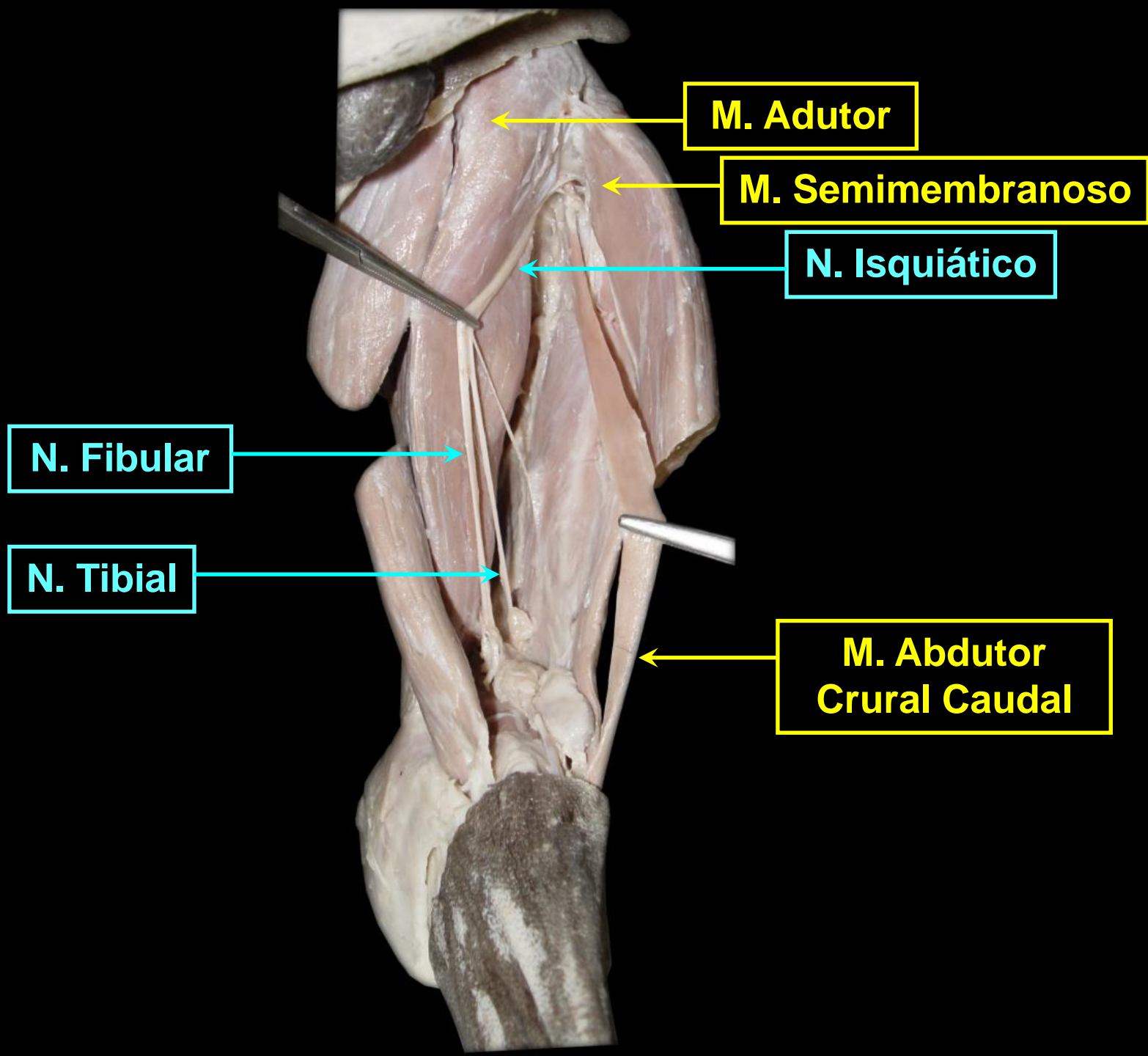
M. Semimembrânico

M. Semitendíneo

M. Gastrocnêmio

Rg. FEMORAL – Face Caudal

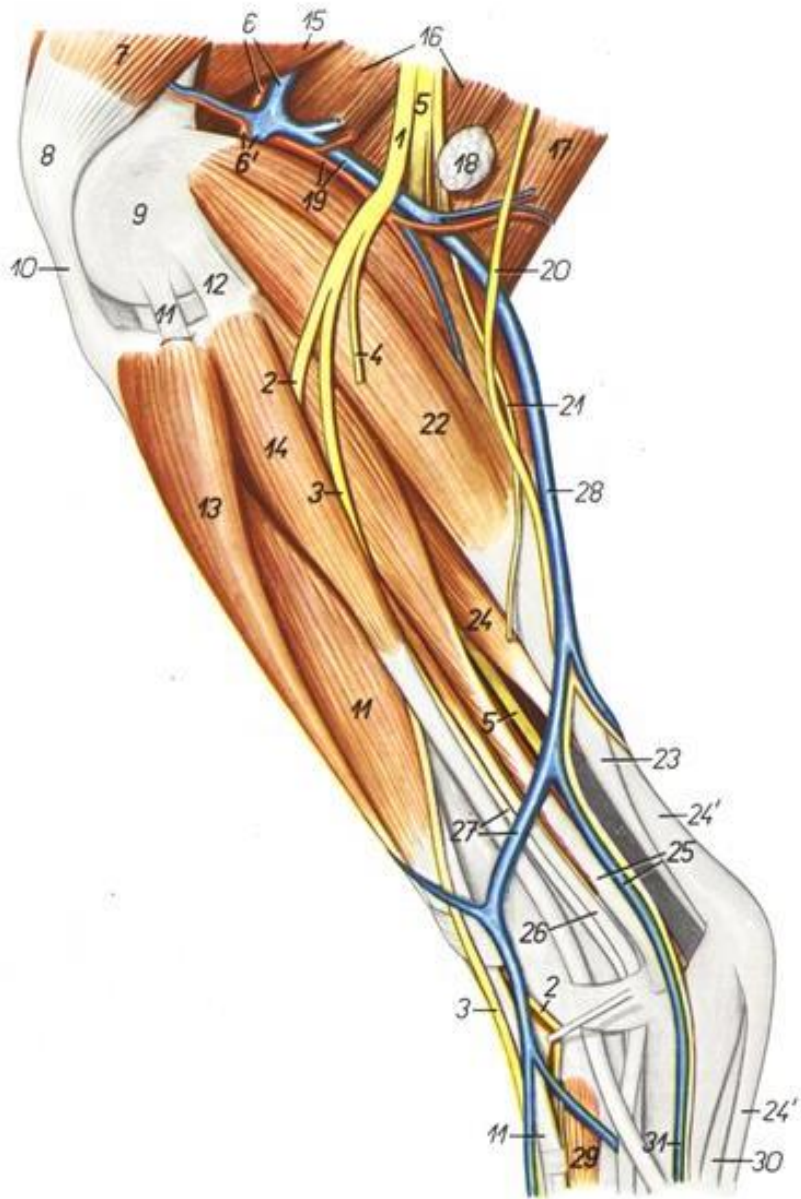




Face lateral da perna

Sequência de cranial para caudal

- 13- m. tibial cranial
- 11- m. extensor digital longo
- 14- m. fibular longo
- 24- m. flexor digital superficial
- 22- m. gastrocnêmio

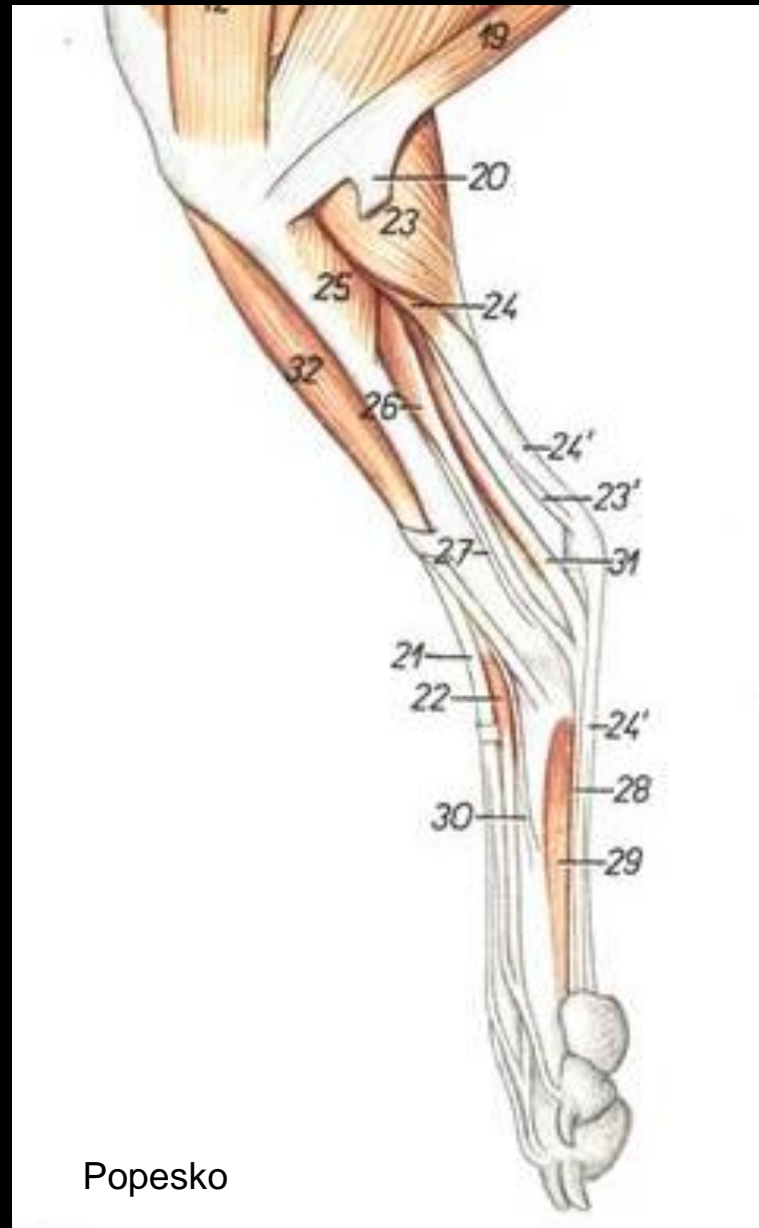


Popesko

Face medial da perna

Sequência de cranial para caudal

- 32- m. tibial cranial
- 25- m. poplíteo
- 26- m. flexor digital longo
- 24- m. flexor digital superficial
- 23- m. gastrocnêmio



Popesko