

IMAGING DIAGNOSIS—POSITIVE CONTRAST PERITONEOGRAPHIC FEATURES OF TRUE DIAPHRAGMATIC HERNIA

JIHYE CHOI, HYUNWOOK KIM, MIEUN KIM, JUNGHEE YOON

A true diaphragmatic hernia is a congenital diaphragmatic malformation that can appear identical to a peritoneopericardial diaphragmatic hernia (PPDH). True diaphragmatic hernias are rare in dogs. Herein we describe the use of positive contrast peritoneography for diagnosis of a true diaphragmatic hernia in two dogs. *Veterinary Radiology & Ultrasound, Vol. 50, No. 2, 2009, pp 185–187.*

Key words: dog, peritoneopericardial diaphragmatic hernia, positive peritoneography, true diaphragmatic hernia.

Dog 1

A 2-YEAR-OLD intact female Pekingese had hypocalcemic neuropathy after parturition. The dog recovered after calcium administration but the owner requested thoracic radiographs for a health inspection. There was an enlarged cardiac silhouette with a focal bulge on its right caudal aspect (Fig. 1). A diaphragmatic hernia was suspected. Positive peritoneography was performed. Nonionic contrast medium, Iohexol* was injected into the peritoneal cavity near the midline at a dosage of 1 ml/kg. The pelvis was elevated for about 5 min to facilitate contrast medium flow to the cranial aspect of the abdomen. The contrast medium delineated a round pouch adjacent to the cardiac silhouette. There was no evidence of leakage of contrast medium in either the pericardium or the pleural cavity. A presumptive diagnosis of true diaphragmatic hernia was made and the dog is being monitored without treatment.

Dog 2

A 1.5-year-old, female Pomeranian was referred because of a suspected pericardioperitoneal diaphragmatic hernia

(PPDH). The right caudal border of the heart was characterized by an abnormal round structure (Fig. 2). A diaphragmatic hernia was suspected. Positive peritoneography was performed as described for Dog 1. A round pouch that protruded into the thoracic cavity identified. There was no communication between the structure and the pericardial sac or the structure and the pleural cavity. A presumptive diagnosis of true diaphragmatic hernia was made and the patient is being monitored without treatment.

Discussion

With a diaphragmatic hernia, some abdominal organs enter the thoracic cavity through an abnormal opening.¹ A diaphragmatic hernia may be congenital or acquired, and can be categorized as a PPDH, a pleuroperitoneal hernia, or a hiatal hernia.¹ A PPDH is characterized by an incomplete closure of the diaphragm, resulting in prolapse of abdominal viscera into the pericardial sac.^{1–3} A PPDH may be a consequence of faulty development of the dorsolateral septum transversum, or a prenatal injury to the septum transversum.⁴ Pleuroperitoneal hernias may be traumatic, or as a consequence of failure of the lateral pleuroperitoneal folds and the ventromedial pars sternalis to unite.⁴

A true diaphragmatic hernia is a congenital diaphragmatic malformation that is distinct from PPDH and also from herniation of abdominal contents into the pleural cavity. With a PPDH, the peritoneal cavity freely communicates with the pericardial sac, but in a true diaphragmatic hernia there is an incomplete diaphragmatic tear in which a direct communication between the pleural and peritoneal

*Omnipaque, Nycomed, Amersham Health, Cork, Ireland.

From the Haemaru Animal Referral Hospital (Choi, Kim), and the College of Veterinary Medicine and BK21 Program for Veterinary Science (Kim, Yoon), Seoul National University, 599 Gwanangno, Gwanak-gu, Seoul 151-742, South Korea.

Address correspondence to Junghee Yoon, DVM, PhD, at the above address. E-mail: heeyoon@snu.ac.kr

Received February 19, 2008; accepted for publication September 15, 2008.

doi: 10.1111/j.1740-8261.2009.01514.x

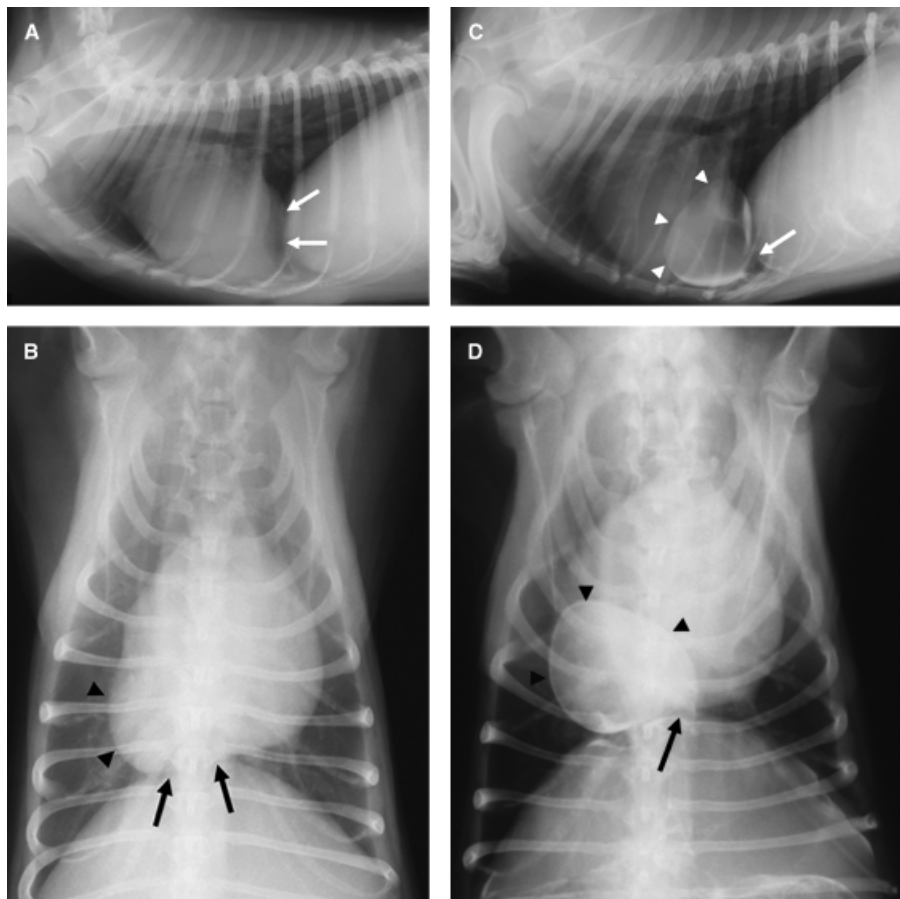


FIG. 1. Thoracic radiographs of Dog 1. On the survey images (A, B), the enlarged, round cardiac silhouette contacts with the diaphragm (arrows). The right caudal border (arrowheads) of the heart is bulging on the ventrodorsal view (B). By positive peritoneography (C, D), a pouch (arrowheads) is delineated by contrast medium within the pleural space and contacts the diaphragm (arrow).

cavities is prevented by the serosa on the thoracic surface of the diaphragm that remains intact.

A true diaphragmatic hernia is rare in dogs and is usually asymptomatic. A PPDH is also usually asymptomatic but can lead to vague clinical signs. Differentiation between a PPDH and a true diaphragmatic hernia may be achieved with positive contrast peritoneography.

Other conditions may appear similar to a diaphragmatic hernia. A diaphragmatic eventration is a condition where the diaphragmatic muscle is malpositioned.^{5,6} A congenital eventration is a developmental abnormality characterized by muscular aplasia of the diaphragm.⁵ Acquired eventration is caused by injury, such as secondary to birth trauma or to an injury sustained during intrathoracic surgery, to the phrenic nerve with resultant paralysis and cranial displacement of the entire diaphragm.⁵ Diaphragmatic eventration is rarely symptomatic, and typically only requires conservative treatment or monitoring.⁶ Diaphragmatic eventration is common in humans.^{5,6} In veterinary medicine, diaphragmatic eventration

has been referred to as a “true diaphragmatic hernia” and is defined as a subtotal diaphragmatic tear in which the serosa on the thoracic surface of the diaphragm remains intact.⁷ A diaphragmatic eventration is characterized by displacement of part of or the whole of the hemidiaphragm cranially without malposition of abdominal organs into the thoracic cavity.

In this report, the abdominal organs did not prolapse into the thoracic cavity, as with the previously reported diaphragmatic eventrations; however, the appearance was different from that expected with a diaphragmatic eventration. The lesion was characterized as a round pouch that contained abdominal viscera and was superimposed over the pericardial sac. In prior reports, the so-called diaphragmatic eventration occurred in the muscular part of the left or right diaphragmatic crura.

A true diaphragmatic hernia may be asymptomatic, as in the dogs in this report, and only monitoring is necessary.⁸ However, clinical signs may develop as a previous report in a cat where surgery was considered necessary.⁷ A PPDH

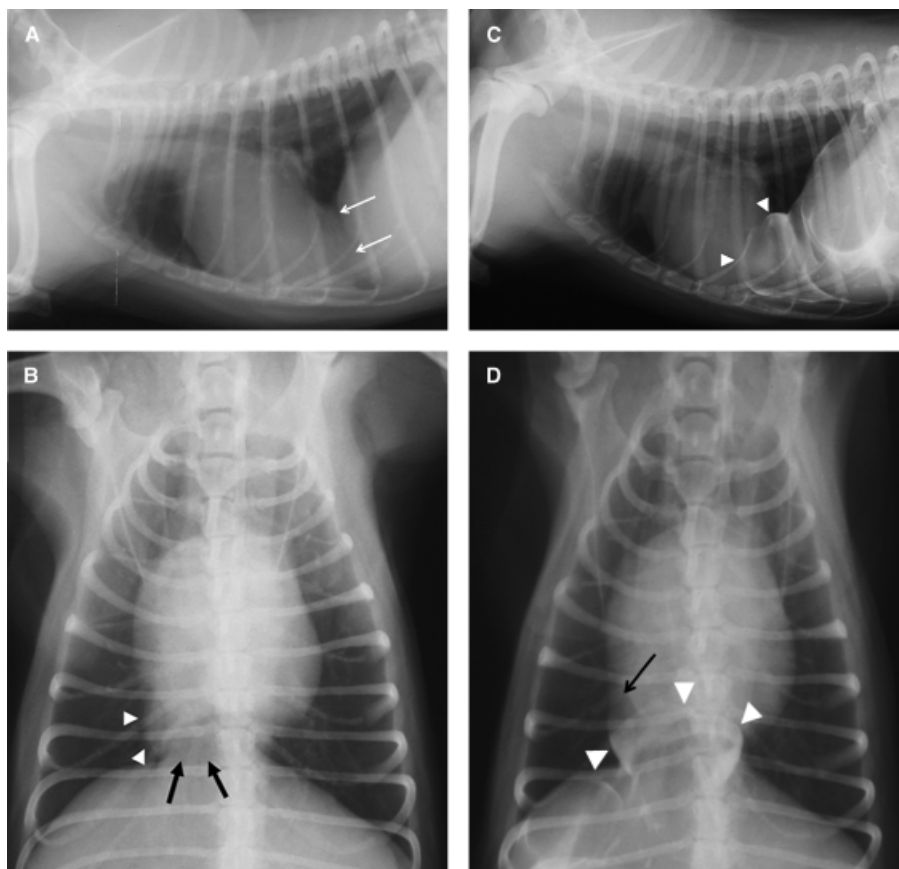


FIG. 2. Thoracic radiographs of Dog 2. On the survey lateral view (A), the caudal aspect of the cardiac silhouette (arrows) overlaps with cranial aspect of the diaphragm and on ventrodorsal view (B), a round soft tissue structure (arrowheads) is positioned between the heart and diaphragm (arrows). By positive peritoneography (C, D), the small pouch (arrowheads), delineated by the contrast medium, protrudes from the peritoneal cavity into the pleural space. This line is differentiated from cardiac border (arrow). Contrast medium does not distribute into the pericardial sac, as with a peritoneopericardial diaphragmatic hernia.

can also be asymptomatic; however, various clinical signs, such as respiratory, gastrointestinal, and other vague signs, can develop necessitating surgical correction.⁸

Limitations of our report are that we cannot definitively clarify where the pouch was located, what organs were

displaced, or the number and characteristics of the wall layers. However, based on the appearance of the lesions in the peritoneograms, and the difference from prior descriptions of PPDH and diaphragmatic eventration, we speculate that they represented true diaphragmatic hernias.

REFERENCES

1. Fossum TW. Pleural and extrahepatic diseases. In: Ettinger SJ, Feldman EC (eds): Textbook of veterinary internal medicine, 5th ed. Philadelphia: WB Saunders, 2000;1098–1111.
2. Wilson GP, Hayes HM. Diaphragmatic hernia in the dog and cat: a twenty five year overview. *Semin Vet Med Surg* 1986;1:318–326.
3. Reed JR. Pericardial disease and cardiac tumors. In: Fox PR, Sisson D, Moise NS (eds): Textbook of canine and feline cardiology: principles and clinical practice, 2nd ed. Philadelphia: WB Saunders, 1999;679–701.
4. Evans SM, Biery DN. Congenital peritoneopericardial diaphragmatic hernia in the dog and cat: a literature review and 17 additional case histories. *Vet Radiol* 1980;21:108–116.
5. Tiryaki T, Livanelioğlu Z, Atayurt H. Eventration of the diaphragm. *Asian J Surg* 2006;29:8–10.
6. Mantoo SK, Mak K. Congenital diaphragmatic eventration in an adult: a diagnostic dilemma. *Singapore Med J* 2007;48:e136–e137.
7. Voges AK, Bertrand S, Hill RC, Neuwirth L, Schaer M. True diaphragmatic hernia in a cat. *Vet Radiol Ultrasound* 1997;38:116–119.
8. Reimer SB, Kyles AE, Filipowicz DE, Gregory CR. Long-term outcome of cats treated conservatively or surgically for peritoneopericardial diaphragmatic hernia: 66 cases (1987–2002). *J Am Vet Med Assoc* 2004;224:728–732.