

Available online at [www.sciencedirect.com](http://www.sciencedirect.com)

ScienceDirect

journal homepage: <http://ees.elsevier.com/gendis/default.asp>

## REVIEW ARTICLE

# Twists and turns of the genetic story of mevalonate kinase-associated diseases: A review

Isabelle Touitou <sup>a,b</sup><sup>a</sup> IRMB, Univ Montpellier, INSERM, Montpellier, France<sup>b</sup> Department of Medical Genetics, Rare Diseases and Personalized Medicine, Rare and Autoinflammatory Diseases Unit, CeRéMAIA, CHU, Montpellier, 34000, France

Received 20 January 2021; received in revised form 19 April 2021; accepted 12 May 2021

**KEYWORDS**Autoinflammatory disease;  
Genetic disease;  
Mevalonate kinase deficiency;  
Porokeratosis;  
Subtypes

**Abstract** Mevalonate kinase (MK)-associated diseases encompass a broad spectrum of rare auto-inflammatory conditions, all resulting from pathogenic variants in the mevalonate kinase gene (*MVK*). Their clinical manifestations are highly variable, ranging from more or less serious systemic disorders, such as hereditary recurrent fevers, to purely localized pathologies such as porokeratosis. The oldest condition identified as linked to this gene is a metabolic disease called mevalonic aciduria, and the most recent is disseminated superficial actinic porokeratosis, a disease limited to the skin. The modes of inheritance of MK-associated diseases also diverge among the different subtypes: recessive for the systemic subtypes and dominant with a post-zygotic somatic genetic alteration for *MVK*-associated porokeratosis. This review quickly retraces the historical steps that led to the description of the various MK-associated disease phenotypes and to a better understanding of their pathophysiology, then summarizes and compares the different genetic mechanisms involved in this group of disorders, and finally discusses the diverse causes that could underlie this phenotypic heterogeneity.

Copyright © 2021, Chongqing Medical University. Production and hosting by Elsevier B.V. This is an open access article under the CC BY-NC-ND license (<http://creativecommons.org/licenses/by-nc-nd/4.0/>).

**Abbreviations:** DSAP, Disseminated superficial actinic porokeratosis; HIDS, Hyper-IgD syndrome with periodic fever; IL-1, Interleukin 1; MA, Mevalonic aciduria; MK, Mevalonate kinase (protein); MKD, Mevalonate kinase deficiency; MVK, Mevalonate kinase (gene); PK, Porokeratosis; RP, Retinitis pigmentosa.

E-mail address: [isabelle.touitou@inserm.fr](mailto:isabelle.touitou@inserm.fr).

Peer review under responsibility of Chongqing Medical University.

<https://doi.org/10.1016/j.gendis.2021.05.002>

2352-3042/Copyright © 2021, Chongqing Medical University. Production and hosting by Elsevier B.V. This is an open access article under the CC BY-NC-ND license (<http://creativecommons.org/licenses/by-nc-nd/4.0/>).

Please cite this article as: I. Touitou, Twists and turns of the genetic story of mevalonate kinase-associated diseases: A review, *Genes & Diseases*, <https://doi.org/10.1016/j.gendis.2021.05.002>

## Introduction

Mevalonate kinase (MK) is an enzyme involved in the isoprenoid pathway and cholesterol synthesis that converts mevalonate into 5-phosphomevalonate.<sup>1</sup> MK is ubiquitously expressed, notably in blood leukocytes and skin keratinocytes. The gene encoding MK, *MVK*, is located on chromosome 12q24 and contains 10 coding exons and one non-coding exon.<sup>2</sup>

Several phenotypes have been associated with pathogenic variants in *MVK*. They all belong to a heterogeneous group of conditions called autoinflammatory diseases, resulting from mutations in genes of the innate immune system.<sup>3,4</sup> The first MK-associated disease described which was most obvious on a pathophysiological level was a recessive metabolic disorder named mevalonic aciduria (MA; OMIM 610377); enzyme precursors were constantly detected in patients' urine.<sup>1</sup> Recently, dominant *MVK* mutations were also identified in patients with prokeratosis (PK), a phenotype localized to the skin and totally different from the systemic form.

The various clinical subtypes and modes of inheritance that have emerged<sup>1,2</sup> and many molecular developments that have occurred over the last 28 years have led to a better knowledge of the pathophysiology of these diseases<sup>5,6</sup> and to improved patient care.<sup>7–9</sup> The main clinical advances brought about by pinpointing the culprit gene was the implementation of sequencing tests for diagnosis.<sup>10</sup> The understanding that MK-associated diseases are caused by a decrease in enzyme activity has led to the development of effective targeted therapies (e.g., the injection of interleukin 1 [IL-1] blockers for patients with the systemic subtype) and gives hope for future local therapy for those with the skin subtypes.<sup>8,9,11</sup>

The literature provides abundant information on the clinical or mutational spectrum and/or therapeutic aspects of MK-associated hereditary recurrent fever and PK. Therefore, this review does not extensively cover these themes already well illustrated elsewhere<sup>12,13</sup> but rather uses the *MVK* gene, instead of the phenotype, as the entry point for the study. Indeed, MK-associated diseases represent a fascinating example of the accumulation of patients and genetic knowledge overturning our initial belief that mutations in this single gene lead to a systemic disease only.<sup>14</sup> The aim was to provide an original historical and genetic overview of MK-associated diseases, to investigate the different genetic mechanisms underlying these disorders and their respective modes of inheritance, and to address questions that have been little explored until now, such as how a single gene can be the cause of so many different clinical pictures.

## A long story in a nutshell

The first major step taken to result in our current understanding of MK-associated diseases was the identification of the human *MVK* gene, in 1992 (Fig. 1).<sup>1</sup> The link between *MVK* mutations and serious MA disease<sup>15,16</sup> as well as its recessive transmission was established in 1997.<sup>17</sup> Two years later, *MVK* variants were also linked to a milder, seemingly different, inflammatory disease called at the time “hyper-

IgD syndrome with periodic fever” (HIDS; OMIM 260920) because high amounts of IgD were found in the serum of most patients.<sup>2,18</sup> It is now suggested that the term “HIDS” be dropped because elevated IgD level is neither specific nor constant and may well be a result rather than a cause of the disease.<sup>19</sup> Phenotypes of intermediate severity have been described as well, revealing a continuum between the milder and severe disease, which thus represent the two extremes of the same genetic disorder.<sup>20,21</sup>

Decreased enzyme activity has been demonstrated in all systemic forms, which therefore are strongly suggested to be grouped under the common umbrella “MK deficiency” (MKD), mild or severe.<sup>3</sup> Recently, and somewhat unexpectedly, whole-exome sequencing in Chinese families with disseminated superficial actinic porokeratosis (DSAP) revealed that dominant pathogenic *MVK* variants were responsible for this purely dermatological disease.<sup>22</sup> A second somatic hit was eventually discovered in the epidermis lesions of some DSAP patients.<sup>23,24</sup>

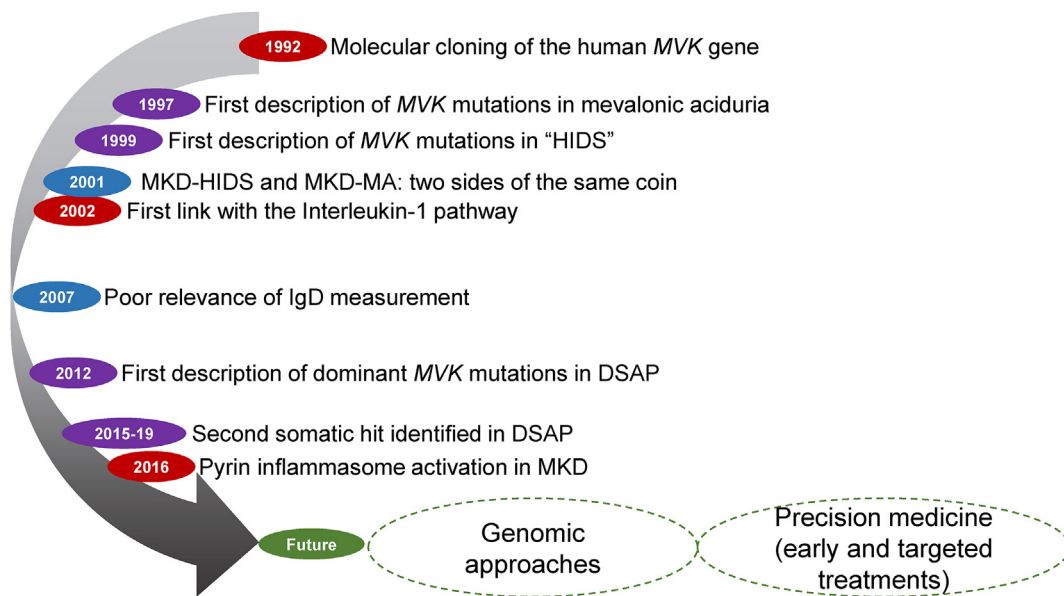
## The clinical and genetic landscape of MK-associated diseases

### Systemic MK-associated diseases (MKDs) are recessively inherited

Although MKD was first described in the Netherlands and France, it is now recognized worldwide.<sup>12,25</sup> The first symptoms occur early in life, generally in the first 2 years and include inflammatory symptoms such as fever and elevated acute-phase reactants.<sup>26</sup> Severe MKD is characterized by a massive and constitutive urinary excretion of metabolites accumulated upstream of the defective enzyme. The activity of the defective enzyme in cultured fibroblasts or leukocytes generally decreases to about 0.5%–2% of that of controls and is sometimes undetectable below 0.5%. Complete enzyme deficiency seems incompatible with life. The inflammatory symptoms are chronic and obscured by severe neurological signs (cerebellar ataxia, seizures, and mental, motor and growth retardation).<sup>15,20</sup> Eye manifestations such as cataract, conjunctivitis and retinitis pigmentosa (RP) are common.<sup>27–30</sup>

In the milder form, bouts of fever last 3–7 days and are typically associated with lymphadenopathy, diarrhea, vomiting and aphthosis. Flares are often triggered by vaccination, fatigue and stress. Mild MKD also features decreased enzyme activity and abnormal urinary excretion of mevalonic acid, but to a much lesser extent, with mevalonic aciduria detectable only during febrile attacks. When patients have sufficient residual enzyme activity, about 10% of that of controls, symptoms appear as attacks and tend to improve from adolescence onward.<sup>26,31,32</sup>

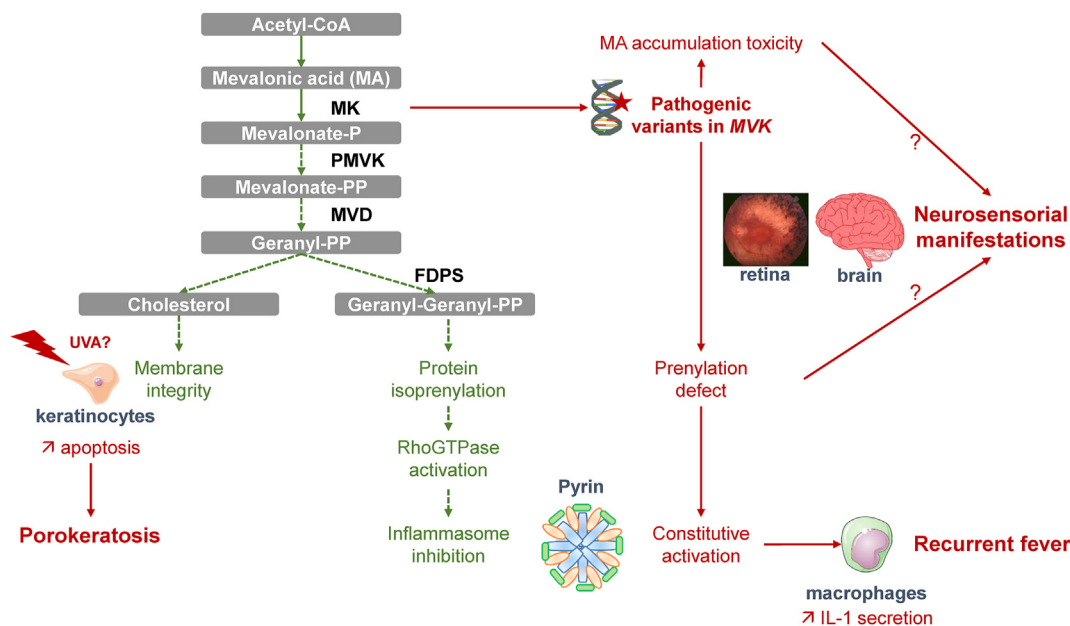
Patients with atypical MKD features have been documented. Ocular symptoms may occur in both MKD subtypes, although they are more frequent in MKD-MA. Non-syndromic RP caused by *MVK* pathogenic variants has been described but almost always with some systemic MKD features.<sup>29</sup> Other atypical presentations that may result in delayed diagnosis include prominent liver<sup>33</sup> or cardiorespiratory disease,<sup>34,35</sup> inflammatory bowel disease<sup>36</sup> or amyloid A amyloidosis.<sup>37–39</sup>



**Figure 1** Key milestones of the clinical and genetic discoveries in mevalonate kinase deficiency (MK-associated diseases). The pathophysiology, clinical, and genetic steps are depicted in red, black and purple, respectively. MA: mevalonic aciduria; HIDS: hyper-IgD syndrome; DSAP: disseminated superficial actinic porokeratosis.

The pathophysiology of MKD, although better understood now, has not yet revealed why certain mutations lead to one phenotype rather than another. In brief (Fig. 2), pathogenic variants impede the folding and stability of MK and therefore its enzymatic activity, which results in

mevalonic acid accumulation and decreased production of downstream geranyl-geranyl-pyrophosphate, itself leading to defective prenylation.<sup>13,15,40</sup> Defective prenylation in turn leads to inactivation of RhoA GTPase and subsequent defective activation of specific kinases, namely, the



**Figure 2** Schematic representation of the MK pathway and various consequences of mevalonate kinase gene (*MVK*) pathogenic variants for the different MK-associated disease subtypes. Pathogenic variants impede the folding and stability of MK and therefore its enzymatic activity, which results in mevalonic acid accumulation, decreased production of geranyl-geranyl-pyrophosphate, and ultimately activation of the pyrin inflammasome. Dashed arrows represent multiple steps in the pathway; green and red arrows and words depict normal MK (protein) pathway and pathogenic consequences of *MVK* (gene) mutations, respectively. PP: pyrophosphate; MVD: mevalonate diphosphodecarboxylase; PMVK: phosphomevalonate kinase; FDPS: farnesyl diphosphate synthase; IL-1: interleukin 1.

serine–threonine kinases protein kinase N1 (PKN1) and PKN2.<sup>5,6</sup> These latter bind and phosphorylate pyrin, blocking activation of the pyrin inflammasome.<sup>41</sup> Inflammasomes are protein platforms that aggregate upon detection of a pro-inflammatory signal to activate secretion of potent pro-inflammatory cytokines such as IL-1.<sup>42</sup> Constitutive activation of pyrin and NOD-like receptor family, pyrin domain containing 3 (NLRP3) inflammasomes has been established in two other hereditary recurrent fevers, familial Mediterranean fever (FMF) and NLRP3-associated autoinflammatory diseases, but remained unsuspected in MKD until recently. The inflammatory features of MKD are caused by excessive production of IL-1,<sup>43</sup> but the neurological or ocular symptoms seen in MKD-MA are less understood.<sup>29,44</sup> Elevated mevalonic acid level could be toxic, or isoprenoids could be differentially regulated in the brain and retinal tissues (Fig. 2).

Patients with systemic MKD have two recessively inherited mutations, in the homozygous or the compound heterozygous state. More than 140 pathogenic MKD-associated variants are known and are registered in an online database dedicated to autoinflammatory mutations (<https://infervers.umai-montpellier.fr/web>).<sup>45</sup> Most variants (115/147; 72%) are substitutions, and others are small intragenic rearrangements, including three deletions of exons 2, 3 or 5. The first reported, p.(Ala334Thr), was repeatedly associated with MA and is therefore considered a severe variant.<sup>17</sup> The most frequent variant, p.(Val377Ile), is derived from a founder effect.<sup>46</sup> Although this latter variant was mainly reported in the milder phenotype,<sup>46</sup> p.(Val377Ile) homozygosity was also reported in one asymptomatic individual<sup>47</sup> or was found combined with another mutation in some patients with severe manifestations such as amyloidosis.<sup>39</sup> Few studies of phenotype–genotype correlation are available,<sup>20,25,32,48,49</sup> and larger series, taking into account not only the two *MVK* alleles but also possible modifiers and epigenetic factors, are needed.

### Localized MK-associated diseases (PK) are dominantly inherited but recessively expressed following a second post-zygotic somatic event

In PK, the autoinflammatory manifestations are restricted to the skin. PK represents a group of dominantly inherited disorders with clinical and genetic heterogeneity,<sup>23</sup> mainly reported in people of Asian origin.<sup>50</sup> These are diseases of epidermal keratinization classified according to lesion type and location, with the disseminated DSAP form being the most common.<sup>50</sup> Keratotic lesions usually appear in adolescents and young adults and are mainly localized on sun-exposed skin areas, but new lesions may arise later in life, which explains the age-dependent penetrance and late onset of the disease.<sup>52</sup>

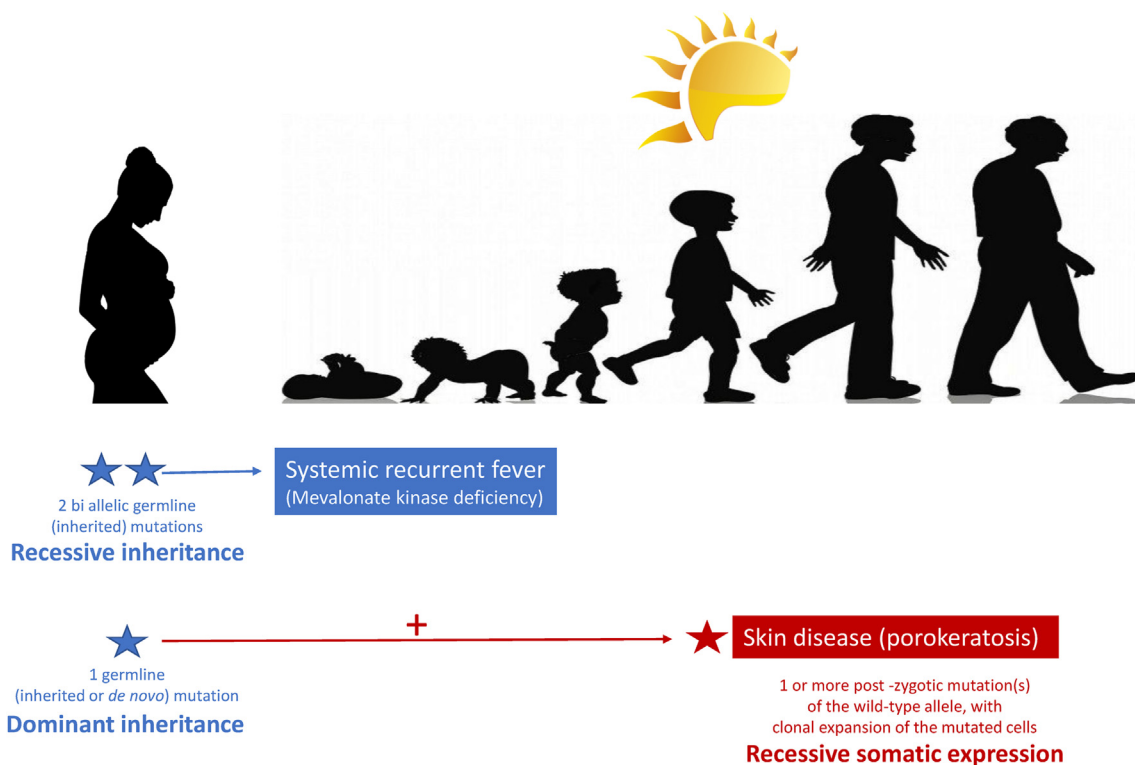
In 2012, Zhang et al.<sup>22</sup> identified for the first time *MVK* pathogenic variants in a series of both familial and sporadic cases of DSAP. Since then, several other DSAP patients with different germline *MVK* mutations have been reported.<sup>53–61</sup> In 2015, and confirmed later, heterozygous germline mutations in genes encoding three other enzymes downstream of MK in

the mevalonate pathway (i.e., mevalonate diphosphate-carboxylase [*MVD*], phosphomevalonate kinase, and farnesyl diphosphate synthase) were also found to cause DSAP and other PK subtypes (Fig. 2).<sup>11,23,24,62,63</sup> One patient had both *MVD* and *MVK* mutations.<sup>23</sup> As compared with patients with mutations in other genes of the MK pathway, those with *MVK* mutations generally showed the widest range of phenotypes in terms of both the number and size of lesions.<sup>23</sup>

The molecular mechanisms underlying *MVK*-associated PK are diverse and appear to involve sequential genetic alterations (Fig. 3). The first hit corresponds to a germline pathogenic variant occurring in *MVK*. Both *de novo* and inherited point mutations and large deletions have been identified by using massively parallel sequencing and copy-number variation analysis. In the initial publication, no somatic variant was found in 5/82 patients with available keratinocytes isolated from skin lesions.<sup>22</sup> However, 3 years later, Zhang et al. identified a somatic alteration in Chinese patients with PK. Using allelic expression imbalance and cDNA mutation analyses in pairwise lesions and neighboring normal-appearing tissues, these authors demonstrated significantly reduced expression of the wild-type allele in lesions. This decreased expression of the normal allele was attributed to gene conversion of the wild type to a mutated allele, resulting in an enhanced proportion of the initial mutation in lesional tissues.<sup>23</sup> The same group identified a second acquired *MVK* mutation in lesions of one patient with DSAP (F38) (i.e., a post-zygotic c.1003G>A transversion resulting from RNA-editing of the wild-type allele in addition to the c.1093T>A germline mutation).

More recently, Kubo et al.<sup>24</sup> detected a second hit in genes of the mevalonate pathway that occurred solely in cutaneous lesions of seven Japanese patients with DSAP. One of these patients acquired several different *MVK* pathogenic variants in the wild-type allele as demonstrated by PCR-based cloning and sequencing of genomic DNA extracted from different biopsies of the lesional epidermis. The somatic events included various transitions (mainly C>T or G>A) as well as loss of heterozygosity due to mitotic homologous recombination. The mutations differed from the germline variant found in blood cells, differed among the cutaneous lesions in a same patient, and were absent in healthy skin. The authors concluded that each skin lesion originated from a postnatal keratinocyte clone. The proportion of cells with genetic alteration among normal cells determined the mosaicism rate in the lesional tissues.

Altogether, these results support that a second, postnatal mutation of the wild type in the mevalonate pathway genes is required for PK to develop. The loss of the normal allele was the result of a gene conversion, RNA modification, or large deletion; a homologous chromosomal recombination; or an as yet unknown epigenetic mechanism (Fig. 3). The acquired genetic alteration transforms the native heterozygous genotype into a biallelic mutated genotype in the sick cells. Thus, the apparent dominant heredity with incomplete time-dependent penetrance observed in some patients in fact reflects a somatic recessive expression due to the late occurrence of a second post-zygotic loss-of-function mutation in keratinocytes. This concept mirrors the “two-hit” hypothesis of Knudson



**Figure 3** Genetic mechanisms involved in the different MK-associated disease subtypes. In the systemic form (mevalonate kinase deficiency [MKD]), two mutations are inherited from each parent (biallelic). In the localized skin porokeratosis form, the two (or more) mutations occur sequentially: the first is germline and dominantly inherited from one parent and the second is acquired later in life on the wild-type allele, presumably after UVA-mediated DNA alteration of epidermis cells in sun-exposed skin areas for some of the pathogenic variants.

for cancers and is consistent with the late onset of PK<sup>64</sup> and with the fact that certain PK patients are at greatest risk for malignant transformation.<sup>51</sup>

How are MK and PK linked? Functional studies are scarce, and levels of enzymatic activity or MA have not been measured (or at least reported) to directly prove the enzyme deficiency in PK patients. However, Liu et al.<sup>61</sup> reported that three mutant MK proteins were less stable than the wild-type protein and that one mutation p.(Gly335Asp) resulted in the misfolding of the ATP binding domain. Zhu et al.<sup>55</sup> recently demonstrated decreased kinase activity, reduced cholesterol production, and increased apoptosis in cells transfected with two *MVK* pathogenic variants identified in DSAP patients. Shortage of isoprenoids could predispose patients to idiopathic inflammation of the skin because the mevalonate pathway is crucial in regulating calcium-induced keratinocyte differentiation and proliferation.<sup>22,23</sup> Moreover, cholesterol, a product of the mevalonate pathway, is a key component of the extracellular lipid matrix that is important for the barrier function of the skin.<sup>65</sup> Overexpression of wild-type *MVK* has been associated with increased differentiation and decreased type A ultraviolet radiation (UVA)-induced apoptosis of keratinocytes.<sup>22</sup> The authors of this study hypothesized that environmental (i.e., UVA) factors precipitate cell death in patients with impaired MK function, which may account for the clinical distribution of the skin lesions in DSAP patients.

## Unanswered questions and perspectives

This review quickly summarizes nearly three decades of intensive studies on MK-associated diseases, focusing on the most recent breakthroughs that have emerged from modern genetics. The understanding, at least in part, of the genetic mechanisms involved in this group of disorders has had many twists and turns, which will have a major impact on both our fundamental knowledge and genetic counseling for patients. Indeed, for the first identified phenotype (i.e., systemic MKD), the recessive mode of transmission, a feature common to most enzyme disorders, has been clear and never discussed, but the latest data on the purely cutaneous PK form have contradicted this paradigm and have revealed an unexpected genetic mechanism, which involves, at least in some patients, an initial germline mutation followed by a second somatic event. This second post-zygotic hit explains why, despite the dominant heredity of PK, its clinical expression is somatically recessive in nature. Nevertheless, several issues remain that have been little explored until now.

One issue concerns a possible phenotype–genotype correlation between the *MVK* variants carried by patients and the MK-associated subtypes they ultimately display. The fact that a same mutation (e.g., p.Gly202Arg) can be found in both systemic and skin forms is puzzling.<sup>45</sup> Is there a link between the gene location or type of the mutation(s) and the clinical expression of the disease? Some general

trends have already been suggested, with p.(Val377Ile) and p.(Ala334Thr) associated with mild and severe or complicated systemic phenotypes, respectively, but exceptions exist.<sup>20,25,32</sup> One clue has recently been provided by a multi-omic approach revealing the role of signal transducer and activator of transcription 1 (STAT1) as a modifier gene.<sup>66</sup> STAT1 is central in the regulatory pathway of inflammation mediated by IFN- $\gamma$ . This study revealed a variant, p.(Arg241Gln) that was differentially expressed in two sisters homozygous for the p.(Val377Ile) genotype who had radically opposite (asymptomatic vs. strongly symptomatic) phenotypes. The authors suggested that the presence of both the homozygous *MVK* p.Val377Ile mutation and the heterozygous STAT1 p.R241Q mutation is required to elicit clinical symptoms.

With respect to PK, UVA, known to be an important trigger in the development of DSAP, seems to be an environmental factor that interacts significantly with genetic factors to influence the clinical expression of skin disease. Still, differential exposure to the sun cannot explain why patients with the systemic form do not have PK skin lesions. An extensive review of all published patients could help resolve the issue of *MVK*-related phenotype–genotype associations.

“A second issue concerns the fact that, although the two loss-of-function variants are present in all cells, including keratinocytes, because they are inherited in systemic MKD, no porokeratotic lesions have ever been described in MKD patients. Regardless, such patients can display other types of rashes such as maculo-papules or urticaria in 39% and 15% of cases, respectively.”<sup>25</sup> Conversely, the fact that PK patients or simple carriers, parents of MKD patients for example, do not have a fever is likely explained by the presence of half a dose of functional enzyme in heterozygous individuals, which is therefore compatible with normal inflammasome regulation.

A third issue is whether the two sequential molecular alterations (Knudson concept) represent a general pathophysiological mechanism of *MVK*-associated PK. Indeed, no second hit was detected in several patients with PK.<sup>22–24</sup> Both technical limitations (low-rate mosaicism undetected) and yet-unknown epigenetic factors have been suggested.<sup>22–24,67</sup>

Finally, does the two-hit hypothesis account for other cases of recessive autoinflammatory diseases such as FMF, with heterozygous patients sometimes being symptomatic?<sup>68</sup> This hypothesis has not been formally investigated, but two cases of acquired FMF have been reported.<sup>69,70</sup>

In conclusion, the example of the genetic story of *MVK*-associated diseases retraces how amazing and various are the mechanisms underlying phenotypic heterogeneity. Large-scale integrated genomic technologies currently under development<sup>66</sup> will undoubtedly provide more surprises in the near future and bring new diagnostic and therapeutic solutions to patients in the context of precision medicine.

## Acknowledgements

The author is indebted to Dr Guilaine Boursier, Dr Laurence Cuisset, and Dr Guillaume Sarrabay for their valuable

discussions and/or comments on the manuscript. Laura Smales (BioMedEditing, Toronto, Canada) is thanked for the English language review.

## References

- Schafer BL, Bishop RW, Kratunis VJ, et al. Molecular cloning of human mevalonate kinase and identification of a missense mutation in the genetic disease mevalonic aciduria. *J Biol Chem.* 1992;267(19):13229–13238.
- Drenth JP, Cuisset L, Grateau G, et al. Mutations in the gene encoding mevalonate kinase cause hyper-IgD and periodic fever syndrome. International Hyper-IgD Study Group. *Nat Genet.* 1999;22(2):178–181.
- Ben-Chetrit E, Gattorno M, Gul A, et al. Consensus proposal for taxonomy and definition of the autoinflammatory diseases (AIDs): a Delphi study. *Ann Rheum Dis.* 2018;77(11):1558–1565.
- Gattorno M, Federici S, Pelagatti MA, et al. Diagnosis and management of autoinflammatory diseases in childhood. *J Clin Immunol.* 2008;28(Suppl 1):S73–S83.
- Park YH, Wood G, Kastner DL, Chae JJ. Pyrin inflammasome activation and RhoA signaling in the autoinflammatory diseases FMF and HIDS. *Nat Immunol.* 2016;17(8):914–921.
- Akula MK, Shi M, Jiang Z, et al. Control of the innate immune response by the mevalonate pathway. *Nat Immunol.* 2016;17(8):922–929.
- Ter Haar N, Lachmann H, Özen S, et al. Treatment of autoinflammatory diseases: results from the Eurofever Registry and a literature review. *Ann Rheum Dis.* 2013;72(5):678–685.
- Galeotti C, Meinzer U, Quartier P, et al. Efficacy of interleukin-1-targeting drugs in mevalonate kinase deficiency. *Rheumatology (Oxford).* 2012;51(10):1855–1859.
- Kostjukovits S, Kalliokoski L, Antila K, Korppi M. Treatment of hyperimmunoglobulinemia D syndrome with biologics in children: review of the literature and Finnish experience. *Eur J Pediatr.* 2015;174(6):707–714.
- Simon A, van der Meer JW, Vesely R, et al. Approach to genetic analysis in the diagnosis of hereditary autoinflammatory syndromes. *Rheumatology (Oxford).* 2006;45(3):269–273.
- Atzmony L, Khan HM, Lim YH, et al. Second-hit, postzygotic *PMVK* and *MVD* mutations in linear porokeratosis. *JAMA Dermatol.* 2019;155(5):548–555.
- Zhang S. Natural history of mevalonate kinase deficiency: a literature review. *Pediatr Rheumatol Online J.* 2016;14(1), e30.
- Favier LA, Schulert GS. Mevalonate kinase deficiency: current perspectives. *Appl Clin Genet.* 2016;9:101–110.
- Aksentijevich I, Kastner DL. Genetics of monogenic autoinflammatory diseases: past successes, future challenges. *Nat Rev Rheumatol.* 2011;7(8):469–478.
- van der Burgh R, Ter Haar NM, Boes ML, Frenkel J. Mevalonate kinase deficiency, a metabolic autoinflammatory disease. *Clin Immunol.* 2013;147(3):197–206.
- Mancini J, Philip N, Chabrol B, Divry P, Rolland MO, Pinsard N. Mevalonic aciduria in 3 siblings: a new recognizable metabolic encephalopathy. *Pediatr Neurol.* 1993;9(3):243–246.
- Hinson DD, Chambliss KL, Hoffmann GF, Krisans S, Keller RK, Gibson KM. Identification of an active site alanine in mevalonate kinase through characterization of a novel mutation in mevalonate kinase deficiency. *J Biol Chem.* 1997;272(42):26756–26760.
- Houten SM, Kuis W, Duran M, et al. Mutations in *MVK*, encoding mevalonate kinase, cause hyperimmunoglobulinemia D and periodic fever syndrome. *Nat Genet.* 1999;22(2):175–177.
- Ammouri W, Cuisset L, Rouaghe S, et al. Diagnostic value of serum immunoglobulinemia D level in patients with a clinical suspicion of hyper IgD syndrome. *Rheumatology (Oxford).* 2007;46(10):1597–1600.

20. Simon A, Kremer HPH, Wevers RA, et al. Mevalonate kinase deficiency: evidence for a phenotypic continuum. *Neurology*. 2004;62(6):994–997.
21. Tsimaratos M, Kone-Paut I, Divry P, Philip N, Chabrol B. Mevalonic aciduria and hyper-IgD syndrome: two sides of the same coin? *J Inherit Metab Dis*. 2001;24(3):413–414.
22. Zhang SQ, Jiang T, Li M, et al. Exome sequencing identifies MVK mutations in disseminated superficial actinic porokeratosis. *Nat Genet*. 2012;44(10):1156–1160.
23. Zhang Z, Li C, Wu F, et al. Genomic variations of the mevalonate pathway in porokeratosis. *Elife*. 2015;4, e06322.
24. Kubo A, Sasaki T, Suzuki H, et al. Clonal expansion of second-hit cells with somatic recombinations or C>T transitions form porokeratosis in MVD or MVK mutant heterozygotes. *J Invest Dermatol*. 2019;139(12):2458–2466.
25. Ter Haar NM, Jeyaratnam J, Lachmann HJ, et al. The phenotype and genotype of mevalonate kinase deficiency: a series of 114 cases from the Eurofever registry. *Arthritis Rheum*. 2016;68(11):2795–2805.
26. Bader-Meunier B, Florkin B, Sibilia J, et al. Mevalonate kinase deficiency: a survey of 50 patients. *Pediatrics*. 2011;128(1):e152–e159.
27. Balgobind B, Wittebol-Post D, Frenkel J. Retinitis pigmentosa in mevalonate kinase deficiency. *J Inherit Metab Dis*. 2005;28(6):1143–1145.
28. Kellner U, Stöhr H, Weintz S, Farmand G, Weber BHF. Mevalonate kinase deficiency associated with ataxia and retinitis pigmentosa in two brothers with MVK gene mutations. *Ophthalmic Genet*. 2017;38(4):340–344.
29. Siemiakowska AM, van den Born LI, van Hagen PM, et al. Mutations in the mevalonate kinase (MVK) gene cause non-syndromic retinitis pigmentosa. *Ophthalmology*. 2013;120(12):2697–2705.
30. Wilker SC, Dagnelie G, Goldberg MF. Retinitis pigmentosa and punctate cataracts in mevalonic aciduria. *Retin Cases Brief Rep*. 2010;4(1):34–36.
31. Galeotti C, Georgin-Lavialle S, Sarrabay G, Touitou I, Koné-Paut I. [Mevalonate kinase deficiency in 2016]. *Rev Med Interne*. 2018;39(4):265–270.
32. Cuisset L, Drenth JP, Simon A, et al. Molecular analysis of MVK mutations and enzymatic activity in hyper-IgD and periodic fever syndrome. *Eur J Hum Genet*. 2001;9(4):260–266.
33. Hinson DD, Rogers ZR, Hoffmann GF, et al. Hematological abnormalities and cholestatic liver disease in two patients with mevalonate kinase deficiency. *Am J Med Genet*. 1998;78(5):408–412.
34. Prietsch V, Mayatepek E, Krastel H, et al. Mevalonate kinase deficiency: enlarging the clinical and biochemical spectrum. *Pediatrics*. 2003;111(2):258–261.
35. Steiner LA, Ehrenkranz RA, Peterec SM, Steiner RD, Reyes-Múgica M, Gallagher PG. Perinatal onset mevalonate kinase deficiency. *Pediatr Dev Pathol*. 2011;14(4):301–306.
36. Bianco AM, Girardelli M, Vozzi D, Crovella S, Kleiner G, Marcuzzi A. Mevalonate kinase deficiency and IBD: shared genetic background. *Gut*. 2014;63(8):1367–1368.
37. Kallianidis AF, Ray A, Goudkade D, de Fijter JW. Amyloid A amyloidosis secondary to hyper IgD syndrome and response to IL-1 blockade therapy. *Neth J Med*. 2016;74(1):43–46.
38. Obici L, Manno C, Muda AO, et al. First report of systemic reactive (AA) amyloidosis in a patient with the hyperimmunoglobulinemia D with periodic fever syndrome. *Arthritis Rheum*. 2004;50(9):2966–2969.
39. Rodrigues F, Pihlit J-B, Giurgea I, et al. AA amyloidosis revealing mevalonate kinase deficiency: a report of 20 cases including two new French cases and a comprehensive review of literature. *Semin Arthritis Rheum*. 2020;50(6):1370–1373.
40. Houten SM, Frenkel J, Rijkers GT, Wanders RJA, Kuis W, Waterham HR. Temperature dependence of mutant mevalonate kinase activity as a pathogenic factor in hyper-IgD and periodic fever syndrome. *Hum Mol Genet*. 2002;11(25):3115–3124.
41. Schnappauf O, Chae JJ, Kastner DL, Aksentijevich I. The pyrin inflammasome in health and disease. *Front Immunol*. 2019;10, e1745.
42. Broderick L, De Nardo D, Franklin BS, Hoffman HM, Latz E. The inflammasomes and autoinflammatory syndromes. *Annu Rev Pathol*. 2015;10:395–424.
43. Frenkel J, Rijkers GT, Mandey SHL, et al. Lack of isoprenoid products raises ex vivo interleukin-1beta secretion in hyperimmunoglobulinemia D and periodic fever syndrome. *Arthritis Rheum*. 2002;46(10):2794–2803.
44. Tricarico PM, Marcuzzi A, Piscianz E, Monasta L, Crovella S, Kleiner G. Mevalonate kinase deficiency and neuroinflammation: balance between apoptosis and pyroptosis. *Int J Mol Sci*. 2013;14(12):23274–23288.
45. Touitou I, Lesage S, McDermott M, et al. Infervers: an evolving mutation database for auto-inflammatory syndromes. *Hum Mutat*. 2004;24(3):194–198.
46. Simon A, Mariman EC, van der Meer JW, Drenth JP. A founder effect in the hyperimmunoglobulinemia D and periodic fever syndrome. *Am J Med*. 2003;114(2):148–152.
47. Messer L, Alsaleh G, Georget P, et al. Homozygosity for the V377I mutation in mevalonate kinase causes distinct clinical phenotypes in two sibs with hyperimmunoglobulinemia D and periodic fever syndrome (HIDS). *RMD Open*. 2016;2(1), e000196.
48. Mandey SHL, Schneiders MS, Koster J, Waterham HR. Mutational spectrum and genotype-phenotype correlations in mevalonate kinase deficiency. *Hum Mutat*. 2006;27(8):796–802.
49. Jeyaratnam J, Ter Haar NM, de Sain-van der Velden MGM, Waterham HR, van Gijn ME, Frenkel J. Diagnostic value of urinary mevalonic acid excretion in patients with a clinical suspicion of mevalonate kinase deficiency (MKD). *JIMD Rep*. 2016;27:33–38.
50. Sertznig P, von Felbert V, Megahed M. Porokeratosis: present concepts. *J Eur Acad Dermatol Venereol*. 2012;26(4):404–412.
51. Sasson M, Krain AD. Porokeratosis and cutaneous malignancy. A review. *Dermatol Surg*. 1996;22(4):339–342.
52. Chernosky ME, Freeman RG. Disseminated superficial actinic porokeratosis (DSAP). *Arch Dermatol*. 1967;96(6):611–624.
53. Zhou MS, Xie HF, Chen ML, et al. A novel mutation for disseminated superficial actinic porokeratosis in the MVK gene. *Br J Dermatol*. 2014;171(2):427–429.
54. Zhou Y, Liu J, Fu X, et al. Identification of three novel frameshift mutations of the MVK gene in four Chinese families with disseminated superficial actinic porokeratosis. *Br J Dermatol*. 2013;169(1):193–195.
55. Zhu T, Tian D, Zhang L, et al. Novel mutations in mevalonate kinase cause disseminated superficial actinic porokeratosis. *Br J Dermatol*. 2019;181(2):304–313.
56. Li CX, Sun SL, Liang JY, et al. A novel non-frameshift deletion in MVK gene responsible for disseminated superficial actinic porokeratosis in one Chinese family. *J Eur Acad Dermatol Venereol*. 2017;31(11):e510–e512.
57. Lu WS, Zheng XD, Yao XH, et al. A novel MVK missense mutation in one Chinese family with disseminated superficial actinic porokeratosis. *Mol Biol Rep*. 2014;41(11):7229–7233.
58. Lu WS, Zheng XD, Yao XH, Zhang LF, Hu B, Lu YJ. Detection of a novel missense mutation in the mevalonate kinase gene in one Chinese family with DSAP. *Int J Clin Exp Pathol*. 2014;7(2):728–732.
59. Dai J, Chen M, Fu X, et al. Mutation analysis of the MVK gene in Chinese patients with disseminated superficial actinic porokeratosis. *J Dermatol Sci*. 2013;72(3):320–322.
60. Glinos GD, Pastar I, Giubellino A, Tomic-Canic M, Miteva M, Stone RC. Novel mevalonate kinase missense mutation in a patient with disseminated superficial actinic porokeratosis. *JAAD Case Rep*. 2018;4(4):340–343.

61. Liu Y, Wang J, Qin Y, et al. Identification of three mutations in the MVK gene in six patients associated with disseminated superficial actinic porokeratosis. *Clin Chim Acta*. 2016;454:124–129.
62. Wang J, Liu Y, Liu F, et al. Loss-of-function mutation in PMVK causes autosomal dominant disseminated superficial porokeratosis. *Sci Rep*. 2016;6, e24226.
63. Shiiya C, Aoki S, Nakabayashi K, Hata K, Amagai M, Kubo A. Linear and disseminated porokeratosis in one family showing identical and independent second hits in MVD among skin lesions, respectively: a proof of concept study. *Br J Dermatol*. 2021 Jun; 184(6):1209–1212. <https://doi.org/10.1111/bjd.19824>. Epub 2021 May 9.
64. Knudson AG. Two genetic hits (more or less) to cancer. *Nat Rev Cancer*. 2001;1(2):157–162.
65. Bouwstra JA, Ponc M. The skin barrier in healthy and diseased state. *Biochim Biophys Acta*. 2006;1758(12):2080–2095.
66. Carapito R, Carapito C, Morlon A, et al. Multi-OMICS analyses unveil STAT1 as a potential modifier gene in mevalonate kinase deficiency. *Ann Rheum Dis*. 2018;77(11): 1675–1687.
67. Atzmony L, Choate KA. Second-hit somatic mutations in mevalonate pathway genes underlie porokeratosis. *J Invest Dermatol*. 2019;139(12):2409–2411.
68. Hentgen V, Grateau G, Stankovic-Stojanovic K, Amselem S, J ru I. Familial Mediterranean fever in heterozygotes: are we able to accurately diagnose the disease in very young children? *Arthritis Rheum*. 2013;65(6):1654–1662.
69. Toutilou I, Dumont B, Pourte in M, Perelman S, Sirvent A, Soler C. Transmission of familial Mediterranean fever mutations following bone marrow transplantation. *Clin Genet*. 2007;72(2):162–163.
70. Shinar Y, Tohami T, Livneh A, et al. Acquired familial Mediterranean fever associated with a somatic MEFV mutation in a patient with JAK2 associated post-polycythemia myelofibrosis. *Orphanet J Rare Dis*. 2015;10, e86.