

Conferences and Reviews

Total Hip Arthroplasty

Discussants

JORGE S. SIOPACK and HARRY E. JERGESEN, MD, *San Francisco, California*

Total hip arthroplasty, or surgical replacement of the hip joint with an artificial prosthesis, is a reconstructive procedure that has improved the management of those diseases of the hip joint that have responded poorly to conventional medical therapy. In this review we briefly summarize the evolution of total hip arthroplasty, the design and development of prosthetic hip components, and the current clinical indications for this procedure. The possible complications of total hip arthroplasty, its clinical performance over time, and future directions in hip replacement surgery are also discussed.

(Siopack JS, Jergesen HE: Total hip arthroplasty. *West J Med* 1995; 162:243-249)

Total hip arthroplasty is an orthopedic procedure that involves the surgical excision of the head and proximal neck of the femur and removal of the acetabular cartilage and subchondral bone. An artificial canal is created in the proximal medullary region of the femur, and a metal femoral prosthesis, composed of a stem and small-diameter head, is inserted into the femoral medullary canal. An acetabular component composed of a high-molecular-weight polyethylene articulating surface is inserted proximally into the enlarged acetabular space (Figures 1 and 2). To yield successful results, these total hip arthroplasty components must be fixed firmly to the bone, either with polymethylmethacrylate cement or, in more recent uncemented designs, by bony ingrowth into a porous coating on the implant, resulting in "biologic" fixation.

Total hip arthroplasty is currently one of the most widely performed procedures in orthopedic practice in the United States.* Since its introduction in this country in 1969, it has proved remarkably successful in eliminating pain and restoring function in hips severely involved with diseases such as osteoarthritis. It is estimated that about 170,000 total hip arthroplasties are performed each year in this country and that about 300,000 are done worldwide.¹ The first total hip replacement is thought to have been done in London by Phillip Wiles in 1938.² The procedure was further developed in the 1950s by pioneers such as McKee and Farrar.³ This early work laid the groundwork for the innovative studies of Sir John Charnley who, in the late 1960s, approached the problem of artificial hip joint design by using the biomechanical principles of human hip joint function.^{4,5} Repeated trials and experimentation with various

materials and prosthetic designs culminated in the creation of the Charnley low-friction arthroplasty, a procedure still considered by many to be the current standard of total hip replacement. The noteworthy innovations of Charnley's arthroplasty included the combination of a small-diameter—22-mm—femoral head with a high-density polyethylene acetabular component to reduce friction and fixation of these prosthetic components to bone with polymethylmethacrylate cement.

Since Charnley's original prosthesis was introduced, several variants of the artificial hip joint have been developed; none have proved to be superior in the clinical setting, however. For example, despite the theoretical advantage of a larger-diameter femoral head, which some think permits more motion, generates less stress, and dislocates less readily, the longevity of the Charnley prosthesis appears to be enhanced by the smaller-diameter head, which reduces friction and the amount of wear debris produced and results in a lower incidence of acetabular loosening.⁶

Revision total hip arthroplasty is carried out in patients where there is failure of a previously implanted prosthesis. In such cases, all cement and prosthetic components are removed carefully to avoid penetrating or fracturing the bone. New components are then implanted and fixed with either a cemented or uncemented technique. Surgical indications for revision arthroplasty include loosening of the prosthetic components, wear-debris osteolysis, acute or chronic deep infection, mechanical failure of the prosthetic components, and chronic recurrent dislocation. Surgical revision is technically more difficult than the primary total hip arthroplasty procedure, both because there is less bone stock to work with and because the removal of adherent cement or prosthetic components may result in fracture or perfora-

*See also editorial by T. A. DeCoster, MD, and D. Rivero, MD, "Total Hip Arthroplasty—A Cure?" on page 274 of this issue.

tion of the bone. With each successive total hip revision, the risk of infection and symptomatic loosening may increase substantially.² The number of these procedures is increasing steadily because many of the primary total hip arthroplasties done in the 1970s are beginning to fail. Improved operative techniques and specialized revision prosthetic components are being developed to decrease the morbidity associated with revision operations.

Indications and Goals

The most common condition for which total hip arthroplasty is done is severe osteoarthritis of the hip, accounting for 70% of cases. The primary indication for this procedure is severe pain and the limitation in activities of daily living that it causes. To warrant doing total hip replacement, pain must be refractory to conservative measures such as oral nonsteroidal anti-inflammatory medication, weight reduction, activity restriction, and the use of supports such as a cane. It is generally preferred that total hip arthroplasty be done in patients older than 60 years because at this age, the physical demands on the prosthesis tend to be fewer and the longevity of the operation approaches the life expectancy of the patient. Other conditions for which the procedure may be indicated and which predispose to the development of secondary osteoarthritis include developmental dysplasia of the hip, Paget's disease, trauma, and osteonecrosis of the femoral head. Patients with rheumatoid arthritis, other collagen diseases such as systemic lupus erythematosus, and ankylosing spondylitis may benefit as well. The large number of operations performed each year reflects the fact that more than 90% of appropriately selected patients achieve complete pain relief and notable improvement in function.⁷

Despite this level of success, total hip arthroplasty occasionally may be associated with complications.

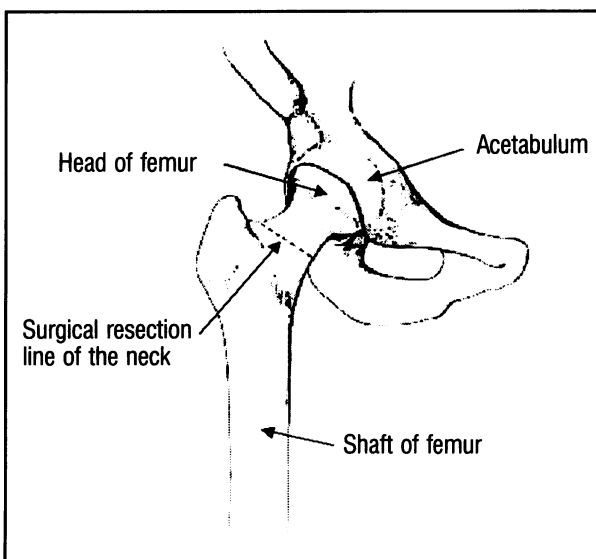


Figure 1.—Anatomy of a right hip shows the site of surgical removal of the femoral neck in total hip arthroplasty.

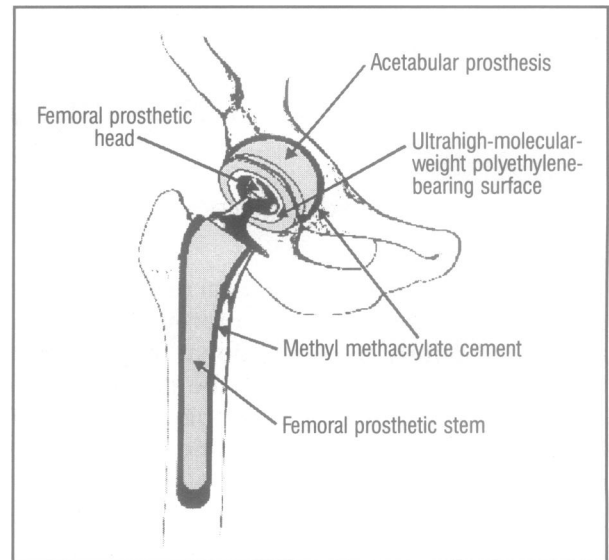


Figure 2.—A total hip arthroplasty with the use of methyl methacrylate cement to fix the prosthetic femoral and acetabular components to the bony structures is shown.

Patients may harbor unrealistic expectations of the degree of activity the prosthesis will safely allow. In pre-operative consultation, physicians must stress that the primary goal of the operation is the relief of pain when other options have failed. Motion may be improved, but not in every patient. Most important, heavy repetitive impact loading with activities such as running or jumping may predispose the prosthesis to wear and loosening, thus shortening its life span.

Biomechanics and Materials

During normal ambulation, the human hip undergoes cyclic loading that can place forces three to five times those of body weight on prosthetic components. During more strenuous activity, such as running or climbing, the joint is exposed to much greater forces—as much as 12 times those of body weight. Biomechanical analysis of these forces has prompted design engineers to position the prosthetic components to maximize support of the implant throughout the walking cycle. In general, implants are designed to closely approximate the function of the natural hip joint. Many considerations in materials and manufacturing technology dictate design requirements in prosthetic components that may limit the achievement of this goal, however.

Most hip prostheses consist of an ultrahigh-molecular-weight polyethylene acetabular cup and a metal-alloy femoral component. In cemented techniques, polymethyl methacrylate cement is used to fix the femoral component in bone, whereas in uncemented arthroplasties, the prosthesis interfaces with bone directly. In current practice, acetabular components are rarely cemented, even if a surgeon chooses to fix the femoral component with cement. Uncemented acetabular components are fixed to the pelvis by bone ingrowth into an outer porous metal shell that surrounds the polyethylene cup.

Acetabular Component

In the past decade, ultrahigh-molecular-weight polyethylene has been introduced to replace high-density polyethylene because of its superior resistance to wear.⁸ Before Charnley's work, metal acetabular cups were used to articulate directly with metal femoral heads (as in the McKee-Farrar and Ring prostheses). The drawback to this design was the high friction between the two metal surfaces, resulting in wear and loosening of the prosthesis due to high frictional torque. Although Charnley's use of high-density polyethylene reduced these problems considerably, the search for even more wear-resistant, biocompatible materials continues.

Femoral Component

The primary goal in the manufacture of femoral components is to ensure long-term biocompatibility and high resistance to the repeated cyclical loads encountered during normal hip function. The most common metals that have been used in the femoral component are alloys of stainless steel, titanium, and cobalt-chrome. Although cobalt-chrome designs have proved successful for many years, titanium implants are also commonly used. The proponents of titanium cite the fact that it is the most biologically inert of these metals and that its relatively low elastic modulus most closely resembles that of femoral cortical bone.⁹

An innovation in the design of femoral components has been the introduction of separate modular cobalt-chrome heads that are fixed to the neck portion of the femoral stem by interference fit. A choice of different neck lengths in the head component permits accurate adjustment of soft-tissue tension and leg length. Ceramic has been introduced recently as an alternative material for the femoral head component. In *in vitro* testing, certain ceramics demonstrate a substantially lower coefficient of friction against polyethylene compared with cobalt-chrome alloys. In clinical practice, modular ceramic head components fitted to metal femoral stems have been used by some surgeons in place of cobalt-chrome head components. The comparative long-term efficacy of ceramic heads is not yet known, and some concern has been expressed over the possibility of brittle failure of ceramic components.

Cement

Polymethylmethacrylate cement is a self-curing acrylic polymer without any adhesive properties. It is used as a grouting agent to securely fix the prosthetic components to bone. The polymer achieves fixation through processes known as "microlocking" and "macrolocking." During microlocking, the cement squeezes into the interstices of the cancellous bone to ensure fixation throughout the whole bone-cement interface. In the process of macrolocking, the cement enhances fixation by filling large irregular spaces within the bone surrounding the implant.

The technique of cement implantation has been of great importance in assuring good long-term fixation. Care is taken to ensure proper penetration of cement into the bone and adequate filling of all empty spaces adjacent to the surface of the prosthesis. This is achieved by introducing the cement under pressure. Either intraoperative centrifugation or preparing the cement mixture in a vacuum serves to remove air bubbles during the early stages of polymerization. Bubbles that remain in the cement once it has cured may act as weak spots, or stress risers, that facilitate the propagation of cracks in the cement mantle. In some circumstances, the cement is impregnated with antibiotics to reduce the incidence of postoperative infection. Not all surgeons favor this option because some studies have shown that antibiotic additives may weaken the polymer. Others have expressed the concern that routinely using antibiotics in this manner may contribute to increased drug resistance of certain bacteria.¹⁰

Cemented Total Hip Arthroplasty

Conventional cemented total hip arthroplasty dramatically improves a patient's function and quality of life. The original Charnley hip arthroplasty provided a good to excellent clinical result in 80% to 85% of patients observed for at least 15 to 20 years. The clinical failures, such as symptomatic aseptic loosening leading to revision arthroplasty, occur at a rate of about 1% per year of follow-up. Radiographic loosening occurs at twice that rate, affecting a third of hip recipients by 15 years.¹¹ With contemporary prostheses and modern cementing techniques, the rate of femoral loosening appears to be substantially reduced.¹² Regardless of the cementing technique, mechanical loosening occurs more commonly in young, heavy, active men and with certain prosthetic designs.

In patients with rheumatoid arthritis, the clinical failure rate of total hip arthroplasty, which may be as high as 25% at 12 years, is generally higher than in those with osteoarthritis. In patients with rheumatoid arthritis, the incidence of delayed wound healing and sepsis may be increased as well.¹³ These patients tend to be younger and to have osteoporosis. In patients with Paget's disease, total hip arthroplasty is usually associated with a satisfactory result, although excessive bleeding from hypervascular bone may complicate the surgical procedure. Total hip arthroplasty may be the only viable treatment alternative in patients with advanced avascular necrosis; some investigators have reported inferior long-term results in these patients, presumably because of their younger age and increased physical demands. In patients with ankylosing spondylitis, total hip arthroplasty is associated with a higher incidence of heterotopic ossification; preexisting soft-tissue contractures may limit hip motion postoperatively.

An important cause of clinical failure leading to surgical revision in cemented total hip arthroplasty is biologic loosening due to aggressive osteolysis.

Phagocytosis of metal, polyethylene, and acrylic wear-debris particles by macrophages leads to localized resorption of bone, with consequent loosening of the prosthetic components. The process is characterized histologically by the presence of macrophages, multinucleated giant cells, and by intracellular particles of cement and polyethylene. On radiographic examination, bone resorption is seen as progressively enlarging lytic foci around the prosthetic components. Mechanical loosening of the device ultimately occurs, occasionally with further fragmentation of the cement surrounding the components.¹⁴ Similar lytic bone resorption may take place in cementless arthroplasties due to debris produced by wear of the femoral head against the polyethylene acetabular component.

Noncemented Total Hip Arthroplasty

Noncemented total hip arthroplasty was developed in response to evidence that cement debris plays an important role in promoting bone lysis and loosening. Prosthetic devices have been developed that achieve fixation without cement either by "press-fit" or by biologic ingrowth. With the press-fit technique, stabilization is achieved by interference fit of the implant into the femur. With biologic ingrowth, fixation occurs by bone ingrowth into a porous surface. Noncemented devices are most frequently used in young patients with high physical demands where a revision surgical procedure in the future will be more likely. Preliminary data suggest that noncemented total hip arthroplasties have a relatively low revision rate and excellent prosthetic durability for as long as 15 years. Compared with cemented hip arthroplasties, however, patients have a higher incidence of low-grade, temporary thigh pain. Although short-term results appear to be less satisfactory compared with cemented hip arthroplasty, after 5 to 20 years, the results in the two procedures are similar.¹⁵ As mentioned, despite the absence of cement debris in noncemented total hip arthroplasties, femoral osteolysis may still occur in as many as 5% of patients as a result of the formation of polyethylene wear debris. Noncemented total hip arthroplasty, whether of the press-fit or biologic ingrowth variety, requires a more exacting surgical insertion technique than does cemented arthroplasty because maximum contact between prosthesis and bone must be achieved. Even in the best of circumstances, complete contact may be difficult to achieve. Some manufacturers have dealt with the problem by creating a variety of implants to better match the various internal shapes and sizes of different femurs. Unfortunately, this approach creates a logistical and cost problem because of the large inventory of implants that must be kept available.

The biologic ingrowth designs are now used extensively. Studies of animals have shown excellent ingrowth of bone into the porous surfaces of both cobalt-chrome and titanium implants. One method used to produce a porous ingrowth surface in cobalt-chrome prostheses is to fuse metal beads 250 to 400 μm in

diameter onto the surface of implants. Small pores are present between the beads. Studies have shown that bone ingrowth into porous surfaces begins within the first 6 to 12 weeks after implantation.¹⁶ Implant-retrieval studies in humans have confirmed that ingrowth of bone and fibrous tissue does occur. Even in prostheses shown radiographically to be well fixed, however, a surprisingly low percentage of available surface area is involved with the ingrowth of bone. Despite concerns about how much ingrowth actually takes place, clinical studies have shown that some noncemented porous-ingrowth designs are as successful as cemented implants.

Some investigators have cautioned that metal ion release from the porous coating of the prosthesis may cause an osteolytic reaction in adjacent bone.¹⁷ Others have suggested that bone fixation can be enhanced by coating the implant with hydroxyapatite or tricalcium phosphate, both of which closely resemble natural bone mineral. These agents may further serve as a barrier to elemental ion transfer from the prosthetic device into the surrounding tissues.¹⁸

Because early reports noted an increased rate of acetabular loosening relative to femoral loosening in cemented arthroplasties, the concept of the "hybrid" total hip arthroplasty has been adopted by many surgeons. The hybrid total hip arthroplasty consists of a cemented femoral stem and a noncemented acetabular cup. Cementing the stem using contemporary techniques allows earlier unrestricted weight bearing and yields a lower incidence of low-grade thigh pain. Leaving the acetabular component uncemented avoids the consequences of cement fragmentation and loosening. In many centers, hybrid total hip arthroplasty is now the preferred technique for primary hip arthroplasty in patients older than 60. Results in patients observed for two to four years show that the hybrid arthroplasty performs as well as cemented total hip arthroplasty in the short term.¹⁹

Operative Aspects

As with any major surgical procedure, cardiovascular, renal, and pulmonary function must be fully assessed preoperatively in all patients undergoing total hip arthroplasty. The procedure may be done under regional as well as general anesthesia, allowing patients with medical contraindications to general anesthesia to undergo it.² Total hip arthroplasty is contraindicated if active infection is present either locally in the pelvic region or elsewhere in the body. The procedure may be performed through various surgical approaches, and in all techniques, scrupulous precautions are taken to prevent bacterial contamination of the open wound. Prophylactic intravenous antibiotics are used routinely. To reduce the chance of infection further, some surgeons advocate added precautions such as operating in laminar-flow enclosures with filtered air or wearing special hoods designed to divert exhaled air from the operative field.

Early Complications

Fracture

The incidence of fracture is about 1%²⁰ and has been reduced with the use of modern prostheses and contemporary surgical techniques. A greater incidence of fractures (6%) occurs in revision arthroplasties with noncemented prostheses. The femur is the most common site of fracture during both primary and revision procedures. Fractures of the acetabulum and pubic rami occur only rarely.

Nerve injury. Transient or permanent nerve injury may occur with total hip arthroplasty. The most common nerve injured is the sciatic, where the incidence is reported to be about 0.7%.²¹ This is usually caused by intraoperative trauma, but can also complicate postoperative dislocation of the prosthesis. The prognosis for nerve recovery is good unless the nerve is severely damaged. Operative trauma results in less frequent injury to the obturator, gluteal, and femoral nerves.

Dislocation. Dislocation of the femoral head component out of the acetabular socket occurs in 1% to 3% of primary total hip procedures. The main causes of dislocation include inadequate patient compliance with postoperative precautions and malposition of the prosthetic components at the time of the operation. Dislocation is second only to loosening as a cause of revision.²⁰ The most common technical error predisposing to dislocation is malposition of the acetabular component. Most dislocations occur within six months of the surgical procedure, and most patients may be managed conservatively. Recurrent dislocations may require surgical revision, however.

Deep vein thrombosis and pulmonary embolism. Much attention has been paid to deep vein thrombosis and pulmonary embolism as a leading cause of morbidity and mortality in patients with total hip arthroplasty. In the absence of prophylaxis, the incidence of deep vein thrombosis may be as high as 70% and of pulmonary embolism, 20%. Mortality from pulmonary embolism has been reported to be as high as 2%.²² Routine prophylaxis against deep vein thrombophlebitis is therefore recommended in total hip arthroplasty. Graded-compression elastic stockings and early mobilization are used as minimum precautions. Various anticoagulation regimens have been administered, but investigators do not agree as to which is most effective. Low-dose heparin is commonly used, but is reported to be of questionable benefit unless combined with antithrombin III.²³ Low-dose warfarin is used in many centers; but many surgeons are reluctant to accept the risk of bleeding complications that may occur with this and other regimens. Using regional anesthesia in total hip arthroplasty is reported to decrease the incidence of deep venous thrombosis and pulmonary embolism by as much as two thirds when compared with general anesthesia.²⁴ Because thromboembolism may occur despite prophylaxis, vigilance is necessary, and clinical suspicion of

this complication may well prompt Doppler ultrasound examination, leg venography, pulmonary scanning, or pulmonary angiography.

Wound Complications

The most noteworthy wound complications in total hip arthroplasty are hematoma and infection. The overall incidence of hematoma is 3.5%.²⁰ Infection may occur as a secondary complication because the hematoma may act as a culture medium for bacteria. Superficial wound infections are rare and must be differentiated from deep infection involving the prosthetic components themselves.

Late Complications

Infection

Most studies report an infection rate of 1% or less in primary total hip arthroplasty. In revision arthroplasties this rate is reported to be 3% or higher. Infections diagnosed within the first few weeks after the procedure or as long as a year later are most likely due to perioperative contamination.²⁵ This relatively low infection rate is due in part to the routine use of prophylactic antibiotics in the perioperative period. Antistaphylococcal drugs such as vancomycin or one of the cephalosporins are used most frequently for this purpose. The additional use of ultraclean air enclosures may reduce infection rates to lower than 1%. As noted earlier, another prophylactic technique adopted by some surgeons is the direct addition of antibiotics to cement, which allows the drug to elute into the adjacent tissue. Although some use this technique routinely, others reserve its use for hips that have been previously infected. By combining different prophylactic strategies during total hip arthroplasty procedures, some report an incidence of deep infection as low as 0.4%.²⁶

Deep infection in total hip arthroplasty that presents more than a year after the procedure may occur as the result of hematogenous seeding of the implant by organisms originating from a distant site. Infections of the skin, urinary tract, gastrointestinal tract, and mouth are most frequently implicated as sources. Because of this phenomenon, patients who have undergone total hip arthroplasty are counseled to seek rapid treatment of any suspected bacterial infection. Routine prophylactic antibiotic treatment is also recommended for any invasive procedure that could result in a hematogenous spread of bacteria.

Established deep infection in these cases has a tendency to persist unless all prosthetic material is removed, infected tissues are thoroughly debrided, and appropriate antibiotic treatment is administered. Some surgeons have advocated immediate reimplantation of another prosthesis at the time of the initial debridement. Most defer such revisions for 3 to 12 months, however, and proceed only if the infection appears clinically quiescent. Subsequent hip aspirates must be culture-negative before revision arthroplasty is attempted.

Heterotopic Ossification

Heterotopic ossification may occur in as many as 70% of patients undergoing total hip arthroplasty. The incidence of this complication in its more severe and limiting form is much less—only about 4%.²⁷ When severe, heterotopic ossification usually compromises range of motion rather than producing pain. Patients at risk include those with previous heterotopic bone formation and those with diffuse idiopathic skeletal hyperostosis, ankylosing spondylitis, or in men, hypertrophic osteoarthritis. Prophylaxis with certain nonsteroidal anti-inflammatory drugs or with postoperative low-dose radiation therapy is effective for those patients who are at risk. In the event that substantial ossification develops, surgical excision may be helpful, but it is usually delayed for a year to allow the ectopic bone to mature fully.

Loosening

Loosening is the most common cause of failure in noninfected hip arthroplasties. It is manifested by absorption of bone around the implant or cement and is usually detected radiographically before the patient has pain. Loosening may be mechanical or biologic in nature and frequently occurs with long-standing infection. Mechanical loosening results from loading that exceeds the strength of either the prosthetic material or its interface with bone. Excessive loading because of overuse, poor prosthetic design, and improper insertion technique may predispose to this problem. Biologic loosening results from bone resorption mediated by cells stimulated by the presence of particulate-wear debris from cement, polyethylene, or metal. Poor cementing technique, common in earlier years, has been implicated as a cause of loosening. In one study, the incidence of aseptic loosening using first-generation cementing techniques was 32% at 15-year follow-up, with a revision rate of 12.7% as a consequence.²⁸ More recent studies in which newer, second-generation cementing techniques have been used show reduced loosening rates.

Future Directions

Total hip arthroplasty is continuously evolving in terms of materials, prosthetic design, surgical technique, prevention of complications, and postoperative management. The future of prosthetic hip design lies in the development of new materials that will have acceptable biocompatibility and better physical properties, leading both to better integration into bone and to better wear characteristics. One direction in design research is the development of an isoelastic prosthesis, which has physical properties similar to bone. To achieve this, some researchers have experimented with composites of plastics and metals, elements that can confer flexibility and strength at the same time.²⁹ Research in the area of noncemented ingrowth prostheses is focusing on designs that will permit greater bony ingrowth to produce better short- and long-term fixation. Finally, research is underway to identify better materials for the bearing surfaces of prosthetic components to eliminate wear particle-induced osteolysis.

Custom-made prostheses designed to improve individual fit have received attention in recent years. The goal of a precise prosthetic fit is to lower the incidence of postoperative discomfort in noncemented total hip arthroplasty and to provide better survival of the arthroplasty. Because of the high cost of materials and engineering, economics will limit the development of these types of devices. Improvements in technology may allow custom implants to be produced more cheaply, however.

New limitations in health care reimbursement by third-party payers are beginning to have an effect on the economics of total hip arthroplasty. Most of the cost of primary total hip arthroplasty is determined by the length of a patient's hospital stay and by the cost of the prosthetic implant. In our institution (University of California, San Francisco, Medical Center), hospital stays for primary total hip arthroplasty that used to range from 10 to 14 days are now being reduced to 5 to 7 days. Efforts are underway to reduce the cost of prosthetic implants both by limiting the types of implants being used and by reducing the unit cost of implants through contracts with vendors based on volume use.

In an era in which increasing attention is being paid to the relative benefits of medical services, outcome studies are being undertaken to document the results of procedures such as total hip arthroplasty. A prospective study in Canada has shown conclusively, from a public health perspective, that both cemented and uncemented total hip arthroplasty are cost-effective and beneficial.³⁰ Similar studies will no doubt be required in this country, both to assess results of new arthroplasty techniques and to monitor the quality of care provided to patients with total hip arthroplasty whose treatment is increasingly affected by cost reduction policies.

REFERENCES

1. Pearcy MJ: A new generation of artificial hip joints. *Eng Med* 1988; 17:199-201
2. Petty W: Total Joint Replacement—§VI, Lower Extremity Replacement: The Hip. Philadelphia, Pa, WB Saunders, 1991, pp 189-465
3. McKee GK, Watson-Farrar J: Replacement of arthritic hips by the McKee-Farrar prosthesis. *J Bone Joint Surg [Br]* 1966; 48:245-259
4. Charnley J: Total hip replacement. *JAMA* 1974; 230:1025-1028
5. Charnley J: Low Friction Arthroplasty of the Hip: Theory and Practice. Berlin, Germany, Springer-Verlag, 1979, pp 332-345
6. Morrey BF, Ilstrup DM: Size of the femoral head and acetabular revision in total hip replacement arthroplasty. *J Bone Joint Surg [Am]* 1989; 71:50-55
7. Sullivan P, Scott K, Johnston R: Current concepts in hip joint replacement. *Iowa Med* 1992; 276:468-469
8. Rose RM, Nusbaum HJ, Schneider H: On the true wear rate of ultra high molecular weight polyethylene in the total hip prosthesis. *J Bone Joint Surg [Am]* 1980; 62:537-549
9. Moreland JR: Primary total hip arthroplasty, chap 55. *In* Chapman MW (Ed): *Operative Orthopaedics*, Vol 1. Philadelphia, Pa, Lippincott, 1988, pp 679-693
10. Hope PG, Kristinsson KG, Norman P, Elson RA: Deep infection of cemented total hip arthroplasties. *J Bone Joint Surg [Br]* 1989; 71:851-855
11. Welch RB, McGann WA, Picetti GD 3d: Charnley low-friction arthroplasty—A 15- to 17-year follow-up study. *Orthop Clin North Am* 1988; 19:551-555
12. Russotti GM, Coventry MB, Stauffer RN: Cemented total hip arthroplasty with contemporary techniques. *Clin Orthop* 1988; 235:141-145
13. Severt R, Wood R, Cracchiolo A: Long-term follow-up of cemented total hip arthroplasty. *Clin Orthop* 1991; 265:137-145
14. Maloney WJ, Jasty M, Rosenberg A: Bone lysis in well-fixed cemented femoral components. *J Bone Joint Surg [Br]* 1990; 72:966-970

15. Cook SD, McCluskey LC, Martir PC: Inflammatory response in retrieved noncemented porous-coated materials. *Clin Orthop* 1991; 264:209-222
16. Haddad RJ, Cook SD, Thomas KA: Biological fixation of porous-coated implants. *J Bone Joint Surg [Am]* 1987; 69:1459-1466
17. Collier JP, Mayor MB, Chae JC: Macroscopic and microscopic evidence of prosthetic fixation with porous-coated materials. *Clin Orthop* 1988; 235:173-178
18. Thomas KA: Biomechanics and biomaterials of hip implants. *Curr Opin Orthop* 1990; 1:28-37
19. Harris WH, Maloney WJ: Hybrid total hip arthroplasty. *Clin Orthop* 1989; 249:21-29
20. Rothman RH: Complications, chap 9, *In* Booth RE, Balderston RA, Rothman RH (Eds): *Total Hip Arthroplasty*. Philadelphia, Pa, WB Saunders, 1988, pp 174-218
21. Weber ER, Daube JR, Coventry MB: Peripheral neuropathies associated with total hip arthroplasty. *J Bone Joint Surg [Am]* 1976; 58:66-69
22. Haake DA, Berkman SA: Venous thromboembolic disease after hip surgery—Risk factors, prophylaxis and diagnosis. *Clin Orthop* 1989; 242:212-231
23. Francis CW, Pelligrini VD, Marder VJ: Prevention of venous thrombosis after total hip arthroplasty. *J Bone Joint Surg [Am]* 1989; 71:327-335
24. Wille-Jørgensen P, Christensen SW, Bjerg-Nielsen A, Stadaeger C, Kjaer L: Prevention of thromboembolism following elective hip surgery—The value of regional anesthesia and graded compression stockings. *Clin Orthop* 1989; 247:163-167
25. Wilson PD, Salvati EA, Aglietti P, Kukner LJ: The problem of infection in endoprosthetic surgery of the hip joint. *Clin Orthop* 1973; 96:213-216
26. Schutzer SF, Harris WH: Deep-wound infection after total hip replacement under contemporary aseptic conditions. *J Bone Joint Surg [Am]* 1988; 70:724-727
27. Brooker AF, Bowerman JW, Robinson RA, Riley LH: Ectopic ossification following total hip replacement. *J Bone Joint Surg [Am]* 1973; 55:1629-1632
28. Kavanagh BF, Deuritz MA, Ilstrup DM, Stauffer RN, Coventry MD: Charnley total hip arthroplasty with cement. *J Bone Joint Surg [Am]* 1989; 71:1496-1503
29. McKee GK: THR—Past, present, future. *Biomaterials* 1990; 3:130-135
30. Bourne RB, Rorabeck CH, Laupacis A: Cemented Versus Cementless Total Hip Replacement—Cost Effectiveness and Its Impact on Health Related Quality of Life. Presented at the Hip Society 21st scientific meeting, San Francisco, California, 1993