



■ ASPECTS OF CURRENT MANAGEMENT

Current concepts in the management of femoroacetabular impingement

J. R. Crawford,
R. N. Villar

From the BUPA
Cambridge Lea
Hospital, Cambridge,
England

Secondary osteoarthritis of the hip occurs due to a known precipitating cause. In primary or idiopathic osteoarthritis the cause remains unknown although some studies^{1,2} have suggested that femoroacetabular impingement (FAI) may be responsible for the progression of degenerative changes in this group of patients. FAI is a distinct pathological entity and can be defined as the abutment between the proximal femur and the acetabular rim.³ It affects active, young adults and presents clinically with groin pain. FAI can occur either in patients with an abnormal morphology of the hip or in patients with a normal anatomical structure but who have an excessive range of hip movement.

Mechanism of femoroacetabular impingement

A widening of the femoral neck or a decreased offset at the anterolateral head-neck junction results in decreased joint clearance.⁴ This results in repetitive contact between the femoral neck and the acetabular rim which is responsible for a range of injuries including anterior hip pain, labral tears and damage to the acetabular articular cartilage.⁵ Several studies have shown that FAI can cause a progressive degenerative process and lead to early osteoarthritis of the hip.^{1,2,6,7}

There are two distinct types of FAI. The first type, 'cam impingement', is more common in young, athletic men. It is commonly due to a nonspherical portion of the femoral head abutting against the acetabular rim especially in flexion and internal rotation.^{1,8} This causes an outside-in abrasion of the acetabular cartilage which may result in its avulsion from the labrum and subchondral bone. Damage to the acetabular cartilage occurs in the anterosuperior area of the acetabulum and can lead to separation of cartilage from the labrum.⁹

The second type of FAI, 'pincer impingement', is more common in middle-aged athletic women. It is due to the contact between the femoral head-neck junction and the acetabular rim. Repeated abutment leads to degeneration

of the labrum resulting in intrasubstance ganglion formation, ossification of the acetabular rim and deepening of the acetabulum. The chondral damage is located more circumferentially and usually includes only a narrow strip of acetabular cartilage. Changes in the labrum occur at adjacent areas often present as ossification of the labrum.⁹

Cam and pincer impingement rarely occur in isolation. In their study of 149 hips, Beck et al⁹ found that only 26 hips had an isolated cam and 16 hips had an isolated pincer impingement. They found that most cases of FAI involve a combination of these two mechanisms and are classified as having mixed cam-pincer impingement.

Histologically, FAI is characterised by a gentle chronic irritation of the labrum located at the site of rupture that elicits a degenerative reaction.¹⁰ In a study of 25 patients with symptomatic FAI, there was no difference in the histopathological features of the acetabular labrum between cam and pincer impingement.¹⁰

Aetiology

Several predisposing conditions reduce the femoral head-neck offset resulting in cam impingement.¹ These include slipped capital femoral epiphysis with posterior tilt of the femoral head,^{2,11} femoral head necrosis with subsequent flattening,¹² previous fracture of the femoral neck with minor rotational malunion¹³ or a femoral head with a nonspherical extension anterosuperiorly.¹⁴ Histological analysis of these resected nonspherical lesions suggests that this is the cause of the impingement rather than the result of repetitive trauma.¹⁵

Pincer impingement may be due to acetabular retroversion where the anterolateral acetabular edge obstructs flexion¹⁶ or due to coxa profunda which increases the relative depth of the acetabulum.¹⁷

Establishing a diagnosis

FAI affects young and middle-aged active adults who typically present with groin pain

■ J. R. Crawford, BSc,
FRCS(Trauma & Orth),
Orthopaedic Specialist
Registrar

■ R. N. Villar, MA, MS, FRCS,
Consultant Orthopaedic
Surgeon
Cambridge Hip and Knee
Unit
BUPA Cambridge Lea
Hospital, Impington,
Cambridge CB4 9EL, UK.

Correspondence should be
sent to Mr R. N. Villar; e-mail:
rnv@myself.com

©2005 British Editorial
Society of Bone and
Joint Surgery
doi:10.1302/0301-620X.87B11.
16821 \$2.00
J Bone Joint Surg [Br]
2005;87-B:1459-62.

and little or no history of precipitating trauma. The pain is usually exacerbated by activities and also by sitting for long periods. Clinical examination reveals some restriction of movement of the hip especially in flexion with adduction and internal rotation and a positive impingement test.¹⁸ Posteroinferior impingement can be detected by extending the patient's legs over the end of the bed and rotating them externally which reproduces their symptoms.

Plain radiographs of the hip may detect underlying bony abnormalities. The anteroposterior view may show a flattened head-neck junction or pistol-grip deformity of the proximal femur.¹⁹ Herniation pits are often present in the femoral neck.^{20,21} The lateral radiograph can also show a pistol-grip deformity with a resultant loss of the anterior femoral neck offset.⁵ There may be specific acetabular changes present such as an os acetabulare or ossification of the acetabular rim. More generalised changes detectable radiologically include hip dysplasia, coxa vara, coxa valga, protrusio acetabuli and coxa profunda.

Magnetic resonance imaging (MRI) is now commonly used in the evaluation of hip pain in the young adult, particularly if plain radiographs are normal. One study has found reduced femoral neck anteversion and head-neck offset on MRI scans of hips in patients with symptomatic impingement.¹ Magnetic resonance arthrography (MRA) is fast becoming the standard investigation for FAI. It is helpful in detecting nonsphericity of the femoral head, a decreased head-neck offset, herniation pits or rim ossification. MRA is also good at detecting labral tears and chondral damage but has poor specificity for detecting chondral separations that remain undetached.

Non-operative treatment

An initial trial of non-operative treatment for patients presenting with FAI is recommended by some authors.³ This may include modification of activity, avoiding excessive hip movement and regular non-steroidal anti-inflammatory medication. Usually, only temporary relief of symptoms is achieved and surgical intervention may subsequently be required.

Operative treatment

The aim of surgery is to improve the clearance for hip movement and to alleviate the abutment of the proximal femur against the acetabular rim.³ Both open^{17,22,23} and arthroscopic²⁴ techniques have been described. For either technique it is important to address both the damage to the labrum and the underlying cause.⁹

Open surgery for femoroacetabular impingement

Operative technique. The open surgical approach is a well-recognised technique for the treatment of FAI.^{3,22} The patient is placed in the lateral position and either a lateral or a posterior approach can be used. A trochanteric osteotomy is usually performed to improve exposure. Care must be taken to protect the medial femoral circumflex artery

which is the main blood supply to the femoral head. Specific sites of FAI may be identifiable before dislocation of the hip. Dislocation is necessary to provide a 360° view of both the femoral head and the acetabulum.

If the femoral head-neck junction is the cause of FAI due to a nonspherical femoral head or a prominent anterior femoral neck then an excision osteoplasty can be performed. The aim is to recreate the normal concave contour of the femoral neck by sequential osteotomies of small sleeves of bone from the femoral head-neck junction.³ In one cadaver study, it has been shown that the total amount of bone resected should not exceed 30% of the anterolateral quadrant of the head-neck junction due to the increased risk of a subsequent fracture.²⁵

Retroversion of the acetabulum describes a posteriorly-orientated acetabular opening with reference to the sagittal plane.¹⁶ It is a predisposition to the development of osteoarthritis.²⁶ The prominent anterolateral rim of the acetabulum can affect hip flexion and internal rotation, causing impingement with subsequent anterior labral disruption and adjacent cartilage lesions.⁴ This can be treated by resection of the excessive anterior acetabular rim. Alternatively, some authors advocate performing a periacetabular osteotomy as an effective way to reorientate the acetabulum. In one study of 29 patients, 26 had a good or excellent result after this procedure.²⁷

If the acetabular articular cartilage remains intact but there is a lack of posterior cover, a reverse periacetabular osteotomy can be performed.³ If there is adequate posterior cover an excision osteoplasty may be preferred. Any labral tears should be treated with partial resection or repair as appropriate.

Results of open surgery

Outcomes after open surgical procedures for the treatment of FAI have been encouraging. In a study of 19 patients undergoing open surgery with a mean follow-up of 4.7 years, 14 had a good outcome and there were no cases of osteonecrosis.¹⁷ In another study, 23 patients underwent open surgical debridement and were followed up for between two and 12 years.²³ At their last follow-up seven patients had required total hip arthroplasty, one had a further arthroscopic debridement of a recurrent labral tear and 15 had no further surgery. No patients in this study developed osteonecrosis.

Arthroscopic surgery for femoroacetabular impingement

Operative technique. Arthroscopic assessment of the hip can include examination of both the central and peripheral compartments.²⁸ The central compartment includes the labrum and all structures located further medially. The peripheral compartment consists of all the structures that are lateral to the labrum but are inside the capsule which includes the femoral head, the femoral neck with its synovial folds and the joint capsule itself.²⁹ Arthroscopy of the

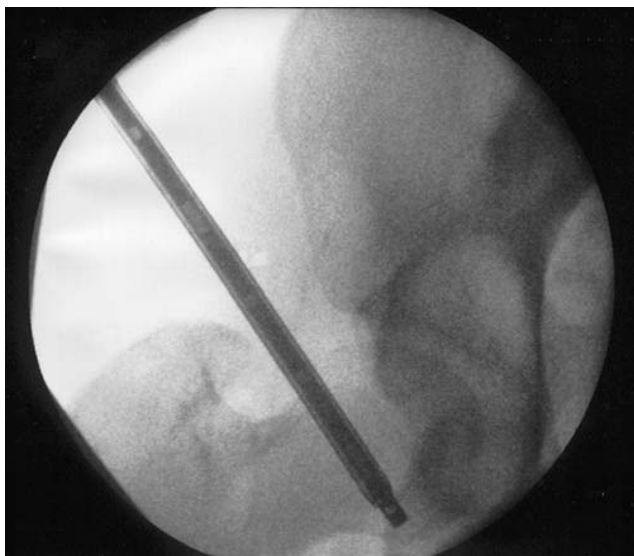


Fig. 1

Fluoroscopic image showing the arthroscope in the peripheral compartment at the inferior aspect of the femoral neck.

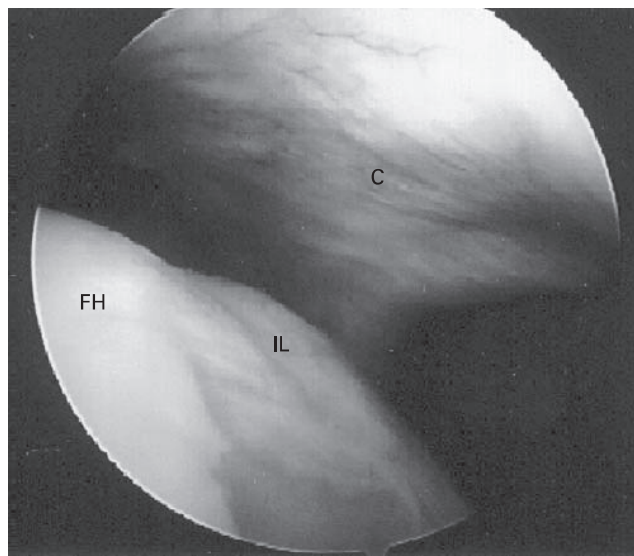


Fig. 2

Operative photograph showing an impingement lesion at the antero-superior aspect of the femoral neck (FH, femoral head; IL, impingement lesion; C, capsule).

peripheral compartment is increasingly undertaken and is certainly indicated when impingement from osteophytes is suspected.³⁰

Hip arthroscopy can be performed with the patient placed in the lateral or supine position³¹⁻³³ with traction applied using a standard distractor and a perineal post. Image-intensifier screening is essential to ensure safe entry of the guide wire and trocars into the joint. Anterolateral and anterior portals are usually required and an additional posterolateral portal may be used if necessary. Characteristic findings include a tear of the labrum anterolaterally and damage to the acetabular cartilage anteriorly which can also extend from the mid-lateral to the posterior portions.²⁴ The labral lesions and any areas of chondral damage are debrided until they are stable.³⁴ Labral repair may be possible for specific tears although the long-term outcome is not yet known.³⁵ For areas of exposed subchondral bone a microfracture technique³⁶ may be performed.

After completing arthroscopy of the central compartment, the traction is released and the peripheral compartment is entered with the arthroscope from the anterolateral portal (Fig. 1). A partial capsulectomy may be required to achieve a satisfactory exposure.²⁴ Any osteophytes located around the femoral head-neck junction can be resected using a burr or a radiothermal device to restore the concavity of the femoral neck (Figs 2 and 3). The external portion of the labrum can also be visualised and rim osteophytes can be resected.

Results of arthroscopic surgery

Arthroscopy has helped to determine the role of FAI in the development of labral tears and to establish appropriate

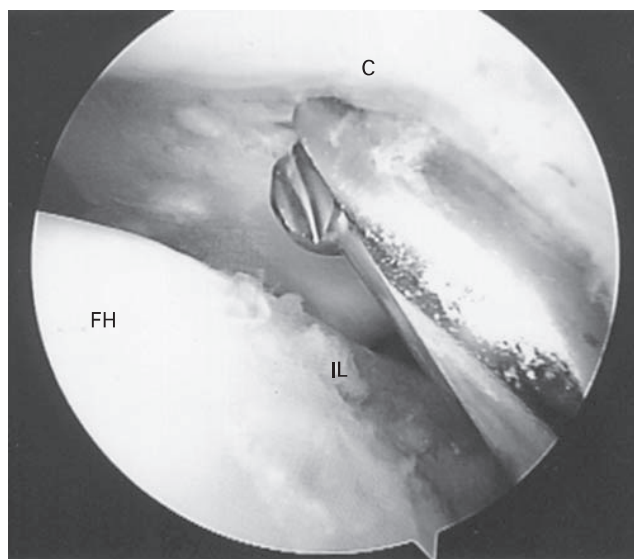


Fig. 3

Operative photograph showing resection of the impingement lesion using a burr (FH, femoral head; IL, impingement lesion; C, capsule).

treatment.³⁷ Favourable results have been reported for the treatment specifically of FAI.²⁴ In a study of 158 patients who underwent arthroscopic surgery, most patients found that 50% of their pain had resolved by three months, 75% by five months and 95% by one year. These results are comparable with those reported for open procedures,¹⁷ although the patients recovered much earlier after arthroscopic surgery.

Outcome and future developments

From the limited number of studies performed addressing the treatment of FAI, surgery gives good results in patients with early degenerative changes of the hip. However, it is not as effective in patients with extensive articular damage or advanced osteoarthritis.

Initial results of arthroscopic surgery for FAI are very favourable and allow a faster post-operative recovery. Early correction of FAI may improve hip pain but long-term studies are still required to determine whether such treatment prevents the progression of osteoarthritis of the hip.

References

- Ito K, Minka MA 2nd, Leunig M, Werlen S, Ganz R. Femoroacetabular impingement and the cam-effect: a MRI based quantitative anatomical study of the femoral head-neck offset. *J Bone Joint Surg [Br]* 2001;83-B:171-6.
- Leunig M, Casillas MM, Hamlet M, et al. Slipped capital femoral epiphysis: early mechanical damage to the acetabular cartilage by a prominent femoral metaphysis. *Acta Orthop Scand* 2000;71:370-5.
- Lavigne M, Parvizi J, Beck M, et al. Anterior femoroacetabular impingement. Part I: techniques of joint preserving surgery. *Clin Orthop* 2004;418:61-6.
- Myers SR, Eijer H, Ganz R. Anterior femoroacetabular impingement after peri-acetabular osteotomy. *Clin Orthop* 1999;363:93-9.
- Tanzer M, Noisieux N. Osseous abnormalities and early osteoarthritis: the role of hip impingement. *Clin Orthop* 2004;429:170-7.
- Ganz R, Parvizi J, Beck M, et al. Femoroacetabular impingement: a cause for osteoarthritis of the hip. *Clin Orthop* 2003;417:112-20.
- Leunig M, Beck M, Woo A, et al. Acetabular rim degeneration: a constant finding in the aged hip. *Clin Orthop* 2004;413:201-7.
- Notzli HP, Wyss TF, Stoecklin CH, et al. The contour of the femoral head-neck junction as a predictor for the risk of anterior impingement. *J Bone Joint Surg [Br]* 2002;84-B:556-60.
- Beck M, Kahlhor M, Leunig M, Ganz R. Hip morphology influences the pattern of acetabular cartilage damage. *J Bone Joint Surg [Br]* 2005;87-B:1012-18.
- Ito K, Leunig M, Ganz R. Histopathological features of the acetabular labrum in femoroacetabular impingement. *Clin Orthop* 2004;429:262-71.
- Rab GT. The geometry of slipped capital femoral epiphysis: implications for movement, impingement and corrective osteotomy. *J Pediatr Orthop* 1999;19:419-24.
- Kloen P, Leunig M, Ganz R. Early lesions of the labrum and acetabular cartilage in osteonecrosis of the femoral head. *J Bone Joint Surg [Br]* 2002;84-B:66-9.
- Eijer H, Myers SR, Ganz R. Anterior femoroacetabular impingement after femoral neck fractures. *J Orthop Trauma* 2001;15:475-81.
- Siebenrock KA, Wahab KHA, Werlen S, et al. Abnormal extension of the femoral head epiphysis as a cause of cam impingement. *Clin Orthop* 2004;418:54-60.
- Wagner S, Hofstetter W, Chiquet M, et al. Early osteoarthritic changes of human femoral head cartilage subsequent to femoro-acetabular impingement. *Osteoarthritis Cartilage* 2003;11:508-18.
- Reynolds D, Lucas J, Klaue K. Retroversion of the acetabulum: a cause of hip pain. *J Bone Joint Surg [Br]* 1999;81-B:281-8.
- Beck M, Leunig M, Parvizi J, et al. Anterior femoroacetabular impingement. Part II: midterm results of surgical treatment. *Clin Orthop* 2004;418:67-73.
- Klaue K, Durnin CW, Ganz R. The acetabular rim syndrome: a clinical presentation of dysplasia of the hip. *J Bone Joint Surg [Br]* 1991;73-B:423-9.
- Harris WH. Etiology of osteoarthritis of the hip. *Clin Orthop* 1986;213:20-33.
- Nokes SR, Vogler JB, Spritzer CE, Martinez S, Herfkens RJ. Herniation pits of the femoral neck: appearance at MR imaging. *Radiology* 1989;172:231-4.
- Pitt MJ, Graham AR, Shipman JH, Birkby W. Herniation pit of the femoral neck. *AJR Am J Roentgenol* 1982;138:1115-21.
- Ganz R, Gill TJ, Gautier E, et al. Surgical dislocation of the adult hip a technique with full access to the femoral head and acetabulum without the risk of avascular necrosis. *J Bone Joint Surg [Br]* 2001;83-B:1119-24.
- Murphy S, Tannast M, Kim Y, Buly R, Millis MD. Debridement of the adult hip for femoroacetabular impingement: indications and preliminary clinical results. *Clin Orthop* 2004;429:178-81.
- Sampson TG. Arthroscopic treatment of femoroacetabular impingement. *Techniques in Orthopaedics* 2005;20:56-62.
- Mardones RM, Gonzalez C, Chen Q, et al. Surgical treatment of femoroacetabular impingement: evaluation of the effect of size of the resection. *J Bone Joint Surg [Am]* 2005;87-A:273-9.
- Tonnis D, Hienecke A. Acetabular and femoral anteversion: relationship with osteoarthritis of the hip. *J Bone Joint Surg [Am]* 1999;81-A:1747-70.
- Siebenrock KA, Schoeniger R, Ganz R. Anterior femoro-acetabular impingement due to acetabular retroversion: treatment with peracetabular osteotomy. *J Bone Joint Surg [Am]* 2003;85-A:278-86.
- Dorfmann H, Boyer T. Arthroscopy of the hip: 12 years of experience. *Arthroscopy* 1999;15:67-72.
- Dienst M, Godde S, Seil R, Hammer D, Kohn D. Hip arthroscopy without traction: in vivo anatomy of the peripheral hip joint cavity. *Arthroscopy* 2001;17:924-31.
- Ilizaliturri VM, Mangino G, Valero F, Camacho-Galindo J. Hip arthroscopy of the central and peripheral compartments by the lateral approach. *Tech Orthop* 2005;20:32-6.
- Byrd JW. Hip arthroscopy: the supine position. *Instr Course Lect* 2003;52:721-30.
- Byrd JW. Hip arthroscopy utilizing the supine position. *Arthroscopy* 1994;10:275-80.
- Byrd JW, Thomas MD. Hip arthroscopy, the supine approach: technique and anatomy of the intraarticular and peripheral compartments. *Tech Orthop* 2005;20:17-31.
- Santori N, Villar RN. Acetabular labral tears: result of arthroscopic partial limbec-tomy. *Arthroscopy* 2000;16:11-15.
- Schenker ML, RobRoy M, Weiland D, Philippon MJ. Current trends in hip arthroscopy: a review of injury diagnosis, techniques, and outcome scoring. *Curr Opinion Orthop* 2005;16:89-94.
- Steadman JR, Rodkey WG, Rodrigo JJ. Microfracture: surgical technique and rehabilitation to treat chondral defects. *Clin Orthop* 2001;391(Suppl):362-9.
- McCarthy JC. The diagnosis and treatment of labral and chondral injuries. *Instr Course Lect* 2004;53:573-7.