



## Case Report

# Ultrasonography and Surgical Treatment of an Unusual Case of Urethral Calculus in an Arabian Horse

Ashraf M. Abu-Seida<sup>\*</sup>, Ashraf A. Shamaa

Faculty of Veterinary Medicine, Department of Surgery, Anesthesiology and Radiology, Cairo University, Giza, Egypt

## ARTICLE INFO

## Article history:

Received 26 April 2020

Received in revised form

1 June 2020

Accepted 1 June 2020

Available online 6 June 2020

## Keywords:

Calcium carbonate

Colic

Distal shadowing

Obstructive urolithiasis

Urethrotomy

Urinary stone

## ABSTRACT

This case report records an obstructive urolithiasis due to a large calcium carbonate urethral stone in an 11-year-old Arabian stallion. The stallion had colicky pain, anuria, and reduction in food and water intakes. Palpation of the penis revealed rhythmic contractions of the urethra, a hard mass in the penile urethra at the level of the ischial arch, and a dilated urethra proximal to the mass. Rectal examination revealed a distended and turgid urinary bladder. Passing a urethral catheter revealed a complete urethral obstruction at the level of the ischial arch. Ultrasonography revealed a calculus that appeared as an irregular, hyperechoic arch-like thick line with acoustic shadowing. Subischial urethrotomy was conducted under epidural anesthesia. Uneventful recovery was seen with no recurrence or complications for 12 months of available follow-up. In conclusion, clinical, rectal, and ultrasound examinations are valuable for definite diagnosis of urethral calculi in horses and the subischial urethrotomy appears to be successful in correcting this condition in horses.

© 2020 Elsevier Inc. All rights reserved.

## 1. Introduction

Obstructive urolithiasis is a rare but potentially serious condition in the horse. Urolithiasis may occur at any anatomical site in the urinary system, but it is most commonly observed in the urinary bladder (UB), particularly in adult male horses with no breed predisposition [1,2].

About 84% of the urolithiasis in horses develop in the UB, where 60% remain in the UB and 24% pass to the urethra causing urethral obstruction, and 16% develop in the renal pelvis, where 12% remain in the renal pelvis and 4% move distally causing ureteral obstruction [1].

Urethral calculi usually result from the small bladder stones that have moved to the urethra and commonly lodge at the ischial arch in horses, where the urethra narrows and changes its direction.

*Animal welfare/ethical statement:* All international and institutional guidelines for animal use and care were followed.

*Conflict of interest statement:* The authors declare no conflict of interest concerning the publication of this case report.

*Financial disclosure:* This case report did not receive any specific grant from funding agencies in the public, commercial, or not-for-profit sectors.

*\* Corresponding author at:* Ashraf M. Abu-Seida, Faculty of Veterinary Medicine, Department of Surgery, Anesthesiology and Radiology, Cairo University, Giza 12211, Egypt.

*E-mail address:* [ashrafseida@yahoo.com](mailto:ashrafseida@yahoo.com) (A.M. Abu-Seida).

However, urethral calculi may occasionally occlude the pelvic urethra [3,4].

The clinical signs, rectal examination, endoscopy, and ultrasonography are valuable for the diagnosis of obstructive urolithiasis in the equine [3–6].

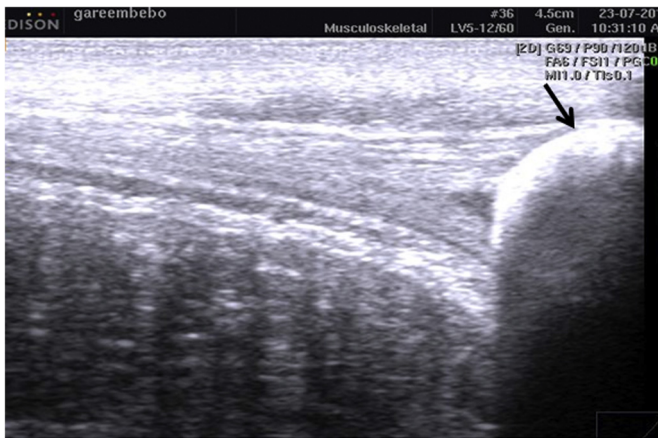Several surgical techniques have been described for the treatment of obstructive urolithiasis, such as laparocystotomy, subischial urethrostomy, urethral sphincterotomy, laparoscopic surgery, laser, shockwave, and electrohydraulic lithotripsy [1,2,4]. The selection of one of these modalities is dictated by the physiological status and gender of the animal, size, number, and location of the stones and the cost and availability of the specialized surgical equipment [1,3].

The main constituent of the equine uroliths is calcium carbonate in its crystalline form of calcite. Other components are calcium phosphates, calcium oxalates, calcium sulfates, silica, and vaterite [7].

According to the available literature, there are scarce reports describing urethral calculi in the horses. This report describes the ultrasonographic features and surgical management of a rare case of an obstructive urethral calculus in an 11-year-old Arabian stallion.

## 2. Case Presentation

An 11-year-old stallion with colicky pain and anuria was admitted to the surgery clinic at Faculty of Veterinary Medicine,



**Fig. 1.** Urethral longitudinal ultrasonogram using a 6 MHz linear transducer in an 11-year-old Arabian stallion with obstructive urethral stone, showing a large urethral hyperechoic calculus (arrow), a strong acoustic shadowing, and an empty urethra distal to the stone. Proximal is to the right.

Cairo University, Egypt. The weight of the stallion was 500 kg. Based on the case history, hematuria was noticed few days before admission, particularly after the exercise and at the end of micturition. Before presentation, the stallion was noted to demonstrate pollakiuria in addition to hematuria as well as noted to demonstrate hypodipsia and hyporexia. No treatment was provided before arrival.

On presentation, physical parameters were noted to be within normal limits. The stallion was noted however to show acute signs of colic (kicking at the abdomen, biting, and tail swishing) in addition to signs of straining, pain, and vocalization when trying to urinate, which resulted in only dribbling of urine. The penis was persistently dropped, and palpation revealed rhythmic contractions with a hard mass in the penile urethra at the level of the ischial arch and a dilated urethra proximal to the mass.

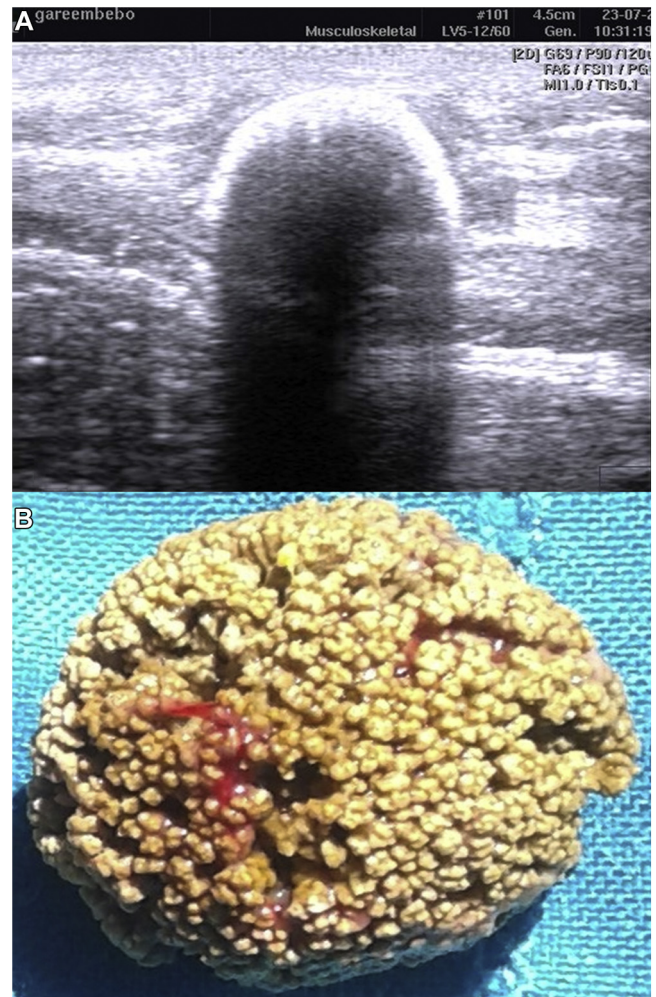
Rectal examination revealed a distended and turbid UB. Passing a flexible plastic urethral catheter with plastic stylet (stallion urinary catheter, 6.6 mm × 137 cm L, Jorgensen Laboratories) failed to reach the UB and revealed a complete obstruction at the ischial arch.

The area of the penile urethra was clipped and examined by ultrasound (SonoVet R3, Samsung, South Korea) using a 6 MHz linear transducer after application of the ultrasound coupling gel. Also, transrectal ultrasound was carried out using a 6.0–10 MHz microconvex linear-array transducer operating at 10 MHz to evaluate the UB and pelvic urethra.

The transcutaneous ultrasonography of the penile urethra revealed a markedly dilated urethra proximal to an irregular, hyperechoic arch-like thick line with a strong acoustic shadowing (Figs. 1 and 2A). The distal urethra ultrasounded within normal limits (Fig. 1). The dilated urethra was filled with anechoic urine with numerous suspended hyperechoic sediments proximal to the mass. Transrectal ultrasound revealed a distended UB and pelvic urethra, and no more urinary calculi were observed.

Based on the clinical, rectal, and ultrasound examinations, a diagnosis of obstructive urolithiasis was made. Surgical intervention was initiated via standing urethrotomy in the standing, sedated horse, under epidural anesthesia.

The stallion was sedated with Xylazine HCl (Xylaject, ADWIA, Egypt) at a dose of 1 mg/kg given intravenously. Caudal epidural anesthesia was then achieved by 8 mL of Lidocaine HCl 2% solution injected into the first intercoccygeal space (0.25 mg/kg, Lidocaine, Hospira Co., Lake Forest, IL). Under complete aseptic condition over the site of urethral obstruction, a 2-cm midline skin incision was



**Fig. 2.** (A) Urethral transverse ultrasonogram using a 6 MHz linear transducer in the same horse, showing a large urethral calculus with an irregular, hyperechoic arch-like line and a strong acoustic shadowing. (B) The removed calcium carbonate urethral calculus showing a hard, round, brown, uniformly granular, and rough surface.

made. Then, the incision was continued through the bulbourethral muscle, corpus spongiosum, and urethral mucosa over the calculus. The calculus was carefully removed, and the retained urine was evacuated. Then, a catheter was introduced proximally to the UB and distally to the urethral orifice to ensure patency, and the UB and urethra were flushed using warm normal saline solution. The urethrotomy wound was left open to heal by the second intention. The stallion was given 3000 IU of antitetanic serum subcutaneously before surgery and penicillin-streptomycin combination (Penstrep, Pharma Swede, Egypt) intramuscularly once daily at a dose of 10000 IU penicillins/kg, 6.2 mg of streptomycin/kg, and 6.25 mg of dihydrostreptomycin/kg for 3 successive days. Intravenous phenylbutazone (Phenylbutazone 20% injection, Aspen co., Durban, South Africa) was administered at a dose of 4 mg/kg once daily for 3 successive days as an anti-inflammatory drug. The wound was dressed 3 times daily by Povidone iodine 10% solution up till its closure on day 10 after surgery. For the first 7 days, the urine was voided through the wound and normal passage as well, and then through the normal route later on. Determination of the urine pH was carried out immediately after collection by use of a portable pH meter (Coming M107). The pH of the urine in the present horse was 7.6.

To acidify the urine, the horse was given ammonium chloride orally at a dose of 50 mg/kg/day and methionine orally at a dose of

1 g/kg/day for one month [8]. The owner was advised to add grains and grass/oat hay to the diet of the horse and to avoid alfalfa. Also enhancing diuresis was recommended by adding 50 g of loose salt daily to the concentrate ration and providing plenty of clean water.

The removed calculus was rounded, hard, and brown and had a uniformly granular and spiculated surface (Fig. 2B). The size of the calculus was 2.47 cm × 2 cm and its weight was 40 g. Different zones of the calculus were analyzed by infrared spectroscopy with a Perkin-Elmer 599B spectrophotometer, using the KBr pellet technique [7]. The chemical analysis of the stone revealed the presence of calcium and carbonate and absence of magnesium, uric acid, phosphate, oxalate, cysteine, and ammonium salt. Based on the chemical analysis, the urethral calculus was confirmed as a calcium carbonate calculus.

### 3. Discussion

Many factors are reported to be responsible for formation of urinary calculi in horses, such as urinary tract infection, type (hard of soft water) and quantity of the water and diets given to the animal, season, age and sex of the horse, and alkalinity of the urine [2,3,9,10].

Urine of the horse is clear to yellow or amber in color and can be cloudy or foamy as a result of calcium carbonate crystals being excreted and with high mucus. This mucus is secreted from the renal pelvis and acts as a lubricant that may prevent the small-sized calcium carbonate crystals from forming into a large stone [11]. Most of the uroliths in horses consist of calcium carbonate because of their hay diet composition [1,3,11]. Therefore, it is not surprising that the chemical analysis of the removed stone here revealed a calcium carbonate stone. The characteristics of the removed stone here were similar to those reported before in the horse [2,9]. On the other hand, a diet rich in phosphorus such as the grains may form stones high in phosphate. Unlike the calcium carbonate stones, this type of urinary stones in horses is dense and has a smooth surface [1,2].

Although a small cystic stone may pass spontaneously in equine and the animal will be well, a large stone may obstruct the urethra and result in rupture of the UB and death, particularly in stallions or geldings, because of their longer and narrower urethra specially at the ischial arch as in the case recorded here [1,5,9].

Hematuria was noticed in this stallion few days before admission, particularly after exercise, because the stone was still in the UB and the movement jostled the wall of the UB between the pelvic bones and the stone, resulting in irritation and bleeding. We suspected that the calculi may have moved from the UB to the urethra causing obstructive urolithiasis later on. Similar findings were reported in previous studies [2,4,9]. This suggestion was confirmed by clinical examination and ultrasonography.

The horse showed colicky pain that was differentiated from the true colic originated from the gastrointestinal tract by the persistently dropped penis associated with the obstruction of the bladder and urethra in horses.

In contrast to previous studies [4,9], the presented stallion had no skin scalding around the prepuce and on the cranial aspect of the lower hind limbs because of the recent and acute condition of this case.

In the presented stallion, the reduction in food and water intakes as well as colic could be attributed to the pressure and pain caused by the distention of the UB and urethra, which were confirmed by rectal and ultrasound examinations. All of the recorded clinical signs resolved after urethrotomy and removal of the calculus.

In large animal practice, ultrasonography is a helpful diagnostic tool for detection of the number, size, surface, and location of the urinary stones [12,13]. In the presented stallion, the urethral

calculus appeared as a hyperechoic structure with acoustic shadowing because of high mineral content.

Therefore, the acoustic shadowing is an important diagnostic ultrasonographic feature during the practical diagnosis of urethral calculi. It is important to examine the entire urinary tract in horses diagnosed with urolithiasis or presenting for urethral obstruction. Also, it is important to perform ultrasonography before cystoscopy, if both are to be performed, to prevent introduction of gas that would obscure ultrasonographic visualization of urinary structures.

For treatment of the stallion, subschial urethrotomy was selected because of the location, and the size of the stone and the availability of surgical facilities. The urethrotomy wound was left open without suture to avoid the narrowing of the urethra as reported by earlier workers [4,9]. The outcome of this treatment was favorable without any complication. These results are in agreement with those reported before [4,9]. In addition, the owner was advised to give the horse plenty of fresh, clean water and decrease the alfalfa that is rich in calcium to decrease the chance of recurrence of the urolithiasis.

About 41% of the horses treated for urolithiasis showed recurrence of the problem between one and 32 months after surgical treatment, particularly after subschial urethrotomy [4]. In the recorded case, no recurrence was observed up to one year of treatment. This difference might be explained by the relatively short follow-up time in this case compared with the follow-up period of the previous study [4]. Also, the postoperative acidification of the urine of the present horse inhibits the recurrence of urolithiasis. Both methionine and ammonium chloride can decrease the urine pH after a single administration [8].

### 4. Conclusions

Horses with obstructive urolithiasis may present with signs of colic and should be considered with history of hematuria. Urethral calculus should be considered in the differential diagnosis of obstructive urolithiasis in horses. Clinical, rectal, and ultrasound examinations are helpful for definite diagnosis of urethral calculi in horses. Subschial urethrotomy appears to be successful in correcting obstructive urolithiasis in horses.

### References

- [1] Edwards B, Archer D. Diagnosis and treatment of urolithiasis in horses. *In Pract* 2011;33:2–10.
- [2] Duesterdieck-Zellmer KF. Equine urolithiasis. *Vet Clin North Am Equine Pract* 2007;23:613–29.
- [3] Foley A, Brounts SH, Hawkins JF. Urolithiasis. *Compend Equine* 2009;4:125–33.
- [4] Laverty S, Pascoe JR, Ling GV, Lavoie JP, Ruby A. Urolithiasis in 68 horses. *Vet Surg* 1992;21:56–62.
- [5] Menzies-Gow N. Diagnostic endoscopy of the urinary tract of the horse. *In Pract* 2007;29:208–13.
- [6] Abd El Kader NA, Farghali HA, Abu-Seida AM, Salem NY, Khatib MS. Evaluation of chromocystoscopy in the diagnosis of cystitis in female donkeys. *PLoS One* 2018;13:e0202596.
- [7] Diaz-Espineira M, Escolar E, Bellanato J, Rodriguez M. Structure and composition of equine uroliths. *J Equine Vet Sci* 1995;15:27–34.
- [8] Wood T, Weckman TJ, Henry PA, Chang SL, Blake JW, Tobin T. Equine urine pH: normal population distributions and methods of acidification. *Equine Vet J* 1990;22:118–21.
- [9] Trotter GW, Bennett DG, Behm RJ. Urethral calculi in five horses. *Vet Surg* 2008;10:159–62.
- [10] Holt PE, Pearson H. Urolithiasis in the horse - a review of 13 cases. *Equine Vet J* 1984;16:31–4.
- [11] Schott HC. Disorders of the urinary system. In: Reed SM, Bayly WM, Sellon DC, editors. *Equine internal medicine*. 3rd ed. W.B. Saunders; 2010. p. 1198–209.
- [12] Abu-Seida AM. Ultrasonographic diagnosis of some scrotal swellings in bulls. *Pak Vet J* 2012;32:378–81.
- [13] Abdelaal AM, Al-Abbadi OS, Abu-Seida AM. Transcutaneous and transrectal ultrasonography in buffalo calves with urine retention. *Asian J Anim Vet Adv* 2016;11:79–88.