

# Arthroscopically Accessible Anatomy of the Tarsal Collateral Ligaments in the Horse

Jan M. Kümmerle, Dr Med Vet, Diplomate ECVS, and  
Martin R. Kummer, Dr Med Vet, Diplomate ECVS

Equine Hospital, Vetsuisse Faculty, University of Zurich, Zurich, Switzerland

## Corresponding Author

Dr. Jan Kümmerle, Equine Hospital  
Vetsuisse Faculty, University of Zurich  
Winterthurer Strasse 260, Zurich CH-8057  
Switzerland  
E-mail: jkuemmerle@vetclinics.uzh.ch

Submitted April 2011  
Accepted March 2012

DOI:10.1111/j.1532-950X.2013.01100.x

**Objective:** To describe the arthroscopically accessible anatomy of the tarsal collateral ligaments in the horse.

**Study Design:** Descriptive study.

**Animals:** Cadaveric equine hind limbs (n = 24) obtained from horses without tarsal disease.

**Methods:** Two pairs of tarsal joints were used to obtain silicone models of the tarsocrural joint and dissect the tarsal collateral ligaments (CLs). Ten pairs of tarsocrural joints had arthroscopic exploration and the accessible parts of the tarsal CLs were marked with an arthroscopic hook knife. Subsequently, the limbs were dissected and the marked positions were allocated to the specific parts of the CLs.

**Results:** Ipsilateral arthroscope and instrument portals were used in each pouch of the tarsocrural joint. Via the plantaromedial pouch, the superficial (2/20 limbs), middle (7), deep (6) or both middle and deep (3) short medial CL and the long medial CL (14) were reached. Access via the plantarolateral pouch allowed manipulation of the deep short lateral CL (20/20 limbs) and the long lateral CL (20). Dorsally, arthroscopy via the dorsomedial pouch gave access to the deep short medial CL (20/20 limbs), while the superficial (9) or middle (10) or both superficial and middle (1) short lateral CL could be reached via the dorsolateral joint recess.

**Conclusions:** Limited parts of the tarsal CLs can be observed or manipulated arthroscopically in normal equine tarsocrural joints.

The equine tarsal collateral ligaments (CLs) have a complex anatomy that was meticulously described by Updike.<sup>1</sup> Based on his results, there is 1 long and 3 short CLs laterally and medially. The long lateral CL originates from the caudal aspect of the lateral malleolus and tibial epiphysis and inserts on a broad area including the distolateral surface of the calcaneus, plantarolateral aspect of the talus, lateral surface of the 4th tarsal bone, and the lateral surfaces of the 3rd and 4th metatarsal bones. At the dorsal border of the long lateral CL, there is a fascial tunnel containing the lateral digital extensor tendon. The origin of the short lateral CL is cranial to the long lateral CL on the lateral malleolus. The short lateral CL consists of 3 parts: a superficial part running distally in a medial spiral to insert on the lateral aspect of the talus and calcaneus just distal to the coracoid process, a middle part inserting on the proximolateral surface of the talus dorsal to the superficial part, and a deep, flat part inserting on the lateral surface of the talus dorsoproximal to the middle part.

The long medial CL is a broad and thick structure with ill-defined dorsal and plantar borders. It originates on the proximal area of the medial tibial malleolus, cranial to the groove of the flexor digitalis medialis muscle. It is described as being incompletely divided into 2 layers; the superficial layer

inserting on the fused 1st and 2nd tarsal bones, 2nd metatarsal bone and 3rd metatarsal bone and the deep layer on the distal tuberosity of the talus and adjacent areas of the central and 3rd tarsal bones. The short medial CL originates from the medial malleolus, cranial to the long medial CL, and is also made up of 3 parts: the superficial part is flat and attaches to the area of the proximal and distal tuberosities of the talus, the middle part is a well-defined, round ligament passing distally in a medial spiraling fashion and inserting on the dorsal part of the medial aspect of the calcaneus while the deep part is a small flat ligament inserting just distal to the proximal tuberosity of the talus.<sup>1</sup>

From a functional perspective, the long CLs are taut during extension and loose during flexion of the tarsocrural joint. The short CLs show a more complex behavior during the range of motion of the tarsocrural joint but most parts are tense in flexion and loose in extension.

Until recently, pathologic conditions of the tarsal CLs were only mentioned sporadically as a cause of lameness in the horse.<sup>2-8</sup> Three retrospective studies describe fractures of the lateral malleolus with involvement of the lateral tarsal CL, most commonly its short part,<sup>9</sup> rupture of the short tarsal CL (Kummer et al., unpublished data) and various pathologic

changes of the tarsal CLs.<sup>10</sup> Besides clinical, radiographic, and ultrasonographic examination,<sup>11,12</sup> tarsocrural joint arthroscopy can provide further diagnostic information on tarsal CL pathology. Furthermore, arthroscopic removal of torn fibers or avulsion fragments is a major part of the therapeutic regime in these horse.<sup>8,9,13</sup>

Although tarsocrural joint arthroscopy is routine in equine surgery,<sup>5</sup> a detailed description of the arthroscopic anatomy of the CLs is lacking. Our purpose was to describe those parts of the equine tarsal CLs that can be identified arthroscopically in the clinically normal tarsocrural joint.

## MATERIALS AND METHODS

### *Silicone Joint Model*

Tarsal joints were collected from 2 adult Warmblood horses euthanatized for reasons unrelated to tarsal disease. Silicone injection was performed using two 3 mm diameter needles inserted into the dorsomedial and plantaromedial pouch of the tarsocrural joint, respectively. Approximately 60 mL red colored silicone with hardener (Silicone red and hardener, Biodur Products, Heidelberg, Germany) were injected via each needle while the joint was maintained in 90–100° of flexion. Subsequently, the limbs were kept cool for 24 hours to allow the silicone to polymerize. Limbs were then dissected to obtain the silicone models of the tarsocrural joint and to prepare the tarsal CLs.

### *Arthroscopy and Dissection Study*

Ten pairs of hind limbs were obtained from adult horses (5 mares, 4 geldings, 1 stallion) euthanatized for reasons unrelated to tarsal disease. Mean horse age was 18 years (range, 5–30 years; median, 17.5 years). There were 5 Warmblood horses, 1 each of Standardbred, Arabian, Friesian, Quarter Horse, and pony mix. Body weight ranged from 260 kg to 680 kg (mean, 530 kg; median, 570 kg). Limbs were harvested and frozen immediately after euthanasia and stored at –20°C until studied. After thawing at room temperature, all limbs had arthroscopic exploration and were dissected. In each pair of hind limbs, tarsocrural joint arthroscopy and subsequent dissection was performed by a board certified surgeon (JMK) in 1 limb and by another board certified surgeon in the contralateral limb (MRK).

### *Arthroscopic Exploration*

For arthroscopic exploration of the tarsocrural joints, limbs were mounted in a custom-made frame in simulated dorsal recumbency and with an initial tarsal angle of 90–100°. During arthroscopic exploration, the tarsal angle was varied between 90° and 130° to evaluate subjectively the effect of a more extended tarsal angle on observation of the CLs. A 4 mm 30° forward oblique 180 mm working length arthroscope (Karl Storz GmbH & Co. KG, Tuttlingen, Germany) was used. After

inserting a 20 g needle into the dorsomedial pouch of the tarsocrural joint, gas distension was achieved using CO<sub>2</sub> administered via an arthroscopic gas insufflator system (Endo-Arthroflator VET, Karl Storz).

An arthroscopic portal was made into the proximoplantar aspect of the distended plantaromedial pouch immediately dorsal to the tarsal sheath and plantar to the trochlear ridges of the talus. Instrument portals were created after determination of their position by percutaneous needle placement. A blunt arthroscopic probe was inserted and used to palpate the CLs in their subsynovial location. A hooked knife (Richard Wolf GmbH, Knittlingen, Germany) was used to create small (2–3 mm long) defects into the accessible parts of the CLs. This procedure was repeated using arthroscopic approaches into the plantarolateral, dorsomedial, and dorsolateral pouches.

The arthroscopic approach into the plantarolateral pouch was located in the center of the distended pouch, dorsal to the tarsal sheath, and plantar to the trochlear ridges of the talus.<sup>5</sup>

The arthroscopic portal in the dorsomedial pouch was located just medial to the tibialis cranialis and peroneus tertius tendons and slightly distal to the medial malleolus.<sup>5</sup>

The arthroscopic approach into the dorsolateral pouch was made ~1 cm abaxial to the long digital extensor tendon at the proximodistal midpoint of the dorsolateral outpouching of the tarsocrural joint.<sup>9</sup>

Instrument portals were located at ~ the same proximodistal level and 1.5–3 cm abaxial to the ipsilateral arthroscopic portal in each pouch.

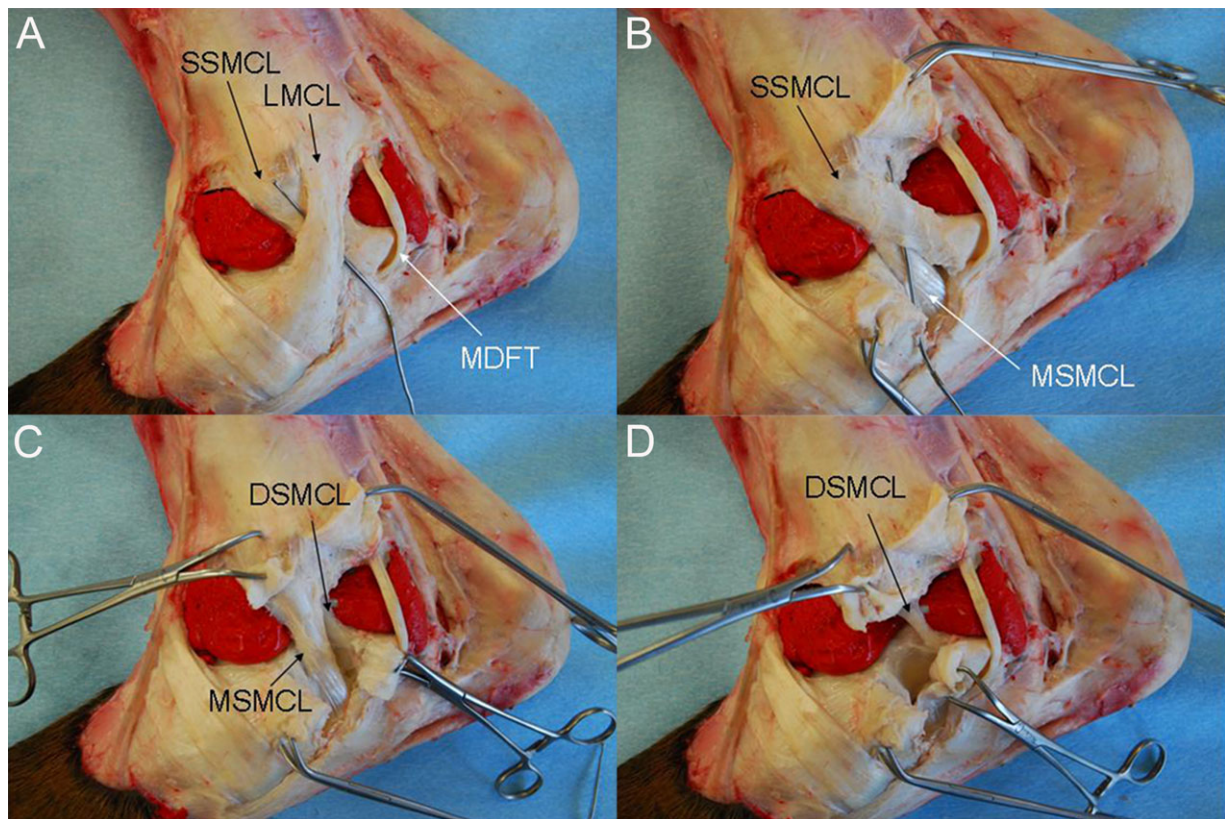
### *Dissection Study*

After completion of arthroscopic exploration, the tarsal joints were carefully dissected. First, the joint pouches were opened around the arthroscope and instrument portals. Then the defects created in the CLs were identified and marked with Halsted-Mosquito forceps. Subsequently, the CLs were dissected and the locations of the iatrogenic defects used to mark these ligaments were recorded.

## RESULTS

### *Silicone Joint Model*

The silicone joint model demonstrated the location of the tarsal CLs in relation to the pouches of the tarsocrural joint. Medially, the proximal aspect of the plantar border of the long medial CL was located adjacent to the plantaromedial pouch (Fig 1A). The superficial part of the short medial CL was running in a distoplantar direction approaching the plantaromedial joint recess (Fig 1B). The plantar border of the middle and deep parts of the short medial CL was located near the plantaromedial joint recess (Fig 1C). The proximal aspect of the deep part of the short medial CL was located between the dorsomedial and plantaromedial pouch; however, the distal part of the short medial CL was situated closer to the plantaromedial than to the dorsomedial pouch (Fig 1D).



**Figure 1** Anatomic preparation of a right equine tarsus after injection of red colored silicone into the tarsocrural joint, medial view. Proximal is on top, distal on the bottom, dorsal on the left, and plantar on the right. (A) A probe has been inserted between the long medial collateral ligament (LMCL) and the superficial part of the short medial collateral ligament (SSMCL). The plantar border of the proximal part of the LMCL is closely associated with the plantaromedial pouch. The medial digital flexor tendon (MDFT) is running directly over the plantaromedial pouch; (B) the long medial collateral ligament has been transected. A probe has been inserted between the superficial part of the short medial collateral ligament (SSMCL) and the middle part of the short medial collateral ligament (MSMCL). The MSMCL is running in a more distal direction than the SSMCL and attaches mainly to the calcaneus; (C) the superficial part of the short medial collateral ligament has been transected. The middle part of the short medial collateral ligament (MSMCL) and the deep part of the short medial collateral ligament (DSMCL) can be seen. The plantar border of the DSMCL and the proximal part of the plantar border of the MSMCL are located close to the plantaromedial pouch; and (D) the middle part of the short medial collateral ligament has been transected and the deep part of the short medial collateral ligament (DSMCL) is visible. The proximal part of the DSMCL is located between the dorsomedial and plantaromedial pouch. The distal part of the DSMCL is situated closer to the plantaromedial pouch than to the dorsomedial pouch.

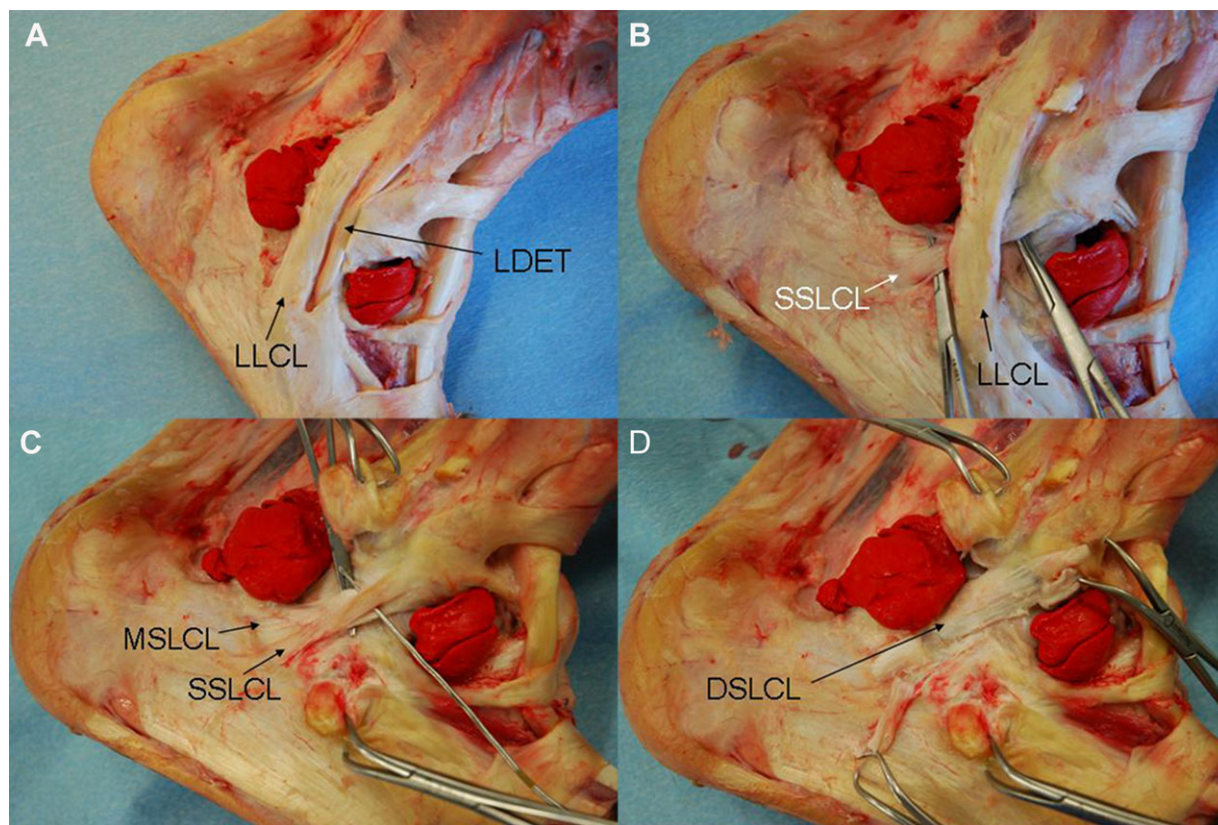
Laterally, the plantar border of the long lateral CL was located directly adjacent to the cranial border of the plantarolateral pouch (Figs 2A and B). The proximal parts of the superficial and middle part of the short lateral CL were located in vicinity to the dorsolateral pouch (Fig 2C). The distal part of the deep part of the short lateral CL was closely associated with the plantarolateral pouch (Fig 2D).

#### *Arthroscopic Exploration and Limb Dissection*

**Plantaromedial pouch.** The CLs could hardly be discerned visually from the homogenous surface of the synovial lining during arthroscopy; however, the medial malleolus could be seen consistently and served as a landmark for palpation with the arthroscopic probe which revealed a ligamentous structure located close to the medial malleolus. An iatrogenic defect

applied into this structure was found in the middle short medial CL in 7/20 limbs, in the deep short medial CL in 6 limbs, in the middle and deep short medial CL in 3 limbs, in the superficial short medial CL in 2 limbs, in either the middle or deep short medial CL in 1 limb (no clear allocation possible during dissection), and was not detected at dissection in 1 limb. Localization of the iatrogenic defect was not always identical in the 2 hind limbs of the same horse (Figs 3 and 4).

Arthroscopic exploration with the probe identified another ligamentous structure running in a proximodistal direction in a slightly more plantar location. This 2nd ligamentous structure was missed during the initial arthroscopic procedures and was surgically addressed in only 7/10 pairs of hind limbs. In these cases, the iatrogenic defect applied with the hooked knife could be detected in the proximal aspect of the plantar border of the long medial CL during dissection.



**Figure 2** Anatomic preparation of a right equine tarsus after injection of red colored silicone into the tarsocrural joint, lateral view. Proximal is on top, distal on the bottom, plantar on the left, and dorsal on the right. (A) The plantar border of proximal part of the long lateral collateral ligament (LLCL) is located directly adjacent to the plantarolateral pouch. The lateral digital extensor tendon (LDET) is closely associated with the dorsal border of the LLCL; (B) the lateral digital extensor tendon has been removed. The superficial part of the short lateral collateral ligament (SSLCL) is located under the long lateral collateral ligament (LLCL) and is demonstrated with forceps; (C) the long lateral collateral ligament has been transected. The probe has been inserted between the superficial part of the short lateral collateral ligament (SSLCL) and the middle part of the short lateral collateral ligament (MSLCL). The forceps is located under the MSLCL. The proximal parts of the SSLCL and MSLCL are located in immediate vicinity to the dorsolateral pouch; and (D) the superficial and middle part of the short lateral collateral ligament has been transected and the deep part of the short lateral collateral ligament (DSLCL) is exposed. The distal part of the DSLCL is located directly adjacent to the plantarolateral pouch.

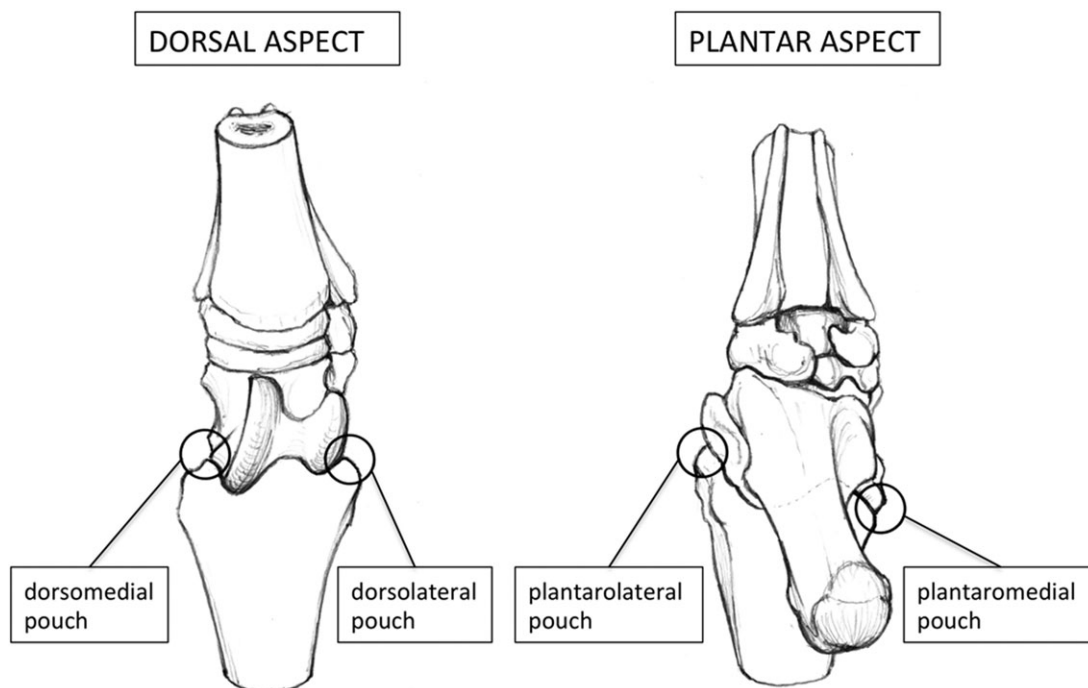
**Plantarolateral pouch.** A ligamentous structure covered only by a thin synovial membrane was clearly visible arthroscopically at the abaxial lateral surface of the talus. This structure was consistently (20/20 limbs) identified as the deep short lateral CL after application of a marker incision and subsequent dissection.

Another ligamentous structure, just plantar to the lateral malleolus, and running in a proximodistal direction could be perceived by palpation using the arthroscopic probe. The iatrogenic defect applied to this ligament was always (20/20 limbs) detected in the proximal half of the plantar margin of the long lateral CL (Figs 3 and 5).

**Dorsomedial pouch.** A ligamentous structure was visible subsynovially adjacent to the medial malleolus. This structure ran in a plantar, slightly distal direction in a mainly dorsoplantar course. The partial thickness incision applied into this structure was located in the deep short medial CL in 20/20 limbs.

Another ligamentous structure could be seen at the distomedial aspect of the talus. The course of this structure was in a distolateral direction and there was only a very thin synovial lining on its surface (Figs 3 and 6). This structure was the talocentrodismetatarsal ligament (i.e. dorsal oblique tarsal ligament).

**Dorsolateral pouch.** Most of the articular surface of the lateral malleolus was covered with a ligamentous structure in a subsynovial location, running in a plantar and slightly distal direction. The partial thickness defect created in it was subsequently identified in the middle short lateral CL in 10/20 limbs, in the superficial short lateral CL in 9 limbs and in both the superficial and the middle short lateral CL in 1 limb. The defects were always located in the proximal aspect of these ligaments. As described for the plantaromedial pouch, localization of the iatrogenic defects was not always identical in the 2 hind limbs of the same horse (Figs 3 and 7).



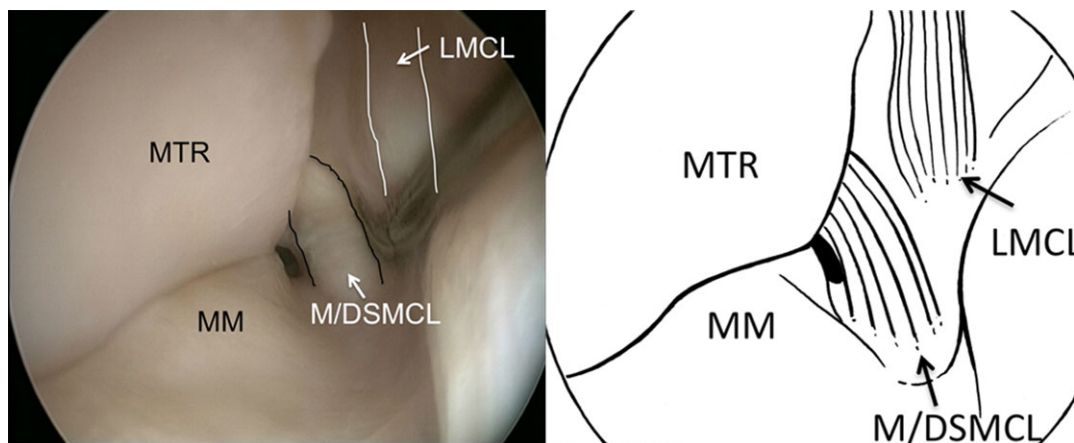
**Figure 3** Diagram of the dorsal and plantar aspect of the bony contours of a right equine tarsus simulating dorsal recumbency. The circles represent the area of arthroscopic observation in the plantaromedial, plantarolateral, dorsomedial, and dorsolateral pouch of the tarsocrural joint as shown in Figs 4–7.

**DISCUSSION**

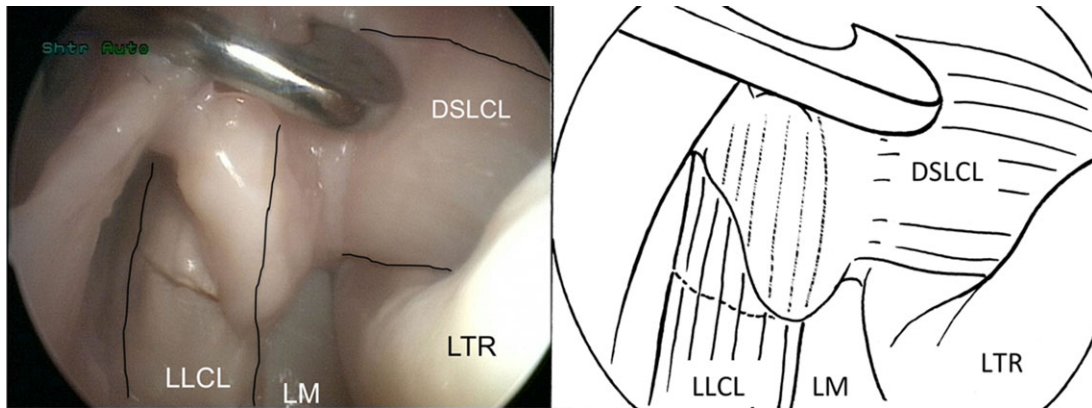
We describe the arthroscopic anatomy of the tarsal CLs in the horse and attempt to define arthroscopically parts of these ligaments. This information should help to evaluate the tarsal CLs as thoroughly as possible during tarsocrural joint

arthroscopy and allow anatomically correct description of areas of tarsal CL damage.

A tarsal joint angle of 90–100° allowed evaluation of the tarsal CL via the dorsal and plantar pouches of the tarsocrural joint. Increasing the tarsal joint angle to 130° subjectively resulted in a slightly increased exposure of the



**Figure 4** (A) Arthroscopic view of the medial malleolus (MM), abaxial aspect of the medial trochlear ridge (MTR), the middle or deep part of the short medial collateral ligament (M/DSMCL) and the long medial collateral ligament (LMCL) as viewed from a plantaromedial approach into a right tarsocrural joint using gas distension. Distal is on the top, proximal on the bottom and medial on the right of the picture. The M/DSMCL can be reached dorsally, close to the medial malleolus. In a few horses, the superficial part of the short medial collateral ligament was reached at this location. The LMCL is located slightly more plantarly running in a proximodistal direction and is difficult to discern due to its subsynovial location. The contours of the LMCL and M/DSMCL are outlined. (B) Corresponding line diagram.



**Figure 5** (A) Arthroscopic view of the lateral malleolus (LM), lateral trochlear ridge (LTR), deep short lateral collateral ligament (DSLCL), and long lateral collateral ligament (LLCL) as viewed from a plantarolateral approach into a right tarsocrural joint using gas distension. Distal is on the top, proximal on the bottom and medial on the right of the image. An iatrogenic defect applied with the hook knife can be seen in the LLCL. The hook knife is seen close to the DSLCL. The contours of the DSLCL and LLCL are outlined. (B) Corresponding line diagram.

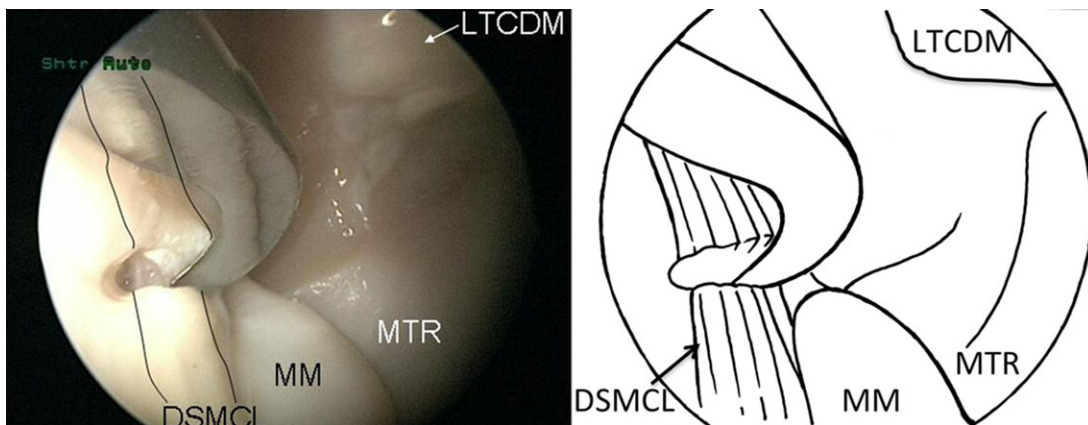
tarsal CL during arthroscopy via the dorsal, but not the plantar pouches.

Ipsilateral arthroscope and instrument portals in each pouch of the tarsocrural joint could theoretically impair triangulation technique but subjectively provided the best access to the CLs in this study. This result is in accordance with the approach used by Smith et al.,<sup>9</sup> ipsilateral arthroscope and instrument portals in the dorsolateral pouch were used to operate on avulsion fractures involving the origin of the lateral tarsal CLs.

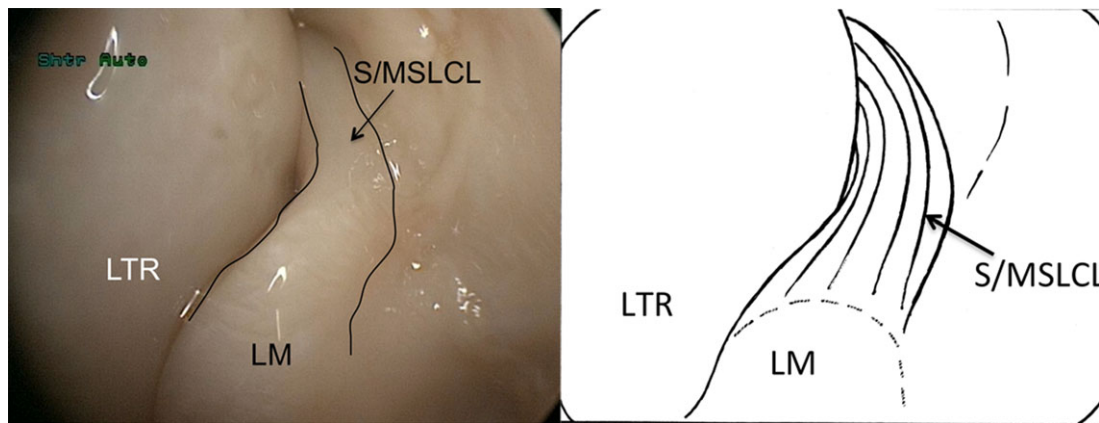
Arthroscopy via each pouch of the tarsocrural joint gives access to different parts of the tarsal CLs. Therefore, arthroscopic evaluation of the CLs should include access via the dorsal and plantar pouches. In our study, the arthroscopic procedure was started on the plantar pouches after appropriate joint distension was achieved. This seems advisable since, in our experience, the anatomic landmarks for portal position in

the plantar pouches are less clear than in the dorsal pouches and slight errors in positioning of the portals dramatically reduce arthroscopic orientation and maneuverability in the plantar aspects of the joint. Localization of the arthroscope portal in the proximoplantar aspect of the plantaromedial pouch is not described<sup>5,14</sup> but turned out to be necessary because otherwise the medial trochlear ridge prevents maneuverability of the arthroscope in the plantar aspect of the joint.

Use of an arthroscopic probe is required for evaluation of the tarsal CLs, since in the absence of pathologic changes, these ligaments are located subsynovially. Whereas the contour of some of these ligaments can be clearly discerned arthroscopically, the location of other parts of these ligaments can only be found by palpation with an arthroscopic probe. This difference might explain some inconsistencies in which parts of the CLs were marked with the hook knife in this study. Whereas the long lateral tarsal CL could always be reached via the



**Figure 6** (A) Arthroscopic view of the medial malleolus (MM), medial trochlear ridge of the talus (MTR) and deep short medial collateral ligament (DSMCL) as viewed from a dorsomedial approach into a right tarsocrural joint using gas distension. Distal is on the top, proximal on the bottom and medial on the left of the picture. The contours of the DSMCL are outlined. The hook knife incising the DSMCL is visible. The talocentrodismetatarsal ligament (LTCDM) is also visualized and should not be confused with a collateral ligament. (B) Corresponding line diagram.



**Figure 7** (A) Arthroscopic view of the lateral trochlear (LTR) ridge and the distal tibia with a part of the lateral malleolus (LM) covered by the short lateral collateral ligament as viewed from a dorsolateral approach into a right tarsocrural joint using gas distension. Distal is on the top, proximal on the bottom and medial on the left of the picture. The part of the short lateral CL accessible with this approach is the superficial or middle part (S/MSLCL), respectively. The contours of the S/MSLCL are outlined. (B) Corresponding line diagram.

plantarolateral pouch (Fig 5), the long medial tarsal CL was marked in the majority, but not all of limbs using a plantaromedial approach (Fig 4). The contour of this medial long tarsal CL could not be discerned visually during arthroscopic exploration and therefore we assume that it was missed in some instances not because of anatomic variation, but because of inappropriate palpation with the arthroscopic probe. On both aspects of the tarsus, the long CLs were running in a vertical direction, along the long axis of the limb. The long CLs were reached via the plantar joint pouches and the iatrogenic defects were located in the proximal part of these ligaments. This corresponds to the more caudal location of the origin of the long compared with the short tarsal CLs on the distal tibia.

The deep part of the short lateral CL was consistently identified on the lateral aspect of the talus using a plantarolateral arthroscopy portal (Fig 5). This ligament was covered only by a thin lining of synovial membrane and therefore, its contours were clearly outlined and easily identified during arthroscopy. In contrast, the short medial CL was difficult to identify during arthroscopy via the plantaromedial pouch of the talocrural joint. Palpation with the arthroscopic probe close to the medial malleolus helped to identify its plantar contour (Fig 4). In contrast to previous reports,<sup>5,15</sup> the medial malleolus could consistently be seen via a plantaromedial arthroscope portal in this study and served as an important anatomic landmark. The part of the short medial CL that was marked by application of an iatrogenic defect during arthroscopic manipulation varied: in most cases, the deep or middle part of the short medial CL was marked but in a few cases, the superficial part of the short medial CL was reached. This reflects the close proximity of the 3 parts of the short medial CL in this location and possibly individual differences in the course and depth of the component parts of the short medial CL.

A dorsomedial arthroscope and instrument portal allowed identification of the deep part of the short medial CL in all limbs. The contour of this ligament was clearly outlined

running horizontally from the medial malleolus in a plantar direction (Fig 6).

It has been reported that the main part of the articular portion of the lateral malleolus is covered by the short lateral CL.<sup>5</sup> Arthroscopy via the dorsolateral cul-de-sac (Fig 7) confirmed this description and dissection of the limbs after arthroscopic application of a partial thickness defect into this ligament revealed that, specifically, the superficial and middle part of the short lateral CL cover the lateral malleolus. Whether this iatrogenic defect was located in the superficial or middle part of the short lateral CL seemed to depend on slight variation of positioning the hooked knife or anatomic variations: in some horses, the superficial part extended slightly more dorsally than the middle part whereas in other horses both of these parts had a similar location of their dorsal border.

During limb dissection, the detailed anatomy of the tarsal CLs presented mainly as described by Updike.<sup>1</sup> However, according to our results, the origin of both long CLs is not located on the lateral or medial malleolus of the tibia but rather more proximally on the distal tibia. This has clinical implications since consequently an avulsion fracture of a malleolus involves the origin of the short rather than the long CLs. This conclusion is supported by the finding that fragments from the lateral malleolus are commonly hinged on the short lateral CLs.<sup>9</sup>

Two tendons are located in close vicinity to the tarsal CLs. The lateral digital extensor tendon is closely associated with the dorsal aspect of the long lateral tarsal collateral ligament (Fig 2A). The tendon of the flexor digitorum profundus muscle runs parallel but in a short distance to the plantar aspect of the long medial tarsal CL (Fig 1A) and could be confused with this CL during arthroscopic exploration of the plantaromedial pouch.

Limitations of our study include the technique used to identify the parts of the CL that were within reach of arthroscopic exploration. During arthroscopic exploration, the CLs were identified either visually or with the help of an arthroscopic probe. The thickness of the synovial lining and the

accessibility of the CLs vary markedly between different sites and therefore, parts of the CLs that are actually accessible arthroscopically might have been missed. The technique of applying partial thickness incisions to mark specific structures has also been used in other studies to evaluate arthroscopic anatomy.<sup>16</sup> However, the different parts of the short CLs are very closely associated at some locations and the depth of the incisions produced by the hooked knife could influence the anatomic position of the iatrogenic defect.

The fact that pathological events can change the local anatomy described in this study should always be borne in mind. These changes can include rupture of the synovial lining or fibers of the CLs and dislocation of the bony attachments. Another limitation is the lack of objective evaluation of the ideal position of arthroscope and instrument portals. Position of arthroscopic portals influences identification of individual structures and we chose portal configurations to allow for best access to the CLs based on our subjective impression only. Finally, CO<sub>2</sub> gas was used as a distension medium during arthroscopy. Fluid distension is more commonly used and can have the advantage of allowing detection of torn fibers because of flotation but gas distension is an established method and has other advantages, that is, a very sharp image can be obtained, movement of tissues is reduced and the synovial villi are compressed and therefore less likely to obscure the operative field.<sup>17</sup>

In conclusion, the tarsal CLs have a specific arthroscopic anatomy in the horse. Despite their subsynovial location, certain parts of their complex anatomy can be observed or manipulated arthroscopically and this has clinical implications for diagnostic and therapeutic purposes.

## DISCLOSURE

The authors report no financial or other conflicts of interest related to any products used in this report.

## ACKNOWLEDGMENTS

We thank Urs Müller and Kathrin Süss for technical assistance with the silicone joint model and limb dissection and Matthias Haab for this artwork.

## REFERENCES

1. Updike SJ: Functional anatomy of the equine tarsocrural collateral ligaments. *Am J Vet Res* 1984;45:867–874
2. Boero MJ, Kneller SK, Baker GJ, et al: Clinical, radiographic, and scintigraphic findings associated with enthesitis of the lateral collateral ligaments of the tarsocrural joint in standardbred racehorses. *Equine Vet J* 1988; (Suppl 6):53–59
3. Bolen G, De Busscher V, Busoni V: Collateral ligament injuries of the equine hock diagnosed by ultrasonography: retrospective study of 11 cases. *Vet Radiol Ultrasound* 2007;48:168; (abstr)
4. Goodrich LR, Trostle SS, White NA II: What is your diagnosis? Avulsion fracture of the calcaneus at the attachment of the long lateral collateral ligament of the tarsus. *J Am Vet Med Assoc* 1997;210:1277–1278
5. McIlwraith CW, Nixon AJ, Wright IM, et al: *Diagnostic and surgical arthroscopy in the horse* (ed 3). Philadelphia, PA, Mosby Elsevier, 2005, pp 295–305
6. Phillips TN: Unusual hock problems. *Proc Am Assoc Equine Practnr* 1986;32:663–667
7. Rose PL, Moore I: Imaging diagnosis—avulsion of the medial collateral ligament of the tarsus in a horse. *Vet Radiol Ultrasound* 2003;44:657–659
8. Wright IM: Ligaments associated with joints, in Dyson S (ed): *Tendon and ligament injuries II*. Philadelphia, PA, Saunders, 1995, pp 283–286
9. Smith MRW, Wright IM: Arthroscopic treatment of fractures of the lateral malleolus of the tibia: 26 cases. *Equine Vet J* 2011;43:280–287
10. Raes EV, Vanderperren K, Pille F, et al: Ultrasonographic findings in 100 horses with tarsal region disorders. *Vet J* 2010;186:201–209
11. Vanderperren K, Raes E, Bree HV, et al: Diagnostic imaging of the equine tarsal region using radiography and ultrasonography. Part 2: bony disorders. *Vet J* 2009;179:188–196
12. Vanderperren K, Raes E, Hoegaerts M, et al: Diagnostic imaging of the equine tarsal region using radiography and ultrasonography. Part 1: the soft tissues. *Vet J* 2009;179:179–187
13. McIlwraith CW, Nixon AJ, Wright IM, et al: *Diagnostic and surgical arthroscopy in the horse* (ed 3). Philadelphia, PA, Mosby Elsevier, 2005, pp 374
14. Auer JA. Tarsus, in Auer JA, Stick JA (eds): *Equine Surgery* (ed 3). Philadelphia, PA, Saunders, 2006, pp 1288–1307
15. Zamos DT, Honnas CM, Hoffman AG: Arthroscopic approach and intra-articular anatomy of the plantar pouch of the equine tarsocrural joint. *Vet Surg* 1994;23:161–166
16. Watts AE, Nixon AJ: Comparison of arthroscopic approaches and accessible anatomic structures during arthroscopy of the caudal pouches of equine femorotibial joints. *Vet Surg* 2006;35:219–226
17. Jansson N: Gas arthroscopy for removal of osteochondral fragments of the palmar/plantar aspect of the metacarpal/metatarsophalangeal joint in horses. *Vet Surg* 2005;34: 128–132