

ABC of clinical electrocardiography

Broad complex tachycardia—Part I

June Edhouse, Francis Morris

Broad complex tachycardias occur by various mechanisms and may be ventricular or supraventricular in origin. In the emergency setting most broad complex tachycardias have a ventricular origin. However, an arrhythmia arising from the atria or the atrioventricular junction will produce a broad complex if associated with ventricular pre-excitation or bundle branch block. The causes of ventricular and supraventricular tachycardias are generally quite different, with widely differing prognoses. Most importantly, the treatment of a broad complex tachycardia depends on the origin of the tachycardia. This article describes monomorphic ventricular tachycardias; other ventricular tachycardias and supraventricular tachycardias will be described in the next article.

Terminology

Ventricular tachycardia is defined as three or more ventricular extrasystoles in succession at a rate of more than 120 beats/min. The tachycardia may be self terminating but is described as “sustained” if it lasts longer than 30 seconds. The term “accelerated idioventricular rhythm” refers to ventricular rhythms with rates of 100-120 beats/min.

Ventricular tachycardia is described as “monomorphic” when the QRS complexes have the same general appearance, and “polymorphic” if there is wide beat to beat variation in QRS morphology. Monomorphic ventricular tachycardia is the commonest form of sustained ventricular tachycardia

Varieties of broad complex tachycardia

Ventricular

Regular

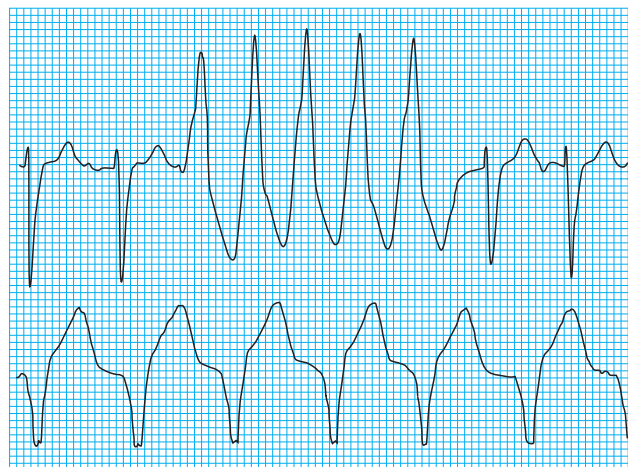
- Monomorphic ventricular tachycardia
- Fascicular tachycardia
- Right ventricular outflow tract tachycardia

Irregular

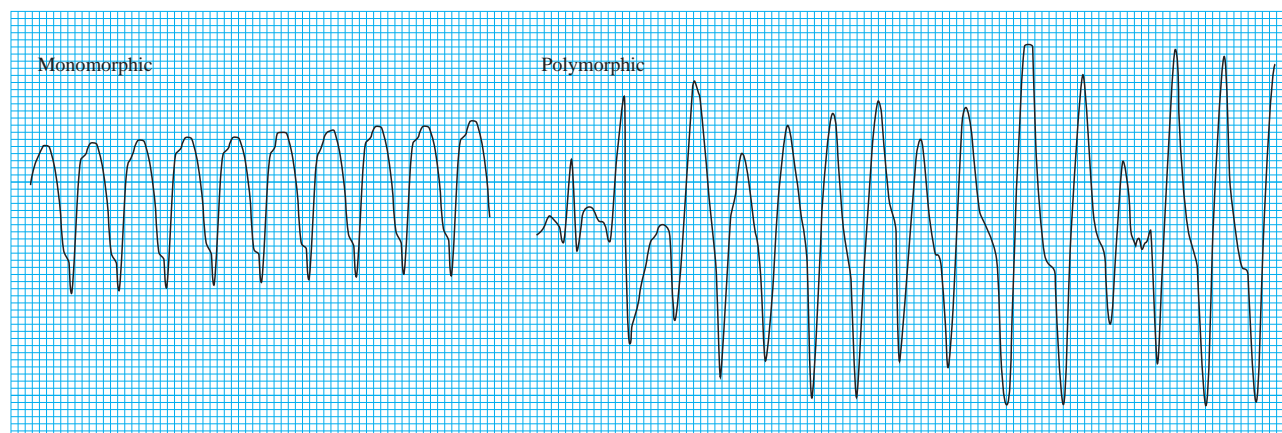- Torsades de pointes tachycardia
- Polymorphic ventricular tachycardia

Supraventricular

- Bundle branch block with aberrant conduction
- Atrial tachycardia with pre-excitation



Non-sustained ventricular tachycardia (top) and accelerated idioventricular rhythm (bottom)



Monomorphic and polymorphic ventricular tachycardia

Mechanisms of ventricular arrhythmias

The mechanisms responsible for ventricular tachycardia include re-entry or increased myocardial automaticity. The tachycardia is usually initiated by an extrasystole and involves two pathways of conduction with differing electrical properties. The re-entry circuits that support ventricular tachycardia can be “micro” or

The electrophysiology of a re-entry circuit was described in last week's article

“macro” in scale and often occur in the zone of ischaemia or fibrosis surrounding damaged myocardium.

Ventricular tachycardia may result from direct damage to the myocardium secondary to ischaemia or cardiomyopathy, or from the effects of myocarditis or drugs—for example, class I antiarrhythmics (such as flecainide, quinidine, and disopyramide). Monomorphic ventricular tachycardia usually occurs after myocardial infarction and is a sign of extensive myocardial damage; there is a high in-hospital mortality, more often resulting from impaired ventricular function than recurrence of the arrhythmia.

Electrocardiographic findings in monomorphic ventricular tachycardia

Electrocardiographic diagnosis of monomorphic ventricular tachycardia is based on the following features.

Duration and morphology of QRS complex

In ventricular tachycardia the sequence of cardiac activation is altered, and the impulse no longer follows the normal intraventricular conduction pathway. As a consequence, the morphology of the QRS complex is bizarre, and the duration of the complex is prolonged (usually to 0.12 s or longer).

As a general rule the broader the QRS complex, the more likely the rhythm is to be ventricular in origin, especially if the complexes are greater than 0.16 s. Duration of the QRS complex may exceed 0.2 s, particularly if the patient has electrolyte abnormalities or severe myocardial disease or is taking antiarrhythmic drugs, such as flecainide. If the tachycardia originates in the proximal part of the His-Purkinje system, however, duration can be relatively short—as in a fascicular tachycardia, where QRS duration ranges from 0.11 s to 0.14 s.

The QRS complex in ventricular tachycardia often has a right or left bundle branch morphology. In general, a tachycardia originating in the left ventricle produces a right bundle branch block pattern, whereas a tachycardia originating in the right ventricle results in a left bundle branch block pattern. The intraventricular septum is the focus of the arrhythmia in some patients with ischaemic heart disease, and the resulting complexes have a left bundle branch block morphology.

Rate and rhythm

In ventricular tachycardia the rate is normally 120-300 beats/minute. The rhythm is regular or almost regular (< 0.04 s beat to beat variation), unless disturbed by the presence of capture or fusion beats (see below). If a monomorphic broad complex tachycardia has an obviously irregular rhythm the most likely diagnosis is atrial fibrillation with either aberrant conduction or pre-excitation.

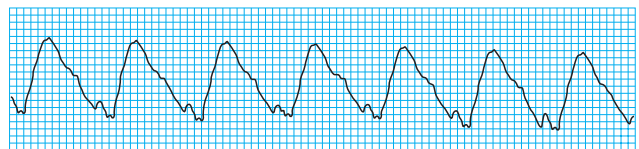
Frontal plane axis

In a normal electrocardiogram the QRS axis in the mean frontal plane is between -30° and $+90^\circ$, with the axis most commonly lying at around 60° . With the onset of ventricular tachycardia the mean frontal plane axis changes from that seen in sinus rhythm and is often bizarre. A change in axis of more than 40° to the left or right is suggestive of ventricular tachycardia.

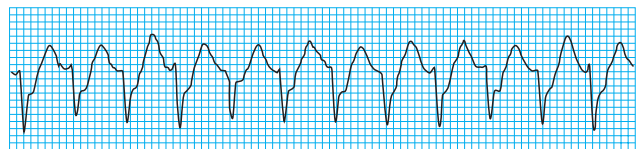
Lead aVR is situated in the frontal plane at -110° , and when the cardiac axis is normal the QRS complex in this lead is negative; a positive QRS complex in aVR indicates an extremely abnormal axis either to the left or right. When the

Triggered automaticity of a group of cells can result from congenital or acquired heart disease. Once initiated, these tachycardias tend to accelerate but slow markedly before stopping

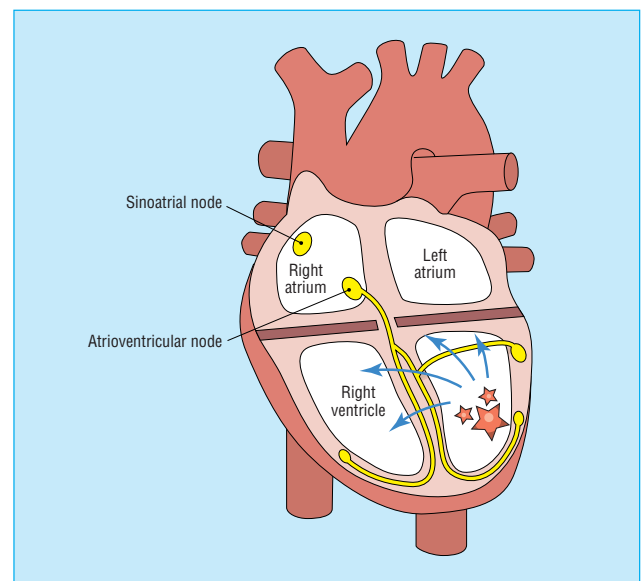
Ventricular tachycardia in a patient with chronic ischaemic heart disease is probably caused by a re-entry phenomenon involving infarct scar tissue, and thus the arrhythmia tends to be recurrent



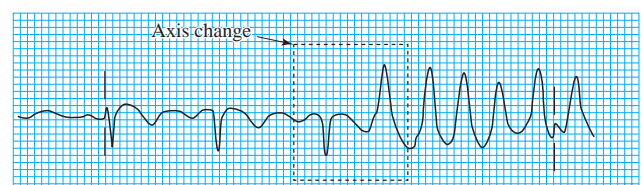
Ventricular tachycardia with very broad QRS complexes



Fascicular tachycardia with narrow QRS complexes



Ventricular tachycardia showing abnormal direction of wave of depolarisation, giving rise to bizarre axis



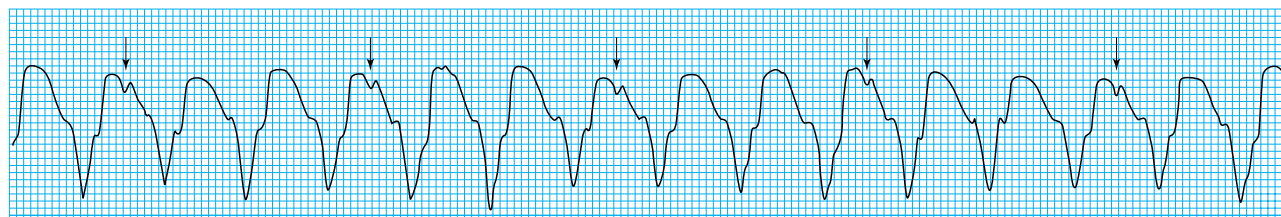
Change in axis with onset of monomorphic ventricular tachycardia in lead aVR

QRS complex in lead aVR is entirely positive the tachycardia originates close to the apex of the ventricle, with the wave of depolarisation moving upwards towards the base of the heart.

Direct evidence of independent atrial activity

In ventricular tachycardia, the sinus node continues to initiate atrial contraction. Since this atrial contraction is completely independent of ventricular activity, the resulting P waves are dissociated from the QRS complexes and are positive in leads I and II. The atrial rate is usually slower than the ventricular rate, though occasionally 1:1 conduction occurs.

In some patients the atrioventricular node allows retrograde conduction of ventricular impulses to the atria. The resulting P waves are inverted and occur after the QRS complex, usually with a constant RP interval.



Atrioventricular dissociation in monomorphic ventricular tachycardia (note P waves, arrowed)

Although evidence of atrioventricular dissociation is diagnostic for ventricular tachycardia, a lack of direct evidence of independent P wave activity does not exclude the diagnosis. The situation may be complicated by artefacts that simulate P wave activity.

However, beat to beat differences, especially of the ST segment, suggest the possibility of independent P wave activity, even though it may be impossible to pinpoint the independent P wave accurately.

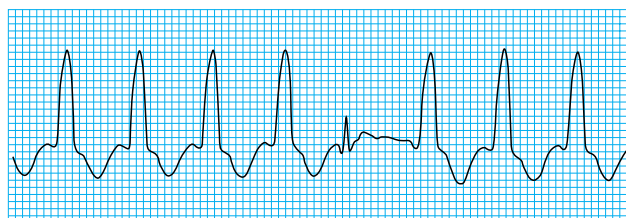
It is important to scrutinise the tracings from all 12 leads of the electrocardiogram, as P waves may be evident in some leads but not in others

Indirect evidence of independent atrial activity

Capture beat

Occasionally an atrial impulse may cause ventricular depolarisation via the normal conduction system. The resulting QRS complex occurs earlier than expected and is narrow. Such a beat shows that even at rapid rates the conduction system is able to conduct normally, thus making a diagnosis of supraventricular tachycardia with aberrancy unlikely.

Capture beats are uncommon, and though they confirm a diagnosis of ventricular tachycardia, their absence does not exclude the diagnosis.

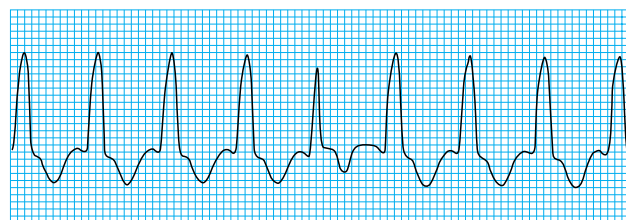

Capture beat

Fusion beats

A fusion beat occurs when a sinus beat conducts to the ventricles via the atrioventricular node and fuses with a beat arising in the ventricles. As the ventricles are depolarised partly by the impulse conducted through the His-Purkinje system and partly by the impulse arising in the ventricle, the resulting QRS complex has an appearance intermediate between a normal beat and a tachycardia beat.

Like capture beats, fusion beats are uncommon, and though they support a diagnosis of ventricular tachycardia, their absence does not exclude the diagnosis.



Fusion beat

QRS concordance throughout the chest leads

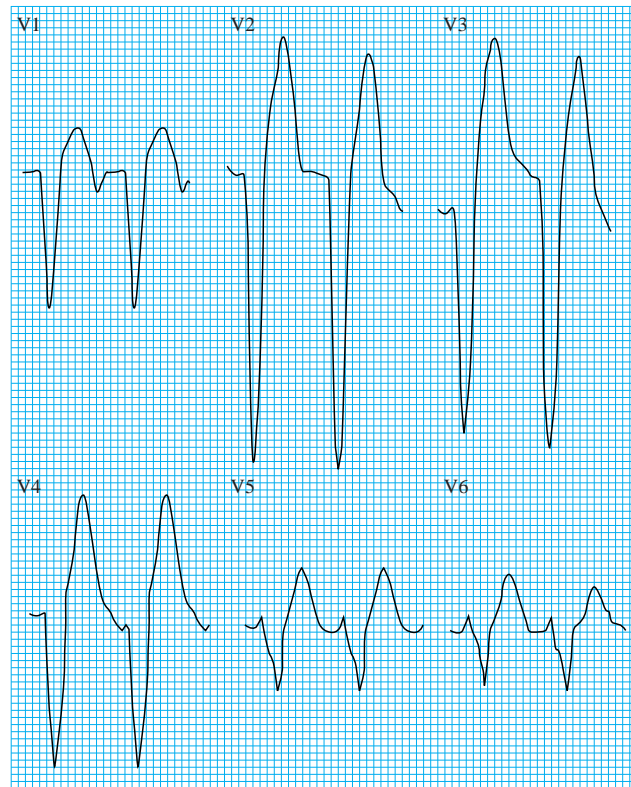
Concordance exists when all the QRS complexes in the chest leads are either predominantly positive or predominantly negative.

The presence of concordance suggests that the tachycardia has a ventricular origin.

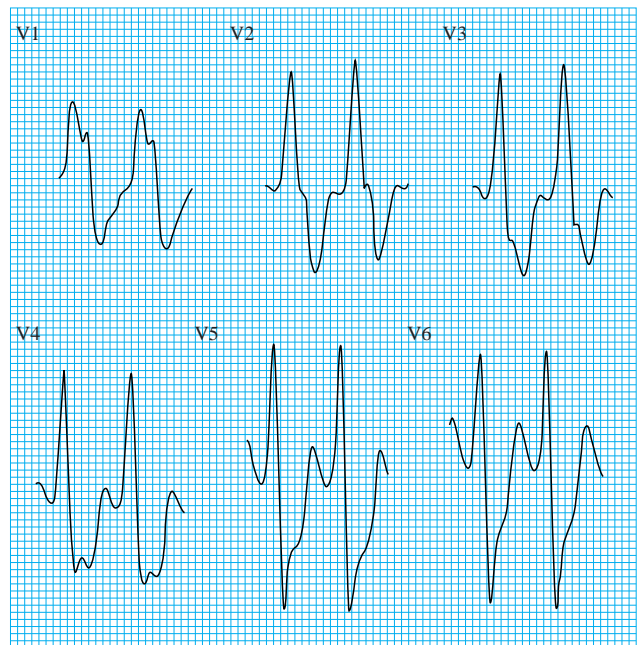
Positive concordance probably indicates that the origin of the tachycardia lies on the posterior ventricular wall; the wave of

Concordance can be either positive or negative

depolarisation moves towards all the chest leads and produces positive complexes. Similarly, negative concordance is thought to correlate with a tachycardia originating in the anterior ventricular wall.



Negative concordance: ventricular tachycardia in a 90 year old woman in congestive cardiac failure



Positive concordance

The ABC of clinical electrocardiography is edited by Francis Morris, consultant in emergency medicine at the Northern General Hospital, Sheffield; June Edhouse, consultant in emergency medicine, Stepping Hill Hospital, Stockport; William J Brady, associate professor, programme director, and vice chair, department of emergency medicine, University of Virginia, Charlottesville, VA, USA; and John Camm, professor of clinical cardiology, St George's Hospital Medical School, London. The series will be published as a book in the summer.

BMJ 2002;324:719-22

One hundred years ago Hospital chapels

Lovers of London are of diverse temperaments: some take pleasure in her humanity, some in her history, some in her treasures of science and art. But, for the full enjoyment of London, a man must have also that imaginative habit of mind which children call make-believe; he must be able to play at being in a foreign town. There are Londoners who keep all the year round the sense of sight-seeing, the holiday feeling, the happy knack of exploring Soho or the Borough as though they were in Paris or Florence. Old City churches, and the Surrey side, and the docks, are dear to them; they prefer not to know where they are; and they will even take a Baedeker's guide with them to heighten the pleasant self-illusion that they are on the Continent. "If one could do London now as a strange place"—that is what they long for; to discover, to wander as tourists, to be where they have not yet been. Everywhere they find something to see: they know the way down to the Early English crypt of St. John's, Clerkenwell, and the way up to the roof of the new Roman Catholic Cathedral. We commend to these wise Londoners the study of hospital

chapels; they will be glad to hear of new sights unstarred by Baedeker.

Not all hospital chapels are worthy of a star; but even those that are ugly have distinction, and none are wholly dull. In some of them there is this or that one thing to be seen; for example, the wood-carving at St. Saviour's, the founder's statue at Guy's, and the windows at St. Bartholomew's, that were the first commission given to the present President of the Royal Academy. But, in the chapels of the Middlesex Hospital and of the Great Ormond Street Hospital for Sick Children, there is not an inch that is not beautiful. Especially in the little chapel of the Middlesex, where ten years have been spent over the decoration of Pearson's exquisite design, the good Londoner will stand amazed at the wealth of marbles in all tints and veinings, and of gold mosaic of the utmost fineness; it is a veritable bit of Italy, a perfect example of the purest and richest decorative art of modern times.

(BMJ 1902;i:728)