

Management of Multidirectional Instability of the Shoulder

Trevor R. Gaskill, MD
COL (Ret) Dean C. Taylor, MD
Peter J. Millett, MD, MSc

From The Steadman Clinic (Dr. Gaskill), the Steadman Philippon Research Institute (Dr. Millett), Vail, CO, and Duke Orthopaedics, Duke University Medical Center, Durham, NC (Dr. Taylor).

Dr. Taylor or an immediate family member serves as a board member, owner, officer, or committee member of the American Orthopaedic Society for Sports Medicine and the Magellan Society and has received research or institutional support from Histogenics. Dr. Millett or an immediate family member has received royalties from and serves as a paid consultant to or is an employee of Arthrex; has stock or stock options held in Game Ready and VuMedi; and has received research or institutional support from Arthrex, OrthoRehab, Össur Americas, Siemens Medical Solutions, Smith & Nephew, and ConMed Linvatec. Neither Dr. Gaskill nor any immediate family member has received anything of value from or owns stock in a commercial company or institution related directly or indirectly to the subject of this article.

J Am Acad Orthop Surg 2011;19:758-767

Copyright 2011 by the American Academy of Orthopaedic Surgeons.

Abstract

Multidirectional shoulder instability is defined as symptomatic instability in two or more directions. Instability occurs when static and dynamic shoulder stabilizers become incompetent due to congenital or acquired means. Nonspecific activity-related pain and decreased athletic performance are common presenting complaints. Clinical suspicion for instability is essential for timely diagnosis. Several examination techniques can be used to identify increased glenohumeral translation. It is critical to distinguish increased laxity from instability. Initial management begins with therapeutic rehabilitation. If surgical management is required, capsular plication has been used successfully. Advanced arthroscopic techniques offer several advantages over traditional open approaches and may have similar outcomes. The role of rotator interval capsular plication is controversial, but it may be used to augment capsular plication in patients with specific patterns of instability. Despite encouraging results, outcomes remain inferior to those associated with traumatic unidirectional instability.

Neer and Foster¹ are widely credited with bringing clinical attention to multidirectional instability (MDI) of the shoulder. Since the initial description of MDI, basic science and clinical research have contributed to a better understanding of glenohumeral stability, and surgical management of MDI has evolved to include arthroscopic reconstruction. Despite these advances, diagnosis and management remain challenging.

The innate complexity of glenohumeral stability contributes to this challenge. To some extent, dynamic and static stabilizers are able to compensate for other deficient structures. Structural deficiencies become apparent only when compensatory mechanisms fail. Thus, objective measures of glenohumeral laxity, which may

be abnormal, are not necessarily indicative of instability or the need for surgical reconstruction. Imaging may provide clues, but findings characteristic of MDI are not pathognomonic.

Standardized criteria that define MDI do not exist in the literature, which contributes to considerable variation in the prevalence of its diagnosis.² Standard criteria may provide more uniform populations for comparative purposes. Neer and Foster¹ described MDI as anterior and posterior instability associated with involuntary inferior subluxation or dislocation. MDI has also been defined as instability in two or three directions.³⁻⁶ Despite the absence of symptoms, instability has been inappropriately diagnosed based on the presence of a sulcus sign or the ability to subluxate the shoulder.^{3,7} MDI may exist in pa-

Table 1**Classification of Dynamic Shoulder Instability⁹**

Classification	Description
Unidirectional instability without hyperlaxity	Symptoms elicited in a single direction Traumatic capsulolabral lesions frequently present
Unidirectional with hyperlaxity	Symptoms elicited in a single direction Patulous capsular tissue frequently present Presence of capsulolabral lesion less likely
Multidirectional instability without hyperlaxity	Symptoms elicited in two or more directions Anterior and posterior capsulolabral lesions frequently present
Multidirectional instability with hyperlaxity	Symptoms elicited in two or more directions Patulous capsular tissue frequently present Signs of generalized hyperlaxity frequently present Frequent recurrent subluxation

Table 2**Static and Dynamic Stabilizing Structures of the Glenohumeral Joint****Static stabilizers**

Glenoid concavity and version
Labral height
Glenohumeral ligaments

Dynamic stabilizers

Scapulothoracic musculature
Rotator cuff
Proprioceptive and neuromuscular control

tients with large labral tears, which are considered evidence of traumatic etiology.^{4,6,8} These patients experience symptomatic instability in multiple directions and have structural lesions that respond favorably to surgical intervention. The lack of a precise definition for MDI underscores the need for detailed inclusion and exclusion criteria.

It is critical to distinguish laxity from instability. Instability is characterized by the presence of symptoms in conjunction with abnormal laxity, which is indicative of deficient static and dynamic glenohumeral stabilizers. Instability can be caused by repetitive microtrauma or a single macrotrauma. Congenital hyperlaxity may predispose to development of shoulder instability.

Historically, the acronyms TUBS (traumatic, unilateral, Bankart lesion, surgery) and AMBRI (atraumatic multidirectional, bilateral, rehabilitation, inferior capsular shift) have been used to describe shoulder instability in etiological terms. However, these classification systems do not help the physician discern instability from hyperlaxity and microtrauma from macrotrauma. Classification based on the direction of instability and the presence of hyper-

laxity avoids this dilemma. Gerber and Nyffeler⁹ classified dynamic instability as unidirectional or multidirectional with or without hyperlaxity (Table 1). This system provides a method to classify specific MDI populations that will likely respond differently to therapeutic intervention. In this article, we define MDI as symptomatic instability in two or more directions with or without associated hyperlaxity.

Glenohumeral Stability

The glenohumeral joint is a highly specialized structure responsible for shoulder motion in multiple planes with a minimum of bony constraint. Static and dynamic stabilizers interact to provide joint stability (Table 2). Stabilizer deficiency can yield instability; therefore, management strategies should focus on restoring or rehabilitating these structures.

Static stabilization of the glenohumeral joint is provided by its inherent bony and ligamentous structures. The native concavity of the glenoid, augmented by the surrounding labrum, provides a small but important restraint to glenohumeral translation. In some series, patients with symptomatic

MDI exhibit a shallower glenoid cavity than that of age-matched controls.^{10,11} The capsuloligamentous structures of the glenohumeral joint have been well described. These ligaments function primarily at the terminal extent of motion as regional ligamentous tightening occurs. Although some of the specific functions of these ligaments have been disputed, results of clinical reconstruction have established the importance of ligamentous restraint to glenohumeral stability.^{1,6,12-16} Insufficiency of these structures places higher demands on other shoulder stabilizers.

Dynamic stabilization of the glenohumeral joint is provided by the muscle-tendon units surrounding the scapula. These muscles are responsible for positioning the glenoid in space and dynamically altering glenoid version and inclination. Abnormal scapular kinematics has been reported in patients with MDI compared with asymptomatic control subjects.¹⁷ This aberration may contribute to an increase in the relative translational forces in the labrum and other stabilizing structures.

The rotator cuff also provides dynamic stabilization of the glenohumeral joint. It acts to compress the humeral head against the glenoid, and its bulk functions as a buttress

to the joint. Lippitt et al¹⁸ reported that concavity compression of the glenohumeral joint could resist translational forces equal to 60% of the applied compressive load. Proprioceptive feedback to and neuromuscular control of the rotator cuff influences its functional effectiveness. Electromyographic evidence has shown that patients with MDI have abnormal patterns of muscle activity.¹⁹ Increased hand position errors with proprioceptive testing²⁰ and abnormal dynamic humeral head centering have also been described in this population.²¹ These abnormal patterns may limit the ability of the rotator cuff to refine motor output, thereby decreasing dynamic stabilizer effectiveness.

Glenohumeral translation may increase when these dynamic stabilizers are damaged or incompetent. Most patients with MDI are not symptomatic from birth. This implies that some component of MDI is acquired. A patulous inferior capsular complex is traditionally described as the etiology of MDI.¹ The presence of this lesion is likely necessary but not sufficient for symptoms to occur. This observation is supported by reports of similar measurements of glenohumeral translational in symptomatic patients with MDI and asymptomatic control subjects.²²

Clinical Presentation

MDI comprises a spectrum of instability patterns and clinical presentations. Most patients present with insidious onset and nonspecific, activity-related pain in the second to third decade of life. Decreased strength and deteriorating athletic performance also may be reported. Paresthesias or radicular symptoms are less common. Identification of specific inciting activities can provide insight into the direction and severity

of instability. Frequently, patients either learn to avoid certain positions or develop compensatory routines to avoid inciting activities. Although bilateral shoulder laxity is common in patients with MDI, the need for bilateral stabilization procedures is infrequent.^{1,16,23} The prevalence of MDI is higher in persons involved in repetitive overhead activities, particularly in sports such as volleyball, swimming, or gymnastics. Collagen disorders can also be a contributing factor and should be considered in patients who present with MDI because surgical stabilization is less successful in patients with these disorders.²⁴

Clinical suspicion is essential for accurate identification of MDI given the variety of presenting complaints. Unidirectional instability is commonly associated with an identifiable anatomic lesion. Therefore, it is prudent to reconsider MDI in the patient with unidirectional instability in the absence of an anatomic lesion. MDI should also be suspected in young patients (aged <40 years) with a history of a failed instability procedure. The distinction should be made, however, between MDI (ie, symptomatic laxity in two or more directions) and unidirectional instability associated with multidirectional hyperlaxity.⁹

Each patient should be evaluated for voluntary instability. In general, patients with willful dislocation respond poorly to surgical stabilization. Issues of secondary gain or psychological conditions should be considered before proceeding with surgical intervention. Patients who demonstrate positions that reproduce their instability (ie, positional instability) but who attempt to avoid these positions generally respond well to surgical stabilization and should not be included in the subset of patients with willful dislocation.

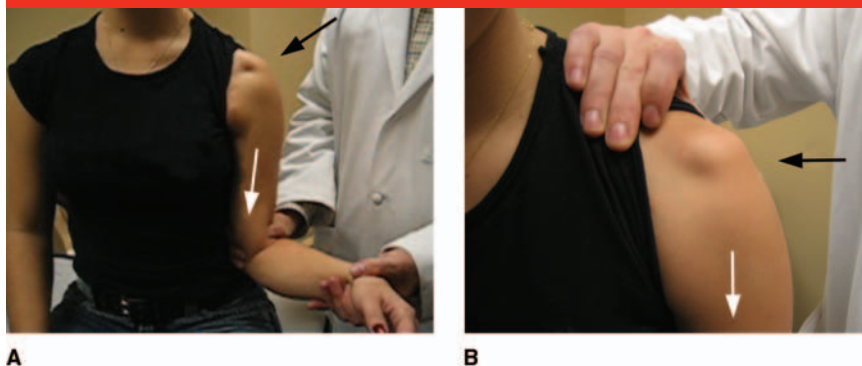
Physical Examination

An accurate physical examination is critical for adequate treatment of patients with MDI. Failure to address all components of instability may result in surgical failure. Asymmetry, atrophy, and previous incisions should be noted. Glenohumeral motion may be normal; however, many patients with MDI describe pain or apprehension with testing. In patients in whom shoulder pain is a primary complaint, a cervical spine evaluation should be performed to evaluate for referred pain syndrome.

Generalized hyperlaxity is also evaluated. Signs suggestive of generalized hyperlaxity include elbow or metacarpophalangeal joint hyperextension, genu recurvatum, patellar instability, and the ability to place the thumb on the ipsilateral forearm. The definition of hyperlaxity remains unclear, which may explain the broad range of its reported prevalence.^{7,25} Surgical stabilization is less successful in patients with connective tissue disorders (eg, Ehlers-Danlos syndrome).²⁴ Aside from these patients, prognostic value associated with the diagnosis of generalized hyperlaxity remains unclear.

The sulcus sign is a dimple that appears distal to the lateral acromion when inferior traction is applied to the arm (Figure 1). The test is performed with the arm in adduction, abduction, and both internal and external rotation. This measurement is subjective, but it is quantified as the distance between the humeral head and the acromion. Humeral head displacement >2 cm from the acromion is considered indicative of a high degree of glenohumeral laxity, but it is not considered abnormal unless the patient is symptomatic. The presence of the sulcus sign with 90° of abduction is indicative of considerable inferior capsular laxity.^{1,26}

Figure 1



Clinical photographs demonstrating sulcus testing of the left shoulder. **A**, Inferior traction (white arrow) is applied to the adducted arm in both neutral and external rotation (external rotation shown). The acromion (black arrow) is evaluated for dimpling. **B**, Dimpling is noted inferior to the acromion (black arrow) when axial traction (white arrow) is applied to the shoulder.

The load-and-shift test is also frequently used to evaluate glenohumeral translation. This test is performed with the patient supine and the shoulder at the edge of the examination table. The humeral head is centered in the glenoid by applying a small axial load. The proximal humerus is then translated to determine laxity. The test is graded in terms of the degree of translation: grade 1, translation to the glenoid rim; grade 2, dislocation with spontaneous reduction; and grade 3, dislocation without spontaneous reduction. This test may be repeated in various degrees of abduction to assess various components of the capsule. Serial examinations may be required because muscular guarding can alter findings. When symptoms are elicited, differences in the magnitude of glenohumeral translation in both shoulders should be noted.

The hyperabduction test developed by Gagey and Gagey²⁷ is useful for evaluating laxity of the inferior glenohumeral ligament. The test was performed in volunteers under anesthesia, and a mean passive range of glenohumeral abduction $\leq 90^\circ$ was reported. Laxity of the inferior glenohumeral ligament is indicated by

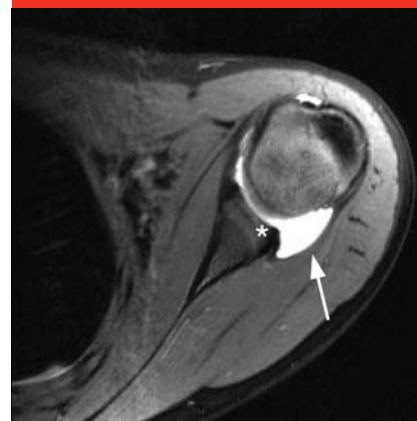passive abduction past 105° .²⁷ Although these tests are helpful, patterns of laxity are not equivalent to patterns of instability. Unidirectional antero-inferior instability is possible in a patient with multidirectional hyperlaxity, and this presentation should not be considered MDI.

Imaging

Diagnosis of MDI is primarily clinical, but imaging is helpful in some circumstances. Occasionally, standard radiographs reveal abnormal glenoid version, dysplasia, hypoplasia, or bone loss that may contribute to patterns of instability. A shallow glenoid concavity may be seen in patients with glenoid dysplasia, and humeral head injuries may also be identified with standard radiography. Reformatted CT can be used to further delineate abnormal findings.

MRI provides excellent detail of soft tissue and is frequently used to evaluate patients with shoulder instability. Magnetic resonance arthrography may be more useful than MRI because the capsule can be distended, thereby improving definition of the glenoid labrum, rotator inter-

Figure 2



Axial T2-weighted magnetic resonance image of the right shoulder demonstrating an enlarged posterior capsule (arrow) and loss of posterior labral height (asterisk) in a patient with multidirectional instability.

val, and glenohumeral ligaments. Structural lesions such as labral tears may also be present as a result of either repetitive microtrauma or macrotrauma. Frequently, a patulous capsule, increased glenohumeral volume, and labral abnormalities are seen in MDI patients²⁸ (Figure 2). These findings, however, are nonspecific and may not reflect actual instability. Some authors have described increased rotator interval dimensions in patients with chronic instability.²⁹ Others suggest that no significant difference in these measurements exists in patients with various patterns of instability compared with control groups.³⁰

Nonsurgical Management

Patients experience symptomatic instability when both static and dynamic restraints are insufficient to maintain glenohumeral stability. The goal of management is to rehabilitate or reconstruct deficient structures to restore stability and alleviate symptoms. For most MDI patients, rehabilitation remains the treatment of

choice at initial presentation. Evaluation and treatment of scapulohumeral dyskinesia is the primary focus of therapy. Improving the dynamic positioning of the glenoid and instituting a proprioceptive exercise program can improve the efficiency of dynamic glenohumeral stabilizers. Preferential strengthening of the rotator cuff may also improve concavity compression. The result is improved humeral head centering and more robust opposition to shear forces.

Motivated patients typically respond well to appropriate protocols, reporting diminished pain and improved stability. Reports suggest that rehabilitation results in substantially increased rotator cuff activation, which functionally reduces instability.³¹ Postoperative protocols appear to successfully restore normal muscle activation and motion patterns after capsular shift.^{31,32} Rehabilitation may improve glenohumeral stability; however, normal muscular activation and motion patterns cannot be restored without surgical intervention. A minimum 6-month trial of therapy should be devoted to improving stability; however, some authors suggest that longer periods may be required.³¹

Burkhead and Rockwood³³ demonstrated the efficacy of nonsurgical management in a study of 115 patients (140 shoulders) with traumatic or atraumatic shoulder instability. Good or excellent results were reported in 83% of patients with atraumatic instability treated with muscle-strengthening exercises. Good or excellent results were reported in 35 of 39 patients with MDI.³³ The authors also indicated that the etiology of instability was prognostic; only 12 of 74 shoulders (16%) with traumatic subluxation had good or excellent results with therapy. More recently, Misamore et al³⁴ reported less encouraging long-term results in patients who

were initially treated with rehabilitation. In a cohort of young, athletic patients, 19 of 36 experienced poor results, and only 8 were free of all pain and instability at a mean 8-year follow-up. This report indicates that athletic patients with MDI and those with instability associated with traumatic etiology may have a less favorable response to rehabilitation. Despite these findings, establishing a maintenance program is essential to maximize long-term outcomes in patients who respond favorably to rehabilitation.

Surgical Management

Surgical intervention should be considered in patients who continue to experience debilitating symptoms despite completion of an appropriate rehabilitation regimen. Surgical management should be individualized to address the anatomic cause of shoulder instability. Reconstructive techniques include glenoid osteotomy, labral augmentation, and capsuloligamentous reconstruction. Capsuloligamentous techniques, which include open inferior capsular shift, thermal capsulorrhaphy, and arthroscopic placcation, are most frequently used.

Open Inferior Capsular Repair

In 1980, Neer and Foster¹ described humeral-based inferior capsular shift for management of MDI. Typically, this technique is performed with the shoulder in 30° of abduction, forward flexion, and external rotation to minimize motion limitations. The subscapularis recess is routinely closed, and a T-shaped incision is made between the middle and inferior glenohumeral ligaments (Figure 3). Capsular flaps are carefully elevated from the neck of the humerus and are advanced to reduce posterior capsular redundancy and eliminate

the inferior capsular pouch. The subscapularis is then reattached separate and superficial to the reconstructed capsule. Management of MDI by eliminating capsular redundancy with subscapularis-sparing³ and glenoid-based⁴ techniques also has been described.

The magnitude of the capsular shift remains an important consideration in terms of maximizing glenohumeral stability and minimizing motion loss. Cadaver studies have demonstrated that capsular volume reduction is proportional to the magnitude of the capsular shift.³⁵ Neer and Foster¹ reported satisfactory results in 39 of 40 shoulders when inferior capsular laxity was eliminated.

Current criteria for successful outcomes in patients treated with open inferior capsular repair are much more stringent than those of Neer and Foster.¹ Surgical success is now measured in terms of persistent apprehension, recurrent subluxation, validated condition-specific outcome measures, and the patient's ability to return to a previous level of sport rather than recurrent dislocation. Using these measures of success, reported subjective clinical outcome scores and stability rates were approximately 95% in two studies that examined the efficacy of the Bankart and inferior capsular shift procedures for management of MDI.^{4,6} However, return to sport rates remain less than optimal. In a study of 40 patients with MDI treated with a modified Bankart procedure, Altchek et al⁴ reported that 33 of 40 patients (83%) returned to full sport. They also noted that all throwing athletes experienced decreased velocity at a mean of 3 years following inferior capsular shift repair. Recently, Pollock et al⁶ reported that only 25 of 36 athletes (69%) were able to return to premorbid levels of sporting activity following an inferior capsular shift procedure. These findings

Figure 3

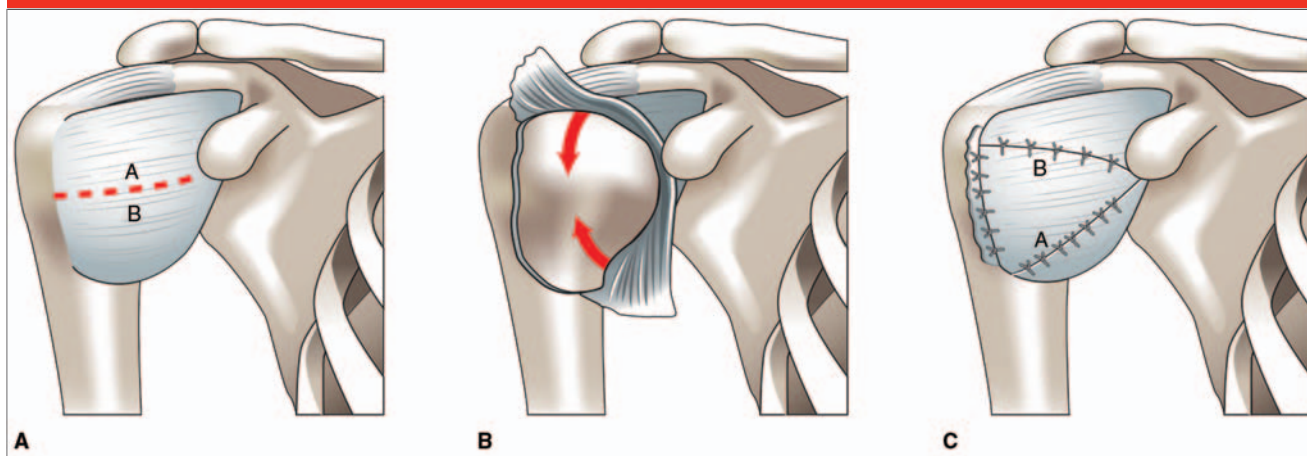


Illustration of the humeral-based capsular shift described by Neer and Foster.¹ **A**, The capsular incision is made between the middle and inferior glenohumeral ligaments, creating superior (A) and inferior (B) capsular leaflets. **B**, The capsular flaps are elevated and each flap is advanced in the appropriate direction (arrows). The inferior flap is shifted first. **C**, The inferior (A) and superior (B) flaps are then sutured.

emphasize the importance of counseling patient expectations.

Thermal Capsulorrhaphy

Thermal capsulorrhaphy was introduced as an alternative to the open capsular shift procedure. Thermal capsulorrhaphy was an attractive alternative because it could be performed quickly and easily and provided immediate visual feedback in terms of capsular shrinkage. However, chondrolysis, thermal nerve injury, and high failure rates have been reported.^{36,37} Hawkins et al³⁷ reported failure rates of approximately 60% in some patient populations. Given these findings, thermal capsulorrhaphy is not recommended for management of MDI.

Arthroscopic Capsular Plication

Advanced arthroscopic techniques have made arthroscopic management of MDI a viable, less invasive treatment option for patients who require soft-tissue repair. Advantages of arthroscopic techniques include decreased morbidity, visual confirmation of decreased capsular laxity, and

avoidance of subscapularis detachment. In addition, redundancy in the anteroinferior and posteroinferior capsule can be addressed using a single approach or by selectively addressing deficiencies in each capsular region. Abnormal posterior labral height can also contribute to instability in some patients with MDI.¹⁰ Insufficient posterior labral tissue results in relative glenoid retroversion and may decrease shear force resistance.¹⁰ In these circumstances, it is easier to identify and, if necessary, augment deficient labral structures arthroscopically.³⁸

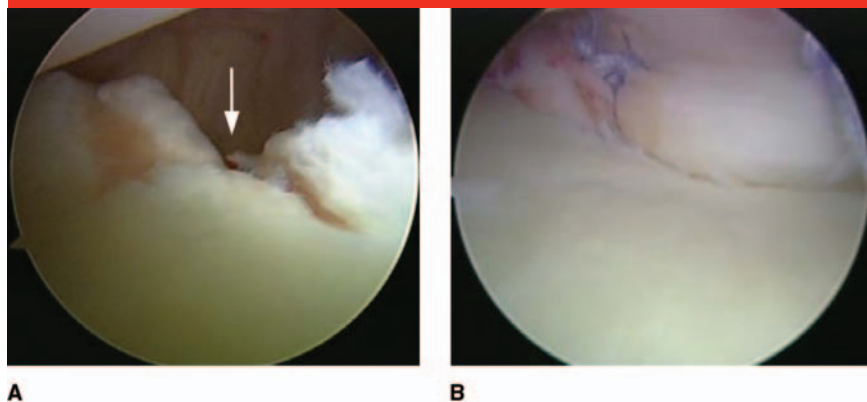
Arthroscopic capsular plication can be performed with the patient in the beach chair or lateral decubitus position. Before the procedure is begun, the direction and magnitude of glenohumeral translation, which was established preoperatively, are confirmed by examining the patient under anesthesia. The posterior portal is established more lateral than usual to provide access to the posterior glenoid rim and posteroinferior capsule. Diagnostic arthroscopy should be used to identify a patulous capsule and labral abnormalities. Af-

ter capsular abrasion, the repair sequence begins in the direction of primary instability to enhance healing (Figure 4). Each plication decreases capsular volume and the size of the working area. Consequently, it is important to proceed from inferior to superior, which facilitates visualization as the capsule is shifted superiorly.

A suture is passed through the capsular tissue and can be sutured directly to the labrum or a suture anchor can be used. These steps are repeated to complete the anterior, inferior, and posterior capsular shifts, as indicated (Figure 5). Authors of cadaver studies report that suturing capsular pleats directly to the labrum exhibits failure load similar to that of suture anchor fixation but is less rigid than suture anchor fixation.³⁹ Concerns regarding in vivo shear stress, suture tear through, and propagation may make anchor fixation preferable.

As with open inferior capsular shift techniques, arthroscopic capsular plication effectively reduces capsular volume and is dependent on plication magnitude.⁴⁰⁻⁴² In a cadaver

Figure 4



A, Posterior arthroscopic view of the left shoulder in a patient placed in the lateral decubitus position. An anterior labral periosteal sleeve avulsion lesion (arrow) healed medially but appears deficient. **B**, Arthroscopic image following labral mobilization, repair, and capsular shift.

model, Flanigan et al⁴³ demonstrated that 5- and 10-mm capsular plications resulted in a mean volume reduction of 16.2% and 33.7%, respectively. Multiple pleat techniques allow incremental volume reduction. In another cadaver study, multiple pleated anterior, inferior, and posterior capsular plications resulted in a significantly larger decrease in capsular volume compared with open inferior capsular shift ($P = 0.006$).⁴² These findings suggest that arthroscopic techniques may be as effective as open plication in decreasing capsular volume.

Capsular volume reduction is important only if it translates to improved clinical glenohumeral joint stability. Results of cadaver and clinical studies suggest that plication with capsulolabral augmentation improves stability by deepening the glenoid concavity and reducing capsular laxity.^{38,44} Gartsman et al¹⁵ reported on a series of 47 patients with MDI who were treated arthroscopically. A rotator interval closure was performed from the superior glenohumeral ligament to the middle glenohumeral ligament when abnormal laxity persisted after capsular shift. The authors reported that

94% of patients had good or excellent results based on Rowe criteria and showed significant improvement in American Shoulder and Elbow Surgeons Shoulder Index, Constant, and University of California Los Angeles shoulder scores ($P = 0.001$). Importantly, 22 of 26 patients (85%) returned to their desired sporting level postoperatively. Recently, Baker et al¹⁶ reported similar American Shoulder and Elbow Surgeons Shoulder Index scores and 31 of 36 patients (86%) were able to return to sport with little or no limitation. Recent evidence suggests that return to sport rates may be superior in properly selected patients who undergo arthroscopic treatment of MDI.^{15,16,23}

Capsular plication is capable of restoring glenohumeral stability in patients with MDI. However, overly aggressive plications can result in glenohumeral motion loss, particularly in external rotation.⁴⁵⁻⁴⁷ Thus, establishing the appropriate magnitude of plication is critical to the success of this procedure. This remains a subjective determination and is individualized to each patient. In general, subluxation of the proximal humerus over the glenoid rim should not be possible after capsular plica-

tion is complete. In addition, compared with the contralateral side, motion should not be markedly limited.

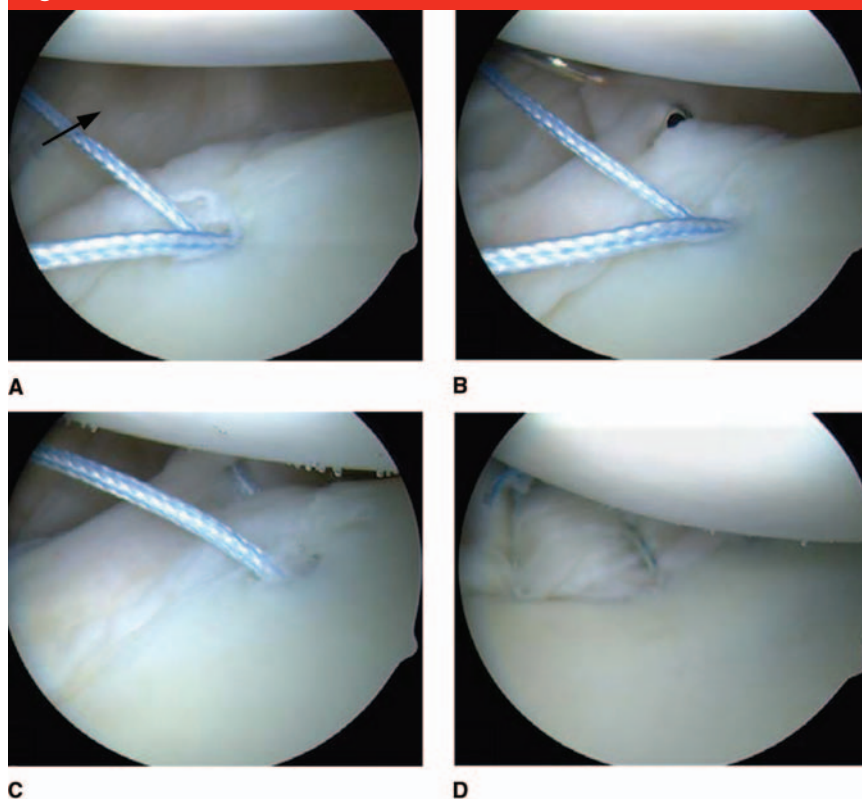
Axillary Nerve Injury

The course of the axillary nerve is in close proximity to the inferior glenohumeral pouch, and injury to this nerve has been reported after open, thermal, and arthroscopic procedures. An open approach facilitates direct identification and protection of the axillary nerve. However, the nerve is typically not visualized arthroscopically; consequently, thorough knowledge of the zones at risk of injury is required. Typically, the teres minor branch is most at risk, representing the portion of the nerve closest to the glenoid rim.⁴⁸ With the patient in the standard lateral decubitus position, this branch is a mean 12.4 mm from the glenoid in the 6 o'clock position.⁴⁸ It passes a mean of 2.5 mm deep to the capsule before emerging from the quadrangular space. However, the proximity of the teres minor branch to the capsule varies by patient and positioning. In a cadaver study of the relationship of the axillary nerve to the capsule, it was suggested that abduction, external rotation, and slight traction results in the largest margin between the axillary nerve and capsule.⁴⁹ Therefore, proper positioning and an understanding of this relationship are useful in avoiding axillary nerve complications.

Rotator Interval Closure

Neer and Foster¹ described closure of the subscapularis recess as a routine part of the inferior capsular shift. Many continue to advocate the use of rotator interval closure; however, its biomechanical role in glenohumeral stability remains controversial.

Figure 5



Anterosuperior arthroscopic view of the left shoulder in a patient with multidirectional instability who was placed in the lateral decubitus position. **A**, A suture is passed through the capsular tissue, and an anchor is placed along the capsular rim. Note the patulous posterior capsule (arrow). **B**, Capsular tuck is achieved using a suture shuttling device. **C**, Posterior capsule after passage of plication stitch. This pinch-tuck technique provides a greater degree of capsular plication by forming a pleat of tissue when tensioned. **D**, Capsular plication is completed using three anchors. Note the decrease in capsular redundancy compared with panel A.

The work of Harryman et al¹² is at the forefront of this debate; they reported a decrease in posterior and inferior translation with open medial-lateral coracohumeral ligament imbrication. These findings are frequently cited to justify arthroscopic rotator interval closure despite fundamental differences in open and arthroscopic techniques. To date, traditional superior-inferior arthroscopic interval capsular closure techniques have failed to replicate these findings, however.^{45,50,51} Using a cadaveric MDI model, Farber et al⁴⁶ recently compared a superior-inferior closure with ar-

throscopic medial-lateral rotator interval closure. The medial-lateral closure resulted in better restoration of motion to the intact state than did the superior-inferior closure, and it improved posterior stability. However, the authors were unable to reproduce all of the findings of Harryman et al¹² using a similar closure orientation.

Clinically, satisfactory results have been obtained both with and without routine rotator interval closure.^{15,52} No clear clinical evidence exists to prove that any rotator interval closure technique adds stability to a shoulder with MDI. However, bio-

mechanical data suggest that this closure may be indicated in MDI patients when laxity is not sufficiently reduced despite adequate capsular plication. Two studies used a human cadaver model to assess the use of arthroscopic superior glenohumeral ligament to middle glenohumeral ligament rotator interval closures and reported a decrease in anterior glenohumeral translation.^{45,50} The ability to decrease posterior or inferior glenohumeral translation with this closure is less well established. The benefit of a rotator interval closure should be weighed against its clinically and biomechanically described potential to limit external rotation. Tensioning the closure in 30° of external rotation should minimize motion limitations.⁵³

Postoperative Rehabilitation

Rehabilitation protocols following open or arthroscopic techniques are similar. Each protocol should be individualized and based on the direction of primary instability and the robustness of the repair. The shoulder is placed in approximately neutral rotation for 4 to 6 weeks using an immobilizer with an abduction pillow. We do not routinely alter the position of immobilization based on the direction of primary instability. In our experience, patients with MDI rarely have difficulty regaining motion. Therefore, we individualize the immobilization period based on the postoperative clinical evaluation. In this population, we prefer to immobilize the shoulder for at least 4 to 6 weeks. Therapy should be initiated if the shoulder becomes stiff. If the glenohumeral joint remains supple, longer periods of immobilization are used. Patients are instructed to perform improvised elbow, wrist, and hand motions.

After the immobilizer is discontin-

ued, patients begin strengthening exercises similar to those of nonsurgical protocols that target shoulder musculature. Patients are allowed to return to full activity approximately 6 months postoperatively if they demonstrate full strength and have completed a sport-specific training program.

Summary

Considerable advances have been made in the diagnosis and management of MDI since its seminal description. However, the lack of pathognomonic, clinical, or radiographic findings makes diagnosis and treatment challenging. Rehabilitation of dynamic stabilizers is the goal of initial nonsurgical management, but if these efforts fail, surgical options can be used. Satisfactory surgical outcomes have been achieved with open and arthroscopic techniques; however, given the persistent discrepancy between the reported surgical outcomes of unidirectional instability and MDI, continued research is warranted. Favorable results can be reliably obtained with careful examination and diagnosis, meticulous surgical technique, and thorough rehabilitation.

References

Evidence-based Medicine: Levels of evidence are described in the table of contents. In this article, references 10, 11, 19, 20, 22, 23, and 30-33 are level III studies. References 1, 3, 4, 6-8, 15, 16, 24, 27-29, 34, 35, and 37-39 are level IV studies. References 2, 5, 9, 25, and 54 are level V expert opinion.

References printed in **bold type** are those published within the past 5 years.

1. Neer CS II, Foster CR: Inferior capsular shift for involuntary inferior and multidirectional instability of the shoulder: A preliminary report. *J Bone*

- Joint Surg Am* 1980;62(6):897-908.
2. McFarland EG, Kim TK, Park HB, Neira CA, Gutierrez MI: The effect of variation in definition on the diagnosis of multidirectional instability of the shoulder. *J Bone Joint Surg Am* 2003;85(11):2138-2144.
3. Bak K, Spring BJ, Henderson JP: Inferior capsular shift procedure in athletes with multidirectional instability based on isolated capsular and ligamentous redundancy. *Am J Sports Med* 2000;28(4):466-471.
4. Altchek DW, Warren RF, Skyhar MJ, Ortiz G: T-plasty modification of the Bankart procedure for multidirectional instability of the anterior and inferior types. *J Bone Joint Surg Am* 1991;73(1):105-112.
5. Neer CS II: Involuntary inferior and multidirectional instability of the shoulder: Etiology, recognition, and treatment. *Instr Course Lect* 1985;34:232-238.
6. Pollock RG, Owens JM, Flatow EL, Bigliani LU: Operative results of the inferior capsular shift procedure for multidirectional instability of the shoulder. *J Bone Joint Surg Am* 2000;82(7):919-928.
7. Cooper RA, Brems JJ: The inferior capsular-shift procedure for multidirectional instability of the shoulder. *J Bone Joint Surg Am* 1992;74(10):1516-1521.
8. **Alpert JM, Verma N, Wysocki R, Yanke AB, Romeo AA: Arthroscopic treatment of multidirectional shoulder instability with minimum 270 degrees labral repair: Minimum 2-year follow-up. *Arthroscopy* 2008;24(6):704-711.**
9. Gerber C, Nyffeler RW: Classification of glenohumeral joint instability. *Clin Orthop Relat Res* 2002;(400):65-76.
10. Kim SH, Noh KC, Park JS, Ryu BD, Oh I: Loss of chondrolabral containment of the glenohumeral joint in atraumatic posteroinferior multidirectional instability. *J Bone Joint Surg Am* 2005;87(1):92-98.
11. **von Eisenhart-Rothe R, Mayr HO, Hinterwimmer S, Graichen H: Simultaneous 3D assessment of glenohumeral shape, humeral head centering, and scapular positioning in atraumatic shoulder instability: A magnetic resonance-based in vivo analysis. *Am J Sports Med* 2010;38(2):375-382.**
12. Harryman DT II, Sidles JA, Harris SL, Matsen FA III: The role of the rotator interval capsule in passive motion and stability of the shoulder. *J Bone Joint Surg Am* 1992;74(1):53-66.
13. Turkel SJ, Panio MW, Marshall JL, Girgis FG: Stabilizing mechanisms preventing anterior dislocation of the glenohumeral joint. *J Bone Joint Surg Am* 1981;63(8):1208-1217.
14. Speer KP, Deng X, Borrero S, Torzilli PA, Altchek DA, Warren RF: Biomechanical evaluation of a simulated Bankart lesion. *J Bone Joint Surg Am* 1994;76(12):1819-1826.
15. Gartsman GM, Roddey TS, Hammerman SM: Arthroscopic treatment of multidirectional glenohumeral instability: 2- to 5-year follow-up. *Arthroscopy* 2001;17(3):236-243.
16. **Baker CL III, Mascarenhas R, Kline AJ, Chhabra A, Pombo MW, Bradley JP: Arthroscopic treatment of multidirectional shoulder instability in athletes: A retrospective analysis of 2- to 5-year clinical outcomes. *Am J Sports Med* 2009;37(9):1712-1720.**
17. **Ogston JB, Ludewig PM: Differences in 3-dimensional shoulder kinematics between persons with multidirectional instability and asymptomatic controls. *Am J Sports Med* 2007;35(8):1361-1370.**
18. Lippitt SB, Vanderhooft JE, Harris SL, Sidles JA, Harryman DT II, Matsen FA III: Glenohumeral stability from concavity-compression: A quantitative analysis. *J Shoulder Elbow Surg* 1993;2(1):27-35.
19. Barden JM, Balyk R, Raso VJ, Moreau M, Bagnall K: Atypical shoulder muscle activation in multidirectional instability. *Clin Neurophysiol* 2005;116(8):1846-1857.
20. Barden JM, Balyk R, Raso VJ, Moreau M, Bagnall K: Dynamic upper limb proprioception in multidirectional shoulder instability. *Clin Orthop Relat Res* 2004;(420):181-189.
21. Inui H, Sugamoto K, Miyamoto T, et al: Three-dimensional relationship of the glenohumeral joint in the elevated position in shoulders with multidirectional instability. *J Shoulder Elbow Surg* 2002;11(5):510-515.
22. Lippitt SB, Harris SL, Harryman DT II, Sidles J, Matsen FA III: In vivo quantification of the laxity of normal and unstable glenohumeral joints. *J Shoulder Elbow Surg* 1994;3(4):215-223.
23. **Yeagan SA III, Briggs KK, Horan MP, Black AK, Hawkins RJ: Determinants of patient satisfaction following surgery for multidirectional instability. *Orthopedics* 2008;31(7):647.**
24. Jerosch J, Castro WH: Shoulder instability in Ehlers-Danlos syndrome: An indication for surgical treatment? *Acta Orthop Belg* 1990;56(2):451-453.
25. Arendt EA: Multidirectional shoulder

- instability. *Orthopedics* 1988;11(1):113-120.
26. Warner JJ, Deng XH, Warren RF, Torzilli PA: Static capsuloligamentous restraints to superior-inferior translation of the glenohumeral joint. *Am J Sports Med* 1992;20(6):675-685.
 27. Gagey OJ, Gagey N: The hyperabduction test. *J Bone Joint Surg Br* 2001;83(1):69-74.
 28. Dewing CB, McCormick F, Bell SJ, et al: An analysis of capsular area in patients with anterior, posterior, and multidirectional shoulder instability. *Am J Sports Med* 2008;36(3):515-522.
 29. Kim KC, Rhee KJ, Shin HD, Kim YM: Estimating the dimensions of the rotator interval with use of magnetic resonance arthrography. *J Bone Joint Surg Am* 2007;89(11):2450-2455.
 30. Provencher MT, Dewing CB, Bell SJ, et al: An analysis of the rotator interval in patients with anterior, posterior, and multidirectional shoulder instability. *Arthroscopy* 2008;24(8):921-929.
 31. Illyés A, Kiss J, Kiss RM: Electromyographic analysis during pull, forward punch, elevation and overhead throw after conservative treatment or capsular shift at patient with multidirectional shoulder joint instability. *J Electromyogr Kinesiol* 2009;19(6):e438-e447.
 32. Kiss RM, Illyés A, Kiss J: Physiotherapy vs. capsular shift and physiotherapy in multidirectional shoulder joint instability. *J Electromyogr Kinesiol* 2010;20(3):489-501.
 33. Burkhead WZ Jr, Rockwood CA Jr: Treatment of instability of the shoulder with an exercise program. *J Bone Joint Surg Am* 1992;74(6):890-896.
 34. Misamore GW, Sallay PI, Didelot W: A longitudinal study of patients with multidirectional instability of the shoulder with seven- to ten-year follow-up. *J Shoulder Elbow Surg* 2005;14(5):466-470.
 35. Wiater JM, Vibert BT: Glenohumeral joint volume reduction with progressive release and shifting of the inferior shoulder capsule. *J Shoulder Elbow Surg* 2007;16(6):810-814.
 36. D'Alessandro DF, Bradley JP, Fleischli JE, Connor PM: Prospective evaluation of thermal capsulorrhaphy for shoulder instability: Indications and results, two- to five-year follow-up. *Am J Sports Med* 2004;32(1):21-33.
 37. Hawkins RJ, Krishnan SG, Karas SG, Noonan TJ, Horan MP: Electrothermal arthroscopic shoulder capsulorrhaphy: A minimum 2-year follow-up. *Am J Sports Med* 2007;35(9):1484-1488.
 38. Kim SH, Kim HK, Sun JI, Park JS, Oh I: Arthroscopic capsulolabroplasty for posteroinferior multidirectional instability of the shoulder. *Am J Sports Med* 2004;32(3):594-607.
 39. Provencher MT, Verma N, Obopilwe E, et al: A biomechanical analysis of capsular plication versus anchor repair of the shoulder: Can the labrum be used as a suture anchor? *Arthroscopy* 2008;24(2):210-216.
 40. Cohen SB, Wiley W, Goradia VK, Pearson S, Miller MD: Anterior capsulorrhaphy: An in vitro comparison of volume reduction—arthroscopic plication versus open capsular shift. *Arthroscopy* 2005;21(6):659-664.
 41. Karas SG, Creighton RA, DeMorat GJ: Glenohumeral volume reduction in arthroscopic shoulder reconstruction: A cadaveric analysis of suture plication and thermal capsulorrhaphy. *Arthroscopy* 2004;20(2):179-184.
 42. Sekiya JK, Willobee JA, Miller MD, Hickman AJ, Willobee A: Arthroscopic multi-pleated capsular plication compared with open inferior capsular shift for reduction of shoulder volume in a cadaveric model. *Arthroscopy* 2007;23(11):1145-1151.
 43. Flanigan DC, Forsythe T, Orwin J, Kaplan L: Volume analysis of arthroscopic capsular shift. *Arthroscopy* 2006;22(5):528-533.
 44. Metcalf MH, Pon JD, Harryman DT II, Loutzenheiser T, Sidles JA: Capsulolabral augmentation increases glenohumeral stability in the cadaver shoulder. *J Shoulder Elbow Surg* 2001;10(6):532-538.
 45. Provencher MT, Mologne TS, Hongo M, Zhao K, Tasto JP, An KN: Arthroscopic versus open rotator interval closure: Biomechanical evaluation of stability and motion. *Arthroscopy* 2007;23(6):583-592.
 46. Farber AJ, ElAttrache NS, Tibone JE, McGarry MH, Lee TQ: Biomechanical analysis comparing a traditional superior-inferior arthroscopic rotator interval closure with a novel medial-lateral technique in a cadaveric multidirectional instability model. *Am J Sports Med* 2009;37(6):1178-1185.
 47. Plausinis D, Bravman JT, Heywood C, Kummer FJ, Kwon YW, Jazrawi LM: Arthroscopic rotator interval closure: Effect of sutures on glenohumeral motion and anterior-posterior translation. *Am J Sports Med* 2006;34(10):1656-1661.
 48. Price MR, Tillett ED, Acland RD, Nettleton GS: Determining the relationship of the axillary nerve to the shoulder joint capsule from an arthroscopic perspective. *J Bone Joint Surg Am* 2004;86(10):2135-2142.
 49. Uno A, Bain GI, Mehta JA: Arthroscopic relationship of the axillary nerve to the shoulder joint capsule: An anatomic study. *J Shoulder Elbow Surg* 1999;8(3):226-230.
 50. Mologne TS, Zhao K, Hongo M, Romeo AA, An KN, Provencher MT: The addition of rotator interval closure after arthroscopic repair of either anterior or posterior shoulder instability: Effect on glenohumeral translation and range of motion. *Am J Sports Med* 2008;36(6):1123-1131.
 51. Van der Reis W, Wolf EM: Arthroscopic rotator cuff interval capsular closure. *Orthopedics* 2001;24(7):657-661.
 52. Kim SH, Ha KI, Yoo JC, Noh KC: Kim's lesion: An incomplete and concealed avulsion of the posteroinferior labrum in posterior or multidirectional posteroinferior instability of the shoulder. *Arthroscopy* 2004;20(7):712-720.
 53. Gartsman GM, Taverna E, Hammerman SM: Arthroscopic rotator interval repair in glenohumeral instability: Description of an operative technique. *Arthroscopy* 1999;15(3):330-332.