

## Disorders of the Paranasal Sinuses

Henry Tremaine and David E Freeman

### Introduction

Inflammation of the equine paranasal sinuses is a relatively uncommon disease that may be caused by primary bacterial or mycotic infections (Mason 1975a), or can be secondary to dental disease (van der Velden & Verzijlberg 1984, Scott 1987, Tremaine & Dixon 2001a), facial trauma, sinus cysts, progressive ethmoid hematoma or sinonasal neoplasia (Mansmann & Wheat 1973, Gibbs & Lane 1987, Tremaine & Dixon 2001a). Equine sinusitis is usually unilateral but bilateral disease has been reported (Coumbe et al 1987, Lane 1993, Tremaine & Dixon 2001a). There is apparently no breed, age or gender predisposition to sinusitis. Clinical signs of any type of sinusitis usually include unilateral purulent nasal discharge, ipsilateral submandibular lymph node enlargement, and epiphora. Less common signs include facial swelling, exophthalmos, abnormal respiratory noises, head shaking, and exercise intolerance (Lane 1993, Tremaine & Dixon 2001a).

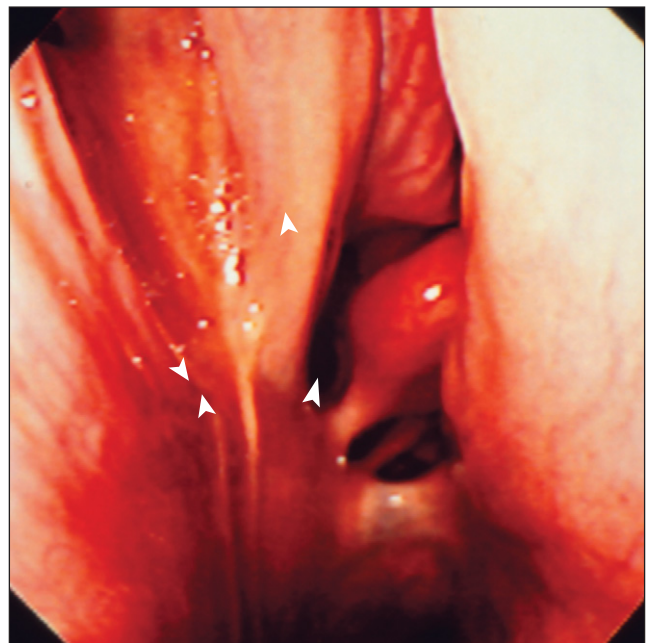
### Primary Sinus Empyema (Primary Sinusitis)

Primary sinusitis is the result of obstruction of the normal nasomaxillary drainage with resulting accumulation of mucus in the sinus, which later becomes infected. Some cases occur following upper respiratory tract infections that cause inflammation, increase mucus production within the sinuses, and decrease drainage of secretions from the sinuses into the nasal cavity via the anatomically narrow nasomaxillary ostia. The nasal discharge in primary sinusitis is traditionally stated to be purulent and odorless (Mason 1975a), but malodorous nasal discharges can occur with primary sinusitis (Tremaine & Dixon 2001a), especially in association with inspissation of purulent material in the ventral conchal sinuses (Schumacher et al 1987).

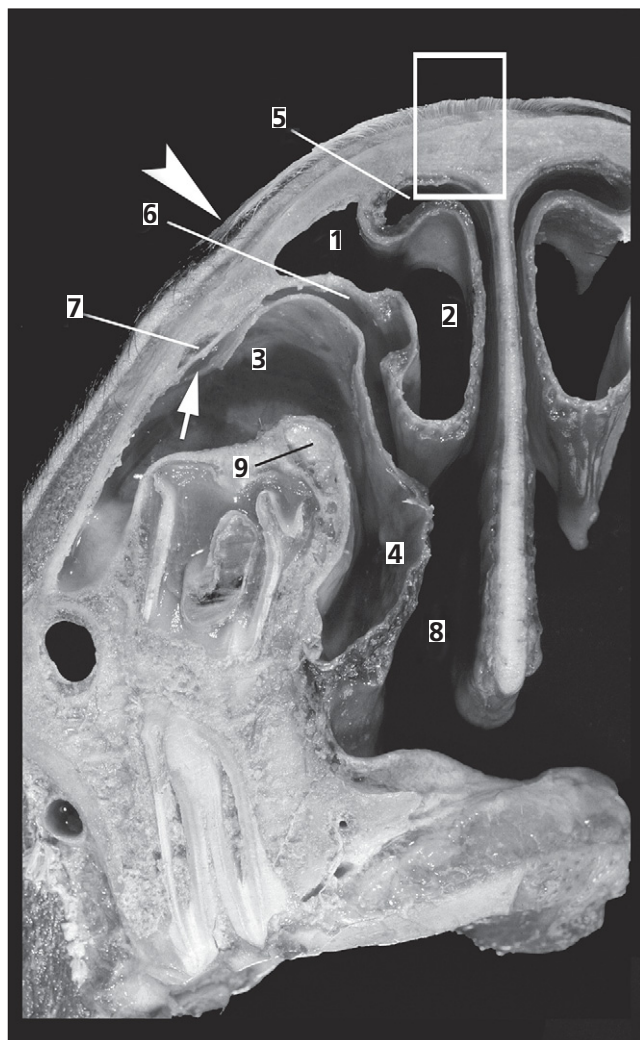
Culture of exudates from primary sinusitis cases often yields a mixed bacterial growth that is of unclear etiologic significance. Isolated bacteria include *Streptococcus equi* var. *zoepidemicus* (Schumacher et al 1987, Ruggles et al 1993), *Corynebacterium* spp., (Schumacher & Crossland 1994), *Staphylococcus* spp. (Mason 1975a, Schumacher et al 1987, Tremaine & Dixon 2001a), *Pseudomonas aerugi-*

*nosa*, *Bacteroides* spp., *Peptostreptococcus* spp. (Ruggles et al 1993, Tremaine & Dixon 2001a), *Streptococcus equi* var. *equi* (Mansmann & Wheat 1973), and *Escherichia coli* (Mason 1975a, Schumacher et al 1987), although as noted, the etiologic importance of these isolates is often unclear.

Nasal endoscopy of horses with sinusitis usually reveals purulent exudate in the caudal nasal cavity draining from the nasomaxillary ostia of the rostral and/or caudal maxillary sinuses (“drainage angle”) (Fig. 26.1). Marked accumulation of exudate in the ventral conchal sinus can result in swelling of the ventral concha, which may eventually prevent passage of the endoscope up the affected nasal cavity. Displacement of the nasal septum can occur in cases with gross distension of this sinus. Straight lateral radiographs of horses with primary sinusitis frequently reveal multiple fluid lines in some of the paranasal sinuses. Oblique radiographs are necessary to separate the left and right rows of maxillary cheek teeth for radiographic



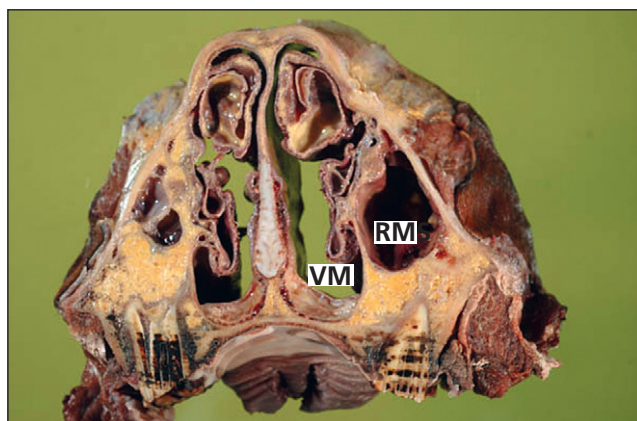
**Fig. 26.1.** Endoscopic view of the caudal aspect of the middle meatus (“drainage angle”) in a horse with sinusitis down which purulent exudate from the maxillary sinuses is draining through the nasomaxillary ostia (arrowheads).



**Fig. 26.2.** Front view of a transverse section of the right paranasal sinuses and nasal passage through tooth 109 at the level of the most rostral end of a frontonasal bone flap. 1 = frontal sinus; 2 = dorsal conchal sinus; 3 = rostral maxillary sinus; 4 = ventral conchal sinus; 5 = dorsal meatus; 6 = middle meatus; 7 = nasolacrimal duct; 8 = ventral meatus; 9 = infraorbital nerve in the infraorbital canal. Arrow points to opening from the rostral maxillary sinus into the middle meatus. Rectangle is the point of fracture for a frontonasal bone flap and includes the point of separation from the underlying reflection of the dorsal nasal concha. The arrowhead is the lateral edge of the bone flap. Note the reserve dental crown occupies a large portion of the sinus cavities in this young horse and along with the infraorbital canal limits access to the sinuses.

examination of the dental apical areas. Dorsoventral radiographs are particularly useful for demonstrating distension of, and exudate within, the ventral conchal sinus (see Chapter 10).

Acute cases of primary sinusitis may spontaneously resolve or may respond to antimicrobial drug administration, with the organisms commonly isolated frequently being sensitive to penicillin. Chronic cases of primary

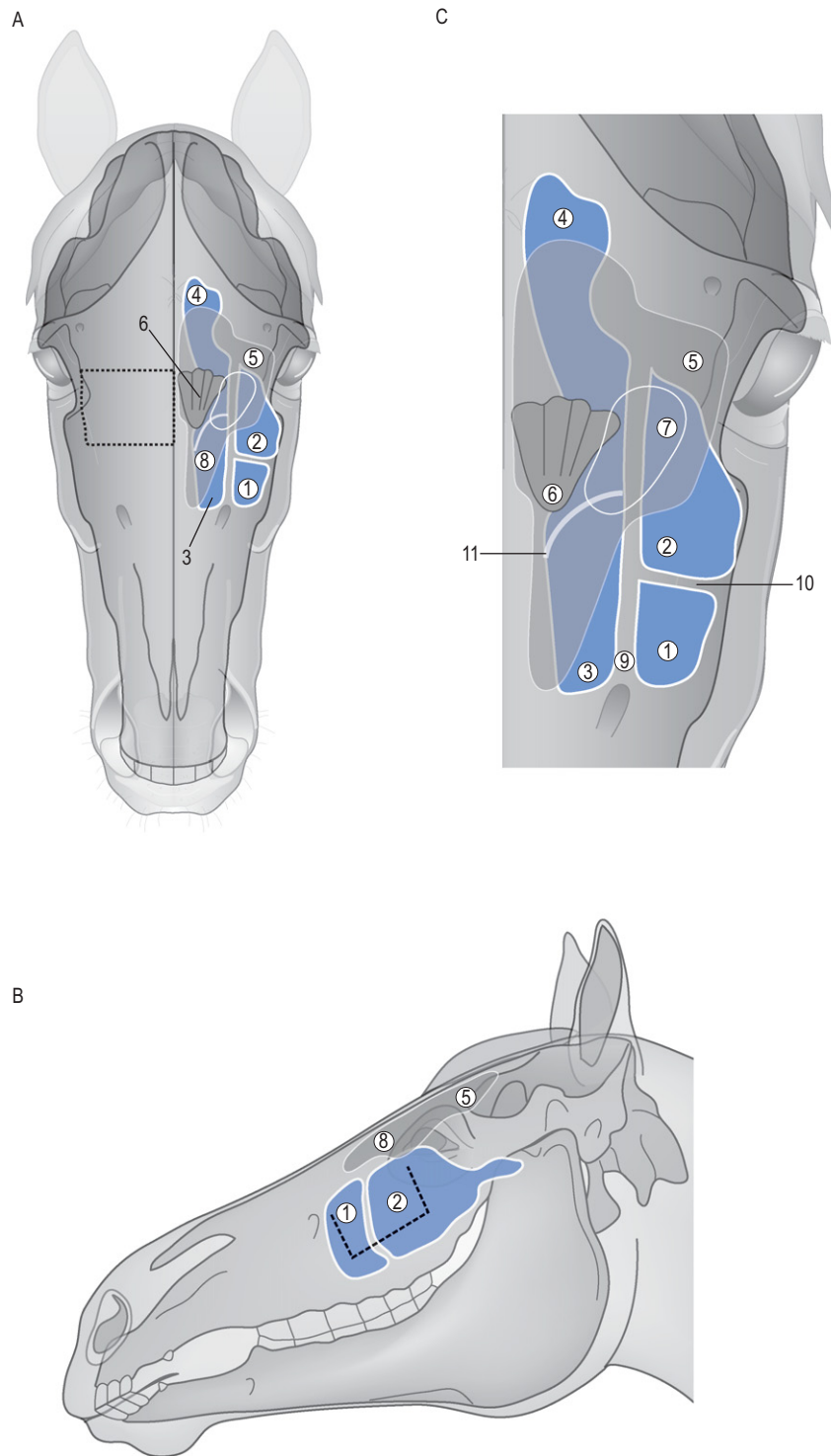


**Fig. 26.3.** Transverse section of the skull of an aged horse at the level of the fourth cheek tooth (109, 209) showing the voluminous rostral maxillary sinus (RMS) and the ventral nasal meatus (VM).

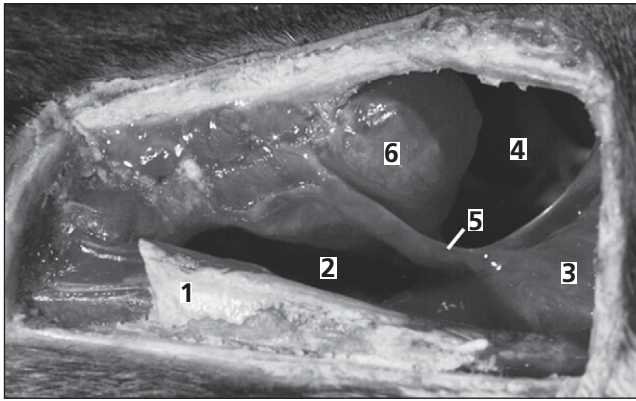
sinusitis (of > 2 months duration) frequently have gross thickening of the sinus mucosa, which can further restrict normal nasomaxillary drainage and such cases may only show a transient improvement to antibiotic treatment (Tremaine & Dixon 2001a). Treatment by sinus irrigation may be performed in these cases, via a sutured irrigation tube or Foley catheter placed via a trephine opening into the frontal or caudal maxillary sinuses (for lavage of the frontal and caudal maxillary sinuses), or into the rostral maxillary sinus (for lavage of the rostral maxillary and ventral conchal sinuses). Such cases may respond to lavage with 5–10 liters of water, saline or dilute disinfectants such as 0.05% povidine-iodine solution, once to twice daily for 5–10 days.

Cases with gross thickening of the sinus mucosa, and in particular cases with accumulations of inspissated pus in the sinus, may require surgical debridement and possibly sinonasal fistulation to improve drainage. An outline of sinus anatomy and surgical approaches is presented in Figs 26.2–26.4. The frontal, maxillary, and ventral conchal sinus are all most easily approached via a large nasofrontal bone-flap osteotomy (Freeman et al 1990) (Figs 26.4 and 26.5) where the bone is preserved or a smaller osteotomy where the bone is discarded (Figs 26.6–26.9). Even when radiographs or computed tomographic images demonstrate that the inflammation mainly involves the maxillary sinuses, a frontonasal flap is the preferred approach for a number of reasons (Freeman et al 1990). When the lesion is in the maxillary sinus, the frontal approach is far enough from it to allow creation of the flap without disturbing the lesion (e.g. sinus cyst), and yet close enough to allow its easy removal. It also provides a sufficiently clear view of the sinus interior to allow complete examination.

The incisions necessary for this type of flap do not involve muscles or large blood vessels, and the size and position of the flap can be designed to suit the lesion, even



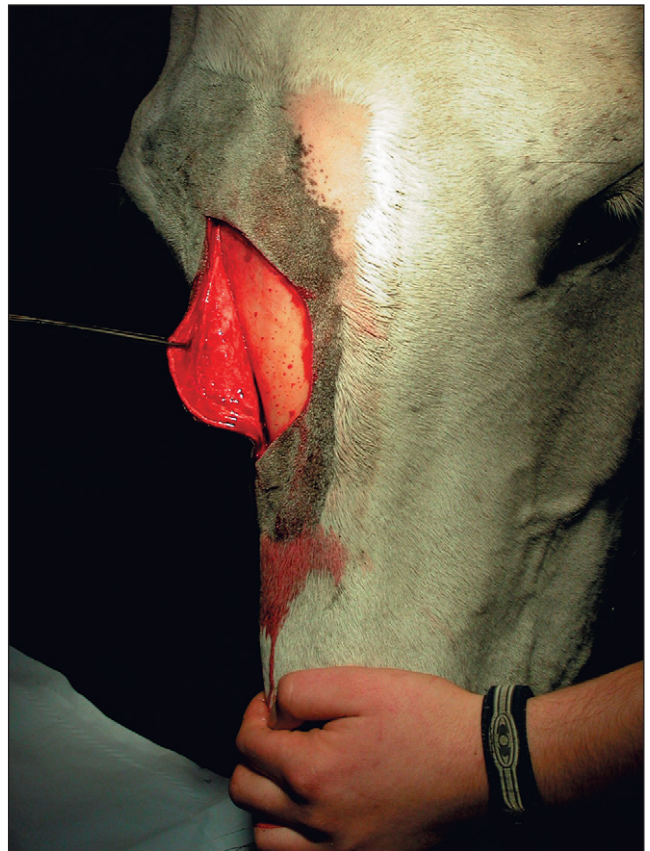**Fig. 26.4.** Approaches to the sinuses through a frontonasal bone flap (broken line in A) and maxillary bone flap (broken line in B), and (C) expanded dorsal view of sinuses. 1 = rostral maxillary sinus; 2 = caudal maxillary sinus; 3 = ventral conchal sinus; 4 = sphenopalatine sinus; 5 = frontal sinus; 6 = ethmoidal labyrinth; 7 = frontomaxillary opening; 8 = dorsal conchal sinus (5 and 8 combine to form the conchofrontal sinus); 9 = infraorbital canal; 10 = bony maxillary septum; 11 = caudal bulla of ventral conchal sinus. Reproduced from Freeman 2003, with permission.



**Fig. 26.5.** Interior of the right conchofrontal sinus as viewed through a frontonasal bone flap in a cadaver specimen. For demonstration purposes, the entire flap has been removed. The rostral part of the head is to the left and the lateral margin is uppermost. 1 = reflection of dorsal nasal concha which has retained some of the bony attachment to the underside of the flap; 2 = dorsal conchal sinus; 3 = ethmoid labyrinth; 4 = caudal maxillary sinus; 5 = medial edge of the frontomaxillary opening; 6 = caudal bulla of the ventral conchal sinus. Reproduced from Freeman et al 1990, with permission.

allowing access to the nasal passage if necessary (Freeman et al 1990). If the bone flap is constructed so that it is hinged on the dorsal midline, it will lie out of the surgeon's way when fully opened. The frontonasal flap can also be used for repulsion of cheek teeth, but access to 109 and 209 (the fourth maxillary cheek teeth) is limited using this approach. Alternatively, a caudal maxillary osteotomy may be used in older (>10 years) horses (Fig. 26.10), but the reserve crowns of the maxillary cheek teeth limit the access to the sinuses via this approach in younger animals. A maxillary approach to the rostral maxillary sinus gives even more restricted access to the sinus lumen because of the position of the reserve crowns of the third and fourth maxillary cheek teeth (Triadan 08s and 09s).

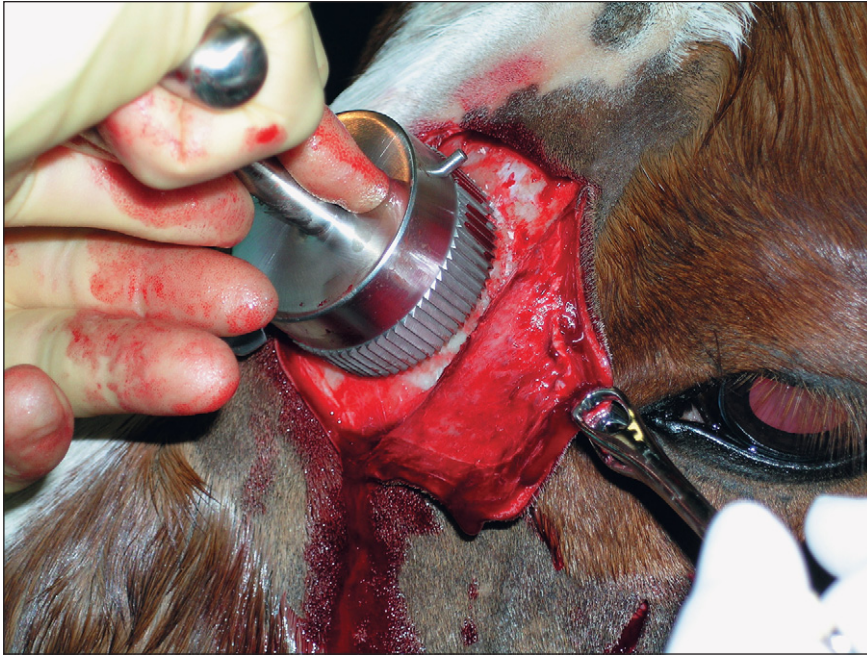Bone flap osteotomies may be created under general anesthesia or in the standing sedated horse (Scrutchfield et al 1994, Quinn et al 2004). After making a rectangular or curved incision through the skin and periosteum, the bone flap is created with an oscillating saw, chisel or Gigli wire; the larger, three-sided bone flap may then be hinged back on its (fourth) uncut side, to fracture the bone, whilst retaining the flap's intact skin, subcutaneous tissue and periosteal attachments. Alternatively, an axial-based curvilinear incision may be made and the skin and periosteum can be reflected. The osteotomy can be created using a 5-cm diameter trephine with the disc of bone being discarded (Figs 26.6–26.8). The skin and periosteum are closed over the osteotomy ensuring that a 5–10-mm shelf of bone is present peripheral to the osteotomy on which the periosteum can be laid, to help prevent dehiscence. Although sequestration of the flap has been cited as a risk



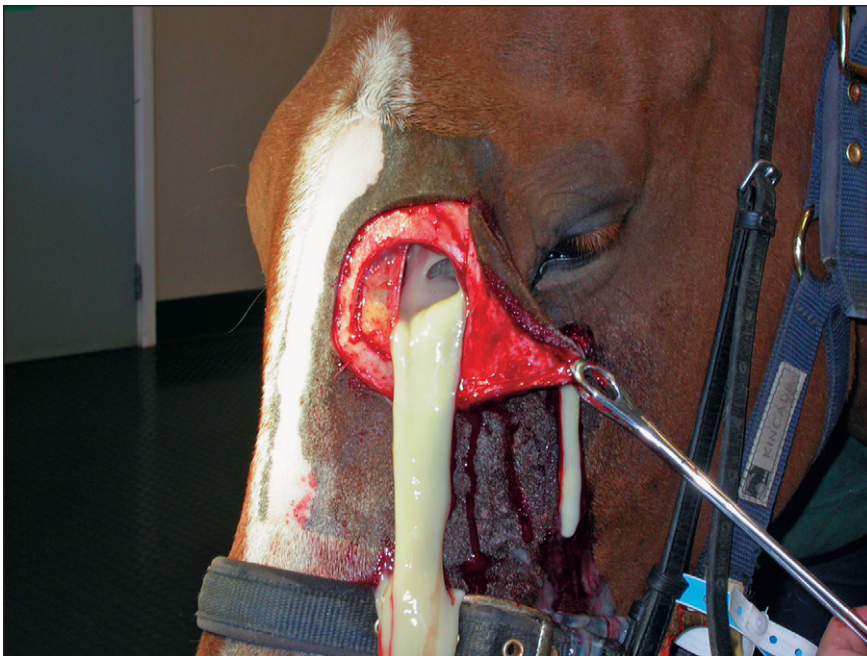**Fig. 26.6.** A curvilinear incision has been made through the skin and periosteum which have then been reflected back, to enable a right-sided nasofrontal bone osteotomy to be made in a standing sedated horse.

of retention of sinus osteotomy flaps, published reports do not confirm this to be a frequent occurrence, especially with larger flaps. Alternatively, despite the loss of a 5-cm disc of bone, albeit over a flat surface, the cosmetic results after discarding the flap are usually acceptable (Quinn et al 2004).

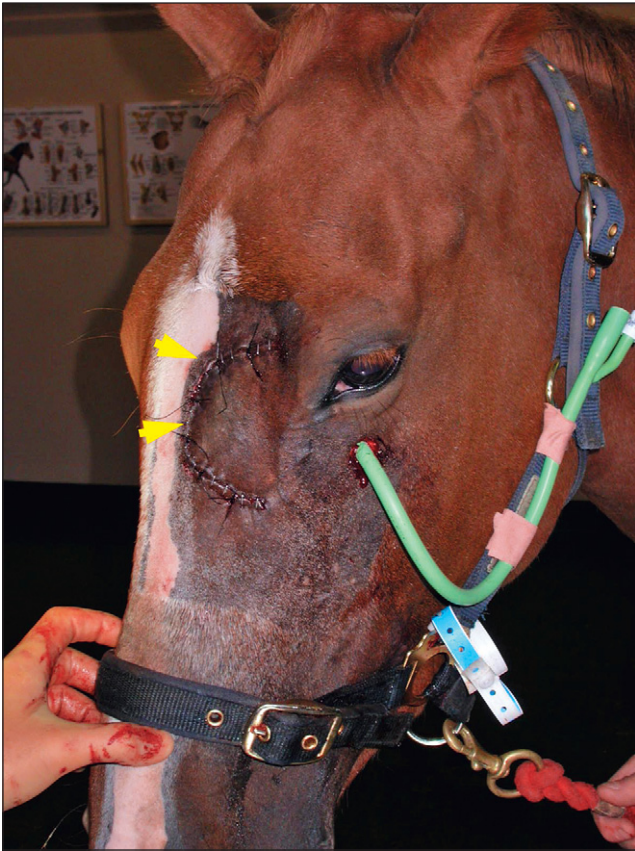At sinusotomy, inspissated pus and grossly thickened mucosa are removed and the sinus can then be irrigated postoperatively (Fig. 26.9). If sinonasal drainage appears to be compromised, it may be improved by creation of a fistula through the dorsomedial wall of the ventral concha into the nasal cavity. Even when performed on the less vascular, dorsal aspect of the medial conchal wall, this fistulation will usually be accompanied by profuse hemorrhage. To control hemorrhage after such fistulation a 3-inch (7.6-cm) elasticated stockinet can be introduced into the sinus via the nasal cavity (Fig. 26.11). To place this packing, an assistant passes a Chambers' mare catheter up the nasal passage until it can be digitally directed into the sinus by the surgeon. A length of umbilical tape is tied to the end of the catheter in the sinus and this end is drawn out of the nostril while the other remains within the sinus. Then saline-soaked gauze



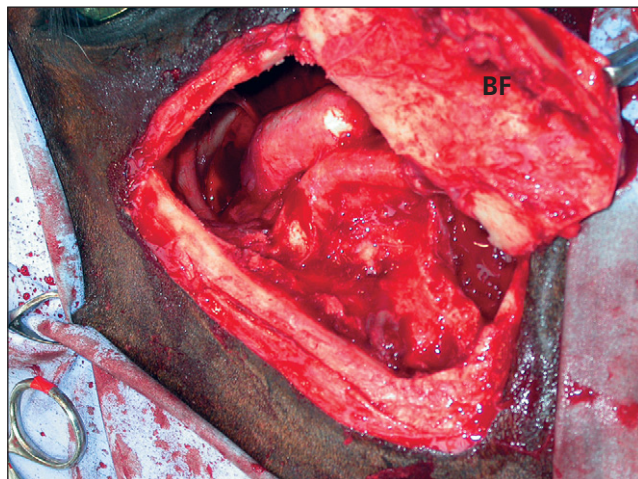
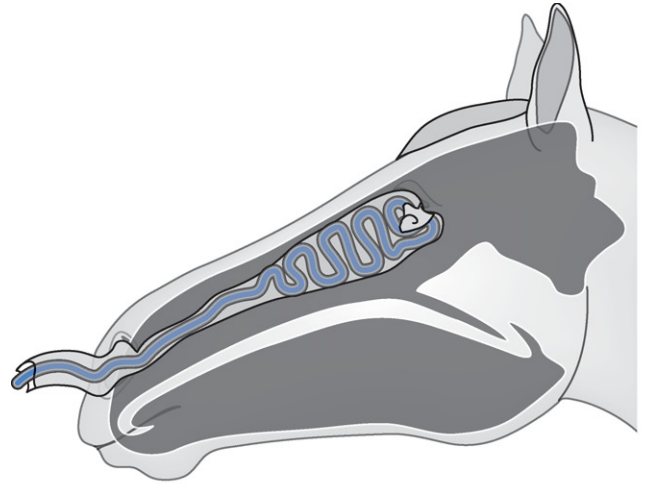
**Fig. 26.7.** A large (5-cm) diameter trephine is being used to create a large bone flap into the left frontal sinus in this horse, enabling surgical access to the dorsal conchal, frontal and caudal maxillary sinuses. The bone flap is discarded and the flap later closed by apposing the skin and periosteum.



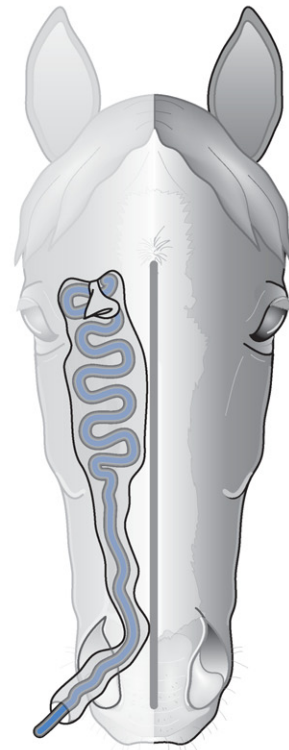**Fig. 26.8.** Copious quantities of purulent exudate flowing from a nasofrontal bone flap osteotomy in a horse with chronic sinus empyema.



**Fig. 26.9.** The skin flap and periosteum are supported by a rim of frontal bone and are apposed using interrupted sutures (arrowheads). A maxillary trephine opening has then been made to allow post-operative irrigation of the maxillary sinuses through a Foley catheter.



**Fig. 26.10.** A large maxillary bone flap (BF) has been created in this horse using an oscillating bone saw. This approach gives exposure to the caudal and rostral maxillary sinuses. The ventral conchal sinus is variably accessible dorsal to the infraorbital canal. This horse has extensive, inflamed soft tissue swelling within its caudal maxillary sinus.



**Fig. 26.11.** Diagram outlining the postsurgical packing of a paranasal sinus to reduce hemorrhage following sinonasal fistulation.

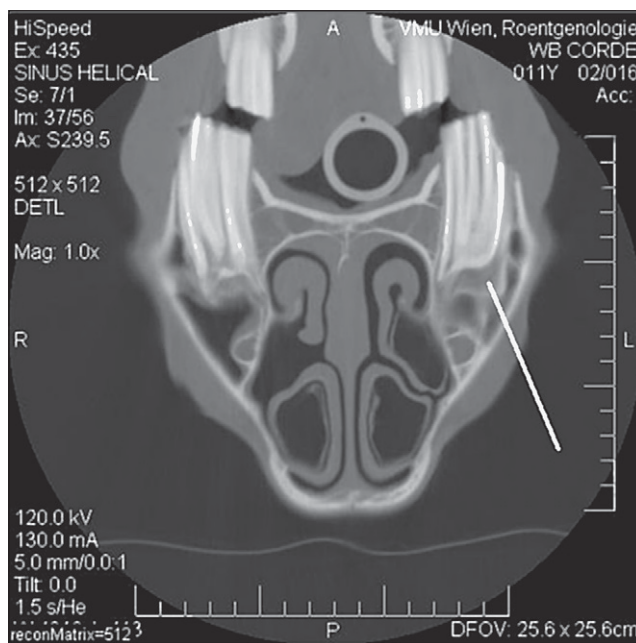
bandage is placed within the “sock” of stockinet in accordion-fashion until the sinuses are packed.

The umbilical tape is tied around the redundant portion of stockinet, and the gauze within it, and used to draw them through the nostrils. The free end of stockinet, and gauze within it, are sutured to the roof of the false nostril with a heavy mattress suture over a butterfly of gauze sponge, and any excess packing is trimmed flush with the nostril. Alternatively, packing can be brought out through a trephine hole in adjacent intact bone. The purpose of the stockinet “sock” is to prevent migration of the packing into the pharynx, where it can be swallowed. It has been suggested that the upright position of the head when the procedure is performed in the standing horse results in less bleeding, although profuse hemorrhage can accompany fistulation of the venous conchal sinuses in standing horses. The necessity and efficacy of this sinonasal fistulation has been questioned (J. Schumacher, personal communication) and it is possible that sinonasal fistulation could alter mucociliary clearance and diminish intrasinus retention of endogenous (possibly bactericidal) nitric oxide.

The bone flap is replaced *in situ* (if retained) and may be secured with one or two wire sutures inserted into pre-placed drill holes in the flap and adjacent bone, although this may be unnecessary. The periosteum is closed with absorbable sutures and the skin is closed with staples or non-absorbable sutures. A lavage cannula or Foley catheter sutured into a separate trephine opening in the frontal sinus or caudal maxillary sinus allows postoperative irrigation of the sinuses. The prognosis for resolution of chronic sinusitis, including cases involving the ventral conchal sinus after surgical debridement, and where necessary, creation of sinonasal drainage is excellent (Tremaine et al 2001b, Quinn et al 2004).

## Dental Sinusitis

Sinusitis commonly occurs with apical infections of the caudal maxillary cheek teeth (Triadan upper 08s–11s) (Mason 1975a, van der Velden & Verzijlenberg 1984, Lane 1993) and such dental infections caused 53% of sinusitis cases in one study (Tremaine & Dixon 2001a). Dental sinusitis occurs most frequently in horses aged 4–7 years (Dixon et al 2000b). Maxillary cheek teeth apical infections commonly occur following anachoresis (blood-borne infections of apices) (Dacre 2004) but also occur secondarily to idiopathic dental fractures (lateral slab or sagittal), or with severe diastemata, and sometimes in conjunction with supernumerary cheek teeth (Dixon et al 1999, 2000a, Dacre 2004). Nasal discharge is frequently fetid when associated with dental secondary sinusitis, and also with intranasal tracts and granulomas resulting from infection of the first or second (or occasionally third) maxillary cheek tooth (Triadan 106–108, 206–208) (Lane 1994). Anaerobes including *Bacteroides fragilis*,



**Fig. 26.12.** Computed tomography transverse image of skull of a young horse at the level of the rostral maxillary sinuses, showing unilateral distortion of the overlying maxillary and nasal bones caused by an expansive soft tissue density mass within the sinus. Reproduced with the permission of Dr Wolfgang Henninger, University of Veterinary Medicine, Vienna.

*B. melaninogenicus*, *B. oralis* and *Fusobacterium mortiferum* have been cultured from nasal discharge with such infections (Mackintosh & Colles 1987), but their precise etiologic role remains unclear.

Radiography is an insensitive technique for detection of dental infections, especially in younger horses, because the radiographic changes associated with anatomical development of cheek teeth apices (i.e. blunt apices, absence of roots, wide periodontal spaces and absence of lamina dura denta in this region) are similar to the radiographic signs of early apical infection (see Chapter 10). In such cases, the presence of apical infection can sometimes be confirmed by gamma scintigraphy, which is more sensitive than radiography in selected cases, particularly in the early stages of the disease (Weller et al 2001) (see Chapter 12). Computed tomography and magnetic resonance imaging are also increasingly used to obtain highly detailed images of structures within the equine head and thus make an early and accurate diagnosis of apical infections (Tiejte et al 1998, Morrow et al 2000, Henninger et al 2003) (Fig. 26.12).

Sinusitis secondary to maxillary dental apical infections usually necessitates removal of the affected cheek tooth before resolution of the sinusitis will occur. Because of difficulty with the extraction of cheek teeth and the major long-term consequences following such extractions, this procedure should never be undertaken lightly. Definite

diagnosis of dental involvement in sinusitis using radiography, scintigraphy or computed tomography is essential before embarking on tooth removal. Anecdotal reports suggesting that endodontic therapy of infected pulp *per os*, effectively sealing the oral cavity from the sinus, will result in resolution of the sinus (T. Johnson, personal communication) have not been critically evaluated.

Infected cheek teeth may be removed via oral extraction, repulsion or via a lateral buccotomy. The latter technique can be used for the rostral three maxillary cheek teeth but not for the caudal maxillary cheek teeth. Extraction *per os* is associated with considerably reduced complications compared to repulsion, and additionally, may be accomplished in the standing horse (Tremaine 2004b, Dixon et al 2005). Dental extractions involving the maxillary cheek teeth that cannot be achieved by oral extraction (e.g. badly fractured or carious cheek teeth) can be performed under general anesthesia via a bone-flap osteotomy or via trephine opening. Intraoperative imaging to ensure accurate alignment of the punch with the affected tooth before repulsing the tooth is advised, to avoid iatrogenic damage to adjacent structures.

If dental extraction is performed *per os* in horses with dental sinusitis, lavage of the affected paranasal sinuses should also be performed post extraction. Intraoperative radiographs should be taken after dental removal (especially by repulsion) to attempt to identify the possible presence of intraalveolar bone or dental fracture fragments that are likely to sequestrate. Following oral extraction the alveolus can be temporarily packed with an antibiotic-soaked swab (Dixon et al 2005), but following repulsion a more robust alveolar packing is required, such as an acrylic plug attached to adjacent cheek teeth, to prevent the development of an oromaxillary fistula. Unsuccessful treatment of sinusitis can be attributed to oromaxillary fistula, persistent alveolar osteitis, abscesses within the overlying sinus, failure to remove all the infected tooth and infected or loose alveolar bone, and failure to treat obligate anaerobes with appropriate antibiotics such as metronidazole (De Moor & Verschooten 1982, Mackintosh & Colles 1987). The presence of small alveolar sequestra, which are not identifiable on postoperative radiographs, are an occasional cause for persistent clinical signs of sinusitis. These apparently develop later as the result of damage to alveoli by the repulsion process. The long-term prognosis for both primary and dental sinusitis cases is good (Tremaine & Dixon 2001b).

### Mycotic Sinusitis

Equine sinonasal diseases associated with fungal infection are rare in the horse in the UK. Greet (1981) first described three cases of mycotic rhinitis in horses caused by *Aspergillus fumigatus*, and subsequent reports are sparse. Of ten cases of sinonasal mycosis described by McGorum

et al (1992), *Aspergillus fumigatus* was cultured from six, *Pseudallescheria boydii* from one, and *Penicillium* spp. from a single case. *Pseudallescheria boydii*, an opportunistic saprophyte, has also been isolated from a frontal sinus lesion (Johnson et al 1975).

*Aspergillus fumigatus* is ubiquitous in dead vegetation including hay and straw. The mechanism of infection of the nasal chambers or paranasal sinuses of horses by normally saprophytic fungi is not clear, but previous trauma from surgery or nasogastric tube passage may be a factor in some cases (Watt 1970, Greet 1981, Tremaine & Dixon 2001b).

Mycotic sinonasal infections caused by other fungal organisms are common in warm humid climates. These have involved infection with *Cryptococcus neoformans* (Watt 1970, Corrier et al 1984), *Coccidioides immitis* (DeMartini & Riddle 1969, Hodgkin et al 1984), *Rhinosporidium seeberi* (Myers et al 1964), *Conidiobolus coronatus* (*Entomophthora coronata*) (Bridges et al 1962, Hanselka 1977, Zamos et al 1996), *Conidiobolus lamprauges* (Humber et al 1989) and *Hyphomyces destruens* (Hutchins & Johnston 1972). Such mycotic granulomas are characterized by the presence of necrotic foci or “kunkers” within proliferative granulation tissue. Nasal infections by these lesions are described in detail in Chapter 25.

Sinus mycosis has also been reported secondary to other intrasinus lesions such as progressive ethmoidal hematoma and can also occur following sinus surgery for other diseases such as progressive ethmoidal hematoma, sinus cysts or following head trauma (McGorum & Dixon 1992, Tremaine & Dixon 2001a).

Mycotic sinus infections commonly cause a unilateral nasal discharge, which may vary from mucopurulent, purulent to sanguineous, and is frequently malodorous (McGorum et al 1992, Tremaine & Dixon 2001a).

The treatment of superficial mycotic lesions with antimycotic drugs including nystatin (Campbell & Peyton 1984), enilconazole or natamycin (McGorum et al 1992) by topical application directly or via an endoscope carries a good prognosis although recurrence is possible. Surgical removal of large intrasinus fungal granulomas or plaques or of any underlying cause such as sequestra, cysts or progressive ethmoidal hematoma lesions, followed by sinus irrigation with a topical antifungal such as natamycin or miconazole, usually results in rapid resolution of the lesions.

### *Halicephalobus gingivalis* Infection

*Halicephalobus gingivalis* is a saprophytic nematode found in decaying humus and infection through an unknown route can involve the sinuses, central nervous system, and, to a lesser extent, the kidney in certain geographical regions (Pearce et al 2001). Infection of the sinuses produces a mass of gray–yellow fibrous tissue that obliterates the sinuses and their walls, loosens teeth and distorts sinus



architecture. Infection can be unilateral or bilateral, can involve both the upper and lower jaws, and can spread from there to the kidneys and cerebellum (Freeman 1991a).

Predominant clinical signs of *H. gingivalis* infection are facial distortion with firm swellings in the maxilla, unilateral or bilateral nasal discharge, marked dyspnea and stridor, difficulty in eating, and weight loss (Pearce et al 2001). The condition can be confused with squamous cell carcinoma but the female rhabditiform nematodes and their larvae and eggs can be seen in clusters or scattered throughout a biopsy specimen. Surgical debulking, intra-operative lavage with ivermectin, and subsequent oral ivermectin was successful in one horse with a periorbital granuloma (Freeman 1991a). However, the response to ivermectin is not always favorable and the prognosis appears to be poor, especially because of risk of spread to other organs.

### Sinus Cysts

Sinus cysts are expansive fluid-filled space-occupying lesions which develop within the sinuses (Leyland & Baker 1975, Dixon 1985, Lane et al 1987) of young to old horses. Congenital intrasinus cysts have also been reported (Sanders-Shamis & Robertson 1987, Beard et al 1990). Equine sinus cysts most commonly occur in the maxillary sinuses but they can also occur in the other sinuses.

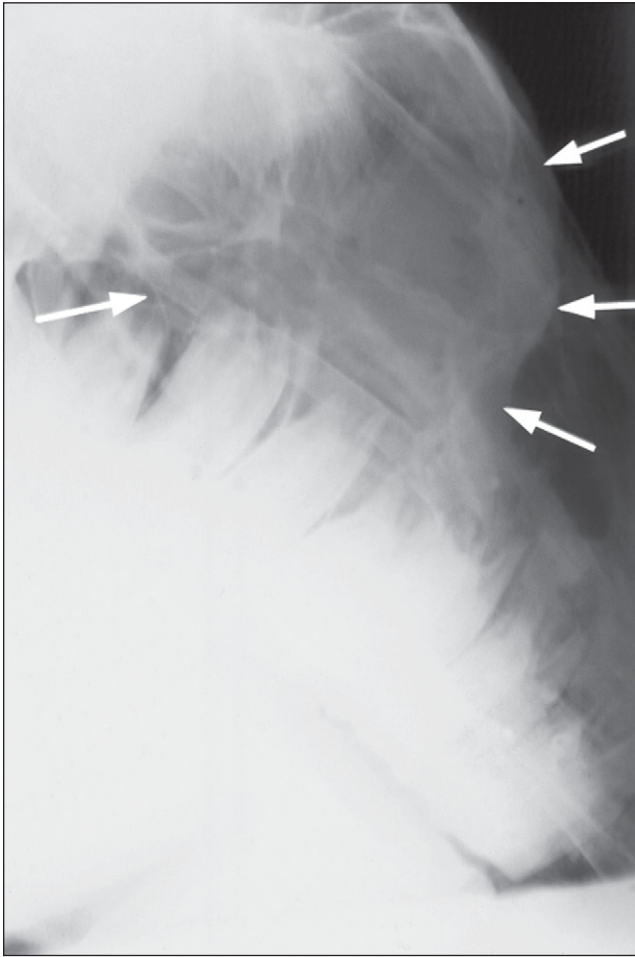
The etiology of these lesions is unclear and no breed or sex predisposition has been identified. It has been suggested that they are developmental in origin (Beard et al 1990), or associated with dental tissues (Boulton 1985), but little evidence for this theory has been found, although one case described by Dixon (1985) was attached to dental alveoli. A common etiology between these lesions and ethmoid hematomas has been suggested (Lane et al 1987) as both lesions histologically contain areas of hemorrhage and hemosiderophages, but little factual evidence for this association has been found (Tremaine et al 1999). Sinus cysts are frequently associated with a nasal discharge and facial swelling (Fig. 26.13). The nasal discharge varies from mucoid, mucopurulent to purulent, and is thought to be the result of sinus infection secondary to obstruction of normal sinonasal drainage. A consistent clinical feature caused by the expansive nature of sinus cysts is distortion of the frontal, maxillary, and conchal bones (Lane et al 1987, Caron 1991, Freeman 1991b, Tremaine & Dixon 2001a). This may result in gross facial swelling and exophthalmos as a result of thinning of the overlying maxillary or frontal bones, and nasal obstruction as a result of the expansion of the lesion within the sinuses and conchae. Horses are affected unilaterally in almost all cases, but expansion of a frontal sinus cyst with lysis of the intersinus septum and expansion into the contralateral frontal sinus, resulting in bilateral clinical signs, can occur (H. Tremaine, personal observations). Large maxillary

sinus cysts can expand into the nasal cavity, causing compression of the nasal septum and bilateral nasal air-flow obstruction.

Diagnosis of sinus cysts is assisted by endoscopy, which may reveal distortion of nasal conchae. Radiographic features of sinus cysts include the presence of a rounded, expansive, soft tissue density lesion in the frontal or maxillary sinuses. Distortion and thinning of the surrounding bones may be evident as the lesion increases in size, and secondary distortion of adjacent dental apices within the sinuses may be present. The contents of the cysts frequently appear radiographically as a homogeneous soft tissue density shadow. The radiodense capsule may contain spicules of mineralized tissue (Fig. 26.14) and extralesional fluid lines may be present if secondary sinus empyema is present (Tremaine & Dixon 2001a). Centesis of the lesion via needle aspiration (e.g. using a 16-gauge needle inserted into areas of thinned, swollen bone) or via a sinusotomy is diagnostic, yielding a viscous, usually sterile, translucent yellow fluid which is odorless and may contain some leukocytes (Dixon 1985, Lane et al 1987, Tremaine & Dixon 2001a, Beard & Hardy 2003). Treatment of the



**Fig. 26.13.** The large swelling of the left side of this 8-year-old horse's rostral maxillary area (arrows) is the result of bone remodeling in response to an expanding cyst within the maxillary sinuses.



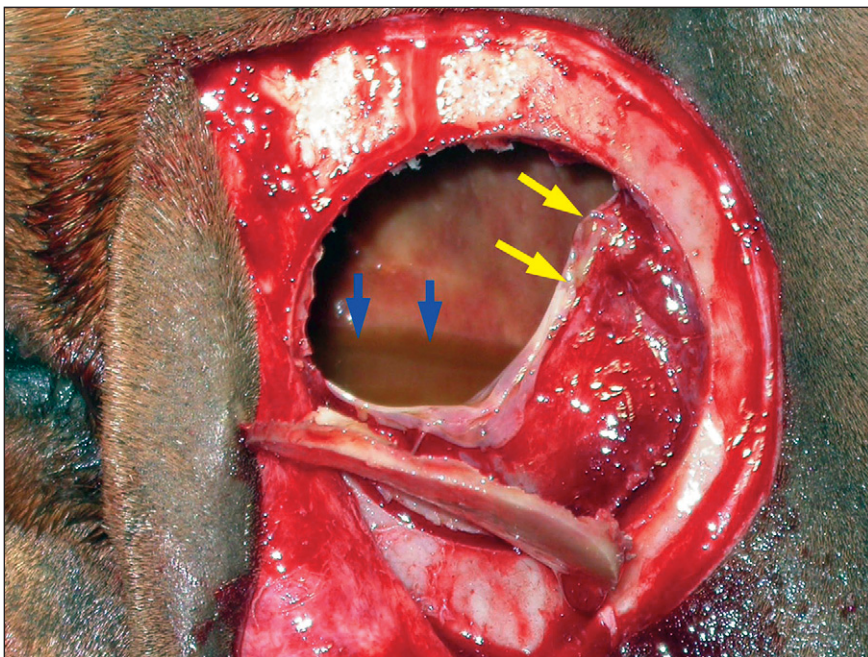
**Fig. 26.14.** Radiograph showing distortion of the sinuses as the result of a sinus cyst with an increased soft tissue density radio-opacity (arrows) throughout the sinus.

lesion by surgical drainage may be effective in some cases (O'Connor 1930, Dixon 1985, Lane et al 1987) but total removal of the lesion via a nasofrontal or maxillary osteotomy approach, under general anesthesia or standing chemical restraint, is the treatment of choice (Fig. 26.15) (Dixon 1985, Lane et al 1987, Tremaine & Dixon 2001b).

Histologic examination of sinus cysts has revealed extensive resorption and remodeling of the bones surrounding the cyst, replacement of the normal bony septa within the sinus by fibrous tissue, and replacement of the loose intrasinus connective tissue with bony spicules (Tremaine et al 1999). The cysts themselves are lined by ciliated columnar respiratory epithelium with focal areas of ulceration, areas of submucosal calcification and of subepithelial hemorrhage, and chronic inflammation may be present (Lane et al 1987, Tremaine et al 1999).

### Progressive Ethmoidal Hematoma

Progressive ethmoidal hematomas are observed most commonly in the nasal cavity arising from the ethmoturbinates. Less commonly, lesions arise in the frontal or maxillary sinuses. The etiology, clinical signs, and treatment of these lesions are discussed in Chapter 27. Cases with clinical signs typical of progressive ethmoidal hematoma (i.e. low-grade chronic, unilateral epistaxis) and with endoscopic evidence of drainage of small volumes of blood from the sinonasal drainage areas and which do not reveal a lesion in the nasal cavities should be subjected to careful examination of the sinuses by radiography, sinuscopy or sinusotomy (Fig. 26.16).



**Fig. 26.15.** Frontal sinus bone flap osteotomy showing a partially removed sinus cyst wall (yellow arrows) with a residual pool of honey-colored exudates (blue arrow) typical of this type of lesion.

## Sinus Neoplasia

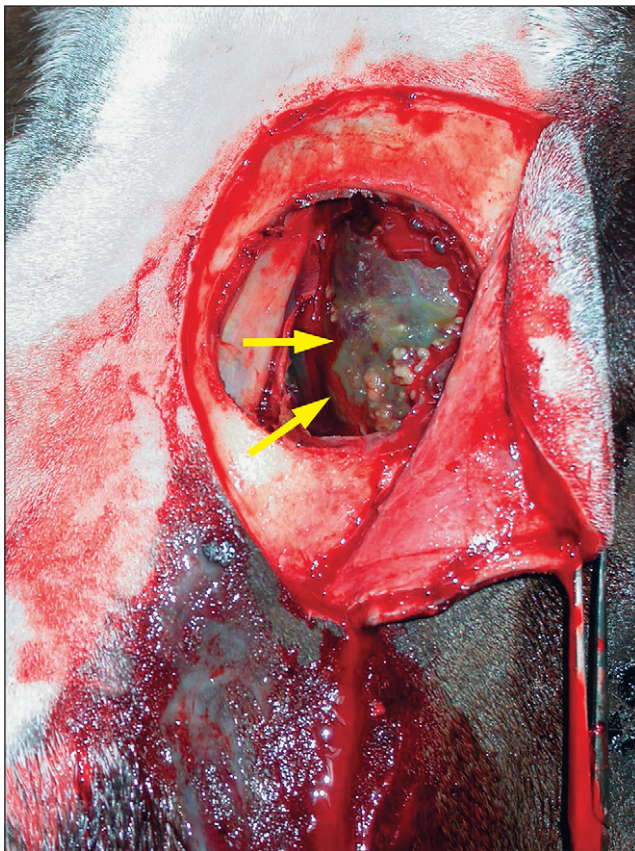
Neoplasia of the nasal and paranasal sinuses is a relatively rare condition in the horse (Cotchin 1956, Madewell et al 1976, Sundbergh et al 1977, Priester & Mackay 1980) and there are only a few multiple case studies of equine sinus neoplasia (Cotchin 1967, Madewell et al 1976, Stunzi & Hauser 1976, Hilbert et al 1988, Dixon & Head 1999).

Although the sinuses are lined by ciliated respiratory mucosa, squamous cell carcinomas are probably the most common sinus neoplasia (Head & Dixon 1999). These lesions are usually direct extensions of lesions originating in the oral cavity (usually the lateral aspects of the hard palate) or from metaplastic epithelium within the sinuses themselves (Reynolds et al 1979, Hill et al 1989, Head & Dixon 1999). They display rapid local expansion and induce considerable necrosis of adjacent tissue.

Other tumor types recorded with paranasal sinus involvement include spindle cell sarcoma, mastocytomas, hemangiosarcoma, angiosarcoma and lymphosarcoma (Lane 1985, Adams et al 1988, Richardson et al 1994, Malikides et al 1996, Dixon & Head 1999).

A group of fibro-osseous lesions, often of overlapping histologic classification, have been reported in the paranasal sinuses of horses. These include osteomas, which have been found in the frontal and maxillary sinuses (Gorlin et al 1963, Schumacher et al 1988, Dixon & Head 1999), osteochondromas (Adair et al 1994), fibromas (Barber et al 1983) and fibrosarcomas (Hultgren et al 1987, Dixon & Head 1999). Tumors of dental tissue origin with involvement of the maxillary sinuses have been reported, although such neoplasms more frequently affect the mandibular or rostral maxillary cheek teeth (Pirie & Dixon 1993) and such lesions, although more common in older animals, have been described in foals (Roberts et al 1978).

Clinical signs associated with neoplasia are similar to those of other expansive lesions affecting the paranasal sinuses and include nasal discharge (purulent or mucopurulent, occasionally hemorrhagic), facial swelling (Fig. 26.17), epiphora, and nasal obstruction. However, as a consequence of the large space into which sinus lesions can expand, facial swelling and other signs may be absent until an advanced stage. Head shaking, exophthalmos, and



**Fig. 26.16.** Nasofrontal sinus bone flap surgery showing an intrasinus progressive ethmoidal hematoma (arrows), which was not detectable on nasal endoscopy and which is covered by inspissated pus.



**Fig. 26.17.** This pony has a rapidly expanding maxillary tumor, which caused loosening and secondary apical infections of the adjacent maxillary cheek teeth.

epistaxis are less commonly observed (Hill et al 1989, Tremaine & Dixon 2001a).

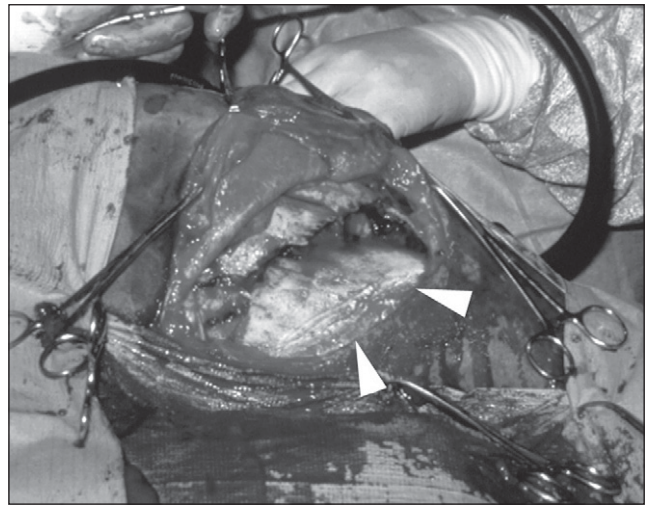The diagnosis of intrasinus neoplasia requires, as for other sinus lesions, clinical and oral examination, radiography, sinuscopy, and possibly scintigraphy and computed tomography. Wherever possible, histopathology of biopsy specimens should be performed to confirm the diagnosis and help establish a prognosis.

Surgical resection of benign lesions, such as osteomas, via a nasofrontal flap, may carry a good long-term prognosis (Schumacher et al 1988, Head & Dixon 1999, Tremaine & Dixon 2001b). However, the aggressive nature and the complex anatomical location of most sinonasal tumors usually prevent complete resection and consequently, a poor prognosis is present following surgical treatment of these lesions (Dixon & Head 1999). Exceptions include osteomas which are usually amenable to treatment because they are benign (some may not even be true neoplasms but hamartomas), grow slowly, have pedunculated or sessile attachments over a small base, and tend to form well-circumscribed lesions rather than infiltrate (Freeman 1991b).

Beta-radiotherapy with cobalt-60 has been attempted with limited success for soft tissue sinus neoplasms. In one report, the results of aggressive radiotherapy of advanced squamous cell carcinomas in three horses was encouraging, because radiation-induced complications were mild, and survival duration and quality of life were good (Walker et al 1998).

## Traumatic Injuries of the Paranasal Sinuses

Fractures involving the premaxilla are common in foals (Hardy 1991) and depression fractures of the frontal and maxillary sinuses have been commonly reported in adult horses (Sullins & Turner 1982, Tremaine & Dixon 2001a). Traumatic hemorrhage into the sinuses may lead to a profuse short-term epistaxis, which is often followed by an unexpectedly prolonged (> 4 weeks) intermittent low-grade epistaxis. Open sinus fractures frequently lead to secondary sinusitis (Dixon 1993a), and the presence of intrasinus sequestra may result in chronic suppuration with persistent sinusitis (Lane 1993). Repair of these fractures is possible by elevating the depressed bone flap (Fig. 26.18) and, if it is unstable once elevated, immobilizing it in the reduced position with stainless steel wires. To facilitate elevation of the fracture fragments, holes can be drilled in adjacent undamaged bone and a periosteal elevator, Steinmann pins, or Langenbeck retractors can be passed through these to pry up depressed fragments. If the elevated fragments wedge firmly together in their normal position and form a stable union it may be unnecessary to wire them (Turner 1979), but large



**Fig. 26.18.** This figure shows a horse with a large depressed maxillary fracture (arrow on fixed side of depressed fracture) undergoing surgical repair of this injury. Fractured bones such as this can be elevated and stabilized with wire with a good cosmetic outcome.

fragments should be wired to stable adjacent bone. The fracture fragments can also be exposed through a large curvilinear skin flap, especially if an open fracture is present and intrasinus access is required. Blood clots and loose bone fragments are removed and the sinus cavity is flushed liberally with saline. All small fragments without full periosteal attachments should also be removed. Following repair of the bone and skin wounds, the head should be bandaged so as to cover the wound, if possible, and the horse should be recovered from general anesthesia either with assistance or wearing a padded headguard. Healing after repair of sinus injuries is usually excellent, particularly if the skin remains intact (Tremaine 2004b) although suture exostoses may remain.

In horses with long-standing, healed depression fractures, fluorocarbon polymer and carbon fiber can be used to restore the facial contour (Valdez & Rook 1981), or the healed maligned areas can be cut with a bone saw, elevated and then wired into a more anatomically normal position. However, a better cosmetic appearance can be obtained by primary open reduction of such large depressed fractures shortly after injury, rather than by facial reconstruction later. If severe or open sinus fractures are not treated, complications such as sinusitis, sequestra formation, facial deformity, abnormal bone growth in young horses, and nasal obstruction can be expected.

## Nasofrontal Suture Exostoses

Swellings of the nasofrontal region of the head as a result of periostitis of the suture lines between the nasal and frontal bones, and more rarely the nasal, lacrimal,

and malar bones have been described (Gibbs & Lane 1987, Speirs 1992, Trotter 1993, Tremaine & Dixon 2001a). They occur in many breeds but the incidence appears to be particularly high in thoroughbreds and thoroughbred crosses (Dixon 1991). Although most are possibly traumatic in origin, including following sinonasal surgery, especially after a large nasofrontal osteotomy, the exact etiology of such lesions remains unknown in other cases. Affected horses present with bilateral, firm, non-painful swellings, rostral to the eye, accompanied by epiphora in some cases. Differentiation from facial fractures and sinusitis is usually possible clinically and radiologically. Radiographs frequently demonstrate proliferative periosteal changes of the widened and incompletely closed suture line. The swellings usually remodel and regress gradually without treatment, but in some cases continued instability has resulted in progressive increases in the size of these swellings.

### Miscellaneous Sinus Disorders

Frontal sinus eversion is probably a congenital defect that forms a hard, slow-growing protuberance over, and communicating with, the frontal sinus (Martin & McIlwraith 1981). The bony protuberance can be removed through a large elliptical incision and the resulting defect in the frontal bone can be repaired with synthetic polypropylene mesh (Marlex) and skin.

Osteodystrophia fibrosa or secondary nutritional hyperparathyroidism can develop in horses on a high phosphorus diet, such as bran, or on some tropical grasses (Clarke et al 1996) and can be attributed to relative calcium deficiency (Freeman 1991b). It is rare under modern management conditions. Conchal necrosis (De Moor & Verschooten 1982) may be caused by advanced mycotic rhinitis (Tremaine & Dixon 2001b) that usually responds to removal of the affected concha by intranasal curettage and lavage.

The reserve tooth crowns of young (2- to 4-year-old) Welsh and miniature ponies and other smaller pony breeds can project a considerable distance into the nasal and sinus cavities and cause firm, painless, bilateral swellings in the maxillary bones that should not be confused with injuries or disease. Facial lumps or "horns" can be seen in horses as symmetrical painless prominences of the nasal and frontal bones and possibly are caused by an embryologic fault.

### REFERENCES

- Adair HS, Duncan RB, Toal RL 1994 Solitary osteochondroma of the nasal bone in a horse. *Cornell Veterinarian* 84: 25–31
- Adams R, Calderwood-Mays MB, Peyton LC 1988 Malignant lymphoma in three horses with ulcerative pharyngitis. *Journal of the American Veterinary Medical Association* 193: 674–676
- Barber SM, Clark EG, Fretz PB 1983 Fibroblastic tumour of the premaxilla in two horses. *Journal of the American Veterinary Medical Association* 182: 700–702
- Beard WL, Hardy J 2003 Diagnosis of conditions of the paranasal sinuses of the horse. *Equine Veterinary Education* 13: 265–273
- Beard WL, Robertson JT, Leeth B 1990 Bilateral congenital cysts in the frontal sinus of a horse. *Journal of the American Veterinary Medical Association* 196: 453–454
- Boulton CH 1985 Equine nasal cavity and paranasal sinus disease: a review of 85 cases. *Journal of Equine Veterinary Science* 5: 268–275
- Bridges CH, Romane WM, Emmons CW 1962 Phycomycosis of horses caused by *Entomophthora coronata*. *Journal of the American Veterinary Medical Association* 140: 673–677
- Campbell ML, Peyton LC 1984 Muscle flap closure of a frontocutaneous fistula in a horse. *Veterinary Surgery* 13: 185–188
- Caron JP 1991 Diseases of the nasal cavity and paranasal sinuses. In: Colahan PT, Mayhew IG, Merritt AM, Moore JN (editors) *Equine Medicine and Surgery*. American Veterinary Publications, Goleta, CA, pp.386–397
- Clarke CJ, Roeder PL, Dixon PM 1996 Nasal obstruction caused by nutritional osteodystrophia fibrosa in a group of Ethiopian horses. *Veterinary Record* 139: 568–570
- Corrier DE, Wilson SR, Scrutchfield WL 1984 Equine cryptococcal rhinitis. *Compendium on Continuing Education for the Practicing Veterinarian* 6: 556–558.
- Cotchin E 1956 Neoplasms of the Domesticated Animals. Commonwealth Agricultural Bureaux, Buckingham, UK
- Cotchin E 1967 Spontaneous neoplasms of the upper respiratory tract in animals In: Muir CS, Shanmugaratnam K (editors) *Cancer of the Naso-Pharynx*. Medical Examination Publishing Co, Flushing, NY, pp.203–259
- Coumbe KM, Jones RD, Kenward JH 1987 Bilateral sinus empyema in a six year-old mare. *Equine Veterinary Journal* 19: 559–560
- Dacre IT 2004 A pathological, histological and ultrastructural study of diseased equine cheek teeth. PhD thesis, University of Edinburgh
- DeMartini JC, Riddle WE 1969 Disseminated coccidiomycosis in two horses and a pony. *Journal of the American Veterinary Medical Association* 155: 149–156
- De Moor Von A, Verschooten F 1982 Empyem und Nekrose der Nasenmuscheln beim Pferd (Empyema and necrosis of the nasal conchae in a horse). *Deutsche Tierärztliche Wochenschrift* 89: 275–281
- Dixon PM 1985 Equine maxillary cysts. *Equine Practice* 7: 25–33
- Dixon PM 1991 Swellings of the head region in the horse. *In Practice* 13: 257–263
- Dixon PM 1993a Nasal cavity. In: *Equine Respiratory Endoscopy*. Boehringer Ingelheim, Bracknell, pp.22–29
- Dixon PM 1993b Ethmoturbinates. In: *Equine Respiratory Endoscopy*. Boehringer Ingelheim, Bracknell, pp.43–48
- Dixon PM, Head KW 1999 Equine nasal and paranasal sinus tumours: part 2: A contribution of 28 case reports. *Veterinary Journal* 157: 279–294
- Dixon PM, Tremaine WH, Pickles K et al 1999 Equine dental disease Part 2: A long term study of 400 cases: disorders of development and eruption and variations in position of the cheek teeth. *Equine Veterinary Journal* 31: 519–528
- Dixon PM, Tremaine WH, Pickles K et al 2000a Equine dental disease Part 3: A long term study of 400 cases: disorders

- of wear, traumatic damage and idiopathic fractures, tumours and miscellaneous disorders of the cheek teeth. *Equine Veterinary Journal* 32: 9–18
- Dixon PM, Tremaine WH, Pickles K et al 2000b Equine dental disease Part 4: A long term study of 400 cases: apical infections of cheek teeth. *Equine Veterinary Journal* 32: 182–194
- Dixon PM, Dacre I, Dacre K et al 2005 Standing oral extraction of cheek teeth in 100 horses (1998–2003). *Equine Veterinary Journal* 37: 105–112
- Freeman DE 1991a Nasal passages. In: Beech J (editor) *Equine Respiratory Disorders*. Lea and Febiger, Philadelphia, pp.253–274
- Freeman DE 1991b Paranasal sinuses In: Beech J (editor) *Equine Respiratory Disorders*. Lea and Febiger, Philadelphia, pp.275–305
- Freeman DE 2003 Sinus disease. *Veterinary Clinics of North America; Equine Practice* 19: 209–243
- Freeman DE, Orsini PG, Ross MW et al 1990 A large fronto-nasal flap for sinus surgery in the horse. *Veterinary Surgery* 19: 122–130
- Gibbs C, Lane JG 1987 Radiographic examination of the nasal and paranasal sinus regions of the horse. Part 2: Radiological findings. *Equine Veterinary Journal* 19: 474–482
- Gorlin RJ, Meskin LH, Brodey R 1963 Odontogenic tumours in man and animals, pathological classification and clinical behaviour – a review. *Annals of the New York Academy of Science* 108: 722–771
- Greet TRC 1981 Nasal aspergillosis in three horses. *Veterinary Record* 109: 487–489
- Hanselka DV 1977 Equine nasal phycomycosis. *Veterinary Medicine/Small Animal Clinician* 72: 251–253
- Hardy J 1991 Upper respiratory obstruction in foals, weanlings, and yearlings. *Veterinary Clinics of North America; Equine Practice* 7: 105–122
- Head KW, Dixon PM 1999 Equine nasal and paranasal sinus tumours. Part 1: review of the literature and tumour classification. *Veterinary Journal* 157: 261–278
- Henninger W, Frame M, Willman M et al 2003 CT features of alveolitis and sinusitis in horses. *Veterinary Radiology and Ultrasound* 44: 269–276
- Hilbert BJ, Little CB, Klein K et al 1988 Tumours of the paranasal sinuses in 16 horses. *Australian Veterinary Journal* 65: 86–88
- Hill FWE, Moulton JE, Schiff PH 1989 Exophthalmos in a horse resulting from an adenocarcinoma of the paranasal sinus. *Journal of South African Veterinary Medicine Association* 60: 104–105
- Hodgkin EC, Conaway DH, Ortenburger AI 1984 Recurrence of obstructive nasal coccidioidal granuloma in a horse. *Journal of the American Veterinary Medical Association* 184: 339–340
- Hultgren BD, Schmotzer WB, Watrous BJ et al 1987 Nasal–maxillary fibrosarcoma in young horses: a light microscopic study. *Veterinary Pathology* 24: 194–196
- Humber RA, Brown CC, Korngay RW 1989 Equine zygomycosis caused by *Conidiobolus lamprauges*. *Journal of Clinical Microbiology* 27: 573–576
- Hutchins DR, Johnston KG 1972 Phycomycosis in the horse. *Australian Veterinary Journal* 48: 269–277
- Johnson GR, Schiefer B, Pantekoek JFCA 1975 Maduromycosis in a horse in Western Canada. *Canadian Veterinary Journal* 16: 341–344
- Lane JG 1985 Palatine lymphosarcoma in two horses. *Equine Veterinary Journal* 17: 465–467
- Lane JG 1993 Management of sinus disorders, part 1. *Equine Veterinary Education* 5: 5–9
- Lane JG 1994 A review of dental disorders of the horse, their treatment and possible fresh approaches to management. *Equine Veterinary Education* 6: 13–21
- Lane JG, Longstaffe JA, Gibbs C 1987 Equine paranasal sinus cysts: a report of 15 cases. *Equine Veterinary Journal* 19: 534–544
- Leyland A, Baker JR 1975 Lesions of the nasal and paranasal sinuses of the horse causing dyspnoea. *British Veterinary Journal* 131: 339–346
- Mackintosh ME, Colles CM 1987 Anaerobic bacteria associated with abscesses in the horse and donkey. *Equine Veterinary Journal* 19: 360–362
- Madewell BR, Priester WA, Gillete EL et al 1976 Neoplasms of the nasal passages and paranasal sinuses in domestic animals as reported by 13 veterinary colleges. *American Journal of Veterinary Research* 37: 851–856
- Malikides N, Reppas G, Hodgson JL et al 1996 Mast cell tumours in the horse: four case reports. *Equine Practice* 18: 12–17
- Mansmann RA, Wheat JD 1973 The diagnosis and treatment of equine upper respiratory diseases. In: *Proceedings of the 18th Annual Convention of the American Association of Equine Practitioners*. Lexington, KY, pp.388–487
- Martin GS, McIlwraith CW 1981 Repair of a frontal sinus eversion in a horse. *Veterinary Surgery* 10: 149
- Mason BJE 1975a Empyema of the equine paranasal sinuses. *Journal of the American Veterinary Medical Association* 167: 727–731
- Mason BJE 1975b Spindle-cell sarcoma of the equine para-nasal sinuses and nasal chamber. *Veterinary Record* 96: 287–288
- McGorum BC, Dixon PM, Lawson GHK 1992 A review of ten cases of mycotic rhinitis. *Equine Veterinary Education* 4: 8–12
- Meschter CL, Allen D 1984 Lymphosarcoma within the nasal cavities of an 18 month old filly. *Equine Veterinary Journal* 16: 475–476
- Morrow K, Park RD, Spurgeon, TL et al 2000 Computed tomography of the equine head. *Veterinary Radiology and Ultrasound* 41: 491–497
- Myers DD, Simon J, Case MT 1964 Rhinosporidiosis in a horse. *Journal of the American Veterinary Medical Association* 145: 345–346
- O'Connor JJ 1930 Operations. *Dollar's Veterinary Surgery*. Bailliere, Tindall and Cox, London, pp.222–231
- Pearce SG, Bouré LP, Taylor JA et al 2001 Treatment of a granuloma caused by *Halicephalobus gingivalis* in a horse. *Journal of the American Veterinary Medical Association* 219: 1735–1738
- Pirie RS, Dixon PM 1993 Mandibular tumours in the horse: a review of the literature and 7 case reports. *Equine Veterinary Education* 5: 287–294
- Priester WA, Mackay FW 1980 The occurrence of tumors in domestic animals. *National Cancer Institute Monograph* 54: 59–99
- Quinn G, Lane JG, Kidd JF 2005 Fronto-nasal flap surgery in standing horses. *Equine Veterinary Journal* 37: 138–142
- Reed SM, Boles CL, Dade AW et al 1979 Localised equine nasal coccidiomycosis granuloma. *Journal of Equine Medicine and Surgery* 3: 119–123
- Reynolds BL, Stedham MA, Lawrence JM et al 1979 Adenocarcinoma of the frontal sinus with extension to the brain in a horse. *Journal of the American Veterinary Medical Association* 174: 734–736

- Richardson JD, Lane JG, Nicholls PK 1994 Nasopharyngeal mast cell tumour in a horse. *Veterinary Record* 134: 238–240
- Roberts MC, Groenendyk S, Kelly WR 1978 Ameloblastic odontoma in a foal. *Equine Veterinary Journal* 10: 91–93
- Ruggles AJ, Ross MW, Freeman DE 1991 Endoscopic examination of normal paranasal sinuses in horses. *Veterinary Surgery* 20: 418–423
- Ruggles AJ, Ross MW, Freeman DE 1993 Endoscopic examination and treatment of paranasal sinus disease in 16 horses. *Veterinary Surgery* 22: 508–514
- Sanders-Shamis M, Robertson JT 1987 Congenital sinus cyst in a foal. *Journal of the American Veterinary Medical Association* 190: 1011–1012
- Schumacher J, Crossland LE 1994 Removal of inspissated purulent exudate from the ventral conchal sinus of three standing horses. *Journal of the American Veterinary Medical Association* 205: 1312–1314
- Schumacher J, Honnas C, Smith B 1987 Paranasal sinusitis complicated by inspissated exudate in the ventral conchal sinus. *Veterinary Surgery* 16: 373–377
- Schumacher J, Smith BL, Morgan SJ 1988 Osteoma of paranasal sinuses of a horse. *Journal of the American Veterinary Medical Association* 192: 1449–1450
- Scott EA 1987 Sinusitis. In: Robinson NE (editor) *Current Therapy in Equine Medicine 2*. WB Saunders, Philadelphia, pp.605–607
- Scrutchfield WL, Schumacher J, Walker M et al 1994 Removal of an osteoma from the paranasal sinuses of a standing horse. *Equine Practice* 16: 24–27
- Speirs VC 1992 Diseases of the paranasal sinuses. In: Robinson NE (editor) *Current Therapy in Equine Medicine 3*. WB Saunders, Philadelphia, pp.217–224
- Stunzi H, Hauser B 1976 Tumours of the nasal cavity (International histological classification of tumours of domestic animals). *Bulletin of the World Health Organisation* 53: 257–263
- Sullins KE, Turner AS 1982 Management of fractures of the equine mandible and premaxilla (Incisive bone). *Compendium on Continuing Education for the Practicing Veterinarian* 4: S480–S489
- Sundbergh JP, Burustein T, Page EH et al 1977 Neoplasms of equidae. *Journal of the American Veterinary Medical Association* 170: 150–152
- Taylor J 1955 *The horse. The Head and Neck*. Oliver & Boyd, London
- Tietje S, Becker M, Bockenhoff G 1998 Computed tomographic evaluation of head diseases in the horse: 15 cases. *Equine Veterinary Journal* 28: 98–105
- Tremaine WH 2004a The management of head fractures in horses. *In Practice* 26: 142–149
- Tremaine WH 2004b Oral extraction of equine cheek teeth. *Equine Veterinary Education* 16: 151–159
- Tremaine WH, Dixon PM 2001a A long-term study of 277 cases of equine sinonasal disease. Part 1: details of horses, historical, clinical and ancillary diagnostic findings. *Equine Veterinary Journal* 33: 274–282
- Tremaine WH, Dixon PM 2001b A long-term study of 277 cases of equine sinonasal disease. Part 2: treatments and results of treatments. *Equine Veterinary Journal* 33: 283–289
- Tremaine WH, Clarke CJ, Dixon PM 1999 Histopathological findings in equine sinonasal disorders. *Equine Veterinary Journal* 31: 296–303
- Trotter GW 1993 Paranasal sinuses. *Veterinary Clinics of North America; Equine Practice* 9: 153–169
- Tulleners EP, Raker C 1983 Nasal septum resection in the horse. *Veterinary Surgery* 12: 41–47
- Turner AS 1979 Surgical management of depression fractures of the equine skull. *Veterinary Surgery* 8: 29
- Valdez H, Rook JS 1981 Use of fluorocarbon polymer and carbon fiber for restoration of facial contour in a horse. *Journal of the American Veterinary Medical Association* 178: 249–251
- van der Velden MA, Verzijlberg K 1984 Chronic purulent maxillary sinusitis in horses. *Tijdschrift voor Dergeneeskunde* 109: 793–799
- Walker MA, Schumacher J, Schmitz DG et al 1998 Cobalt 60 radiotherapy for treatment of squamous cell carcinoma of the nasal cavity and paranasal sinuses in three horses. *Journal of the American Veterinary Medical Association* 212: 848–851
- Watt DA 1970 A case of cryptococcal granuloma in the nasal cavity of a horse. *Australian Veterinary Journal* 46: 493–494
- Weller R, Livesey L, Maierl J et al 2001 Comparison of radiography and scintigraphy in the diagnosis of dental disorders in the horse. *Equine Veterinary Journal* 33: 49–58
- Zamos DT, Schumacher J, Loy JK 1996 Nasopharyngeal conidiobolomycosis in a horse. *Journal of the American Veterinary Medical Association* 208: 100–101