



# Hepatitis E Virus Infection in a Liver Transplant Recipient in the United States: A Case Report

H.S. Te, J. Drobeniuc, S. Kamili, C. Dong, J. Hart, and U.M. Sharapov

---

## ABSTRACT

**Background.** Chronic infection with hepatitis E virus (HEV) has recently been recognized in immunocompromised or immunosuppressed individuals.

**Case Report.** We report a case of concurrent HEV and human herpes virus-6 (HHV-6) infection, documented by serum HEV RNA and HHV-6 DNA, in an orthotopic liver transplant (OLT) recipient in the United States, where HEV genotype 3 infection, although prevalent, is considered to be self-limited and almost always asymptomatic. The coinfection was accompanied by elevated serum aminotransaminases, liver biopsies demonstrating chronic hepatitis, and the presence of HEV RNA in the tissue. After lowering of immunosuppressive therapy and 2 courses of valganciclovir, sequential clearance of the viruses and normalization of the serum aminotransaminases were observed.

**Conclusions.** HEV infection can lead to chronic hepatitis in OLT recipients, and evaluation of this virus should be considered in immunosuppressed individuals with unexplained liver test abnormalities.

---

**I**N THE UNITED STATES, acute hepatitis E virus (HEV) genotype 1 is typically diagnosed in travelers returning from developing countries as a self-limited illness. Rarely, it progresses to liver failure, particularly among pregnant women or patients with underlying liver disease. Whereas travel-related HEV infection has been associated with waterborne HEV genotypes 1 and 2 from developing countries, autochthonous HEV infection in industrialized countries have been associated with zoonotic transmission of genotypes 3 and 4.<sup>1</sup>

The first case of possible chronicity was described in a patient with T-cell lymphoma, where HEV infection was observed over a course of 6 months.<sup>2</sup> More recently, chronic hepatitis E from HEV genotype 3 has been reported in a patient infected with HIV infection<sup>3</sup> and in liver, kidney and pancreas transplant recipients in The Netherlands, France, and Germany.<sup>4-7</sup>

We report a case of concurrent HEV and human herpes virus (HHV)-6 infection in a liver transplant recipient in the United States, and their sequential clearance from the serum after treatment with 2 courses of valganciclovir.

## CASE REPORT

A 60-year-old man of Indian origin underwent orthotopic liver transplantation (OLT) on January 13, 2005, for hepatitis B virus

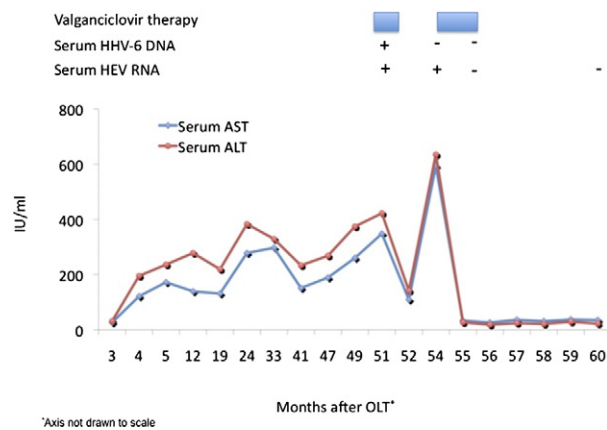
(HBV)-related cirrhosis and hepatocellular carcinoma. At the time of OLT, he was on treatment with lamivudine, and HBV DNA was not detectable in his serum. After OLT, he received hepatitis B immunoglobulin perioperatively and remained on lamivudine to prevent HBV recurrence. All follow-up serum specimens were negative for HBV DNA. Immunosuppression consisted of tacrolimus and sirolimus. The patient recovered well, and liver function tests were normal by 2 months posttransplantation.

Four months after OLT, the patient had elevated liver enzymes with serum aspartate aminotransferase (AST) 121 IU/mL and alanine aminotransferase (ALT) 195 IU/mL (Fig 1) accompanied by fatigue and malaise. Serum HBV DNA, hepatitis C virus (HCV) RNA, cytomegalovirus (CMV) DNA, and antinuclear antibody were all negative. The enzyme elevations persisted, and a liver biopsy obtained at 24 months after OLT revealed chronic hepatitis (grade 2, stage 0) but of unknown etiology. The portal tracts were expanded by mononuclear cell infiltrates composed primarily of

---

From the Center for Liver Diseases (H.S.T.), Department of Medicine, University of Chicago Medicine, Chicago, Illinois; Division of Viral Hepatitis (J.D., S.K., C.D., U.M.S.), Centers for Disease Control and Prevention, Atlanta, Georgia; Department of Pathology (J.H.), University of Chicago Medicine, Chicago, Illinois.

Address correspondence to Helen S. Te, MD, 5841 S. Maryland Ave., MC 7120, Chicago, IL 60637. E-mail: [hte@medicine.bsd.uchicago.edu](mailto:hte@medicine.bsd.uchicago.edu)



**Fig 1.** Course of serum AST, ALT, and viral serologies in relation to valganciclovir therapy.

lymphocytes, with rare scattered admixed eosinophils and macrophages. There were also rare scattered lymphocytes within the lobules, and a few acidophil bodies were identified. Plasma cells were not evident, and there was mild interface activity. Bile ducts were unremarkable. Minimal macrovesicular steatosis, involving <5% of the hepatocytes, was present. No ground glass hepatocytes were identified and immunohistologic stains utilizing hepatitis B surface antigen and hepatitis B core antigen were both negative. No viral intranuclear inclusions were identified.

At 50 months after OLT (March 2009), the patient's liver function tests remained elevated with serum AST 241 IU/mL, ALT 369 IU/mL, and alkaline phosphatase 158 IU/mL, although the total bilirubin remained normal at 0.7 mg/dL; he continued to experience fatigue and malaise, but also complained of dizziness and abdominal bloating.

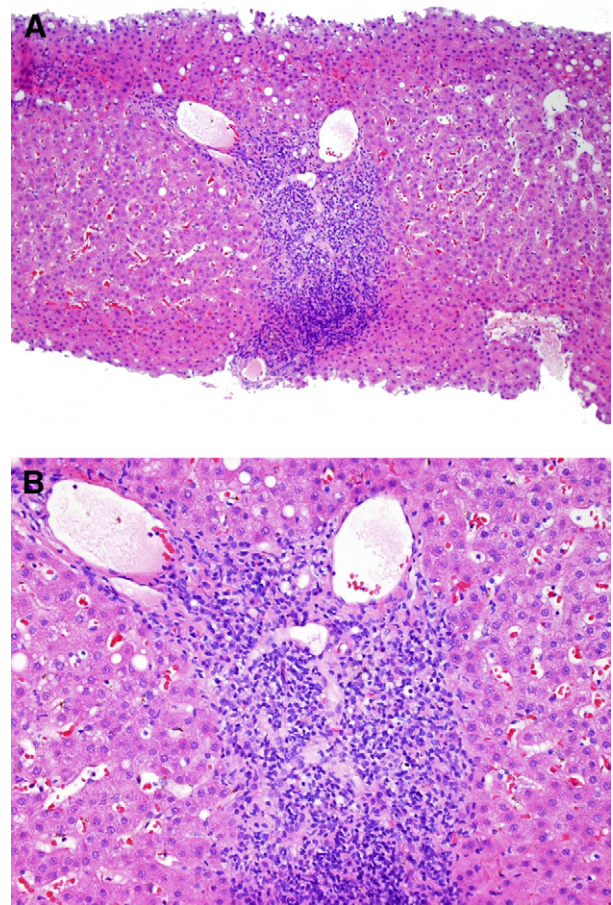
He came to our institution for further management. Additional evaluation included a repeat serum HBV DNA, hepatitis D antibody, HCV RNA, Epstein-Barr virus immunoglobulin (Ig)M, herpes simplex virus IgM, and HIV antibody, which were all negative. However, the serum HHV-6 DNA and anti-HEV IgG were positive, and anti-HEV IgM was negative. Serology for hepatitis E was repeated on a subsequent serum sample collected 3 months later at the Division of Viral Hepatitis Laboratory, US Centers for Disease Control and Prevention. The sample tested positive for both IgM and IgG anti-HEV. Furthermore, HEV RNA was detected in the serum and sequencing studies showed it belonged to HEV genotype 3. A repeat liver biopsy showed similar findings as the first, mild chronic hepatitis (grade 2, stage 0) of unknown etiology (Fig 2). Polymerase chain reaction (PCR) detection of HEV RNA was performed on the second liver biopsy and was positive. The liver tissue was scratched from the block, homogenized, RNA extracted and subjected to PCR as described previously.<sup>8</sup> The patient's last travel to India was 18 months before his visit to our institution, and he denied consuming any raw meat products, or known exposure to live animals or known cases of viral hepatitis.

Immunosuppression was reduced with discontinuation of sirolimus, but tacrolimus was continued (serum trough level, 5.8 mg/dL). He was treated with valganciclovir at 900 mg PO BID for 3 weeks for the HHV-6 viremia, which led to eradication of his HHV-6 DNA and improvement in his liver function tests to serum AST 109 IU/mL and ALT 141 IU/mL (Fig 1). After completing the course of valganciclovir, however, the liver function tests were further ele-

vated to serum AST 593 IU/mL and ALT 635 IU/mL, despite a negative repeat serum HHV-6 DNA titer. The serum HEV RNA remained positive. The patient was then retreated with 8 weeks of valganciclovir 900 mg PO BID. One month later, his liver enzymes normalized, IgM anti-HEV became negative, and HEV RNA at the end of treatment was undetectable. At 6 months' follow-up, his liver function tests remain normal and his symptoms have resolved. In addition, the HEV RNA and serum IgM anti-HEV remained negative; IgG anti-HEV remained positive.

## DISCUSSION

Chronic HEV infection has been recently reported in immunosuppressed or immunocompromised patients, occasionally leading to significant hepatic injury or advanced fibrosis and cirrhosis.<sup>5,6,9,10</sup> Anti-HEV prevalence of 4%–14% has been reported in liver or other solid-organ trans-



**Fig 2.** Histologic findings on liver biopsy, at medium (A) and high power views (B). The portal tracts were expanded by mononuclear cell infiltrates composed primarily of lymphocytes, with rare scattered admixed eosinophils and macrophages. There were also rare scattered lymphocytes within the lobules, and a few acidophil bodies were identified. Plasma cells were not evident, and there was mild interface activity. Bile ducts were unremarkable. Minimal macrovesicular steatosis, involving <5% of the hepatocytes, was present. There was no fibrosis.

plant recipients in France, Germany, and The Netherlands<sup>4,7,9,11</sup>; these rates are within the HEV seroprevalence ranges of the general population of these countries. However, hepatitis E viremia is less common at 1%–6%, and chronic infection accounts for 1%–4%.<sup>4,7,12</sup> All identified chronic infections in this population involved HEV genotype 3,<sup>5,6,9,10</sup> which is commonly found in pigs and pig meats.

In a study population of kidney, kidney–pancreas, and liver transplant recipients with unexplained short-term elevations of liver function tests in France ( $n = 271$ ), 6% were found to harbor HEV RNA in their serum. Six of 14 patients had normalization of their liver function tests within 6 months without specific therapy. Six of the remaining 8 patients underwent liver biopsies, and all biopsies showed chronic hepatitis.<sup>6</sup> In Germany, 4% of OLT recipients ( $n = 226$ ) were positive for HEV antibodies compared with 3% of patients with chronic liver diseases and 1% of healthy controls. One third ( $n = 3$ ) of these previously exposed OLT recipients were viremic, and 1 had advanced fibrosis on histology. Notably, anti-HEVs were detected several months after the detection of HEV RNA.<sup>7</sup> In The Netherlands, 1 patient had HEV RNA but was negative for anti-HEVs.<sup>4</sup>

Chronic HEV infection in the liver transplant recipients occurred within months to years after liver transplantation,<sup>4–7</sup> and may lead to the development of cirrhosis and its complications requiring repeat liver transplantation in 2 patients.<sup>5</sup> The infection, however, recurred after retransplantation in 1 of the 2 patients. Four other liver transplant recipients with chronic HEV infection had significant histologic injury ranging from mild to bridging fibrosis.<sup>6,7</sup> In all of the preceding reports, none of the patients received specific treatment, and only 1 recipient resolved the infection after undergoing repeat liver transplantation.<sup>5</sup>

There is no known treatment for HEV infection, hence providing little option to retard the progression of histologic disease in chronic cases. Most recently, 2 cases of chronic hepatitis E were successfully treated with pegylated interferon alpha-2b for 4–12 months,<sup>13</sup> and with pegylated alpha interferon and ribavirin in another patient.<sup>14</sup> Yet, interferon therapy for chronic hepatitis C in OLT recipients has been associated with many adverse effects, including a risk for graft rejection.<sup>15</sup> Ribavirin, a nucleoside analog, has also been reported to normalize liver function tests and suppress HEV RNA in chronic HEV infection, although the follow-up periods were short<sup>16,17</sup> and relapses have occurred.<sup>18</sup>

Valganciclovir, an orally administered pro-drug of ganciclovir, is used to prevent and treat CMV infection in solid-organ transplant recipients. It is also active against HHV-6, a virus implicated in cases of post-OLT hepatitis but believed by many to be a marker of overimmunosuppression in the OLT recipient rather than a true pathogen. Despite its lack of known action against RNA viruses such as HEV, valganciclovir was used for HEV in this case

because, despite an initial improvement of the serum aminotransaminases during the first course of antiviral therapy, there was a significant rebound as soon as therapy was completed, suggesting a possible activity against HEV.

Although our patient had known HBV infection before OLT, serum HBV DNA remained undetectable throughout the pre- and post-OLT periods. After having elevated serum AST and ALT for 2 years accompanied by a liver biopsy demonstrating chronic hepatitis, the patient was found to have detectable serum HHV-6 DNA and HEV RNA. The initial negative serum IgM test may have been a false negative result owing to a lower sensitivity of the commercial assay. A 3-week course of valganciclovir improved his serum AST and ALT and eradicated the HHV-6 infection, but the clinical hepatitis worsened and HEV RNA persisted. These events highlight the role of HEV as an important and probable causative agent. It was noted that serum HEV RNA clearance and sustained normalization of the liver function tests coincided with the longer repeat treatment course with valganciclovir for 8 weeks, and remained normal during 6-month follow-up period after the therapy. Unfortunately, no banked serum was available to allow for testing for HEV serology or RNA at the onset of the chronic hepatitis at 4 months after OLT, but the normalization of the liver function tests concomitant with clearance of HEV RNA from the serum support the significant role of HEV in the causation of the chronic hepatitis.

Whether hepatitis E in this patient was a new infection or a reactivation of previous infection cannot be clearly established. Despite being born and raised in India, he was infected with HEV genotype 3, which has been identified more often in zoonotic reservoirs and as sporadic infection in humans in developed countries such as Europe and the United States.<sup>19</sup> Infection with genotype 3 in our patient suggests that he may have been exposed to HEV following his arrival in the United States. Hepatitis E antibodies have been detected in 21% of the general population in the United States.<sup>20</sup> The absence of major outbreaks despite the high prevalence of serum HEV antibodies in these countries suggests that the infection is either asymptomatic or mildly symptomatic in immunocompetent individuals. However, its course may follow a different path in immunosuppressed individuals, leading to chronic hepatitis, and in rare cases, potentially to liver failure or death.

In conclusion, HEV infection can lead to chronic hepatitis in OLT recipients, which can progress into a spectrum of hepatic injury, including graft loss. Evaluation for chronic HEV infection should be considered in immunosuppressed individuals with unexplained liver test abnormalities, and serum HEV RNA may be necessary to detect viral presence as seroconversion may be delayed or impaired in these immunosuppressed patients. Effective treatment, particularly for chronic HEV infection, needs to be explored further.

## REFERENCES

1. Nelson KE, Kmush B, Labrique AB. The epidemiology of hepatitis E virus infections in developed countries and among immunocompromised patients. *Expert Rev Anti Infect Ther*. 2011;9:1133–1148.
2. Tamura A, Shimizu YK, Tanaka T, et al. Persistent infection of hepatitis E virus transmitted by blood transfusion in a patient with T-cell lymphoma. *Hepatol Res*. 2007;37:113–120.
3. Dalton HR, Bendall RP, Keane FE, et al. Persistent carriage of hepatitis E virus in patients with HIV infection. *N Engl J Med*. 2009;361:1025–1027.
4. Haagsma EB, Niesters HG, van den Berg AP, et al. Prevalence of hepatitis E virus infection in liver transplant recipients. *Liver Transpl*. 2009;15:1225–1228.
5. Haagsma EB, van den Berg AP, Porte RJ, et al. Chronic hepatitis E virus infection in liver transplant recipients. *Liver Transpl*. 2008;14:547–553.
6. Kamar N, Selves J, Mansuy JM, et al. Hepatitis E virus and chronic hepatitis in organ-transplant recipients. *N Engl J Med*. 2008;358:811–817.
7. Pischke S, Suneetha PV, Baechlein C, et al. Hepatitis E virus infection as a cause of graft hepatitis in liver transplant recipients. *Liver Transpl*. 2010;16:74–82.
8. Meng J, Dai X, Chang JC, Lopareva E, et al. Identification and characterization of the neutralization epitope(s) of the hepatitis E virus. *Virology*. 2001;288:203–211.
9. Kamar N, Mansuy JM, Cointault O, et al. Hepatitis E virus-related cirrhosis in kidney- and kidney-pancreas-transplant recipients. *Am J Transplant*. 2008;8:1744–1748.
10. Gerolami R, Moal V, Colson P. Chronic hepatitis E with cirrhosis in a kidney-transplant recipient. *N Engl J Med*. 2008;358:859–860.
11. Legrand-Abravanel F, Kamar N, et al. Hepatitis E virus infection without reactivation in solid-organ transplant recipients, France. *Emerg Infect Dis*. 2011;17:30–37.
12. Pas SD, de Man RA, Mulders C, et al. Hepatitis E virus infection among solid organ transplant recipients, the Netherlands. *Emerg Infect Dis*. 2012;18:869–872.
13. Haagsma EB, Riezebos-Brilman A, van den Berg AP, et al. Treatment of chronic hepatitis E in liver transplant recipients with pegylated interferon alpha-2b. *Liver Transpl*. 2010;16:474–477.
14. Amon JJ, Drobeniuc J, Bower WA, et al. Locally acquired hepatitis E virus infection, El Paso, Texas. *J Med Virol*. 2006;78:741–746.
15. Stanca CM, Fiel MI, Kontorinis N, et al. Chronic ductopenic rejection in patients with recurrent hepatitis C virus treated with pegylated interferon alfa-2a and ribavirin. *Transplantation*. 2007;84:180–186.
16. Mallet V, Nicand E, Sultanik P, et al. Brief communication: case reports of ribavirin treatment for chronic hepatitis E. *Ann Intern Med*. 2010;153:85–89.
17. Chaillon A, Sirinelli A, De Muret A, et al. Sustained virologic response with ribavirin in chronic hepatitis E virus infection in heart transplantation. *J Heart Lung Transplant*. 2011;30:841–843.
18. Kamar N, Rostaing L, Abravanel F, et al. Ribavirin therapy inhibits viral replication on patients with chronic hepatitis e virus infection. *Gastroenterology*. 2010;139:1612–1618.
19. Teshale EH, Hu DJ, Holmberg SD. The two faces of hepatitis e virus. *Clin Infect Dis*. 2010;51:328–334.
20. Kuniholm MH, Purcell RH, McQuillan GM, et al. Epidemiology of hepatitis E virus in the United States: results from the Third National Health and Nutrition Examination Survey, 1988–1994. *J Infect Dis*. 2009;200:48–56.