

# C L I N I C A L M A N A G E M E N T

# extra

## Hyperbaric Oxygen Therapy: Exploring the Clinical Evidence



**Gretl Lam, BA** • Fourth-year Medical Student • New York University School of Medicine • New York, New York

**Rocky Fontaine, CHT** • Certified Hyperbaric Technologist • Healogics • Philadelphia, Pennsylvania

**Frank L. Ross, MD** • Associate Professor • Department of Surgery • New York University School of Medicine • New York, New York • Associate Director • Helen L. and Martin S. Kimmel Hyperbaric and Advanced Wound Healing Center • New York, New York

**Ernest S. Chiu, MD** • Associate Professor • Department of Surgery • New York University School of Medicine • New York, New York • Director • Helen L. and Martin S. Kimmel Hyperbaric and Advanced Wound Healing Center • New York, New York

All authors, faculty, staff, and planners, including spouses/partners (if any), in any position to control the content of this CME activity have disclosed that they have no financial relationships with, or financial interests in, any commercial companies pertaining to this educational activity.

To earn CME credit, you must read the CME article and complete the quiz online, answering at least 13 of the 18 questions correctly.

This continuing educational activity will expire for physicians on April 30, 2018, and for nurses on April 30, 2020.

All tests are now online only; take the test at <http://cme.lww.com> for physicians and [www.nursingcenter.com](http://www.nursingcenter.com) for nurses. Complete CE/CME information is on the last page of this article.

### GENERAL PURPOSE:

**To provide information about hyperbaric oxygen therapy (HBOT), its mechanisms, indications and safe applications based on clinical evidence.**

### TARGET AUDIENCE:

**This continuing education activity is intended for physicians, physician assistants, nurse practitioners, and nurses with an interest in skin and wound care.**

### LEARNING OBJECTIVES/OUTCOMES:

**After participating in this educational activity, the participant should be better able to:**

- 1. Recall the physiology of wound healing and the mechanisms of action of HBOT.**
- 2. Identify current applications of HBOT based on clinical evidence as well as its risks and contraindications.**

## ABSTRACT

Treating chronic wounds and infections are challenging medical problems worldwide. Hyperbaric oxygen therapy (HBOT), the administration of 100% oxygen at pressures greater than 1.4 atmosphere absolute in a series of treatments, can be used as an adjunctive therapy in many wound care settings because it improves oxygenation and neovascularization and decreases inflammation in chronic wounds. A growing number of studies support the benefits of HBOT for enhancing wound healing and decreasing the likelihood of negative events such as amputation. However, many practitioners are unfamiliar with HBOT. This article provides a general introduction to HBOT, reviews the physiology and mechanisms of behind HBOT, discusses all the indications for HBOT, and explores in-depth the clinical evidence for HBOT in the treatment of arterial insufficiencies, diabetic ulcers, delayed radiation injury, and chronic refractory osteomyelitis.

**KEYWORDS:** chronic wounds, diabetic ulcers, delayed radiation injury, chronic osteomyelitis, hyperbaric chamber, hyperbaric oxygen therapy, nonhealing wounds

ADV SKIN WOUND CARE 2017;30:181-90.

## INTRODUCTION

### Definition

Hyperbaric oxygen therapy (HBOT) is a treatment in which patients breathe 100% oxygen while inside a hyperbaric chamber pressurized to greater than sea level (1 atmosphere absolute [ATA]).<sup>1</sup> For clinical efficacy, the Undersea and Hyperbaric Medical Society specifies that the pressure must be greater than or equal to 1.4 ATA; in clinical practice, pressures applied usually range from 2 to 3 ATA.<sup>1,2</sup> Treatment is delivered in multiplace chambers (Figure 1) or in monoplace chambers (Figure 2). In a monoplace chamber, a single patient breathes compressed pure oxygen. In a multiplace chamber, multiple patients are exposed to pressurized air together while they each breathe pure oxygen through a face mask, hood, or endotracheal tube.<sup>1,2</sup> Depending on the indication, patients can be treated with up to 3 sessions of HBOT daily.<sup>2</sup> In wound care, HBOT is used as an adjunct to standard wound care treatment, and protocols typically involve HBOT treatments of 1.5 to 2 hours per treatment for 20 to 40 treatments<sup>2</sup> and can go even up to 60 treatments.

Because patients must be subjected to increased atmospheric pressures (>1 ATA) during true HBOT treatments, it is important to note that breathing 100% oxygen at 1 ATA or exposing isolated parts of the body to 100% oxygen does not constitute HBOT.<sup>1</sup>

## History of Hyperbaric Oxygen Therapy

The use of HBOT has been attempted since the 1600s, but for many decades, its use was unfounded, as enterprising individuals marketed HBOT as a miracle treatment for a variety of ailments ranging from nervous disorders to influenza to carcinoma. In 1956, however, Ite Boerema published the first clinical paper on HBOT, and for this reason, he is recognized as the father of hyperbaric medicine. Boerema was the chief of surgery at the University of Amsterdam, the Netherlands, and he initially wrote about the intraoperative use of hyperbaric oxygen to prolong safe operating times during cardiac surgery.<sup>3,4</sup> Boerema and his colleagues at the University of Amsterdam continued to study HBOT and later reported on its beneficial effects for the treatment of necrotizing infections and ischemic leg ulcers.<sup>5,6</sup> Since that time, numerous groups have investigated this therapy, and scientifically sound guidelines for the use of HBOT have been developed.

## PHYSIOLOGY AND MECHANISMS

The mechanisms that make HBOT an effective treatment for decompression sickness and arterial gas embolism are different from the mechanisms that make HBOT an effective treatment for chronic wounds, osteomyelitis, and other related conditions. This article briefly discusses the mechanisms by which HBOT relieves illnesses caused by gas bubbles and then explores the phases of normal wound healing and how HBOT improves impaired wound healing.

### Treatment of Illnesses Caused by Gas Bubbles

Exposing patients to increased pressures causes the reduction in volume of gas-filled spaces within the body according to Boyle's law, which states that the pressure and volume of an ideal gas are inversely proportional.<sup>2</sup> Reducing the volume of gas bubbles plays an important role in the acute treatment of arterial gas embolism and decompression sickness.<sup>2</sup> In a 2014 review of HBOT for air or gas embolism, Moon<sup>7</sup> reported that a review of 597 cases of arterial gas embolism demonstrated superior patient outcomes with use of HBOT compared with nonrecompression treatment.<sup>7</sup> Good outcomes are most likely to occur when patients are treated with HBOT as early as possible following embolism formation.<sup>7</sup>

### Phases of Normal Wound Healing

Before discussing how HBOT may improve wound healing, it is important to review the phases of normal wound healing. These phases are hemostasis, inflammation, proliferation, and maturation (Figure 3). Immediately after injury, platelets attach to the injured endothelium, and the subsequent coagulation cascade triggers the formation of a provisional wound matrix to achieve

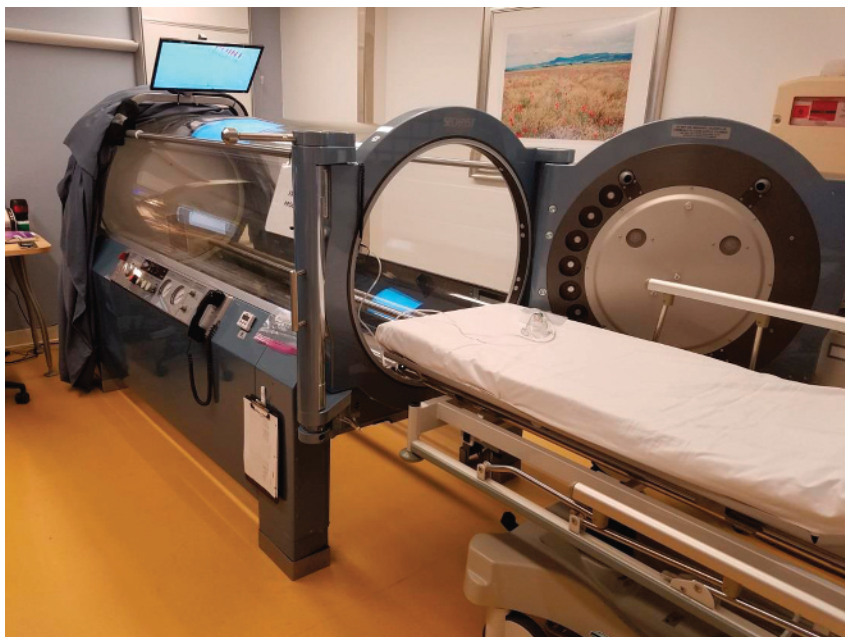---

**Figure 1.**  
**MULTIPLACE CHAMBER**

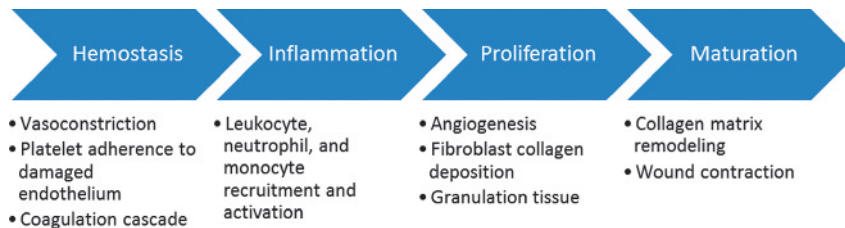


---

**Figure 2.**  
**MONOPLACE CHAMBER**



**Figure 3.**  
**FOUR PHASES OF NORMAL WOUND HEALING**



hemostasis. This process also activates the inflammatory response, which includes leukocyte, neutrophil, and macrophage migration and activation. The inflammatory phase ends a few days after the initial injury, with apoptosis of the aforementioned inflammatory response cells.<sup>8,9</sup>

The proliferative phase begins as the inflammatory phase subsides. During the proliferative phase, neovascularization occurs via vasculogenesis, the recruitment of endothelial progenitor cells from the bone marrow that differentiate into capillary-forming endothelial cells, and via angiogenesis, the formation of new blood vessels from existing endothelial cells in the wound capillary network.<sup>10</sup> Robust neovascularization is vital to the formation of granulation tissue because it supplies the migrating and proliferating dermal and epidermal cells in the wound bed with oxygen and nutrients. Key proliferating cells are fibroblasts, which create a new matrix of connective tissue to close wound gaps and restore mechanical strength to the wound.<sup>9</sup>

In the final phase, wound contraction and matrix remodeling occur, resulting in scar tissue with 80% the tensile strength of unwounded skin.<sup>8,9,11</sup> Chronic wounds are characterized by a prolonged inflammatory phase, with an inability to progress to the proliferative phase or form newly vascularized granulation tissue.<sup>8,9</sup>

### Accelerating Impaired Healing

In HBOT, increasing the partial pressure of oxygen inhaled by a patient—by administering 100% oxygen and elevating the pressure—increases the amount of oxygen that can be dissolved in a patient’s blood serum in accordance with Henry’s law, which states that the amount of ideal gas dissolved in solution is directly proportional to its partial pressure.<sup>12</sup> During treatment, arterial oxygen tension often exceeds 2000 mm Hg, and oxygen levels of 200 to 400 mm Hg occur in tissues.<sup>2</sup>

During tissue repair and wound healing, oxygen demand and utilization rates are increased, and chronic hypoxia in a wound is associated with reduced or absent wound healing.<sup>12</sup> Conversely,

increased oxygen supply to hypoxic tissues has multiple beneficial effects on wound healing.<sup>13</sup> Because oxygen cannot be stored in tissue, daily HBOT supports an adequate oxygen supply to the site of injury to promote wound healing progression from the inflammatory phase to the proliferative phase. Increased oxygen concentrations lead to an increased production of reactive oxygen species and reactive nitrogen species, which play important roles in signaling pathways for promoting neovascularization, matrix formation, and decreasing inflammation (Figure 4).<sup>2</sup> Hypoxia is a stimulus for angiogenesis. New blood vessel formation, however, is dependent on normal levels of oxygenation. Hyperbaric oxygen therapy creates a gradient between tissues of low oxygenation in the center to higher concentrations at the periphery, thus creating a driving force conducive to neovascularization.

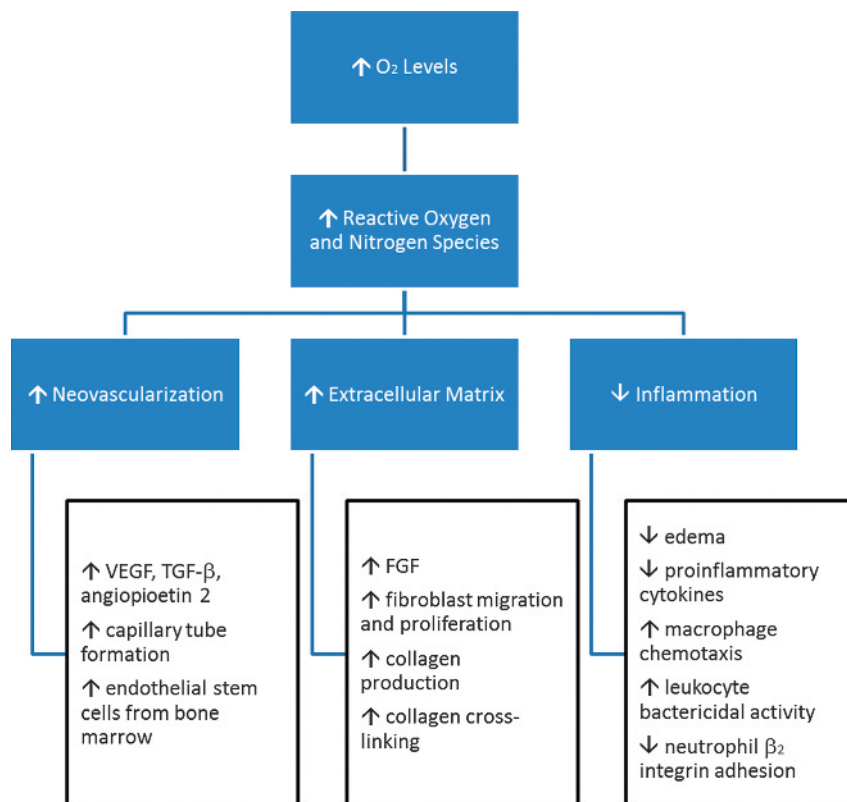
Improved neovascularization occurs through both local and distant processes. Locally, reactive oxygen species and reactive nitrogen species signal an increased production of wound growth factors, such as vascular endothelial growth factor (the most specific factor for neovascularization), transforming growth factor  $\beta$ 1, and angiopoietin 2.<sup>2,13</sup> Endothelial cells exposed to hyperbaric oxygen exhibit enhanced capillary tube formation and enhanced oxidative stress resistance.<sup>2</sup>

Although hypoxia stimulates neovascularization, chronic hypoxia actually inhibits new vessel formation. For this reason, hyperoxia induced by HBOT promotes the neovascularization and healing of chronic wounds.<sup>12</sup> In addition, it is important to distinguish between oxidative stress and oxygen toxicity. Excessive reactive oxygen species are associated with harmful effects; however, studies have shown that the body’s antioxidant defenses protect against the limited number of reactive oxygen species generated by HBOT treatment sessions.<sup>2</sup>

Hyperbaric oxygen therapy improves neovascularization by acting more distantly from the wound site. Increased oxygen leads to increased production of nitric oxide in the bone marrow, and multiple studies have shown that this stimulates increased

Figure 4.

MECHANISMS OF HYPERBARIC OXYGEN THERAPY IN WOUND HEALING



Abbreviations: FGF, fibroblast growth factor; TGF-β, transforming growth factor beta; VEGF, vascular endothelial growth factor

vasculogenic stem/progenitor cell mobilization from the bone marrow in healthy human subjects, diabetic patients, and patients previously treated with radiation therapy, leading to more stem cells recruited to skin wounds and accelerated blood vessel formation.<sup>2,14,15</sup> Hyperoxia also improves the function of endothelial progenitor cells once they arrive at the wound site to differentiate into capillary-forming endothelial cells.<sup>2</sup>

Extracellular matrix formation is an oxygen-dependent process linked closely to neovascularization.<sup>2</sup> Fibroblast growth factor production is also increased by HBOT, promoting fibroblast migration and proliferation.<sup>2,12,13</sup> Increased oxygen stimulates the proliferating fibroblasts to produce collagen at increased rates and also enhances collagen cross-linking to improve tissue tensile strengths.<sup>2,12</sup>

Hyperoxia also promotes decreased inflammation by impacting 3 major inflammatory cell types—macrophages, leukocytes, and

neutrophils—and by inducing vasoconstriction to decrease local edema.<sup>13</sup> Macrophages are impacted in 2 very different ways. First, HBOT has been shown to reduce expression of proinflammatory cytokines by monocyte-macrophages in both animal and human studies.<sup>2,13</sup> Second, HBOT promotes macrophage chemotaxis to facilitate the clean-up of cellular debris at the wound site. Increased oxygen also enhances the bactericidal activity of leukocytes.<sup>12,13</sup> Finally, HBOT inhibits neutrophil β2 integrin adhesion in both animals and humans, and this mechanism has been shown to decrease tissue reperfusion injuries without reducing the neutrophils' antibacterial function.<sup>2</sup>

In summary, chronic wounds are characterized by hypoxia, impaired angiogenesis, and prolonged inflammation. Hyperbaric oxygen therapy is a successful adjunctive treatment for wound healing because it acts through diverse mechanisms to promote angiogenesis and decrease inflammation.



## HYPERBARIC OXYGEN THERAPY INDICATIONS

In 1976, the Undersea and Hyperbaric Medical Society (at the time, Undersea Medical Society) began maintaining a list of conditions for which HBOT is medically indicated; since its development, this list is updated every 2 years to include new indications based on available clinical evidence (Table 1).<sup>5</sup> This review focuses on HBOT's applications in wound care. Some of the most common chronic wounds encountered in medical practice result from diabetes, arterial and/or venous disease, and radiation therapy.<sup>6</sup> The authors discuss the clinical evidence for HBOT in the treatment of arterial insufficiencies, diabetic wounds, radiation injury, and chronic refractory osteomyelitis.

## APPLICATIONS OF HYPERBARIC OXYGEN THERAPY IN THE WOUND CARE SETTING

### Arterial Insufficiency and Diabetic Wounds

The Undersea and Hyperbaric Medical Society categorizes diabetic wounds under the indication of arterial insufficiencies because much of the existing HBOT literature discusses wounds that are concurrently diabetic and ischemic.<sup>1</sup> Consequently, this article discusses the clinical evidence for these conditions together.

Treating diabetic ulcers of the lower extremity is an important issue in healthcare. According to the World Health Organization, an estimated 347 million people suffer from diabetes mellitus.<sup>16</sup> Approximately 1 in 20 persons with diabetes will develop a foot

ulcer, and more than 10% of these ulcers will lead to amputation.<sup>13</sup> More than 60% of nontraumatic lower-extremity amputations occur in patients with diabetes.<sup>17</sup> In addition, long-term studies have found that 45% of patients with a diagnosis of diabetic foot ulcers are deceased at 5-year follow-up.<sup>18</sup>

Diabetic peripheral neuropathy that leads to the loss of protective sensation in the foot, peripheral arterial disease (PAD), limited foot mobility, and foot deformities are the main challenges to the prevention and treatment of diabetic foot ulcers.<sup>19</sup> The National Health and Nutrition Examination Survey of 4769 participants found that 13.9% of patients with diabetes also had PAD.<sup>20</sup> Because PAD independently impairs wound healing, it significantly increases the risk of lower-extremity amputation in patients (odds ratio [OR], 12.97; 95% confidence interval [CI], 3.44–48.88).<sup>21</sup> These nonhealing wounds also put patients at continuous risk of local and systemic infection, sepsis, and death.<sup>19</sup>

Treatment of diabetic and/or ischemic foot ulcers requires a multimodal approach, involving local wound care, good glycemic control, revascularization of ischemic limbs, treatment of infections, and pressure off-loading.<sup>13</sup> Unfortunately, even with optimal care, complete wound healing rates can be as low 60% a year.<sup>13</sup> Hyperbaric oxygen therapy has been used as an adjunctive therapy for patients with refractory ulcers.

A range of studies have examined the efficacy of HBOT for improving wound healing and reducing amputation rates in patients with diabetic ulcers. Earlier studies reported very favorable results, which are summarized in a 2009 systematic review by Goldman et al.<sup>13,22</sup> Goldman et al<sup>22</sup> considered data from 8 studies ranging from retrospective case series to randomized controlled trials and concluded that in diabetic patients HBOT significantly improved chances of wound healing (OR, 9.992; 95% CI, 3.972–25.123) and reduced chances of amputation (OR, 0.242; 95% CI, 0.137–0.428).<sup>22</sup>

In 2014, Stoekenbroek et al<sup>13</sup> performed a systematic review of randomized controlled trials that included 3 studies of ischemic diabetic ulcers (measured by ankle-brachial index, great toe-brachial index, ankle blood pressure, or toe blood pressure), 2 studies of nonischemic ulcers, and 2 studies that did not specify ulcer type. Two of the studies on ischemic diabetic ulcers found that HBOT improved rates of complete wound healing at 1-year follow-up (number needed to treat [NNT] 1.8; 95% CI, 1.1–4.6) but did not impact amputation rates, whereas the third study did not report on wound healing rates but found that HBOT significantly decreased major amputation rates (NNT, 4.2; 95% CI, 2.4–17).<sup>13,23–25</sup> The 2 studies on nonischemic ulcers reported no significant differences in wound healing or amputation rates after HBOT.<sup>13,26,27</sup> Finally, 1 of the studies that did not specify ulcer type reported a significant decrease in major amputation rates following HBOT (NNT, 2.9; 95% CI, 2.1–4.8).<sup>13,28</sup>

**Table 1.**

### INDICATIONS FOR HYPERBARIC OXYGEN THERAPY

1. Air or gas embolism
2. Carbon monoxide poisoning
3. Clostridial myositis and myonecrosis (gas gangrene)
4. Crush injury, compartment syndrome, and other acute traumatic ischemias
5. Decompression sickness
6. Arterial insufficiencies
7. Severe anemia
8. Intracranial abscess
9. Necrotizing soft tissue infections
10. Osteomyelitis (refractory)
11. Delayed radiation injury (soft tissue and bony necrosis)
12. Compromised grafts and flaps
13. Acute thermal burn injury
14. Idiopathic sudden sensorineural hearing loss

More recently, the 2015 Cochrane review of HBOT for chronic wounds examined 8 randomized controlled trials of patients with diabetic ulcers. Based on these studies, they reported that HBOT appeared to improve short-term wound healing (up to 6 weeks) and might decrease rates of major amputation. More studies on long-term wound healing were needed to draw further conclusions, and there were no trials that studied arterial ulcers independently.<sup>6</sup>

Ultimately, the literature most strongly supports use of HBOT in cases of ischemic diabetic ulcers to improve wound healing and decrease amputation rates. Current evidence for the use of HBOT in nonischemic diabetic ulcers and in nondiabetic arterial ulcers is more limited. A recent study by Margolis et al<sup>29</sup> used a longitudinal cohort study looking at more than 6000 patients with diabetic foot ulcers and adequate arterial inflow and response to HBOT. They concluded that HBOT neither reduced the risk of amputation nor improved the likelihood that the wound would heal.<sup>29</sup> Past studies have generally been hindered by small sample sizes, variable HBOT regimens, and differing outcome measures, leading to inconsistent results.<sup>6,13</sup> Chronic diabetic and/or ischemic ulcers are a major healthcare challenge that HBOT can help to address, and additional studies would clarify and perhaps expand its clinical applications.

## Delayed Radiation Injury

Radiation therapy is a common and well-established treatment for many malignancies.<sup>30</sup> Although it is an effective treatment, radiation injury can occur to the normal tissues surrounding the tumor. This injury can occur months to years after radiation therapy and occurs as a result of microvasculature deterioration and increased fibrosis, leading to tissue ischemia.<sup>30,31</sup> Without sufficient oxygenation, the tissue cannot maintain normal function and integrity, and ulcers or areas of radionecrosis can develop. Some of the most common radiation injuries are osteoradionecrosis, laryngeal radionecrosis, dermal soft tissue radionecrosis, radiation-induced cystitis, and radiation-induced proctitis.<sup>32</sup>

Because HBOT increases oxygen delivery to tissues, it was proposed as an adjunctive treatment for such injuries. The current literature supports the use of HBOT for several different types of radiation-related injuries.

The 2012 Cochrane review on HBOT for late radiation tissue injury examined 11 randomized controlled trials and concluded that HBOT may improve outcomes in patients with radiation injury to the head, neck, rectum, and anus, such as after hemimandibulectomy with mandible reconstruction, and in cases of radiation proctitis.<sup>32</sup>

Subsequently, Hoggan and Cameron<sup>30</sup> conducted a systematic review in 2014 that yielded similar findings, supporting the use of HBOT for radiation tissue injury to the head, neck, rectum,

and anus. In 1 randomized controlled trial, significantly more patients receiving HBOT versus a sham treatment experienced at least “moderate” healing of proctitis (87.5 vs 62.5%,  $P = .0009$ ).<sup>30,33</sup> In the head and neck, a randomized controlled trial of patients who had soft tissue flap reconstruction in previously irradiated areas found that patients treated with HBOT were less likely to develop wound infection, wound dehiscence, and delayed wound healing.<sup>30</sup>

Neither the Cochrane review nor the systematic review by Hoggan and Cameron<sup>30</sup> found strong evidence supporting the use of HBOT for radiation injury to other tissues such as radiation-induced cystitis and irradiated neurologic tissue.<sup>30,32</sup>

As in the case of diabetic ulcers, the number of studies on HBOT for radiation injury is limited, and they involve only a small number of patients. However, the body of literature increases yearly, and these studies generally support the benefit of HBOT. For example, a 2015 retrospective study reported successful or improved outcomes following HBOT in 95.7% of patients with osteoradionecrosis ( $n = 23$ ), and 88.1% with soft tissue radiation necrosis ( $n = 42$ ).<sup>34</sup> Thus, HBOT is a promising adjunctive treatment for several types of radiation injuries.

## Chronic Refractory Osteomyelitis

Osteomyelitis is an infection of bone or bone marrow, usually caused by pyogenic bacteria or mycobacteria. Refractory osteomyelitis is defined as a chronic osteomyelitis that persists or recurs after appropriate interventions have been performed or where acute osteomyelitis has not responded to accepted management techniques.<sup>35</sup> *Staphylococcus aureus* is the most common cause of bone infection in adults. *Staphylococcus epidermidis*, *Pseudomonas aeruginosa*, *Serratia marcescens*, and *Escherichia coli* may also be isolated, especially in cases of chronic osteomyelitis caused by contiguous soft tissue infection.<sup>35</sup>

Standard treatment of chronic osteomyelitis involves appropriate antibiotic therapy and surgical debridement of infected or necrotic tissue. However, overall recurrence rates after prolonged antibiotic therapy and surgical debridement remain approximately 30% at 1 year, and recurrence rates for cases caused by *P aeruginosa* are close to 50%.<sup>35</sup>

Hyperbaric oxygen therapy is an adjunctive treatment for patients with chronic refractory osteomyelitis. Because chronic refractory osteomyelitis is less common than diabetic ulcers and radiation injury, it is more difficult to study, and at the time of writing, no randomized controlled trials have evaluated the efficacy of HBOT for this indication. However, a number of case series and cohort studies suggest that HBOT improves clinical outcomes.

A systematic review by Goldman et al<sup>22</sup> summarized the findings of 15 observational studies on HBOT for recalcitrant osteomyelitis; 14 of these studies reported positive findings,

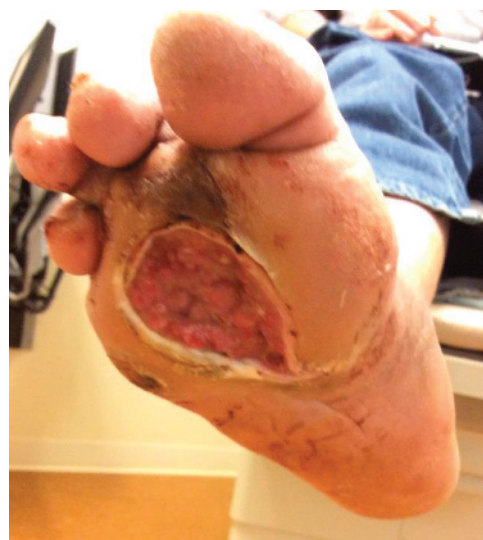whereas 1 study reported equivocal findings. Overall, the median remission rate was 89% (range, 37%-100%) for the 309 patients in the 15 studies.<sup>22</sup> A subsequent retrospective study reported successful or improved outcomes in 82.6% of patients (n = 23) who received HBOT for chronic refractory osteomyelitis.<sup>34</sup>

Thus, current data suggest that HBOT is a useful adjunct in the treatment of chronic refractory osteomyelitis. Additional studies, particularly randomized controlled trials, would help to validate its efficacy.

## RISKS AND CONTRAINDICATIONS

Hyperbaric oxygen therapy is a safe treatment modality with few serious adverse effects and contraindications (Table 2). Most adverse effects are minor and reversible. Patients may experience progressive myopia during treatment due to pressure-induced lens deformity, but this typically reverses within 6 weeks of treatment termination.<sup>2,12,22</sup> Hyperbaric oxygen therapy can also cause cataracts to mature more quickly but does not cause new cataract formation.<sup>22</sup> Barotrauma to the ear and sinuses is another common adverse effect, particularly in older patient populations, but most cases are mild and reversible.<sup>12,22</sup> Serious adverse effects of HBOT, resulting from oxygen toxicity, are seizures, congestive heart failure (CHF) exacerbation, pulmonary edema, and retinal changes, but these are rare.<sup>12</sup> For example, reported incidences of

**Figure 5.**  
**RIGHT MID-PLANTAR DIABETIC FOOT ULCER**



grand mal seizures following HBOT range from 1 to 4 cases in 10,000 patient treatments.<sup>2</sup>

The most serious contraindication to HBOT is an unrecognized and/or untreated pneumothorax, which would worsen under chamber pressure.<sup>12</sup> Relative contraindications to HBOT include febrile illness, which lowers the central nervous system seizure toxicity threshold, poorly controlled seizure disorder, and hyperthyroidism.<sup>22</sup> Because oxygen is a vasoconstrictor, and HBOT may increase cardiac afterload, CHF is also a relative contraindication for anyone with an ejection fraction of less than 30%. Other relative contradictions include patients with underlying pulmonary disease, such as chronic obstructive pulmonary disease, and severe claustrophobia.<sup>22</sup>

## SAFETY PRECAUTIONS

The primary safety concern during the administration of HBOT is the prevention of fire. For a fire to occur in a hyperbaric chamber, 3 elements must exist:

- heat
- ignition source
- oxygen

This is known as the fire triangle. Patients must go through a daily checklist prior to entering the chamber. In addition, they are required to wear cotton-based hospital gowns/scrubs (100% cotton or 50/50 cotton/polyester blend). No outside clothing or shoes are allowed in the chamber. Patients undergo a pre-treatment education process, and a list of items/materials that are

**Table 2.**

### POSSIBLE ADVERSE EVENTS AND CONTRAINDICATIONS OF HYPERBARIC OXYGEN THERAPY

#### Minor Adverse Events

- Barotrauma to ears and sinuses
- Myopia
- Accelerated cataract maturation

#### Major Adverse Events

- Seizures
- Congestive heart failure (CHF) exacerbation
- Pulmonary edema
- Retinal changes

#### Relative Contraindications

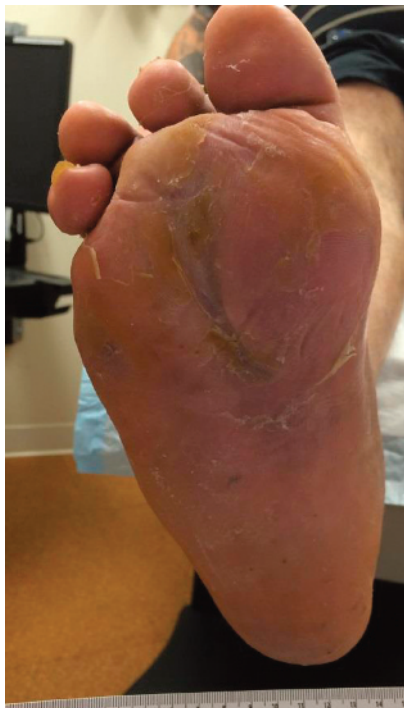- Febrile illness
- Seizure disorder
- Hyperthyroidism
- CHF
- Pulmonary disease (eg, chronic obstructive pulmonary disease)
- Severe claustrophobia

#### Absolute Contraindications

- Untreated pneumothorax



**Figure 6.**  
**HEALED RIGHT MID-PLANTAR DIABETIC FOOT ULCER**



forbidden in the chamber is provided to them. Examples include newspaper, hairspray, nail polish, cell phones, hand warmers, heating pads, and perfume. Items that may cause sparks or damage the acrylic tube of monoplace chambers are also prohibited. Examples include keys, coins, jewelry, and toys.

### CASE EXAMPLE

The patient is a 46-year-old man employed in a job that requires him to be on his feet most of the day lifting heavy parcels. He has type 2 diabetes mellitus and a prior amputation of his right fifth toe from a diabetic foot infection. He presented with a large ulcer on the plantar surface of his right foot that penetrated to the joints of his third and fourth right toes and was classified as a grade III Wagner diabetic foot ulcer. When other therapies failed, the wound was treated topically with a silver alginate, and off-loading was provided by total contact casting. He received 30 90-minute treatments of HBOT at 2.0 ATA. The patient progressed to complete wound healing after 10 weeks, which included the HBOT. Pretreatment and posttreatment photographs are provided (Figures 5 and 6).

### CONCLUSIONS

Hyperbaric oxygen therapy has been in medical use for half a century. Its mechanisms of action in the healing of chronic wounds include promoting neovascularization and decreasing inflammation. Clinical studies have demonstrated its efficacy in treating various conditions, and it is currently used for 14 different indications. For example, it is a useful adjunctive therapy in the treatment of ischemic diabetic wounds, radiation-induced wounds, and chronic osteomyelitis. Additional studies are needed to determine the full benefits of HBOT.

### PRACTICE PEARLS

- Hyperbaric oxygen therapy is a treatment in which patients breathe 100% oxygen while inside a pressurized hyperbaric chamber. For wound care, HBOT treatment regimens consist of 1.5 to 2 hours per treatment for 20 to 40 treatments, and up to 60 treatments if needed.
- The Undersea and Hyperbaric Medical Society maintains an evidence-based list of indications for HBOT; there are currently 14 indications.
- These 14 indications include arterial insufficiency wounds (ie, ischemic diabetic ulcers), delayed radiation injury (ie, to the soft tissue, osteoradionecrosis, cystitis, proctitis), and chronic refractory osteomyelitis.
- Common and reversible adverse effects of HBOT include barotrauma to the ear and myopia.
- Serious adverse events are rare but include seizures, CHF exacerbation, pulmonary edema, and retinal changes.
- Untreated pneumothorax is an absolute contraindication to HBOT.

### REFERENCES

1. Undersea and Hyperbaric Medical Society. Indications for hyperbaric oxygen therapy. <https://www.uhms.org/resources/hbo-indications.html>. Last accessed January 25, 2017.
2. Thom SR. Hyperbaric oxygen: its mechanisms and efficacy. *Plast Reconstr Surg* 2011; 127(Suppl 1):131S-41S.
3. Camporesi EM, Bosco G. Mechanisms of action of hyperbaric oxygen therapy. *Undersea Hyperb Med* 2014;41:247-52.
4. Ozirk F, Emmertan AT, Inanir I. Hyperbaric oxygen therapy for the management of chronic wounds. *Cutan Ocul Toxicol* 2013;32:72-7.
5. Dauwe PB, Pulikkottil BJ, Lavery L, Stuzin JM, Rohrich RJ. Does hyperbaric oxygen therapy work in facilitating acute wound healing: a systematic review. *Plast Reconstr Surg* 2014;41:159-66.
6. Kranke P, Bennett MH, Martyn-St James M, Schnabel A, Debus SE, Weibel S. Hyperbaric oxygen therapy for chronic wounds. *Cochrane Database Syst Rev* 2015;6:CD004123.
7. Moon RE. Hyperbaric oxygen treatment for air or gas embolism. *Undersea Hyperb Med* 2014;41:159-66.
8. Demidova-Rice TN, Hamblin MR, Herman IM. Acute and impaired wound healing: pathophysiology and current methods for drug delivery, part 1: normal and chronic wounds: biology, causes, and approaches to care. *Adv Skin Wound Care* 2012;25:304-14.
9. Reinke JM, Sorg H. Wound repair and regeneration. *Eur Surg Res* 2012;49:35-43.
10. Stavrou D. Neovascularization in wound healing. *J Wound Care* 2008;17:298-300.

11. Levenson SM, Geever EF, Crowley LV, Oates JF 3rd, Berard CW, Rosen H. The healing of rat skin wounds. *Ann Surg* 1965;161:293-308.
12. Howard MA, Asmis R, Evans KK, Mustoe TA. Oxygen and wound care: a review of current therapeutic modalities and future direction. *Wound Repair Regen* 2013;21:503-11.
13. Stoekenbroek RM, Santema TB, Legemate DA, Ubbink DT, van den Brink A, Koelemay MJ. Hyperbaric oxygen for the treatment of diabetic foot ulcers: a systematic review. *Eur J Vasc Endovasc Surg* 2014;47:647-55.
14. Thom SR, Bhopale VM, Velazquez OC, Goldstein LJ, Thom LH, Buerk DG. Stem cell mobilization by hyperbaric oxygen. *Am J Physiol Heart Circ Physiol* 2006;290:H1378-86.
15. Thom SR, Milovanova TN, Yang M, et al. Vasculogenic stem cell mobilization and wound recruitment in diabetic patients: increased cell number and intracellular regulatory protein content associated with hyperbaric oxygen therapy. *Wound Repair Regen* 2011;19:149-61.
16. World Health Organization. Diabetes. [www.who.int/mediacentre/factsheets/fs312/en/](http://www.who.int/mediacentre/factsheets/fs312/en/). Last accessed January 25, 2017.
17. National Diabetes Fact Sheet, 2011. Center for Disease Control Web site. [https://www.cdc.gov/diabetes/pubs/pdf/ndfs\\_2011.pdf](https://www.cdc.gov/diabetes/pubs/pdf/ndfs_2011.pdf). Last accessed January 25, 2017.
18. Morbach S, Furchert H, Groblinghoff U, et al. Long-term prognosis of diabetic foot patients and their limbs: amputation and death over the course of a decade. *Diabetes Care* 2012;35:2021-7.
19. Fedorko L, Bowen JM, Jones W, et al. Hyperbaric oxygen therapy does not reduce indications for amputation in patients with diabetes with nonhealing ulcers of the lower limb: a prospective, double-blind, randomized controlled clinical trial. *Diabetes Care* 2016;39:392-9.
20. Cheung CL, Lam KS, Cheung BM. Diabetes is associated with increased risks of low lean mass and slow gait speed when peripheral artery disease is present. *J Diabetes Complications* 2016;30:306-11.
21. Pemayun TG, Naibaho RM, Novitasari D, Amin N, Minuljo TT. Risk factors for lower extremity amputation in patients with diabetic foot ulcers: a hospital-based case-control study. *Diabet Foot Ankle* 2015;6:29629.
22. Goldman RJ. Hyperbaric oxygen therapy for wound healing and limb salvage: a systematic review. *PM R* 2009;1:471-89.
23. Löndahl M, Katzman P, Nilsson A, Hammarlund C. Hyperbaric oxygen therapy facilitates healing of chronic foot ulcers in patients with diabetes. *Diabetes Care* 2010;33:998-1003.
24. Abidia A, Laden G, Kuhan G, et al. The role of hyperbaric oxygen therapy in ischemic diabetic lower extremity ulcers: a double-blind randomised-controlled trial. *Eur J Vasc Endovasc Surg* 2003;25:513-8.
25. Faglia E, Favale F, Aldeghi A, et al. Adjunctive systemic hyperbaric oxygen therapy in treatment of severe prevalently ischemic diabetic foot ulcer: a randomized study. *Diabetes Care* 1996;19:1338-43.
26. Kessler L, Bilbault P, Ortga F, et al. Hyperbaric oxygenation accelerates the healing rate of nonischemic chronic diabetic foot ulcers: a prospective randomized study. *Diabetes Care* 2003;26:2378-82.
27. Ma L, Li P, Shi Z, Hou T, Chen X, Du J. A prospective, randomized, controlled study of hyperbaric oxygen therapy: effects on healing and oxidative stress of ulcer tissue in patients with a diabetic foot ulcer. *Ostomy Wound Manage* 2013;59(3):18-24.
28. Duzgan AP, Satir HZ, Ozozan O, Saylam B, Kulah B, Coskun F. Effect of hyperbaric oxygen therapy on healing of diabetic foot ulcers. *J Foot Ankle Surg* 2008;47:515-9.
29. Margolis DJ, Gupta J, Hoffstad O. Lack of effectiveness of hyperbaric oxygen therapy for the treatment of diabetic foot ulcer and the prevention of amputation: a cohort study. *Diabetes Care* 2013;36:1961-66.
30. Hoggan BL, Cameron AL. Systematic review of hyperbaric oxygen therapy for the treatment of non-neurological soft tissue radiation-related injuries. *Support Care Cancer* 2014;22:1715-26.
31. Niezgoda JA, Serena TE, Carter MJ. Outcomes of radiation injuries using hyperbaric oxygen therapy: an observational cohort study. *Adv Skin Wound Care* 2016;29:12-9.
32. Bennett MH, Feldmeier J, Hampson NB, Smee R, Milross C. Hyperbaric oxygen therapy for late radiation tissue injury. *Cochrane Database Syst Rev* 2012;5:CD005005.
33. Clarke RE, Tenorio LM, Hussey JR, et al. Hyperbaric oxygen treatment of chronic refractory radiation proctitis: a randomized and controlled double-blind crossover trial with long-term follow-up. *Int J Radiat Oncol Biol Phys* 2008;72:134-43.
34. Skeik N, Porten BR, Isaacson E, et al. Hyperbaric oxygen treatment outcome for different indications at a single center. *Ann Vasc Surg* 2015;29:206-214.
35. Hatzenbuehler J, Pulling TJ. Diagnosis and management of osteomyelitis. *Am Fam Physician* 2011;84:1027-33.

For more than 153 additional continuing education articles related to Skin and Wound Care topics, go to [NursingCenter.com/CE](http://NursingCenter.com/CE).

## CE CONNECTION

### CONTINUING MEDICAL EDUCATION INFORMATION FOR PHYSICIANS

Lippincott Continuing Medical Education Institute, Inc. is accredited by the Accreditation Council for Continuing Medical Education to provide continuing medical education for physicians.

Lippincott Continuing Medical Education Institute, Inc. designates this journal-based CME activity for a maximum of 1 *AMA PRA Category 1 Credit™*. Physicians should claim only the credit commensurate with the extent of their participation in the activity.

### PROVIDER ACCREDITATION INFORMATION FOR NURSES

Lippincott Williams & Wilkins, publisher of the *Advances in Skin & Wound Care* journal, will award 1.0 contact hour for this continuing nursing education activity.

LWW is accredited as a provider of continuing nursing education by the American Nurses Credentialing Center's Commission on Accreditation.

This activity is also provider approved by the California Board of Registered Nursing, Provider Number CEP 11749 for 1.0 contact hour. LWW is also an approved provider by the District of Columbia, Georgia, and Florida CE Broker #50-1223. Your certificate is valid in all states.

### OTHER HEALTH PROFESSIONALS

This activity provides ANCC credit for nurses and *AMA PRA Category 1 Credit™* for MDs and

DOs only. All other healthcare professionals participating in this activity will receive a certificate of participation that may be useful to your individual profession's CE requirements.

### CONTINUING EDUCATION INSTRUCTIONS

- Read the article beginning on page 181. For nurses who wish to take the test for CE contact hours, visit [www.nursingcenter.com](http://www.nursingcenter.com). For physicians, who wish to take the test for CME credit, visit <http://cme.lww.com>.
- You will need to register your personal CE Planner account before taking online tests. Your planner will keep track of all your Lippincott Williams & Wilkins online CE activities for you.
- There is only one correct answer for each question. A passing score for this test is 13 correct answers. If you pass, you can print your certificate of earned contact hours or credit and access the answer key. Nurses who fail have the option of taking the test again at no additional cost. Only the first entry sent by physicians will be accepted for credit.

Registration Deadline: April 30, 2019 (nurses); April 30, 2018 (physicians).

### PAYMENT AND DISCOUNTS

- The registration fee for this test is \$12.95 for nurses; \$22 for physicians.