

Marshall Z. Schwartz

## INTRODUCTION

Gastroschisis is one of several congenital abdominal wall defects that evolves in the first four post-conception weeks. It is generally accepted that this congenital abdominal wall defect is embryologically different from omphalocele. The anomaly is thought to be the result of a defect at the site where the second umbilical vein involutes. Nonrotation of the bowel always accompanies this anomaly and there is an increase in intestinal abnormalities including atresia (mostly involving the small intestine) perforation, and infarction resulting from in utero midgut volvulus or vascular thrombosis. However, unlike omphalocele, there is no increase in anomalies of other organs. The incidence of gastroschisis is approximately 1 in 4,000–6,000 live births. Infants with gastroschisis typically are slightly premature (35–37 weeks of gestation) and frequently have growth retardation with birth weights from approximately 2000–2500 g.

Most abdominal wall defects can be diagnosed in utero after 14 weeks gestation when the fetal midgut has returned to the peritoneal cavity. If gastroschisis is noted on fetal ultrasonography it is strongly recommended that serial examinations be performed looking for changes in the size and thickness of the bowel as well as the diameter of the abdominal wall defect. Significant bowel wall thickening and bowel dilatation, especially associated with a decrease in

the diameter of the abdominal wall defect, may be indications for earlier delivery to avoid bowel infarction. It is important to provide an opportunity for the family to meet with a fetal management team including perinatology, paediatric surgery, and neonatology to review the problem and likely course following delivery. The recommended mode of delivery over the past several decades has been somewhat controversial. It is generally believed that caesarian section is not necessary unless for obstetric reasons. Elective premature delivery is also unnecessary.

Management immediately following delivery and prior to surgical correction requires prompt attention and is critical to the outcome. The two most important goals are to provide a mechanism of maintaining normal thermogenesis and establishing intravenous access to provide appropriate fluid resuscitation. Infants with gastroschisis are usually hypovolemic and require at least 125–150% of maintenance intravenous fluid to establish and maintain adequate hydration. Establishing intravenous access initially can be done through a peripheral intravenous site. Infants with gastroschisis require central venous access. Once intravenous access is established, it is optimal to institute broad spectrum antibiotic coverage. To avoid having the bowel get more distended, a nasogastric tube should be inserted and placed on suction.

**Figure 17.1**

The specific features of gastroschisis include an abdominal wall defect measuring 2–4 cm in diameter, which is almost always to the right of a normal umbilical cord. There is no sac covering the herniated contents. The herniated contents typically include the entire intestinal mid-gut. There is shortening of the mesentery and thickening of the bowel wall. The bowel surface may be covered with a fibrin “peel”. Depending on the size of the abdominal wall defect, it is possible that the stomach, and/or the urinary bladder, and the fallopian tubes and ovaries in a female may be herniated through the abdominal wall defect.

General anaesthesia including muscle relaxation is required for the appropriate intra-operative management of gastroschisis. The bowel and anterior abdominal wall should be prepped. It is my preference to use a warm, dilute 50/50 mixture of povidone iodine and saline. The umbilical cord should be clamped and tied 2–3 cm above the abdominal wall and the excess umbilical cord then removed. At this point, appropriate draping is indicated.

**Figure 17.2**

Because the abdominal wall defect in gastroschisis is relatively small (2–3 cm) it may be difficult to reduce the herniated mid-gut through this small opening. Thus, it may be necessary to enlarge the abdominal wall opening. The optimum way to do this is extending the gastroschisis defect superiorly by incising the fascia along the midline with a finger placed below the fascia to avoid an injury to the bowel.

Extending the defect superiorly is safer than a caudal incision because the bladder is very close to the inferior aspect of the abdominal wall defect and this limits the ability to extend the opening inferiorly.

Figure 17.1

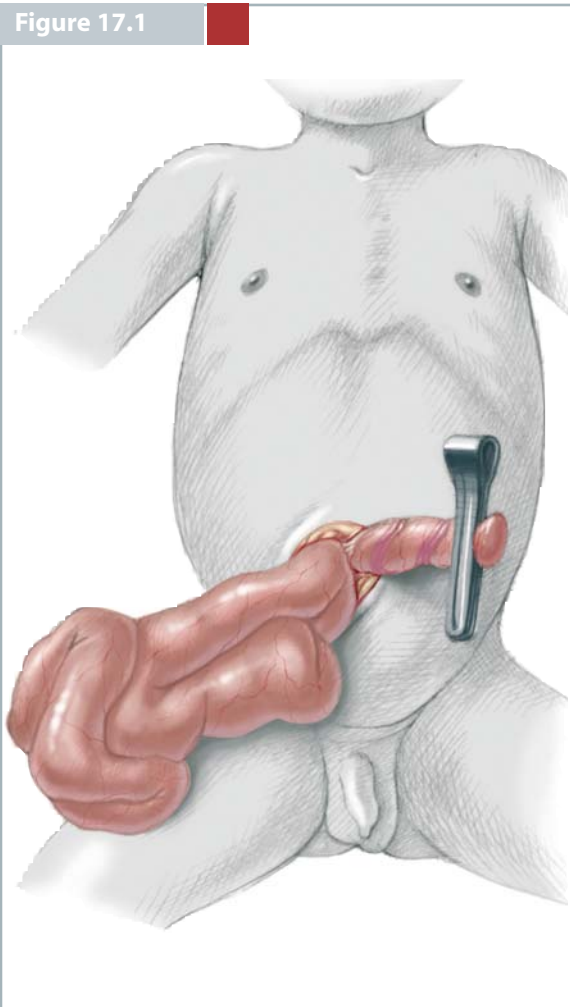
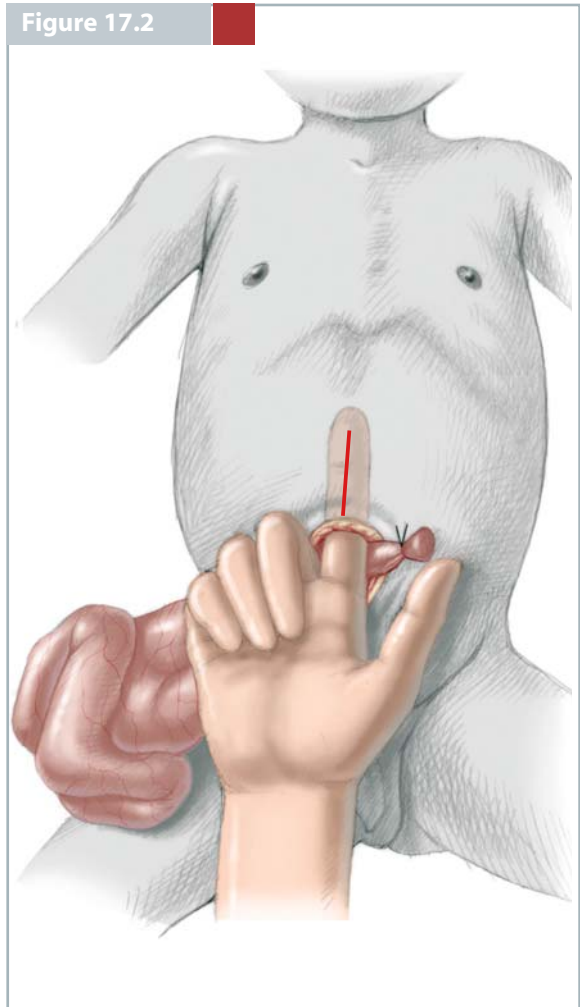


Figure 17.2



**Figure 17.3**

After enlarging the abdominal wall defect, the bowel can be reduced into the peritoneal cavity. The degree of thickening and fibrin peel determines how malleable the herniated bowel is and how easily it is to place it within the abdominal cavity. If the initial assessment suggests that primary closure may not be obtainable, two techniques have been described to increase the chances of a primary abdominal wall closure. The first approach is to attempt to empty the intestinal contents either retrograde into the stomach which then can be aspirated through the nasogastric tube or antegrade into the colon and out the rectum. A second technique is manual stretching of the anterior abdominal wall to increase the size of the peritoneal cavity. Although gentle stretching is potentially advantageous, vigorous stretching can result in haemorrhage and swelling of the rectus muscles in the rectus sheath.

**Figure 17.4**

If it is possible to reduce all of the herniated intestinal contents into the peritoneal cavity, primary closure should be undertaken. It is important to identify good fascial edges for the closure. The choice of suture material and the technique for placement of sutures, whether they are interrupted, figure-of-eight sutures, or a running suture is personal preference. It has been my approach to use 3/0 or 2/0 absorbable braided suture if there is mild to moderate tension and 3/0 or 2/0 monofilament sutures if there is moderate-to-significant tension. These sutures are placed in a figure-of-eight fashion.

It is preferable to place all of the sutures prior to tying them. An important point in patients with gastroschisis is the placement of sutures at the level of the umbilicus. The incidence of an umbilical defect following gastroschisis closure is high. To avoid this, the fascia lateral to the umbilical ring should be clearly identified and used for placement of the suture. If the sutures are placed medial to the umbilical ring, then it is highly likely that an umbilical defect will result in requiring subsequent repair. In tying the sutures in sequence a thin ribbon retractor placed in the peritoneal cavity underneath the fascia is advantageous to avoid trapping the bowel during tying of the sutures. Prior to closing the skin, any compromised or ischaemic skin should be trimmed. The degree of tension on the skin sutures can dictate the type of closure.

Figure 17.3

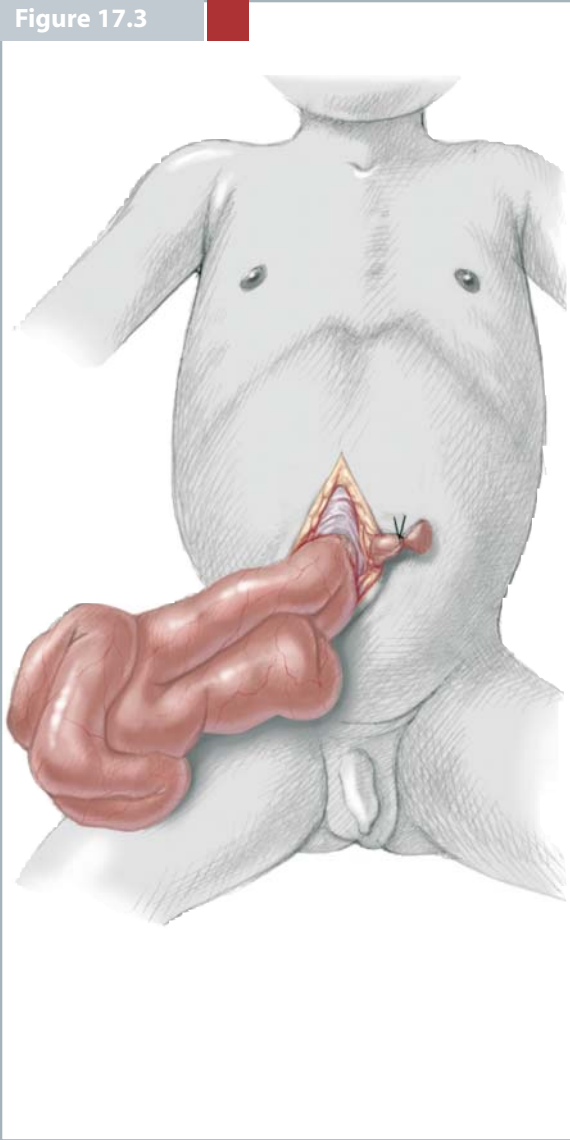
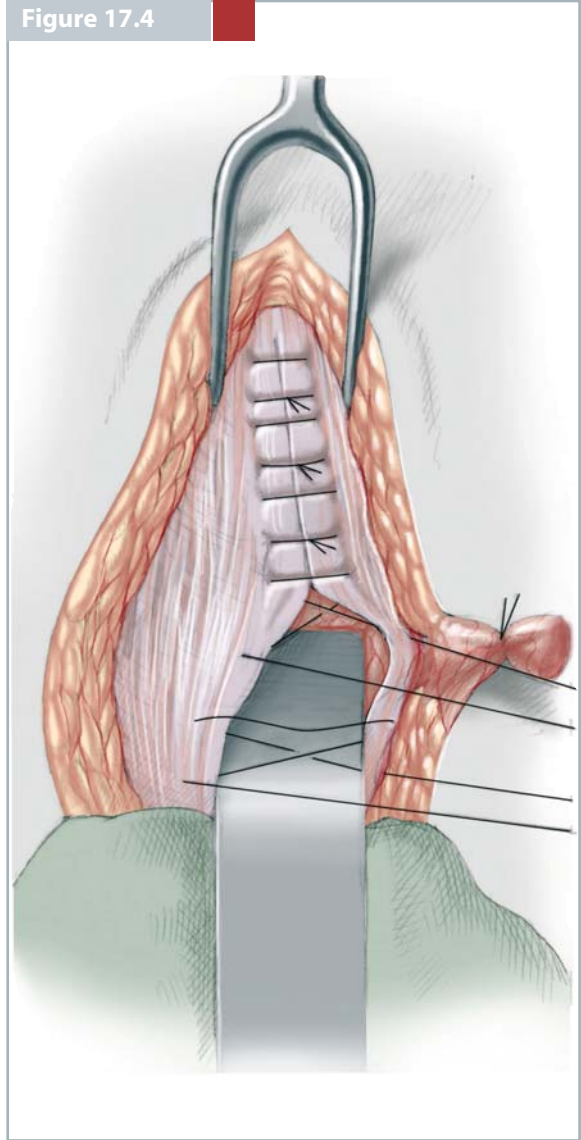


Figure 17.4



**Figure 17.5**

A significant percentage of infants with gastroschisis can undergo reduction of the herniated intestinal contents and primary abdominal wall closure. The reported percentage ranges from 60% to nearly 100%.

If it is determined at the time of the initial operative procedure that primary closure is not possible, then an abdominal wall “silo” can be created. This technique, initially described by Schuster and colleagues, has undergone several modifications since its initial description in 1967. However, the concept remains the same. Creation of a sac, which is sewn to the abdominal fascia circumferentially and then around the herniated contents, allows for staged reduction of the sac with resulting reduction of the herniated contents into the abdominal cavity. This approach produces progressive stretching of the abdominal cavity with simultaneous reduction of the swelling and rigidity of bowel. Shown in this illustration is placement of reinforced silastic sheeting which is sutured to the fascial edges with horizontal mattress sutures of interrupted 3/0 silk suture.

**Figure 17.6**

After the sheets are attached to the fascia on either side of the defect, they are then sewn around the herniated contents with a running suture. As much bowel as will be tolerated is reduced into the peritoneal cavity and then a running suture line is placed across the top of the silastic sac. On successive days the sac is squeezed as much as possible to reduce the herniated contents. A row of running suture in the silo is placed to maintain the reduction. Once the bowel has been reduced into the peritoneal cavity, the fascial edges approximate enough to allow removal of the silo, then primary fascial and skin closure is performed in the operating theatre.

Figure 17.5

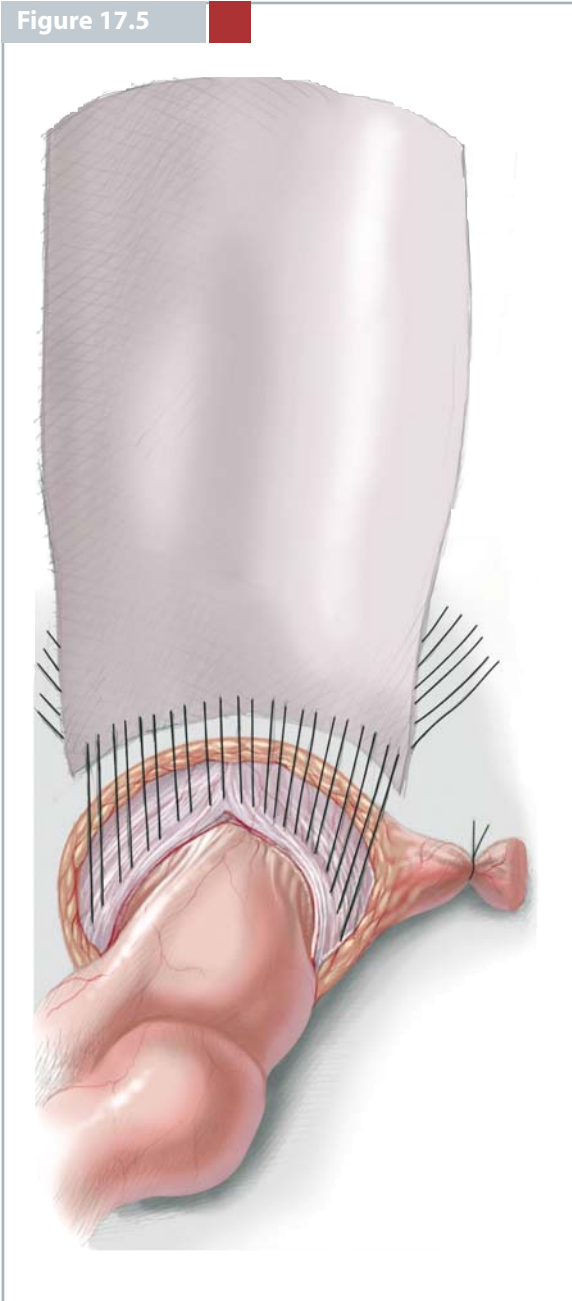


Figure 17.6



**Figure 17.7, 17.8**

Recently, the use of a preformed spring-loaded silo bag in infants with gastroschisis has been shown to be associated with improved fascial closure rates, fewer ventilator days, more rapid return of bowel

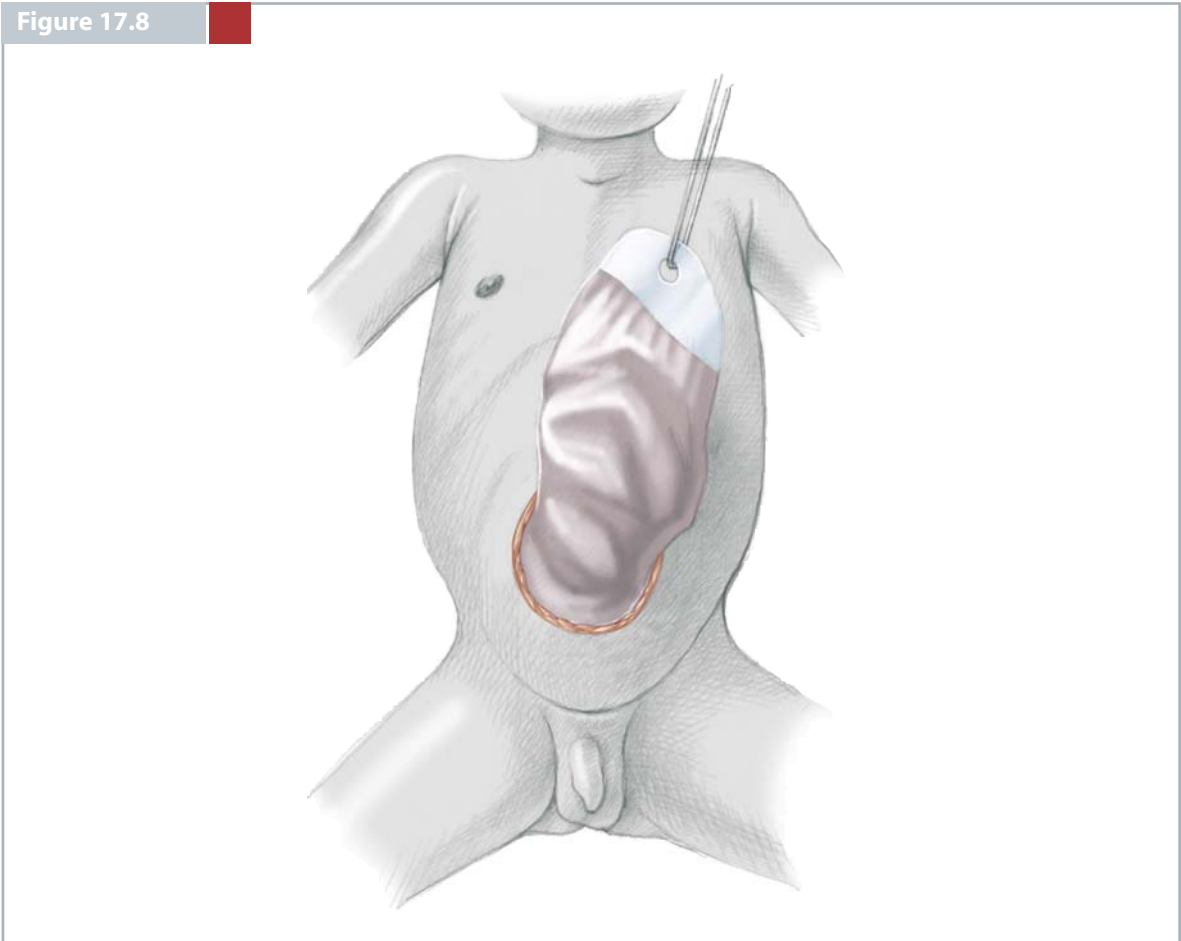
function and fewer complications. Also recently, reduction of gastroschisis bowel has been successfully performed with and without anaesthesia, and without enlarging the abdominal wall defect.



Figure 17.7



Figure 17.8



## CONCLUSION

The outcome for patients with gastroschisis has dramatically improved. Whereas the mortality was 80 to 90% three or four decades ago, the survival is now more than 90%. The improvement in outcome is related to the availability of intravenous nutrition and the use of staged closure when indicated. Late complications and mortality are related to sepsis either from an intra-abdominal or wound complication or from a central venous catheter placed for parental nutrition.

Once there is evidence of bowel function it is appropriate to begin enteral feeding. An elemental formula may be better tolerated. When the infant has reached adequate caloric intake enterally then discharge is appropriate.

In the absence of complications during the recovery from surgery and resolution of the bowel oedema, infants with gastroschisis usually reach goal feedings within 3–4 weeks. Long-term complications are unusual once the infants are discharged from the hospital.

## SELECTED BIBLIOGRAPHY

- Baerg J, Kaban G, Tonita J et al (2003) Gastroschisis: a sixteen year review. *J Pediatr Surg* 38:771–774
- Driver CP, Bruce J, Bianchi A et al (2000) The contemporary outcome of gastrochisis. *J Pediatr Surg* 35:1719–1723
- Schlatter M, Norris K, Uitvlugt N et al (2003) Improved outcomes in the treatment of gastroschisis using a preformed silo and delayed repair approach. *J Pediatr Surg* 38:459–464
- Schuster SR (1967) A new method for the staged repair of large omphaloceles. *Surg Gynecol Obstet* 125:837–850
- Schwartz MZ, Tyson KR, Milliorn K et al (1983) Staged reduction using a silastic sac is the treatment of choice for large congenital abdominal wall defects. *J Pediatr Surg* 18:713–719