

■ ASPECTS OF CURRENT MANAGEMENT

Modern concepts in the treatment of hallux valgus

A. H. N. Robinson,
J. P. Limbers

From Addenbrooke's
Hospital, Cambridge,
England

More than 130 operations have been described for the treatment of hallux valgus. The plethora of techniques indicates that no single operation is perfect, and none will address all cases. Treatment which is poorly planned or executed leads to high levels of patient dissatisfaction. In recent years, a number of new osteotomies have been described. Determining which to use can be difficult. This review will examine the important factors in choosing the most appropriate techniques.

Aetiology and pathogenesis

The wearing of constricting and high heel shoes are extrinsic factors which are important in the development of hallux valgus.^{1,2} Heredity is likely to be a major predisposing factor in some patients, with up to 68% of patients showing a familial tendency.³

The role of pes planus is complex. It is unlikely that it is an important initiating factor in hallux valgus but in the presence of pes planus the progression of hallux valgus is more rapid. This is particularly so in those patients with a compromised medial joint capsule as in rheumatoid arthritis, collagen deficiency or a neuromuscular disorder.⁴ The presence of pes planus does not reduce the rate of success of operations for hallux valgus.^{5,6}

Hypermobility of the first tarsometatarsal joint is thought by some^{7,8} to be a causative component in some cases of hallux valgus. In these patients a fusion of the first tarsometatarsal joint (the Lapidus procedure), should be considered for surgical correction as opposed to an osteotomy. There is a correlation between hypermobility of the first ray and hallux valgus,⁸⁻¹⁰ and a higher incidence of hypermobility at this site causes a hallux valgus deformity which is painful.^{8,11} The accurate clinical assessment of hypermobility of the first ray is difficult.⁹ However, a recent cadaver study¹² has shown that correction of a hallux valgus deformity by a distal soft-tissue procedure and a basal crescentic osteotomy significantly reduces hypermobility of the first ray,

implying that the hypermobility maybe a secondary phenomenon in some cases.

The pathogenesis of hallux valgus has been well described by Stephens.¹³ Weakening of the tissues on the medial side of the first metatarsophalangeal joint and erosion of the ridge on the metatarsal head between the medial and lateral sesamoids occur early (Fig. 1). The proximal phalanx drifts into valgus and the metatarsal head into varus. A groove appears on the medial side of the articular cartilage of the metatarsal head as it atrophies from the lack of normal pressure and this gives rise to the apparent prominence of the medial exostosis. The medial bursa develops in response to the excessive pressure of shoes over this prominence. As the soft tissues on the medial side become further attenuated, the metatarsal head moves medially so that the medial sesamoid lies under the eroded metatarsal ridge and the lateral sesamoid articulates with the lateral side of the metatarsal head in the first intermetatarsal space. The tendons of extensor hallucis longus and flexor hallucis longus are carried laterally with the phalanx, thus becoming adductors and exacerbating the deformity. The adductor hallucis and lateral head of flexor hallucis brevis contribute further to this and with time they become contracted, as does the lateral joint capsule. The abductor hallucis and medial head of flexor hallucis brevis also lose their abduction moment. The resultant imbalance causes dorsiflexion and pronation of the first toe rendering its pulp non-functional.

The resultant reduction in plantar pressure under the first ray leads to insufficiency of the first ray and overload of the lesser rays. As a result, the second toe may claw and eventually the second metatarsophalangeal joint will dislocate.

Clinical assessment

Mann, Rudicel and Graves¹⁴ have shown that patients present with restriction in the wearing of their shoes in 80%, pain over the medial

■ A. H. N. Robinson, BSc,
FRCS(Orth), Consultant
Orthopaedic Surgeon
■ J. P. Limbers, FRACS(Orth),
Fellow
Department of Trauma and
Orthopaedics
Box 37, Addenbrooke's
Hospital, Cambridge CB2
2QQ, UK.

Correspondence should be
sent to Mr A. H. N. Robinson;
e-mail: fredrobinson@
uk-consultants.co.uk

©2005 British Editorial
Society of Bone and
Joint Surgery
doi:10.1302/0301-620X.87B8.
16467 \$2.00
J Bone Joint Surg [Br]
2005;87-B:1038-45.

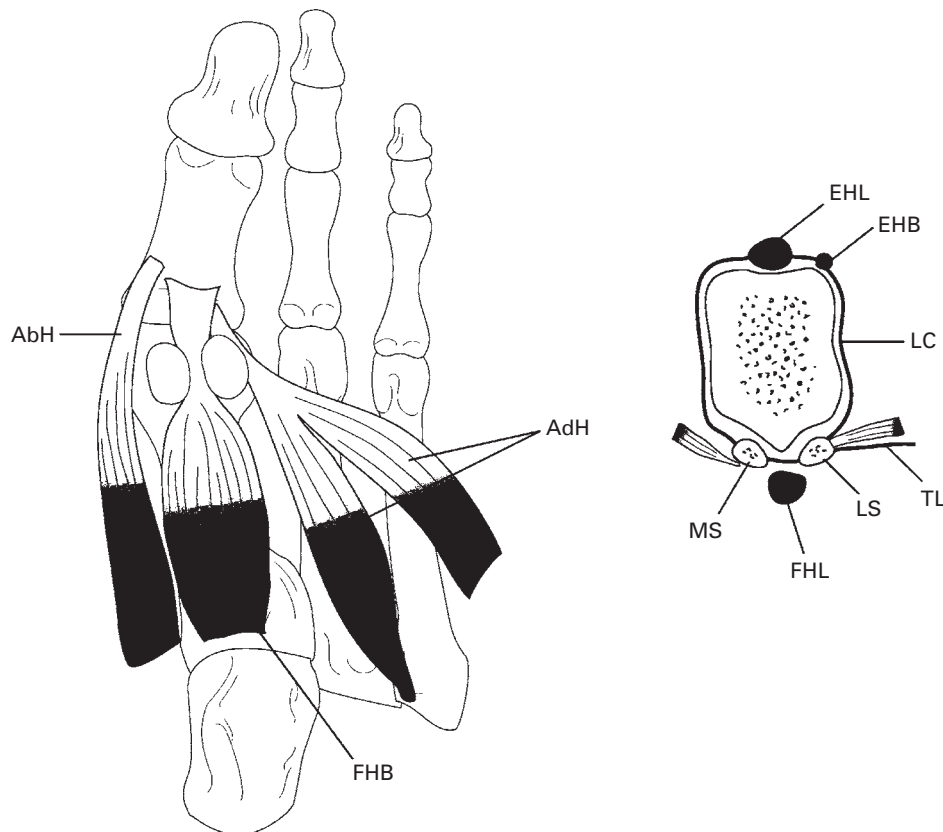


Fig. 1

Anatomy of the structures around the first metatarsophalangeal joint (AbH, abductor hallucis; FHB, flexor hallucis brevis; AdH, adductor hallucis; EHL, extensor hallucis longus; EHB, extensor hallucis brevis; LC, lateral capsule (lateral sesamoid suspensory ligament); TL, transverse ligament; LS, lateral sesamoid; FHL, flexor hallucis longus; MS, medial sesamoid).

eminence (bunion) in 70%, cosmetic concerns in 60% and pain underneath the second metatarsal head in 40%. Pain may also be felt in the distribution of the dorsal cutaneous nerve, due to pressure. Deformities of the lesser toes such as corns and calluses are often a source of symptoms and are largely due to insufficiency of the first ray and overcrowding. Synovitis of the second metatarsophalangeal joint with pain and swelling is particularly painful.

The physical examination begins with the patient standing as this often increases the hallux valgus and associated deformities. It is important to assess the hindfoot as well as the forefoot. Planovalgus deformities and tightness of the gastrocnemius and soleus can often exacerbate loading and pain under the forefoot. The severity of the hallux valgus deformity and whether it is correctable is documented. Any pronation of the great toe is noted. The first metatarsophalangeal joint is examined to assess the range of movement. The lesser toes should be examined for associated deformities and callosities. The intermetatarsal spaces should be palpated for interdigital neuromas. The plantar surface of the foot should be checked for tender callosities under the lesser metatarsal heads (transfer lesions). In order to assess first tarsometatarsal instability, the examiner

immobilises the lesser metatarsals with the thumb and fingers of one hand. The thumb and index finger of the other hand grasp the first metatarsal and move it from a plantar-lateral to dorsomedial direction. Movement of more than 9 mm indicates hypermobility.⁸ The patient should also be examined for signs of generalised ligamentous laxity.

Radiological assessment

Weight-bearing anteroposterior (AP) and lateral radiographs of the foot are taken to help assess the deformity and assist in pre-operative planning (Fig. 2). The hallux valgus angle (HVA) (normal $< 15^\circ$) and intermetatarsal angle (IMA) (normal $< 9^\circ$) are measured. The distal metatarsal articular angle (DMAA) (normal $< 10^\circ$) is the angle between the articular surface of the head and shaft of the first metatarsal. In most cases the DMAA is normal and the first metatarsophalangeal joint is subluxed. This is commonly termed an incongruent hallux valgus. In a small percentage of patients who are usually young, the joint is congruent and not subluxed. In these cases the DMAA is increased, the metatarsal articulation points more laterally than normal, and there is no subluxation of the metatarsophalangeal joint. A congruent hallux valgus is less prone to

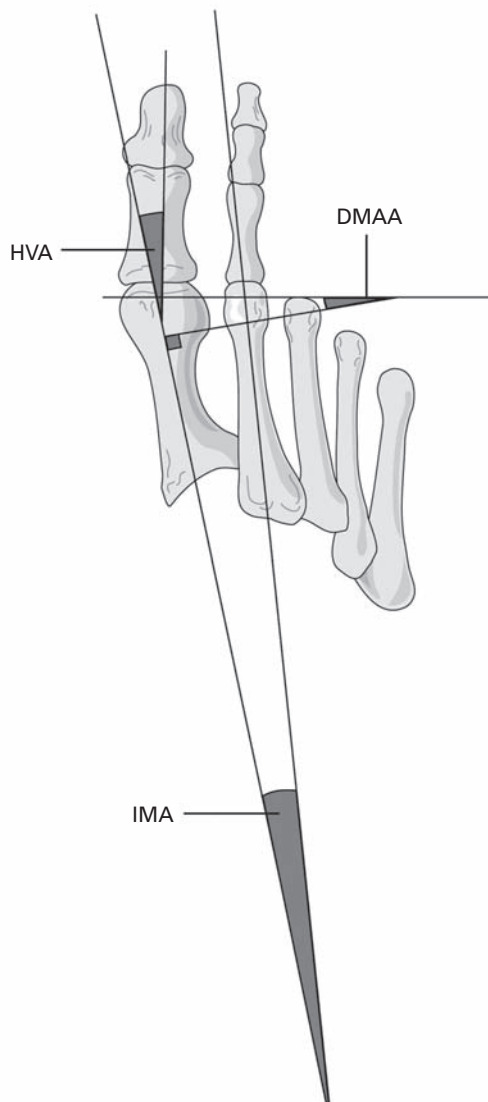


Fig. 2

Radiological assessment of hallux valgus (HVA, hallux valgus angle; IMA, intermetatarsal angle; DMAA, distal metatarsal articular angle).

progression than one which is incongruent. The DMAA is difficult to measure, with high inter- and intra-observer variability.

Hallux valgus interphalangeus deformity is present if there is significant angulation between the proximal and distal phalanges.

The relationship of the first metatarsal head to the sesamoids, the size of the medial eminence and the presence of degeneration should also be recorded.

It has become traditional to classify the severity of the deformity using radiological criteria in order to help formulate an algorithm for surgical treatment: mild (HVA up to 19° , IMA up to 13°); moderate (HVA 20° to 40° , IMA 14° to 20°); severe (HVA $> 40^\circ$, IMA $> 20^\circ$).

The congruency of the first metatarsophalangeal joint should be noted.

Non-operative treatment

Hallux valgus can be treated with accommodative footwear. The provision of a soft leather shoe with extra width and depth of the toe box can alleviate the symptoms in many patients. This may be the treatment of choice in the elderly and those with neurological or vascular compromise.

The provision of orthoses is often discussed but there is little evidence to substantiate the use of these devices which are often expensive. A support for the medial longitudinal arch has been shown to relieve symptoms for approximately six months only.¹⁵ There is no evidence to show that orthoses prevent progression of hallux valgus.

Surgical treatment

The indication for surgery is pain which is not adequately controlled by non-operative means. The pain may be over the bunion itself or in the second metatarsophalangeal joint as a result of insufficiency of the first ray. The management of patient expectation is important. The outcomes from hallux valgus surgery are not always ideal and extensive pre-operative counselling is required. Only 60% of patients can expect to wear unlimited shoes following surgery.¹⁶ If transfer lesions are present before operation, it may be necessary to wear cushioned shoes or even insoles following operation.

The surgical procedures available are numerous and discussed in detail here.

The Keller's procedure. This is a simple operation in which approximately one-third of the proximal phalanx of the great toe is resected. This decompresses the joint and relaxes the tight lateral structures, allowing correction of the deformity. Although once widely used this procedure has significant limitations. There is a high rate of recurrence of the deformity and the IMA is improved little, if at all.^{17,18} The procedure reduces the function of the first ray with one study¹⁹ showing a mean 40% loss of power of plantar flexion of the hallux. Metatarsalgia from overload of the lesser metatarsal heads is seen in between 20% and 40% of cases.²⁰⁻²² A cock-up deformity and a reduced range of movement of the first metatarsophalangeal joint is common.^{20,23}

The salvage of a failed Keller's procedure is difficult. Machacek et al²³ showed that a further Keller's procedure or an isolated soft-tissue release lead to very low levels of patient satisfaction. Fusion of the first metatarsophalangeal joint is often the only viable operative option, but this is made more difficult by the shortening and loss of bone stock. In many cases it is necessary to use an interpositional bone graft in order to re-establish length, but this is technically-demanding and associated with a high rate of non-union and other complications.^{24,25} Consequently, a Keller's procedure should only be considered in an elderly person with extremely low functional demands who would not tolerate a larger procedure.^{17,20,21} In essence, a Keller's procedure is not an operation for hallux valgus.

The distal soft-tissue procedure. Usually through an incision in the first dorsal webspace, the adductor hallucis and lateral joint capsule, also known as the lateral sesamoid suspensory ligament, are released (Fig. 1). This allows the sesamoids to be reduced underneath the first metatarsal head. The lateral collateral ligament is usually left intact as its release predisposes to hallux varus. The medial eminence of the first metatarsal is excised with plication of the medial joint capsule.

Mann and Coughlin²⁶ found that a distal soft-tissue procedure in isolation reduced the HVA by 14.8° and the IMA by 5.2°, but there was an incidence of hallux varus of 11%. A distal soft-tissue procedure showed significantly worse results in the presence of a pre-operative IMA > 15°. ^{15,16} Johnson et al²⁷ showed that a Chevron osteotomy resulted in a significantly greater radiological correction than an isolated distal soft-tissue procedure in patients with a mild to moderate deformity. A distal soft-tissue procedure is an important part of the armamentarium of the correction of hallux valgus, but it is not the complete answer.

Simple bunionectomy and capsular plication is ineffective, with the HVA increasing by 4.8° and the IMA by 1.7° at five years after operation.²⁸ The patients were dissatisfied in 41% of cases.

Osteotomies of the first metatarsal. Osteotomy may be undertaken proximally or distally. Proximal osteotomies allow a greater correction of the increased intermetatarsal angle than distal osteotomies which are usually used for mild or moderate deformities. Distal osteotomies usually require a less extensive exposure, which allows a shorter recovery time. In recent years, intermediate diaphyseal osteotomies such as the scarf and Ludloff procedures have become popular.

There are a number of important principles that should be remembered when selecting a first metatarsal osteotomy:

1. The technique should be technically easy to undertake and reproducible.
2. The osteotomy should be stable so that re-displacement does not occur.
3. The length of the first metatarsal should be maintained to prevent the development of transfer lesions and metatarsalgia. Similarly, dorsiflexion, with the resultant elevation of the metatarsal head, should be avoided.
4. The technique should be versatile so that the HVA, the IMA and the DMAA can be corrected.
5. The metatarsal blood supply should be preserved in order to avoid avascular necrosis of the metatarsal head.
6. The long-term outcome should show a low recurrence rate of the deformity.

Distal metatarsal osteotomies

The Wilson procedure. This is an oblique metaphyseal osteotomy from distal medial to proximal lateral, allowing displacement of the metatarsal head laterally and proximally. This technique allows correction of the IMA and HVA. Satisfactory results have been described in approximately 90% of patients.²⁹ Pouliart, Haentjens and Opdecam³⁰ found an

average of 8.5 mm shortening of the first metatarsal and a 24% incidence of dorsal angulation with this operation. Metatarsalgia occurred in 35% of their patients post-operatively and correlated with the amount of shortening. Callosities were present under the second metatarsal head in 78% of their patients. More than 5 mm of shortening has been shown to correlate strongly with the onset of transfer metatarsalgia.³¹ Due to these shortcomings this operation is not recommended.

The Mitchell osteotomy. This involves a double cut through the first metatarsal neck, leaving a step in the lateral cortex. This step is used to 'hitch' on to the metatarsal head. The capital fragment is displaced laterally and plantarward and held with a suture through drill holes. Good clinical results have been reported with this procedure with a 91% rate of patient satisfaction.³² It is recommended for an IMA up to 15° and HVA up to 35°. Good correction of the deformity has been reported.^{33,34} Nevertheless, shortening of the first metatarsal occurs due to removal of bone to create the step-cut. This, combined with a lack of inherent stability resulting in dorsal malunion, has led to reports of transfer metatarsalgia in between 10% and 30% of patients.^{33,35} Loss of correction can also occur. Some authors have reported a decrease in these complications by the use of internal fixation in order to increase stability.^{32,34}

The distal Chevron osteotomy. This is a V-shaped osteotomy through the metatarsal neck followed by lateral displacement of the capital fragment. This procedure leads to minimal shortening and is intrinsically stable against dorsiflexion. It is indicated for mild to moderate deformities.³⁶ Excellent clinical results have been reported^{31,37} with little or no transfer metatarsalgia when the procedure has been used within limits of correction of the IMA of 4° to 8° and the HVA of 11° to 18°. ^{31,37} Loss of correction and recurrence can occur from extending the indications to more severe deformities and from loss of position at the osteotomy site. The latter complication can be minimised by cutting the osteotomy with a long dorsal or plantar arm and using internal fixation.^{31,38} Some authors maintain that the results are not as good in patients > 60 years.⁶ However, others have not found this to be the case.^{20,37} The operation is most often used in a non-congruent deformity with a normal DMAA. However, it can also be employed to correct an increased DMAA by taking a medially-based closing wedge by allowing medial rotation of the metatarsal head.³¹ This is termed a biplanar Chevron osteotomy.

Complications with distal osteotomies. A concern with the Chevron and other distal osteotomies is the development of avascular necrosis of the first metatarsal head with a reported incidence of between 0% and 20%.³⁸⁻⁴¹ Some authors have noted a higher incidence when a concomitant lateral release is performed^{41,42} and have cautioned against such a combined procedure. Others have not found this to be the case.³⁷

A number of studies⁴³⁻⁴⁵ have described the blood supply of the head of the first metatarsal. Laterally it is derived

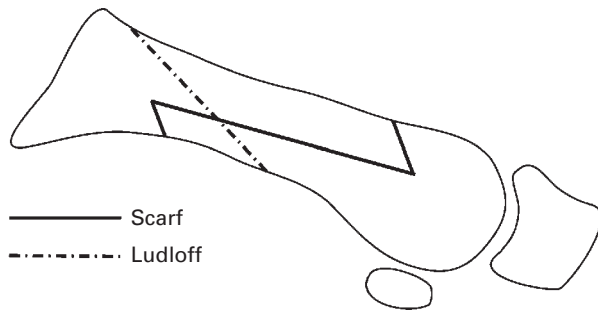


Fig. 3

Lateral view of the osteotomy cuts for the scarf and Ludloff osteotomies.

from the first dorsal and first plantar metatarsal artery and medially from the superficial branch of the medial plantar artery. From these vessels a multitude of capillaries envelop the capsule and periosteum of the metatarsal head, including a leash of vessels which enter the head just proximal to its inferior surface. It is possible to dissect through the first dorsal webspace and release the tendon of adductor hallucis and the intermetatarsal ligament, performing a longitudinal incision in the capsule of the first metatarsophalangeal joint without damaging the dorsolateral blood supply to the head.⁴⁴ If the sawblade passes too far beyond the lateral cortex of the metatarsal it may damage the first dorsal metatarsal artery. The blood supply to the metatarsal head will also be seriously damaged if the dorsal, lateral or inferior capsular attachments are disrupted. It is therefore important when performing a distal osteotomy that the surgeon ensures that the dorsal and plantar cuts exit the bone proximal to the capsular attachments, the plantar soft tissues to the metatarsal head are left intact and the sawblade passes through, but not beyond, the lateral cortex. It is crucial to follow these guidelines in order to avoid avascular necrosis following a Chevron osteotomy.

Diaphyseal osteotomies

Diaphyseal osteotomies have been recommended if the IMA is between 14° and 20° .^{46,47} They allow longitudinal division of the diaphysis and either translation (scarf) or rotation (Ludloff) of the metatarsal to correct the IMA. Plication of the medial capsule and lateral release are usually performed simultaneously.

The modified Ludloff osteotomy (Fig. 3). This osteotomy consists of a bone cut extending distally and inferiorly from the dorsal cortex, 2 mm distal to the metatarsocuneiform joint, to the plantar cortex.⁴⁸ The osteotomy forms an angle of 30° to the long axis of the metatarsal. The distal fragment is rotated laterally on the proximal fragment and held with two screws. It is also possible to displace the metatarsal head plantarwards by angling the osteotomy. This ensures that elevation of the metatarsal head does not occur and can help relieve pressure on the second metatarsal head. Excellent clinical results have been reported with the Ludloff osteotomy, with good correction of the deformity and without subsequent transfer metatarsalgia.^{48,49} There is minimal shortening of the metatarsal and it is bio-

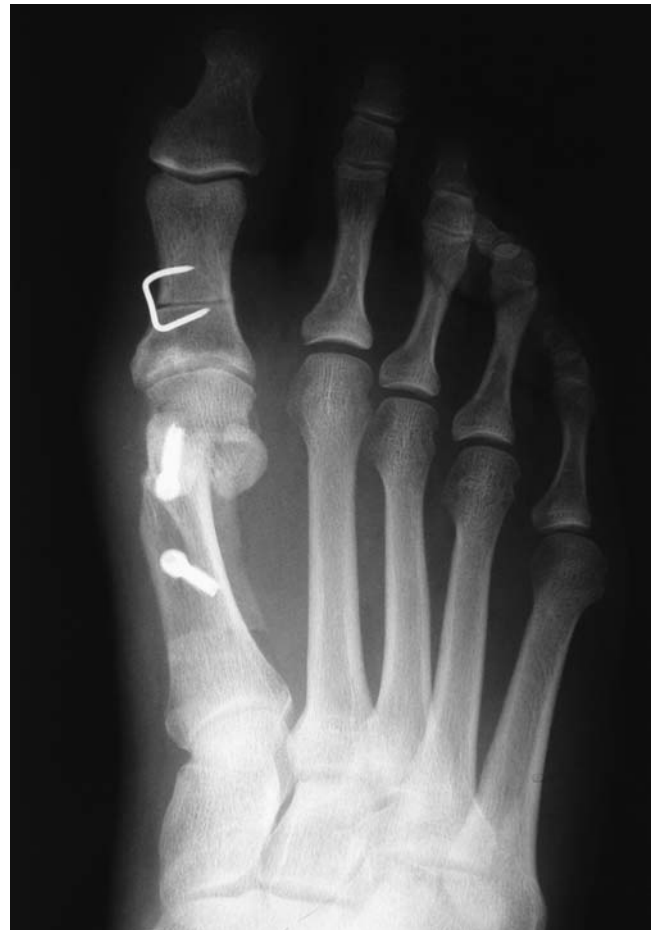

Fig. 4

A post-operative view of hallux valgus treated with scarf and Akin osteotomies.

mechanically more stable than the proximal chevron and proximal crescentic osteotomies.⁴⁹⁻⁵¹

The scarf osteotomy (Fig. 3). This is a Z-shaped step-cut osteotomy and is named after its woodworking equivalent. A longitudinal cut is made along the length of the diaphysis, sloping plantarward as it passes laterally, allowing plantar displacement and off-loading of the lesser rays. Chevrons

are made at each end of the osteotomy to connect it to the dorsal cortex distally and the plantar cortex proximally. The head and the plantar cortical fragment are then translated laterally and the osteotomy held with two compression screws. As the technique relies on translation of the metatarsal head rather than rotation, shortening and increase in the DMAA is avoided.^{50,52} By altering the geometry of the cuts it is possible to shorten the metatarsal, or reduce an abnormally-elevated DMAA. It can be modified so that an abnormally increased DMAA can be corrected.^{46,53} This osteotomy has a high degree of inherent biomechanical stability and is more stable than the basal osteotomies.^{54,55}

Studies have shown that the clinical outcomes of the scarf osteotomy compare favourably with those of basal osteotomies, but there is an incidence of significant complications of between 4% and 11%.^{46,47,56} However, other studies have reported less favourable results with a much higher incidence of complications,⁵⁷ indicating that it is a technically-demanding procedure with a learning curve. However, once mastered, it is a highly effective and versatile procedure. It has traditionally been recommended for an IMA of up to 18° to 20°^{46,47} but with experience it can be used for more severe deformities.^{52,58,59} The corrective power can be increased by adding a varus osteotomy of the proximal phalanx (Akin procedure) (Fig. 4). It is our preferred operation for deformities with an IMA > 14° as we believe that it best fulfills the previously mentioned guidelines for osteotomies.

Diaphyseal osteotomies are technically demanding and require an extensive surgical exposure. This necessitates post-operative physiotherapy to prevent stiffness.

Basal osteotomies

The final group of procedures are the proximal (basal) osteotomies. Opening wedge, closing wedge, crescentic and basal chevron osteotomies have all been described. They are normally combined with a distal soft-tissue procedure. They have high corrective power due to their proximal location providing a long lever arm. They can therefore be used for moderate and severe deformities, but if the DMAA is increased pre-operatively, a congruent deformity, they will worsen this problem. Coughlin and Carlson⁶⁰ overcame this by adding a distal osteotomy to rotate the metatarsal head medially (a double osteotomy), and in some cases also an Akin osteotomy to correct hallux valgus interphalangeus (triple osteotomy). They reported a rate of patient satisfaction of 81% but an incidence of major complications of 19% and a mean of 5 mm of metatarsal shortening.

Proximal wedge osteotomy. An opening wedge osteotomy causes elongation and stretching of the medial soft-tissues and requires a bone graft. It therefore has greater potential for stiffness and nonunion. A closing wedge osteotomy is easier to perform but leads to excessive shortening of the metatarsal.^{17,50} It is inherently unstable and dorsal malunion occurs in up to 38%, leading to the potential for

post-operative transfer lesions.¹⁷ Distraction plates are now available to fix opening wedge osteotomies and these may improve the results.

The crescentic osteotomy. This osteotomy is associated with Mann and Coughlin.⁴ It is created 1 cm distal to the metatarsocuneiform joint with a crescentic sawblade and the concavity directed proximally, through a dorsal approach. The metatarsal shaft is rotated laterally and the osteotomy held with a lag screw, a Steinmann pin or multiple Kirschner wires. It leads to minimal shortening of the first metatarsal. Excellent results have been described with rates of patient satisfaction of > 90% and good correction of the IMA and HVA even in severe cases.^{14,61} However, some have found it technically difficult and its instability has led to dorsal malunion in up to 17% of patients with consequent transfer metatarsalgia.^{62,63}

The proximal Chevron osteotomy. This is technically easier and intrinsically more stable to dorsiflexion than the crescentic osteotomy. It has been shown to cause less transfer lesions.⁶³⁻⁶⁵ Good results have been described.^{65,66} It involves a medial approach to the metatarsal and creation of a proximally based V-shaped osteotomy. The metatarsal shaft is rotated laterally on the inferior limb of the cut and a bone graft from the excised medial eminence is inserted into the superior limb for stability. The corrected position is held with a suture between the first and second metatarsals, although other forms of internal fixation can be added if desired.

Arthrodeses

First metatarsophalangeal joint arthrodesis. This procedure is indicated for hallux valgus in the rheumatoid patient and when there are significant degenerative changes in the metatarsophalangeal joint. It is also an option in severe or recurrent deformity, particularly in the older patient. Other indications include hallux valgus secondary to neuromuscular diseases and as a salvage procedure following failed surgery. Various techniques have been described with an overall success rate of 90% and high levels of patient satisfaction in appropriately-selected patients. The increased IMA will be reduced after operation even in the most severe deformities and a concomitant basal osteotomy is not indicated.⁶⁷

First tarsometatarsal joint arthrodesis (Lapidus). This is indicated in combination with a distal soft-tissue procedure in the patient with hypermobility of the first tarsometatarsal joint, especially if associated with generalised ligamentous laxity. Mann and Coughlin⁴ estimate this to occur in approximately 3% to 5% of patients. Hypermobility can be determined clinically as outlined previously but it is difficult to estimate accurately and reproducibly. The procedure is also indicated in the presence of degenerative changes in the first or second tarsometatarsal joint and is an option in severe deformity with an IMA of > 20°. It is contraindicated in the adolescent with an open physis at the base of the first metatarsal and also in patients with a short first metatarsal or degenerative changes in the first meta-

Table I. The authors' preferred methods of treatments

Type	Description
Mild hallux valgus (IMA* up to 14°) Normal DMAA† Increased DMMA	Chevron osteotomy with a long inferior limb; internally fixed with a single screw. A biplanar chevron osteotomy, excising a medial wedge to allow medial rotation of the metatarsal head as it is translated laterally; internally fixed with a single screw.
Moderate hallux valgus (IMA 14° to 20°) Normal DMAA Increased DMMA	A scarf osteotomy with a distal soft-tissue procedure is used. A varus osteotomy of the proximal phalanx (Akin procedure) is added if more correction is desired. The Akin osteotomy is fixed with a staple. If there is any residual pronation of the hallux this can be reduced by rotating the Akin osteotomy. The same procedure is undertaken, but the DMAA is corrected by rotating the scarf osteotomy
Severe hallux valgus (IMA > 20°)	For intermetatarsal angles > 20° there are four principle options: extend the indications for a scarf osteotomy, undertake a rotational osteotomy (Ludloff, crescentic or chevron) or perform a fusion either at the tarsometatarsal or metatarsophalangeal joint. Our preference is to perform a scarf osteotomy in most cases.
Hallux valgus with first tarsometatarsal hypermobility	A first tarsometatarsal fusion (Lapidus) with a distal soft-tissue procedure may be undertaken
Hallux valgus with first metatarsophalangeal joint degeneration Hallux valgus interphalangeus	First metatarsophalangeal joint arthrodesis is performed This is treated with an Akin osteotomy. Hallux valgus interphalangeus in isolation is rare, and an Akin osteotomy is normally performed in conjunction with other procedures which correct the intermetatarsal angle.

* IMA, intermetatarsal angle

† DMAA, distal metatarsal articular angle

tarsophalangeal joint. The procedure is technically demanding and associated with a prolonged period of recovery and increased morbidity when compared to metatarsal osteotomies.^{68,69} It also leads to shortening and care must be taken to resect as little bone as possible to avoid this. As the varus of the first metatarsal is corrected the first ray should be plantarflexed slightly to avoid elevation and transfer metatarsalgia. The rate of patient satisfaction varies between 75% and 90% with fusion rates of approximately 90%.⁶⁸⁻⁷⁰

Conclusion

Surgery for hallux valgus, while technically demanding, has a high rate of success in appropriately selected patients. However, a small number of patients have poor outcomes following operation. Randomised, controlled trials are needed to elucidate the factors which determine a good outcome. There is also a need for a good validated outcome score.

Our preferred methods of treatment are shown in Table I.

References

- Lam SL, Hodgson AR. A comparison of foot forms among the non-shoe and shoe-wearing Chinese population. *J Bone Joint Surg [Am]* 1958;40-A:1058-62.
- Kato S, Watanabe S. The etiology of hallux valgus in Japan. *Clin Orthop* 1981;157:78-81.
- Glynn MK, Dunlop JB, Fitzpatrick D. The Mitchell distal metatarsal osteotomy for hallux valgus. *J Bone Joint Surg [Br]* 1980;62-B:188-91.
- Mann RA, Coughlin MJ. Adult hallux valgus. In: Coughlin MJ, Mann RA, eds. *Surgery of the foot and ankle*. Vol. 1. Seventh ed. St. Louis: Mosby Inc., 1999:150-269.
- Coughlin MJ, Shurnas PS. Hallux valgus in men: part II: first ray mobility after bunionectomy and factors associated with hallux valgus deformity. *Foot Ankle Int* 2003;24:73-8.
- Coughlin MJ. Juvenile hallux valgus: etiology and treatment. *Foot Ankle Int* 1995;16:682-97.
- Myerson MS, Badekas A. Hypermobility of the first ray. *Foot Ankle Clin* 2000;5:469-84.
- Klaue K, Hansen ST, Masquelet AC. Clinical, quantitative assessment of first tarsometatarsal mobility in the sagittal plane and its relation to hallux valgus deformity. *Foot Ankle Int* 1994;15:9-13.
- Lee KT, Young K. Measurement of first-ray mobility in normal vs. hallux valgus patients. *Foot Ankle Int* 2001;22:960-4.
- Glasoe WM, Allen MK, Saltzman CL. First ray dorsal mobility in relation to hallux valgus deformity and first intermetatarsal angle. *Foot Ankle Int* 2001;22:98-101.
- Ito H, Shimizu A, Miyamoto T, Katsura Y, Tanaka K. Clinical significance of increased mobility in the sagittal plane in patients with hallux valgus. *Foot Ankle Int* 1999;20:29-32.
- Coughlin MJ, Jones CP, Viladot R, et al. Hallux valgus and first ray mobility: a cadaveric study. *Foot Ankle Int* 2004;25:537-44.
- Stephens MM. Pathogenesis of hallux valgus. *Eur J Foot Ankle Surg* 1994;1:7-10.
- Mann RA, Rudicel S, Graves SC. Repair of hallux valgus with a distal soft-tissue procedure and proximal metatarsal osteotomy: a long-term follow-up. *J Bone Joint Surg [Am]* 1992;74-A:124-9.
- Torkki M, Malmivaara A, Seitsalo S, et al. Surgery vs orthosis vs watchful waiting for hallux valgus: a randomized controlled trial. *JAMA* 2001;285:2472-80.
- Mann RA, Pfeffinger L. Hallux valgus repair: DuVries modified McBride procedure. *Clin Orthop* 1991;272:213-18.
- Zembsch A, Trnka HJ, Ritschl P. Correction of hallux valgus: metatarsal osteotomy versus excision arthroplasty. *Clin Orthop* 2000;376:183-94.
- Axt M, Wildner M, Reichelt A. Late results of the Keller-Brandes operation for hallux valgus. *Arch Orthop Trauma Surg* 1993;112:266-9.
- Donley BG, Vaughn RA, Stephenson KA, Richardson EG. Keller resection arthroplasty for treatment of hallux valgus deformity: increased correction with fibular sesamoidectomy. *Foot Ankle Int* 2002;23:699-703.
- Schneider W, Knahr K. Keller procedure and chevron osteotomy in hallux valgus: five-year results of different surgical philosophies in comparable collectives. *Foot Ankle Int* 2002;23:321-9.
- Majkowski RS, Galloway S. Excision arthroplasty for hallux valgus in the elderly: a comparison between the Keller and modified Mayo operations. *Foot Ankle* 1992;13:317-20.
- Vallier GT, Petersen SA, LaGrone MO. The Keller resection arthroplasty: a 13 year experience. *Foot Ankle* 1991;11:187-94.

23. Machacek F Jr, Easley ME, Gruber F, Ritschl P, Trnka HJ. Salvage of a failed Keller resection arthroplasty. *J Bone Joint Surg [Am]* 2004;86-A:1131-8.
24. Myerson MS, Schon LC, McGuigan FX, Ozgur A. Result of arthrodesis of the hallux metatarsophalangeal joint using bone graft for restoration of length. *Foot Ankle Int* 2000;21:297-306.
25. Brodsky JW, Ptaszek AJ, Morris SG. Salvage first MTP arthrodesis utilizing ICBG: clinical evaluation and outcome. *Foot Ankle Int* 2000;21:290-6.
26. Mann RA, Coughlin MJ. Hallux valgus: etiology, anatomy, treatment and surgical considerations. *Clin Orthop* 1981;157:31-41.
27. Johnson JE, Clanton TO, Baxter DE, Gottlieb MS. Comparison of Chevron osteotomy and modified McBride bunionectionomy for correction of mild to moderate hallux valgus deformity. *Foot Ankle Int* 1991;12:61-8.
28. Kitaoka HB, Franco MG, Weaver AL, Ilstrup DM. Simple bunionectionomy with medial capsulorrhaphy. *Foot Ankle Int* 1991;12:86-91.
29. Keogh P, Jaishanker JS, O'Connell RJ, White M. The modified Wilson osteotomy for hallux valgus. *Clin Orthop* 1990;255:263-7.
30. Pouliart N, Haentjens P, Opdecam P. Clinical and radiological evaluation of Wilson osteotomy for hallux valgus. *Foot Ankle Int* 1996;17:388-94.
31. Nery C, Barroco R, Réssio C. Biplanar chevron osteotomy. *Foot Ankle Int* 2002;23:792-8.
32. Blum JL. The modified Mitchell osteotomy-bunionectionomy: indications and technical considerations. *Foot Ankle Int* 1994;15:103-6.
33. Kuo CH, Huang PJ, Cheng YM, et al. Modified Mitchell osteotomy for hallux valgus. *Foot Ankle Int* 1998;19:585-9.
34. Briggs TW, Smith P, McAuliffe TB. Mitchell's osteotomy using internal fixation and early mobilisation. *J Bone Joint Surg [Br]* 1992;74-B:137-9.
35. Hawkins FB, Mitchell CL, Hedrick CW. Correction of hallux valgus by metatarsal osteotomy. *J Bone Joint Surg [Am]* 1945;27-A:387-94.
36. Coull R, Stephens MM. Operative decision making in hallux valgus. *Current Orthop* 2002;16:180-6.
37. Trnka HJ, Zembach A, Weisauer H, et al. Modified Austin procedure for correction of hallux valgus. *Foot Ankle Int* 1997;18:119-27.
38. Donnelly RE, Saltzman CL, Kile TA, Johnson KA. Modified chevron osteotomy for hallux valgus. *Foot Ankle Int* 1994;15:642-5.
39. Green MA, Dorris MF, Baessler TP, Mandel LM, Nachlas MJ. Avascular necrosis following distal Chevron osteotomy of the first metatarsal. *J Foot Ankle Surg* 1993;32:617-22.
40. Horne G, Tanzer T, Ford M. Chevron osteotomy for the treatment of hallux valgus. *Clin Orthop* 1984;183:32-6.
41. Meier PJ, Kenzora JE. The risks and benefits of distal first metatarsal osteotomies. *Foot Ankle Int* 1985;6:7-17.
42. Hatstrup SJ, Johnson KA. Chevron osteotomy: analysis of factors in patients' dissatisfaction. *Foot Ankle Int* 1985;5:327-32.
43. Shreff M, Yang Q, Kummer F. Extraosseous and intraosseous arterial supply to the first metatarsal and MTP joint. *Foot Ankle Int* 1987;8:81-93.
44. Peterson DA, Zilbergarb JL, Greene MA, Colgrove RC. Avascular necrosis of the first metatarsal head: incidence in distal osteotomy combined with lateral soft tissue release. *Foot Ankle Int* 1994;15:59-63.
45. Jones KJ, Feiwell LA, Freedman EL, Cracchiolo A 3rd. The effect of Chevron osteotomy with lateral capsular release on the blood supply to the first metatarsal head. *J Bone Joint Surg [Am]* 1995;77-A:197-204.
46. Kristen KH, Berger C, Steizig S, et al. The SCARF osteotomy for the correction of hallux valgus deformities. *Foot Ankle Int* 2002;23:221-9.
47. Crevoisier X, Mouhsine E, Ortolano V, Udin B, Dutoit M. The scarf osteotomy for the treatment of hallux valgus deformity: a review of 84 cases. *Foot Ankle Int* 2001;22:970-6.
48. Chlodo CP, Schon LC, Myerson MS. Clinical results with the Ludloff osteotomy for correction of adult hallux valgus. *Foot Ankle Int* 2004;25:532-6.
49. Saxena A, McVammon D. The Ludloff osteotomy: a critical analysis. *J Foot Ankle Surg* 1997;36:100-5.
50. Nyska M, Trnka HJ, Parks BG, Myerson MS. Proximal metatarsal osteotomies: a comparative geometric analysis conducted on sawbone models. *Foot Ankle Int* 2002;23:938-45.
51. Nyska M, Trnka HJ, Parks BG, Myerson MS. The Ludloff metatarsal osteotomy: guidelines for optimal correction based on a geometric analysis conducted on a sawbone model. *Foot Ankle Int* 2003;24:34-9.
52. Smith AM, Alwan T, Davies MS. Perioperative complications of the Scarf osteotomy. *Foot Ankle Int* 2003;24:222-7.
53. Nyska M. Principles of first metatarsal osteotomies. *Foot Ankle Clin* 2001;6:399-408.
54. Popoff I, Negrine JP, Zecovic M, Svehla M, Walsh WR. The effect of screw type on the biomechanical properties of SCARF and crescentic osteotomies of the first metatarsal. *J Foot Ankle Surg* 2003;42:161-4.
55. Newman AS, Negrine JP, Zevovic M, Stanford P, Walsh WR. A biomechanical comparison of the Z step-cut and basilar crescentic osteotomies of the first metatarsal. *Foot Ankle Int* 2000;21:584-7.
56. Weil LS. Scarf osteotomy for correction of hallux valgus: historical perspective, surgical technique and results. *Foot Ankle Clin* 2000;5:559-80.
57. Coetzee JC. Scarf osteotomy for hallux valgus repair: the dark side. *Foot Ankle Int* 2003;24:29-33.
58. Barouk LS. Scarf osteotomy for hallux valgus correction: local anatomy, surgical technique, and combination with other forefoot procedures. *Foot Ankle Clin* 2000;5:525-58.
59. Dereymaeker G. Scarf osteotomy for correction of hallux valgus: surgical technique and results as compared to distal chevron osteotomy. *Foot Ankle Clin* 2000;5:513-24.
60. Coughlin MJ, Carlson RE. Treatment of hallux valgus with an increased distal metatarsal articular angle: evaluation of double and triple first ray osteotomies. *Foot Ankle Int* 1999;20:762-70.
61. Veri JR, Pirani SP, Claridge R. Crescentic proximal metatarsal osteotomy for moderate to severe hallux valgus: a mean 12.2 year follow-up study. *Foot Ankle Int* 2001;22:817-22.
62. Brodsky JW, Beischer A, Robinson AHN, et al. Hallux valgus correction with modified McBride bunionectionomy and proximal crescentic osteotomy: clinical, radiological and pedobarographic outcome [abstract]. *Procs American Academy of Orthopaedic Surgeons*, 2001.
63. Easley ME, Kiezbak GM, Davis WH, Anderson RB. Prospective, randomized comparison of proximal crescentic and proximal chevron osteotomies for correction of hallux valgus deformity. *Foot Ankle Int* 1996;17:307-16.
64. Acevedo JI, Sammarco VJ, Boucher HR, et al. Mechanical comparison of cyclic loading in five different first metatarsal shaft osteotomies. *Foot Ankle Int* 2002;23:711-16.
65. Markbreiter LA, Thompson FM. Proximal metatarsal osteotomy in hallux valgus correction: a comparison of crescentic and chevron procedures. *Foot Ankle Int* 1997;18:71-6.
66. Borton DC, Stephens MM. Basal metatarsal osteotomy for hallux valgus. *J Bone Joint Surg [Br]* 1994;76-B:204-9.
67. Mann RA, Katcherian DA. Relationship of metatarsophalangeal joint fusion on the intermetatarsal angle. *Foot Ankle Int* 1989;10:8-11.
68. Myerson MD. Metatarsocuneiform arthrodesis for treatment of hallux valgus and metatarsus primus varus. *Orthopaedics* 1990;13:1025-31.
69. Sangeorzan BJ, Hansen ST Jr. Modified Lapidus procedure for hallux valgus. *Foot Ankle Int* 1989;9:262-6.
70. Coetzee JC, Wickum D. The Lapidus procedure: a prospective cohort outcome study. *Foot Ankle Int* 2004;25:526-31.