

---

# Taphonomic Applications in Forensic Anthropology

# 5

DOUGLAS H. UBELAKER

---

## Introduction

The field of taphonomy was generally defined by Efremov in 1940 as the study of the processes by which organic remains pass from the biosphere into the lithosphere as the result of geological and biological processes. Interest in the field began within paleontology as the study of the fossilization process. Later, archaeologists recognized the importance of understanding taphonomic processes to properly interpret human modifications of organic materials.

Recently, taphonomic assessment has emerged as an important and vital component of forensic anthropological analysis. In particular, forensic contexts necessitate the reconstruction of perimortem and postmortem processes and the discrimination of natural from human-induced trauma. This paper reviews some of the taphonomic research which applies to such interpretations and presents case studies in which these approaches were used.

## Taphonomic Processes

---

Many processes can alter the appearance of bone and related organic materials after death (Morlan 1984; Shipman 1981). Factors in the transport and dispersal of skeletal elements include animals, gravity, or water and fluvial processes (Marshall 1989). The properties of the bones influence their reaction to these processes.

Animal-related processes include trampling, entrance fall, gnawing, and digestion. Physical factors include rockfall, water transport, sandblasting, weathering, burial, diagenic movement, volcanic shockwave, acid attack by roots, cryoturbation, release and breakup by bottom-fast ice, and mineralization by ground water (Marshall 1989). All of these can act independently or in unison to produce alteration of bones. Both animal and physical processes need to be understood in reconstructing the context of death and the sequences after death in forensic cases.

The usual sequence of disarticulation and scattering of mammal skeletons has been documented through studies by Hill (1979) in Lake Turkana, Kenya; Andrews and Cook (1985); and others. Hill and Behrensmeyer (1984) found the pattern of disarticulation to be very predictable. Human remains, exposed in outdoor scenes, can become disarticulated and scattered in a pattern similar to other large mammals. Knowledge about such patterns can be of use in scene recovery of remains and interpretation of missing elements.

Andrews and Cook (1985) documented the taphonomic processes operating on the carcass of a dead cow in Somerset, England during a 7.5 year period beginning in 1977. They found that trampling and movement by carnivores were the most significant factors leading to disarticulation and alteration of the remains. Eventually they found many fine striations, trough and V-shaped grooves, and depressions that were similar to those produced by human artifacts.

Miller found considerable variation in patterns of animal chewing. Miller (1969) adds that seasonal shifts involving freezing and thawing and/or wetting and drying can also alter bone.

Behrensmeyer et al. (1986) emphasize the important role of trampling in taphonomic bone change. Their experiments reveal that even at the microscopic level it is not always easy to distinguish alterations caused by tools from those produced by trampling and other taphonomic processes. Trampling marks in particular can mimic cut marks. They note "cutmark mimics can occur on bones subjected to trampling and original true cutmarks can be obscured by the same process" (Behrensmeyer et al. 1986:3). Discrimination of natural mimics from human-induced trauma can be critical in a forensic analysis. It is particularly important to be able to support a conclusion that natural processes cannot be ruled out.

Environmental assessment can play an important role in interpretation. The burial context, the presence of potentially abrading sand and gravel, and the pattern of the marks on the bones all provide clues (Behrensmeyer et al. 1986). The implication of this study for interpretation in archaeology and forensic anthropology is clear: taphonomic factors must be considered in judging possible tool marks on bone.

## **Animal Chewing and Other Causes of Bone Breakage**

---

Since animal chewing represents an obvious and well-known taphonomic factor, researchers have accumulated useful information on carnivore feeding patterns. In a study of 125 carcasses in the Arctic, Haynes (1982) documented considerable variation in the gnawing damage sustained by carcasses. Haynes (1983a) noted that different patterns of bone alteration resulted from canids, hyenas, bears, and felids.

Sutcliffe (1971) notes that bone-chewing animals are not confined to carnivores. The herbivores cattle, red deer, reindeer, muntjac deer, camels, giraffes, wildebeest, kudu, gemsbok, and sable antelopes also have been documented to produce chewing-type alterations on bones.

Research also has documented that the pattern of chewing varies for different bones, and that animal chewing can produce spiral fractures that frequently are interpreted as evidence of human activity in archaeology and potentially in forensic anthropology as well (Beebe 1983; Haynes 1980a,b; Morlan 1980).

In a study of bison and moose remains, Haynes (1983b) found that about 5% of the bones showed spiral fractures due to trampling and 8% due to carnivore activity. He suggested that up to 50% of the bones of smaller species may show such fractures. As noted by Hill (1976), the internal structure of bone strongly influences the nature of the fracture.

As a result of taphonomic research, archaeologists now routinely consider such factors in interpreting faunal remains to assess the number of individuals present (Aaris-Sorensen 1983), the possible products of the hunt (Binford and Ho 1985), and the possible use of tools.

Agenbroad (1989) reported the presence of spiral fractures that others might have interpreted as being of human origin on the bones of 34 mammoths excavated at a natural sinkhole trap in South Dakota. The remains date between 21,000 and 26,000 B.P., well before the presence of humans in the area. Agenbroad identified the following processes that modified the bones at the Hot Springs Mammoth Site: biological (trampling, torsion/falling, carnivores), hydrological (spring effluent, subaqueous down-slope movement), geological/structural (postdepositional movement), and mechanical (boulder fall, freezing, overbank fall).

Animal chewing, and other causes of bone breakage, can be confounding variables in forensic interpretations. On the one hand, such processes can obscure evidence of the cause and manner of death. On the other hand, some modifications such as spiral fractures with impact scars, can be difficult to interpret. It is necessary to examine the patterns using taphonomic models of animal modification and careful scene reconstruction.

## Weathering Patterns

---

In the taphonomic process, weathering represents the response of the bone to its immediate environment, e.g., soil, sun, etc. as opposed to carnivore modifications, trampling, fluvial transport, and geochemical changes (Behrensmeyer 1978; Miller 1975). From her research with bones of recent mammals in the Amboseli Basin in southern Kenya, Behrensmeyer (1978) recognized six progressive stages of bone weathering:

**Stage 0.** Bone surface shows no sign of cracking or flaking due to weathering. Usually bone is still greasy. Marrow cavities contain tissue; skin and muscle/ligament may cover part or all of the bone surface.

**Stage 1.** Bone shows cracking, normally parallel to the fiber structure (e.g., longitudinal in long bones). Articular surfaces may show mosaic cracking of covering tissue as well as in the bone itself. Fat, skin, and other tissue may or may not be present.

**Stage 2.** Outermost concentric thin layers of bone show flaking, usually associated with cracks, in that the bone edges along the cracks tend to separate and flake first. Long thin flakes, with one or more sides still attached to the bone, are common in the initial part of stage 2. Deeper and more extensive flaking follows, until most of the outermost bone is gone. Crack edges are usually angular in cross section. Remnants of ligaments, cartilage, and skin may be present.

**Stage 3.** Bone surface is characterized by patches of rough, homogeneously weathered compact bone, resulting in a fibrous texture. In these patches, all the external, concentrically layered bone has been removed. Gradually the patches extend to cover the entire bone surface. Weathering does not penetrate deeper than 1.0 to 1.5 mm at this stage, and bone fibers are still firmly attached to each other. Crack edges usually are rounded in cross section. Tissue rarely present at this stage.

**Stage 4.** The bone surface is coarsely fibrous and rough in texture; large and small splinters occur and may be loose enough to fall away from the bone when it is moved. Weathering penetrates into inner cavities. Cracks are open and have splintered or rounded edges.

**Stage 5.** Bone is falling apart *in situ*, with large splinters lying around what remains of the whole, which is fragile and easily broken by moving. Original bone shape may be difficult to determine. Cancellous bone usually exposed, when present, and may outlast all traces of the former more compact, outer parts of the bones. (Behrensmeyer 1978:151).

The Behrensmeyer weathering model can assist in understanding and reconstructing the postmortem interval (see Lyman and Fox this volume). Although in human forensic cases that interval is much shorter than in paleontological contexts, weathering changes can frequently be key to ruling out perimortem trauma.

## Forensic Anthropology Applications

---

Many of the paleontological and archaeological principles outlined above have direct utility in forensic anthropology (Micozzi 1991; Ubelaker 1989, 1991). Particular areas of application are: (1) estimation of postmortem interval (time since death); (2) environmental reconstruction

or the detection of unknown postmortem scenarios; (3) reconstruction of postmortem events; and (4) distinguishing evidence of foul play from alterations caused by other taphonomic factors.

Taphonomic assessment of human remains differs from that of nonhuman animals not only in the structural differences between humans and nonhuman animals that may influence response to taphonomic forces, but especially in that human behavior frequently is involved normally in the postmortem treatment of the dead. Thus, with humans, postmortem interpretation includes not only the possible effects of weathering, trampling, etc., but also embalming, cremation, or other types of burning (Buikstra and Swegle 1989; Dawson and Santos 1990; Murray and Rose 1993; Nelson 1992), burial, coffin enclosure and many other cultural factors.

In the practice of forensic anthropology, taphonomic consideration has come to mean interpretation of all events affecting the remains between death and discovery. Since most forensic anthropologists also are experienced in aspects of archaeology and in the interpretation of archaeologically recovered human remains, they are most qualified to make such assessments. With many cases, taphonomic assessment represents the most important contributions made by anthropologists. This is especially true in the interpretation of skeletal evidence for foul play.

## **Estimation of Postmortem Interval**

---

Although the study of arthropods associated with remains and other factors can contribute to the estimation of the postmortem interval (Goff and Flynn 1991; Haglund and Reay 1993; Haglund et al. 1990; Schoenly et al. 1991, 1992; Skinner et al. 1988), usually such interpretations of largely skeletonized human remains involve assessment of their condition. Recent research and experience have documented how variable the rate of decomposition can be. Influencing factors can be the ambient temperature, amount of rainfall, clothing, burial type, burial depth, extent of animal chewing and disarticulation, extent of perimortem trauma, body weight, and general environmental conditions (Bass and Meadows 1990).

The pattern of postmortem change varies regionally and among microenvironments within each region. Galloway et al. (1989) document rapid bloating, but extensive mummification in the dry environment of southern Arizona. Tropical environments can involve skeletonization within 2 weeks (Ubelaker 1989). Freezing and thawing as well as mechanical injury can influence the process (Micozzi 1986). The formation of adipocere in wet environments can lead to exceptionally long-term preservation (Mellen et al. 1993).

The general pattern of disarticulation and bone weathering documented in experimental studies stemming from paleontological interests generally applies to humans as well. In fact, Bielenstein (1990) demonstrates that Behrensmeier's (1978) stages of bone weathering match the sequence seen in modern forensic cases.

Much of the research on animal chewing of animal carcasses documented above also has been extended to humans. Different animals leave distinct patterns of tooth marks on human bone (Haglund et al. 1988; Haglund 1992; Milner and Smith 1989; Ubelaker 1989; Willey and Snyder 1989). The amount of carnivore activity varies considerably due to circumstances that shelter the remains from animal access and the human population density in the area (Haglund et al. 1988). With human remains, Haglund et al. (1989) document five stages of sequential alteration due to canid scavenging. These are (1) no bony involvement, (2) ventral thorax damage with one or both upper extremities removed, (3) lower extremity involvement, (4) only vertebral segments remaining articulated, and (5) total disarticulation. Obviously, previous trauma to the remains or other unusual factors may influence the sequence of change.

Research at the University of Tennessee in Knoxville also has shown that volatile fatty acids produced from soft tissue decomposition and anions and cations also from soft tissue may be detected within the soil beneath human remains. Measurement of these factors in

controlled samples can allow accurate estimates of postmortem interval in some circumstances (Vass et al. 1992).

Experimentation and experience have revealed useful information on the decomposition process. Usually with surface burials, most odor and much of the soft tissue are gone within 6 months (depending upon the season). Sun bleaching, bone surface cracking, and the processes identified in Behrensmeier's (1978) stages 2 through 5 usually indicate many months or even many years, depending upon the circumstances.

The variability in the rate of postmortem change can be impressive. Obviously, in arid environments such as coastal Peru or even the American southwest, mummification can occur naturally, leading to soft tissue preservation for hundreds or even thousands of years. In a tropical environment where remains are exposed to scavenging animals, a human body can be skeletonized within 14 days (Ubelaker 1989).

Such variability can occur even within a single site. At one South Dakota historic cemetery that had not been in use for several decades, a relocation project discovered some remains had been reduced to unrecognizable fragments while others were mummified and extremely well preserved.

Bass (1984) provides an excellent example of how difficult estimating time since death can be. His examination of the remains within the recently disturbed grave of a man who died 113 years previously revealed excellent soft tissue preservation, extensive odor and clothing as well. He initially suspected the remains were a recent deposit in the old grave. Later he learned that the remains actually were those of the man described on the tombstone. A cast iron coffin allowed the unusual preservation.

## **Environmental Reconstruction**

---

Although little has been written about the importance of environmental reconstruction from taphonomic indicators, in my experience, it can be of potential significance in forensic anthropology. Barnacles adhering to bones indicate exposure to salt water. Green algae stain frequently is present on remains from moist shaded areas. Soil embedded in orifices indicates previous burial. Bleaching of bone surfaces usually indicates prolonged sun exposure, although salt water can produce similar results. Adipocere usually indicates a wet environment.

Such observations usually reflect the known conditions surrounding the discovery site. Cobwebs are found within a skull recovered from a garage. Soil-filled bones with sun exposure are expected from remains found from a grave disturbed years ago in a sunny area.

Remains originating from previous burial in a cemetery also can be detected. Berryman et al. (1991) note that physical characteristics associated with the embalming process, artifacts associated with the coffin, devices used in embalming, and levels of chemicals in the soft tissue all provide clues to the remains' history.

## **Sequence of Postmortem Events**

---

Occasionally, taphonomic observations can be used not only to describe postmortem events, but also to determine their sequence. Mann and Owsley (1992) describe a case in which a skeleton was discovered in a farmer's field with a shotgun in association. A spent slug casing was present in the breach of the shotgun. Skeletal analysis revealed cranial fragmentation as well as numerous small round perforations in the pelvic area.

Although not all of the cranial fragments were present, those present were multicolored. Some fragments that articulated showed marked contrast in color, ranging from sun bleached white to a dark brown. Although no clear-cut exit or entry gunshot injury was found, the overall pattern of fracture was consistent with gunshot wound. The variability in coloration

of anatomically adjacent fragments suggested that breakage occurred early in the postmortem interval. Microscopic examination coupled with infrared spectrometry of small particles imbedded within fractured cranial surfaces revealed them to be plastics containing cellulose nitrate, a known residue of gunpowder. All of these observations suggested “a perimortem close-range gunshot to the face or throat” (Mann and Owsley, 1992:1387).

In contrast, the alterations on the postcranial skeleton revealed a different pattern. Analysis revealed fractures of the right tibia, left scapula, and fifth lumbar vertebra, obvious plow cuts on other bones, alga stains on the mandible and the medullary cavity of the fractured right tibia, and 71 pellet-type perforations on the os coxae, right femoral head, proximal left femur, and the spinous process of the third lumbar vertebra.

Several taphonomic factors indicated that the pellet injury was sustained postmortem. Several of the perforations were located on the head of the femur with no injury to the corresponding area of the acetabulum area of the pelvis. This clearly indicated that the femur and pelvis were not articulated when the injury was sustained. Perforations also were present on the symphyseal surface of the left pubis with no damage to the corresponding area of the right symphyseal surface.

Small weathering cracks were present on the bones of the pelvis, indicating exposure of 2 to 3 years. Pellet perforations intersected several of the small cracks, indicating cracks had formed prior to the formation of the perforations. If the reverse had been true, the cracks would have terminated at the perforations and not have passed through them. Clearly the skeleton had been resting in the field long enough for the weathering cracks to form before the perforations were made. Taphonomic observations allowed the sequence of postmortem events to be established and the recognition that two events of gunshot trauma were present, one perimortem in the cranial area and another postmortem in the pelvic area.

## **Pseudo-Trauma**

---

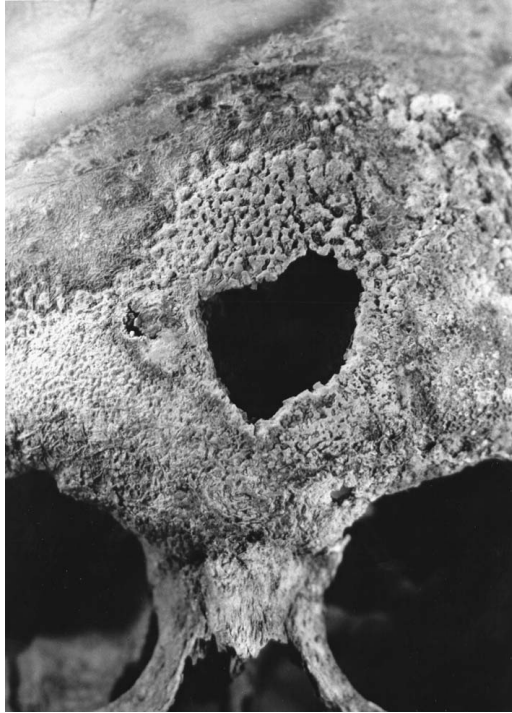Weathering cracks can resemble those produced by blunt force trauma. Trampling and carnivore chewing can cause spiral fractures similar to those caused by foul play-associated trauma. Fungus can cause a blackening of bones that simulates burning. Carnivore tooth marks can appear very similar to sharp force trauma. All of these factors call for detailed examination of such remains by an experienced forensic anthropologist (Ubelaker 1991).

## **The Lady in the Cistern**

---

At times evidence of foul play and taphonomic conditions that mimic foul play may appear on the same skeleton or even the same bone. In 1984 human remains were found within an unused cistern near a midwestern U.S. airport. The remains were identified by dental comparison as those of a young woman reported missing in 1975 (Ubelaker and Sperber 1988). Witnesses indicated she had attended a party hosted by a local Hell's Angels group on the night of her disappearance. Authorities found evidence of a fire in the basement of the house and noted that some wooden steps leading to the basement were missing. They suspected that after she had been killed, her attackers had attempted to burn the body before depositing it within the cistern. The theory was strengthened by the presence of a blackened distal femur. Analysis revealed, however, that the blackened area was produced by fungus growing within the damp dark cistern and was a postmortem phenomenon not related to foul play.

In contrast to this natural process, much of the outer structures of the face had been destroyed, apparently by an acid-like material (Figure 1). The destruction was too severe and too localized to represent a natural taphonomic process and thus had to represent foul play.



**Figure 1** Localized destruction of skull due to acid-like substance.

Confronted with the evidence, the defense argued that perhaps the alterations had been produced within the cistern, with the skull in contact with caustic substances within the soil.

The soil had been tested and was found to be relatively neutral pH. The proof rested with the observation that the pattern of destruction extended across the occlusal plane from the maxilla to the mandible. The skull and mandible were not found in contact; the cranium had rolled off the skeleton and was resting on its side. The alterations on the bones had to have originated perimortem before decomposition when the bones were still articulated.

Additional alterations were observed on the top of the cranium. Roughly circular white circles were present. Initially it was thought they must be related to the destruction on the face, but the bone in the affected area was only whitened and showed none of the extensive bone loss seen on the bones of the face. Apparently the white dots were produced by sunlight beaming through perforations in the thick manhole cover above.

## **Carl Weiss**

---

In 1991, I was invited to participate in the exhumation and study of the remains of Dr. Carl Austin Weiss of Baton Rouge, LA. Dr. Weiss had been a 29-year-old ear, nose, and throat specialist in Baton Rouge when he was killed on September 8, 1935 (Ubelaker and Scammell 1992). He was accused of shooting former Governor and State Senator Huey P. Long and was in turn shot many times by Senator Long's bodyguards. Controversy followed the shooting, not only because, as a young physician with a family and house calls to make, Weiss was a very unlikely assassin, but also because a nurse who treated Long noticed he had a cut lip. When asked about the cut, Long replied: "That's where he hit me." Critics of the assassin theory argue that if Weiss hit Long with his fist, then he likely did not shoot him.

Careful reconstruction and study of the bone fragments included in Weiss' remains indicated that he had been shot at least 20 times, with about half of them coming from behind. Because of the historical controversy regarding the scenario that Weiss struck Long with his fist, I carefully examined the hand bones for evidence of trauma. Radiographs and visual examination revealed no apparent gross fractures. However, microscopic examination revealed a series of small fractures within the metacarpals of the right hand, raising the possibility that Weiss had sustained stress fractures of the metacarpal diaphyses but had not completely fractured the necks of the bones. However, additional analysis revealed similar small fractures on the diaphyses of the metacarpals of the left hand and on some of the metatarsals as well. Clearly the microfractures resulted from postmortem taphonomic factors and not from perimortem trauma.

Another unusual feature of the Weiss skeleton was a peculiar metallic blackening of the teeth. The black stain was located on the lingual aspects of most of the teeth but on the buccal surfaces of only the mandibular teeth. Analysis of the stain by electron-induced X-ray spectroscopy with a scanning electron microscope revealed a mercury composition. Had Dr. Carl Weiss consumed mercury turning him into a deranged killer? No. I reasoned that if such were the case, mercury would be dispersed throughout his system and would be detected within those structures growing at the time of death. Analysis of the basal extremes of body hair and toenails revealed no evidence of mercury.

The mercury on the teeth apparently originated from Weiss' amalgam fillings that were obviously deteriorating after 56 years in the ground. The released mercury concentrated on the lingual margins of the teeth in the immediate area. Weiss' marked dental overbite created the space through which some mercury managed to travel to eventually settle on the labial surfaces of the anterior teeth.

Coincidentally, a nonmetallic-looking black stain was present on many bones of the skeleton. Analysis revealed this stain to be primarily sulfuric in origin and likely originating from byproducts of soft tissue decomposition, held captive by the burial container.

Other interesting taphonomic features of the Weiss remains were small white crystalline deposits located throughout the postcranial skeleton. Analysis revealed these also were of sulfuric origin, likely originating from soft tissue decomposition. When the small deposits were removed, they left behind a small crater-like perforation in the bone cortex that perhaps to some would imitate a disease condition.

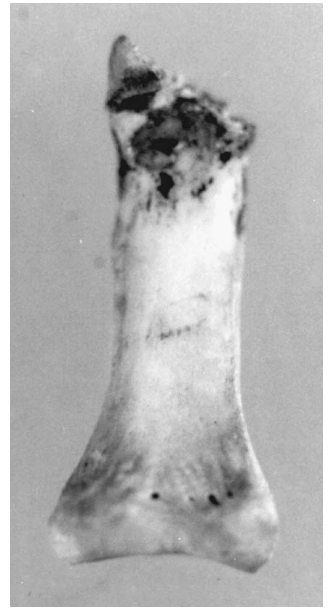
## Goochland, Virginia

---

In 1982, a skeleton was found by berry pickers in rural Goochland County, VA. A shoestring was present around the cervical vertebrae, indicating manual strangulation. The remains were brought to the National Museum of Natural History where forensic anthropologist J. Lawrence Angel observed an angular sheared planar surface on the distal end of a carpal phalanx. Angel's report noted, "A striking peculiarity is the diagonal cut amputating a 3 to 5 mm section of the distal joint of the basal phalanx of the left little finger (Figure 2). Does this come from the killer's removal of fingertips? from a defense slash (though there are no cuts on the facial bones)? from a postmortem cut? or, least likely, from accidental amputation by some kind of meat-packing machine shortly before death?"

The skeleton was later identified as being a young woman from Puerto Rico (Ubelaker and Scammell 1992). In 1991, a suspect was charged with the crime. The prosecutor in the case realized that cause of death was ligature strangulation but also focused on the possibility that in addition, her finger may have been amputated. The original examiner at the Smithsonian, Dr. Angel, had died in 1986 and the evidence of the altered phalanx apparently had been buried with the rest of the remains back in Puerto Rico.





**Figure 2** Diagonal amputation of the left fifth proximal carpal phalanx.

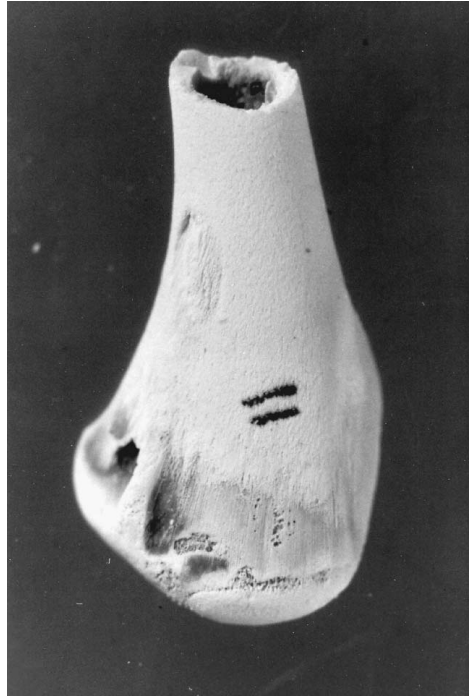
Recognizing that I could not offer an opinion on evidence that I had not examined, I accepted the prosecutor's invitation to travel to Puerto Rico to supervise the exhumation of the remains and to try to locate the altered phalanx. In May, 1991, the remains were exhumed and examined in the nearby Medical Examiners Office.

Since Dr. Angel's examination, the remains had become stained dark gray, apparently by moisture and decomposing materials within the carton in which they were buried. The altered phalanx was found within a sealed plastic bag mixed in with the other remains and retained the original coloration. Some nonhuman animal bones were present, as well as evidence of extensive carnivore gnawing throughout the skeleton, including hand bones.

As noted by Angel, the left fifth proximal hand phalanx displayed loss of bone. A 3- to 7-mm section of this bone was missing from the lateral surface. The broken surface was roughly planar. Microscopic examination indicated irregular fracturing of the cancellous bone and slight irregularity in the axis of the cut or broken surface. Microscopic examination also revealed two alterations on the bone that were likely produced by carnivore chewing; one small indentation on the lateral surface immediately proximal to the cut or altered surface; and a small scratch on the superior surface near the midline. The cut or broken surface lacked the uniformly planar surface and pattern of evenly cut bone that would be expected if the bone had been cut with a sharp knife.

To reinforce my impression, I conducted a series of experiments. Chicken thighs and wings were purchased, recognizing that the cortical thickness and cancellous bones on the extreme ends were similar to those of the relevant aspect of human phalanges. The chicken parts were struck with a sharp knife, a dull knife, a digging tool and an axe. Parts were also tested by slamming them in the doors and hatchback of a 1974 Ford Pinto (the same model as that owned by the victim). One possible scenario suggested by the prosecutor was that the finger may have been damaged by the car door slamming on it during a struggle.

Following the testing, all of the chicken parts were defleshed, degreased, and examined grossly and microscopically. A planar pattern of fracture with irregular cancellous bone similar to that observed on the human phalanx was found on the chicken bones altered by a dull knife, axe, and the digging tool. Even one (the hatchback) of 16 tests of the Ford Pinto produced similar injury ([Figure 3](#)).



**Figure 3** Typical pattern of amputation of chicken bone by a dull blade or straight edge.

I concluded that “the pattern of alteration is consistent with it being forcibly cut or broken with a dull (not sharp) blade or straight edge. In my opinion, this type of alteration could have been produced by the finger being struck with a dull knife, dull shovel, mattock, or similar instrument. Conceivably, this type of alteration also could have been produced if a car door was forcibly closed on the finger. It is also possible that a dog-size carnivore could have caused this damage with its posterior shearing teeth. Note that I have never before seen damage like this caused by carnivore chewing. Typically carnivore chewing will cause fractured and crushed bones with irregular jagged surfaces of the type seen with all other examples of alterations on this skeleton. The alteration on the left fifth phalanx is distinct from all of the other alterations in that it is relatively planar and evenly cut. Although such a cut by a carnivore would be very unusual, it is possible given the structure of the carnivore posterior teeth.”

## **Bones from the Cemetery: Recent or Old?**

---

In July of 1991, a young woman was reported missing. Subsequent investigation revealed that she may have been abducted and killed, with the body buried in a local cemetery. In September, 1992, excavation of a likely unauthorized burial site within the cemetery recovered a number of bones thought to possibly represent those of the victim. The remains were submitted for analysis to the Department of Anthropology, National Museum of Natural History, Smithsonian Institution in Washington, D.C. through the FBI Laboratories.

Analysis revealed that the only bones present were a left scapula, one cervical vertebra, one left upper rib, one right foot navicular, one thoracic vertebra, one right metatarsal, and one cranial fragment. Neither soft tissue nor odor was present. All of the bones showed considerable surface cracking and exfoliation of the periosteal surfaces. Many areas of the bones were fragmented and/or eroded.

Analysis indicated that all bones likely originated from one individual, a young to middle-age adult female. Although this information was consistent with the age and sex of the missing

person, the extent of weathering changes indicated the bones originated from an old grave in the cemetery and not the recent missing person.

In addition, the thoracic vertebra showed planar trauma on the proximal surface of the centrum. Sharp force trauma consisted of a wide, deep incision on the anterior surface of the centrum. The lack of soil adhesion, lack of erosion of the exposed trabeculae and a coloration pattern distinct from that seen on the other outer bone surfaces indicated the alterations had not been made perimortem but much more recently. They appeared to be typical of alterations made by a shovel.

Besides recovery damage, previous examiners of forensic remains may leave alterations on the bones that can be mistaken for perimortem trauma. With several cases, I have discovered definitive evidence of sharp force trauma only to realize that it was produced by a scalpel or striker saw during previous examination. White and Toth (1989) report that the measuring instruments of an anthropologist likely produced marks on a human fossil that others interpreted as being ancient cutmarks.

## Summary

---

Taphonomic interpretation has assumed a vital and unique place in the forensic anthropology tool kit. Consideration of taphonomic factors is essential in past environmental reconstruction, estimation of postmortem interval, reconstruction of the sequence of postmortem events, and the assessment of trauma and pseudotrauma.

## References

- Aaris-Sorensen, K.  
1983 An Example of Taphonomic Loss in a Mesolithic Faunal Assemblage. In *Animals and Archaeology: Hunters and Their Prey*, edited by J. Clutton-Brock and C. Grigson, pp. 243–247. BAR International Series 163, British Archaeological Research, Oxford, U.K.
- Agenbroad, L.  
1989 Spiral Fractured Mammoth Bone from Nonhuman Taphonomic Processes at Hot Springs Mammoth Site. In *Bone Modification*, edited by R. Bonnicksen and M.H. Sorg, pp. 139–147. Center for The Study of the First Americans, Orono, ME.
- Andrews, P., and J. Cook  
1985 Natural Modifications to Bones in a Temperate Setting. *Man* 20:675–691.
- Bass, W.M.  
1984 Time Interval since Death, a Difficult Decision. In *Human Identification, Case Studies in Forensic Anthropology*, edited by T.A. Rathbun and J.E. Buikstra, pp. 136–147. Charles C Thomas, Springfield, IL.
- Bass, W.M., and L. Meadows  
1990 Time since Death and Decomposition of the Human Body: Variables and Observations in Case and Experimental Field Studies. *Journal of Forensic Sciences* 35:103–111.
- Beebe, B.F.  
1983 Evidence of Carnivore Activity in a Late Pleistocene/Early Holocene Archaeological Site (Bluefish Cave 1), Yukon Territory. In *Carnivores, Human Scavengers and Predators: A Question of Bone Technology*, edited by G.M. LeMoine and A.S. Mac Eachern, pp. 1–14. Archaeological Association of the University of Calgary, Calgary.

- Behrensmeyer, A.K.  
1978 Taphonomic and Ecological Information from Bone Weathering. *Paleobiology* 4:150–162.
- Behrensmeyer, A.K., K.D. Gordon, and G.T. Yanagi  
1986 Trampling as a Cause of Bone Surface Damage and Pseudo-Cutmarks. *Nature* 319(6065):768–771.
- Berryman, H.E., W.M. Bass, S.A. Symes, and O.C. Smith  
1991 Recognition of Cemetery Remains in the Forensic Setting. *Journal of Forensic Sciences* 36:230–237.
- Bielenstein, D.E.M.  
1990 *Forensic Taphonomy: Definitions and Applications to Forensic Anthropology and Paleoanthropology*. Unpublished master's thesis, George Washington University, Washington, D.C.
- Binford, L.R., and C.K. Ho  
1985 Taphonomy at a Distance: Zhoukoudian, "The Cave Home of Beijing Man." *Current Anthropology* 26:413–442.
- Buikstra, J.E., and M. Swegle  
1989 Bone Modification Due to Burning: Experimental Evidence. In *Bone Modification*, edited by R. Bonnichsen and M.H. Sorg, pp. 247–258. Center for The Study of the First Americans, Orono, ME.
- Dawson, G.D., and J.F. Santos  
1990 Differences in Final Arrangements between Burial and Cremation as the Method of Body Disposition. *Omega* 21:129–146.
- Efremov, I.A.  
1940 Taphonomy, a New Branch of Paleontology. *Izvestiya Akademii Nauk SSSR Leningrad, Biology Series*, 3, pp. 405–413.
- Galloway, A., W.H. Birkby, A.M. Jones, T.H. Henry, and B.O. Parks  
1989 Decay Rates of Human Remains in an Arid Environment. *Journal of Forensic Sciences* 34:607–616.
- Goff, M.L., and M.M. Flynn  
1991 Determination of Postmortem Interval by Arthropod Succession: A Case Study from the Hawaiian Islands. *Journal of Forensic Sciences* 36:607–614.
- Haglund, W.D.  
1992 Contribution of Rodents to Postmortem Artifacts of Bone and Soft Tissue. *Journal of Forensic Sciences* 37:1459–1465.
- Haglund, W.D., and D.T. Reay  
1993 Problems of Recovering Partial Human Remains at Different Times and Locations: Concerns for Death Investigators. *Journal of Forensic Sciences* 38: 69–80.
- Haglund, W.D., D.T. Reay, and D.R. Swindler  
1988 Tooth Mark Artifacts and Survival of Bones in Animal Scavenged Human Skeletons. *Journal of Forensic Sciences* 33:985–997.  
1989 Canid Scavenging/Disarticulation Sequence of Human Remains in the Pacific Northwest. *Journal of Forensic Sciences* 34:587–606.
- Haglund, W.D., D.G. Reichert, and D.T. Reay  
1990 Recovery of Decomposed and Skeletal Human Remains in the Green River Murder Investigation: Implications for Medical Examiner/Coroner and Police. *American Journal of Forensic Medicine and Pathology* 11:35–43.

Haynes, G.

- 1980a Evidence of Carnivore Gnawing on Pleistocene and Recent Mammalian Bones. *Paleobiology* 6:341–351.
- 1980b Taphonomical Studies in North America: Analogues for Paleocology. *American Quaternary Association, Abstracts of the Sixth Biennial Meeting*, p. 93. University of Maine, Orono.
- 1982 Utilization and Skeletal Differences of North American Prey Carcasses. *Arctic* 35:266–281.
- 1983a A Guide for Differentiating Mammalian Carnivore Taxa Responsible for Gnaw Damage to Herbivore Limb Bones. *Paleobiology* 9:164–172.
- 1983b Frequencies of Spiral and Green-Bone Fractures on Ungulate Limb Bones in Modern Surface Assemblages. *American Antiquity* 48:102–114.

Hill, A.

- 1976 On Carnivore and Weathering Damage to Bone. *Current Anthropology* 17:335–336.
- 1979 Disarticulation and Scattering of Mammal Skeletons. *Paleobiology* 5:261–274.

Hill, A.P., and A.K. Behrensmeyer

- 1984 Disarticulation Patterns of Some Modern East African Mammals. *Paleobiology* 10:366–376.

Mann, R.W., and D.W. Owsley

- 1992 Human Osteology: Key to the Sequence of Events in Postmortem Shooting. *Journal of Forensic Sciences* 37:1386–1392.

Marshall, L.G.

- 1989 Bone Modification and “The Laws of Burial.” In *Bone Modification*, edited by R. Bonnicksen and M.H. Sorg, pp. 7–24. Center for the Study of the First Americans, Orono, ME.

Mellen, P.F.M., M.A. Lowry, and M.S. Micozzi

- 1993 Experimental Observations on Adipocere Formation. *Journal of Forensic Sciences* 38:91–93.

Micozzi, M.S.

- 1986 Experimental Study of Postmortem Change under Field Conditions: Effects of Freezing, Thawing, and Mechanical Injury. *Journal of Forensic Sciences* 32:953–961.
- 1991 *Postmortem Change in Human and Animal Remains: A Systematic Approach*. Charles C Thomas, Springfield, IL.

Milner, G.J.

- 1969 A Study of Cuts, Grooves, and Other Marks on Recent and Fossil Bone. I Animal Tooth Marks. *Tebiwa* 12:20–26.
- 1975 A Study of Cuts, Grooves, and Other Marks on Recent and Fossil Bone. II Weathering Cracks, Fractures, Splinters, and Other Similar Natural Phenomena. In *Lithic Technology*, edited by E. Swanson, pp. 211–226. Mouton Publishers, Paris.

Milner, G.J., and V.G. Smith

- 1989 Carnivore Alteration of Human Bone from a Late Prehistoric Site in Illinois. *American Journal of Physical Anthropology* 79:43–49.

Morlan, R.E.

- 1980 *Taphonomy and Archaeology in the Upper Pleistocene of the Northern Yukon Territory: A Glimpse of the Peopling of the New World*. Mercury Series Paper No. 94, National Museum of Man, Ottawa.
- 1984 Toward the Definition of Criteria for the Recognition of Artificial Bone Alterations. *Quaternary Research* 22:160–171.

- Murray, K.A., and J.C. Rose  
1993 The Analysis of Cremains: a Case Study Involving the Inappropriate Disposal of Mortuary Remains. *Journal of Forensic Sciences* 38:98–103.
- Nelson, R.  
1992 A Microscopic Comparison of Fresh and Burned Bone. *Journal of Forensic Sciences* 37:1055–1060.
- Schoenly, K., M.L. Goff, and M. Early  
1992 A BASIC Algorithm for Calculating the Postmortem Interval from Arthropod Successional Data. *Journal of Forensic Sciences* 37:808–823.
- Schoenly, K., K. Griest, and S. Rhine  
1991 An Experimental Field Protocol for Investigating the Postmortem Interval Using Multidisciplinary Indicators. *Journal of Forensic Sciences* 36:1395–1415.
- Shipman, P.  
1981 *Life History of a Fossil: An Introduction to Taphonomy and Paleoecology*. Harvard University Press, Cambridge, MA.
- Skinner, M.F., A. Syed, J. Farrell, and J.H. Borden  
1988 Case Report in Forensic Anthropology: Animal and Insect Factors in Decomposition of Homicide Victim. *Canadian Society Forensic Science Journal* 21:71–81.
- Sutcliffe, A.J.  
1971 Similarity of Bones and Antlers Gnawed by Deer to Human Artifacts. *Nature* 246(5433):428–430.
- Ubelaker, D.H.  
1989 *Human Skeletal Remains. Excavation, Analysis, Interpretation*. 2nd ed. Taraxacum, Washington, D.C.  
1991 Perimortem and Postmortem Modification of Human Bone. Lessons from Forensic Anthropology. *Anthropologie* 29:171–174.
- Ubelaker, D.H., and H. Scammell  
1992 *Bones: A Forensic Detective's Casebook*. HarperCollins, New York.
- Ubelaker, D.H., and N.D. Sperber  
1988 Alterations in Human Bones and Teeth as a Result of Restricted Sun Exposure and Contact with Corrosive Agents. *Journal of Forensic Sciences* 33:540–548.
- Vass, A.A., W. Bass, J.D. Wolt, J.E. Foss, and J.T. Ammons  
1992 Time Since Death Determinations of Human Cadavers Using Soil Solution. *Journal of Forensic Sciences* 37:1236–1253.
- White, T.D., and N. Toth  
1989 Engis: Preparation Damage, Not Ancient Cutmarks. *American Journal of Physical Anthropology* 78:361–368.
- Wiley, P., and L.M. Snyder  
1989 Canid Modifications of Human Remains: Implications for Time-Since-Death Estimations. *Journal of Forensic Sciences* 34:894–901.