Clinical Radiology (2004) **59**, 977–983

REVIEW

Computed tomography in the imaging of colonic diverticulitis

O. Buckley[a], T. Geoghegan[b], D.S. O'Riordain[a], I.D. Lyburn[c], W.C. Torreggiani[b,*]

Departments of [a]Surgery and [b]Radiology, Adelaide and Meath Incorporating the National Children's Hospital, Tallaght, Dublin, Ireland; and [c]Radiology, Cheltenham General Hospital, Cheltenham, UK

Received 28 August 2003; received in revised form 13 April 2004; accepted 4 May 2004

KEYWORDS
Computed tomography (CT); Diagnostic imaging; Diverticulitis; Colonic

Colonic diverticulitis occurs when diverticula within the colon become infected or inflamed. It is becoming an increasingly common cause for hospital admission, particularly in western society, where it is linked to a low fibre diet. Symptoms of diverticulitis include abdominal pain, diarrhoea and pyrexia, however, symptoms are often non-specific and the clinical diagnosis may be difficult. In addition, elderly patients and those taking corticosteroids may have limited findings on physical examination, even in the presence of severe diverticulitis. A high index of suspicion is required in such patients in order to avoid a significant delay in arriving at the correct diagnosis. Imaging plays an important role in establishing an early and correct diagnosis. In the past, contrast enema studies were the principal imaging test used to make the diagnosis. However, such studies lack sensitivity and have limited success in identifying abscesses that may require drainage. Conversely computed tomography (CT) is both sensitive and specific in making a diagnosis of diverticulitis. In addition, it is the imaging technique of choice in depicting complications such as perforation, abscess formation and fistulae. CT-guided drainage of diverticular abscesses helps to reduce sepsis and to permit a one-stage, rather than two-stage, surgical operation. The purpose of this review article is to discuss the role of CT in the imaging of diverticulitis, describe the CT imaging features and complications of this disease, as well as review the impact and rationale of CT imaging and intervention in the overall management of patients with diverticulitis.

Definition and incidence

Colonic diverticula represent herniations through the colonic wall. Acquired diverticular disease affects 5–10% of people over the age of 45 years, increasing to affect almost 80% by the age of 80 years.[1] This is most likely related to the structural changes that reduce the tensile strength and elasticity of the colon wall with advancing age.[2] Qualitative alterations rather than quantitative changes in collagen content of the colon appear to be central in this regard.[3] Between 10–25% of individuals with colonic diverticular disease will develop diverticulitis at some point, with a recurrence risk of 7–35%.[4] McConnell et al.[5] described the population-based incidence of complicated diverticular disease of the sigmoid colon based on gender and age in 934 patients requiring surgery for complicated diverticular disease and demonstrated that, on average, women presented 5 years later than their male counterparts.

*Guarantor and correspondent: W. C. Torreggiani, Department of Radiology, Adelaide and Meath Hospital, Tallaght, Dublin 24, Ireland. Tel.: +353-14143700; fax: +353-14143508.
E-mail address: william.torreggiani@amnch.ie

0009-9260/$ - see front matter
doi:10.1016/j.crad.2004.05.003

Aetiology

Colonic diverticular disease most commonly affects the rectosigmoid colon. The pathophysiology of diverticular disease is likely to be related to a complex relationship between age, dietary factors, colon structure and motility. Diverticular disease is traditionally accepted as a condition of Western civilization.[6] The condition is rarely encountered in populations inhabiting rural regions with Asia and Africa. Raised intra-colonic pressure occurs as an adaptative mechanism to a low-fibre diet, which is associated with an increased transit time.[7] This is associated with increased desiccation and viscosity of the faecal content,[8] promoting the development of diverticula.

Diverticulitis is the most common clinical complication of colonic diverticular disease. Diverticulitis results from obstruction at the neck of a diverticulum leading to localized inflammation.[9] Smoking is associated with an increased risk of complications in diverticular disease.[10] Opioid analgesics, non-steroidal anti-inflammatory drugs and corticosteroids are all positively associated with an increased risk of perforated colonic diverticular disease.[11] Calcium channel blockers, which reduce colonic contractility and tone, protect against perforation in colonic diverticular disease.[12]

Clinical presentation

The diagnosis of acute diverticulitis is made using a combination of history, clinical examination, biochemical analysis and radiological investigations. The symptoms of acute diverticulitis may be non-specific and include abdominal pain, fever and diarrhoea. Physical examination may reveal tenderness in the right or left iliac fossae and occasionally the presence of a palpable tender mass. Initial blood tests typically show elevated inflammatory markers with a leucocytosis, polynuclear left shift and a raised C-reactive protein. The effective management of diverticulitis depends on the recognition and evaluation of the extent of the inflammatory process.

Computed tomography (CT) parameters in patients with suspected acute diverticulitis

At our institution, CT is performed from the diaphragm to the pubic symphysis. Oral water-soluble contrast medium is administered 60 min before the examination. Non-ionic contrast medium (100 ml) is administered at a rate of 2 ml/s via an infusion pump, and imaging performed after a 60 s delay. Slice thickness is characteristically 10 mm. In selected cases, water-soluble contrast medium may be administered rectally. The use of oral and intravenous contrast media improves the ability to diagnose small perforations and characterize related complications.[13]

CT findings in acute diverticulitis

CT is the most sensitive and specific imaging technique for the diagnosis of acute diverticulitis. Retert et al.[14] have reported sensitivities and specificities of 100%. In addition to establishing the diagnosis of acute diverticulitis, the identification of colonic perforation, abscess formation, colonic strictures and fistula formation have a direct impact on the management of the patient.

Hulnick et al.[15] have described the complications of diverticulitis demonstrated on CT in 43 patients with colonic diverticulitis. The complications of colonic diverticulitis included inflammation of the peri-colic fat in 98% of cases (Fig. 1), thickening of the colon wall in 70%, pericolic abscess in 35% (Fig. 2), peritonitis in 16%, colonic obstruction in 12% (Fig. 3) and intra-mural sinus tracts in 9%. The secondary complications included distant abscess formation in 12% and ureteral obstruction in 7%. Diverticulitis may result in a localized (Fig. 4) or generalized perforation of the colon.[16] (Fig. 5). The diverticulum perforates when the neck of the diverticulum becomes obstructed and the perfusion

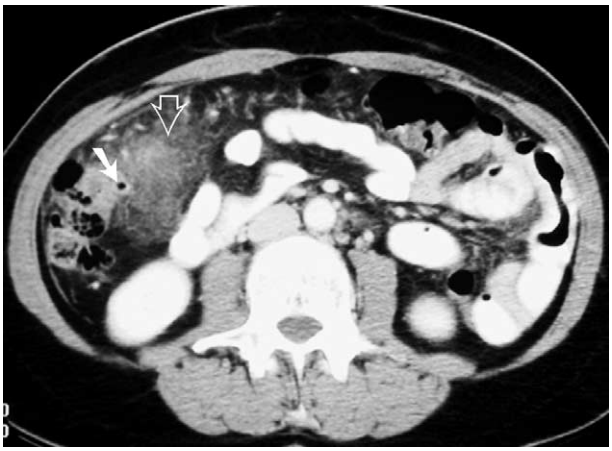

Figure 1 Transverse CT of the lower abdomen post-oral and intravenous contrast media demonstrates marked stranding (open arrow) surrounding a thickened diverticulum (closed arrow) within the right colon. The features are pathognomonic of acute diverticulitis.

Figure 2 Transverse CT post-intravenous contrast medium in a patient with acute diverticulitis shows a 5 cm abscess cavity in the left iliac fossa (straight arrow). There is a pocket of air within the abscess cavity (curved arrow) indicating communication to bowel. Diverticulitis is present within the sigmoid colon as evidenced by thickening of the bowel wall and stranding.

of the mucosa is compromised inducing hypoxia and tissue death. Pockets of free air may represent a localized perforation of an inflamed diverticulum. Occasionally, air may track from a localized diverticular perforation into the mesenteric venous system and portal vein (Fig. 6). The demonstration of free air under the diaphragm represents a more significant perforation (Fig. 7).

Fistula formation occurs in 14% of cases complicating acute diverticulitis.[16] Colo-vesical fistula are the most frequent (Fig. 8), however, colo-enteric and colo-uterine fistula may also occur. CT of a colo-vesical fistula characteristically demonstrates the triad of colonic diverticula, thickening of the colonic segment adjacent to the bladder and air in the bladder. This finding may be accentuated by the

Figure 3 Transverse CT post-intravenous contrast medium in a patient with known diverticulitis demonstrates a 4 cm abscess within the right lobe of the liver. The abscess was successfully drained under imaging guidance.

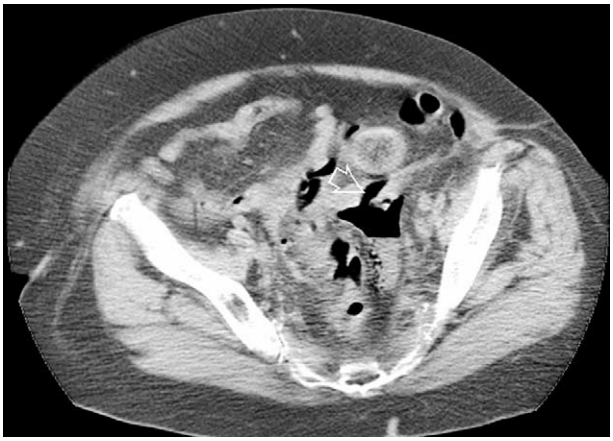

Figure 4 Transverse CT through the pelvis in a patient with diverticulitis demonstrates a localized perforation in the left side of the pelvis. A tract of air can be seen connecting the sigmoid colon to the air collection (arrow).

administration of rectal water-soluble contrast medium.

Diverticulitis is the cause of 10% of bowel obstructions. The bowel can become obstructed in two ways: inflammation and oedema of the affected segment of bowel, or, a pericolic abscess can narrow the lumen or chronic inflammation can result in fibrous bands across the bowel lumen causing obstruction. A stricture resulting from diverticulitis can be difficult to differentiate from an obstructing neoplasm. Imaging alone may not distinguish the benign from the malignant causes of luminal narrowing and colonoscopy is required where diagnostic uncertainty remains.

Diverticulitis may present with profuse colonic haemorrhage in 17% of cases, often requiring blood

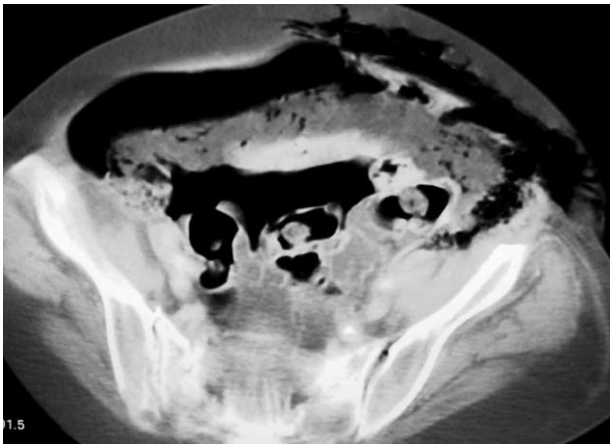

Figure 5 Transverse CT in a patient with palpable subcutaneous emphysema and a known past history of diverticulitis. There is extensive air extending from adjacent to the descending colon through the abdominal wall into the subcutaneous tissues.

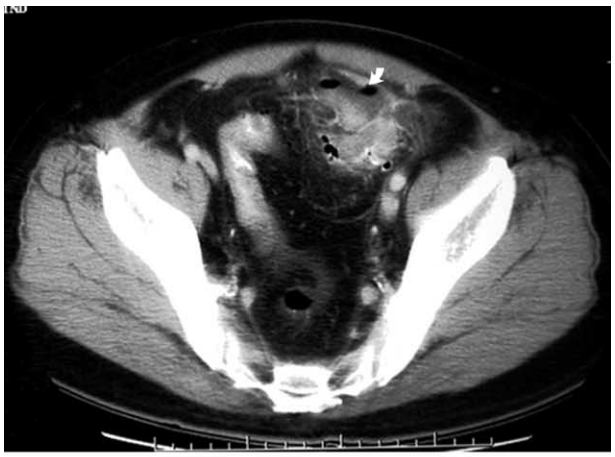

(a)

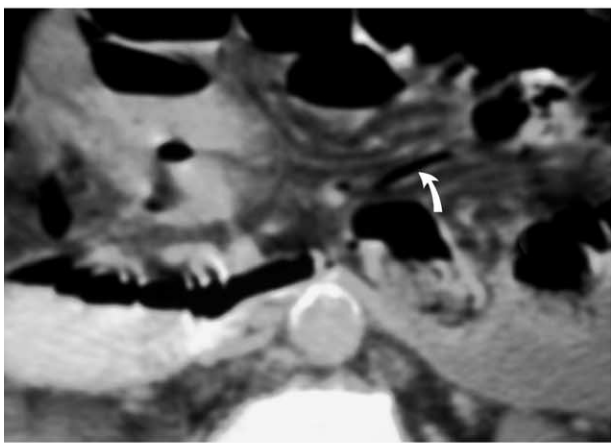

(b)

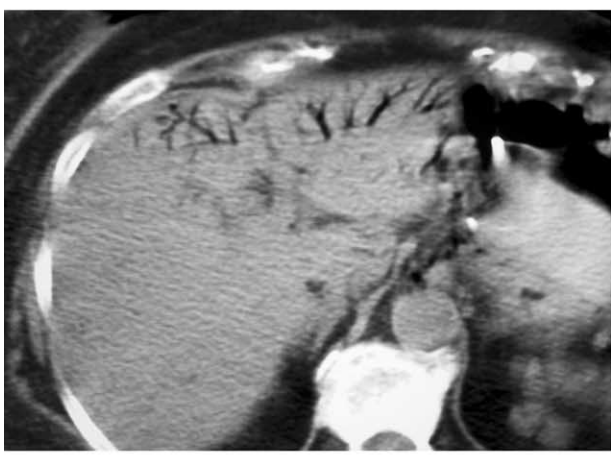

(c)

Figure 6 (a) Transverse CT through the pelvis demonstrates acute diverticulitis of the proximal sigmoid colon with bowel wall thickening, diverticula and some localized free air (arrow). (b) Magnified view at a higher level shows air within the branches of the superior mesenteric vein (arrow). (c) There is portal venous air within the liver. Despite these findings, the patient was not acutely unwell and made a full recovery after surgery.

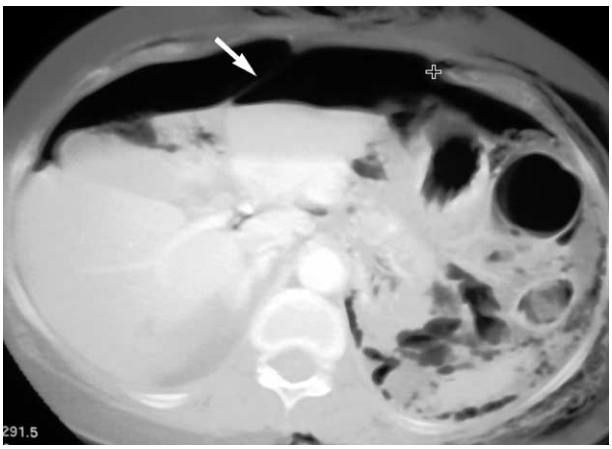

Figure 7 Transverse CT through the upper abdomen in a patient with perforated diverticulitis viewed on lung windows. There is extensive free intra-peritoneal air with visualization of the falciform ligament (arrow). There is also extensive retroperitoneal air and subcutaneous air on the left side.

transfusions. Haemorrhage may be massive and life-threatening but usually stops spontaneously.[17] CT findings will largely depend on whether there is active haemorrhage present at the time of imaging. In such cases contrast extravasation may be seen. In other cases, signs of haemorrhage may be sparse as bleeding in typically intra-luminal, where it is subsequently passed per rectum.

The CT classification of the severity of acute diverticulitis

Classical diverticulitis can be divided into mild,

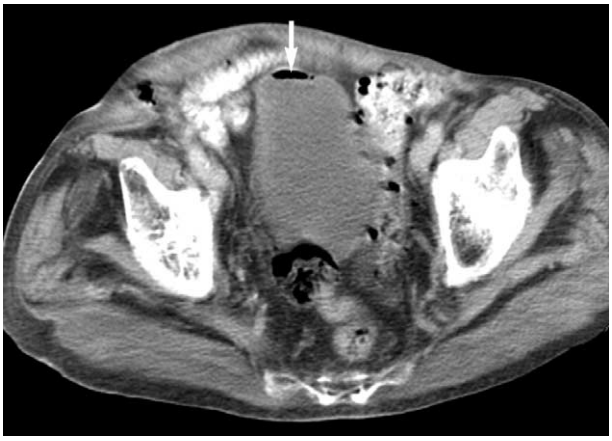

Figure 8 A patient with sigmoid diverticulitis and a colovesical fistula. There is free air within the anterior aspect of the bladder (arrow). The patient had no recent bladder instrumentation. There is also associated thickening of the sigmoid colon, which is adherent to the left side of the bladder.

moderate and severe according to the findings at CT. "Mild" diverticulitis manifests itself on CT as the evidence of diverticula in association with bowel wall thickening and pericolic fat stranding (Fig. 9). "Moderate" diverticulitis is defined loosely as significant bowel wall thickening >3 mm in association with phlegmon or small abscess formation (Fig. 10). "Severe" diverticulitis is present when the bowel wall is thickened >5 mm, perforation is seen as localized or sub-diaphragmatic free air and abscess >5 cm in size can be present with or without extension into the pelvis (Fig. 11).

Differential diagnosis

As the clinical manifestations of acute diverticular disease are often non-specific, CT enables the exclusion of other conditions in the differential diagnosis of the acute abdomen. The differential diagnosis includes renal colic, urinary tract infection, gynaecological disease, epiploic appendicitis and other inflammatory conditions of the colon.[18]

The differentiation of acute diverticulitis from malignancy is a common clinical problem. Focal or circumferential thickening of the bowel wall up to 1–3 cm may occur as a consequence of the inflammatory process.[19] Accordingly, there is a significant overlap in the CT appearances of diverticulitis and colon cancer, the differentiation of which is of fundamental importance. Chintapalli et al.[20] demonstrated a significant overlap in the diagnosis of both conditions (51%) and evaluated the CT signs associated with diverticulitis or colon cancer and prospectively applied these signs in the differentiation of the diseases. For the diagnosis of diverticulitis, the most specific finding is pericolonic stranding and a length of the involved segment of greater than 10 cm. When there are no pericolonic lymph nodes adjacent to a segment of colonic thickening, with pericolonic inflammatory changes, diverticulitis is the most likely diagnosis. If pericolonic lymph nodes are present adjacent to a segment of colonic thickening, colon cancer is the most likely diagnosis.[20]

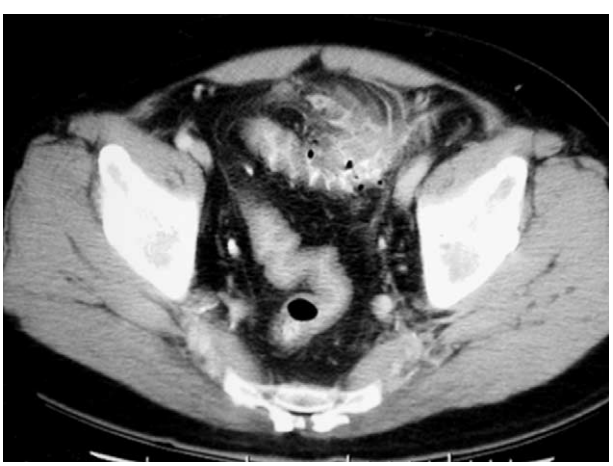

Figure 9 Mild diverticulitis of the sigmoid colon. CT demonstrates evidence of multiple diverticula in association with mild bowel wall thickening and pericolic fat stranding.

Figure 10 Moderate diverticulitis of the distal descending colon. CT shows moderate bowel wall thickening in association with marked stranding and phlegmon formation.

Alternative imaging strategies in diverticular disease

Plain radiographs are insensitive and play no useful role in diagnosing diverticulitis and its complications. In a review by Ahn et al.,[21] abdominal radiography had 0% sensitivity for acute diverticulitis. Previously, either barium or water-soluble contrast enemas were the imaging technique of choice for the diagnosis of diverticulitis. However, such studies lack sensitivity. A diagnosis of acute diverticulitis requires the demonstration of extraluminal air or contrast medium within collections in the pericolic space.[22] The advantages of contrast enemas include the demonstration of fistula formation to adjacent viscera and in differentiating acute diverticulitis from a perforated colonic cancer.[23] However, contrast enemas cannot directly demonstrate the presence of a peri-colic inflammatory process and a diagnosis of diverticulitis may be overlooked.[24] If a contrast enema is to be performed in a patient with suspected acute diverticulitis, the use of a water-soluble contrast medium is advocated. Performing a barium enema may preclude immediate CT due to beam-hardening artefacts from barium within the colon. For these

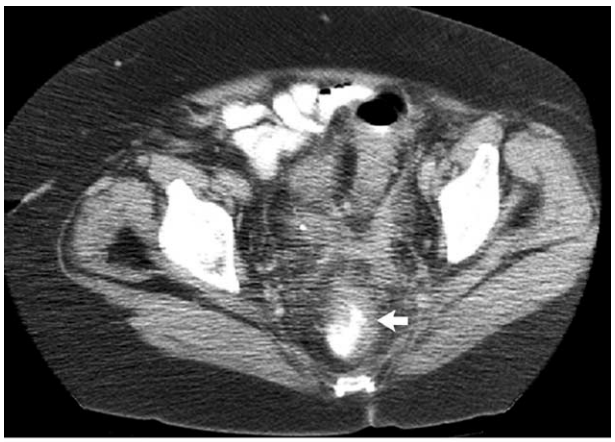

(a)

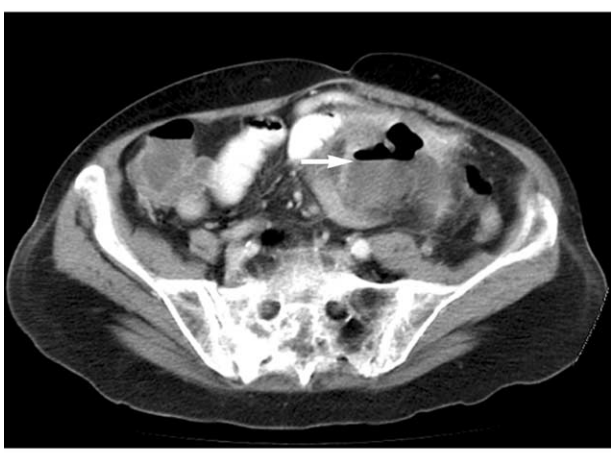

(b)

Figure 11 Severe diverticulitis of the recto-sigmoid colon with localized perforation and abscess formation. (a) Transverse CT through the lower pelvis demonstrates marked thickening of the proximal contrast-filled rectum (arrow). There is extensive stranding of the mesocolon. (b) At a higher level, there is a localized perforation with abscess formation (arrow).

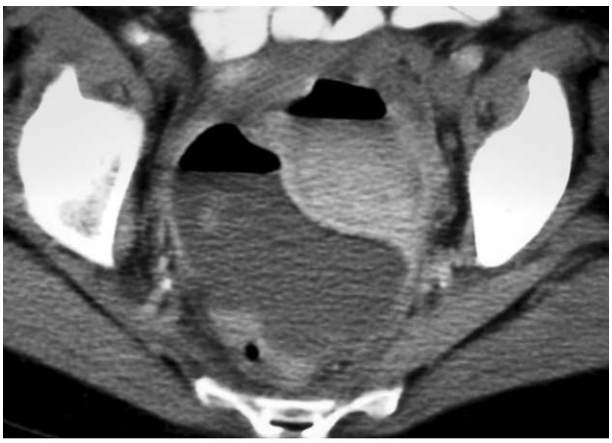

(a)

(b)

Figure 12 (a) Transverse CT in a patient with sigmoid diverticulitis demonstrates a large pelvic abscess with an air fluid level situated in the pouch of Douglas. (b) An 8 F pigtail drainage catheter has now been successfully placed trans-gluteally into the collection. The collection resolved fully on subsequent imaging.

reasons, barium enemas should not be routinely performed in the initial evaluation of diverticulitis.

In experienced hands, ultrasound is a useful technique in the evaluation of acute diverticulitis and its complications. Pradel et al.[25] have suggested a comparable sensitivity to CT. Hollerweger et al.[26] reported a sensitivity of 77% and a specificity of 99% for ultrasound in the detection of diverticulitis. However, ultrasound in the evaluation of diverticulitis is highly operator dependant.

Magnetic resonance imaging (MRI) has not been widely used owing to the excellent sensitivity and specificity of CT in the detection of acute diverticulitis. Heverhagen et al.[27] demonstrated excellent results in the evaluation of 20 patients using short tau inversion recovery (STIR) and free induction with steady state precession (FISP) sequences to diagnose acute diverticulitis.[27] Extra-luminal collections of air may be overlooked because of the poor sensitivity of MRI in the demonstration of air.

Limitations of CT diagnosis of acute diverticulitis

Balthazar et al.[28] described the limitations of CT in the diagnosis of acute diverticulitis. In a review of 16 patients, the limitations of CT were related to marked thickening of the colon wall simulating colon carcinoma in all patients, an inability to demonstrate small volumes of fibro-purulent inflammatory exudates in the absence of peri-

colic inflammatory changes (eight patients) and failure to visualize discrete intra-mural abscesses (five patients).

The implications of CT in the strategy of patient management

Patients with the history, examination and laboratory findings suggestive of acute diverticulitis should undergo CT. The key to the effective management of acute diverticulitis is the rapid and accurate assessment of the extent of inflammation on CT, as this is the only parameter proven to have a definitive predictive value in the outcome of the disease.[29] CT facilitates the percutaneous drainage of diverticular abscesses, promoting antibiotic therapy and achieving the successful spontaneous resolution of the acute inflammatory episode in 75% of cases (Fig. 12). An emergency operation is converted into an elective procedure and the requirement for a second operation is avoided.[30] The demonstration of perforation or obstruction necessitates urgent surgical intervention.

Conclusions

CT is a highly specific and sensitive imaging method in the evaluation of acute diverticulitis. It is the most accurate imaging technique available for the assessment of the inflammatory process. CT-guided percutaneous drainage of diverticular abscesses plays a crucial role in improving patient outcome.

References

1. Ferzoco LB, Raptopoulos V, Silen W. Acute diverticulitis. *N Eng J Med* 1998;**338**:1521—6.
2. Waters DA, Smith AN, Eastwood MA, Anderson KC, Elton RA, Mugerwa JW. Mechanical properties of the colon: comparison of the features of the African and European colon in vitro. *Gut* 1985;**26**:384—92.
3. Simpson J, Scholefield JH, Spiller RC. Pathogenesis of colonic diverticula. *Br J Surg* 2002;**89**:546—54.
4. Parks TS. Natural history of diverticular disease of the colon. *Clin Gastroenterol* 1975;**4**:53—69.
5. McConnell EJ, Tessier DJ, Wolff BG. Population based incidence of complicated diverticular disease of the sigmoid colon based on gender and age. *Dis Colon Rectum* 2003;**46**:1110—4.
6. Painter NS, Burkitt DP. Diverticular disease of the colon: a deficiency disease of Western civilization. *BMJ* 1971;**ii**:450—4.
7. Hinton JM, Lennard-Jones JE, Young AC. A new method for studying gut transit times using radiopaque markers. *Gut* 1969;**10**:842—7.
8. Painter NS. The cause of diverticular disease of the colon, its symptoms and its complications. Review and hypothesis. *J R Coll Surg Edinb* 1985;**30**:118—22.
9. Cohn JrI, Nance FC. Mechanical, inflammatory, vascular and miscellaneous benign conditions. In: Sebaston DC, editor. *Textbook of surgery: the biological basis of modern surgical practice*. Philadelphia: WB Saunders; 1986. p. 997—9.
10. Papagrigoriadis S, Macey L, Bourantas N, Rennie JA. Smoking may be associated with complications in diverticular disease. *Br J Surg* 1999;**86**:923—6.
11. Morris CR, Harvey IM, Stebbings WS, Speakman CT, Kennedy HJ, Hart AR. Anti-inflammatory drugs, analgesics and the risk of perforated colonic diverticular disease. *Br J Surg* 2003; **90**:1267—72.
12. Morris CR, Harvey IM, Stebbings WS, Speakman CT, Kennedy HJ, Hart AR. Do calcium channel blockers and antimuscarinics protect against perforated colonic diverticular disease? A case control study. *Gut* 2003;**52**:1734—7.
13. Urban BA, Fishman EK. Tailored helical CT evaluation of acute abdomen. *RadioGraphics* 2000;**20**:725—49.
14. Retert H, Noldge G, Encke J, Richter GM, Dux M. The value of CT for the diagnosis of acute diverticulitis. *Radiologe* 2003; **43**:51—8.
15. Hulnick DH, Megibow AJ, Balthazar EJ, Naidich DP, Bosniak MA. Computed tomography in the evaluation of diverticulitis. *Radiology* 1984;**152**:491—5.
16. Suros J, Lee RA. Pneumoretroperitoneum, pneumomediastinum and subcutaneous emphysema. Complications of acute perforated diverticulitis. *Minn Med* 1973;**56**:747—9.
17. DeMarkles MP, Murphy JR. Acute lower gastrointestinal bleeding. *Med Clin North Am* 1993;**77**:1095—6.
18. Hollerweger A, Macheiner P, Gritzmann N. Acute left lower quadrant abdominal pain: ultrasonographic differential diagnosis. *Ultraschall Med* 2003;**24**:7—16.
19. Birnbaum BA, Balthazar EJ. CT of appendicitis and diverticulitis. *Radiol Clin North Am* 1994;**32**:885—98.
20. Chintapalli KN, Chopra S, Ghiatas AA, Escola CC, Fields SF, Dodd 3rd GD. Diverticulitis versus colon cancer: differentiation with helical CT findings. *Radiology* 1999;**210**:429—35.
21. Ahn SH, Mayo-Smith WW, Murphy BL, Reinert SE, Cronan JJ. Acute non-traumatic abdominal pain in adult patients: abdominal radiography compared with CT evaluation. *Radiology* 2002;**225**:159—64.
22. Rubesin SE, Laufer I. Diverticular disease. In: Levine MS, Rubesin SE, Laufer I, editors. *Double contrast gastrointestinal radiology*, 3rd ed. Philadelphia: WB Saunders; 2000. p. 471—93.
23. Rubesin SE, Levine MS. Radiologic diagnosis of gastrointestinal perforation. *Radiol Clin North Am* 2003;**41**:1095—115.
24. Halligan S, Saunders B. Imaging diverticular disease. *Best Pract Res Clin Gastroenterol* 2002;**16**:595—610.
25. Pradel JA, Adell JF, Taourel P, Djafari M, Monnin-Delhom E, Bruel JM. Acute colonic diverticulitis: prospective comparative evaluation with CT. *Radiology* 1997;**205**:503—12.
26. Hollerweger A, Macheiner P, Rettenbacher T, Brunner W, Gritzmann N. Colonic diverticulitis: diagnostic value and appearance of inflamed diverticula: sonographic evaluation. *Eur Radiol* 2001;**11**:1956—63.
27. Heverhagen JT, et al. Feasibility of MRI in the diagnosis of acute diverticulitis: initial results. *MAGMA* 2001;**12**:4—9.
28. Balthazar EJ, Megibow A, Schinella RA, Gordon R. Limitations in the CT diagnosis of acute diverticulitis: comparison of CT, contrast enema and pathological findings in 16 patients. *AJR Am J Roentegenol* 1990;**154**:281—5.
29. Ambrosetti P, Becker C, Terrier F. Colonic diverticulitis: impact on surgical management; a prospective study of 542 patients. *Eur Radiol* 2002;**12**:1145—9.
30. Boulos PB. Complicated diverticulosis. *Best Prac Res Clin Gastroenterol* 2002;**16**:649—62.