Clinical Radiology (2001) **56**: 819–827
doi:10.1053/crad.2001.0848, available online at http://www.idealibrary.com on IDEAL®

Pictorial Review

Radiological Features of Epiploic Appendagitis and Segmental Omental Infarction

MARK J. MCCLURE*, KOROSH KHALILI†, JOSÉE SARRAZIN*, ANTHONY HANBIDGE†

**Department of Radiology, Sunnybrook and Women's Health Science Centre, Toronto, Ontario Canada and †Department of Radiology, Mount Sinai Hospital and University Health Network Toronto General Hospital, Toronto, Ontario Canada*

Received: 18 July 2000 Accepted: 26 March 2001

Epiploic appendagitis and segmental omental infarction are more frequently encountered with the increased use of abdominal ultrasound and Computed tomography (CT) in the radiological assessment of the patient who presents clinically with acute abdominal pain. Recognition of specific imaging abnormalities enables the radiologist to make the correct diagnosis. This is important, as the appropriate management of both conditions is often conservative. Follow-up imaging features correlate with clinical improvement. McClure, M. J. *et al*. (2001). *Clinical Radiology* **56**, 819–827.
© 2001 The Royal College of Radiologists

Key words: abdomen, pain, CT, inflammation, epiploic appendage, omentum, infarction.

INTRODUCTION

Epiploic appendages are visceral peritoneal outpouchings containing fat and blood vessels. They are numerous and located on the serosal surface of the colon from the caecum to the rectosigmoid junction (Fig. 1). They are usually 1–2 cm thick and 2–5 cm long, and are most prominent in size and number in the descending and sigmoid colon [1]. In patients with ascites, ultrasound (US) and CT may identify normal epiploic appendages due to their homogeneous fat content. With US, it is important to distinguish epiploic appendages from other appendages such as appendix and diverticula. In our experience, the appendix is more rigid, in a more typical location, and may have gut signature, blood supply within a mesoappendix, and gas in the lumen. Diverticula tend to have luminal gas and are not homogeneous in echotexture.

Primary epiploic appendagitis (EA) is inflammation and infarction of the epiploic appendage without an underlying cause such as acute appendicitis, diverticulitis or cholecystitis. Segmental omental infarction (SOI) is caused by thrombosis of omental vessels with resultant infarction. The clinical presentation is similar to EA and both should be considered in the differential diagnosis of the patient presenting with acute abdominal pain.

Author for correspondence and guarantor of study: Dr Mark J. McClure, Department of Radiology, Craigavon Area Hospital, 68 Lurgan Road, Portadown, Craigavon BT63 5QQ, Northern Ireland UK. Fax: +44(0) 28 3835 1466; E-mail: drmmcclure@cahgt.n-i.nhs.uk

DISCUSSION

Epiploic Appendagitis

Epiploic appendagitis (EA) is usually caused by torsion of the epiploic appendage with resultant ischemia, but may also result from spontaneous venous thrombosis, without associated torsion. Theories proposed relate to the frequent association of EA with moderate or unaccustomed exercise before the onset of pain, possibly related to redistribution of blood flow, and mechanical causes such as excessive abdominal stretching manoevres [2].

Patients typically present with acute localized lower abdominal pain, usually on the left side. Nausea, vomiting, altered bowel habit and pyrexia are unusual. On clinical examination, there is localized abdominal tenderness and signs of peritonitis. The leukocyte count is often normal.

Ultrasound features include a solid, hyperechoic, non-compressible, ovoid mass, devoid of blood flow, deep to the region of maximal tenderness (Figs 2*a*, 3). Associated

0009-9260/01/100819+09 $35.00/0
© 2001 The Royal College of Radiologists

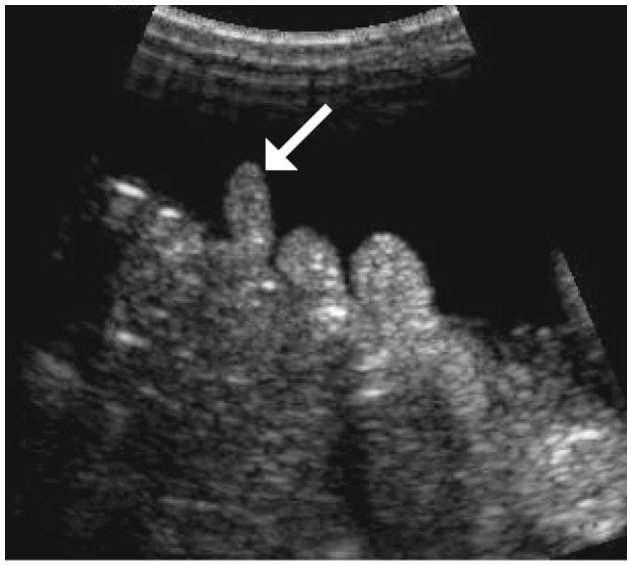

(*a*)

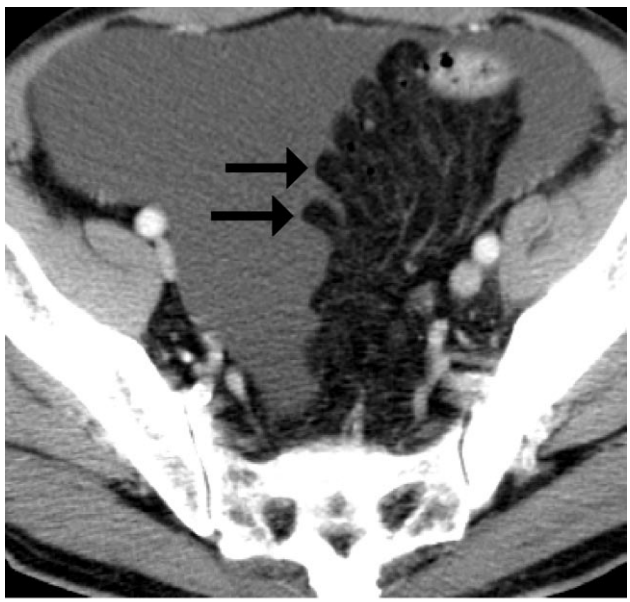

(*b*)

Fig. 1 – Normal epiploic appendages. US (*a*) demonstrates normal echogenic appendages (arrow) (courtesy of Dr. S. R. Wilson, Toronto). Contrast enhanced CT (*b*) illustrates normal fat-attenuating appendages, seen well because of the presence of ascitic fluid (arrows). Note the opacified supplying blood vessels.

findings include mass effect on adjacent bowel wall, bowel wall thickening and thickened, adherent parietal peritoneum [2] (Fig. 3*a*, *b*) The lesion is often circumscribed by a hypoechoic rim, and may contain hypoechoic foci, likely representing haemorrhagic changes (Figs 2*a*, 3a) [3].

CT shows (Fig. 2*b*, 3*c*) a peritoneal fat attenuating mass located adjacent to the serosal surface of the colon. Typically, there is a hyperattenuating peripheral ring (Fig. 4) surrounding a slightly increased attenuating fatty

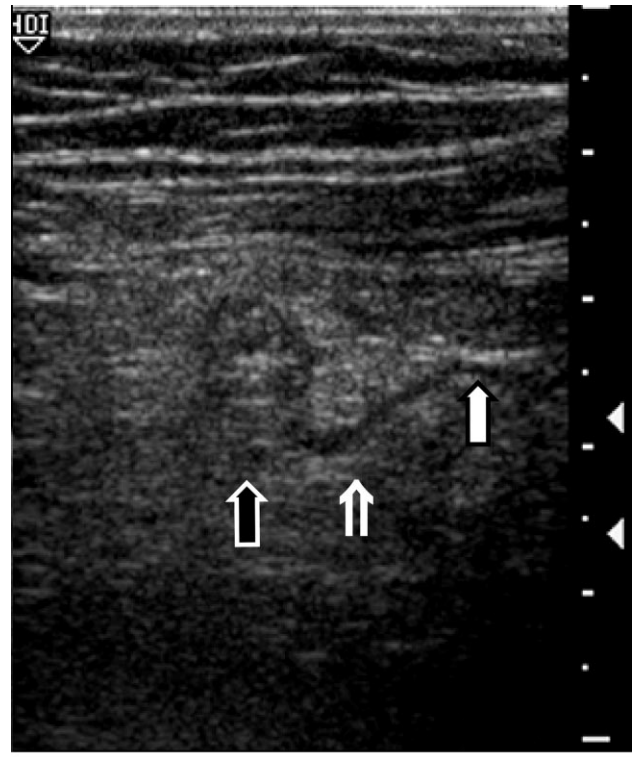

(*a*)

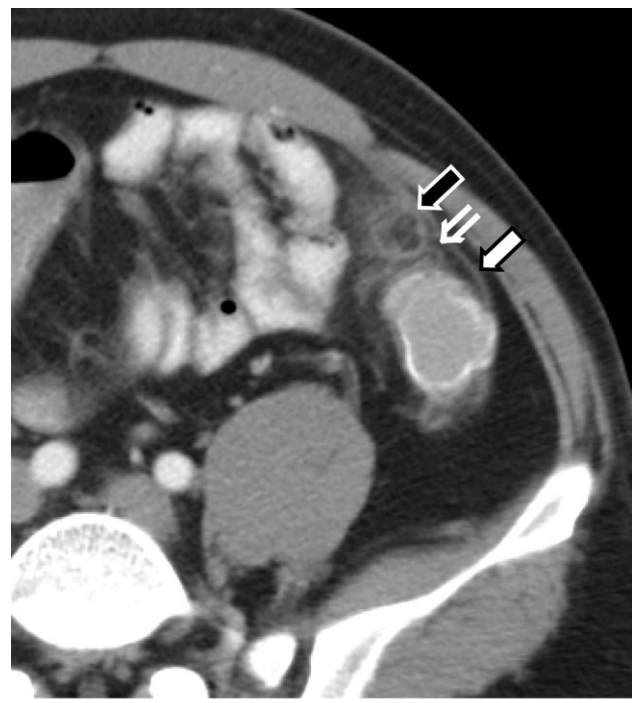

(*b*)

Fig. 2 – 28-year-old man with acute left-sided abdominal pain. US (*a*) and CT (*b*) demonstrate the EA with thickened parietal peritoneum (solid white-filled arrow), inflamed adjacent fat (hollow arrow) which is echogenic on US and of increased attenuation on CT, and the thickened visceral peritoneum (open black-filled arrow). On US, note the mixed echoic centre, likely due to haemorrhagic changes, and a hypoechoic rim.

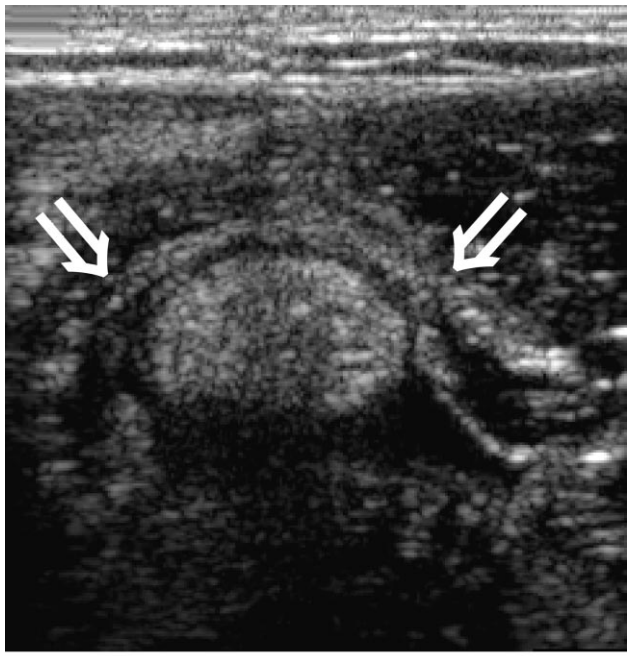

(*a*)

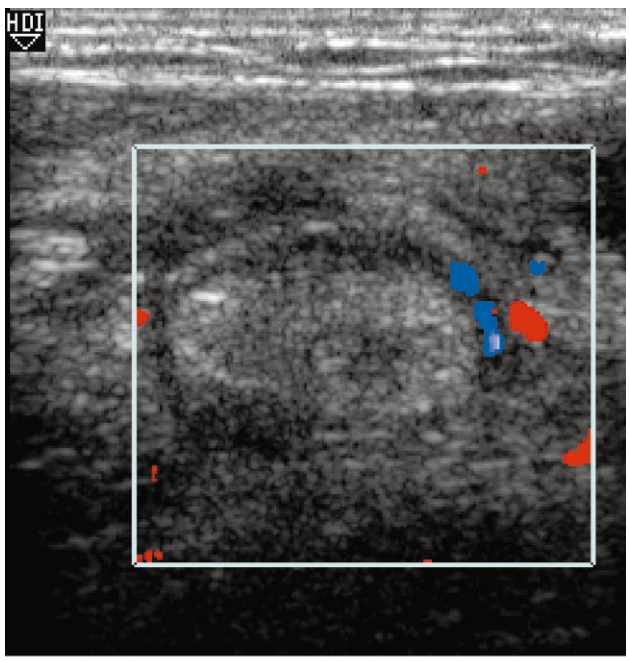

(*b*)

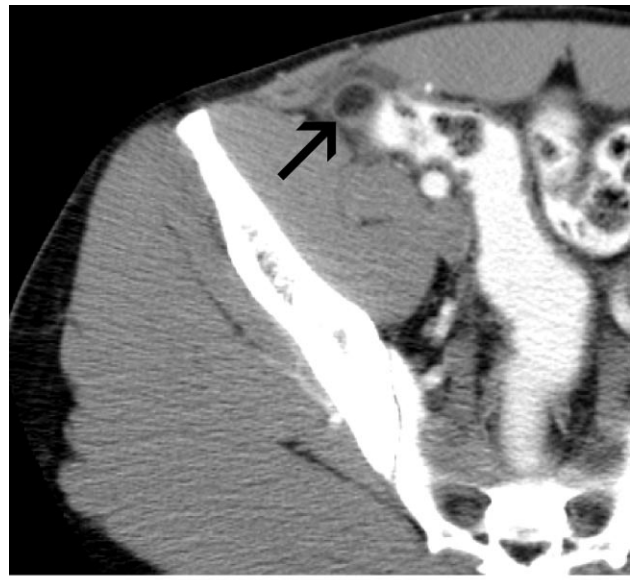

(*c*)

Fig. 3 – 27-year-old man with suspected appendicitis. (*a*) US demonstrates a well-defined echogenic mass (arrow) with a hypoechoic rim, and adjacent inflammatory fat changes, consistent with EA. (*b*) Colour Doppler shows the mass is avascular. During the CT examination, the mass was clearly adherent to the anterior abdominal wall while adjacent loops of bowel moved with respiration. (*c*) CT shows the mass adherent to the sigmoid colon (arrow), which loops to

centre (approximately −60 Hounsfield units), compared to the normal peritoneal fat (approximately −120 Hounsfield units) [2,4]. This 'ring sign' is due to thickening of a rim of visceral peritoneum. Periappendageal fat stranding, parietal peritoneal thickening (Fig. 5), bowel wall thickening and mass effect (Fig. 6) may be present. Within the centre of the mass, there is often an ill-defined hyperdense area or a well-defined hyperattenuating dot (Figs. 7, 8). This latter feature is thought to represent the thrombosed blood vessel and/or haemorrhagic changes [2]. The lesions may be very small and subtle (Figs. 9). EA is usually managed conservatively. Follow-up US and/or CT will show the lesion to reduce in size and become well defined (Fig. 10) [5].

SEGMENTAL OMENTAL INFARCTION

Segmental omental infarction is a relatively uncommon disorder, which appears to be increasing in frequency, probably as a result of the increased use of CT for suspected

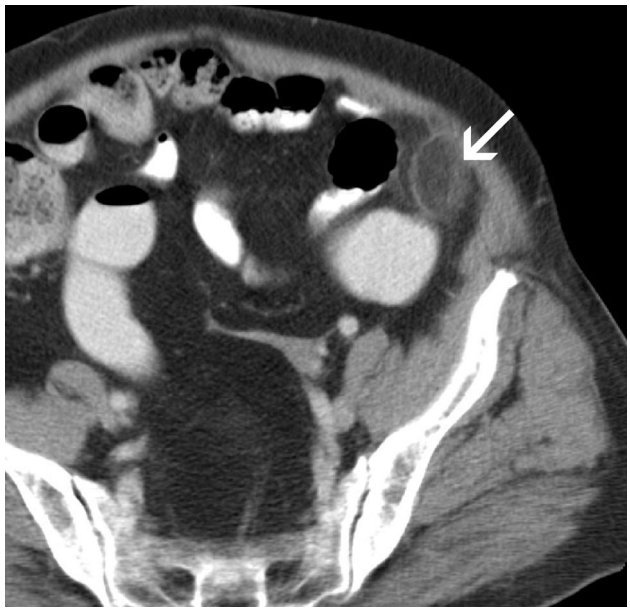

Fig. 4 – 77-year-old woman with suspected acute diverticulitis. CT shows a fatty mass anterior–lateral to the descending colon. This has the classic peripheral hyperattenuating 'ring sign' (arrow) of EA with an inflamed fatty centre.

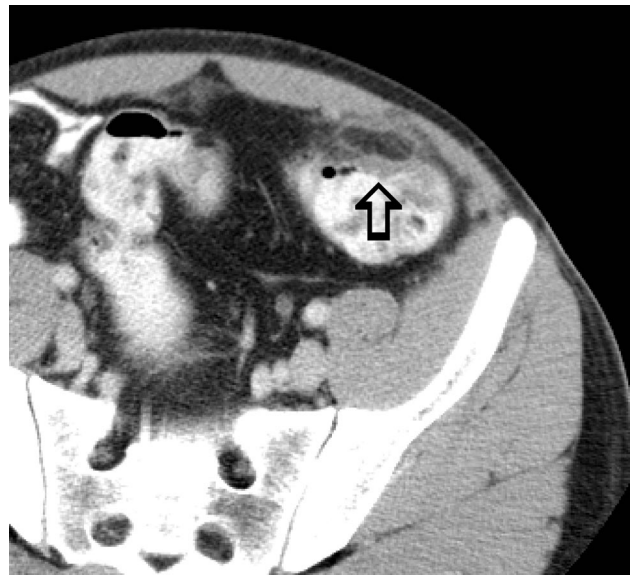

Fig. 6 – 27-year-old man with focal left lower quadrant pain, clinically acute diverticulitis. The ring-shaped EA is seen anterior to the descending colon, with wall thickening (arrow) and associated mass effect.

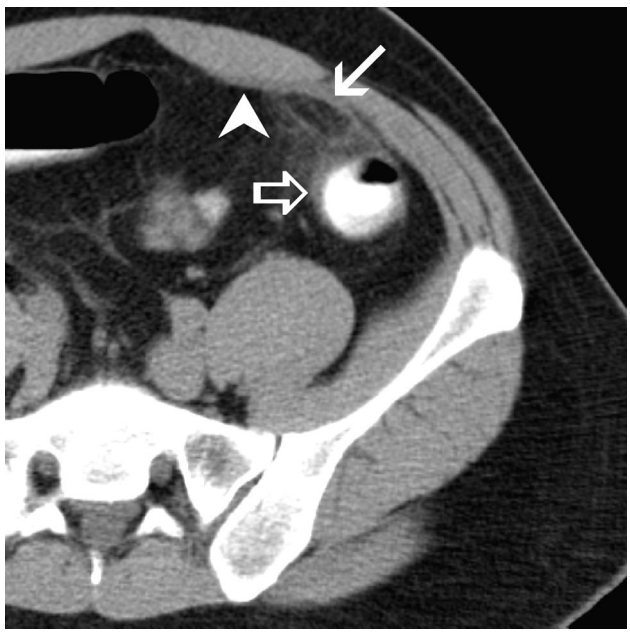

Fig. 5 – 48-year-old woman with suspected acute diverticulitis. The EA is seen anterior to the descending colon (thin arrow). Note the prominent periappendageal fat stranding. The adjacent parietal peritoneum (arrowhead) and bowel wall (white transparent arrow) are minimally thickened.

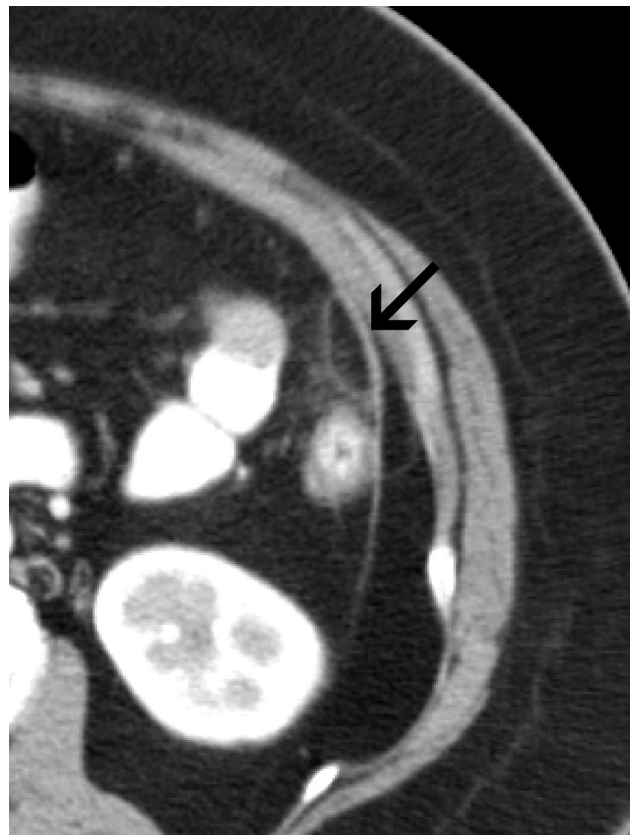

Fig. 7 – 33-year-old man with acute EA. Note the subtle thickening of the parietal peritoneum (arrow). The small focal central hyperattenuating focus may represent the thrombosed blood vessel.

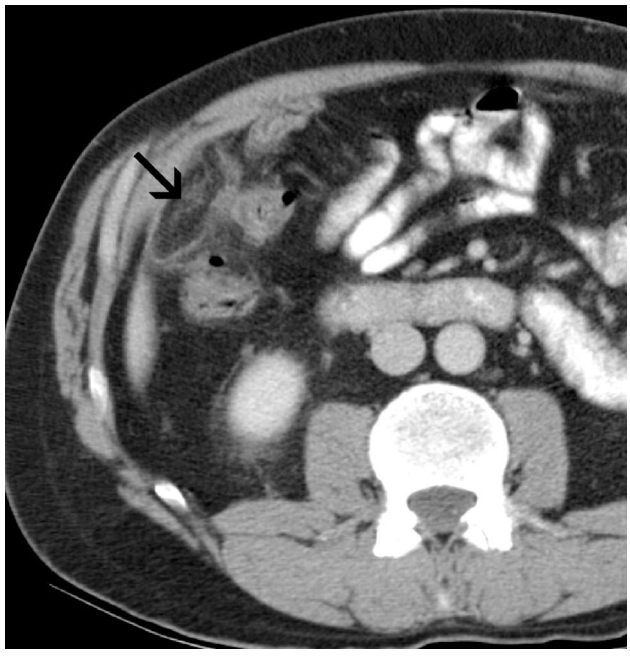

Fig. 8 – 49-year-old man with acute right-sided flank pain, suspected acute appendicitis. This EA lesion is somewhat unusual, being on the right side and larger than expected (5.4 × 2.4 cm). A focal central hyperdensity is seen (arrow), likely the thrombosed blood vessel, or haemorrhagic changes.

acute appendicitis, diverticulitis and renal colic. The aetiology remains uncertain. However, anomalous arterial supply to the omentum, kinking of veins secondary to increased intra-abdominal pressure and post-prandial vascular congestion have been proposed [6,7].

Patients typically present with acute abdominal pain and signs of peritonitis. When the pain is on the right, acute appendicitis, cholecystitis or right renal colic may be considered in the differential diagnosis, depending on findings of clinical examination. There may be a fever or leukocytosis.

Ultrasound shows a large solid, hyperechoic, and non-compressible mass, deep to the area of maximal tenderness (Figs 11*a*, 13*a*). CT demonstrates a heterogeneous fatty mass anterior to the colon, adherent to inflamed parietal peritoneum [6–8] and contains strands of soft tissue attenuation (Fig 12). It is usually on the right side, but may be on the left (Fig. 13) [7]. SOI is also a self-limiting condition that resolves spontaneously with conservative management. Follow-up imaging shows the mass to reduce in size and become better defined (Fig. 11*b*, *c*).

COMMENTS

A recent article [3] reviewed 40 cases over almost a 10-year period (20 EA, 11 SOI and 9 indeterminate). During a one-year period at our institution, we encountered 12 cases of EA and four of SOI. No patient went to surgery. This apparent increased prevalence perhaps reflects a combination of increased referral for imaging of patients with acute abdominal pain, increased awareness and recognition of these conditions and improved imaging equipment and techniques.

The term 'intra-abdominal focal fat infarction' [3] has been proposed to describe both conditions, as treatment and prognosis is identical. However, in our experience, it is possible to confidently differentiate between these two entities in most cases, on the basis of the typical location, size discrepancy and appearance ('ring sign' versus heterogeneous mass). Furthermore, EA tends to be smaller in size, with a more rapid radiological resolution, and therefore this distinction may enable the radiologist to predict the degree of patient morbidity.

CONCLUSION

Radiological features that are helpful to differentiate SOI from EA include larger size, heterogeneous mass, greater mass effect on adjacent bowel wall, typical right-sided location, absence of the 'ring sign' and more obvious parietal peritoneal thickening and adherence. In contrast, EA is usually on the left side, smaller in size and demonstrates the typical 'ring sign'. Both conditions illustrate the importance of US and CT in the diagnosis of these conditions, particularly when the correct diagnosis may remove the need for surgery. Follow-up imaging features correlate with clinical improvement and are useful to confirm resolution.

Acknowledgements. Dr Stephanie R. Wilson, Professor of Radiology and Obstetrics and Gynecology, University of Toronto, Head, Division of Ultrasound, University Health Network–Toronto General Hospital, kindly helped in supplying the ultrasound illustrations.

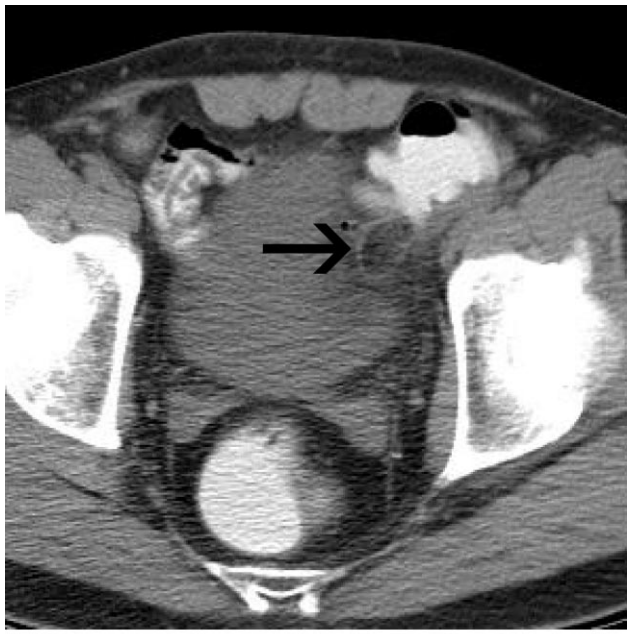

(*a*)

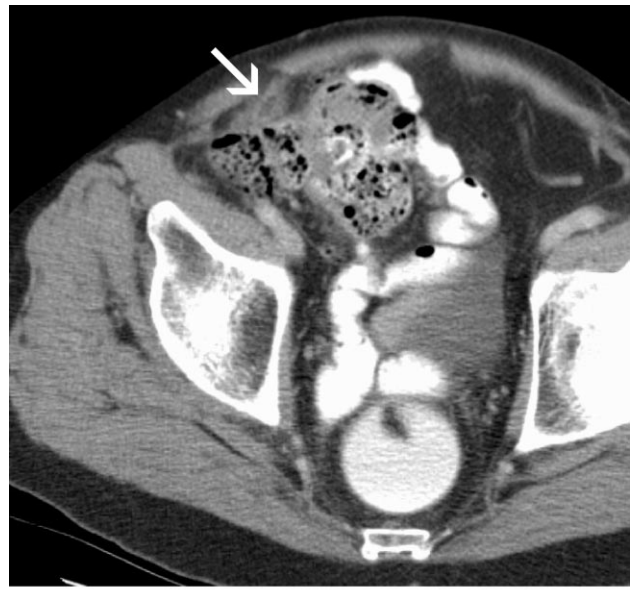

(*c*)

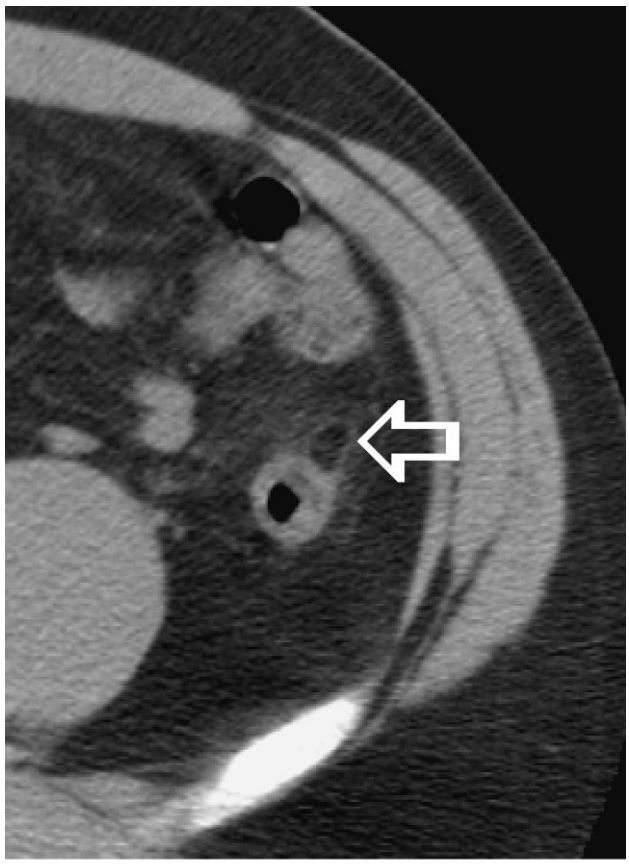

(*b*)

Fig. 9 – Subtle cases of EA. (*a*) 48-year-old man with suspected diverticulitis. A subtle lesion (arrow) is identified (only on two contiguous 5 mm slices) on the under surface of the sigmoid colon as it loops over the dome of the bladder. (*b*) 42-year-old man with acute left flank pain, clinically renal colic. Unenhanced CT shows how subtle (1.3 × 0.9 cm) these lesions can be (arrow). Note the adjacent thickening of the colonic wall. (*c*) 76-year-old man with clinically suspected appendicitis. This lesion is small (2.1 × 1.2 cm) and located in an atypical location near the caecal pole (arrow). There is mild thickening of the caecal wall and excess faecal residue. A normal appendix was identified more caudad.

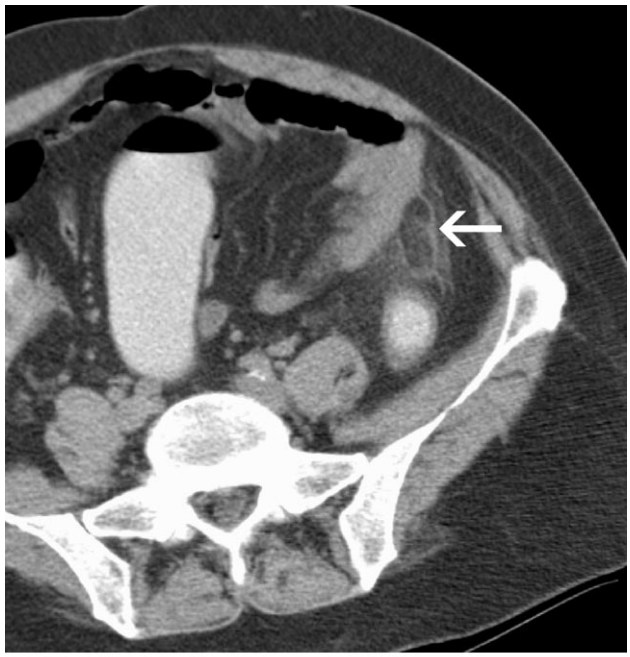

(*a*)

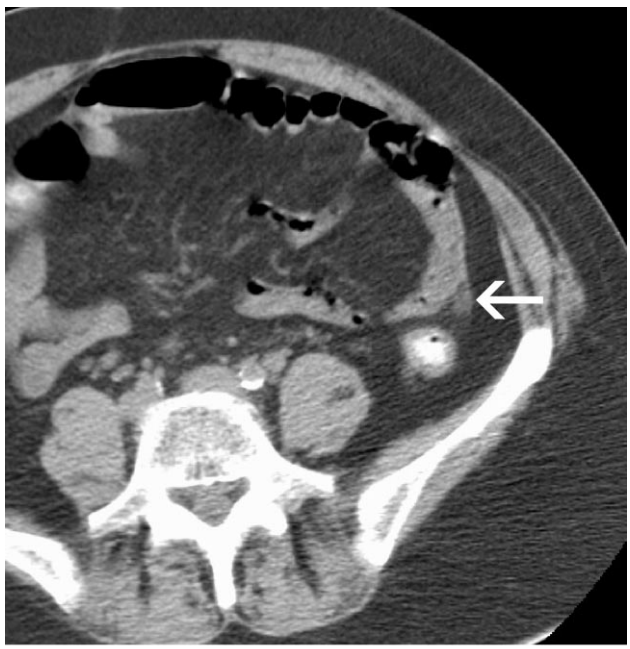

(*b*)

Fig. 10 – 67-year-old woman with left-sided abdominal pain, suspected acute diverticulitis. (*a*) Initial CT demonstrates the classic peripheral 'ring sign' of EA (arrow), with a central hyperattenuating focus and periappendageal fat inflammatory changes. Note mild colonic wall thickening. (*b*) Follow-up CT at 4 months, confirms the lesion is reduced in size and well-defined (arrow).

(*a*)

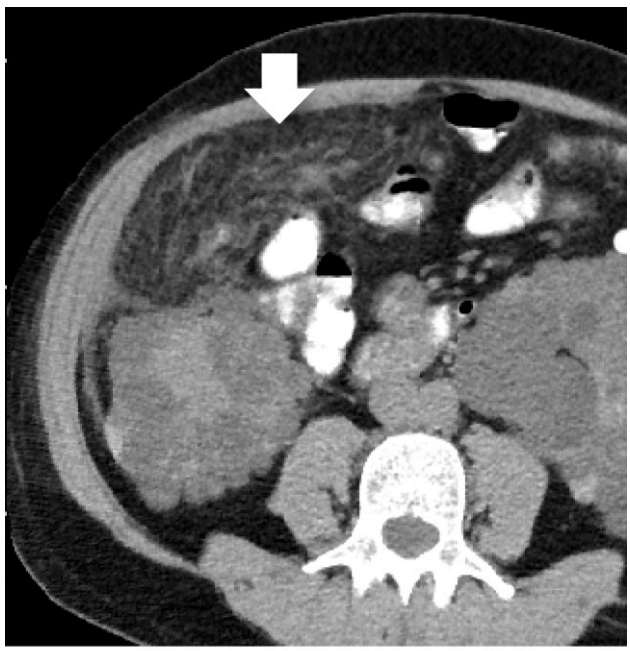

(*b*)

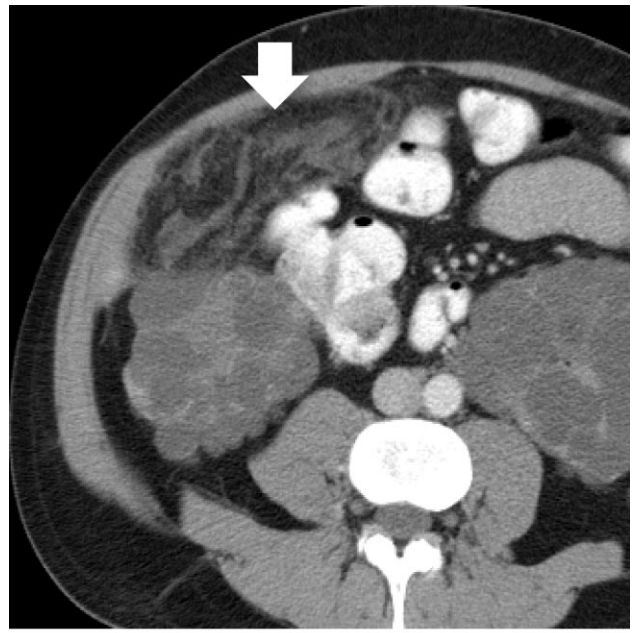

(*c*)

Fig. 11 – 56-year-old man with acute right-sided pain, suspected haemorrhagic renal cyst. His past history included adult polycystic kidney disease and renal transplantation. (*a*) US demonstrates SOI as echogenic inflamed fat adherent to the anterior abdominal wall (arrow), liver (L) and polycystic right kidney (K). (*b*) CT of the same date shows the large heterogeneous mass of SOI and thickened parietal peritoneum (arrow). (*c*) Follow-up CT at 1 month, shows the streaky inflammatory changes within the omentum have become better defined (arrow). The right lateral conal fascia is also less thickened.

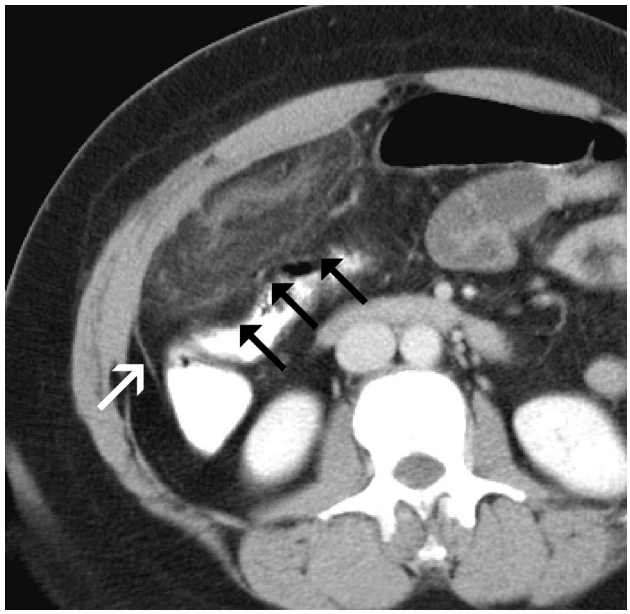

Fig. 12 – 32-year-old woman with right-sided pain, suspected acute appendicitis or cholecystitis. (*a*) CT shows a large (10.3 × 4.9 cm) fatty mass with streaky inflammatory changes located between the colon and abdominal wall, consistent with SOI. (*b*) Note the mass effect on the ascending colon (black arrows) and the peritoneal thickening (white arrow).

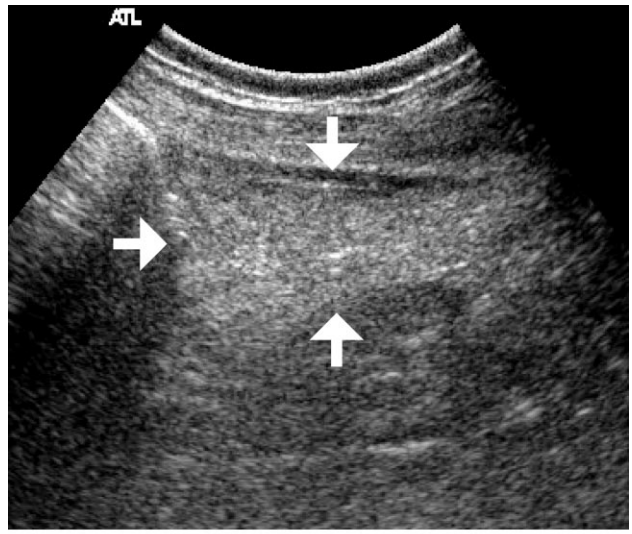

(*a*)

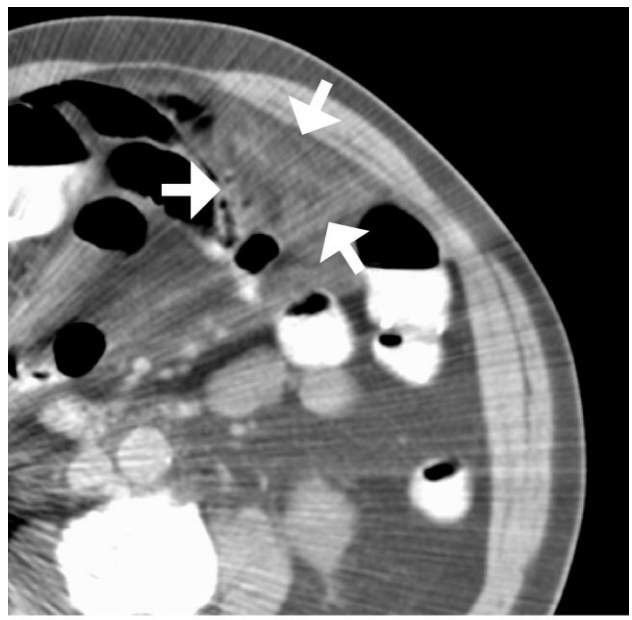

(*b*)

Fig. 13 – 52-year-old man presenting as acute left-sided abdominal pain. (*a*) US left upper quadrant shows a large echogenic mass (arrows) of SOI, deep to the area of maximal tenderness. (*b*) CT demonstrates the fat-attenuating mass (arrows), with peritoneal thickening and mass effect on adjacent bowel. The beam hardening artefact is due to recent barium enema for suspected diverticulitis (negative).

REFERENCES

1 Myers MA. *Dynamic Radiology of the Abdomen*, 4th ed. New York, USA: Springer-Verlag, 1994, 485–486.
2 Rioux M, Langis P. Primary epiploic appendagitis: clinical, US, and CT findings in 14 cases. *Radiology* 1994;191:523–526.
3 van Breda Vriesman AC, Lohle PNM, Coerkamp EG, Puylaert JBCM. Infarction of omentum and epiploic appendage: diagnosis, epidemiology and natural history. *Eur Radiol* 1999;9:1886–1992.
4 Danielson K, Chernin MM, Amberg JR, Goff S, Durham JR. Epiploic appendagitis: CT characteristics. *J Comput Assist Tomogr* 1986;10:142–143.
5 Rao PM, Wittenberg J, Lawrason JN. Primary epiploic appendagitis: evolutionary changes in CT appearances. *Radiology* 1997;204: 713–717.
6 Puylaert JBCM. Right-sided segmental infarction of the omentum: clinical, US, and CT findings. *Radiology* 1992;185:169–172.
7 Balthazar EJ, Leftkowitz RA. Left-sided omental infarction with associated omental abscess: CT diagnosis. *J Comput Assist Tomogr* 1993;17:379–381.
8 Karak PK, Millmond SH, Neumann D, Yamase HT, Ramsby G. Omental infarction: report of three cases and review of the literature. *Abdom Imaging* 1998;23:96–98.