Update on Imaging for Acute Appendicitis

Nancy A. Parks, MD, Thomas J. Schroeppel, MD*

KEYWORDS

• Imaging • Acute • Appendicitis • CT • US • MRI

Acute appendicitis (AA) remains one of the most common surgical emergencies in the United States with over 250,000 cases diagnosed each year. Lifetime risk of developing AA is 8.6% in men and 6.7% in women, with an overall appendectomy rate of 12% in men and 23% in women.[1] The pathophysiology of AA is likely related to luminal obstruction of the vermiform appendix. This condition leads to rising intraluminal pressure, ischemia, and eventual perforation. Perforation increases the mortality rate of AA from 0.0002% to 3% and increases the morbidity from 3% to 47%.[2] This increase in complications associated with advanced appendicitis and perforation has led to the traditional surgical teaching that a negative appendectomy rate of 20% is acceptable to balance the need for early diagnosis and avoid perforation. Current negative appendectomy rates are lower because of the increasing use of imaging. A recent population-based review found the rate of negative appendectomy to be 4.5% in those with imaging and 9.8% in those with no imaging.[3]

Advances in imaging techniques over the past 20 years have changed the way suspected AA is evaluated. Traditionally, the diagnosis was made based solely on the history taking and physical examination. However, AA is known as the "great masquerader" and has highly variable presentations and findings on examination. The presentation of AA may be atypical, complicating the diagnosis and leading to delays in treatment, prolonged hospitalization, and unnecessary surgery. Diagnostic accuracy based on clinical findings alone is 80%. Based solely on history taking and physical examination, men are diagnosed correctly 78% to 92% of the time, whereas women are diagnosed correctly only 58% to 85% of the time.[4] This difference is because in women of childbearing age, the diagnosis of lower abdominal pain is difficult and may be secondary to gynecologic conditions, such as ovarian disease or pelvic inflammatory disease. Clinicians are able to use a variety of imaging techniques in the evaluation of suspected AA. In this article, ultrasonography (US), computed tomography

The authors have nothing to disclose.

Department of Surgery, University of Tennessee Health Science Center, 910 Madison Avenue, Suite 220, Memphis, TN 38163, USA
* Corresponding author.
E-mail address: tschroep@uthsc.edu

Surg Clin N Am 91 (2011) 141–154
doi:10.1016/j.suc.2010.10.017 **surgical.theclinics.com**
0039-6109/11/$ – see front matter

(CT), and magnetic resonance imaging (MRI) are reviewed with respect to their accuracy in the diagnosis of AA and their ability to reduce negative appendectomy rates.

PLAIN RADIOGRAPHS

Plain abdominal radiographs are not routinely recommended for the evaluation of suspected AA. If they are obtained in patients with acute abdominal pain, nonspecific findings suggestive of AA may be evident. A calcified density in the right lower quadrant, or appendicolith, suggests the diagnosis of AA in the appropriate clinical setting (**Fig. 1**). However, an appendicolith is visualized on plain radiographs in less than 5% of patients with AA.[4] Other findings on plain radiographs include abnormal gas patterns in the right lower quadrant, a thickened appendix with irregular walls, or a general haziness in the right lower quadrant. These findings are nonspecific and present infrequently, greatly limiting their reliability in the diagnosis of AA.[5]

Perforated appendicitis (PA) with abscess can occasionally be demonstrated on plain radiographs. Abscesses may appear as irregularly shaped, unilocular lucencies, which occasionally contain gas. An abscess can cause an obstructive pattern on radiograph, and in the correct clinical setting, PA should be considered as a possible cause. Although a small amount of air may be released with PA, it is typically not enough to be detected as pneumoperitoneum on plain radiographs.[6]

US

US has been used as a tool to aid in the diagnosis of AA since the 1980s. Over the last 30 years, advances in ultrasound technology and the graded compression technique

Fig. 1. Plain radiograph of the abdomen with arrow highlighting the calcified appendicolith.

have improved the ability to visualize the appendix. The graded compression technique involves applying steady, gradual pressure to the right lower quadrant in an effort to collapse the normal bowel and eliminate normal bowel gas to visualize the appendix. If AA is present, the appendix will be immobile, noncompressible, and thickened with a diameter of greater than 6 to 7 mm (**Figs. 2–4**).[7]

US is operator dependent, and therefore, the reported sensitivity and specificity of US in the diagnosis of AA is variable. US is most reliable in centers with considerable experience using this imaging modality. In 2 recent meta-analyses reviewing the utility of US, the sensitivity was reported as 78% and 83% and the specificity was 83% and 93%.[8,9] Although both of these meta-analyses reported higher sensitivity and specificity data for CT than for US, a prospective trial comparing US with CT showed that the diagnostic performance of both modalities was similar. In that trial, 94 adult patients suspected of having AA underwent US and CT scanning. Findings on US and CT were compared to clinical follow-up or surgical pathologic findings. The diagnostic accuracy of US and CT were not significantly different, but there were significantly more inconclusive findings with ultrasonography.[10]

Poortman and colleagues[11] have developed an imaging pathway to minimize radiation exposure from CT, while attempting to achieve a high accuracy in the diagnosis of AA. In their prospective trial, 151 adults with suspected AA were evaluated. All patients had an initial US. Of these patients, 79 (52%) were diagnosed with AA on US and proceeded directly to appendectomy. The remaining 72 patients had a subsequent CT scan. CT diagnosed AA in 21 patients and found an alternative diagnosis in 12 patients and no cause for the abdominal pain in 39 patients. This strategy yielded a negative appendectomy rate of 8%.

US has been particularly useful in the diagnosis of AA in children. Pediatric centers have gained a large experience in US because of the concerns with childhood exposure to ionizing radiation. A recent study of pediatric patients evaluated for acute abdominal pain underscored the value of ultrasonography. Of the 622 patients, 152 were evaluated clinically and discharged. Another 81 patients were taken directly to the operating room for appendectomy based on history taking and physical examination alone. Of these patients, 16 had a normal appendix on pathologic examination (20% negative appendectomy rate). The remaining 389 patients had imaging performed to evaluate their abdominal pain; 386 patients underwent US and 7 patients underwent CT scans. Of the 389 patients, 137 were diagnosed with AA; only 3% of

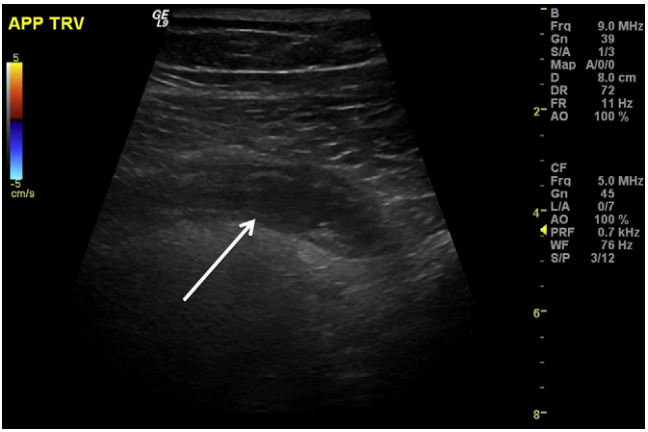

Fig. 2. Sagittal US image of the appendix. Arrow highlights the thickened appendix.

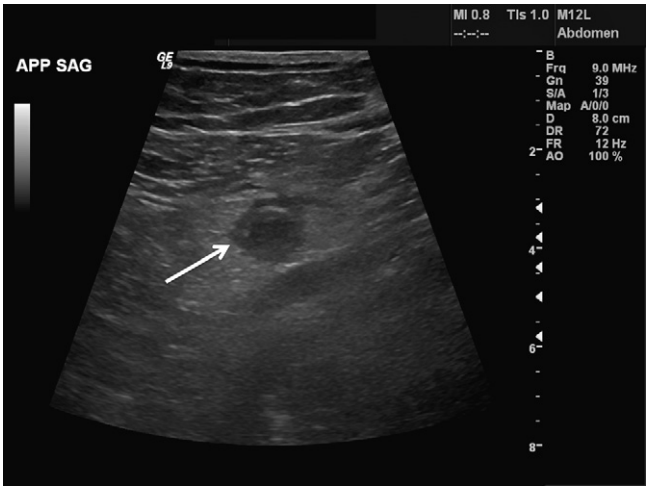

Fig. 3. Transverse US image of the appendix. Arrow highlights the thickened appendix.

this group had a negative appendectomy. No patients returned with a missed diagnosis of appendicitis. In this series, US was the primary imaging modality in children with abdominal pain, yielding a lower rate of negative appendectomy than clinical evaluation alone.[12]

US is also valuable in the diagnosis of AA in pregnant women. US is safe during all trimesters of pregnancy and therefore is the initial imaging study of choice in pregnant women with new-onset abdominal pain. US in pregnancy has a variable sensitivity, ranging from 66% to 100%, but a good specificity of 95% to 96%.[13] Because US is safe, easy to obtain, and widely available, it is a good imaging study for pregnant women with suspected AA. However, if the US result is negative or inconclusive, AA cannot be excluded and further imaging studies are recommended.

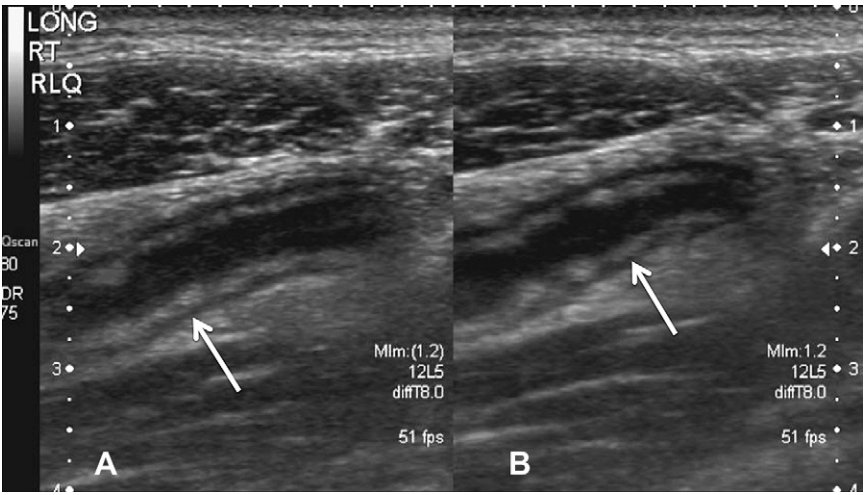

Fig. 4. US of the appendix. (*A*) A thick-walled appendix inferior to the abdominal wall. (*B*) Compression view demonstrating a noncompressible appendix. Arrows highlight the thickened wall of the appendix.

Advantages of US include the absence of ionizing radiation, low cost, and widespread availability. In addition, it is noninvasive, safe, and quick to obtain and can identify other causes of abdominal pain. A significant disadvantage of US is that it is operator dependent, relying both on the US technician and the interpretation by the radiologist. Also, if the appendix is not visualized, the study is inconclusive and no decision can be made about the cause of the abdominal symptoms.

CT

CT is a highly accurate and effective modality for the evaluation of patients with suspected AA. Modern helical CT scans have excellent resolution, are widely available, and are operator independent. CT scans are easy to interpret and can provide significant information regarding alternative diagnoses. CT has been shown to have a sensitivity of 90% to 100%, specificity of 91% to 99%, positive predictive value of 92% to 98%, and negative predictive value of 95% to 100%.[14] This high accuracy is maintained in large university and rural community hospitals.[15] However, in spite of the widespread use and high accuracy of CT scanning, there is still considerable debate regarding the true benefit of CT in patients with suspected AA.

CT diagnosis of AA is based on the appearance of a thickened, inflamed appendix and surrounding signs of inflammation. In AA, the appendix is usually greater than 7 mm in diameter with circumferential wall thickening and mural enhancement, which may give the appearance of a "target sign" on CT scan (**Fig. 5**).[14] A calcified appendicolith may be seen in up to 30% of cases (**Fig. 6**). Periappendiceal inflammation, such as fat stranding, periappendiceal fluid, and clouding of the adjacent mesentery, are common in AA. In PA, there may be a right lower quadrant abscess or extraluminal gas (see **Fig. 6; Figs. 7** and **8**).[16] If the appendix is not visualized and there are no findings of inflammation in the right lower quadrant, the diagnosis of AA can be excluded.[17]

Many possible protocols have been described for CT imaging in suspected AA. One of the original articles to show a benefit with routine CT scanning in the evaluation of suspected AA was done by Rao and colleagues[18] using a limited appendiceal

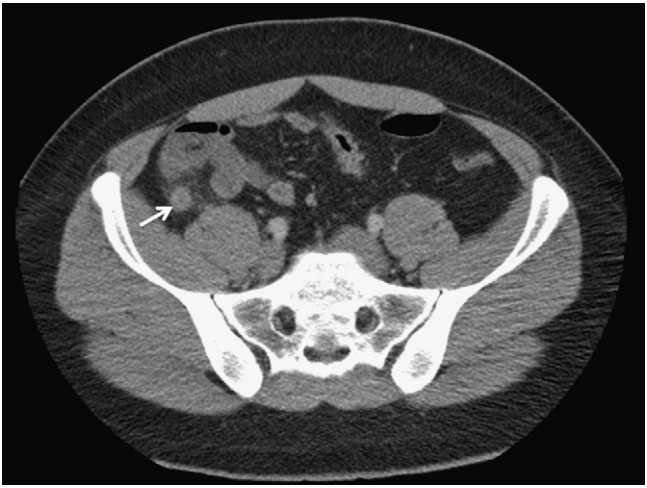

Fig. 5. CT axial image demonstrating thick-walled appendix with stranding and inflammation. The arrow highlights the appendix with a "target sign."

Fig. 6. CT axial image demonstrating PA. The white arrow highlights a calcified appendicolith. The black arrow highlights an abscess cavity with a bubble of air adjacent to the appendix.

Fig. 7. CT sagittal image of PA. Arrow highlights the abscess cavity containing a calcified appendicolith.

Fig. 8. CT coronal image of PA. Arrow highlights the abscess cavity containing a calcified appendicolith.

protocol. In this study, 100 consecutive patients with suspected AA underwent a limited scan through the region of the ileocecal valve after receiving enteric contrast injected per rectum. The field of the scan included a 15-cm region centered around the cecum as seen on the initial CT radiograph. The benefit of the limited scan is that it requires approximately one-third the radiation of a full CT scan of the abdomen and pelvis. Using this technique, the appendix was visualized in 94% of the patients. The CT scan had an accuracy of 94%, and hence, the treatment plan in 59 patients was changed, including preventing unnecessary appendectomy in 13 patients. A cost analysis demonstrated an overall savings with the increased use of CT scanning because of a decrease in the number of negative appendectomies and decreased inpatient observation for equivocal cases.

There continues to be controversy regarding the optimal extent of the CT scan and the need for contrast. A recent retrospective review of 100 consecutive, nonfocused abdominal CT scans obtained for suspected AA concluded that limited appendiceal CT scans should not be done because alternative diagnoses can be missed. The investigators identified 7 patients with abnormalities in the upper abdomen, and 4 of them required surgery. These findings would have been missed on a limited CT scan. Based on these findings, the investigators concluded that full-abdomen and pelvis CT scans should be obtained in the evaluation of suspected AA.[19]

There is also significant debate considering which, if any, contrast to administer with CT scanning. In a series of 300 consecutive patients with suspected AA, CT scans of the abdomen and pelvis were obtained without using any intravenous (IV) or enteric contrast material to rapidly scan the abdomen. Radiological findings were compared to clinical follow-up and surgical pathologic findings, yielding a sensitivity of 96%, a specificity of 99%, and an accuracy of 97%. There were 5 false-negative results

in this series, 3 of which occurred in thin, young women with little intraperitoneal fat. The lack of intraperitoneal fat in a noncontrast CT scan was thought to lead to difficulty in identifying the inflammatory process.[20]

Other investigators have reported on the value of contrast-enhanced CT scans. A prospective randomized trial of 91 patients was done comparing the traditional triple-contrast CT of the abdomen and pelvis with a limited appendiceal CT with rectal contrast only. In this study, the limited scan with only rectal contrast was determined to be superior to the triple contrast scan because it was more specific for AA, was well tolerated by the patients, and quicker to perform.[21] Other investigators have stated that CT scans should be obtained with IV contrast to visualize the mild changes in the appendix associated with early appendicitis.[22]

The final major area of debate is regarding which patients suspected of having AA should have a CT scan before appendectomy. There are multiple articles in the literature, which argue against routine preoperative imaging of patients with suspected AA.[23–25] In these articles, the routine use of imaging has not been shown to decrease the rate of negative appendectomy. In addition, concerns have been raised that ordering routine imaging in the emergency department, before surgical consultation, may actually delay the diagnosis and appropriate intervention in cases of AA.[26] Early surgical consultation and involvement of the surgeon while deciding to obtain a CT scan may avoid an unnecessary delay.

Other studies have shown a benefit from preoperative imaging in suspected AA. Naoum and colleagues[27] showed that the development of a guideline to obtain a CT in patients with an equivocal presentation decreased the rate of negative appendectomy from 25% to 6%. Over the same time period, the use of preoperative CT scan increased from 32% to 84% and the rate of PA remained unchanged. A review of a large, prospectively gathered database of general surgical procedures in Washington State found the negative appendectomy rate to be 9.8% in patients with no preoperative imaging and only 4.5% in those who had a preoperative CT scan. This difference was statistically significant.[3] Based on these findings, CT scans seem to have significant benefit in the evaluation of patients with suspected AA.

MRI

MRI has had little role in the evaluation of acute abdominal pain. However, increasing concerns over the potentially hazardous effects of ionizing radiation associated with CT have made MRI the study of choice to evaluate pregnant women and children with symptoms of appendicitis and equivocal US findings.[28]

MRI has excellent resolution and has been shown to be highly accurate in diagnosing AA when based on standard criteria. A normal appendix is less than or equal to 6 mm in diameter and filled with air or oral contrast material. MRI is considered to provide positive results for AA when the appendix is enlarged (>7 mm), the appendiceal wall is thicker than 2 mm, or there are signs of inflammatory changes surrounding the appendix, such as fat stranding, phlegmon, or abscess formation (**Figs. 9–11**).[29]

Cobben and colleagues[30] have evaluated the accuracy of MRI in diagnosing AA. In this prospective study, 138 patients underwent both abdominal US and a limited, noncontrast MRI through the region of the ileocecal valve. Overall, 62 patients were found to have appendicitis, 42 had alternative diagnoses, and 34 did not have a cause for abdominal pain identified. Their imaging results were compared to surgical pathological findings or clinical follow-up in the patients not requiring surgery. US had a sensitivity of 88% and a specificity of 99%. MRI was highly accurate with a sensitivity of

Fig. 9. MR scan with T1-weighted axial image of the abdomen in a gravid woman. Arrow highlights the thickened appendix.

100%, specificity of 98%, positive predictive value of 98%, and negative predictive value of 100%. MRI identified AA in 8 of the 36 patients with nondiagnostic US results. The cost of obtaining an MRI in patients with equivocal US results was compared to the cost of one day of inpatient hospital observation, and an overall cost savings was found with MRI because patients could be discharged home safely after negative MRI results.

Although MRI may be used in any patient with suspected AA, there is a special role for MRI in pregnant women with new-onset abdominal pain. AA is the most common

Fig. 10. MR scan with T1-weighted coronal image of the abdomen in a gravid woman. Arrow highlights the thickened appendix.

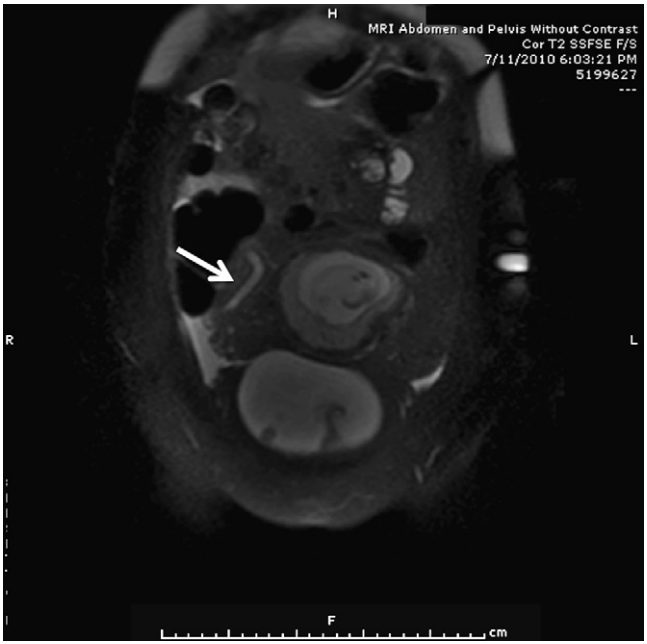

Fig. 11. MR scan with T2-weighted coronal image of the abdomen in a gravid woman. Arrow highlights the thickened appendix.

nonobstetric surgical emergency during pregnancy, complicating 1 in 766 births.[31] AA can be difficult to diagnose during pregnancy because the history and clinical presentation are often atypical. The location of abdominal pain associated with AA is highly variable during pregnancy, with the appendix being displaced superiorly and laterally by the enlarging uterus. Leukocytosis is a nonspecific finding during pregnancy.[32] Traditional surgical teaching had been aggressive in recommending that pregnant women with suspected AA undergo appendectomy because it was believed that the risk of appendiceal perforation and subsequent fetal loss was greater than the risk associated with negative appendectomy.[33] A recent review found that negative appendectomy rates were higher in pregnant women (23%) than in nonpregnant women (18%). However, in this review negative appendectomy was associated with fetal loss in 4% of cases and preterm delivery in 10% of cases. In comparison, rates of fetal loss after appendectomy were 2% in simple appendicitis and 6% in complicated appendicitis. Preterm delivery occurred in 4% of patients with simple appendicitis and 11% of patients with complicated appendicitis.[34] These data underscore the need for appropriate and timely diagnosis of AA in pregnancy.

MRI has been shown to reliably exclude the diagnosis of AA in pregnant women. In a study by Pedrosa and colleagues,[35] 51 consecutive pregnant women suspected of having AA underwent MRI. The patients were given oral contrast but no IV contrast. Based on clinical follow-up and pathology results, this study showed that MRI had a sensitivity of 100%, specificity of 93.6%, accuracy of 94%, and negative predictive value of 100% in diagnosing pregnant women with AA.

MRI has many advantages. It is highly valuable in the imaging of pregnant women and children because there is no exposure to ionizing radiation. Although MRI is safe during pregnancy, no IV contrast should be used during pregnancy because gadolinium is a category C drug and potentially teratogenic. However, noncontrast

MRI provides detailed images, which usually provide the correct diagnosis. MRI is operator independent and the results are highly reproducible. MRI is more useful than US in obese patients and in patients with a retrocecal appendix, which is difficult to visualize on US. Drawbacks of MRI are that it is more expensive than other imaging modalities and not as widely available. The examination itself takes longer to perform and may be degraded by motion artifact. There are concerns that, with the exception of trained radiologists, other health care providers are not comfortable interpreting MRI findings. As MRI becomes more available and faster protocols are developed, these limitations may become less of an issue.[36]

PA

The imaging of advanced appendicitis merits special discussion because the preoperative recognition of PA or a well-formed abscess associated with AA may alter treatment. US findings of PA are an irregular contour of the appendiceal wall or a periappendiceal fluid collection. However, the appendix decompresses with perforation, making PA more difficult to diagnose with US.[2] Surrounding inflammatory changes may be the most obvious findings on US after appendiceal perforation. A phlegmon may be seen as a hypoechoic region with surrounding inflammation. An abscess is seen as a fluid collection, possibly containing gas bubbles.[14] Pickuth and colleagues[37] obtained both CT and US in 120 consecutive patients suspected of having appendicitis and found that CT was superior to US in assessing periappendiceal inflammation. On CT, 15% of the patient population had an identifiable abscess or phlegmon, whereas on US, the abscess or phlegmon in only 9% of the patients was identified.

Horrow and colleagues[38] studied the ability of CT to differentiate PA and AA. By retrospectively reviewing the CT scans of 94 patients with appendicitis, the investigators were able to evaluate the sensitivity and specificity of the following findings, abscess, phlegmon, extraluminal air, extraluminal appendicolith, and focal defect in the appendiceal wall. Although the sensitivity for any one finding was low, using the presence of any 1 of the 5 findings together increased the sensitivity to 94.9%. The overall specificity was 94.5%. A similar study by Bixby and colleagues[39] retrospectively reviewed the CT scans of 244 patients with proven appendicitis. The specificity for PA was as follows: abscess 99%, extraluminal gas 98%, and ileus 93%, but the sensitivities were 34%, 35%, and 53%, respectively. Only the visualization of a defect in the enhancing appendiceal wall has been shown to have both a high sensitivity (95%) and specificity (96.8%) for PA.[40]

TYPHLITIS

Typhlitis, or neutropenic colitis, is an inflammatory condition of the cecum, ascending colon, and occasionally the terminal ileum and appendix, which can easily be mistaken for AA. Patients are typically immunocompromised, and imaging studies show bowel wall thickening with intramural edema and surrounding inflammatory changes. Radiographic studies showing colonic thickening greater than 0.3 cm, fluid or fat stranding surrounding the colon, or edematous bowel wall are consistent with typhlitis. AA and typhlitis can be differentiated by a clinical history of neutropenia as well as imaging findings. The finding of symmetric thickened cecum and ascending colon strongly suggests typhlitis; in addition, the extent of bowel involvement is usually much greater in typhlitis than in AA.[41]

Both US and CT have been used in the evaluation of suspected typhlitis. McCarville[42] has evaluated 92 children being treated for cancer who developed typhlitis. In this study, US measurements of bowel wall thickness correlated with duration of

Table 1
Statistics of imaging modalities for AA

	Sensitivity (%)	Specificity (%)	PPV (%)	NPV (%)
US[8,9,13,14]	66–100	83–96	91–94	89–97
CT[14]	90–100	91–99	92–98	95–100
MRI[30,35,36]	97–100	92–98	57–98	96–100

Abbreviations: NPV, negative predictive value; PPV, positive predictive value.

symptoms, whereas CT measurements did not, which may be because of overestimation of bowel wall thickness on CT. Although CT may overestimate the edema of the bowel wall, it provides additional information about the extent of inflammatory changes in the right lower quadrant. Findings on CT associated with typhlitis include pericolonic fluid collections, fat stranding, pneumatosis coli, or low-attenuation regions within the colon wall indicative of possible necrosis.[43]

SUMMARY

Appendicitis is one of the most common surgical emergencies in the United States, but it remains a diagnostic challenge in many patients who may present with atypical clinical findings. Traditionally, negative appendectomy rates of approximately 20% have been considered acceptable to avoid delayed diagnosis and increased rates of PA. Imaging studies aid in the evaluation of suspected AA and reduction of negative appendectomy rate. US is readily available and inexpensive, but it is highly operator dependent and has lower overall sensitivity and specificity than CT or MRI. US is a good screening test particularly in children, pregnant women, and centers with an established US program. CT is widely available, is not operator dependent, and has excellent accuracy in the diagnosis of appendicitis. However, care must be taken to select patients with an equivocal clinical presentation and to involve the surgical consultant early to yield the full benefits of CT scanning. CT scans are highly valuable in the diagnosis of abdominal pain in women of childbearing age. Although CT scans provide significant information about the inflammatory process associated with appendicitis, only a CT scan result showing a defect in the appendiceal wall is diagnostic of PA. MRI is another highly accurate tool in evaluating suspected AA. The drawbacks to MRI include its expense, longer time to obtain the study, and limited availability compared with other imaging modalities. MRI is of the greatest value in evaluating patients, such as children and pregnant women, who should not be exposed to additional ionizing radiation and who have equivocal or nondiagnostic findings on US. The respective sensitivities, specificities, and positive and negative predictive values of US, CT, and MRI in the evaluation of suspected AA are seen in **Table 1**. AA remains a disease that is diagnosed first and foremost with the initial history and physical examination. If there is diagnostic uncertainty, then imaging studies can improve negative appendectomy rates and diagnose alternatives, including PA and typhlitis. CT remains the diagnostic study of choice for most patients requiring imaging to aid in the diagnosis of AA.

REFERENCES

1. Addiss DG, Shaffer N, Fowler BS, et al. The epidemiology of appendicitis and appendectomy in the United States. Am J Epidemiol 1990;132:910–25.

2. Rybkin AV, Thoeni RF. Current concepts in imaging of appendicitis. Radiol Clin North Am 2007;45:411–22.
3. Cuschieri J, Florence M, Flum DR, et al. The SCOAP Collaborative. Negative appendectomy and imaging accuracy in the Washington State Surgical Care and Outcomes Assessment Program. Ann Surg 2008;248:557–63.
4. Old JL, Dusing RW, Yap W, et al. Imaging for suspected appendicitis. Am Fam Physician 2005;71:71–8.
5. Rypins EB, Evans DG, Hinrichs W, et al. Tc-99m-HMPAO white blood cell scan for diagnosis of acute appendicitis in patients with equivocal clinical presentation. Ann Surg 1997;226:58–65.
6. Baker SR. Acute appendicitis: plain radiographic considerations. Emerg Radiol 1996;3:63–9.
7. Prystowsky JB, Pugh CM, Nagle AP. Appendicitis. Curr Probl Surg 2005;42: 694–742.
8. Van Randen A, Bipat S, Zwinderman AH, et al. Acute appendicitis: meta-analysis of diagnostic performance of CT and graded compression US related to prevalence of disease. Radiology 2008;249:97–106.
9. Doria AS, Moineddin R, Kellenberger CJ, et al. US or CT for diagnosis of appendicitis in children and adults? A meta-analysis. Radiology 2006;241:83–94.
10. Keyzer C, Zalcman M, De Maertelaer V, et al. Comparison of US and unenhanced multi-detector row CT in patients suspected of having acute appendicitis. Radiology 2005;236:527–34.
11. Poortman P, Oostvogel HJM, Bosma E, et al. Improving diagnosis of acute appendicitis: results of a diagnostic pathway with standard use of ultrasonography followed by selective use of CT. J Am Coll Surg 2009;208:434–41.
12. Hernandez JA, Swischuk LE, Angel CA, et al. Imaging of acute appendicitis: US as the primary imaging modality. Pediatr Radiol 2005;35:392–5.
13. Patel SJ, Reede DL, Katz DS, et al. Imaging the pregnant patient for nonobstetric conditions: algorithms & radiation dose considerations. Radiographics 2007; 27(6):1705–22.
14. Birnbaum BA, Wilson SR. Appendicitis at the millennium. Radiology 2000;215: 337–48.
15. Holloway JA, Westerbuhr LM, Chain J, et al. Is appendiceal computed tomography in a community hospital useful? Am J Surg 2003;186:682–4.
16. Whitley S, Sookur P, McLean A, et al. The appendix on CT. Clin Radiol 2009;64: 190–9.
17. Brown MA. Imaging acute appendicitis. Semin Ultrasound CT MR 2008;29: 293–307.
18. Rao PM, Rhea JT, Novelline RA, et al. Effect of computed tomography of the appendix on treatment of patients and use of hospital resources. N Engl J Med 1998;338:141–6.
19. Kamel IR, Goldberg SN, Keogan MT, et al. Right lower quadrant pain and suspected appendicitis: nonfocused appendiceal CT—review of 100 cases. Radiology 2000;217:159–63.
20. Lane MJ, Liu DM, Huynh MD, et al. Suspected acute appendicitis: nonenhanced helical CT in 300 consecutive patients. Radiology 1999;213:341–6.
21. Mittal VK, Goliath J, Sabir M, et al. Advantages of focused helical computed tomographic scanning with rectal contrast only vs triple contrast in the diagnosis of clinically uncertain acute appendicitis. Arch Surg 2004;139:495–500.
22. Birnbaum BA, Jeffrey RB. CT and sonographic evaluation of acute right lower quadrant abdominal pain. AJR 1998;170:361–71.

23. Perez J, Barone JE, Wilbanks TO, et al. Liberal use of computed tomography scanning does not improve diagnostic accuracy in appendicitis. Am J Surg 2003;185:194–7.
24. Vadeboncoeur TF, Heister RR, Behling CA, et al. Impact of helical computed tomography on the rate of negative appendicitis. Am J Emerg Med 2006;24:43–7.
25. Morris KT, Kavanagh M, Hansen P, et al. The rational use of computed tomography scans in the diagnosis of appendicitis. Am J Surg 2002;183:547–50.
26. Lee SL, Walsh AJ, Ho HS. Computed tomography and ultrasonography do not improve and may delay the diagnosis and treatment of acute appendicitis. Arch Surg 2001;136:556–62.
27. Naoum JJ, Mileski WJ, Daller JA, et al. The use of abdominal computed tomography scan decreases the frequency of misdiagnosis in cases of suspected appendicitis. Am J Surg 2002;184:587–90.
28. Singh A, Danrad R, Hahn PF, et al. MR imaging of the acute abdomen and pelvis: acute appendicitis and beyond. Radiographics 2007;27:1419–31.
29. Tkacz JN, Anderson SA, Soto J. MR imaging in gastrointestinal emergencies. Radiographics 2009;29:1767–80.
30. Cobben L, Groot I, Kingma L, et al. A simple MRI protocol in patients with clinically suspected appendicitis: results in 138 patients and effect on outcome of appendectomy. Eur Radiol 2009;19:1175–83.
31. Andersen B, Nielsen TK. Appendicitis in pregnancy: diagnosis, management and complications. Acta Obstet Gynecol Scand 1999;78:758–62.
32. Gjelsteen AC, Ching BH, Meyermann MW, et al. CT, MRI, PET/CT, and ultrasound in the evaluation of obstetric and gynecologic patients. Surg Clin North Am 2008; 88:361–90.
33. Freeland M, King E, Safcsak K, et al. Diagnosis of appendicitis in pregnancy. Am J Surg 2009;198:753–8.
34. McGory ML, Zingmond DS, Tillou A, et al. Negative appendectomy in pregnant women is associated with a substantial risk of fetal loss. J Am Coll Surg 2007; 205:534–40.
35. Pedrosa I, Levine D, Eyvazzadeh AD, et al. MR imaging evaluation of acute appendicitis in pregnancy. Radiology 2006;238:891–9.
36. Lam M, Singh A, Kaewlai R, et al. Magnetic resonance of acute appendicitis: pearls and pitfalls. Curr Probl Diagn Radiol 2008;37:57–66.
37. Pickuth D, Heywang-Kobrunner SH, Spielmann RP. Suspected acute appendicitis: is ultrasonography or computed tomography the preferred imaging technique? Eur J Surg 2000;166:315–9.
38. Horrow MM, White DS, Horrow JC. Differentiation of perforated from nonperforated appendicitis at CT. Radiology 2003;227:46–51.
39. Bixby SD, Lucey BC, Soto JA, et al. Perforated versus nonperforated acute appendicitis: accuracy of multidetector CT detection. Radiology 2006;241:780–6.
40. Tsuboi M, Takase K, Kaneda I, et al. Perforated and nonperforated appendicitis: defect in enhancing appendiceal wall—depiction with multi-detector row CT. Radiology 2008;246:142–7.
41. Hoeffel C, Crema MD, Belkacem A, et al. Multi-detector row CT: spectrum of disease involving the ileocecal area. Radiographics 2006;26:1373–90.
42. McCarville MB. Evaluation of typhlitis in children: CT versus US. Pediatr Radiol 2006;36:890–1.
43. Yu J, Fulcher AS, Turner MA, et al. Helical CT evaluation of acute right lower quadrant pain: part II, uncommon mimics of appendicitis. AJR 2005;184:1143–9.