Splenectomy in Dogs and Cats: Indications, Surgical Technique, and Postoperative Care

drstephenbirchard.blogspot.com.br/2016/03/splenectomy-in-dogs-and-cats.html

Splenectomy is the partial or total removal of the spleen. Common indications for splenectomy include splenic neoplasia, severe splenic trauma and splenic torsion.
(Fig 1)
Thrombosis of the spleen can also occur, sometimes associated with gastric dilatation/volvulus, and also requires splenectomy. (Fig 2)

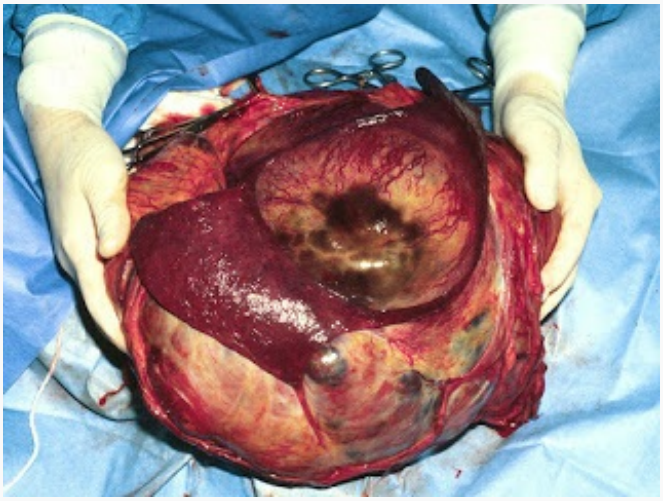

Fig. 1: Abdominal exploratory revealing a very large splenic hematoma in a golden retriever. The tumor and spleen were surgically removed.

Preoperative Considerations

History and Physical Examination– Animals requiring splenectomy can present with a variety of clinical signs depending on the disorder. Acute onset of pale mucous membranes, collapse and hemoabdomen are common findings in animals with splenic neoplasia, especially hemangiosarcoma. For splenic fracture, there is usually a recent history of blunt or penetrating trauma. Animals with splenic rupture will have hemoabdomen and develop pale mucous membranes, collapse, tachycardia, tachypnea, and evidence of fluid on abdominal palpation. Abdominal palpation may also reveal abdominal discomfort or a cranial abdominal mass.

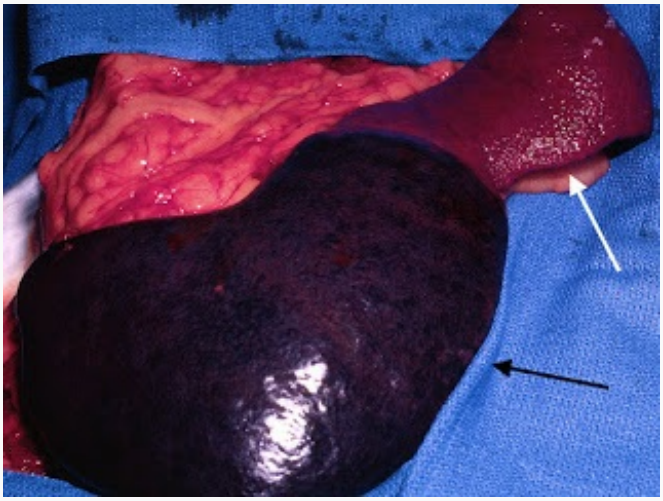

Fig. 2: Thrombosis of part of the spleen in a dog. (normal spleen white arrow, thrombotic spleen black arrow) Note sharp demarcation between the normal and abnormal portions of spleen.

Diagnostic Evaluation – A complete blood count (including platelet count), biochemical profile and urinalysis are indicated in animals with suspected splenic disease. Assessment of coagulation may also be indicated, especially in dogs with suspected hemangiosarcoma since disseminated intravascular coagulation can occur with that neoplasm. Arterial blood pressure is performed to detect hypotension. Abdominal radiographs or ultrasonography may discover fluid or a cranial abdominal mass. Ultrasonography may also reveal evidence of metastasis of the primary splenic tumor to other sites such as the liver and regional lymph nodes. If fluid is present, perform abdominocentesis, and evaluate the fluid packed cell volume, total protein and cytology. Obtain thoracic radiographs to examine for metastasis or other problems.

Initial Treatment – Prior to anesthesia and surgery, stabilize patients with intravenous fluids and blood transfusions if necessary. Although it may be impossible to return the animal to normal circulatory status prior to surgery, improvement of their condition is desirable to make them a better candidate for anesthesia and surgery.

Surgical Anatomy

The spleen is located in the left cranial abdomen and lies parallel to the greater curvature of the stomach. The splenic artery is a branch of the celiac artery. Branches of the splenic artery also supply the left limb of the pancreas (pancreatic branch), the fundus of the stomach (short gastric arteries and veins), and the greater curvature of the stomach (left gastroepiploic artery and vein). (Fig 3) Many small branches arise from the terminal branches of the splenic artery and vein and enter the splenic parenchyma perpendicular to the long axis of the spleen. The splenic vein drains the spleen and transports blood into the gastrosplenic vein and ultimately to the portal vein.

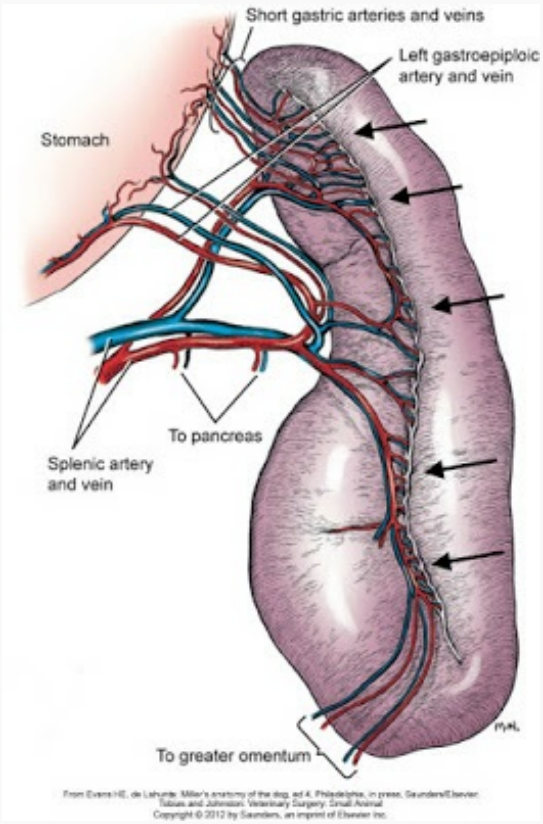

Fig. 3: Surgical anatomy of the spleen. Arrows indicate the small vessels that are dissected, ligated in small groups, and divided during total splenectomy. (from: Evans HE, de Lahunta *Miller's Anatomy of the Dog* Saunders/Elsevier 4th ed. Tobia and Johnston, *Veterinary Surgery Small Animal* Elsevier, 2012)

Surgical Technique

Perform a routine ventral abdominal approach from the xyphoid to a few centimeters cranial to the pubis. After a thorough exploratory of the abdomen, the spleen is exteriorized and isolated with moistened abdominal sponges. A partial or total splenectomy can be performed, depending on the reason for the splenectomy. Partial splenectomy will preserve splenic function, but total splenectomy is usually performed since it is technically easier and there are few long-term complications from total splenectomy in dogs and cats.

If one or more tumors are present on the spleen, omental adhesions may be present and should be ligated and sharply divided. Dissection and ligation of the small splenic vessels close to the hilus can then be done. These vessels can be ligated and divided in small groups when they are close together. Be careful to preserve the short gastric vessels that supply the gastric fundus, and the left gastroepiploic vessel that supplies blood to the greater curvature of the stomach. Also avoid ligating the pancreatic branch of the splenic artery. If the small vessels are ligated close to the splenic parenchyma, vessels to the pancreas and stomach will not be compromised. Splenic vessels can be ligated with suture (e.g. Monocryl), hemostatic clips; the LDS device (ligate, divide, staple), or the Ligasure vessel-sealing device (see video below). The author prefers the Ligasure for splenectomy since it is a rapid and effective means of providing hemostasis.

In animals with splenic torsion, the blood vessels to the spleen are twisted into a pedicle that contains the mesentery and vessels. Do not untwist the spleen since this will allow cellular breakdown products, thrombi, and other toxic substances to be released into circulation.(1) Ligate the entire vascular pedicle with full and transfixing ligatures and remove the spleen.

After removal of the spleen, check all ligated vessels for lack of persistent hemorrhage and then close the abdomen routinely.

Postoperative Care and Complications

Maintain supportive care immediately after surgery consisting of intravenous fluids, analgesics and monitoring of vital signs. If preoperative or intraoperative blood loss was excessive monitor the animal's PCV postoperatively and consider blood transfusion if the PCV drops below 20. With appropriate care most dogs will recover from splenectomy quickly with many being discharged from the hospital the day after surgery.

The most common complication associated with splenectomy is hemorrhage. Other potential complications include pancreatitis, cardiac arrhythmias, and postoperative pain.

The prognosis for dogs undergoing splenectomy varies depending on the splenic disease. Dogs and cats with splenic trauma, splenic torsion, or benign neoplasia have a good prognosis assuming they survive the perioperative period. In contrast, animals with malignant neoplasia, most commonly hemangiosarcoma, have a poor prognosis due to the tendency for metastasis of the primary tumor.(2)

References

1. Richter MC. Spleen, in Veterinary Surgery: Small Animal, eds. KM Tobias, SA Johnston, Elsevier, St. Louis, 2012, pg. 1341.
2. Spangler WL1, Kass PH. Pathologic factors affecting postsplenectomy survival in dogs. J Vet Intern Med. 1997 May-Jun;11(3):166-71.