

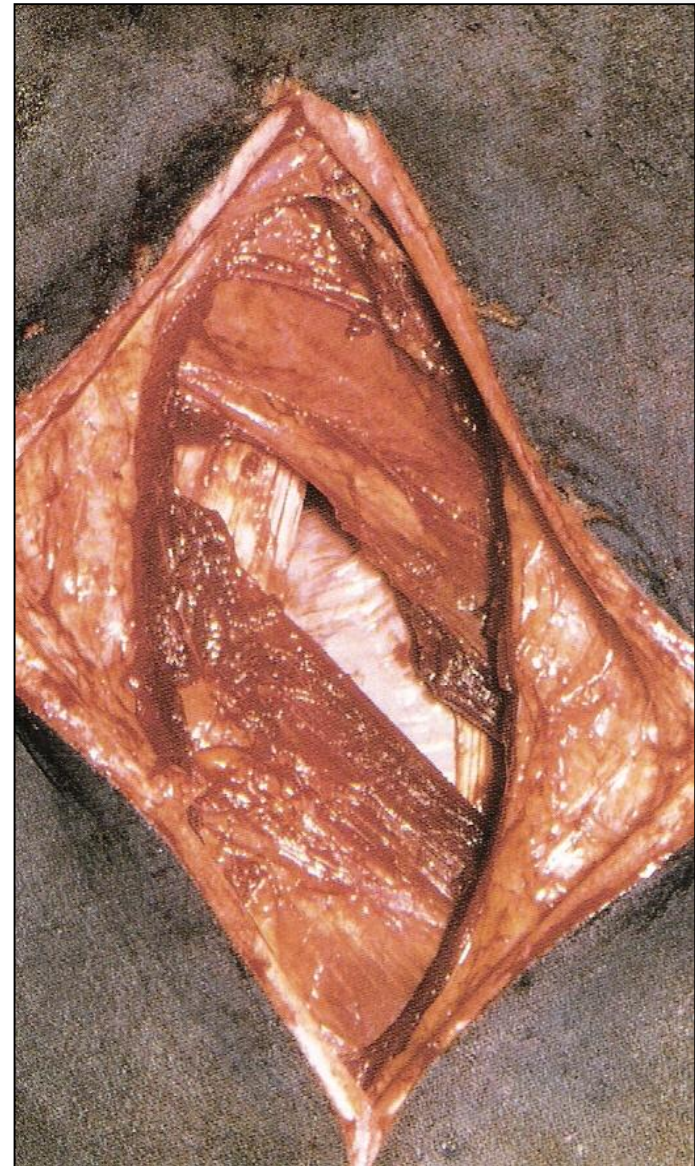
VCI 516 – Cirurgia de Grandes Animais

# AFECÇÕES CIRÚRGICAS DO SISTEMA DIGESTÓRIO DOS RUMINANTES

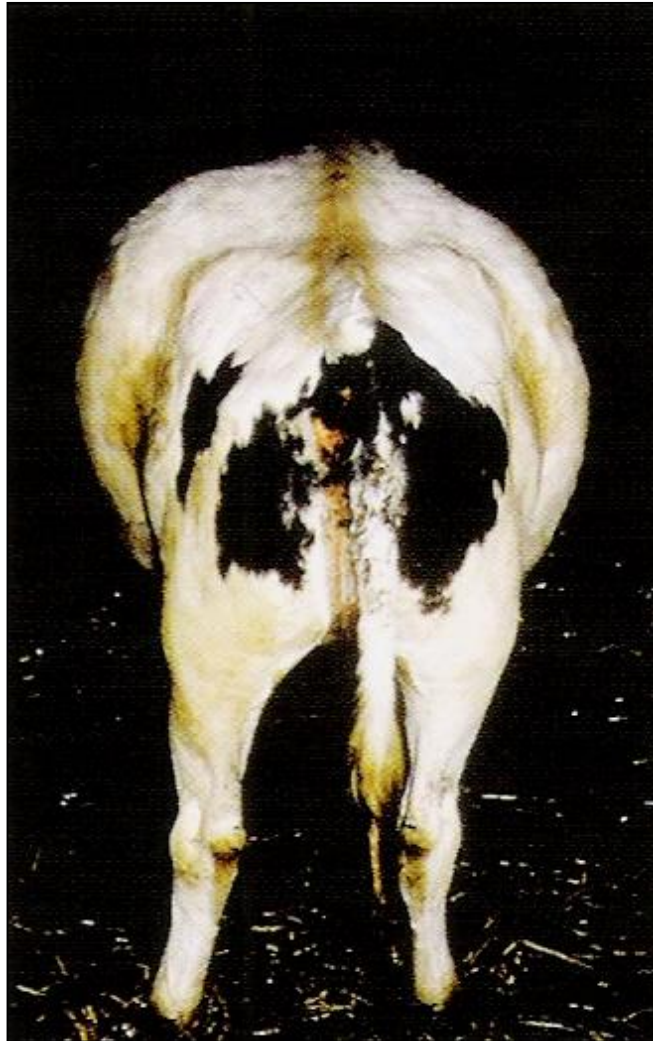Prof. Dr. Rodrigo Romero Corrêa  
romero@usp.br

# LAPAROTOMIA EXPLORATÓRIA

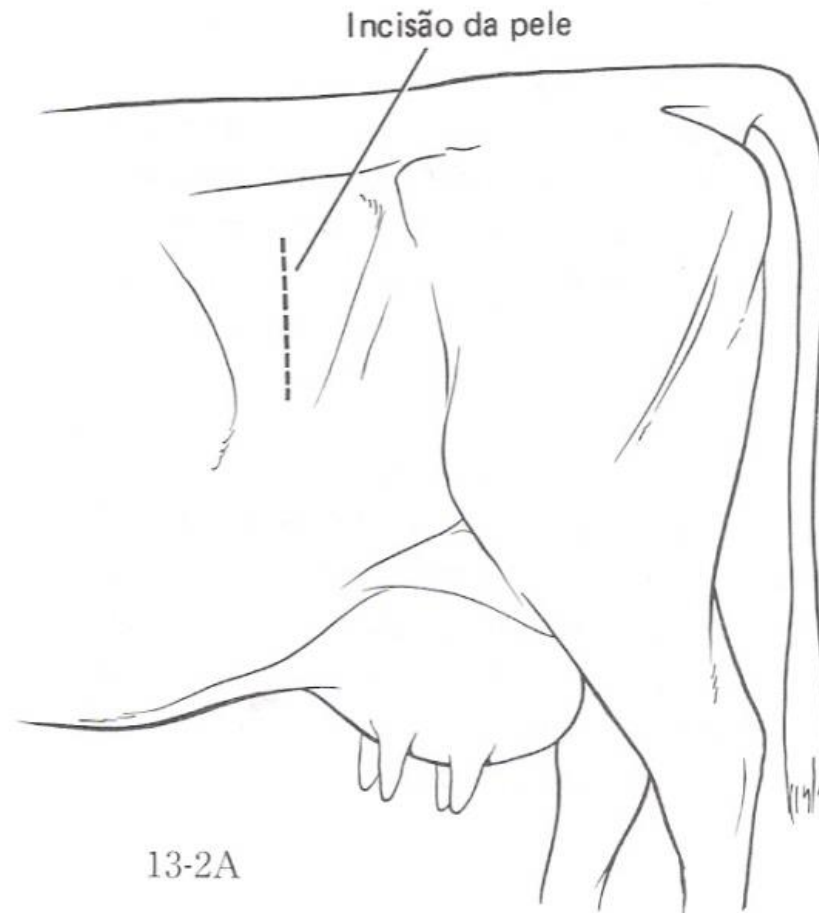
- Indicações
- Acessos cirúrgicos
- Pré-operatório
- Técnicas cirúrgicas
- Pós-operatório



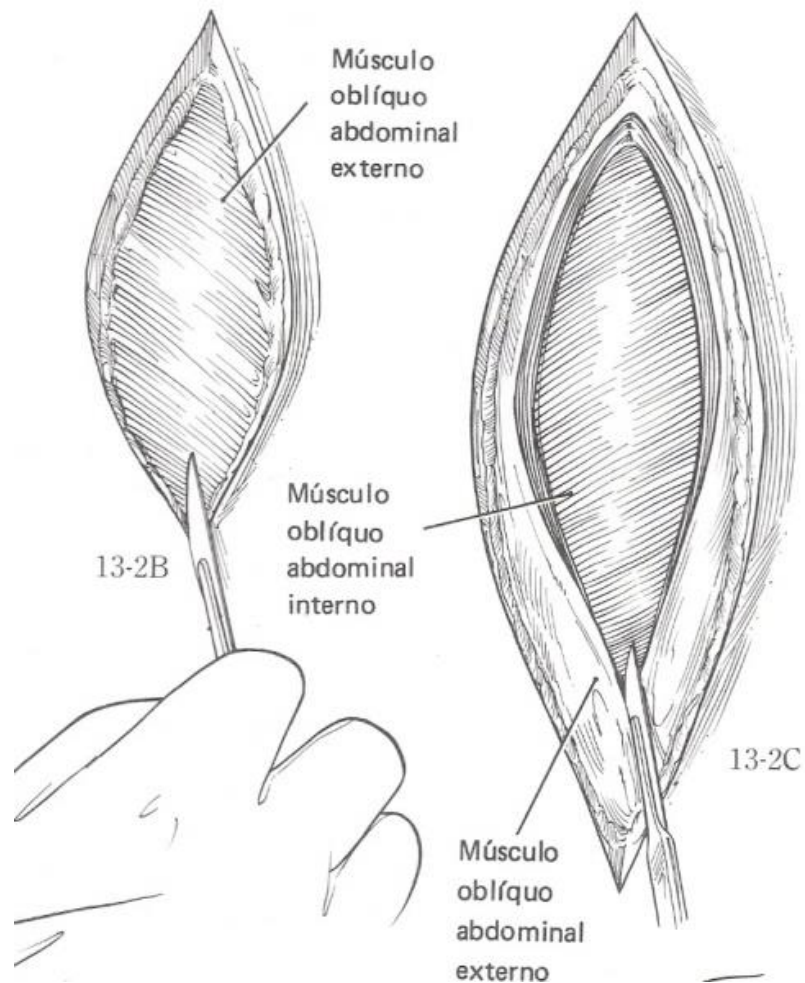
# LAPAROTOMIA PELO FLANCO ESQUERDO RUMENOTOMIA



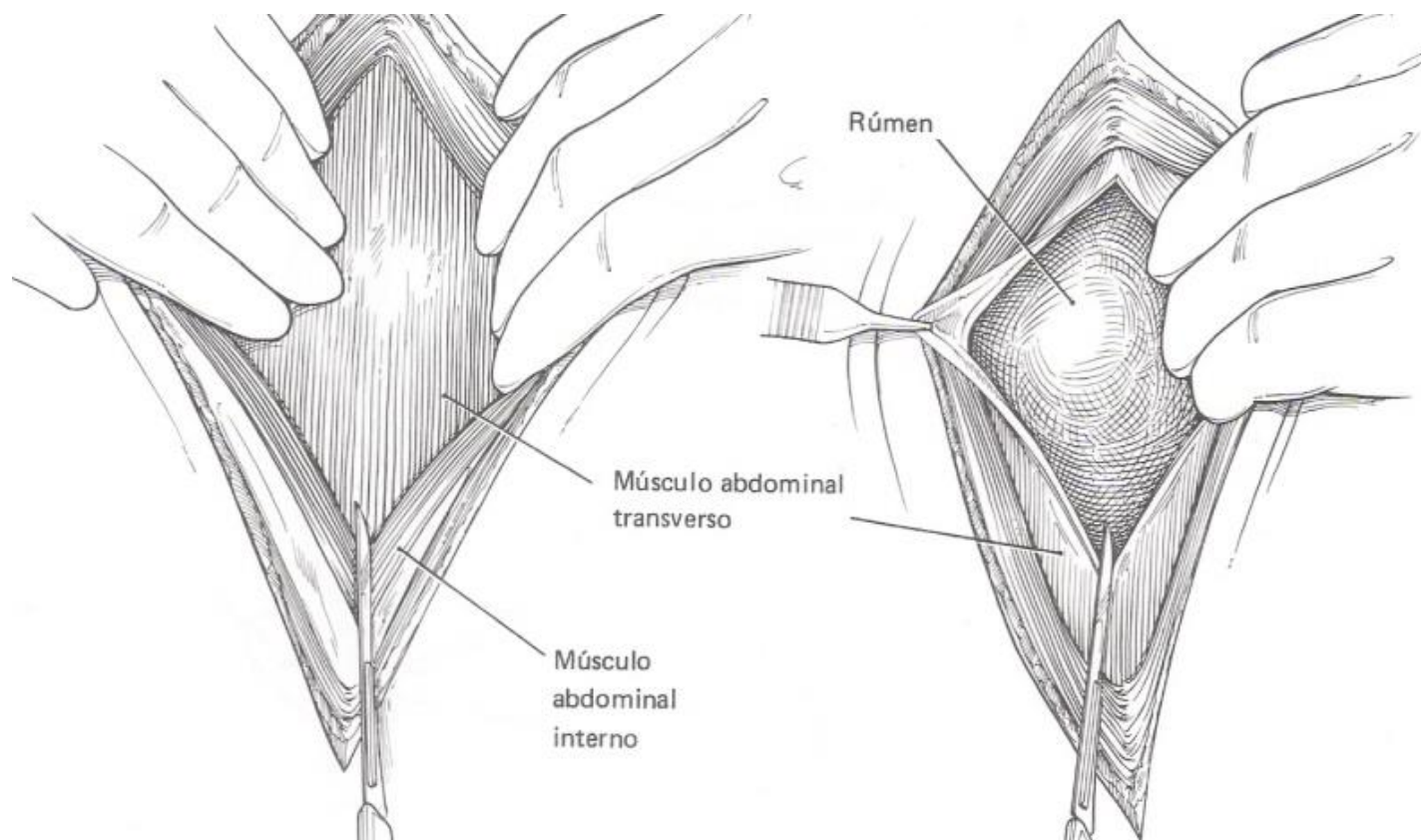
# LAPAROTOMIA PELO FLANCO ESQUERDO RUMENOTOMIA



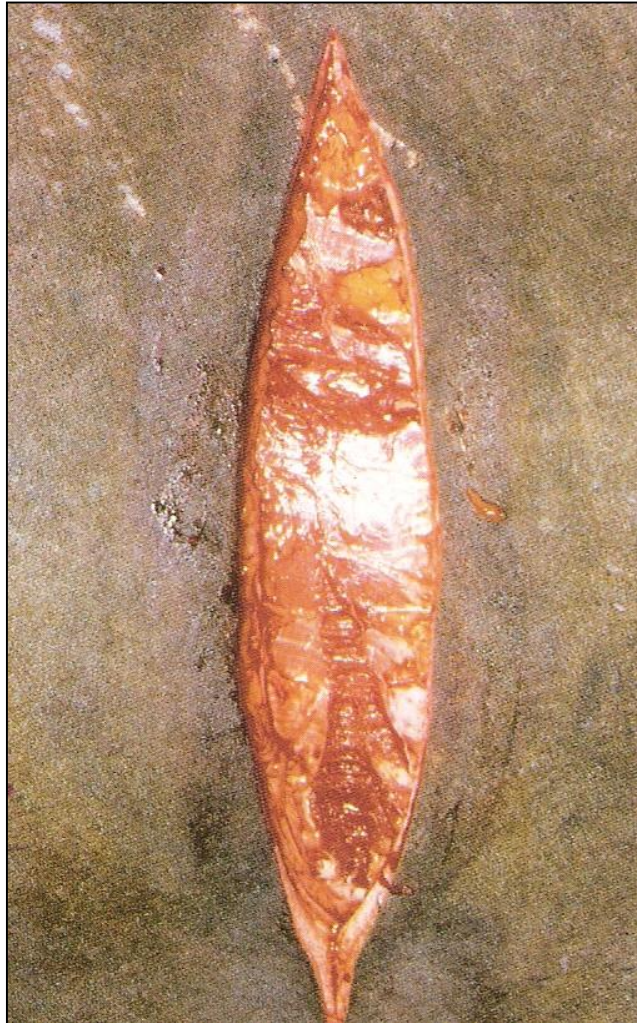# LAPAROTOMIA PELO FLANCO ESQUERDO RUMENOTOMIA



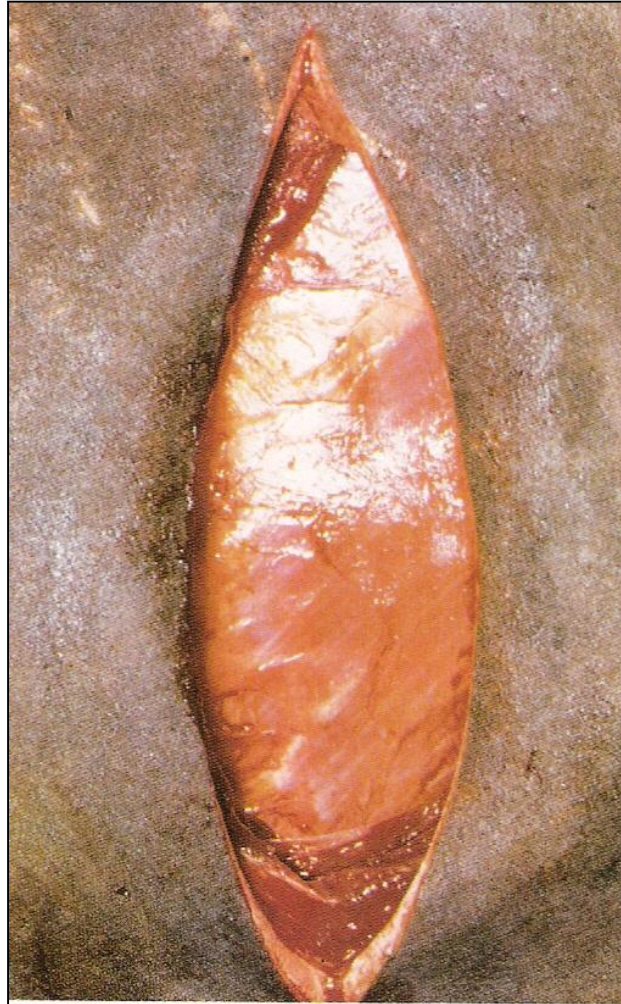# LAPAROTOMIA PELO FLANCO ESQUERDO RUMENOTOMIA



# LAPAROTOMIA PELO FLANCO ESQUERDO RUMENOTOMIA

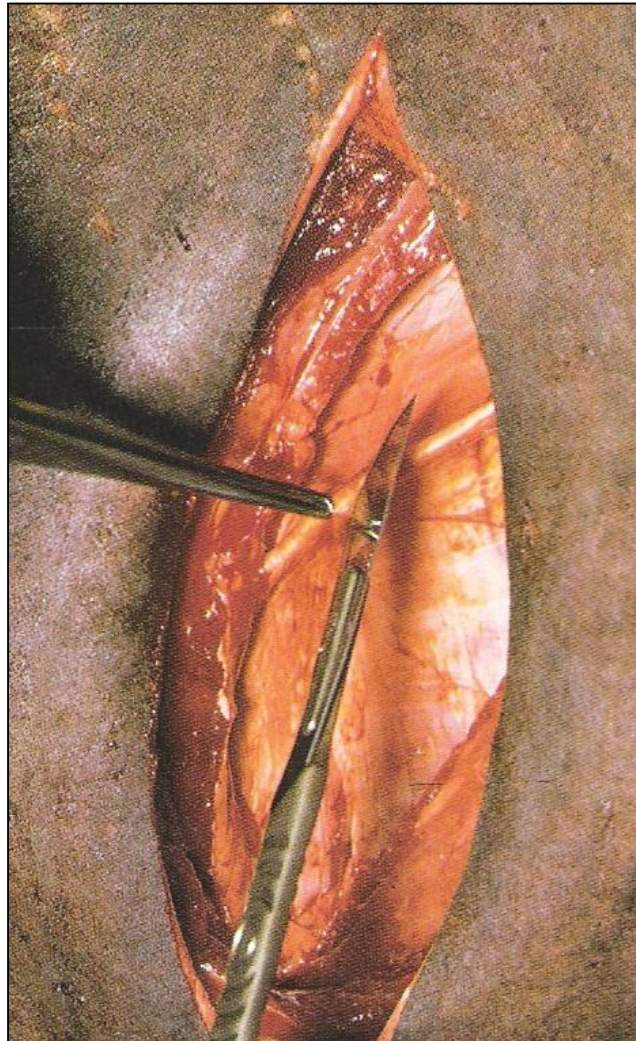


# LAPAROTOMIA PELO FLANCO ESQUERDO RUMENOTOMIA

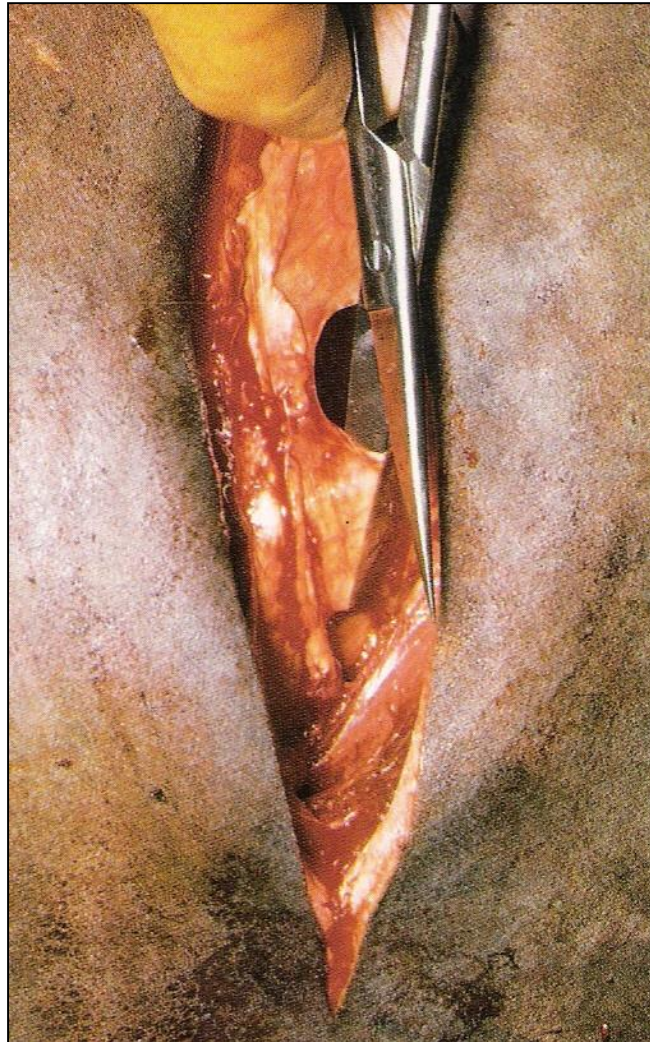




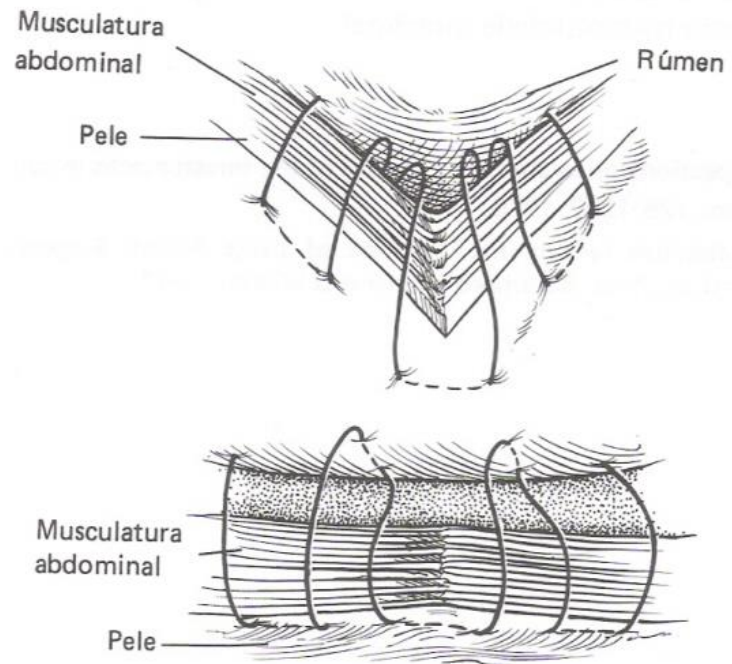
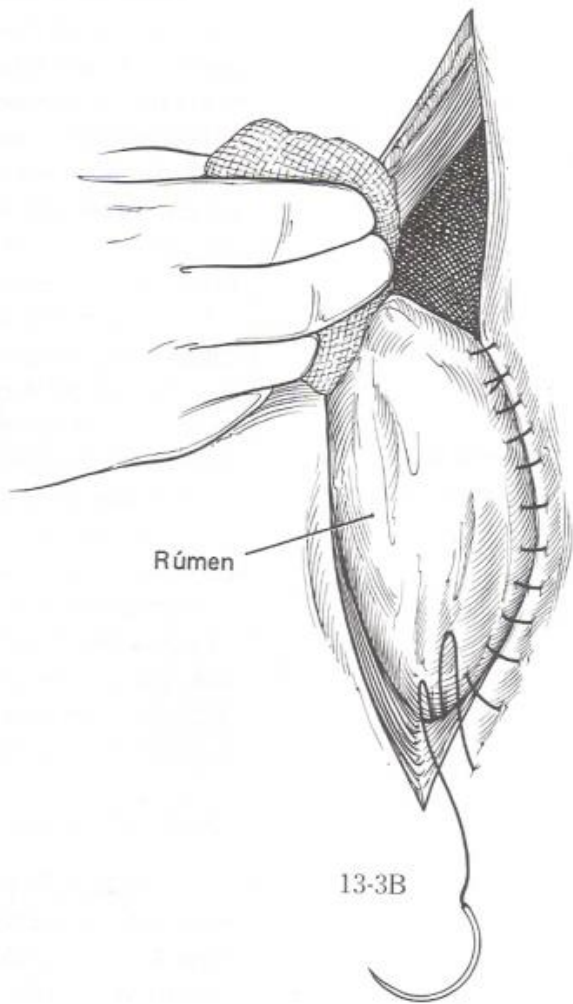
# LAPAROTOMIA PELO FLANCO ESQUERDO RUMENOTOMIA



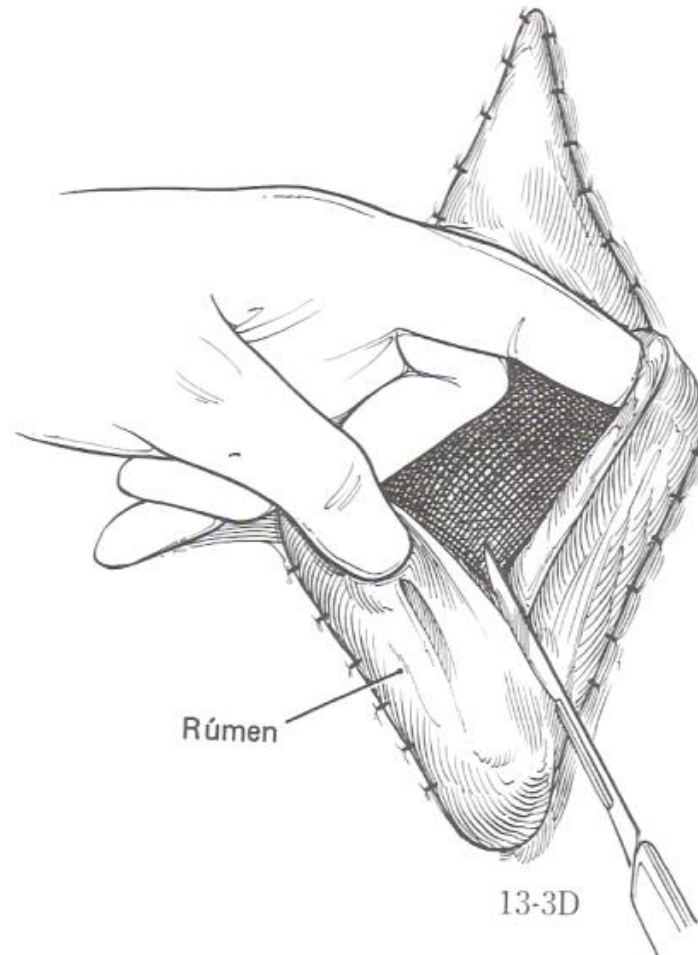
# LAPAROTOMIA PELO FLANCO ESQUERDO RUMENOTOMIA



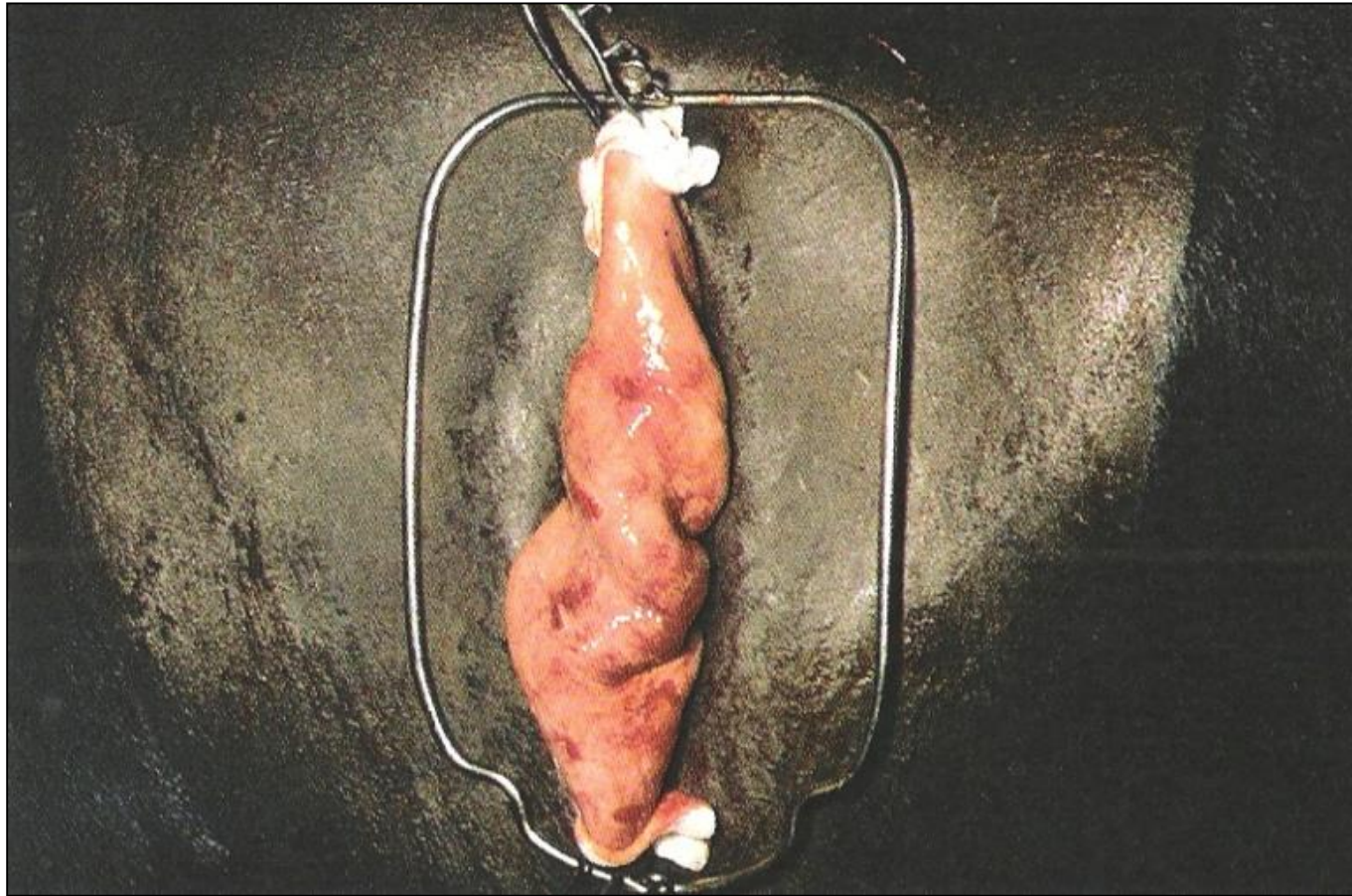
# LAPAROTOMIA PELO FLANCO ESQUERDO RUMENOTOMIA



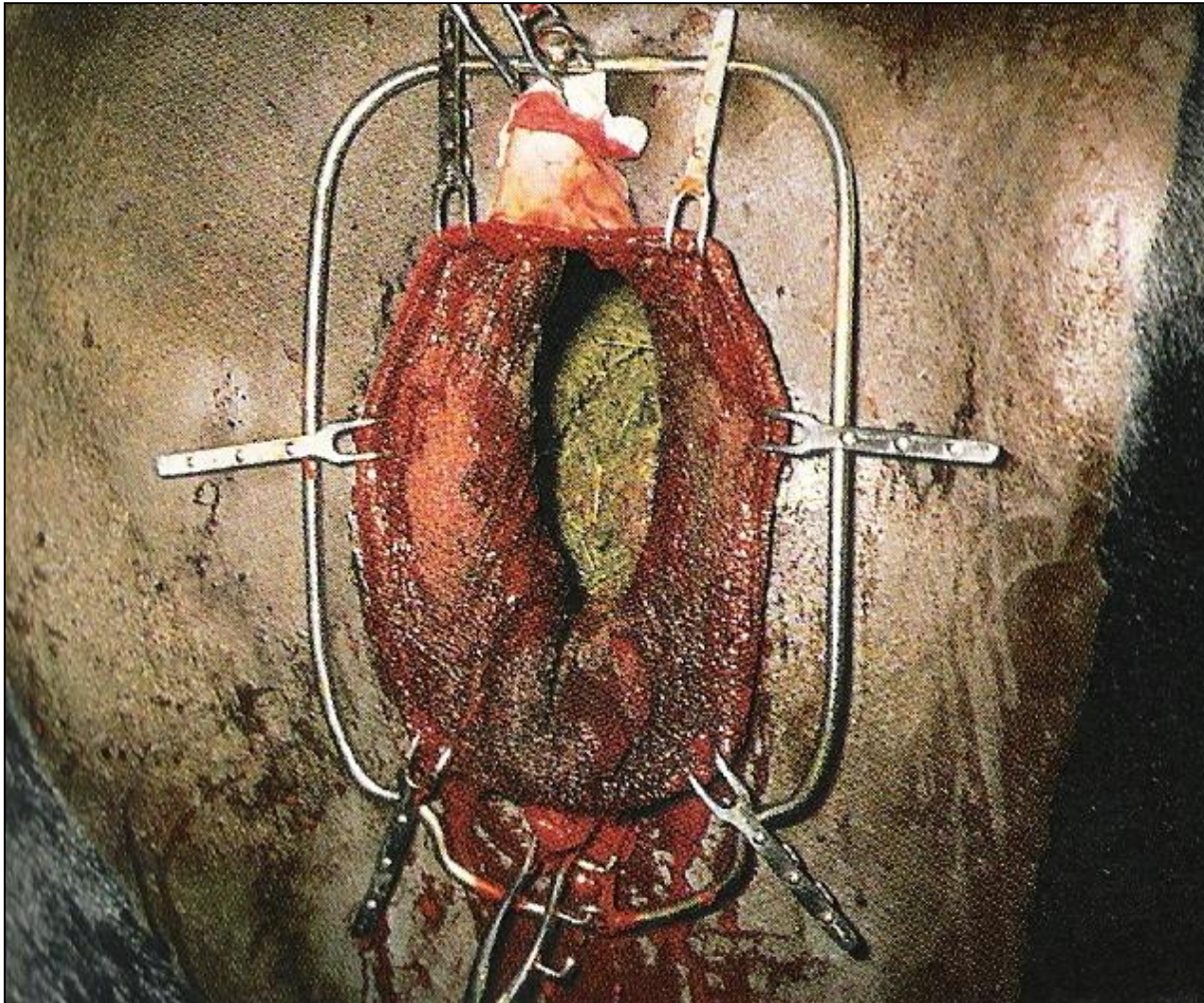
# LAPAROTOMIA PELO FLANCO ESQUERDO RUMENOTOMIA



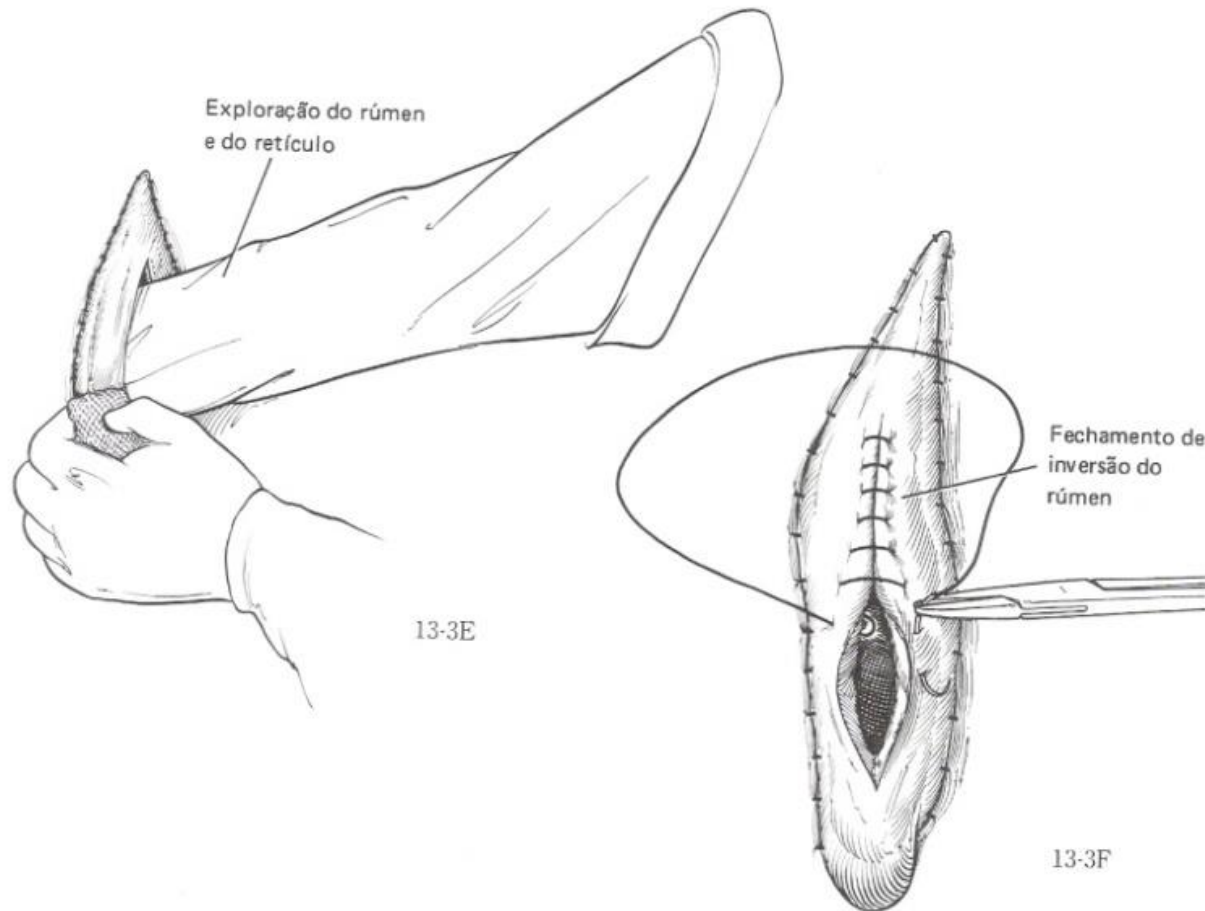
# LAPAROTOMIA PELO FLANCO ESQUERDO RUMENOTOMIA



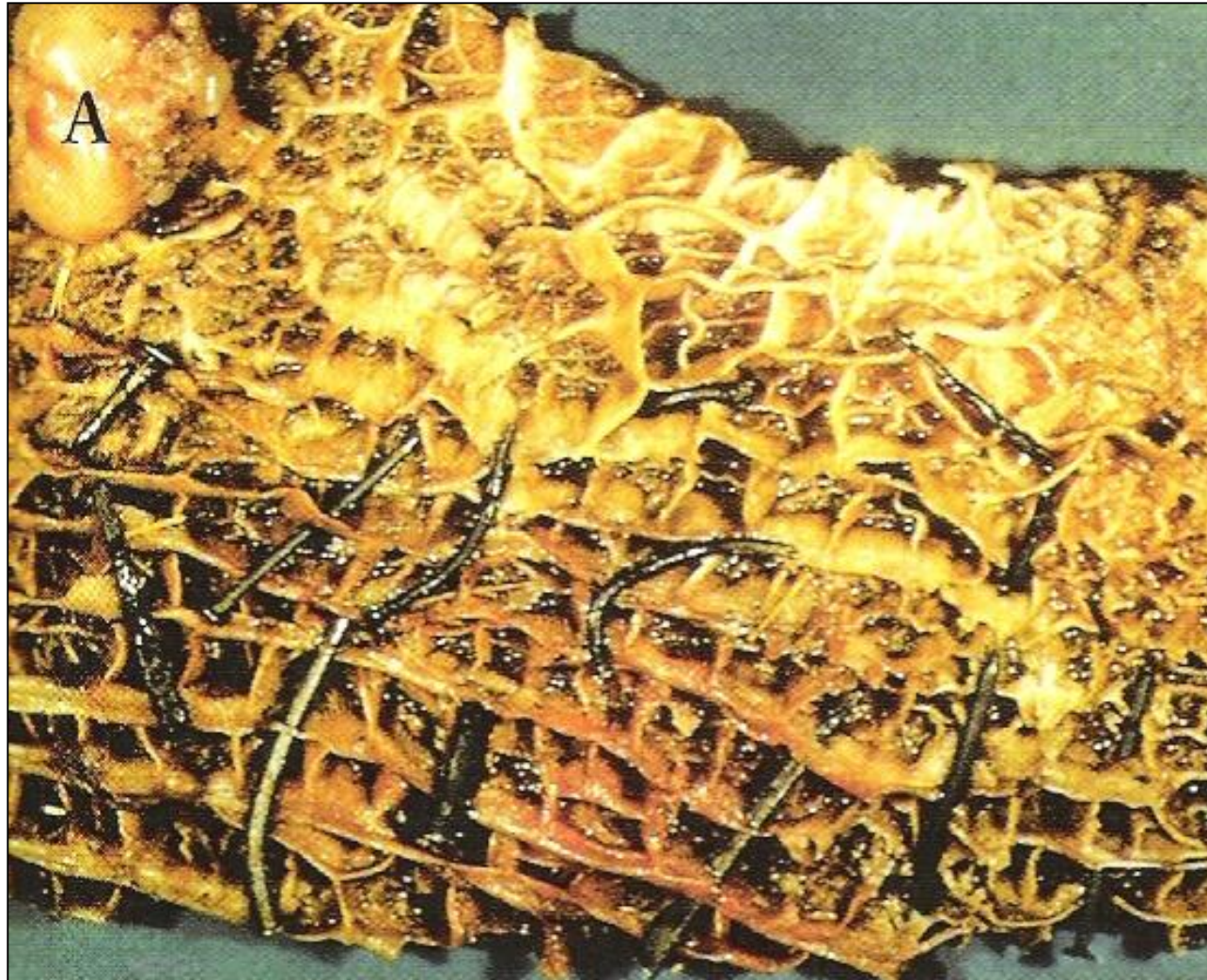# LAPAROTOMIA PELO FLANCO ESQUERDO RUMENOTOMIA



# LAPAROTOMIA PELO FLANCO ESQUERDO RUMENOTOMIA

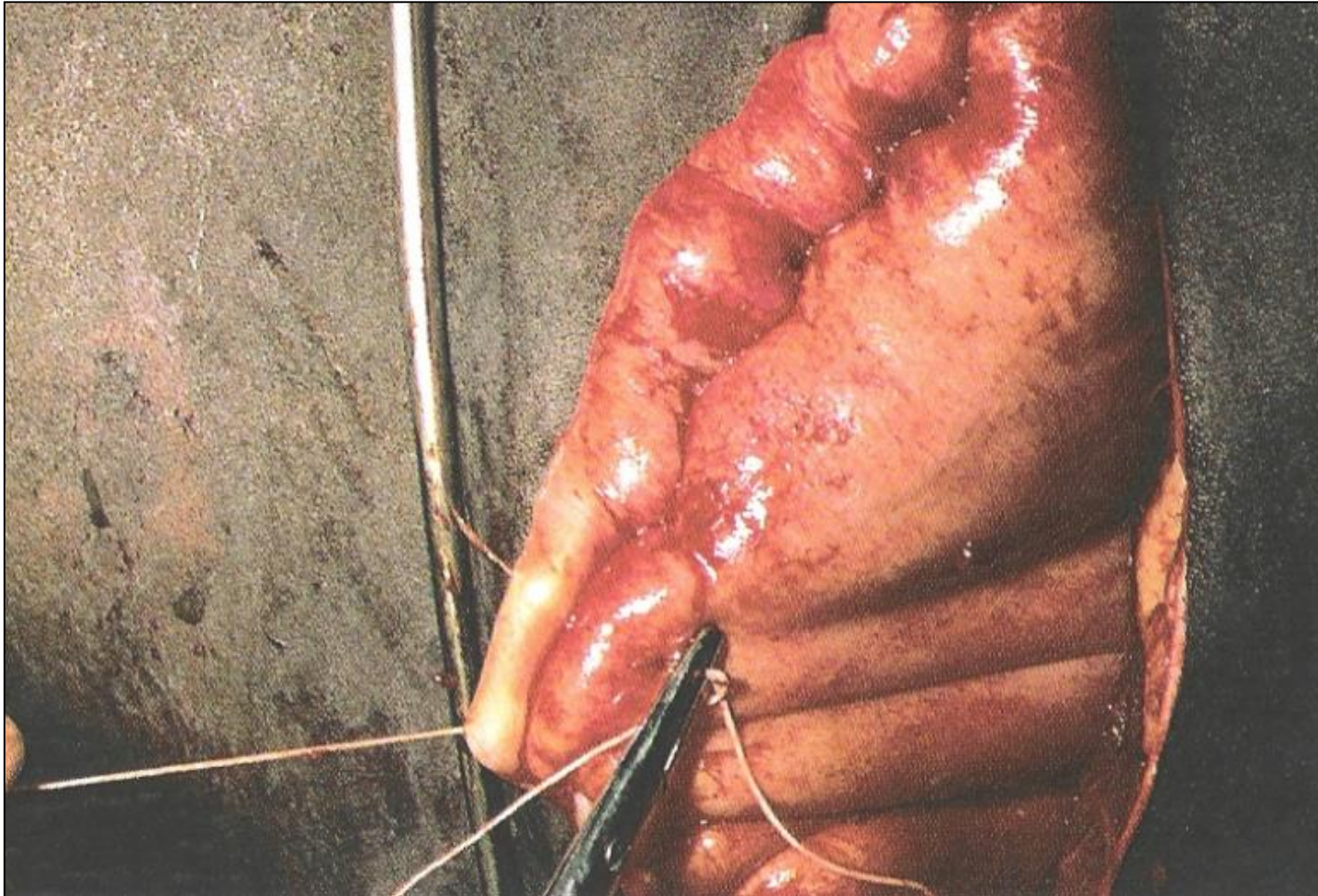

# LAPAROTOMIA PELO FLANCO ESQUERDO RUMENOTOMIA

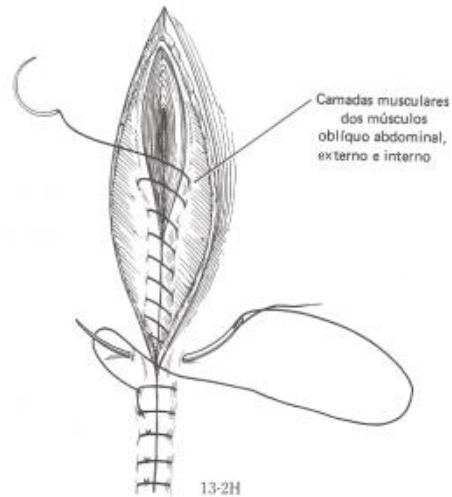
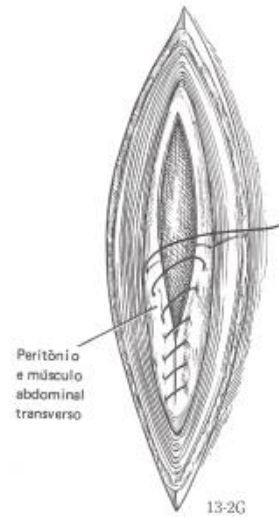
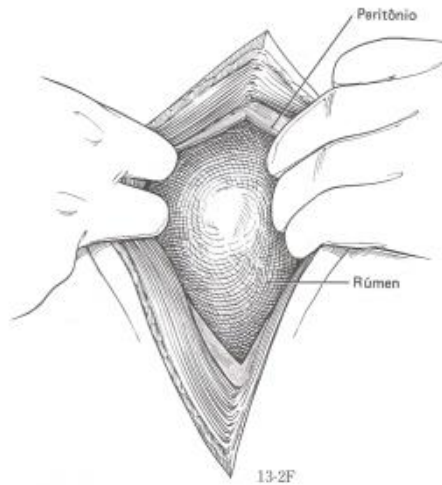




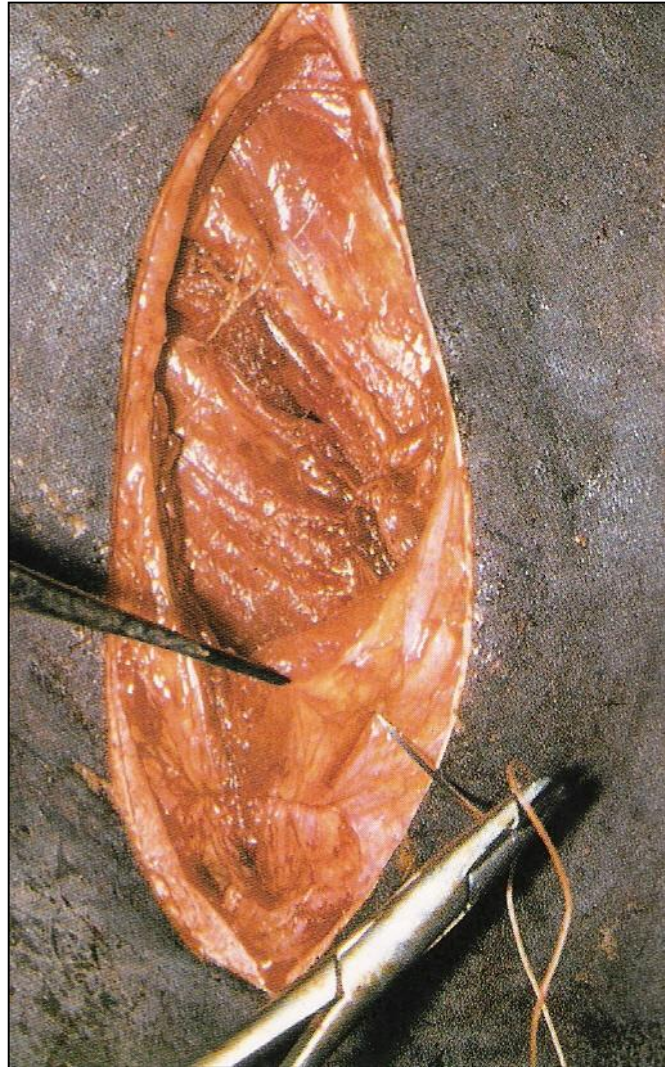# LAPAROTOMIA PELO FLANCO ESQUERDO RUMENOTOMIA



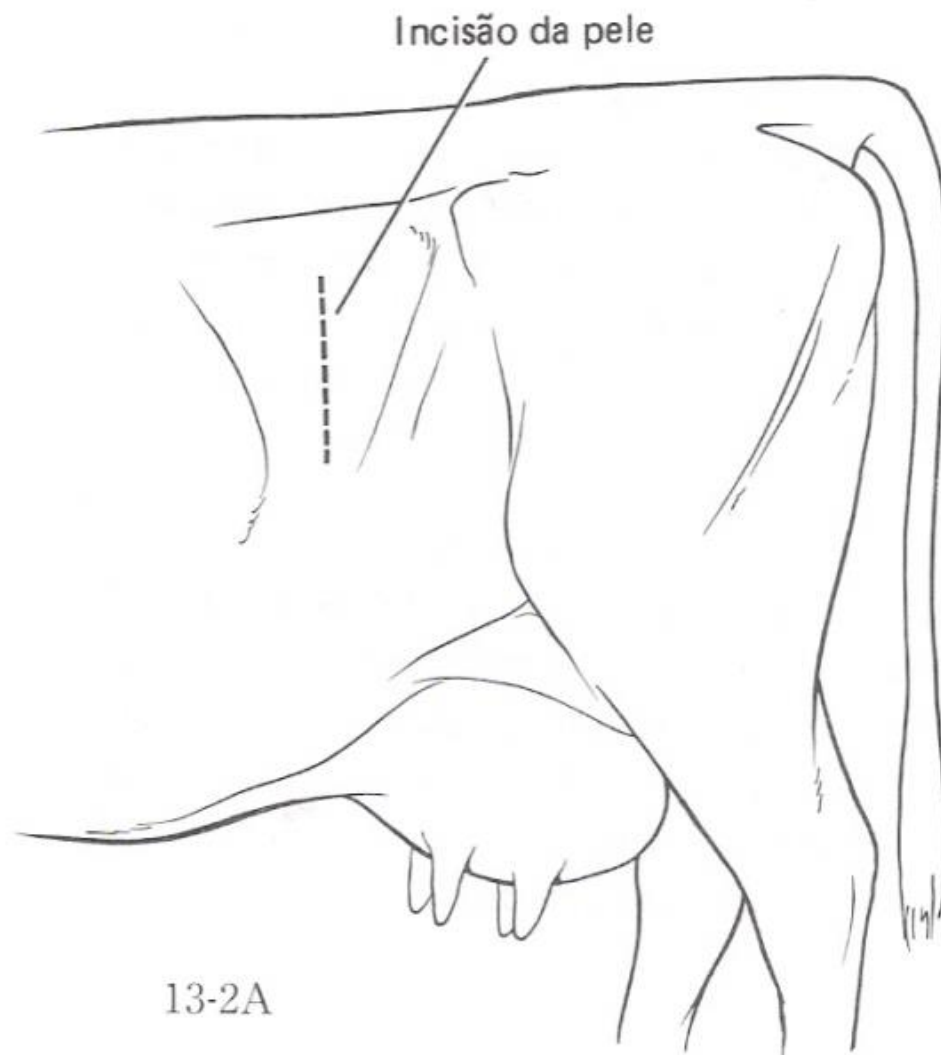
# LAPAROTOMIA PELO FLANCO ESQUERDO RUMENOTOMIA



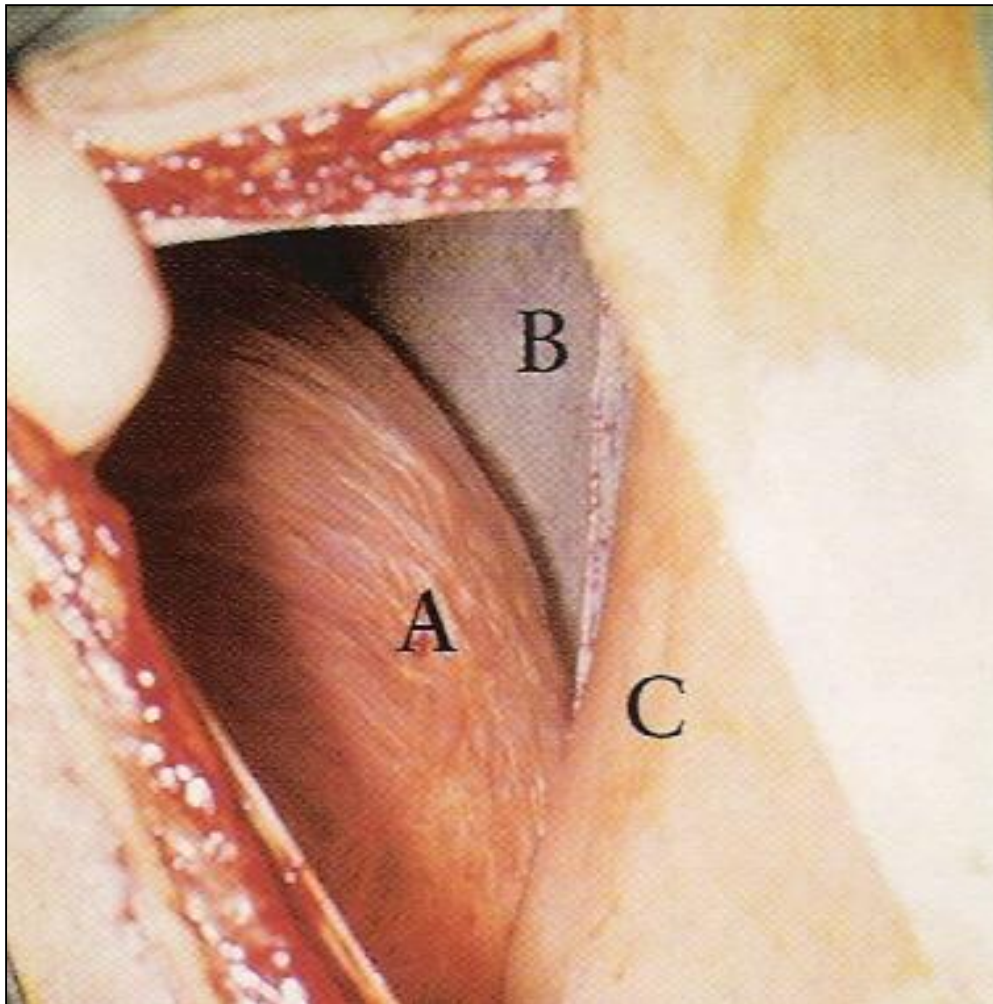
# LAPAROTOMIA PELO FLANCO ESQUERDO RUMENOTOMIA



# ABOMASOPEXIA PELO FLANCO ESQUERDO



# ABOMASOPEXIA PELO FLANCO ESQUERDO



# ABOMASOPEXIA PELO FLANCO ESQUERDO

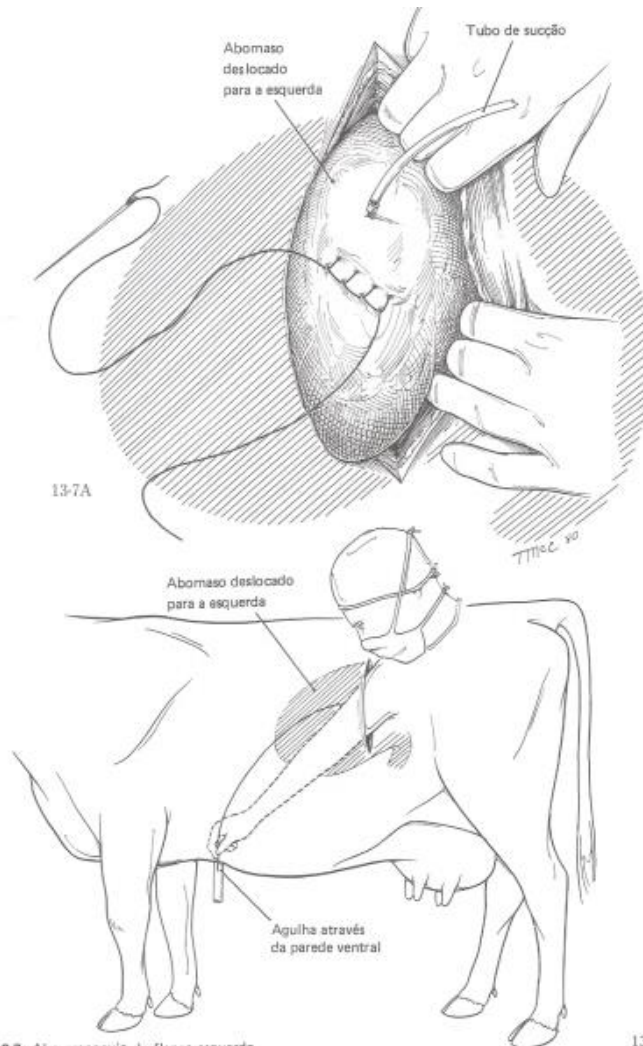
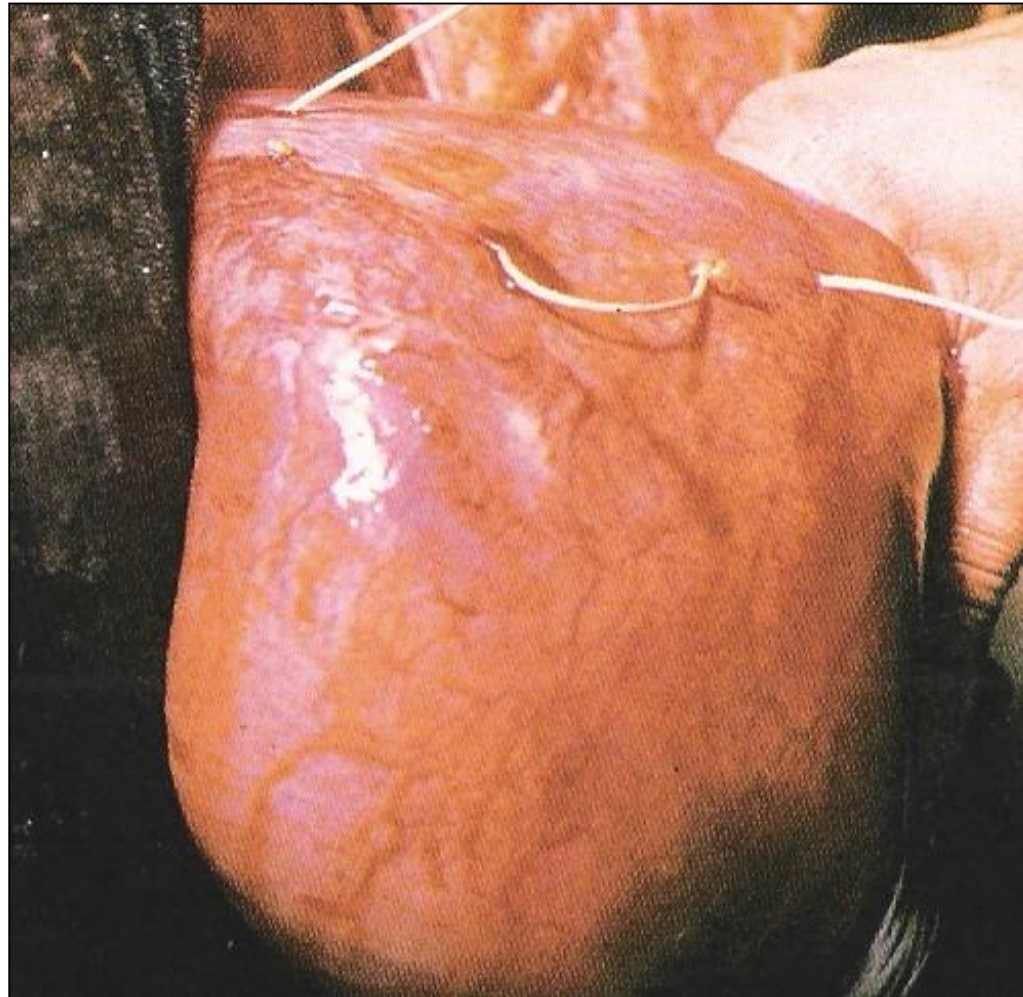
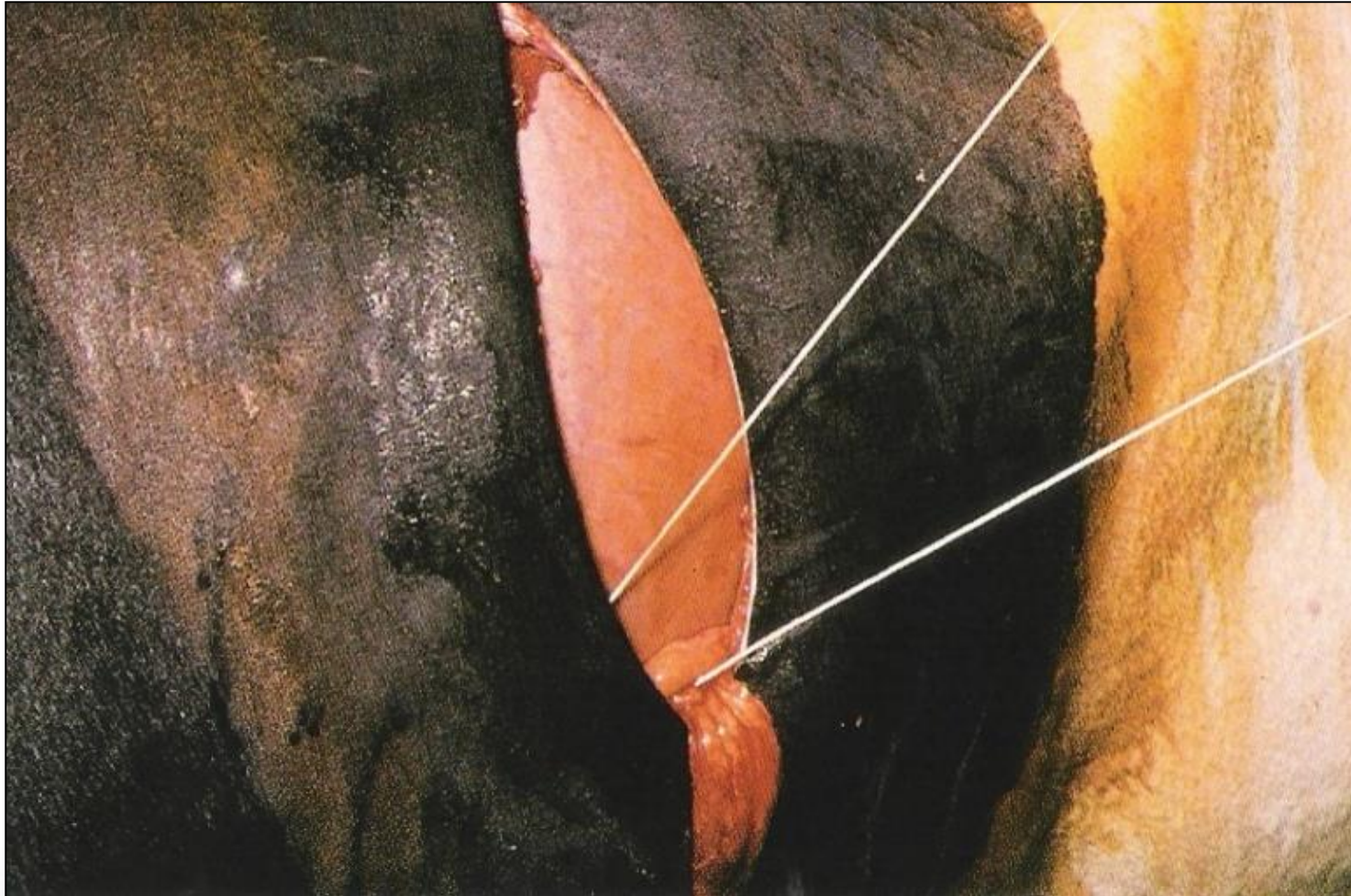


Fig. 13-7. Abomasopexia do flanco esquerdo.

# ABOMASOPEXIA PELO FLANCO ESQUERDO



# ABOMASOPEXIA PELO FLANCO ESQUERDO

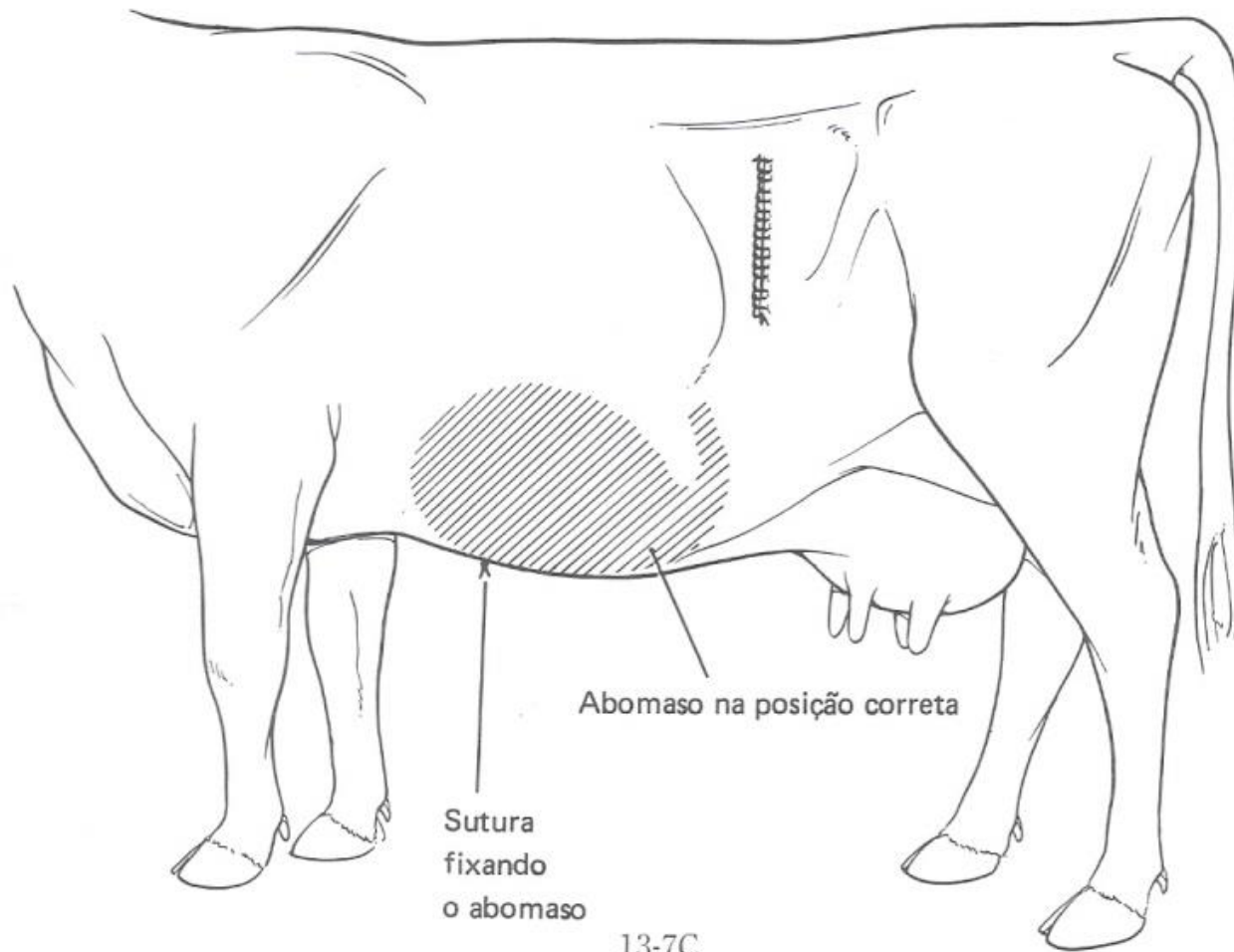




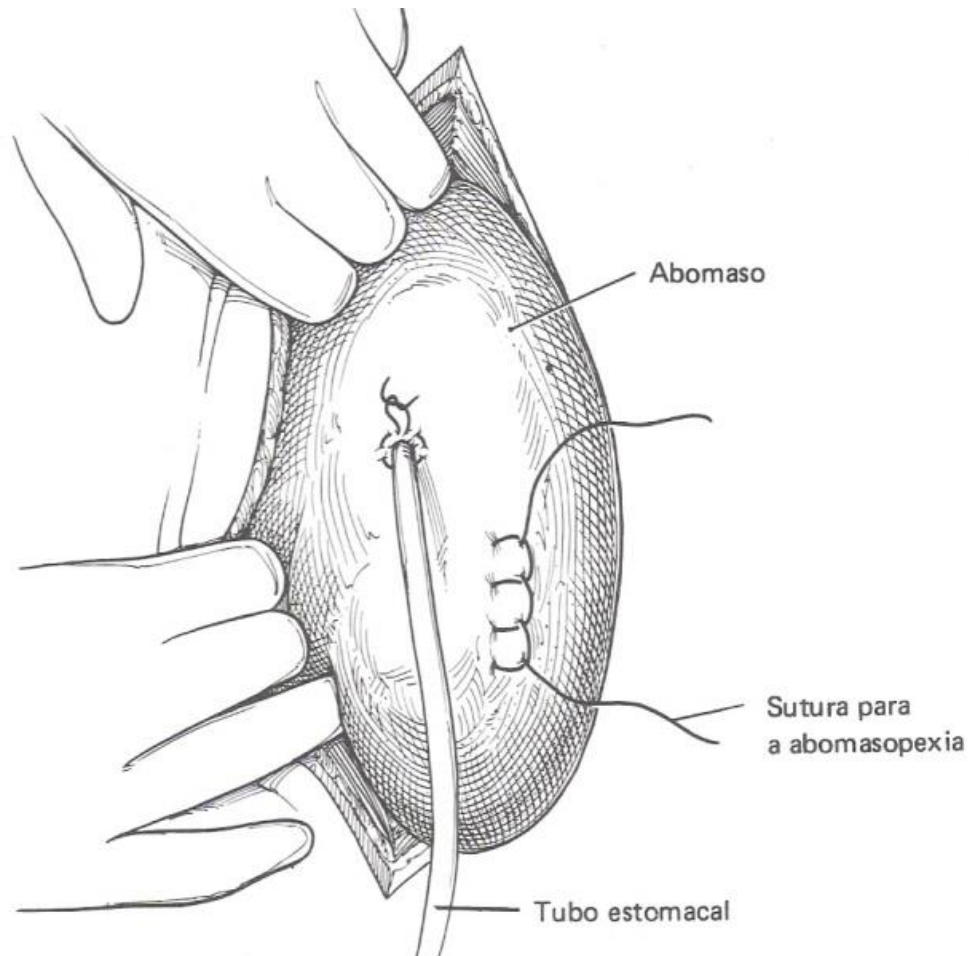
# ABOMASOPEXIA PELO FLANCO ESQUERDO



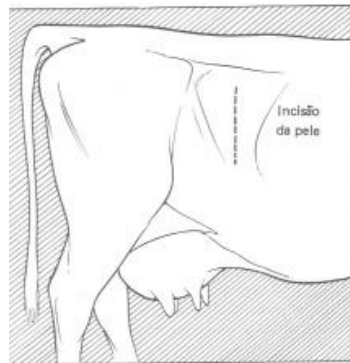# ABOMASOPEXIA PELO FLANCO ESQUERDO



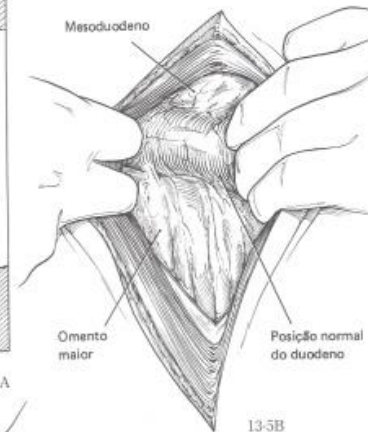
# ABOMASOPEXIA / OMENTOPEXIA PELO FLANCO DIREITO



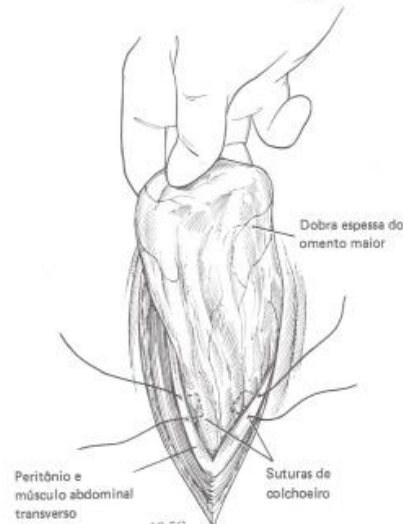# ABOMASOPEXIA / OMENTOPEXIA PELO FLANCO DIREITO



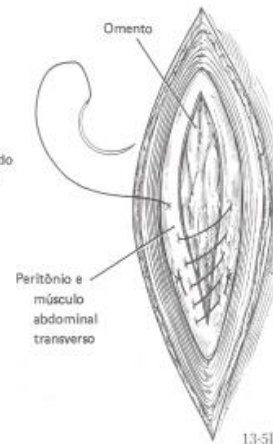
13-5A



13-5B



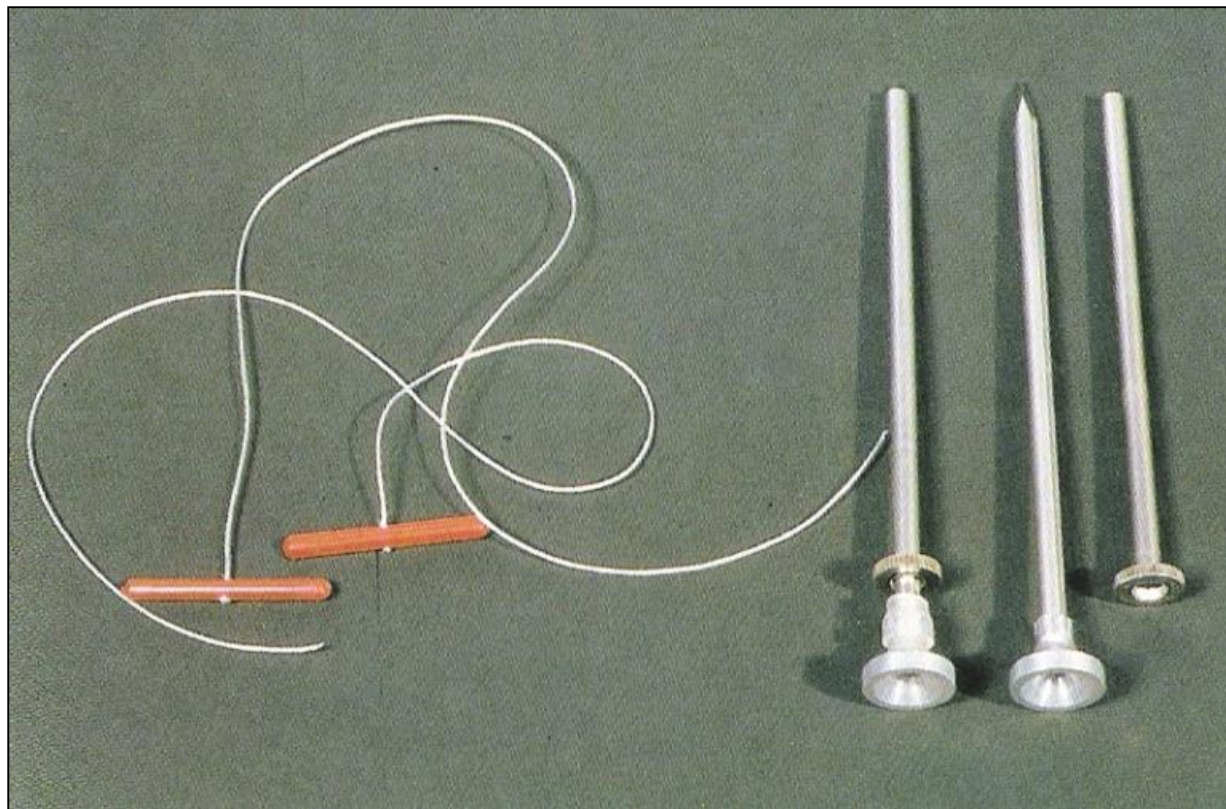
13-5C



13-5D

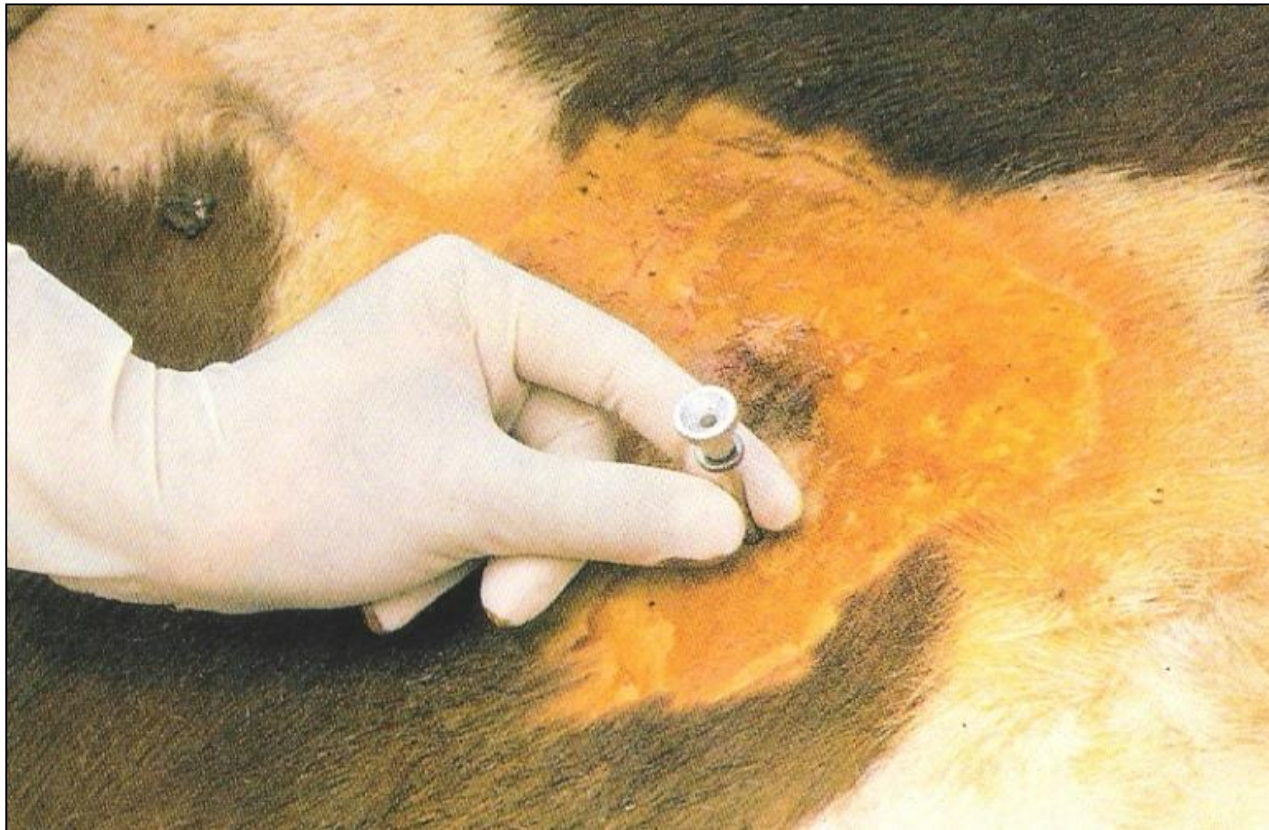# ABOMASOPEXIA

Técnica fechada



# ABOMASOPEXIA

Técnica fechada




# ABOMASOPEXIA

Técnica fechada



# ABOMASOPEXIA

Técnica fechada





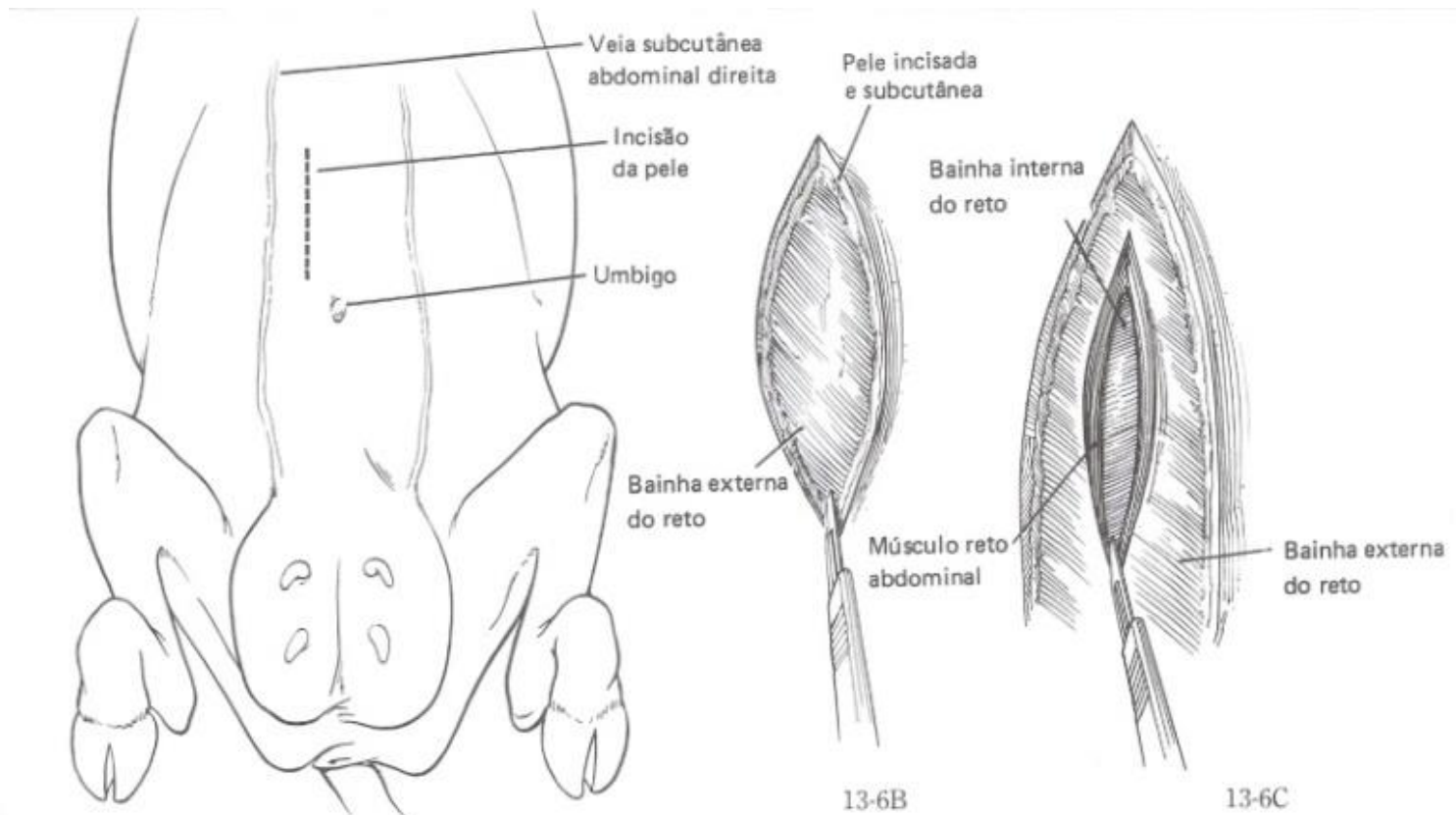
# ABOMASOPEXIA

Técnica fechada



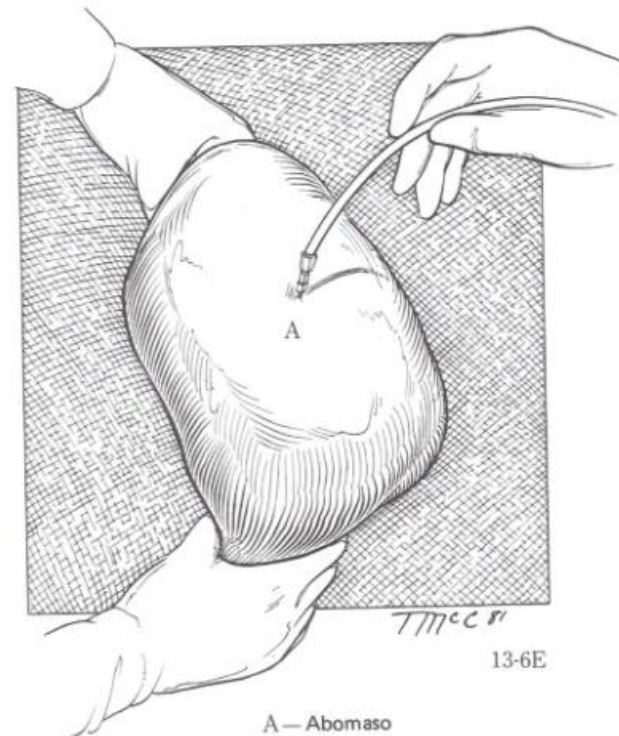
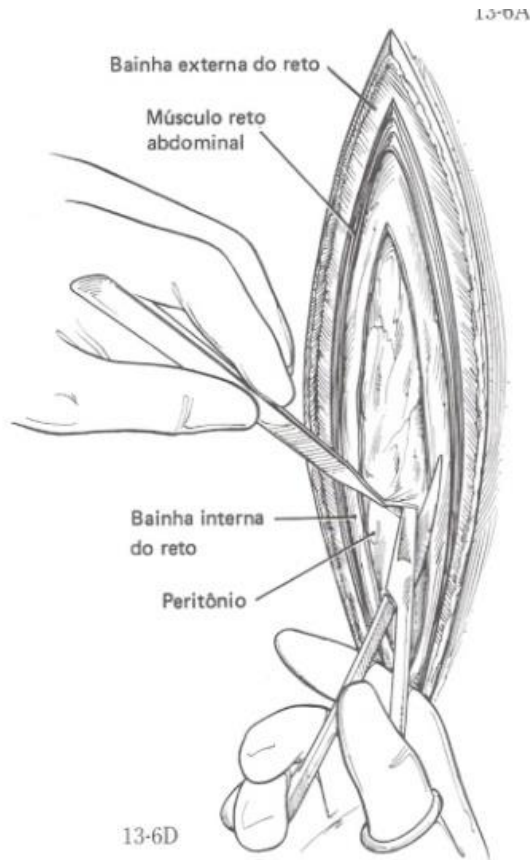
# ABOMASOPEXIA

## Laparotomia paramediana



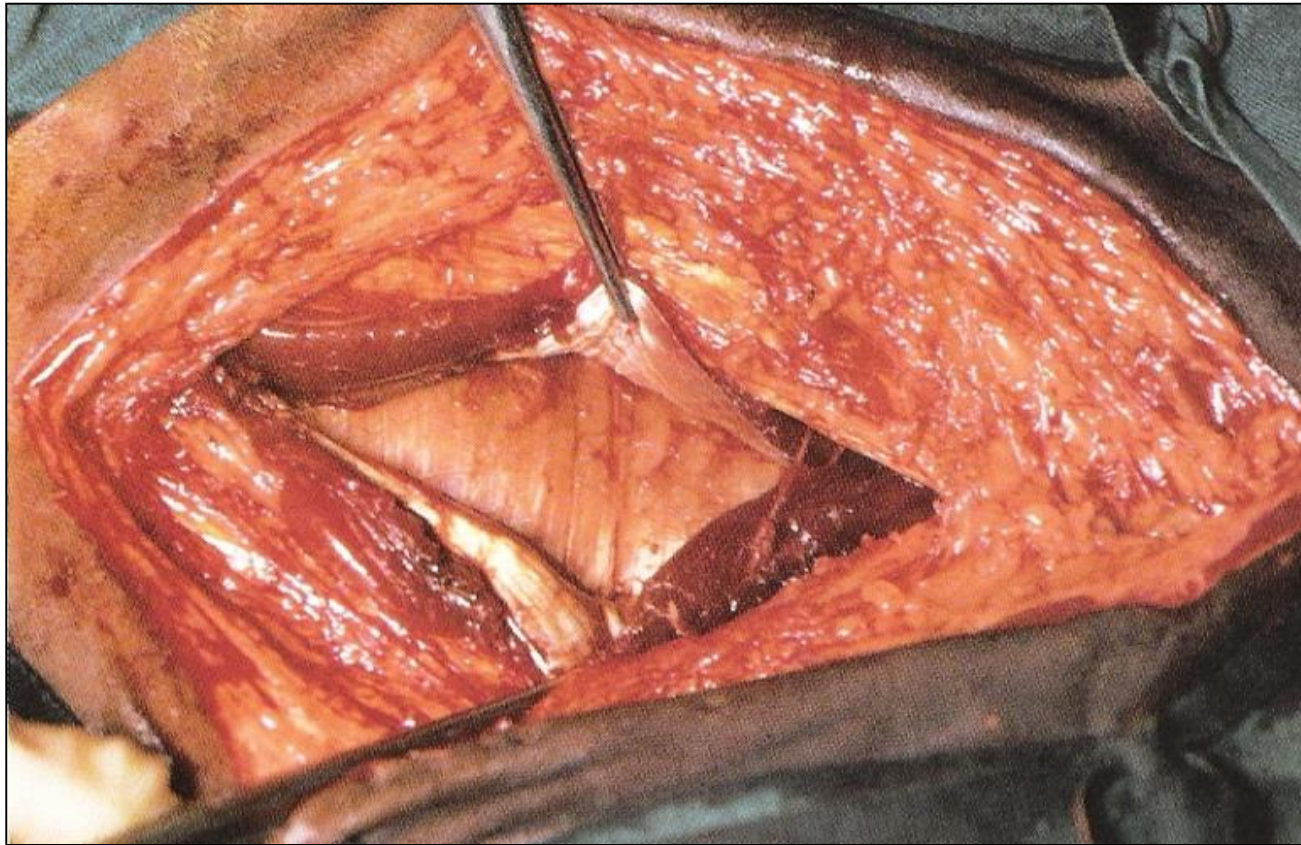
# ABOMASOPEXIA

## Laparotomia paramediana



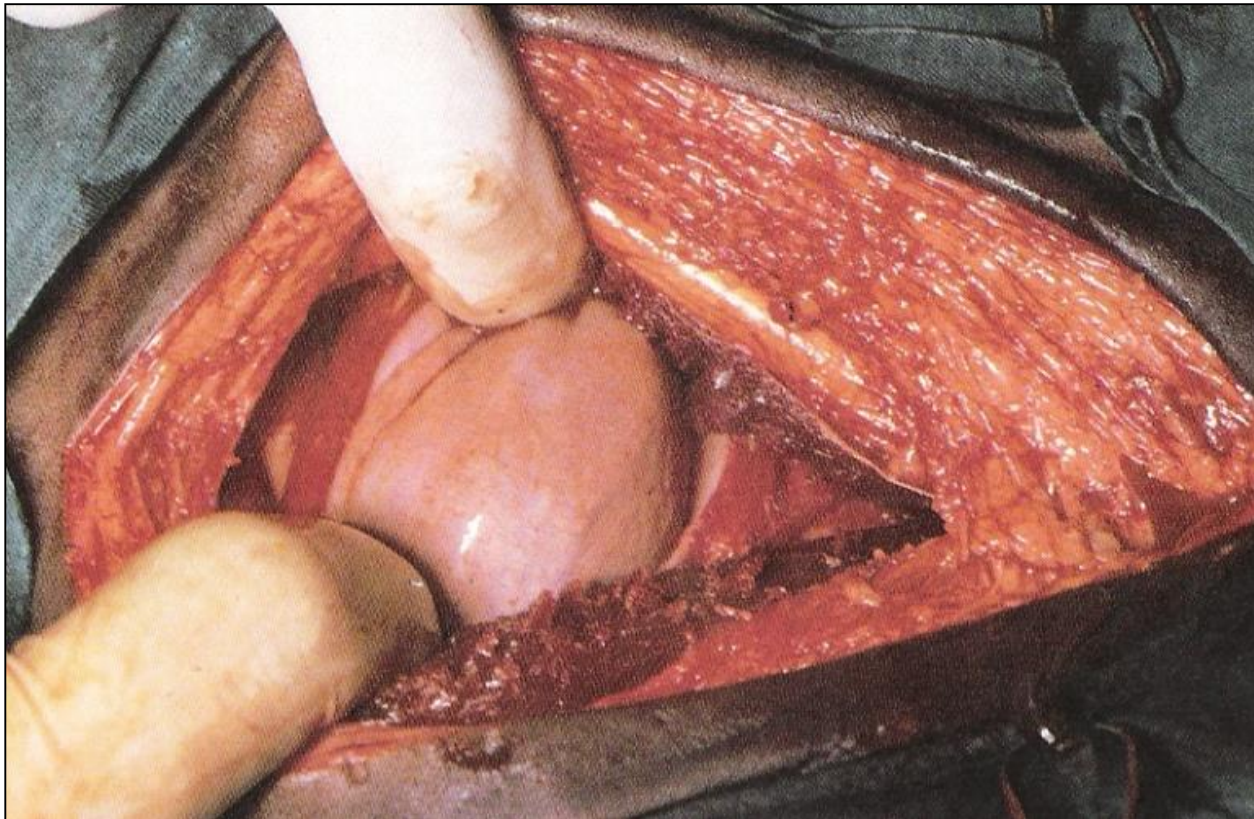
# ABOMASOPEXIA

Laparotomia paramediana



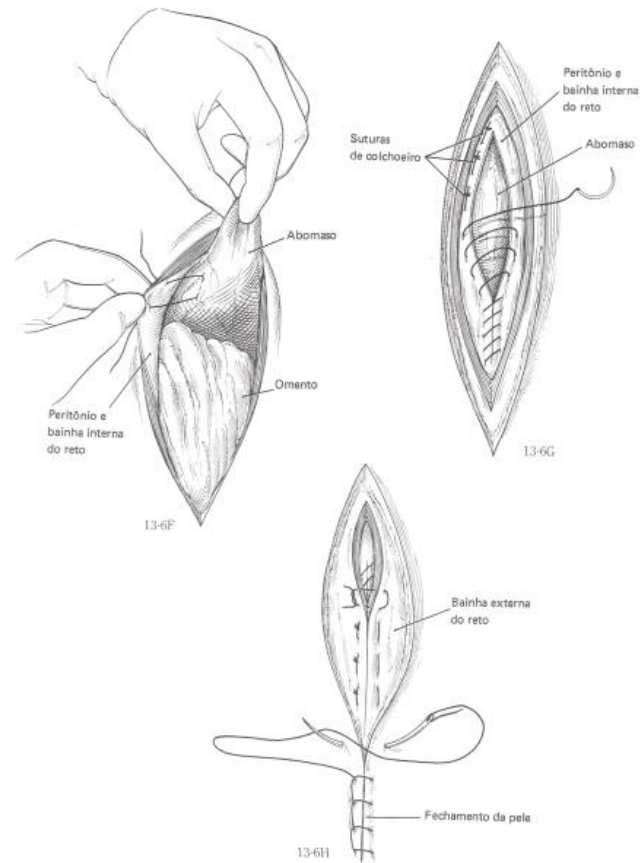
# ABOMASOPEXIA

Laparotomia paramediana



# ABOMASOPEXIA

## Laparotomia paramediana



# ABOMASOPEXIA

Laparotomia paramediana

