

Hypertrophic Pyloric Stenosis

Takao Fujimoto

INTRODUCTION

Infantile hypertrophic pyloric stenosis (IHPS) is a common surgical condition encountered in early infancy, occurring in 2–3 per 1,000 live births. It is characterized by hypertrophy of the circular muscle, causing pyloric narrowing and elongation. The incidence of disease varies widely with geographic location, season and ethnic origin. Boys are affected four times more than girls.

There is evidence of a genetic predisposition to the development of this condition. Siblings of patients with IHPS are 15 times more likely to suffer the condition than children who have no family history of IHPS. The cause of hypertrophic circular muscle of pylorus is still obscure and various hypotheses have been advocated including abnormal peptidergic innervation, abnormality of nitrergic innervation, abnormalities of extracellular matrix proteins, abnormalities of smooth-muscle cells and abnormalities of intestinal hormones.

Typical clinical presentation of infants with IHPS is non-bilious vomiting usually occurring at 2–8 weeks of age. Initially there is only regurgitation of feeds, but over several days vomiting progresses to be characteristically projectile. It occasionally contains altered blood in emesis appearing as brownish discoloration or coffee-grounds as a result of gastritis and/or oesophagitis.

The diagnosis is usually based on the clinical history and physical examination of a “palpable pyloric tumour”. Ultrasonographic scanning of abdomen re-

veals typical hypoechoic ring with echogenic centre of increased muscle thickness. A contrast meal may be required in difficult and/or complicated presentation and shows characteristic narrowed elongated pyloric canal.

Persistent non-bilious vomiting in these patients results in chloride depletion, metabolic alkalosis and dehydration. Haematological and biochemical analysis should be undertaken. Any fluid and electrolyte and acid base imbalance should be corrected prior to surgery. Oral feeding should be discontinued and a nasogastric tube inserted prior to surgery to keep the stomach empty. The operation for pyloric stenosis is not an emergency and should never be undertaken until serum electrolytes have returned to normal.

Ramstedt’s pyloromyotomy is the universally accepted operation for pyloric stenosis. A 3-cm transverse right upper quadrant, muscle-splitting incision provides excellent exposure and direct access to the pylorus with minimal retraction. Another incision that is commonly used is a supra-umbilical fold incision. Although supra-umbilical skin-fold incision has a better cosmetic result, it has been argued that delivery of the pyloric tumour can be difficult and time consuming and may damage the serosa of the stomach or duodenum by tearing. Recently, laparoscopic pyloromyotomy has been advocated. The main advantage of the laparoscopic pyloromyotomy is the superior cosmetic result.

Figure 18.1

A nasogastric tube must be placed before the induction of anaesthesia if the tube was not placed pre-operatively. And if the barium meal study has been carried out prior to surgery, it may be necessary to remove the residual barium meal by gastric aspiration and irrigation. The patient is placed in the supine position. After the induction of anaesthesia and endotracheal intubation, careful abdominal palpation will usually identify the site of the pyloric tumour. A 2.5- to 3-cm long transverse incision is made lateral to the lateral border of the rectus muscle. The incision is deepened through the subcutaneous tissue and the

underlying external oblique, internal oblique and transverse muscles are split. The peritoneum is opened transversely in the line of the incision.

When supra-umbilical skin fold incision is employed, a circumumbilical incision is made through about two-thirds of the circumference of the umbilicus. The skin is undermined in a cephalad direction above the umbilical ring and the linea alba is exposed. The linea alba is divided longitudinally in the midline from the umbilical ring to as far cephalad as necessary to allow easy delivery of the pyloric tumour.

Figure 18.2

The stomach is identified and is grasped proximal to the pylorus with non-crushing clamp and brought through the wound. Then, the greater curvature of the stomach can be held in a moist gauze swab, and with traction inferiorly and laterally, the pylorus can

be delivered through the wound. Grasping the duodenum or pyloric tumour directly by forceps often results in serosal laceration, bleeding or perforation, therefore should be avoided.

Figure 18.1

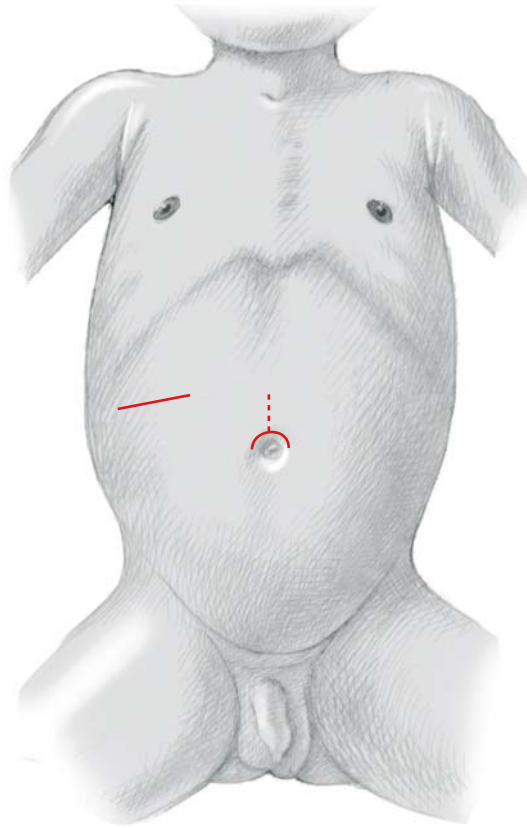


Figure 18.2

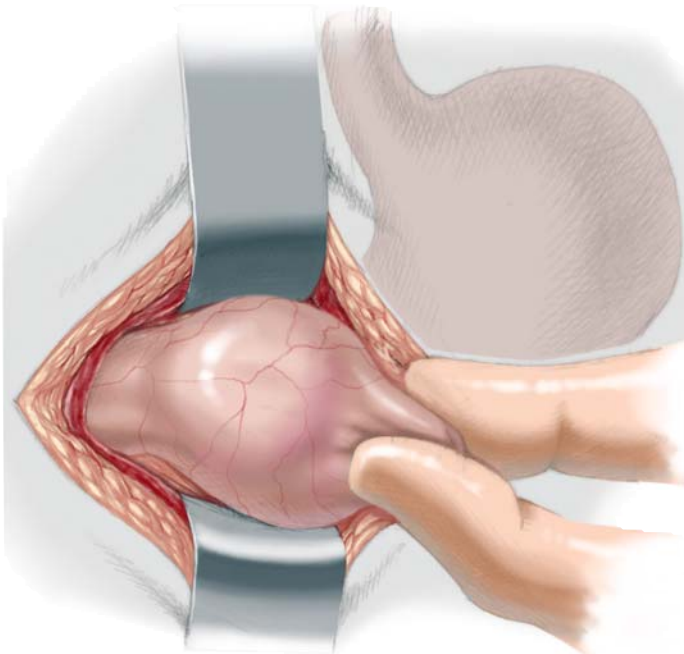


Figure 18.3

The pylorus is held with surgeon's thumb and forefinger to stabilize and assess the extent of hypertrophied muscle. A seromuscular incision is made over the avascular area of pylorus with a scalpel, commencing 1~2 mm proximal to the pre-pyloric vein

along the gastric antrum. The incision should go far enough onto the gastric antrum at least 0.5~1.0 cm from the antropyloric junction where the muscle is thin.

Figure 18.4, 18.5

The scalpel handle is used to further split the hypertrophied muscle down to the submucosal layer. Then pyloric muscle is spread widely. Spreader is placed at the midpoint of incision line and muscle is spread perpendicularly and spreading must be continued proximally and distally. Gentle spreading is required to obtain a complete myotomy. Mucosal tears are most common at the pyloroduodenal junction because of the attempt to split all remaining muscle fibres. In order to reduce the risk of mucosal tear, care should be taken when spreading pyloric muscle fibres at the duodenal end.

Loose prolapsing of intact mucosa is evidence of a satisfactory myotomy. To test the mucosal injury, the stomach is inflated through the nasogastric tube, and passage of air through the pylorus to duodenum is confirmed. Then the pylorus is dropped back into the abdomen. Bleeding from the myotomy edge or submucosal surface is frequently seen; however, it is generally venous and always stops after returning the pylorus to the abdominal cavity. Posterior rectus fascia and peritoneum is approximated with a running 4/0 absorbable suture material and anterior fascia is closed with 5/0 absorbable suture material.

Figure 18.3

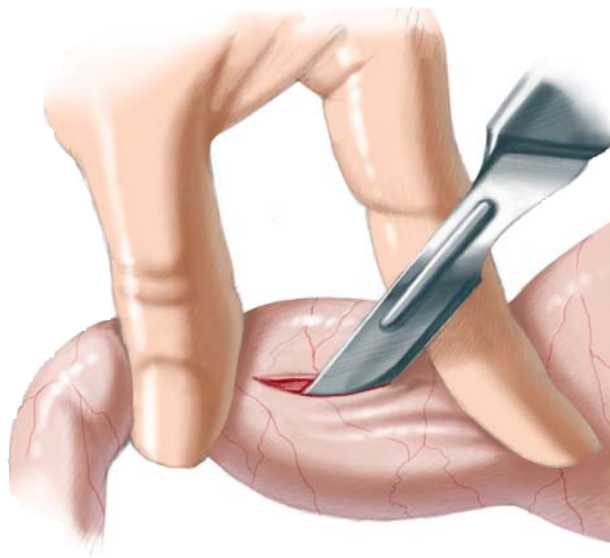


Figure 18.4

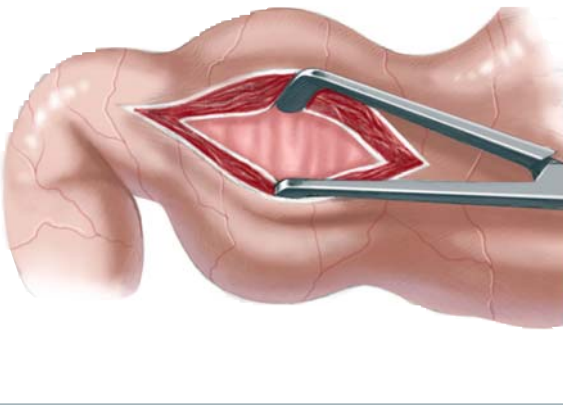


Figure 18.5

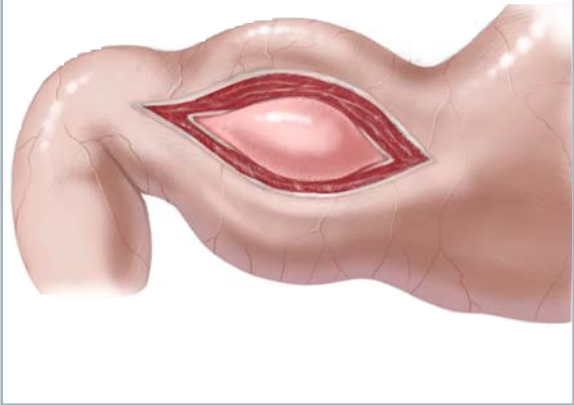


Figure 18.6

For the laparoscopic procedure the patient is placed in the supine position at the end of the operating table (or 90° to the anaesthesiologist). The video monitor is placed at the head of the table, and the surgeon stands at the end of the table with the assistant to the patient's right. The abdomen is scrubbed and draped in a sterile fashion. Attention must be paid to ensure the appropriate preparation of the umbilicus.

The access sites are injected with local anaesthetic (0.25% bupivacaine) with epinephrine, which is used to reduce the post-operative pain and reduce the risk of bleeding from the stab wound. The author prefers an open procedure for insertion of the primary port. A 4.0- to 5.0-mm curvilinear supra-umbilical incision is made and carried down to the peritoneal cavity. At the level of umbilical fascia, 4/0 absorbable suture material is placed circumferentially to anchor the port and to use for closure of the peritoneal cav-

ity after laparoscopic pyloromyotomy is completed. Intra-abdominal pressure is maintained at 8 mmHg, and insufflation rate is set at 0.5 l/min. In the right mid-clavicular line just below the costal margin (just above the liver edge), a no. 11 scalpel blade is used to make a 2- to 3-mm stab incision under direct vision. Also using the no. 11 scalpel blade, a second stab incision is made under direct vision, just below the costal margin in the left mid-clavicular line.

An atraumatic grasper is placed directly through the right upper quadrant stab wound and is used to retract the inferior border of the liver superiorly and expose the hypertrophic pylorus. A retractable myotomy knife (retractable arthrotomy knife or Endotome) is inserted directly through the left stab wound. Working ports are usually not necessary and instruments are directly introduced through these stab wounds.

Figure 18.6

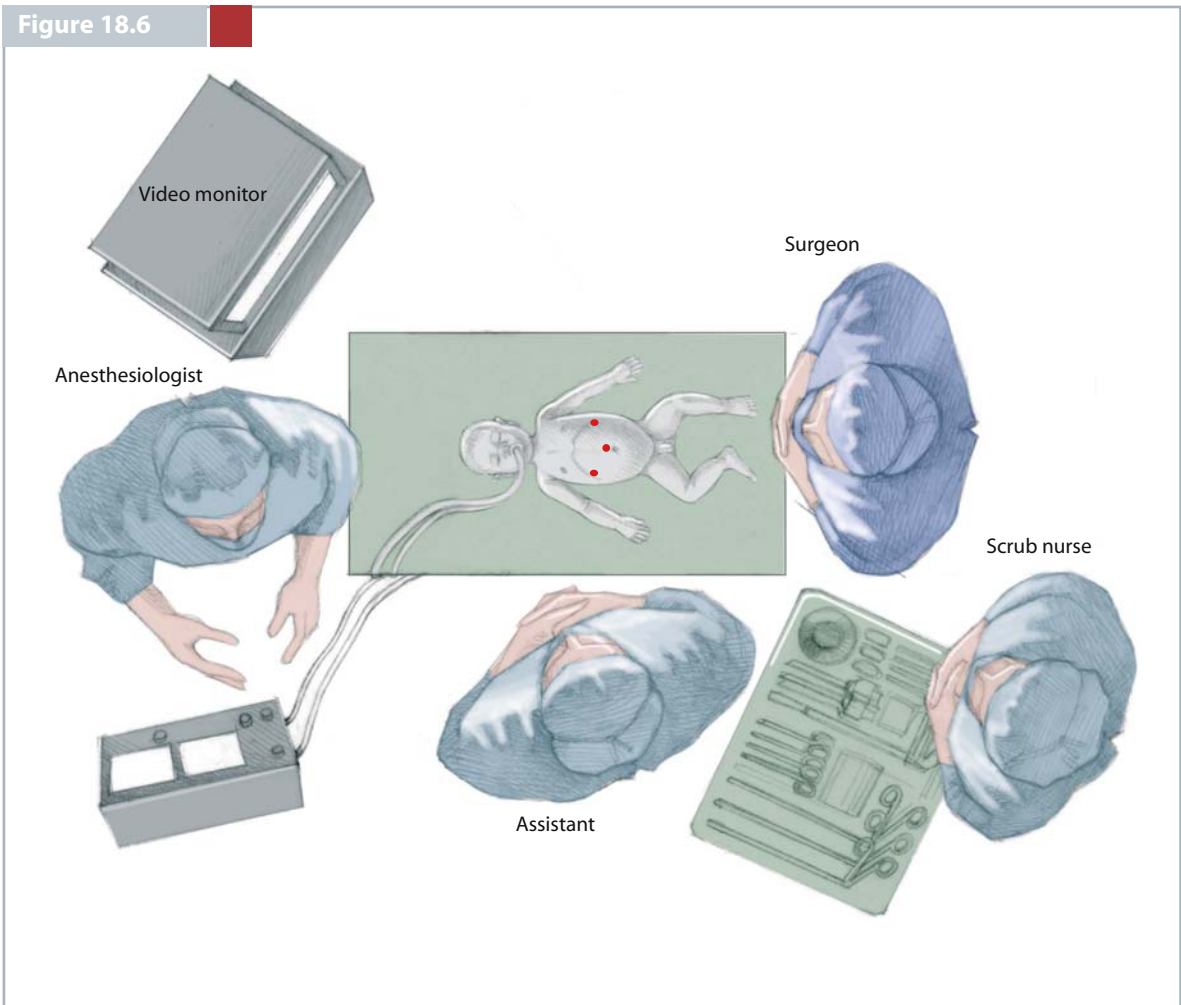


Figure 18.7

The working instruments, retractable myotomy knife, atraumatic laparoscopic grasper are used to assess the extent of the hypertrophied pylorus by palpating the margins of the pylorus as one would use with thumb and forefinger in the open procedure.

The duodenum is then grasped just distal to the pyloric vein (pyloroduodenal junction) and retracted using the atraumatic grasper to expose the avascular surface of hypertrophic pylorus. The tips of positioning the pylorus for myotomy is that lateral and slightly anterocephalad retraction of the distal pylorus achieve excellent exposure of the avascular surface of hypertrophic pylorus. This manoeuvre also expos-

es the proximal margin of hypertrophied muscle that is seen as a deep fold in the wall of stomach.

A seromuscular incision is made over the hypertrophic pylorus with retractable myotomy knife commencing at 1–2 mm proximal to the pyloroduodenal junction extending to the gastric antrum. The incision should go far enough onto antrum at least 0.5–1.0 cm proximal to antropyloric junction. Care must be taken at this stage that this incision is deep enough to allow the insertion of the pyloric spreader blades and must penetrate the pyloric muscle somewhat deeper than is usual with the conventional open procedure.

Figure 18.8

After the muscle is incised, the blade is then retracted and the sheath of the knife is used to further split the hypertrophied muscle fibre, as the scalpel handle is used in open procedure, until mucosa is visualized. The retractable myotomy knife is removed and a laparoscopic pyloromyotomy spreader is introduced into abdominal cavity directly through the left stab wound to complete the pyloromyotomy. The spreader is placed in the midpoint of the seromuscular incision line and the muscle is spread perpendicularly. Once the initial spread reaches the mucosa, spreading must be continued proximally and distally. Pushing the spreader towards the mucosa or rapid spreading can result in mucosal tear. In order to avoid the mucosal tear, the spreader should not be placed at the proximal and distal edges of the incisional (myotomy) line.

To test for the mucosal injury, the stomach is inflated through the nasogastric tube (160–180 ml) as is usually done in open techniques. Bulging of the mucosal layer with no evidence of defect should be confirmed. Greenish or yellowish fluid at the myotomy area is a sign of mucosal tear.

After the successful myotomy, the instruments are withdrawn under direct vision and the pneumoperitoneum is evacuated. The nasogastric tube is also removed after completing the surgery. The umbilical fascia is reapproximated with 4/0 absorbable suture material, which is already in place, and the skin of all the wound is reapproximated with skin adhesive tapes.

Figure 18.7

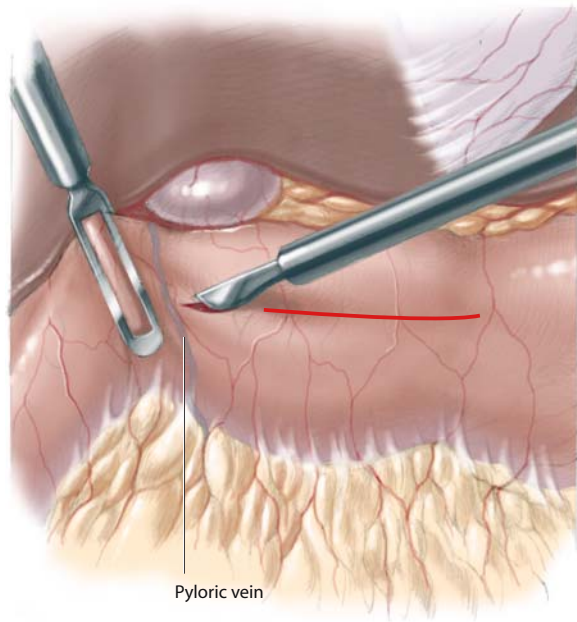
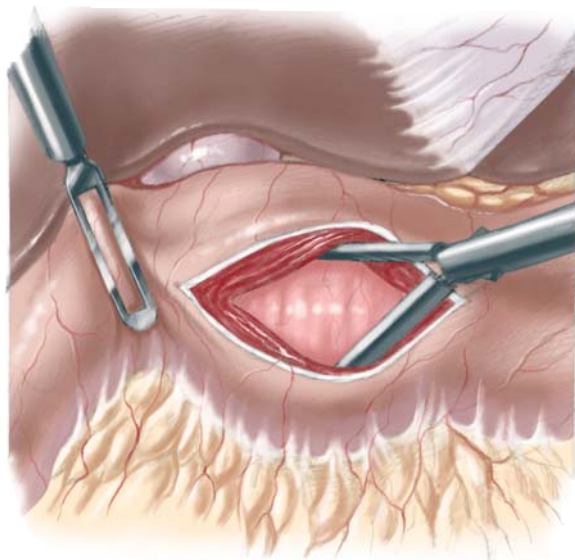


Figure 18.8



CONCLUSION

Pyloromyotomy is the standard therapy for IHPS. Mortality associated with this operation is very uncommon today. Early diagnosis and proper peri-operative management reduces complications. In spite of these advances, there remains about an 8–10% incidence of associated peri-operative morbidity such as perforation, wound infection and wound dehiscence.

In an open procedure, essentially right umbilical incision and circumumbilical incision, manipulation

of and tension on the pylorus to deliver it through the wound can induce oedema in muscle layer, mucosal swelling and, occasionally serosal laceration. A laparoscopic pyloromyotomy (LP) is a less traumatic operation. The tolerance of an early feeding regimen in the LP confirms that there is lack of trauma to the pylorus during the procedure. We feel this is the most considerable benefit of LP. Use of 3.0-mm instruments allow us to improve the cosmesis.

SELECTED BIBLIOGRAPHY

- Fujimoto T, Lane GJ, Segawa O et al (1999) Laparoscopic extramucosal pyloromyotomy versus open pyloromyotomy for infantile hypertrophic pyloric stenosis: which is better? *J Pediatr Surg* 34: 370–372
- Leinwand MJ, Shaul DB, Anderson KD (1999) The umbilical fold approach to pyloromyotomy: is it a safe alternative to right upper quadrant approach. *J Am Coll Surg* 189: 362–367
- Puri P, Lakshmanadaas G (2003) Hypertrophic pyloric stenosis In: Puri P (ed) *Newborn surgery*. Arnold, London, pp 389–398
- Tan KC, Bianchi A (1986) Circumumbilical incision for pyloromyotomy. *Br J Surg* 73:399