

## ORIGINAL ARTICLE

**Hepatic diseases in horses**D. Bergero<sup>1</sup> and J. Nery<sup>2</sup>

1 DIPAE, Grugliasco (TO), Italy, and

2 École nationale vétérinaire de Nantes, Nantes, France

**Keywords**

horse, hepatobiliary disease, nutrition, hyperlipaemia

**Correspondence**D. Bergero, DIPAE, Grugliasco (TO), Italy.  
Tel: +39 011 6709207; Fax: +39 011 6709240;  
E-mail: domenico.bergero@unito.it

Received: 2 April 2007;

accepted: 12 November 2007

First published online: 13 March 2008

**Summary**

The concept 'liver disease' includes several pathological conditions affecting liver's functions. It can either consist of a temporary impaired functioning of the liver and/or it can progress to its failure. The purpose of this review is to update the knowledge on hepatobiliary diseases and in particular on equine hyperlipaemia. Hepatobiliary disease's aetiology, clinical signs, diagnosis and nutritional management are thus described in the first part of the review the second part being devoted to hyperlipaemia's lipid metabolism, epidemiology, clinical signs, post-mortem observations and nutritional management. Diagnosis of hepatic disease is usually based on the assessment of the serum activities while hepatic biopsy is considered as the golden standard of diagnosis of hepatic function. Nutritional management is often very useful in management of hepatic diseases: diet should be low in protein (of good biological value) and high in non-structural carbohydrates except for chronic hepatic disease (slightly high protein). Equine hyperlipaemia's mortality is around 70%. It consists of a disorder of lipid metabolism, characterized by increase in plasma triglycerides and deposition of fat on organs. From a nutritional point of view, hyperlipaemia in horses can be approached by maintaining positive energy balance, fighting dehydration and metabolic acidosis, and by the use of lipotropic factors.

**Introduction**

The liver is the largest gland of the organism with both endocrine and exocrine functions. Endocrine functions of liver include the secretion of plasma proteins as albumin and  $\alpha$ - and  $\beta$ -globulins and cholinesterase. Bile excretion in the gastrointestinal (GI) tract constitutes the exocrine function of the liver (Frandsen and Spurgeon, 1995). Moreover liver's functions include clearance of drugs and toxins from the circulation, metabolism of carbohydrate and fat, synthesis of proteins as well as catabolism of immunoglobulin A and insulin, metabolism of several nitrogenous compounds, uptake and conjugation of bilirubin, free fatty acids and bile acids and storage of vitamins and minerals (Divers, 1998). The diversity

and complexity of these functions are thus of utmost importance to the overall health of the animal.

Liver's susceptibility to disease relies on its functions as a clearance organ for many toxins and drugs, and grazing animals like horses are particularly prone to liver disease (West, 1996). Hepatic disease in equines is frequently reversible because of the liver's wide functional capacity that offers the possibility of regeneration.

The purpose of this review is to update the knowledge (i) on hepatobiliary diseases in general and (ii) on equine hyperlipaemia in particular. Hepatobiliary disease's aetiology, clinical signs, diagnosis and nutritional management are thus described in the first part of the review, the second part being devoted to hyperlipaemia's lipid metabolism, epidemiology,

clinical signs, post-mortem observations and nutritional management.

### Hepatobiliary disease

The hepatocyte constitutes the functional cell of the liver. Along the hepatocyte lines, bile ducts are responsible for the transport of bile products into the duodenum (Frandsen and Spurgeon, 1995). Liver diseases most commonly affect both the two structures but yet at different levels concerning its nature (Divers, 1998). The concept 'liver disease' includes several pathological conditions that affect liver's functions and it can either consist of a temporary impaired functioning of the liver and/or it can progress to its failure (Lehrer, 2006). In equines, liver failure is rare. It becomes clinically apparent when more than around 70% of the liver function is lost (West, 1996; Divers, 1998; Durham et al., 2003a). The most common liver diseases in horses that lead to hepatic failure are Theiler's disease, Tyzzer's disease, pyrrolizidine alkaloid toxicosis, ferrous fumarate toxicosis, hepatic lipidosis, suppurative cholangitis, cholelithiasis and chronic active hepatitis (Kahn, 2006).

### Aetiology

A number of different aetiological causes may be ascribed to the development of horse hepatic diseases. Toxic, infectious, non-infectious inflammatory, metabolic, obstructive and some unknown causes are recognized in the panorama of liver diseases in horses (Divers, 2005). Among toxic causes of hepatic disease, the most important is pyrrolizidine alkaloid hepatotoxicosis. It is induced by the major plant hepatoxins, the pyrrolizidine alkaloid (PA), which is present in *Senecio* spp., *Amsinckia* spp., *Crotalaria* spp., *Cynoglossum officinale* and others. Pyrrolizidine alkaloids are synthesized in the root of plants and then translocated to all other plant organs (Ober and Hartmann, 1999). Several case studies concerning *Senecio* spp. (Lessard et al., 1986; Small et al., 1993), *Cynoglossum officinale* (Knight et al., 1984) and *Crotalaria* spp. (Arzt and Mount, 1999) hepatotoxicosis in horses were reported in the last quarter of century. Pyrrolizidine alkaloid hepatotoxicosis is characterized by liver necrosis and fibrosis. According to a case study of Knight et al. (1984), the observed clinical signs of PA hepatotoxicosis were weight loss, icterus, photosensitization and hepatic encephalopathy, while Arzt and Mount (1999) observations included inappetence, emaciation, ataxia and icterus. Both levels of copper (Dewes and Lowe, 1985) and iron

(Garrett et al., 1984) were found to increase in horse's liver with *Senecio* poisoning being the cause in the first case, related to wood and shavings ingestion. In addition to the hepatic damage, the PA has carcinogenic, teratogenic and abortifacient properties, which are the consequences observed long after the ingestion of the plants (Knight, 1995).

Alsike clover (*Trifolium hybridum*) and Panicum grasses (*Panicum coloratum*) grazing during wet or humid weather have been observed to induce photosensitivity and hepatitis. Although unclear, the causes of this type of poisoning have been pointed out to be mycotoxins or plant metabolites because of its sporadic and weather-related occurrence (Knight, 1995). Alsike clover poisoning has been reviewed elsewhere (Nation, 1989, 1991) and literature on specific clinical cases dates back to the 20s and 30s (1928–33; Nation, 1989). Briefly, the pathological findings of alsike clover poisoning includes enlargement and discolouration of the liver with increased bile duct proliferation and perilobular fibrosis without inflammation (Nation, 1991). Literature on *P. coloratum* grasses hepatotoxicosis reveals deposition of crystalline substances in the bile ducts. The exact cause of liver damage in this case is rather controversial. The origin of these crystals is plant saponin derivatives. As a high-dose administration of isolated saponins to induce photosensibilization experimentally is necessary, the controversy of this condition relies on a possible synergistic action with mycotoxins (Cheeke, 1995). Details of hepatic toxicosis because of the consumption of *P. coloratum* in horses (Cornick et al., 1988) and sheep (Bridges et al., 1987) have been published in the late 80s. Recently Johnson et al. (2006) have reported a clinical case on hepatotoxicosis in 14 horses fed with fall panicum hay (*Panicum dichotomiflorum*) in USA. High levels of activity of aspartate aminotransferase, sorbitol dehydrogenase, gamma-glutamyl transferase and alkaline phosphatase were observed in this study in addition to necrosis of hepatocytes. Because of the absence of fibrosis was observed in the reported cases, the authors suggested that the withdrawal of hay was sufficient as a measure to allow recovery from acute exposure.

Indospicine (Knight, 1995) hepatotoxicosis constitutes another toxic cause of liver disease. Indospicine is a hepatotoxic amino acid that is present in various species of *Indigofera* (highly palatable to horses). As an antagonist of arginine, this amino acid inhibits protein synthesis. Diets containing high quantities of arginine, as cottonseed meal and peanut meal are known to protect horses against the effect of

indospicine. This type of poisoning leads ultimately to death from liver necrosis and nodular fibrosis and it affects similar animals that might consume the meat of poisoned horses (Knight, 1995).

Dietary iron and copper excesses can also be toxic to the liver: the frequent administration of iron and iron-containing preparations to improve horse's performance constitutes a risk for iron toxicosis (Lewis, 1995b). Ferrous fumarate toxicosis was reported in the literature (Mullaney and Brown, 1988) to be one of the causes of hepatic failure (Kahn, 2006). Oral administration of this compound to new-born Shetland foals provoked death by acute hepatic failure, which lesions were compared with the toxic hepatopathy syndrome reported in USA (Divers et al., 1983; Acland et al., 1984). These two previous studies reported a toxic hepatic failure in foals aged 2–5 days because of oral administration of (i) a product containing a microorganism (Divers et al., 1983) and (ii) a paste containing both *Aspergillus* sp and an iron compound (Acland et al., 1984). From their very first day of life, foals are particularly susceptible to iron toxicosis (toxic dose is 25 times greater in adult horses). Prior to death, animals to which iron was administered together with an inoculum, presented depression, diarrhoea, icterus, dehydration and coma. Association of excesses in iron with deficiencies of selenium and/or vitamin E may boost this foals' susceptibility (Mullaney and Brown, 1988; Lewis, 1995b). Hepatic alterations because of excess of iron include liver deposition of iron and liver degeneration (Lewis, 1995b). According to Lewis (1995b), horses are quite resistant to copper excesses as, for some extent, they adapt their absorption of copper to ingestion levels. Lewis (1995b) reports a level of 2800 ppm of copper for a period of 2 months to provoke liver damage and 6 months to lead to death.

Finally mycotoxins can also be one of the toxic causes affecting liver functioning. Naturally occurring fungi in animal feeds produce mycotoxins in favourable environment conditions allowing its growth. Some of these mycotoxins can affect horse's liver (Pier et al., 1980). *Aspergillus flavus* in particular is a producer of some aflatoxins, the presence of which was reported in mouldy corn fed to horses prior to death. Aflatoxicosis in horses has been related with liver necrosis in this case report (Vesonder et al., 1991). The same observation (liver necrosis) was patent in a second case study in which one horse was fed with mouldy hay (McGavin and Knake, 1977). Bile duct hyperplasia and fibrous liver was reported in a third study concerning

aflatoxicosis in horses (Angsubhakorn et al., 1981). Experimentally induced aflatoxicosis with aflatoxin B1 in weanling ponies (Bortell et al., 1983) has revealed hepatic necrosis and bile duct hyperplasia.

Infectious causes of hepatic disease include cholangiohepatitis and Tizzer's disease. Parasitism of horses by *Fasciola hepatica* or *Parascaris equorum* can also affect overall hepatic health. Cholangiohepatitis arises from a liver infection of *Salmonella* sp, *E. coli*, *Pseudomonas* sp or *Actinobacillus equuli* leading to inflammation of the bile ducts and adjacent liver. Other bacteria, such as *Clostridium* sp., *Pasteurella* sp., and *Streptococcus* sp. are less frequently recovered from horses suffering from cholangiohepatitis. On the other hand, Tizzer's disease is because of an infection of the liver by *Clostridium piliforme*. It is usually an infection that starts in the low intestinal tract and spreads via blood and lymph circulation (Kahn, 2006).

The most important parasites affecting the liver are *P. equorum* and *F. hepatica*. Larvae of strongyles also parasite the host's liver, while adult forms affect the large intestine. Strongyles parasitism [both large: *Strongylus* spp., *Triodontophorus serratus*, and small: *Cyathostomum* spp., *Cylicostephanus* spp., *Poteriostomum imperidentum* (Mfitilodze and Hutchinson, 1990)] is the most frequent parasitism observed in several coproscopical examination studies concerning horses (Mirck, 1978; Epe et al., 1993, 2004; Dausgchies and Epe, 1995). A questionnaire study in Germany (Dausgchies and Epe, 1995) including 3500 veterinarians reported a prevalence of strongyles in 42.3% of their patients. Coproscopical examination studies from Germany and the Netherlands have reported prevalences of 55.5% [ $n = 9192$  (Epe et al., 1993)], 37.4% [ $n = 4399$  (Epe et al., 2004)] and 57.3% [ $n = 3791$  (Mirck, 1978)].

The prevalence of *P. equorum* reported in the literature was of 12.0% from post-mortem intestinal collection [ $n = 85$  (Kornaś et al., 2006)]. Results from coproscopical examination were much lower: 4.0% (Epe et al., 1993), 0.9% (Epe et al., 2004) and 6.1% (Mirck, 1978). A previous study on *P. equorum* administration to ponies has described both clinical evolution and lifecycle of these parasites (Srihakim and Swerczek, 1978). *Parascaris equorum*'s lifecycle is characterized by transport of larvae to the liver by the bloodstream, migration to the lungs and development of larvae in the intestine because of caughing and swallowing of larvae by the animals. Besides caughing, clinical signs are very indistinct and include anorexia, rough coat and loss of weight. Blood parameters reveal mild anaemia, marked

eosinophilia, and leukopenia. Post-mortem findings included haemorrhagic and necrosed liver (Srihakim and Swerczek, 1978). The prevalences of *F. hepatica* from coproscopical examination were of 0.2% (Epe et al., 1993), 0.04% (Epe et al., 2004) and 0.6% (Mirck, 1978). Several published studies of induced infection with *F. hepatica* have been reported (Nansen et al., 1975; Grelck et al., 1977; Alves et al., 1988; Soulé et al., 1989). *Fasciola hepatica* eggs were hardly ever found in faeces in several studies (Grelck et al., 1977; Alves et al., 1988; Soulé et al., 1989) revealing the inadequacy of this diagnosis tool in detecting infection of the liver by *F. hepatica* (liver fluke). According to Nansen et al. (1975), horses present a high resistance to liver fluke. Plasma enzymatic activity of glutamate dehydrogenase and gamma-glutamyl transferase was found to significantly increase 3 to 5 months after experimentally induced infection (Soulé et al., 1989).

Inflammatory causes of liver disease include chronic active hepatitis and liver neoplasia. Although chronic active hepatitis is often related to cholangiohepatitis, it can also arise from immune-mediated or toxic processes. Primary hepatic neoplasia is not commonly observed in horses. The bile ducts, hepatocytes or metastasis are the onset structures of carcinomas of the liver (Kahn, 2006).

The most common biliary duct obstructive cause of hepatic disease is cholelithiasis (Gerros et al., 1993). Cholelithiasis can occur because of ascariasis, biliary stasis, ascending biliary infection or variation of bile composition. According to the mentioned case report, the clinical signs observed were abdominal pain, icterus and pyrexia. Other obstructive causes include colon displacements and associated right hepatic lobe compression, papillary stricture, neoplasia, hepatic torsion and thrombosis of the portal vein. Recent case reports concerning hepatic neoplasia have been published (Patton et al., 2006; Schnabel et al., 2006; Loynachan et al., 2007). In Patton et al. (2006) case report, clinical signs of neoplasia in a thoroughbred mare included depression, head pressing and blindness. Further investigation observations following euthanasia included increased sorbitol dehydrogenase, gamma-glutamyl transpeptidase and alkaline phosphatase activities, increased total serum bilirubin (from which 95% was unconjugated) and serum activity of creatine kinase, increased plasma ammonia level, hyperglobulinemia and hyperglycemia. The liver presented neoplastic cell masses and a large thrombus of these cells was found in the portal vein.

Hepatic lipidosis and hyperammonemia are recognized metabolic aetiological causes of liver disease. Hepatic lipidosis will be described in detail further on this work. An impaired development of urease-producing bacteria in the intestine of the horse can be the cause of hyperammonemia, which is almost always associated with enteric disease, diarrhoea or colic (Kahn, 2006).

Theiler's disease and neonatal isoerythrolysis are some of not fully understood causes of hepatic disease. Theiler's disease or idiopathic acute hepatic disease is the most common cause of acute hepatitis.

### Clinical signs

Some typical clinical signs associated with specific liver diseases have been described previously with the aetiological factors. Hepatic failure can lead to different clinical signs. The most common signs are weight loss, neurological troubles linked to ammonia excesses, icterus, hypoglycaemia, haemoglobinuria, while less frequently observed signs are photosensitivity, bleeding abnormalities, oedemas and ascites.

Weight loss can be one of the most common signs of liver failure (Cornick et al., 1988; McGorum et al., 1999; Kahn, 2006) in particular resulting from PA toxicosis. The decreased appetite and/or decreased metabolism at a hepatic level are factors that will direct liver disease clinical signs in this direction. In cases of neoplasia of the liver, both infection and circulating tumour-induced cytokines are the onset causes of weight loss.

Hepatoencephalopathy, neurological troubles associated with liver disease are also very often described (McGorum et al., 1999; Durham et al., 2003b) and it is related to the excess of ammonia in the blood stream. It consists mainly on depression, head pressing, apparent blindness, circling and other symptoms. The excess of ammonia in the blood stream is because of an insufficient conversion by the liver of ammonia in urea, arriving from the colon. This hyperammonemia will interfere with normal neurotransmission; will structurally change the blood brain barrier and will interfere with biochemical or electrophysiological pathways in the brain. Aromatic amino acids metabolism in the liver will also be affected leading to its increased concentration in the blood stream. As false neurotransmitters, aromatic amino acids in the blood will also have neurological consequences. Gut-synthesized gamma-aminobutyric acid's increased concentration in the blood stream, associated with augmented aromatic amino acids and bile acids concentration, will potentially have an

inhibitory role in neurotransmission, leading to consequences at a neurological level (Divers, 1998). Because of a reduced hepatic gluconeogenesis capacity, hypoglycaemia has also been observed in foals suffering from hepatic disease (Humber et al., 1988).

Icterus and hyperbilirubinemia are often related to liver disease (McGorum et al., 1999; Durham et al., 2003b), haemolysis or anorexia although cases in healthy thoroughbred horses have been reported (Divers et al., 1993). Some healthy horses do present icterus without liver disease because of an impaired bilirubin-uridine diphosphate glucunoryl transferase activity and consequent wide variations in blood bilirubin concentrations. In affected horses, however, concentration of unconjugated bilirubin increases because of a diminished capacity of the liver for its uptake and conjugation. A study in fasting fistulated ponies has shown that it is not bilirubin input in the plasma that is increased but it is rather its removal that is affected (Gronwall et al., 1980). Conjugated bilirubin concentration on the blood stream can also increase in obstructive types of liver disease. Among other factors that are not yet fully understood, blood free fatty acids concentration has been found to compete for hepatocellular membrane carriers in the liver (Engelking, 1993). An augmented concentration of conjugated bilirubin is additionally found in urine (haemoglobinuria) because of its free filtration by the glomerulus, which leads to an orange discoloration of urine. As urine colour varies greatly in the horse, urine dipsticks that allow the measurement of this component are advised for a correct diagnosis (Divers, 1998).

An impaired capacity of the liver concerning the metabolism of phyloerythrin, a gut-derived breakdown product of chlorophyll, may lead to the appearance of white markings commonly seen in the muzzle and legs of horses exposed to the sunlight. This photosensitivity is commonly observed in sub-acute to chronic diseases and its manifestations are particularly evident in plant poisoning, by mechanisms mentioned previously.

Clinical bleeding abnormalities are observed mostly in bile duct obstruction and arise both from self-inflicted trauma because of hepatoencephalopathy, stomach tubing and decreased clotting factor production by the liver. Severe to acute liver failure may lead to intravascular coagulation which is because of both diminished liver production of anti-thrombin III, plasminogen and proteins responsible for the inhibition of impaired coagulation, and increasing circulation of endotoxins (Divers, 1998). Oedema, ascites and diarrhoea are not common

findings in horses with liver failure because of a long life of albumin in the horse on one hand and to a typically low-fat containing diet fed to horses.

### Diagnosis

Diagnosis of hepatobiliary disease and determination of hepatic function can be achieved basically with three types of diagnosis tools: serum biochemical analysis, liver biopsy and ultrasound imaging. Despite all work that has been carried out concerning hepatic diseases in horses, only recently published works have focused seriously on the diagnostic value of the above-mentioned tools. These very interesting works of Durham et al. (2003a,b) have focused on ultrasound imaging, clinical and clinicopathological data and its adequacy to discriminate affected from non-affected horses.

Serum biochemical diagnosis is based on the assessment of the serum activities of gamma-glutamyl transferase and sorbitol dehydrogenase, bilirubin and bile acids (Divers, 1998). Although blood ammonia is commonly high when loss of hepatic function occurs, it is not so for liver failure so its use as a diagnosis tool is reserved. In plant poisoning, particularly PA hepatotoxicosis, diagnosis is often difficult because of late suggestion of poisoning. Often the cause of liver damage remains unknown besides the diagnosis tests mentioned and the bromsulphophthalein clearance test. In these cases, biopsy or necropsy is frequently the only reliable diagnosis tool (Knight, 1995). Durham et al. (2003c) have developed a scoring system for liver biopsies that has taken in consideration five pathological processes. Hepatic biopsy is useful for diagnosis and to plan for a specific therapy, but generally blood analysis is the most common diagnosis tool to detect liver disease. In several studies, biopsy is considered as the 'gold standard' technique for hepatic disease diagnosis (Spycher et al., 2001; Durham et al., 2003c).

The results obtained by Durham et al. (2003b) have highlighted that neither single nor grouped results of clinical data, serum biochemical analysis and ultrasonography were found to fully discriminate affected from non-affected horses when compared to liver biopsy. Hepatic encephalopathy, gamma-glutamyl transferase, hyperglobulinaemia, hypoalbuminaemia, high alkaline phosphatase activity, increased total bile acids and increased total bilirubin were the most valuable single positive results. Ultrasonography on the other hand has proven to be useful to detect particular abnormalities or add some

insights on the diagnosis together with the other mentioned tools.

Moreover, techniques using radiopharmaceuticals have also been already applied to analyse hepatic function: scintigraphy (Theodorakis et al., 1982) and clearance tests (Morandi et al., 2005). The necessity of both radiopharmaceuticals and adequate imaging machinery are the disadvantages that restrain scintigraphy's daily life application. Despite the practical issues related to authorization of institutions to use radiopharmaceuticals, Morandi et al. (2005) studied the  $^{99m}\text{Tc}$ -mebrofenin clearance from the blood in seven horses, reporting the simplicity and reliability of the method. The results of this study have shown that with a clearance plasma-based method it is possible to access hepatic function.

### Nutritional management

Among therapies, nutritional management is very often useful. Literature regarding nutritional requirements in horses affected with liver disease is scarce and focus mainly on hyperlipaemia (which will be described further on this review). Lewis (1995c) suggested five main points to have in consideration when feeding the liver diseased horse: (i) meet energy requirements; (ii) meet without exceeding dietary protein needs (low protein in case of hyperammonaemia); (iii) feed high ratio of branched-chain amino acids (BCAA)/aromatic amino acids; (iv) feed low fat and salt and (v) feed high-starch diets.

Diets must contain low levels of proteins (Hussein et al., 2004) of good biological value. High protein forages (e.g. alfalfa and fresh rich spring grass) are advised not to be fed to liver-diseased horses. On the contrary, first cut meadow hays and fall pasture grazing (avoiding long exposure to sun) can be considered optimal.

Increased number of daily meals could be also useful. Lewis (1995c) suggests feeding 0.5–0.6 kg/100 kg body weight BW/day divided in three to six daily meals. Ott (2001) suggests that higher levels of dietary protein induce higher urea-N serum concentration while blood ammonia remains constant. This observation was confirmed by Hussein et al. (2004), who added that after being fed, mares had statistically increasing serum ammonia concentrations. In the previous study, Hussein et al. (2004) have fed the mares twice daily. It is thus wise to consider that the higher number of meals can decrease the intensity of fermentation in the hindgut and consequently decrease ammonia peaks in the serum, which is a

factor contributing for hyperammonaemia when considering liver-diseased horses.

As blood concentrations of BCAA may be decreased, and the aromatic amino acids (AAA) and ammonia are usually augmented in acute hepatobiliary disease, BCAA/tryptophan ratio in the diet must thus be kept high. Corn and molasses are often used. Table 1 summarizes some of BCAA/AAA ratio and protein content in several feedstuffs fed to horses. Horses with chronic hepatic disease, conversely, must be fed slightly high-protein diets. Non-structural carbohydrates are required in large amounts to meet the energy requirements and avoid mobilization of body glycogen, fat and protein.

As mentioned previously (aetiology), copper and iron excesses can affect liver function: liver damage was observed for horses consuming 2 800 ppm of copper (Lewis, 1995b) for 2 months and led to death in 6 months. Administration of supplements like iron-containing haematinics to horses to enhance performance must be precautious to avoid iron toxicosis (Lewis, 1995b; Casteel, 2001). Pearson and Andreasen (2001) have studied the effect of iron oral administration on hepatic biopsies and serum analysis. Ferrous sulphate (50 mg/kg BW/day; 20% elemental iron) was orally administered to ponies during 28 weeks. By week 8, hepatic and serum iron concentration had increased when compared with control and baseline concentrations but these values have decreased by the twenty-eighth week. Hepatic biopsies did not present any lesions at hepatocyte's level. This study suggests that a primary hepatopathy might be the cause for a secondary haemorrhiderin accumulation. The susceptibility to iron toxicosis is influenced also by selenium and vitamin E deficiencies. According to Lewis (1995b), despite the infrequent clinical selenium or vitamin E deficiencies,

**Table 1** BCAA/AAA ratio and protein content of feedstuffs (Vervuert and Coenen, 2004)

Feedstuffs	BCAA/AAA	Protein (% dry matter)
Soybean	1.8	50
Linseed	1.9–2.1	35–50
Rice	1.35	7–9
Wheat	1.5	11–14
Oats	1.65	10–13
Barley	1.65	13
Rye	1.85	14
Corn	2.15	8–10
Sorghum	2.3	12–13

BCAA, branched-chain amino acids; AAA, aromatic amino acids.

horse diets are usually below the concentrations required (selenium requirement is of 0.1 ppm of diet dry matter against some cases of 0.05 ppm supply; vitamin E minimum requirement for maintenance being of 50 IU). In pigs, vitamin E bioavailability is positively related with fat content in the diet (Moreira and Mahan, 2002) but that is not the case regarding humans (Roodenburg et al., 2000) and horses (Kienzle et al., 2003).

Finally, fluid therapy is often very useful to improve perfusion, restore electrolytes and glucose levels and help toxin removal. Dextrose is used in hypoglycaemic horses (Divers, 1998). A successful treatment of a mare with encephalopathy and concurrent hypocalcaemia by continuous infusion of Ringer's solution, calcium gluconate, dextrose, B-complex vitamins, sodium ampicillin and flunixin meglumine was previously reported by Scarratt et al. (1991).

### Hyperlipaemia

Horses' liver function is also severely affected as a result of equine hyperlipaemia, which is characterized, by increased plasma triglycerides and fatty infiltration of body organs. The incidence of this metabolic disorder has been reported in population surveys, varying between 3% and 5% while clinical studies of animals presented to veterinary hospitals have described incidences between 11% and 18% (Watson, 1998). Although of minor economical importance in the equine industry (Jeffcott and Field, 1985), mortality of affected animals is high, like in other species, ranging between 60% and 80% (Watson, 1998).

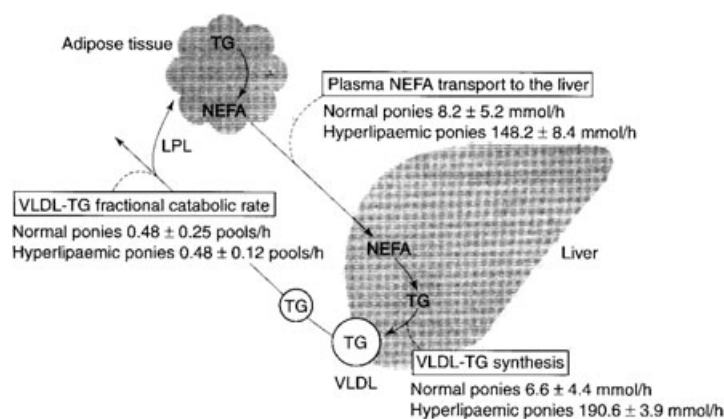
### Lipid metabolism

Equine hyperlipaemia is a disorder of lipid metabolism, characterized by increase in plasma

triglycerides. Because of hormone sensitive lipase activation in hyperlipaemic animals, an increase of plasma non-esterified fatty acids (NEFA) occurs, exceeding the oxidative, gluconeogenic and ketogenic pathways (Watson, 1998). Unlike other species, horses have a limited capacity for ketogenesis and do not develop pronounced ketonaemia associated with hyperlipaemia (Naylor et al., 1980). The synthesis of triglycerides in the liver is thus increased in the form of very low density lipoproteins (VLDL), which are secreted in the circulation increasing plasma triglycerides (Watson, 1998). Fatty infiltration of different organs may follow. Liver's fatty infiltration is because of an increased VLDL synthesis that does not match the rate of triglycerides synthesis. Differences of lipid metabolism between hyperlipaemic and normal ponies have been described by Watson (1998) and are schematically shown in Fig. 1. Hyperlipaemic ponies have shown a much higher transportation of plasma NEFA to the liver ( $148.2 \pm 8.4$  mmol/h) when comparing to normal ponies ( $8.2 \pm 5.2$  mmol/h) as well as a higher VLDL-triglyceride (TG) synthesis ( $190.6 \pm 3.9$  mmol/h against  $6.6 \pm 4.4$  mmol/h). On the other hand, the VLDL-TG fractional catabolic rate is similar in both cases.

### Epidemiology

Risk factors for hyperlipaemia can either precipitate or predispose to hyperlipaemia. Table 2 (source: Watson, 1998) summarizes the risk factors of hyperlipaemia which are followed by a general description. Although not being a condition observed strictly in ponies, a marked insensibility to insulin of these animals comparing to larger horses indicates a higher promptness for triglycerides mobilization and consequently hyperlipaemia (Jeffcott and Field, 1985). The presence of



**Fig. 1** Lipid metabolism differences between healthy and hyperlipaemic ponies (Watson 1998).

**Table 2** Risk factors for hyperlipaemia

Predispose	Precipitate
Breed	Anorexia
Sex (female)	Malnutrition
Obesity	Stress
Pregnancy/lactation	Disease

hyperlipaemia was observed both in ponies, donkeys and horses in a serum chemical profile study enrolling both clinically normal and sick, either with or without hyperlipaemia equids (Naylor et al., 1980).

Although sex was thought to be involved as the predisposing factors, it seems that pregnancy and lactation are the factors that place females in a predisposing circumstances for hyperlipaemia. Moreover, a study with donkeys has evidenced the highest risk of females and body condition regardless of pregnancy status (Reid and Mohammed, 1996). Stated percentages of obese ponies that have developed hyperlipaemia vary between 60% and 90% (Watson, 1998) which indicates the tendency of obesity in ponies to be related with hyperlipaemia. Anorexia is very frequently observed immediately before the clinical signs onset. It can be because of underlying disease, insufficient supply of pasture/supplementary feeding or even diet/environment modifications (Watson, 1998).

Stress is one of the major risk factors pointed out in literature (Jeffcott and Field, 1985; Watson, 1998). Transportation, change of environment, nutritional stress and pregnancy, lactation and disease-associated stress are among the stress situations that can represent a risk regarding hyperlipaemia. Its association with animal-focused predisposing factors have tendency to enhance the probability for hyperlipaemia occurrence.

Gastrointestinal tract diseases have been observed as a primary disease leading to hyperlipaemia. Among which, case records stated in literature (Moore et al., 1994) have observed associated septicaemia, colitis, parasitism, oesophageal obstruction, faecalith and gastric impaction. Other references include additional systemic diseases as pneumonia (Lewis, 1995a) and pancreatic pathology, renal insufficiency and laminitis (Watson et al., 1992). Although age is considered an important factor for development of hyperlipaemia, which risk tends to be higher for older animals, occurrence in foals from 2 days to 6 months has been reported (Moore et al., 1994).

### Clinical signs

Reported clinical signs of hyperlipaemia include dullness and depression, loss of appetite, production of scant faeces, obesity, weight loss, production of diarrhoeic faeces, increased pulse rate, pyrexia, increased respiratory rate, ventral oedema, jaundiced membranes, petechial haemorrhages, lipaemic serum (West, 1996) and failure to drink, progressive drowsiness, muscle fasciculations, colic, incoordination and coma (Lewis, 1995a). Plasma TG increase in horses with hyperlipaemia reaching values as high as 1500 mg/dl as well as plasma alkaline phosphatase activity (Lewis, 1995a). Often hyperlipaemia is associated with a primary disease. Gastrointestinal diseases are commonly referred to in this context (Moore et al., 1994; Watson, 1998) and recovery is thus often closely related to the success of treatment of the primary disease (Lewis, 1995a).

### Post-mortem observations

Post-mortem observations of affected animals comprise deposition of fat in the liver, kidneys, skeletal muscle, adrenal cortex and myocardium, vascular thrombosis in the lungs, kidneys and brain, renal nephrosis and proliferative glomerulonephritis, atrophy of the exocrine pancreas, lymphoid follicle depletion of the spleen, lymph nodes and mucosal ulceration of the GI tract as well as excessive fluidity of the GI contents (Jeffcott and Field, 1985).

### Nutritional management

Hyperlipaemia in horses, from a nutritional point of view can be approached by maintaining positive energy balance with low-fat diets, fighting dehydration and metabolic acidosis, and by the use of lipotropic factors. Fluid therapy includes the use of lactate or pyruvate; bicarbonate can be used with caution (Watson, 1998). High energy feedstuffs can be used for hyperlipaemic horses; sometimes nasogastric tube feeding is required. Dextrose is often used at quite high dosages (100 g/day for miniature horses) with galactose being used on alternate days to avoid/recover from metabolic acidosis. Nevertheless, it is important to monitor for insulin sensitivity and hyperglycaemia situations (Watson, 1998). Schmidt et al. (2001) have studied the effect of dietary fat on plasma metabolites in healthy ponies and they have concluded that fat feeding increases clearance of TG from the blood stream but it deteriorates glucose tolerance. To our knowledge, further work



on this topic including hyperlipaemic animals has not been performed so far.

Enteral low fat and partially hydrolysed feeding preparation for humans (Vital HN, Ross laboratories, Columbus, Ohio, USA) has been successfully used in a miniature horse (Golenz et al., 1992). Fasting ponies have also been fed with a fat-free preparation consisting of glucose, casein, minerals and vitamins, which has also shown to successfully decrease the level of plasma triacylglycerol, although being much lower in fasting animals than in sick horses (Hallebeek and Beynen, 2001). Though supplementation in sick horses has not been studied, the authors state that, in association with conventional therapy, the potential of the diet to aid hyperlipaemia treatment is real (Hallebeek and Beynen, 2001). Complete feeds and increased daily meal numbers are also useful. Both Golenz et al. (1992) and Moore et al. (1994) propose an energetic level of approximately 1.2 to 2.0 maintenance level corresponding this value to a 'stress factor'. Prevention of hyperlipaemia relies on ensuring an adequate intake of good quality feeds mostly in situations at risk and in predisposed animals.

## References

- Acland, H. M.; Mann, P. C.; Robertson, J. L.; Divers, T. J.; Lichtensteiger, C. A.; Whitlock, R. H., 1984: Toxic hepatopathy in neonatal foals. *Veterinary Pathology* **21**, 3–9.
- Alves, R. M.; van Rensburg, L. J.; van Wyk, J. A., 1988: Fasciola in horses in the Republic of South Africa: a single natural case of *Fasciola hepatica* and the failure to infest ten horses either with *F. hepatica* or *Fasciola gigantica*. *The Onderstepoort Journal of Veterinary Research* **55**, 157–163.
- Angsubhakorn, S.; Poomvises, P.; Romruen, K.; Newberne, P. M., 1981: Aflatoxicosis in horses. *Journal of the American Veterinary Medical Association* **178**, 274–278.
- Arzt, J.; Mount, M. E., 1999: Hepatotoxicity associated with pyrrolizidine alkaloid (*Crotalaria* spp) ingestion in a horse on Easter Island. *Veterinary and Human Toxicology* **41**, 96–99.
- Bortell, R.; Asquith, R. L.; Edds, G. T.; Simpson, C. F.; Aller, W. W., 1983: Acute experimentally induced aflatoxicosis in the weanling pony. *American Journal of Veterinary Research* **44**, 2110–2114.
- Bridges, C. H.; Camp, B. J.; Livingston, C. W.; Bailey, E. M., 1987: Kleingrass (*Panicum coloratum* L.) poisoning in sheep. *Veterinary Pathology* **24**, 525–531.
- Casteel, S. W., 2001: Metal toxicosis in horses. *Veterinary Clinics of North America. Equine Practice* **17**, 517–527.
- Cheeke, P. R., 1995: Endogenous toxins and mycotoxins in forage grasses and their effects on livestock. *Journal of Animal Science* **73**, 909–918.
- Cornick, J. L.; Carter, G. K.; Bridges, C. H., 1988: Kleingrass-associated hepatotoxicosis in horses. *Journal of the American Veterinary Medical Association* **193**, 932–935.
- Dauguschies, A.; Epe, C., 1995: Inquiry of veterinarians in Niedersachsen concerning the occurrence of parasitic diseases and their control in large animals. *DTW. Deutsche tierärztliche Wochenschrift* **102**, 81–84.
- Dewes, H. F.; Lowe, M. D., 1985: Haemolytic crisis associated with ragwort poisoning and rail chewing in two thoroughbred fillies. *New Zealand Veterinary Journal* **33**, 159–160.
- Divers, T. J., 1998: Metabolic manifestations of hepatobiliary disease in horses. In: T. Watson (ed), *Metabolic and Endocrine Problems of the Horse*. W.B. Saunders, Harcourt Brace and Company Ltd., London, pp. 113–127.
- Divers, T. J., 2005: Diagnosis and treatment of liver disease. Proceedings of the American Association of Equine Practitioners - Focus Meeting, Québec QC, Canada, hosted by IVIS (<http://www.ivis.org>) edited by AAEP.
- Divers, T. J.; Warner, A.; Vaala, W. E.; Whitlock, R. H.; Acland, H. A.; Mansmann, R. A.; Palmer, J. E., 1983: Toxic hepatic failure in newborn foals. *Journal of the American Veterinary Medical Association* **183**, 1407–1413.
- Divers, T. J.; Schappel, K. A.; Sweeney, R. W.; Tennant, B. C., 1993: Persistent hyperbilirubinemia in a healthy thoroughbred horse. *The Cornell Veterinarian* **83**, 237–242.
- Durham, A. E.; Newton, J. R.; Smith, K. C.; Hillyer, M. H.; Hillyer, L. L.; Smith, M. R. W.; Marr, C. M., 2003a: Retrospective analysis of historical, clinical, ultrasonographic, serum biochemical and haematological data in prognostic evaluation of equine liver disease. *Equine Veterinary Journal* **35**, 542–547.
- Durham, A. E.; Smith, K. C.; Newton, J. R., 2003b: An evaluation of diagnostic data in comparison to the results of liver biopsies in mature horses. *Equine Veterinary Journal* **35**, 554–559.
- Durham, A. E.; Smith, K. C.; Newton, J. R.; Hillyer, M. H.; Hillyer, L. L.; Smith, M. R. W.; Marr, C. M., 2003c: Development and application of a scoring system for prognostic evaluation of equine liver biopsies. *Equine Veterinary Journal* **35**, 534–540.
- Engelking, L. R., 1993: Equine fasting hyperbilirubinemia. *Advances in Veterinary Science and Comparative Medicine* **37**, 115–125.
- Epe, C.; Ising-Volmer, S.; Stoye, M., 1993: Parasitological fecal studies of equids, dogs, cats and hedgehogs during the years 1984–1991. *DTW. Deutsche tierärztliche Wochenschrift* **100**, 426–428.
- Epe, C.; Coati, N.; Schnieder, T., 2004: Results of parasitological examinations of faecal samples from horses,

- ruminants, pigs, dogs, cats, hedgehogs and rabbits between 1998 and 2002. *DTW. Deutsche tierärztliche Wochenschrift* **111**, 243–247.
- Fransson, R. D.; Spurgeon, T. L., 1995: *Anatomia y fisiología de los animales domésticos*, 5th edn. Interamericana McGraw Hill, Mexico, 298–324.
- Garrett, B. J.; Holtan, D. W.; Cheeke, P. R.; Schmitz, J. A.; Rogers, Q. R., 1984: Effects of dietary supplementation with butylated hydroxyanisole, cysteine, and vitamins B on tansy ragwort (*Senecio jacobaea*) toxicosis in ponies. *American Journal of Veterinary Research* **45**, 459–464.
- Gerros, T. C.; McGuirk, S. M.; Biller, D. S.; Stone, W. C.; Ryan, J., 1993: Cholelithiasis attributable to a foreign body in a horse. *Journal of the American Veterinary Medical Association* **202**, 301–303.
- Golenz, M. R.; Knight, D. A.; Yvorchuk-St Jean, K. E., 1992: Use of a human enteral feeding preparation for treatment of hyperlipemia and nutritional support during healing of an esophageal laceration in a miniature horse. *Journal of the American Veterinary Medical Association* **200**, 951–953.
- Grelck, H.; Hörchner, F.; Wöhr, H., 1977: Experimental infection of horses with *Fasciola hepatica*. *Berliner und Münchener Tierärztliche Wochenschrift* **90**, 371–373.
- Gronwall, R.; Engelking, L. R.; Noonan, N., 1980: Direct measurement of biliary bilirubin excretion in ponies during fasting. *American Journal of Veterinary Research* **41**, 125–126.
- Hallebeek, J. M.; Beynen, A. C., 2001: A preliminary report on a fat-free diet formula for nasogastric enteral administration as treatment for hyperlipaemia in ponies. *The Veterinary Quarterly* **23**, 201–205.
- Humber, K. A.; Sweeney, R. W.; Saik, J. E.; Hansen, T. O.; Morris, C. F., 1988: Clinical and clinicopathologic findings in two foals infected with *Bacillus piliformis*. *Journal of the American Veterinary Medical Association* **193**, 1425–1428.
- Hussein, H. S.; Vogedes, L. A.; Fernandez, G. C.; Frankeny, R. L., 2004: Effects of cereal grain supplementation on apparent digestibility of nutrients and concentrations of fermentation end-products in the feces and serum of horses consuming alfalfa cubes. *Journal of Animal Science* **82**, 1986–1996.
- Jeffcott, L. B.; Field, J. R., 1985: Current concepts of hyperlipaemia in horses and ponies. *Veterinary Record* **116**, 461–466.
- Johnson, A. L.; Divers, T. J.; Freckleton, M. L.; McKenzie, H. C.; Mitchell, E.; Cullen, J. M.; McDonough, S. P., 2006: Fall panicum (*Panicum dichotomiflorum*) hepatotoxicosis in horses and sheep. *Journal of Veterinary Internal Medicine* **20**, 1414–1421.
- Kahn, C. M., (ed.), 2006: *The Merck Veterinary Manual*, 9th edn. Merck & Company, Whitehouse Station, NJ, USA.
- Kienzle, E.; Kaden, C.; Hoppe, P. P.; Opitz, B., 2003: Serum beta-carotene and alpha-tocopherol in horses fed beta-carotene via grass-meal or a synthetic beadlet preparation with and without added dietary fat. *Journal of Animal Physiology and Animal Nutrition (Berlin)* **87**, 174–180.
- Knight, A. P., 1995: Plant poisoning of horses. In: L. D. Lewis (ed.), *Equine Clinical Nutrition – Feeding and Care*. Williams & Wilkins, Baltimore, USA, pp. 447–502.
- Knight, A. P.; Kimberling, C. V.; Stermitz, F. R.; Roby, M. R., 1984: *Cynoglossum officinale* (hound's-tongue) – a cause of pyrrolizidine alkaloid poisoning in horses. *Journal of the American Veterinary Medical Association* **185**, 647–650.
- Kornaś, S.; Skalska, M.; Nowosad, B., 2006: Occurrence of roundworm (*Parascaris equorum*) in horses from small farms based on necropsy. *Wiadomości Parazytologiczne* **52**, 323–326.
- Lehrer, J. K., 2006: *Liver Disease Definition*. The MedlinePlus Medical Encyclopedia, <http://www.nlm.nih.gov/medlineplus/encyclopedia.html>.
- Lessard, P.; Wilson, W. D.; Olander, H. J.; Rogers, Q. R.; Mendel, V. E., 1986: Clinicopathologic study of horses surviving pyrrolizidine alkaloid (*Senecio vulgaris*) toxicosis. *American Journal of Veterinary Research* **47**, 1776–1780.
- Lewis, L. D., 1995a: Broodmare feeding and care. In: L. D. Lewis (ed.), *Equine Clinical Nutrition – Feeding and Care*, 1st edn. Williams & Wilkins, Baltimore, USA, pp. 286–306.
- Lewis, L. D., 1995b: Minerals for horses. In: L. D. Lewis (ed.), *Equine Clinical Nutrition – Feeding and Care*, 2nd edn. Williams & Wilkins, Baltimore, USA, pp. 19–41.
- Lewis, L. D., 1995c: Feeding and care of horses with health problems. In: L. D. Lewis (ed.), *Equine clinical nutrition – Feeding and Care*, 2nd edn. Williams & Wilkins, Baltimore, USA, pp. 289–299.
- Loynachan, A. T.; Bolin, D. C.; Hong, C. B.; Poonacha, K. B., 2007: Three equine cases of mixed hepatoblastoma with teratoid features. *Veterinary Pathology* **44**, 211–214.
- McGavin, M. D.; Knake, R., 1977: Hepatic midzonal necrosis in a pig fed aflatoxin and a horse fed moldy hay. *Veterinary Pathology* **14**, 182–187.
- McGorum, B. C.; Murphy, D.; Love, S.; Milne, E. M., 1999: Clinicopathological features of equine primary hepatic disease: a review of 50 cases. *Veterinary Record* **145**, 134–139.
- Mfitlodze, M. W.; Hutchinson, G. W., 1990: Prevalence and abundance of equine strongyles (Nematoda: Strongyloidea) in tropical Australia. *Journal of Parasitology* **76**, 487–494.
- Mirck, M. H., 1978: Studying the faeces for the presence of parasites in horses and ponies. *Tijdschrift voor Diergeneeskunde* **103**, 991–997.

- Moore, B. R.; Abood, S. K.; Hinchcliff, K. W., 1994: Hyperlipaemia in 9 miniature horses and miniature donkeys. *Journal of Veterinary Internal Medicine* **8**, 376–381.
- Morandi, F.; Frank, N.; Avenell, J.; Daniel, G. B., 2005: Quantitative assessment of hepatic function by means of  $^{99m}\text{Tc}$ -mebrofenin. *Journal of Veterinary Internal Medicine* **19**, 751–755.
- Moreira, I.; Mahan, D. C., 2002: Effect of dietary levels of vitamin E (all-rac-tocopheryl acetate) with or without added fat on weanling pig performance and tissue alpha-tocopherol concentration. *Journal of Animal Science* **80**, 663–669.
- Mullaney, T. P.; Brown, C. M., 1988: Iron toxicity in neonatal foals. *Equine Veterinary Journal* **20**, 119–124.
- Nansen, P.; Andersen, S.; Hesselholt, M., 1975: Experimental infection of the horse with *Fasciola hepatica*. *Experimental Parasitology* **37**, 15–19.
- Nation, P. N., 1989: Alsike clover poisoning: a review. *The Canadian Veterinary Journal* **30**, 410–415.
- Nation, P. N., 1991: Hepatic disease in Alberta horses: A retrospective study of 'alsike clover poisoning' (1973–1988). *The Canadian Veterinary Journal* **32**, 602–607.
- Naylor, J. M.; Kronfeld, D. S.; Acland, H., 1980: Hyperlipemia in horses: effects of undernutrition and disease. *American Journal of Veterinary Research* **41**, 899–905.
- Ober, D.; Hartmann, T., 1999: Homospermidine synthase, the first pathway-specific enzyme of pyrrolizidine alkaloid biosynthesis, evolved from deoxyhypusine synthase. *Proceedings of the National Academy of Sciences of the United States of America* **96**, 14777–14782.
- Ott, E. A., 2001: Protein and amino acids. In: J. D. Pagan, R. J. Geor (eds.), *Advances in Equine Nutrition II*. Nottingham University Press, Nottingham, UK, pp. 237–244.
- Patton, K. M.; Peek, S. F.; Valentine, B. A., 2006: Gastric adenocarcinoma in a horse with portal vein metastasis and thrombosis: a novel cause of hepatic encephalopathy. *Veterinary Pathology* **43**, 565–569.
- Pearson, E. G.; Andreasen, C. B., 2001: Effect of oral administration of excessive iron in adult ponies. *Journal of the American Veterinary Medical Association* **218**, 400–404.
- Pier, A. C.; Richard, J. L.; Cysewski, S. J., 1980: Implications of mycotoxins in animal disease. *Journal of the American Veterinary Medical Association* **176**, 719–724.
- Reid, S. W.; Mohammed, H. O., 1996: Survival analysis approach to risk factors associated with hyperlipemia in donkeys. *Journal of the American Veterinary Medical Association* **209**, 1449–1452.
- Roodenburg, A. J.; Leenen, R.; van het Hof, K. H.; Weststrate, J. A.; Tijburg, L. B.; , 2000: Amount of fat in the diet affects bioavailability of lutein esters but not of alpha-carotene, beta-carotene, and vitamin E in humans. *The American Journal of Clinical Nutrition* **71**, 1187–1193.
- Scarratt, W. K.; Furr, M. O.; Robertson, J. L., 1991: Hepatoencephalopathy and hypocalcemia in a miniature horse mare. *Journal of the American Veterinary Medical Association* **199**, 1754–1756.
- Schmidt, O.; Deegen, E.; Fuhrmann, H.; Dühlmeier, R.; Sallmann, H. P., 2001: Effects of fat feeding and energy level on plasma metabolites and hormones in Shetland ponies. *Journal of Veterinary Medicine. A, Physiology, Pathology, Clinical Medicine* **48**, 39–49.
- Schnabel, L. V.; Njaa, B. L.; Gold, J. R.; Meseck, E. K., 2006: Primary alimentary lymphoma with metastasis to the liver causing encephalopathy in a horse. *Journal of Veterinary Internal Medicine* **20**, 204–206.
- Small, A. C.; Kelly, W. R.; Seawright, A. A.; Mattocks, A. R.; Jukes, R., 1993: Pyrrolizidine alkaloidosis in a two month old foal. *Zentralbl Veterinarmed A* **40**, 213–218.
- Soulé, C.; Boulard, C.; Levieux, D.; Barnouin, J.; Plateau, E., 1989: Experimental equine fascioliasis: evolution of serologic, enzymatic and parasitic parameters. *Annales de recherches vétérinaires* **20**, 295–307.
- Spycher, C.; Zimmermann, A.; Reichen, J., 2001: The diagnostic value of liver biopsy. *Gastroenterology* **1**, 2–7.
- Srihahim, S.; Swerczek, T. W., 1978: Pathologic changes and pathogenesis of *Parascaris equorum* infection in parasite-free pony foals. *American Journal of Veterinary Research* **39**, 1155–1160.
- Theodorakis, M. C.; Bermudez, A. J.; Manning, J. P.; Kowitz, G. D.; Hillidge, C. J., 1982: Liver scintigraphy in ponies. *American Journal of Veterinary Research* **43**, 1561–1565.
- Vervuert, I.; Coenen, M., 2004: *Nutritional management in horses: selected aspects to gastrointestinal disturbances and geriatric horses*. Proceedings of the 2nd European Equine Nutrition & Health Congress, Lelystad, The Netherlands, 19–20 March. pp. 20–30.
- Vesonder, R.; Haliburton, J.; Stubblefield, R.; Gilmore, W.; Peterson, S., 1991: *Aspergillus flavus* and aflatoxins B1, B2, and M1 in corn associated with equine death. *Archives of Environmental Contamination and Toxicology*, **20**, 151–153.
- Watson, T., 1998: Equine hyperlipaemia. In: T. Watson (ed.), *Metabolic and Endocrine Problems of the Horse*. W.B. Saunders, Harcourt Brace and Company Ltd., London, pp. 23–40.
- Watson, T. D.; Murphy, D.; Love, S., 1992: Equine hyperlipaemia in the United Kingdom: clinical features and blood chemistry of 18 cases. *Veterinary Record* **131**, 48–51.
- West, H. J., 1996: Clinical and pathological studies in horses with hepatic disease. *Equine Veterinary Journal* **28**, 146–156.