



Review Article

Global epidemiology of sporotrichosis

Arunaloke Chakrabarti^{1,*}, Alexandro Bonifaz²,
Maria Clara Gutierrez-Galhardo³, Takashi Mochizuki⁴ and Shanshan Li⁵

¹Department of Medical Microbiology, Postgraduate Institute of Medical Education & Research, Chandigarh, India, ²Department of Mycology & Service of Dermatology, General Hospital of Mexico, México city, Mexico, ³Laboratório de Dermatologia Infecciosa, Instituto de Pesquisa Clínica Evandro Chagas, Fundação Oswaldo Cruz, Rio de Janeiro, Brazil, ⁴Department of Dermatology, Kanazawa Medical University, Uchinada, Kahoku, Ishikawa, Japan and ⁵Department of Dermatology and Venereology, First Hospital of Jilin University, Changchun, Jilin, China

*To whom correspondence should be addressed. Arunaloke Chakrabarti, Department of Medical Microbiology, Postgraduate Institute of Medical Education and Research (PGIMER), Chandigarh 160012, India. Tel: + 91 172 2755155; Fax: +91 172 2744401; E-mail: arunaloke@hotmail.com

Received 23 April 2014; Revised 11 July 2014; Accepted 18 August 2014

Abstract

Sporotrichosis is an endemic mycosis caused by the dimorphic fungus *Sporothrix schenckii sensu lato*. It has gained importance in recent years due to its worldwide prevalence, recognition of multiple cryptic species within the originally described species, and its distinctive ecology, distribution, and epidemiology across the globe. In this review, we describe the current knowledge of the taxonomy, ecology, prevalence, molecular epidemiology, and outbreaks due to *S. schenckii sensu lato*. Despite its omnipresence in the environment, this fungus has remarkably diverse modes of infection and distribution patterns across the world. We have delved into the nuances of how sporotrichosis is intimately linked to different forms of human activities, habitats, lifestyles, and environmental and zoonotic interactions. The purpose of this review is to stimulate discussion about the peculiarities of this unique fungal pathogen and increase the awareness of clinicians and microbiologists, especially in regions of high endemicity, to its emergence and evolving presentations and to kindle further research into understanding the unorthodox mechanisms by which this fungus afflicts different human populations.

Key words: sporotrichosis, epidemiology, taxonomy, *Sporothrix*, zoonoses.

Introduction

Sporotrichosis, an endemic disease caused by the dimorphic fungus *Sporothrix schenckii sensu lato*, is prevalent worldwide in tropical and subtropical areas. Patients with this infection usually present with “implantation mycoses” that is caused by transcutaneous trauma through which the fungal conidia enter the host. Such infections may progress into chronic cutaneous, subcutaneous, and/or even deeper

infections involving the lymphatics, fascia, muscles, cartilage, and bones. Although sporotrichosis causes considerable morbidity, it is only rarely associated with mortality. The etiological agents thrive in soil and decaying vegetation such as dead wood, sphagnum moss, cornstalks, and hay. Humans usually acquire the infection through traumatic inoculation of the fungus during outdoor activities such as farming, gardening, animal husbandry, and similar

occupations [1]. Among dimorphic fungal diseases, sporotrichosis stands out for the following distinctive characteristics: despite being an endemic fungal disease, its endemicity is widespread; the etiological agents are widely distributed in the environment; it is the only infection caused by a dimorphic agent in which the pulmonary system is not the major route of infection; its ecology, epidemiology, and clinical features vary across different geographical regions; and it is the only dimorphic fungal disease that seems to have substantial zoonotic transmission.

Sporotrichosis has emerged as a major fungal infection over the last two decades due to changes emerging in epidemiology, distribution, taxonomic evolution, and multiple outbreaks. Here, we present a treatise on the present status and global epidemiology of sporotrichosis.

Etiological agent and taxonomy

Ever since its isolation by Benjamin Schenck in 1898, the taxonomic position of *Sporothrix* species has remained an

enigma. Smith, a mycologist, identified the fungus isolated by Schenck as “*Sporotricha*” [2], and Howard confirmed its dimorphic nature in 1961 [3]. In 1962 Carmichael distinguished it from the basidiomycetous fungal group and classified it under *Sporotrichum* by identifying the septum and woronin body characteristic of this group [4]. The fungus was eventually named *Sporothrix schenckii*, and Guarro et al. classified the fungus under division *Ascomycota*, class *Pyrenomyces*, order *Ophistomatales*, family *Ophistomataceae* [5]. While no sexual stage has yet been identified, molecular analysis of the 18s region of ribosomal DNA suggests that *Ophistoma stenoceras* may represent its sexual form [6]. However, further examination of phenotypic and genotypic characteristics refuted such a possibility, though a sexual stage within the genus *Ophistoma* was not ruled out [7].

In 1979 Kwon-Chung first reported the heterogeneity of *Sporothrix schenckii sensu lato* strains. She noted that the isolates from lymphocutaneous and fixed cutaneous (Fig. 1a, b) forms of disease differed in their growth at

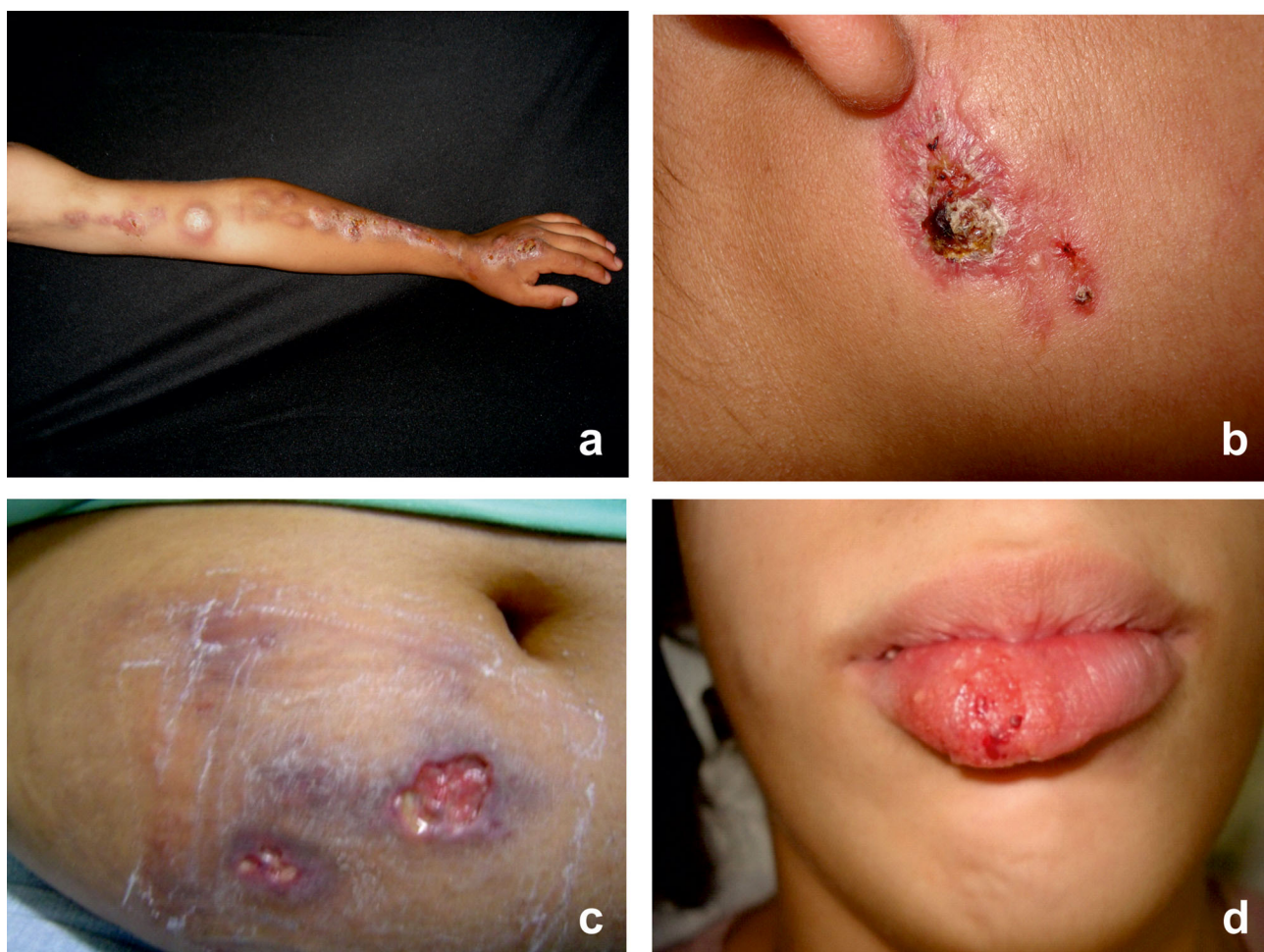

Figure 1. Different clinical presentations of sporotrichosis. (a) Lymphocutaneous sporotrichosis, (b) fixed cutaneous sporotrichosis, (c) ulcerating lesions in a patient who slept with her cat, (d) oro-labial sporotrichosis in a patient who kissed her cat.

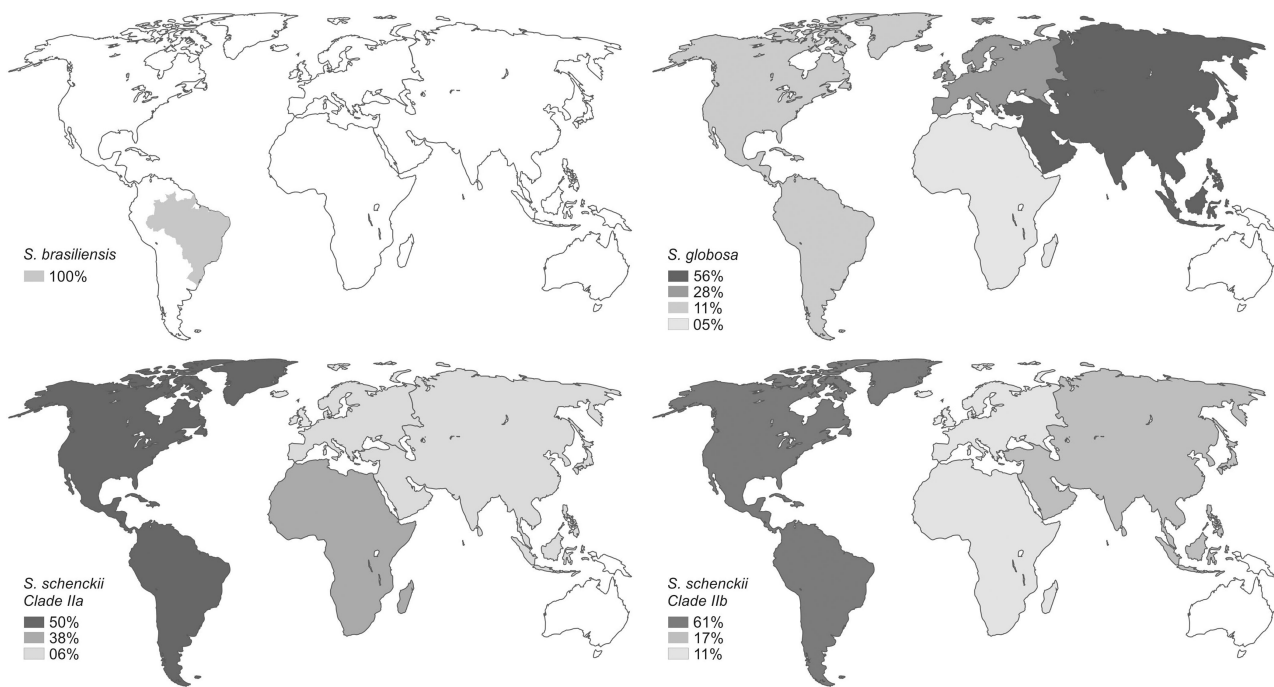


Figure 2. Global distribution of *Sporothrix brasiliensis*, *S. globosa*, *S. schenckii* clade IIa, and *S. schenckii* clade IIb. (Adapted from Zhou et al., 2013)

37°C and virulence in animal models [8]. However, this heterogeneity was better established by subsequent mitochondrial and ribosomal DNA analyses. Restriction fragment length polymorphism (RFLP) of different gene targets [9,10], random amplified polymorphic DNA (RAPD) analysis, DNA sequencing of internal transcribed spacer (ITS) regions of ribosomal DNA [11,12], amplified fragment length polymorphism (AFLP) [13], polymerase chain reaction (PCR) of DNA topoisomerase II gene [14], and M13 PCR fingerprinting of *S. schenckii* isolates corroborated the heterogeneity noted earlier [15]. Based on phylogeny of DNA and rDNA types, isolates were clustered into the following two groups: group A comprising most of the isolates from the United States and Latin America and group B comprising Asian isolates [9]. However, Marimon et al. [16,17] described six species based on sequence analysis of three protein-encoding loci (chitin synthase, β -tubulin, and calmodulin) and phenotypic characteristics (morphology of conidia; growth at 30°C, 35°C, and 37°C; and assimilation of sucrose, raffinose, and ribitol). Three were clinically relevant cryptic species under *S. schenckii* (*S. brasiliensis*, *S. globosa*, *S. luriei*) and two environmental fungi (*S. mexicana* and *S. albicans*), with the original *S. schenckii* now known as *S. schenckii sensu stricto*. *Sporothrix* species differ in their geographical distribution. *Sporothrix globosa* is distributed worldwide and has been recovered from clinical specimens in Europe (the United Kingdom, Spain, Italy), the United States, South America (Mexico, Guatemala, Columbia), and Asia (India, China, Japan). A recent study from

China described two clades for *S. globosa* [18]. Similarly, *S. schenckii sensu stricto* has wide geographical distribution and has been isolated from the Americas (Argentina, Bolivia, Brazil, Columbia, Guatemala, Mexico, Peru, the United States, Venezuela), Europe (France, Italy, the United Kingdom), Africa (South Africa), and Asia (Japan). *Sporothrix schenckii sensu stricto* is also classified into two clades, wherein clade IIa represents a homogenous clade that includes isolates from South America (Argentina, Bolivia, Columbia, Peru) and North American isolates. Clade IIb isolates, on the other hand, are geographically restricted to South America, particularly Peru and Argentina. Isolates from Asia and Africa have not been evaluated [19]. *Sporothrix brasiliensis* is an emerging species restricted to Brazil and is highly pathogenic to humans and animals [20]. *Sporothrix luriei* has been described from three human infections in Africa [21], Italy [22], and India [23] and a canine infection in Brazil [24]. *Sporothrix mexicana* has been recovered from the environment in Australia, Mexico, and Portugal and has been reported to cause occasional human infections [20]. Recently, a study of 124 isolates identified as *Sporothrix* ($n = 99$) and *Ophiostoma* ($n = 25$) species [25] elucidated the global distribution pattern of clinically important *Sporothrix* species (Fig. 2).

Ecology

Though *S. schenckii* is omnipresent in the environment in soil, dead wood, mosses, hay, and cornstalks, its ecology remains poorly understood. *Sporothrix schenckii sensu lato*

is strongly embedded in the genus *Ophiostoma*, members of which are primarily associated with bark beetles and Protea or plant pathogens [26,27]. *Sporothrix schenckii sensu lato* have never been observed as plant pathogens, as they fail to grow on living plants probably due to the antifungal activity of plants [28–30]. However, the fungus abundantly grows on dead wood. As Findlay and Vismer [31] showed, *S. schenckii* produces prolific conidia when a wood source is present in culture media. Further, Vismer and Eicker [32] studied 37 exotic and indigenous species of trees in order to ascertain species that can support the growth of this fungus and noted that the fungus grew best on *Acacia melanoxylon*, *Cinnamomum camphora*, *Eucalyptus grandis*, *E. sideroxylon*, and *Ginkgo biloba*.

Sporothrix schenckii sensu lato grows in the environment at a temperature of 22°C–27°C and 90% humidity. Organic material in the soil possibly helps its growth. It requires soil rich in cellulose, a temperature around 30°C, pH between 3.5 and 9.4, and high humidity [33]. Therefore, *S. schenckii sensu lato* has specific high-prevalence ecological niches within countries and regions in which it has been described as being endemic. However, the environmental niche of *S. schenckii* is not clearly understood; for example, sporotrichosis is prevalent both in Jilin province (average temperature of 2°C–6°C) and Guandong province (average temperature of 19°C–24°C) of China (L. Shanshan, unpublished data).

The fungus grows in mycelial form in the environment, producing abundant conidia. During occupational and recreational activities, humans tend to acquire the infection usually by traumatic implantation. The disease is also widely prevalent in warm-blooded animals including cats, dogs, armadillos, birds, and parrots. The fungus has also been isolated from aquatic fauna, mainly fishes and dolphins [34,35].

Prevalence of the disease

Since sporotrichosis is not a reportable disease, its exact prevalence is unknown, but the disease has been reported in the United States, South America (Brazil, Columbia, Guatemala, Mexico, Peru), Asia (China, India, Japan), and Australia [1]. After the large number of cases reported in France during the early part of the last century, the number of cases has decreased and the disease is rarely reported in Europe. In certain hyperendemic regions such as Peru, the incidence ranges from 48 to 98 cases per 100 000 persons [36], with a mean incidence of 156 per 100 000 persons in children [37]. In Japan, from 1946 to 1982, about 155 cases were reported every year [38,39], but this has decreased to 50 cases per year. In contrast, the number of cases has increased steadily in Brazil, with the Evandro Chagas Clin-

ical Research Institute in Rio de Janeiro reporting 759 human, 1503 cat, and 64 dog sporotrichosis cases between 1998 and 2004. These results stand in sharp contrast to 13 human cases noted from 1987 to 1997 [40]. More recently, Barros et al. [41] described approximately 2200 human and 3244 feline cases of sporotrichosis as having been diagnosed between 1998 and 2009 in Rio de Janeiro, Brazil. This is the largest cohort of human and animal sporotrichosis on record in the world, and it is expanding to neighboring states around Rio de Janeiro. In the Jalisco and Puebla mountain ranges of Mexico, sporotrichosis is hyperendemic, with a prevalence of 25 cases per 1000 inhabitants (Fig. 3) [42].

Distribution across age, gender, and occupations

Although specific age groups and/or genders are supposedly highly susceptible to sporotrichosis, the fact is that sporotrichosis can affect anyone regardless of age or gender; it all depends on exposure. Occupational and recreational habits specific to different populations increase the risk of infection. In Uruguay, for instance, sporotrichosis has a higher prevalence among males and armadillo hunters [19], as the former become infected from scratches received during armadillo hunting. In northeast India and Japan, there is a higher prevalence in females due to their greater engagement in agricultural activities [38,43]. Sporotrichosis in Brazil has two unique patterns of transmission, that is, through infected cats and dogs and via infected vegetative matter. Middle-aged women from low socioeconomic background who engage in domestic activities are frequently infected due to their exposure while caring for infected animals at home [44]. In South Africa, on the other hand, male patients outnumber females at a rate of 3:1 because men more frequently engage in outdoor and mining activities [45]. In the Peruvian Andes, children have three times higher incidence compared with adults. Case-controlled studies indicate that playing in crop fields and on dirty floors in houses are the possible modes of exposure in these children [13,37]. Interestingly, even infants have been reported to acquire sporotrichosis if exposed [46].

Outbreaks of sporotrichosis

Several small to large outbreaks of sporotrichosis, originating from a common source, have been reported worldwide. One of the largest outbreaks on record, affecting more than 3000 gold mine workers, has been described in South Africa. The possible *S. schenckii sensu lato* contamination of pit props used to maintain roofs of the mines was considered the source of the outbreak [47]. A cluster of 53 cases over 3 years in fishermen that was reported around

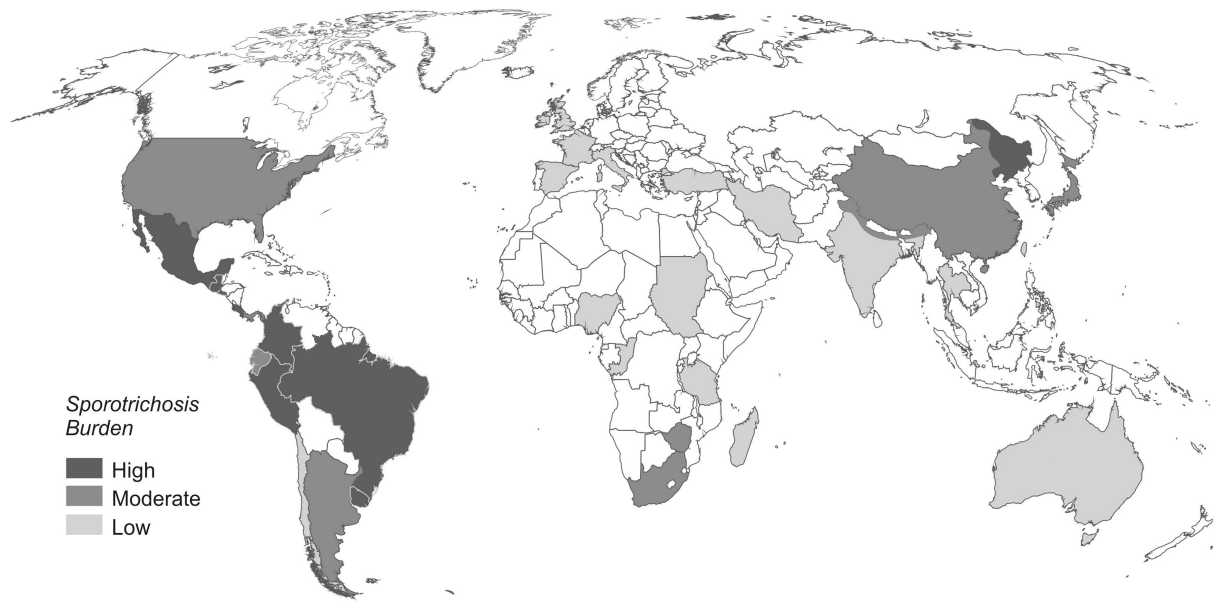


Figure 3. Distribution and relative burden of sporotrichosis throughout the world.

Lake Ayarza in Guatemala was the result of injuries involving contaminated fish [48]. In Florida, nine cases of sporotrichosis among 65 employees of a garden center (attack rate of 14%) were shown, through case-control multivariate analysis, to likely be due to contact with sphagnum moss for a period of 20 hours/week [49]. In Wisconsin, a large number of forest workers involved in packaging pine seedlings in sphagnum moss became infected, as did others engaged in similar activities in 14 other US states during the same period. Investigators tracked the possible source of the fungus to pine seedlings packed in sphagnum moss supplied by two nurseries in Pennsylvania [50,51]. Investigations of the recent Brazilian case clusters indicate that infected cats were the possible source of infection [52]. The clonality of *S. brasiliensis* isolates and the presence of the species only in the restricted region of Brazil support the common source of this large case cluster [20]. In a unique outbreak of sporotrichosis in China, 15 infants aged <10 months were found to be infected with the disease. Since no history of trauma or contact with any animal was reported, it was thought that contaminated cornstalks stacked by families for cooking and heating during the winter were the source of this outbreak [46].

Sporotrichosis as zoonoses

Among endemic mycoses, sporotrichosis is distinct in the supposed high prevalence of animal-to-human transmission of the disease. However, it is not clear how the yeast phase transmits the infection through this route since it is generally accepted that conidia of the mycelial phase are the

infectious propagules for humans. However, the evidence from several studies of feline transmission provides compelling support for this means of transmission [20,52]. In a study by the Evandro Chagas Clinical Research Institute, Rio de Janeiro, Brazil, 83% of patients and 85% of dogs were reported to have contact with cats, 56% of humans reported being bitten or scratched by a cat with sporotrichosis preceding the occurrence of the disease among owners, and *S. schenckii sensu lato* was isolated from the skin and nasal and oral cavities of the animals (Fig. 1c) [40]. In another study, it was reported that *S. brasiliensis* is highly prevalent among cats (96.9%) and that the genotypes of the fungus isolated from the cats were identical to those of *S. brasiliensis* from humans [20]. A case of sporotrichosis of the lips has been described in Brazil after a patient kissed an infected cat (Fig. 1d). In the lone case of possible feline transmission in India, samples from both patient and his domestic cat were positive for *S. schenckii sensu lato*; however, the patient presented in his medical history that he engaged in gardening activities as well [53]. Infected nine-banded armadillos may be another source of zoonotic transmission, given their predilection for spontaneous systemic sporotrichosis [54], which has been extensively reported in Uruguay among armadillo hunters.

Mode of spread

The mode of transmission of sporotrichosis has always been considered to be through traumatic implantation of *S. schenckii sensu lato* conidia from a contaminated source. However, occasional cases of pulmonary and disseminated

sporotrichosis have also been reported [55]; in these cases, the disease must have been acquired through a different route. In a review of 86 pulmonary sporotrichosis cases, 74% with primary pulmonary and 28% multifocal involvement, it was suggested that infection occurred through inhalation of the fungal conidia [55]. Sporadic pulmonary cases have been reported in immunosuppressed patients, especially those with the human immunodeficiency virus (HIV)/acquired immunodeficiency syndrome, although immunocompetent individuals rarely have also acquired pulmonary infections [55,56].

Sporotrichosis in Africa

Sporotrichosis has been reported regularly in South Africa since the first case was described in 1914 [45,57]. The mines in the country provide suitable conditions for *S. schenckii sensu lato* to thrive, and the disease has been reported from Gauteng province including Pretoria, Botswana, Mpumalanga, and North West provinces, especially among gold mine workers [45,58]. A small outbreak among workers handling bricks in the Pretoria region was described from 1959 to 1961 [59]. After those reported in South Africa, several cases were reported from Zimbabwe [60], with occasionally cases from Nigeria [61] and Sudan as well [62]. However, distribution of sporotrichosis in Africa has not been clearly mapped out because there are very few mycology laboratories across this continent.

Sporotrichosis in Australia

Sporotrichosis cases have been reported from Australia over the last three decades, especially in the eastern and western parts of the country. In Queensland, the disease was reported in bushwalkers, especially those who had contact with mouldy hay [63,64]. The disease has also been described from New South Wales, especially from February to April when the region experiences heavy rainfall [65]. However, the disease was extensively studied during the outbreak in western Australia in which the source was traced to hay. Molecular typing by pulsed field gel electrophoresis [66] and macrorestriction analysis [67] confirmed that the identity of clinical and hay isolates were the same. Furthermore, the isolates from western Australia were found to be different from those circulating in the eastern part of the country. The study had tremendous impact, as the number of cases markedly declined after the recommendation was made that long-sleeve shirts and gloves be worn when handling hay [67].

Sporotrichosis in Asia

Sporotrichosis in Japan

Sporotrichosis is the most frequently occurring deep cutaneous mycosis in Japan. According to a clinical review by Fukushima, about 2500 cases were reported between 1946 and 1982 and 155 new cases are being reported on average per year [38]. Since Fukushima's report, sporotrichosis has continuously been reported and there have been more than 3000 cases in Japan. However, the annual rate of new cases has decreased to fewer than 50 per year [39,68], and sporotrichosis is now rather rare in Japan. A multicenter epidemiological survey of dermatomycoses by the Japanese Society for Medical Mycology in 2006 showed that only 4 of 8717 cases of dermatomycoses were caused by *Sporothrix* spp. [69]. The reason for the decrease in the number of cases is unclear. Changing agricultural practices, with farmers no longer required to have direct contact with the soil in rural areas, and changing demographics in the Japanese population, with a decreasing number of children who are prone to acquire this disease, could be the reasons for recent decline. However, in certain areas, such as the northern part of Kyushu island and the central part of Honshu island, a significant number of patients are still observed. In addition, sporotrichosis appear to be spreading toward the northern parts of Japan where the land is often covered with snow, rendering it unsuitable for agriculture in winter.

Ishizaki and Kawasaki examined the global epidemiology of *Sporothrix* isolates through the use of restriction fragment length polymorphism analysis (RFLP) of mitochondrial DNA (mtDNA) and categorized the isolates into group A and group B [68]. This grouping was later supported by genetic analysis of membrane transporter gene [70] and RFLP analysis of ITS regions of the ribosomal RNA gene [11]. Correlating the above analysis with the recent classification described by Marimon et al. [71], *S. schenckii sensu stricto* is considered to be equivalent to mtDNA group A and *S. globosa* is considered to be equivalent to mtDNA group B. Ishizaki et al. [68] allocated 357 Japanese isolates of *Sporothrix* to these two groups by RFLP analysis of mtDNA and found that almost all were group B (342/357, 95.8%) and very few group A (15/357, 4.2%).

Sporotrichosis in China

Xinde Diao first reported clinical sporotrichosis in China in 1916, and Guoliang Yang presented the first culture-proven case in Shanghai in 1951 [72]. Since that time, more than 4000 cases from China have been described in the Chinese and English literature, but the exact incidence is not clear. Sporotrichosis had been noted in nearly all provinces of China, with the largest number of cases reported in Jilin

province of northeast China. *Sporothrix* isolates have been recovered from cornstalks, dead branches, rotten wood, sludge, soil, and tree bark in this region at a rate of 8.6% positives of 70 samples to 15% of 120 samples [73,74]. In the Ulan Hot of Neimenggu Autonomous Region next to Jilin, the isolation rate of *Sporothrix* from natural samples was 11.6% of 69 samples evaluated [75]. In southeast China, a study of environmental dematiaceous fungi in Jinwan area of Zhuhai, Guangdong province, confirmed the widespread presence of *Sporothrix* in nature (the isolation rate was 15% of 160 samples tested) [76], which was similar to the rate in northeast China and south China. Sporotrichosis has been reported in all provinces of China (Fig. 3) except Xizhang and Hainan. In addition to Jilin, sporotrichosis is very common in other provinces such as Heilongjiang and Liaoning in northeast China. In other parts of China, most of the sporotrichosis cases cluster in provinces along the Yangtze River (Sichuan, Jiangsu) and provinces in southeast China (Guangdong and Guangxi). However, the burden appears to be much lower than that in northeast China where most patients are farmers or residents of rural areas.

Most reports from north China, note the incidence is higher during cold seasons when the temperature is usually below zero. A possible source could be the cornstalks, reeds, and branches these farmers stock and use for cooking and heating. The fungus that thrives on this material can cause in-door contamination, as *Sporothrix* species have been isolated from stacked cornstalks and, as a result, may be an important factor for the high incidence in cold seasons [77]. A study of childhood sporotrichosis from Hubei province in south China also noted a high incidence during winters, though the temperatures there are much higher than in northeast China. The authors concluded that the incidence was lower when the temperature and moisture were high and the air pressure was low [78]. However, the onset of disease with the change in season was interesting despite the marked differences in climate, modes of agriculture, and lifestyles.

There have been some recorded outbreaks of sporotrichosis in China; for example, 87 villagers contracted sporotrichosis after they received intramuscular injections from six village doctors from September 1995 to January 1996 [79]. All patients lived in a 47.3-km² area of Shibeit Township in Sichuan province and received the injections one to six months before the onset of symptoms; all initial lesions manifested at the injection site. *Sporothrix* was isolated from the syringes that were believed to be the source of this outbreak. During 1991–1993, more than 400 villagers contracted sporotrichosis after floods in China [80]. Most of the patients gave a history of contact with reeds, and investigators eventually isolated

Sporothrix from these plant sources. Among the patients, 78.0% had involvement on their faces and 79.9% manifested a fixed form of sporotrichosis. In 1998, the Nen River flooded, ravaging Heilongjiang province. Three to six months after the disaster, 224 villagers from three villages along the river were diagnosed with sporotrichosis [81]. These patients had collected reeds washed ashore by the floods and had stored them for domestic use. Close to half (45.2%) of the patients also had family members who had simultaneously contracted the infection. All patients had lesions on exposed parts of the face and upper extremities, though the rate of obvious trauma was low (15.2%).

Several molecular epidemiological studies of sporotrichosis have been conducted in China. RAPD analyses of strains from different regions have delineated certain geographical differences [82–84]. The ITS and nontranscribed spacer regions of ribosomal DNA analyses have also shown differences between strains causing disseminated disease and those causing other forms of sporotrichosis [85]. Molecular studies confirm *S. globosa* as the most prevalent strain in China [18,86,87].

Sporotrichosis in India

The first case of sporotrichosis in India was reported by Ghosh in 1932 [88]. Though sporotrichosis cases have been reported throughout India, the disease is prevalent primarily in the sub-Himalayan region in the north, the northeast states, and certain pockets of south Karnataka [52,89,90]. In an explorative population-based study using sporotrichin and peptido–rhabdomannan skin test antigens, the Kangra region of Himachal Pradesh state was identified as an endemic area [91]. In this survey, the rate of skin test positivity in “test” villages (as defined by a minimum of two cases per village) ranged from 23% to 40% in comparison with 6.5% to 7.6% in “control” villages. The skin test positivity rate was high in those who were older (>55y age) and in people engaged in horticulture or agricultural activities [91]. The study helped increase awareness in the local community. A recent single-center investigation from the same area reported 306 cases over an 18.5-year period [92], with the infection rate seeming to spike during March and April, though these months are usually dry. The fungus has been isolated from soil and cornstalks in the same region [89]. Lymphocutaneous sporotrichosis is more common than the fixed cutaneous type of disease throughout India (Fig. 1a,b) [41]. Molecular typing studies of Indian isolates found them to be homogeneous with other Asian isolates [9]. The isolates are largely *S. globosa*, apart from rare sporadic cases of pulmonary sporotrichosis due to *S. luriei*, such as those reported from north India [23].

Sporotrichosis in the Americas

The largest outbreak of sporotrichosis in the United States occurred in 1988 and involved 84 cases across 15 states, affecting workers involved in reforestation programs. The cases were associated with exposure to sphagnum moss used for packing pine seedlings that were supplied by a nursery in Pennsylvania [93]. An outbreak from contaminated hay has also been described [94].

The incidence of sporotrichosis varies among Latin American countries, with endemic areas found in Brazil, Colombia, Costa Rica, Guatemala, Mexico, and Uruguay [95–97]. The estimated prevalence rates of sporotrichosis range from 0.1% to 0.5% in Brazil, Colombia, El Salvador, Mexico, Uruguay, and Venezuela to 0.01% to 0.02% in Argentina, Ecuador, and Panama; the disease is extremely rare in Chile [95,96]. In some regions of South America, the disease occurs more frequently during humid autumn and summer seasons, whereas in Mexico, the incidence spikes during the cold and dry seasons [96,97].

Sporotrichosis epidemiology in Brazil has been largely elucidated from large descriptive case series. Historically, the classic route of transmission has been traumatic inoculation of the etiologic agent while handling organic matter, as is prevalent in other countries. The majority of cases are adult men who have frequent contact with soil as part of their occupation [98,99]. However, since the late 1990s, sporotrichosis in the Rio de Janeiro state of Brazil has become an urban endemic/epidemic phenomenon, with transmission from infected cats to humans [100–102]. The high prevalence of cases from the metropolitan area of Rio de Janeiro (the capital city of Rio de Janeiro state) has created a sporotrichosis belt in this region [102]. The majority people there are from poor socioeconomic backgrounds, and health services are scarce in this region. Female patients with a mean age of 39 years predominate, and the majority acquire the disease through domiciliary or professional contact (bite or scratch) with cats infected with sporotrichosis (Fig. 1c,d) [100–102]. The number of cases has been continuously increasing for more than 15 years; at present, there are more than 4000 cases on record at the Reference Unit of Infectious Dermatology. In one of the largest case series recorded to date, Freitas et al. [103] described the clinical manifestations and evolution of sporotrichosis in HIV-infected patients. Today, sporotrichosis, irrespective of HIV infection, is a major cause of hospitalization and mortality in Rio de Janeiro [102].

Sporotrichosis in Mexico occurs primarily in regions with a tropical and humid climate. While cases have been reported throughout the country, the highest burden has been noted in two zones—the states of Jalisco and Puebla [104–106]. The state of Jalisco in western Mexico recorded

more than 1000 proven cases [104,105], and the state of Puebla in central Mexico has the second-highest prevalence [106]. Fewer cases have been reported there compared with Jalisco. However, a recent study based on intradermal skin tests found that 53.2% of inhabitants were reactive to sporotrichin, the majority being children aged 11–15 years [42]. Overall, the primary epidemiological features of sporotrichosis in Mexico are that the disease occurs in persons of all ages, about 70% being young adults and 30% being children, and the disease may be more common in remote areas such as the mountains of Puebla and Guerrero [42,107] where the frequency can reach up to 50%, which is similar to the burden reported in the mountains of Acambay [36,95]. There is no gender difference with the male-to-female ratio of infection being equal. There are two peaks in the age distribution curve, the first is school-aged children (30% of all cases) [105,108,109] and the second is young adults aged 16–35 years (50% of the cases). Most patient's report disease onset subsequent to different types of trauma including handling flowers and plants and bites by rodents such as rats, mice, and squirrels. In general, the disease is observed in temperate and humid climates, with an average temperature between 20°C and 25°C and a relative humidity above 90% [1,107]. Although cases occur year-round, the incidence increases during late fall to early winter, which also marks the end of the rainy season and offers conducive temperature and humidity for proliferation of *S. schenckii*. The disease is noted primarily among farmers, housewives who participate in farming activities, school-aged children, and flower vendors. Sporadic outbreaks in nonendemic areas are due to accidental contact with contaminated material [1,107,110,111]. Since sporotrichosis is not a reportable condition, its exact prevalence remains unknown. However, it is evident that there are regions of high endemicity, with an incidence of 25 cases per 1000 population in Xilocaautla, Puebla [42]. The few molecular epidemiological studies that have been conducted in Mexico reveal *S. schenckii sensu stricto* as the main etiological agent in approximately 90% of cases, with *S. globosa* and *S. mexicana* afflicting patients to a lesser extent [112].

In Venezuela, most sporotrichosis patients are aged <30 years (66.15%), with the most common occupation being students (37.6%) followed by farmers (29.3%) and housewives (6.8%). Interestingly, the mode of transmission could not be identified in 61.6% of the cases [113].

In Uruguay, armadillo hunting has been associated with sporotrichosis. Conti-Diaz reported 138 cases of sporotrichosis over a 16-year period during which 81% were attributed to contact with armadillos [96]. Similar trends have been noted recently in Argentina and southern Brazil where cases were associated with hunting of armadillos [114,115].

It has been hypothesized that a change in environmental factors in Rio Grande do Sul, Brazil, that is, a shift from raising cattle to cultivating soybeans, has contracted the natural savannah habitat of armadillos, diminishing space available for them to burrow, thereby rendering them more vulnerable to hunting [115].

There have been isolated case reports from Costa Rica, El Salvador, Guatemala, Honduras, and Nicaragua. The largest number of cases has been reported in Guatemala where an epidemic occurred around a lake in Ayarza District (South) involving the handling of fish [48,107]. It is speculated that there are several more cases but few are reported.

Sporotrichosis in Europe

Sporotrichosis is rare in Europe. It virtually disappeared from Europe after the Great War of 1914–1918 [22]. In addition to occasional sporadic cases, a sizable number of infections have been observed in returning travellers, aid workers, archaeologists, and immigrants [116]. A few ecological niches have been reported in southern Italy and around the Mediterranean region. A total of 58 cases were described in Italy from 1962 to 1992, with 42 (73.7%) being from Apulia in southern Italy. *Sporothrix schenckii* var. *lurei* has also been reported in Italy [22]. More recently, the first cases of sporotrichosis were reported in Calabria and Sicily in southern Italy [117], and a case of sporotrichosis in a hunting dog has also been noted [118]. Interestingly, 26 isolates of *S. schenckii sensu lato* were recently recovered from commercial garden soils in southern Italy, providing the first evidence of an environmental reservoir of *Sporothrix* species in this region [119]. Sporotrichosis is rarely seen on the British Isles; very few cases were recorded prior to 1911 and only 16 cases from 1911 to 1968 have been described [120]. France witnessed a sizable number of cases before the Great War, after which the incidence rapidly declined. Six cases were identified in a survey of small mammals in France [121]. More recently, an autochthonous case was reported in a man engaged in an occupation predisposing him to contact with soil [122]. Two cases of Mediterranean sporotrichosis have been reported in Barcelona province [123]. A case of sporotrichosis of the feet due to *S. mexicana* was diagnosed in Portugal in 2009, presumably acquired from travel abroad to Malaysia [124], and, more recently, the first autochthonous case from Portugal was reported, caused by *S. globosa* [125].

Acknowledgment

We acknowledge help from Dr Prashant Sood in preparation of the manuscript and illustrations.

Declaration of interest

The authors report no conflicts of interest. The authors alone are responsible for the content and the writing of the paper.

References

1. Barros MB, de Almeida Paes R, Schubach AO. *Sporothrix schenckii* and sporotrichosis. *Clin Microbiol Rev* 2011; **24**: 633–654.
2. Schenck BR. On refractory subcutaneous abscess caused by a fungus possibly related to the Sporotricha. *Bull Johns Hopkins Hosp* 1898; **9**: 286–290.
3. Howard DH. Dimorphism of *Sporotrichum schenckii*. *J Bacteriol* 1961; **81**: 464–469.
4. Carmichael JW. *Chrysosporium* and some other aleuriosporic hypomycetes. *Canad J Bot* 1962; **40**: 1137–1173.
5. Guarro J, Gene J, Stchigel AM. Developments in fungal taxonomy. *Clin Microbiol Rev* 1999; **12**: 454–500.
6. Berbee ML, Taylor JW. Convergence in ascospore discharge mechanism among pyrenomycete fungi based on 18S ribosomal RNA gene sequence. *Mol Phylogenet Evol* 1992; **1**: 59–71.
7. Oliveira MM, Almeida-Paes R, Gutierrez-Galhardo MC, Zancope-Oliveira RM. Molecular identification of the *Sporothrix schenckii* complex. *Rev Iberoam Micol* 2014; **31**: 2–6.
8. Kwon-Chung KJ. Comparison of isolates of *Sporothrix schenckii* obtained from fixed cutaneous lesions with isolates from other types of lesions. *J Infect Dis* 1979; **139**: 424–431.
9. Ishizaki H, Kawasaki M, Anzawa K et al. Mitochondrial DNA analysis of *Sporothrix schenckii* in India, Thailand, Brazil, Colombia, Guatemala and Mexico. *Nihon Ishinkin Gakkai Zasshi* 2009; **50**: 19–26.
10. Lin J, Kawasaki M, Aoki M et al. Mitochondrial DNA analysis of *Sporothrix schenckii* clinical isolates from China. *Mycopathologia* 1999; **148**: 69–72.
11. Watanabe S, Kawasaki M, Mochizuki T, Ishizaki H. RFLP analysis of the internal transcribed spacer regions of *Sporothrix schenckii*. *Nihon Ishinkin Gakkai Zasshi* 2004; **45**: 165–175.
12. Zhang Z, Liu X, Yang G, Gao X, Jin L, An L. Genotyping of *Sporothrix schenckii* by analysis of ribosomal DNA regions. *Mycoses* 2006; **49**: 305–310.
13. Neyra E, Fonteyne PA, Swinne D et al. Epidemiology of human sporotrichosis investigated by amplified fragment length polymorphism. *J Clin Microbiol* 2005; **43**: 1348–1352.
14. Kanbe T, Natsume L, Goto I et al. Rapid and specific identification of *Sporothrix schenckii* by PCR targeting the DNA topoisomerase II gene. *J Dermatol Sci* 2005; **38**: 99–106.
15. Galhardo MC, DeOliveira RM, Valle AC et al. Molecular epidemiology and antifungal susceptibility patterns of *Sporothrix schenckii* isolates from a cat-transmitted epidemic of sporotrichosis in Rio de Janeiro, Brazil. *Med Mycol* 2008; **46**: 141–151.
16. Marimon R, Gene J, Cano J et al. Molecular phylogeny of *Sporothrix schenckii*. *J Clin Microbiol* 2006; **44**: 3251–3256.
17. Marimon R, Gene J, Cano J, Guarro J. *Sporothrix luriei*: a rare fungus from clinical origin. *Med Mycol* 2008; **46**: 621–625.
18. Yu X, Wan Z, Zhang Z, Li F, Li R, Liu X. Phenotypic and molecular identification of *Sporothrix* isolates of clinical origin in Northeast China. *Mycopathologia* 2013; **176**: 67–74.

19. Rodrigues AM, Bagagli E, de Camargo ZP, de Moraes Gimenes Bosco S. *Sporothrix schenckii sensu stricto* isolated from soil in an armadillo's burrow. *Mycopathologia* 2014; **177**: 199–206.
20. Rodrigues AM, de Melo Teixeira M, de Hoog GS et al. Phylogenetic analysis reveals a high prevalence of *Sporothrix brasiliensis* in feline sporotrichosis outbreaks. *PLoS Negl Trop Dis* 2013; **7**: e2281.
21. Ajello L, Kaplan W. A new variant of *Sporothrix schenckii*. *Mykosen* 1969; **12**: 633–644.
22. Alberici F, Paties CT, Lombardi G et al. *Sporothrix schenckii* var *luriei* as the cause of sporotrichosis in Italy. *Eur J Epidemiol* 1989; **5**: 173–177.
23. Padhye AA, Kaufman L, Durry E et al. Fatal pulmonary sporotrichosis caused by *Sporothrix schenckii* var. *luriei* in India. *J Clin Microbiol* 1992; **30**: 2492–2494.
24. Oliveira DC, Lopes PG, Spader TB et al. Antifungal susceptibilities of *Sporothrix albicans*, *S. brasiliensis*, and *S. luriei* of the *S. schenckii* complex identified in Brazil. *J Clin Microbiol* 2011; **49**: 3047–3049.
25. Zhou X, Rodrigues A, Feng P, Hoog GS. Global ITS diversity in the *Sporothrix schenckii* complex. *Fungal Diversity* 2013: 1–13.
26. Zipfel RD, de Beer ZW, Jacobs K, Wingfield BD, Wingfield MJ. Multi-gene phylogenies define *Ceratocystiopsis* and *Grosmanina* distinct from *Ophiostoma*. *Stud Mycol* 2006; **55**: 75–97.
27. Roets F, Wingfield BD, de Beer ZW, Wingfield MJ, Dreyer LL. Two new *Ophiostoma* species from *Protea caffra* in Zambia. *Persoonia* 2010; **24**: 18–28.
28. Gordon MA, Lapa EW, Fitter MS, Lindsay M. Susceptibility of zoopathogenic fungi to phytoalexins. *Antimicrob Agents Chemother* 1980; **17**: 120–123.
29. Masoko P, Mdee LK, Mampuru LJ, Eloff JN. Biological activity of two related triterpenes isolated from *Combretum nelsonii* (Combretaceae) leaves. *Nat Prod Res* 2008; **22**: 1074–1084.
30. Masoko P, Picard J, Howard RL, Mampuru LJ, Eloff JN. *In vivo* antifungal effect of *Combretum* and *Terminalia* species extracts on cutaneous wound healing in immunosuppressed rats. *Pharm Biol* 2010; **48**: 621–632.
31. Findlay GH, Vismar HF. Studies in sporotrichosis: fungal morphogenesis and pathogenicity in differing environments. *Mycopathologia* 1986; **96**: 115–122.
32. Vismar HF, Eicker A. Growth of human pathogenic isolates of *Sporothrix schenckii* on indigenous and exotic wood species in South Africa. *Mycol Res* 1994; **98**: 121–124.
33. Noriega CT, Garay RR, Sabanero G, Basurto RT, Sabanero-Lopez M. *Sporothrix schenckii*: cultures in different soils. *Rev Latinoam Micol* 1993; **35**: 191–194 [in Spanish].
34. Haddad VJ, Miot HA, Bartoli LD, Cardoso Ade C, de Camargo RM. Localized lymphatic sporotrichosis after fish-induced injury (*Tilapia* sp.). *Med Mycol* 2002; **40**: 425–427.
35. Migaki G, Font RL, Kaplan W, Asper ED. Sporotrichosis in a Pacific white-sided dolphin (*Lagenorhynchus obliquidens*). *Am J Vet Res* 1978; **39**: 1916–1919.
36. Pappas PG, Tellez I, Deep AE et al. Sporotrichosis in Peru: description of an area of hyperendemicity. *Clin Infect Dis* 2000; **30**: 65–70.
37. Lyon GM, Zurita S, Casquero J et al. Population-based surveillance and a case-control study of risk factors for endemic lymphocutaneous sporotrichosis in Peru. *Clin Infect Dis* 2003; **36**: 34–39.
38. Fukushima R. Epidemiology and ecology of sporotrichosis in Japan. *Zentralbl Bakteriol Mikrobiol Hyg A* 1984; **257**: 228–233.
39. Mochizuki T, Anzawa K. Deep mycosis in Japan. In: Eun HC, Kim SC, Lee WS, (eds). *Aging and skin diseases*. Special book of the 22nd World Congress of Dermatology; 2011; Seoul, Korea: Medrang Inc: 393–397.
40. Schubach A, Barros MB, Wanke B. Epidemic sporotrichosis. *Curr Opin Infect Dis* 2008; **21**: 129–133.
41. Barros MB, Schubach TP, Coll JO et al. Sporotrichosis: development and challenges of an epidemic. *Rev Panam Salud Publica* 2010; **27**: 455–460.
42. Bonifaz A, Araiza J, Pérez-Mejía A, Ochoa LA, Toriello C. Intradermal test with sporotrichin in a community in the Sierra Norte de Puebla. *Dermatol Rev Mex* 2013; **57**: 428–432 [in Spanish].
43. Bhutia PY, Gurung S, Yegneswaran PP et al. A case series and review of sporotrichosis in Sikkim. *J Infect Dev Ctries* 2011; **5**: 603–608.
44. Barros MB, Schubach AO, Schubach TM, Wanke B, Lambert-Passos SR. An epidemic of sporotrichosis in Rio de Janeiro, Brazil: epidemiological aspects of a series of cases. *Epidemiol Infect* 2008; **136**: 1192–1196.
45. Vismar HF, Hull PR. Prevalence, epidemiology and geographical distribution of *Sporothrix schenckii* infections in Gauteng, South Africa. *Mycopathologia* 1997; **137**: 137–143.
46. Song Y, Yao L, Zhong SX et al. Infant sporotrichosis in north-east China: a report of 15 cases. *Int J Dermatol* 2011; **50**: 522–529.
47. Helm MAF, Berman C. The clinical, therapeutic and epidemiological features of the sporotrichosis infection on the mines. In: Sporotrichosis infection on mines of the Witwatersrand. Proceedings of the Transvaal Mine Medical Officers' Association, Dec 1944. Johannesburg, South Africa: The Transvaal Chamber of Mines; 1947: 59–67.
48. Mayorga R, Caceres A, Toriello C et al. An endemic area of sporotrichosis in Guatemala. *Sabouraudia* 1978; **16**: 185–198 [in Spanish].
49. Hajjeh R, McDonnell S, Reef S et al. Outbreak of sporotrichosis among tree nursery workers. *J Infect Dis* 1997; **176**: 499–504.
50. Cote TR, Kasten MJ, England AC, 3rd. Sporotrichosis in association with Arbor Day activities. *N Engl J Med* 1988; **319**: 1290–1291.
51. Grotte M, Younger B. Sporotrichosis associated with sphagnum moss exposure. *Arch Pathol Lab Med* 1981; **105**: 50–51.
52. Schubach A, Schubach TM, Barros MB, Wanke B. Cat-transmitted sporotrichosis, Rio de Janeiro, Brazil. *Emerg Infect Dis* 2005; **11**: 1952–1954.
53. Yegneswaran PP, Sripathi H, Bairy I et al. Zoonotic sporotrichosis of lymphocutaneous type in a man acquired from a domesticated feline source: report of a first case in southern Karnataka, India. *Int J Dermatol* 2009; **48**: 1198–1200.

54. Kaplan W, Broderson JR, Pacific JN. Spontaneous systemic sporotrichosis in nine-banded armadillos (*Dasypus novemcinctus*). *Sabouraudia* 1982; 20: 289–294.
55. Aung AK, Teh BM, McGrath C, Thompson PJ. Pulmonary sporotrichosis: case series and systematic analysis of literature on clinico-radiological patterns and management outcomes. *Med Mycol* 2013; 51: 534–544.
56. Callens SF, Kitetele F, Lukun P et al. Pulmonary *Sporothrix schenckii* infection in a HIV positive child. *J Trop Pediatr* 2006; 52: 144–146.
57. Pijper A, Pullinger BD. An outbreak of sporotrichosis among South African native miners. *The Lancet* 1927; 210: 914–916.
58. Quintal D. Sporotrichosis infection on mines of the Witwatersrand. *J Cutan Med Surg* 2000; 4: 51–54.
59. Findlay GH. The epidemiology of sporotrichosis in the Transvaal. *Sabouraudia* 1970; 7: 231–236.
60. Ross MD, Gelfand M. Deep fungal infections in Rhodesia—a 10-year survey of histological material. Part I. *Cent Afr J Med* 1978; 24: 208–212.
61. Jacyk WK, Lawande RV, Tulpule SS. Deep mycoses in West Africa: a report of 13 cases and review of the Nigerian literature. *J Natl Med Assoc* 1981; 73: 251–256.
62. Gumaa SA. Sporotrichosis in Sudan. *Trans R Soc Trop Med Hyg* 1978; 72: 637–640.
63. Conias S, Wilson P. Epidemic cutaneous sporotrichosis: report of 16 cases in Queensland due to mouldy hay. *Australas J Dermatol* 1998; 39: 34–37.
64. Pinn TG. Sporotrichosis in a Queensland bushwalker. *Med J Aust* 1998; 169: 287.
65. Sivagnanam S, Bannan AM, Chen SC, Ralph AP. Sporotrichosis (*Sporothrix schenckii*) infection in the New South Wales mid-north coast, 2000–2010. *Med J Aust* 2012; 196: 588–590.
66. Feeney KT, Arthur IH, Whittle AJ, Altman SA, Speers DJ. Outbreak of sporotrichosis, Western Australia. *Emerg Infect Dis* 2007; 13: 1228–1231.
67. O'Reilly LC, Altman SA. Macrorestriction analysis of clinical and environmental isolates of *Sporothrix schenckii*. *J Clin Microbiol* 2006; 44: 2547–2552.
68. Ishizaki H, Kawasaki M. Molecular epidemiology of *Sporothrix schenckii*. *Nihon Ishinkin Gakkai Zasshi* 2000; 41: 245–249 [in Japanese].
69. Sei Y. 2006 Epidemiological survey of dermatomycoses in Japan. *Med Mycol J* 2012; 53: 185–192 [in Japanese].
70. Sugita Y. Molecular analysis of DNA polymorphism of *Sporothrix schenckii*. *Nihon Ishinkin Gakkai Zasshi* 2000; 41: 11–15.
71. Marimon R, Cano J, Gene J et al. *Sporothrix brasiliensis*, *S. globosa*, and *S. mexicana*, three new *Sporothrix* species of clinical interest. *J Clin Microbiol* 2007; 45: 3198–3206.
72. Wu SX. Sporotrichosis in China. *Chin J Zoonoses* 1991; 7: 53–54.
73. Jin XZ, Li FQ, Zhu MJ et al. Isolation of *Sporothrix* from reed and soil. *Chin J Dermatol* 1998; 31: 298–299.
74. Tian YP, Zhong SX, Zhang CY, Jin XZ. Isolation of *Sporothrix schenckii* and dematiaceous fungi. *J Jilin Univ (Medicine Edition)* 2004; 30: 360–365.
75. Jiang CY, Li JQ, Jin XZ et al. Study on ecology of *Sporothrix schenckii* and dematiaceous fungi in Ulan Hot. *J Clin Dermatol* 2001; 30: 223–224.
76. Ji Q, Xiang Y, Luo QP et al. The ecologic features of *Sporothrix schenckii* and dematiaceous fungi in Jinwan district of Zhuhai City in Guangdong Province. *Diag Ther J Dermatovenereology* 2010; 17: 28–30.
77. Song Y, Li SS, Zhong SX et al. Report of 457 sporotrichosis cases from Jilin province, northeast China, a serious endemic region. *J Eur Acad Dermatol Venereol* 2013; 27: 313–318.
78. Li YA, Xiao XF, Zeng LJ. Clinical analysis of 62 cases of children sporotrichosis. *Chin J Pract Ped* 2003; 18: 285–286.
79. Dai GW, Ding Z, Cao LQ et al. Report of 87 sporotrichosis cases in an outbreak. *Chin J Dermatol* 1997; 30: 340.
80. Li HY, Song J, Zhang Y et al. Epidemiological investigation of sporotrichosis in Zhaodong, Heilongjiang. *Chin J Dermatol* 1995; 28: 401–402.
81. Yang FZ, Li YZ, Yao JY. Clinical analysis of 224 cases of cutaneous dermatology. *Chin J Zoonoses* 2005; 21: 59–60.
82. Wang J, You G, Wang XH, Li RY. RAPD typing research of *Sporothrix schenckii*. *J Clin Dermatol* 2006; 35: 451–452.
83. Lian CH, Jin LJ, Liu XM. Characterization of *Sporothrix schenckii* by random amplification of polymorphic DNA assay. *Chin J Dermatol* 2001; 34: 355–357.
84. Kong X, Xiao T, Lin J, Wang Y, Chen HD. Relationships among genotypes, virulence and clinical forms of *Sporothrix schenckii* infection. *Clin Microbiol Infect* 2006; 12: 1077–1081.
85. Zhang Z, Liu X, Lv X, Lin J. Variation in genotype and higher virulence of a strain of *Sporothrix schenckii* causing disseminated cutaneous sporotrichosis. *Mycopathologia* 2011; 172: 439–446.
86. Tan JW, Liu W, Wan Z, Li RY. Reclassification of 33 clinical strains of *Sporothrix* from northern China based on phenotypic and molecular characters. *Mycosystema* 2013; 32: 161–167.
87. Liu TT, Zhang K, Zhou X. Molecular identification of *Sporothrix* clinical isolates in China. *J Zhejiang Univ Sci B* 2014; 15: 100–108.
88. Ghosh LM. An unusual case of sporotrichosis. *Indian Med Gaz* 1932; 67: 570.
89. Mehta KI, Sharma NL, Kanga AK, Mahajan VK, Ranjan N. Isolation of *Sporothrix schenckii* from the environmental sources of cutaneous sporotrichosis patients in Himachal Pradesh, India: results of a pilot study. *Mycoses* 2007; 50: 496–501.
90. Chakrabarti A, Roy SK, Dhar S, Kumar B. Sporotrichosis in north-west India. *Indian J Med Res* 1994; 100: 62–65.
91. Ghosh A, Chakrabarti A, Sharma VK, Singh K, Singh A. Sporotrichosis in Himachal Pradesh (north India). *Trans R Soc Trop Med Hyg* 1999; 93: 41–45.
92. Verma S, Verma GK, Singh G et al. Sporotrichosis in sub-Himalayan India. *PLoS Negl Trop Dis* 2012; 6: e1673.
93. Centers for Disease Control and Prevention. Multistate outbreak of sporotrichosis in seedling handlers. *Morb Mortal Wkly Rep* 1988; 37: 652–653.
94. Dooley DP, Bostic PS, Beckius ML. Spook house sporotrichosis. A point-source outbreak of sporotrichosis associated with hay bale props in a Halloween haunted-house. *Arch Intern Med* 1997; 157: 1885–1887.

95. Bustamante B, Campos PE. Endemic sporotrichosis. *Curr Opin Infect Dis* 2001; **14**: 145–149.
96. Conti-Diaz IA. Epidemiology of sporotrichosis in Latin America. *Mycopathologia* 1989; **108**: 113–116.
97. Queiroz-Telles F, Nucci M, Colombo AL, Tobon A, Restrepo A. Mycoses of implantation in Latin America: an overview of epidemiology, clinical manifestations, diagnosis and treatment. *Med Mycol* 2011; **49**: 225–236.
98. Sampaio SAP, Lacaz CS, Almeida F. Clinical aspects of sporotrichosis in Sao Paulo—analysis of 235 cases. *Rev Hosp Clin Fac Med Sao Paulo* 1954; **9**: 391–402 [in Portuguese].
99. daRosa AC, Scroferneker ML, Vettorato R et al. Epidemiology of sporotrichosis: a study of 304 cases in Brazil. *J Am Acad Dermatol* 2005; **52**: 451–459.
100. Barros MB, Schubach Ade O, do Valle AC et al. Cat-transmitted sporotrichosis epidemic in Rio de Janeiro, Brazil: description of a series of cases. *Clin Infect Dis* 2004; **38**: 529–535.
101. Freitas DF, do Valle AC, de Almeida Paes R, Bastos FI, Galhardo MC. Zoonotic sporotrichosis in Rio de Janeiro, Brazil: a protracted epidemic yet to be curbed. *Clin Infect Dis* 2010; **50**: 453.
102. Silva MB, Costa MM, Torres CC et al. Urban sporotrichosis: a neglected epidemic in Rio de Janeiro, Brazil. *Cad Saude Publica* 2012; **28**: 1867–1880 [in Portuguese].
103. Freitas DF, de Siqueira Hoagland B, do Valle AC et al. Sporotrichosis in HIV-infected patients: report of 21 cases of endemic sporotrichosis in Rio de Janeiro, Brazil. *Med Mycol* 2012; **50**: 170–178.
104. Mayorga J, Tarango MV, Barba RJ. Sporotrichosis 100 years later (1898–1998). *Dermatol Rev Mex* 1999; **43**: 22–29 [in Spanish].
105. García-Vargas A, Mayorga J, Soto Ortiz A, Barba Gómez JF. Sporotrichosis in children. Study of 133 cases in the Dermatological Institute of Jalisco “Dr. José Barba Rubio.” *Med Cutan Iber Lat Am* 2008; **36**: 18–22 [in Spanish].
106. Macotela-Ruiz E, Nochebuena-Ramos E. Sporotrichosis among rural communities in the Northern Sierra in Puebla. Report of 55 cases September 1995–December 2005. *Gac Med Mex* 2006; **142**: 377–380 [in Spanish].
107. Bonifaz A, Vazquez-Gonzalez D. Sporotrichosis: an update. *G Ital Dermatol Venereol* 2010; **145**: 659–673.
108. Bonifaz A, Saul A, Paredes-Solis V et al. Sporotrichosis in childhood: clinical and therapeutic experience in 25 patients. *Pediatr Dermatol* 2007; **24**: 369–372.
109. Padilla-Desgarenes MC, Medina-Castillo DE, Cortés-Lozano N. Sporotrichosis in the pediatric age group: experience of the Centro Dermatológico Pascua. *Piel* 2004; **19**: 350–363 [in Spanish].
110. Hay RJ, Morris-Jones R. Outbreaks of sporotrichosis. *Curr Opin Infect Dis* 2008; **21**: 119–121.
111. Campos P, Arenas R, Coronado H. Epidemic cutaneous sporotrichosis. *Int J Dermatol* 1994; **33**: 38–41.
112. Madrid H, Cano J, Gene J, Bonifaz A, Toriello C, Guarro J. *Sporothrix globosa*, a pathogenic fungus with widespread geographical distribution. *Rev Iberoam Micol* 2009; **26**: 218–222.
113. Mata-Essayag S, Delgado A, Colella MT et al. Epidemiology of sporotrichosis in Venezuela. *Int J Dermatol* 2013; **52**: 974–980.
114. Vidal G, Rodriguez-de-Kopp N. Sporotrichosis: clinical, therapeutic and epidemiologic overview. *Arch Argent Dermatol* 1993; **63**: 221–234 [in Spanish].
115. Alves SH, Boettcher CS, Oliveira DC et al. *Sporothrix schenckii* associated with armadillo hunting in Southern Brazil: epidemiological and antifungal susceptibility profiles. *Rev Soc Bras Med Trop* 2010; **43**: 523–525.
116. Bonifaz A, Vazquez-Gonzalez D, Perusquia-Ortiz AM. Subcutaneous mycoses: chromoblastomycosis, sporotrichosis and mycetoma. *J Dtsch Dermatol Ges* 2010; **8**: 619–627; quiz 628.
117. Criseo G, Malara G, Romeo O, Puglisi Guerra A. Lymphocutaneous sporotrichosis in an immunocompetent patient: a case report from extreme southern Italy. *Mycopathologia* 2008; **166**: 159–162.
118. Cafarchia C, Sasanelli M, Lia RP et al. Lymphocutaneous and nasal sporotrichosis in a dog from southern Italy: case report. *Mycopathologia* 2007; **163**: 75–79.
119. Criseo G, Romeo O. Ribosomal DNA sequencing and phylogenetic analysis of environmental *Sporothrix schenckii* strains: comparison with clinical isolates. *Mycopathologia* 2010; **169**: 351–358.
120. Symmers WS. Sporotrichosis in Ireland. *Ulster Med J* 1968; **37**: 85–101.
121. Mariat F. Ecology of *Sporothrix schenckii* and of *Ceratomyces stenoceras* in Corsica and Alsace, French provinces free of sporotrichosis. *Sabouraudia* 1975; **13**: 217–225 [in French].
122. Magand F, Perrot JL, Cambazard F, Raberin MH, Labeille B. Autochthonous cutaneous sporotrichosis in France. *Ann Dermatol Venereol* 2009; **136**: 273–275 [in French].
123. Ventin M, Ramirez C, Ribera M et al. A significant geographical area for the study of the epidemiological and ecological aspect of Mediterranean sporotrichosis. *Mycopathologia* 1987; **99**: 41–43.
124. Dias NM, Oliveira MM, Santos C, Zancoppe-Oliveira RM, Lima N. Sporotrichosis caused by *Sporothrix mexicana*, Portugal. *Emerg Infect Dis* 2011; **17**: 1975–1976.
125. de Oliveira MM, Verissimo C, Sabino R et al. First autochthonous case of sporotrichosis by *Sporothrix globosa* in Portugal. *Diagn Microbiol Infect Dis* 2014; **78**: 388–390.