

Alberto Peña, Marc A. Levitt

## INTRODUCTION

Anorectal malformations, represent a wide spectrum of defects. Surgical techniques useful to repair the most common types of anorectal malformations seen by a general pediatric surgeon are presented following an order of complexity from the simplest to the most complex.

Malformations considered “low” have traditionally been approached perineally, without a protective colostomy, whereas malformations that are considered “high” were treated by colostomy in the newborn period, subsequent definitive repair of the malformation, and eventual closure of the colostomy. Surgical management has been evolving towards fewer operations and minimally invasive procedures. Anorectal malformations have been included in this trend.

Colostomy is still a widely accepted procedure for children born with rather high and complex malformations. The circumstances in which this procedure is performed vary from one institution to another and from one country to another. Some surgeons feel confident approaching newborns without a protective colostomy. This is feasible and safe, provided the surgeon has experience in the management of these defects. Some surgeons do not feel confident with this approach and prefer a safer path in which they open a protective colostomy, particularly when the baby is premature or has severe associated anomalies.

### Figure 27.1

The colostomy that we recommend in the management of anorectal malformations is a descending colostomy. The surgeon must understand that all colostomies performed in a mobile portion of the colon have a tendency to prolapse. The mobile portion, in the type of colostomy that we propose, is the distal stoma (mucous fistula) and therefore the surgeon must either to fix this distal sigmoid colon to the anterior abdominal wall or make the mucous fistula very small (4 mm in diameter) since it will be used only for colonic irrigations or distal colostogram imaging procedures. The incision is created in the left lower quadrant, long enough as to be sure that both the stomas are sufficiently separated as to be able to accommodate the stoma bag over the proximal stoma. The mucosa fistula should not be included under the stoma bag.

When creating the colostomy in the newborn, the surgeons should look for the descending colon and select the first portion of mobile sigmoid to open the colostomy. That part of the colon is usually very distended and full of meconium. The surgeon can place a purse-string suture, make an orifice in the centre, and pass a catheter to irrigate the sigmoid until all the meconium has been removed. This simple maneuver facilitates the manipulation of the colon and helps to create a better colostomy.

Loop colostomies are contraindicated in children with anorectal malformations. They have a tendency to prolapse, and with them stool can pass into the distal stoma, which may provoke faecal impaction in the distal rectum and also contaminate the urinary tract with faeces.

## MALE DEFECTS

### Figure 27.2

■ **Perineal Fistula.** This malformation represents the simplest of the spectrum. In this defect, the rectum opens immediately anterior to the centre of the sphincter, yet, the anterior rectal wall is intimately attached to the posterior urethra. The anal orifice is frequently strictured. These patients will have bowel control with and without an operation. Some surgeons decide not to operate on these patients. In such a case, the anus should be dilated to allow the easy passing of stool, and the orifice should be sequentially dilating up to no. 12 Hegar in a newborn baby. We prefer to operate on these babies to achieve a better cosmetic effect. We also believe that the operation must be done as soon as the diagnosis is made. We perform these operations without a colostomy in the newborn baby.

The baby is placed in prone position with the pelvis elevated. It is *mandatory* to place a catheter in the urethra of the patient. The most common intra-operative complication is a urethral injury. The incision usually extends mid-sagittally approximately two cm posterior to the anal orifice, dividing the entire sphincter mechanism. Multiple very fine nonabsorbable sutures are placed in the anal orifice in order to exert traction to facilitate the dissection of the rectum. The posterior incision divides the entire sphinc-

ter until the posterior rectal wall that has a characteristic whitish appearance is identified. The surgeon continues dissecting in this plane, first the lateral walls of the rectum and eventually the anterior rectal wall. While dissecting the anterior rectal wall, the surgeon must put special emphasis in trying to avoid urethral injury since there is no plane of separation between rectum and urethra. Once the rectum has been mobilized enough as to be moved back to be placed within the limits of the sphincter. The limits of the sphincter are determined with an electrical stimulator. The perineal body is then reconstructed with long-term fine absorbable sutures and the rectum is anchored to the posterior edge of the muscle complex. An anoplasty is performed within the limits of the sphincter with 16 circumferential 6/0 long-term absorbable sutures. The baby does not have any diet limitations and receives intravenous antibiotics for 24–48 h.

Dilatations are performed twice per day beginning 2 weeks after surgery. The parents learn to advance one size (1 mm) every week until they reach the size adequate for the patient's age, which is no. 12 for a newborn baby, no. 13 for a 4-month-old, no. 14 for an 8-month-old, no. 15 for a 1-year-old, and no. 16 for older patients.

Figure 27.1

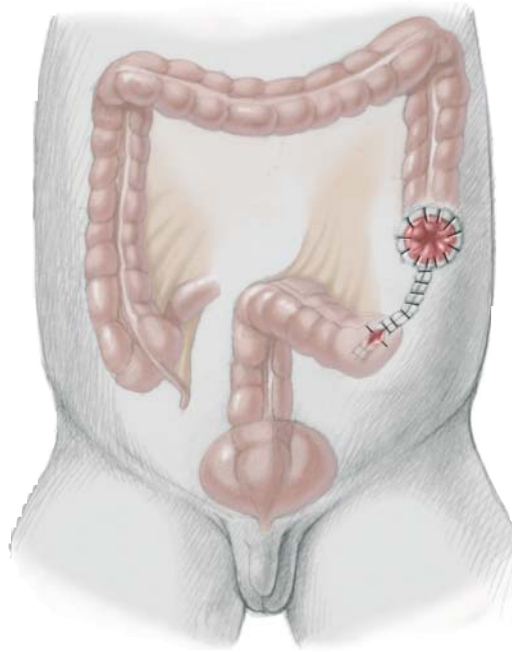
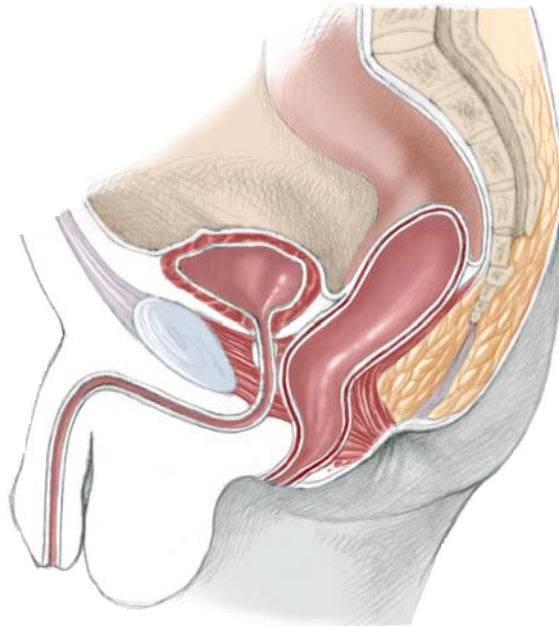


Figure 27.2



### Figure 27.3, 27.4

■ **Rectourethral Fistula.** This group of patients include two specific categories: (a) rectourethral bulbar fistula (Fig 3), and (b) rectoprostatic fistula (Fig 4). These two variants represent the majority of male patients with anorectal malformations. We believe that it is important to recognize the difference between these types because of the prognostic and therapeutic implications. Rectourethral bulbar fistula patients, in our experience have an 80% chance of having bowel control by the age of 3, whereas the rectoprostatic fistula patients only have a 60% chance. Patients with a rectoprostatic fistula have a higher incidence of associated defects (60%) compared to patients with rectourethral bulbar fistula for whom the incidence is 30%. The rectoprostatic patients require a more demanding perirectal dissection to mobilize the rectum that is located higher in the pelvis. These operations are performed at our institution when the babies are 4 weeks old. If the neonatal approach with no colostomy is to be attempted, per-

haps the kind of patient for this management would be the one who has a rectal pouch located below the coccyx. In that way, the surgeon knows for sure that, when he or she opens posteriorly, the rectum is going to be found. The dissection of this distal rectum must be meticulous as it is intimately attached to the urethra.

If the surgeon does not have a specific and reliable image that shows the rectum is located below the coccyx, he or she should *never* approach a patient posteriorly without a colostomy and without a distal colostogram. The distal colostogram is by far the most valuable study in defining the anorectal anatomy. That study is done in patients with anorectal malformations and can only be done when the patient already has a colostomy. We have seen catastrophic complications during the performance of posterior sagittal operations in male patients, that did not have a distal colostogram.

### Figure 27.5a–c

We like to perform a cystoscopy in all patients, which helps the surgeon confirm the location of the fistula. A Foley catheter is inserted and the patient is placed in prone position with the pelvis elevated. The incision is a posterior sagittal one, in between both buttocks, running from the middle portion of the sacrum down to the anal dimple, which is electrically determined. The incision goes through skin, subcutaneous tissue, parasagittal fibres, muscle complex and levator muscle. When the surgeon is dealing with a rectourethral bulbar fistula (Fig. 4), he expects to see a bulging rectum as soon as he opens the levator

muscle. In cases of the rectoprostatic fistula, (Fig. 5) the rectum is much smaller, it may not bulge through the incision, and the surgeon expects to find the rectum immediately below the coccyx. The surgeon should not look for the rectum in the lower part of the incision in patients with rectoprostatic fistula. Looking for a rectum without evidence that the rectum is there is the main source of complications in this approach. The surgeon will find the urethra, vas deferens, prostate, and seminal vesicles and will damage the nerves important for urinary control and sexual potency.

Figure 27.3

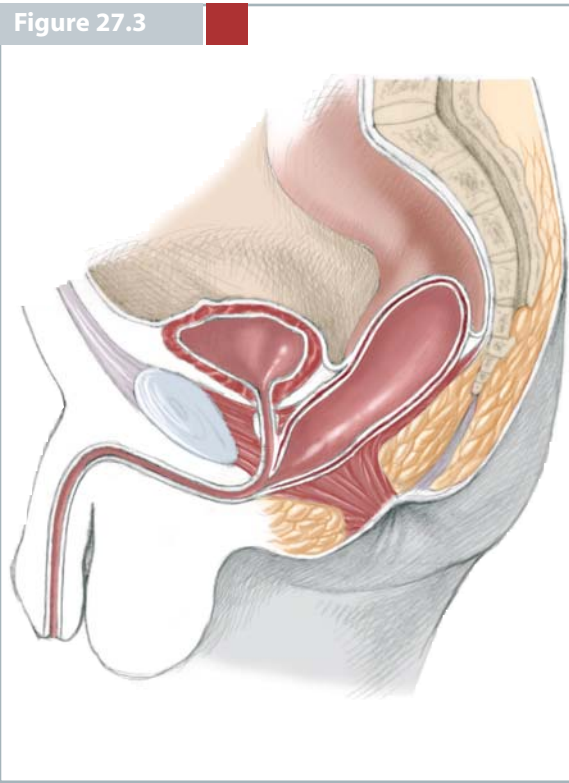


Figure 27.4

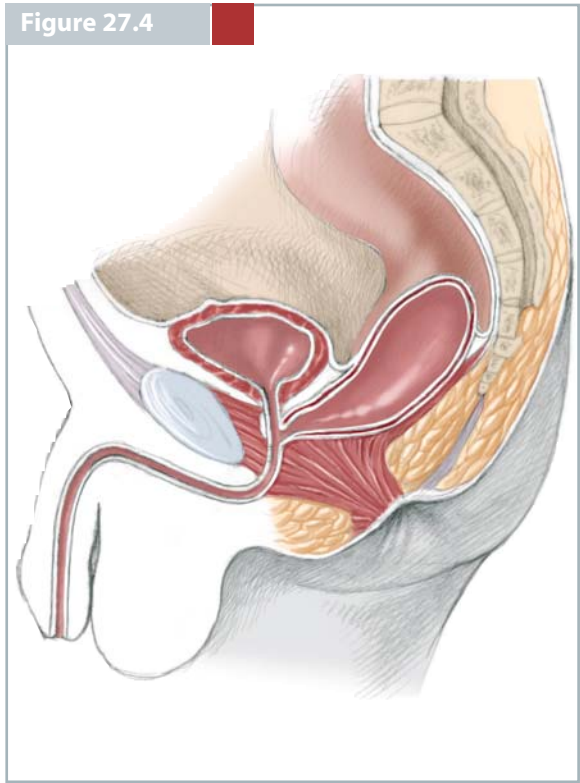
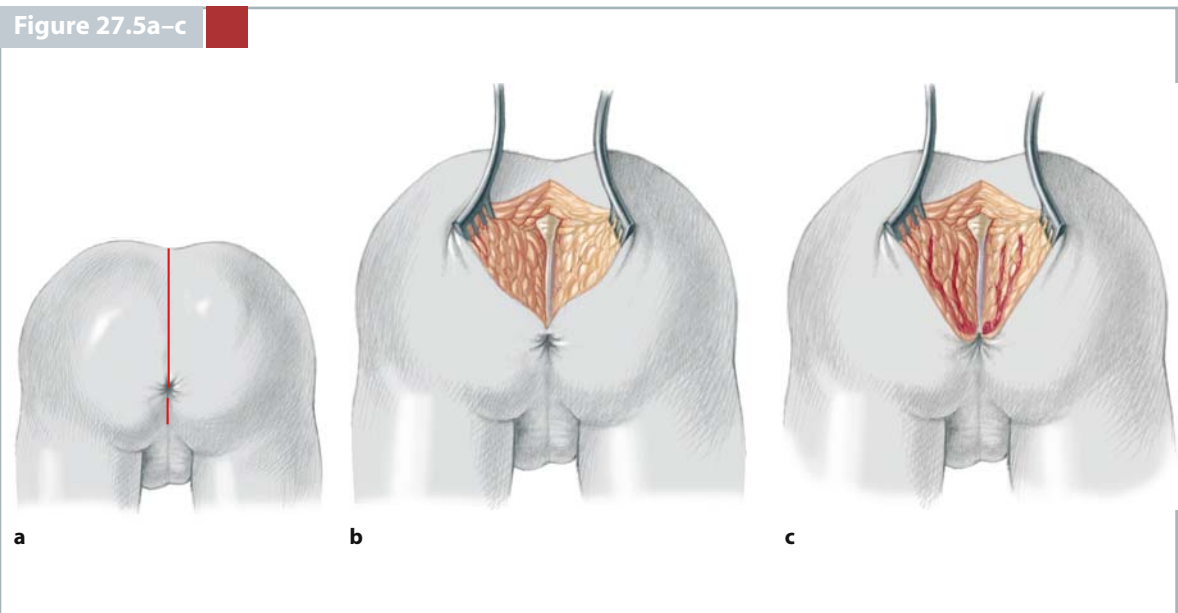


Figure 27.5a-c



**Figure 27.6, 27.7**

The posterior rectal wall is easily identified by its characteristic whitish appearance. The surgeon must keep in mind that there is a fascia that covers the rectum posterior and laterally that must be removed. The dissection of the rectum must be performed staying as close as possible to the rectal wall without injuring the rectal wall itself. The posterior rectal wall is opened in the midline, in between two 5/0 silk

stitches. The incision is continued distally, staying in the midline while applying stitches in the edges of the rectum. The traction on these stitches will allow the surgeon to see the lumen of the rectum. When the incision continues, extending distally in the midline, it ends directly into the rectourethral fistula that is identified usually as a 1–2 mm orifice.

Figure 27.6

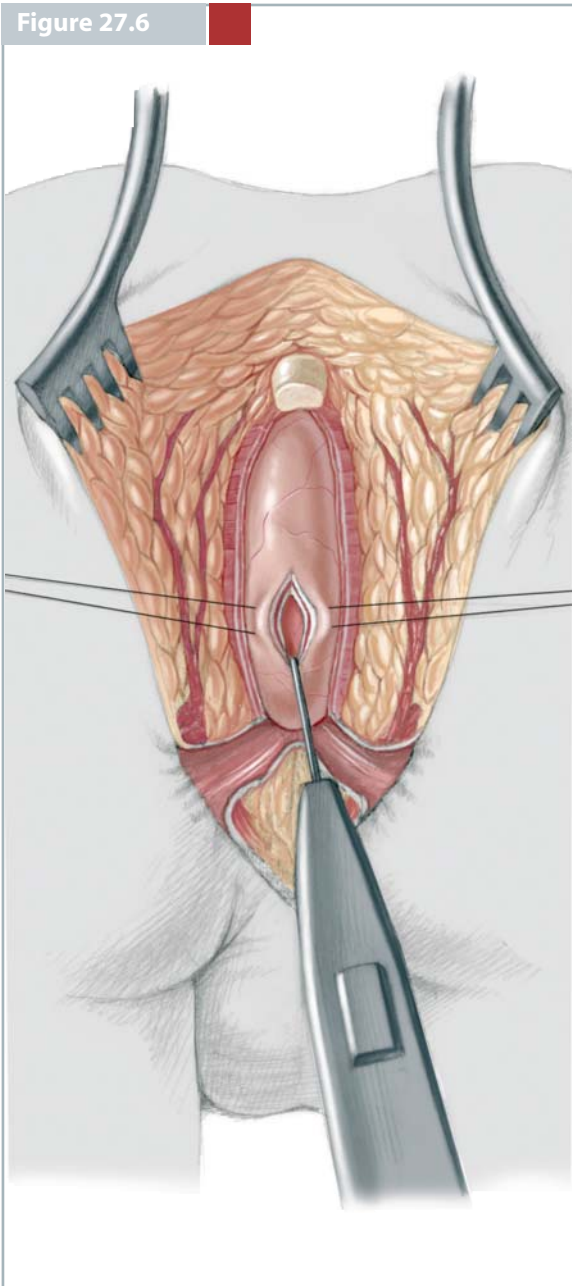
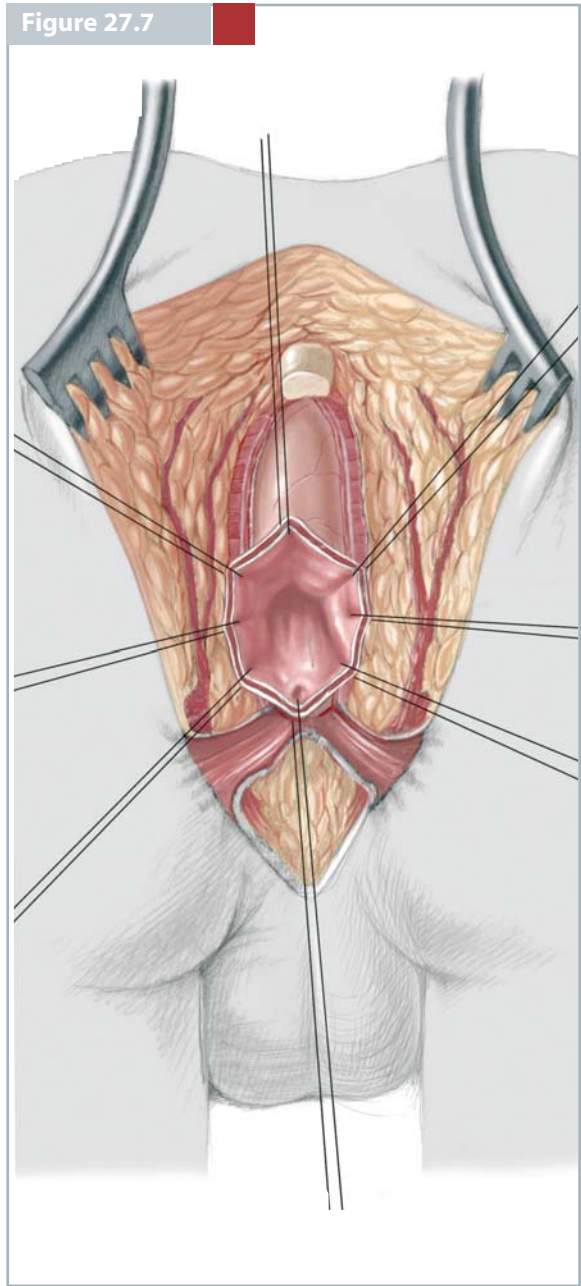


Figure 27.7



**Figure 27.8**

Multiple 6/0 silk sutures are placed in a semi-circumferential fashion surrounding the fistula site above and lateral to the fistula. These multiple sutures serve the purpose of exerting uniform traction on the rectal mucosa to facilitate the separation of the rectum

from the urinary tract. The fascia that covers the rectum is removed, creating the lateral planes of the rectum. The mucosa of the anterior rectal wall distal to the multiple 6/0 silk sutures is divided about 1 mm deep.

**Figure 27.9, 27.10**

The dissection continues between the rectum and urinary tract in a submucosal plane for approximately 5–10 mm and then gradually becomes a full-thickness dissection, looking at the lateral planes until the rectum is completely separated from the urinary

tract. The separation of the urethra from the rectum is the most delicate part of the operation. Most of the serious complications occur during this part of the procedure. The fistula site is closed with three or four 6/0 long-term absorbable sutures.



Figure 27.8

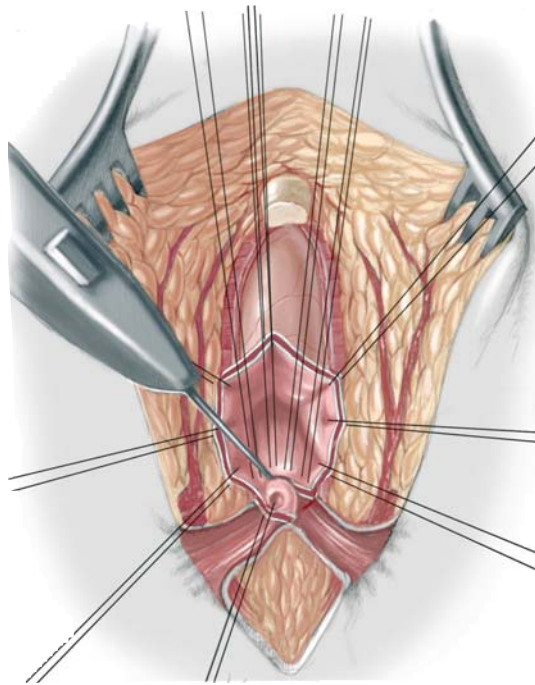


Figure 27.9

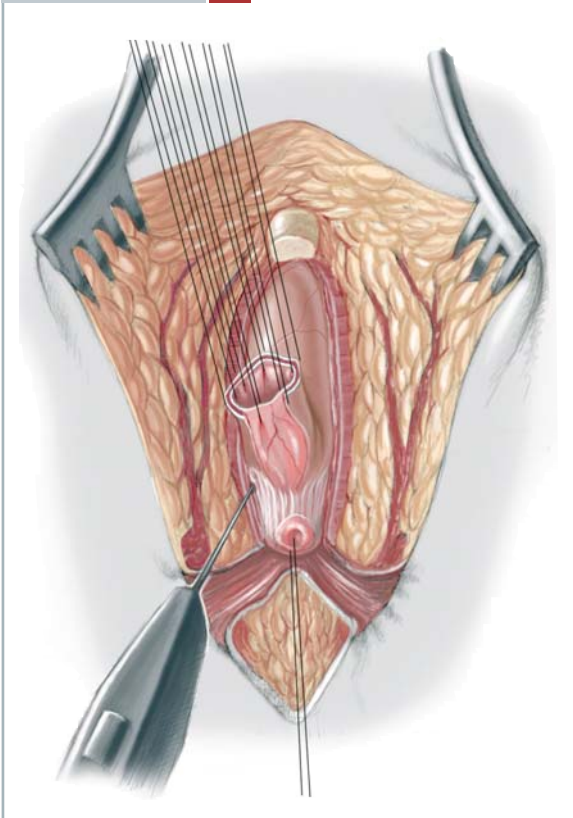
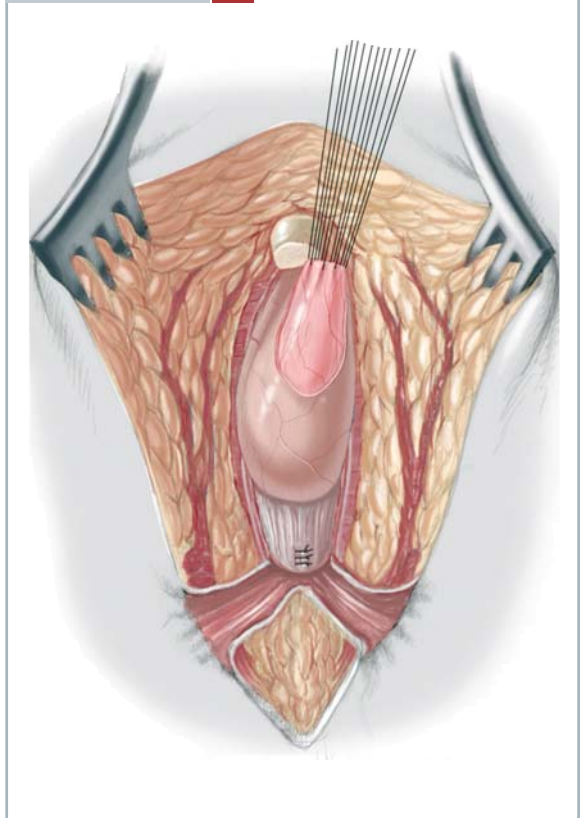


Figure 27.10



**Figure 27.11**

The surgeon should then evaluate the size of the rectum and compare it to the available space to decide if the rectum has to be tapered to be accommodated within the limits of the sphincters. In the past, we performed many of these tapering procedures and we believe that is because patients came later in life, had inadequate colostomies, and therefore suffered from severe megarectum. Currently, babies are referred to us earlier, surgeons are opening better, totally diverting colostomies, and we therefore do not see megarectums as often. Consequently, tapering is rarely necessary.

When a tapering procedure is required, we recommend to remove an adequate portion of the posterior rectal wall, closing this wall into two layers of interrupted long-term absorbable sutures. Tapering on the anterior wall is absolutely contraindicated as it would leave a rectal suture line against the urethral fistula repair and a recurrent fistula may develop.

**Figure 27.12**

The limits of the sphincter are then electrically determined and marked with temporary silk sutures. The perineal body is reconstructed when the incision extends anterior to the centre of the sphincter. The anterior limits of the sphincter must be reconstructed.

**Figure 27.13**

The posterior edge of the levator muscle is electrically determined, and the rectum is placed in front of the levator. The posterior edges of the levator muscle are sutured together with interrupted 5/0 long-term absorbable sutures. The distal continuation of the levator muscle is arbitrarily called the muscle complex.

The posterior edge of this muscle structure is sutured together in the midline with interrupted 5/0 long-term absorbable sutures. These sutures also take a bite of the posterior rectal wall in order to anchor the rectum in a good position to avoid retraction and/or prolapse.

Figure 27.11

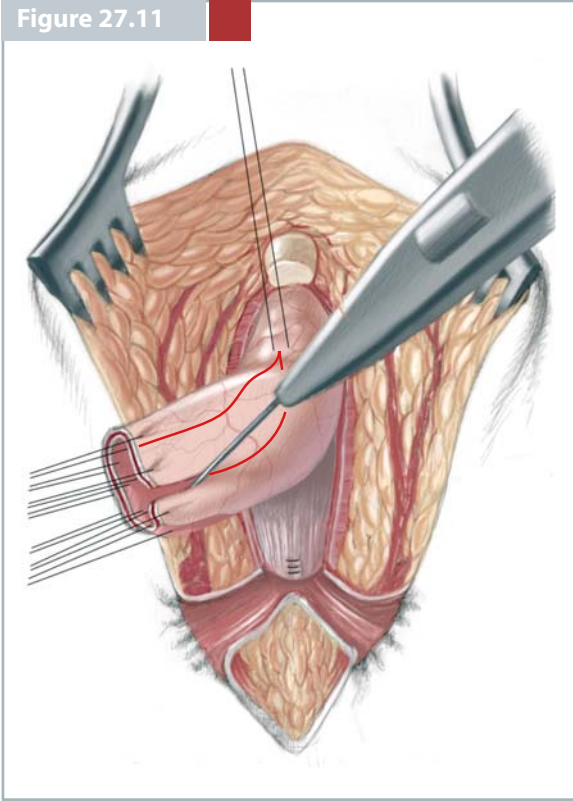


Figure 27.12

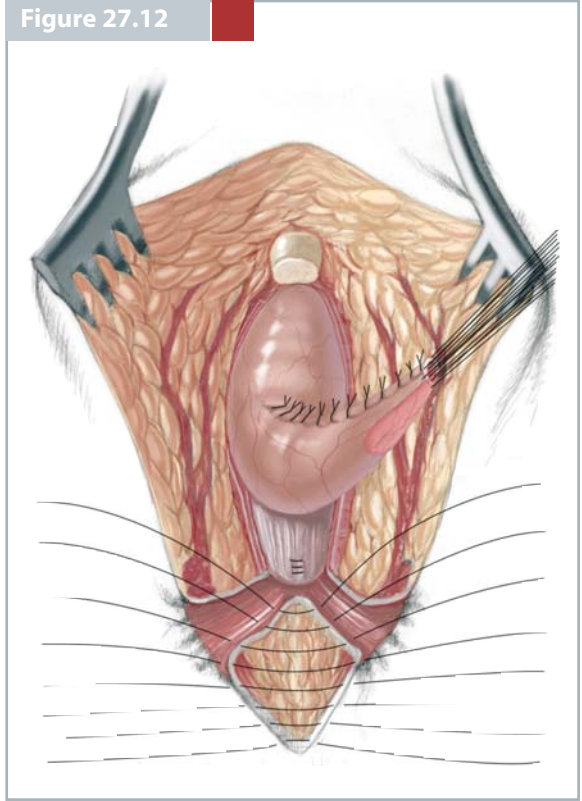
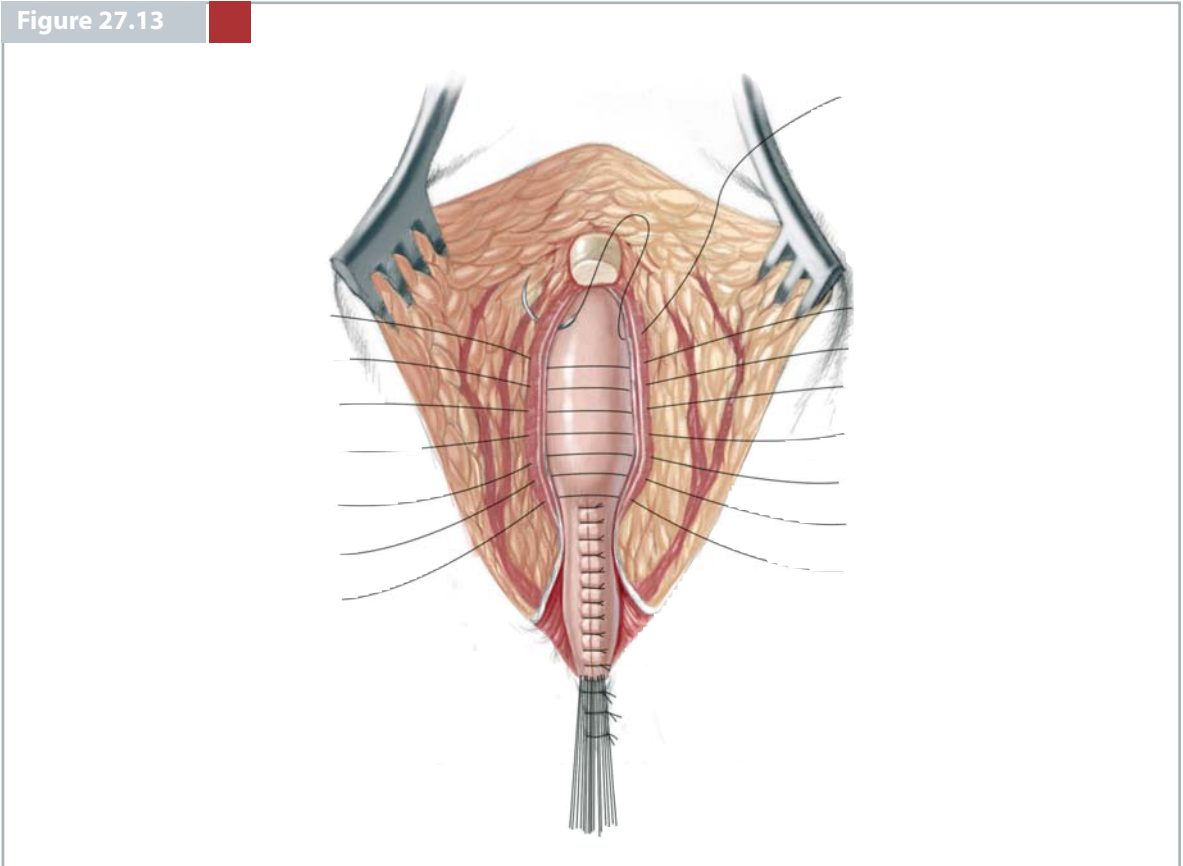


Figure 27.13



### Figure 27.14, 27.15

The rest of the incision is closed meticulously reapproximating all the layers of the wound. An anoplasty is performed with 16 circumferential stitches of

6/0 long-term absorbable sutures, trimming off that part of the rectum that has been damaged or does not have adequate blood supply.

### Figure 27.16

■ **Recto-Bladder Neck Fistula.** This malformation is the highest of all defects seen in male patients. Fortunately, only 10% of male patients suffer from this particular defect. Associated defects occur in 90% of these patients. Usually, the sacrum is hypodeveloped. This particular group of malformations is the only one that, in order to be repaired, requires not only a posterior sagittal approach, but also an abdominal one, either by laparotomy or laparoscopy.

The advent of minimally invasive procedures has been extended to anorectal malformations and we believe that it has specific indications in those patients that formerly required a laparotomy. We still do not believe that the laparoscopic repair of a rectourethral fistula is less invasive than the posterior

sagittal approach alone. However, in a case of recto-bladder neck fistula, the rectum can be separated from the urinary tract laparoscopically avoiding a laparotomy. These patients, unfortunately, do not have a good functional prognosis. In our experience, only 15% of them have voluntary bowel movements by the age of 3. These patients require a posterior sagittal approach to create the space through which the rectum will be pulled down. During the laparotomy or laparoscopy, the surgeon must separate the rectum from the urinary tract. Fortunately, in these very high malformations, the common wall between the rectum and the urinary tract is very short. In other words, the rectum connects to the bladder neck in a “T” fashion.

Figure 27.14

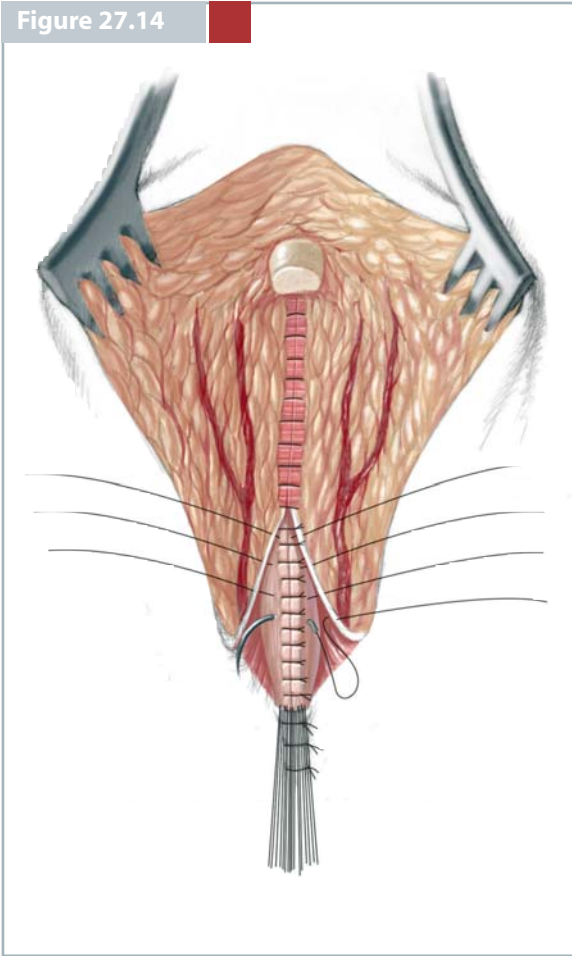


Figure 27.15

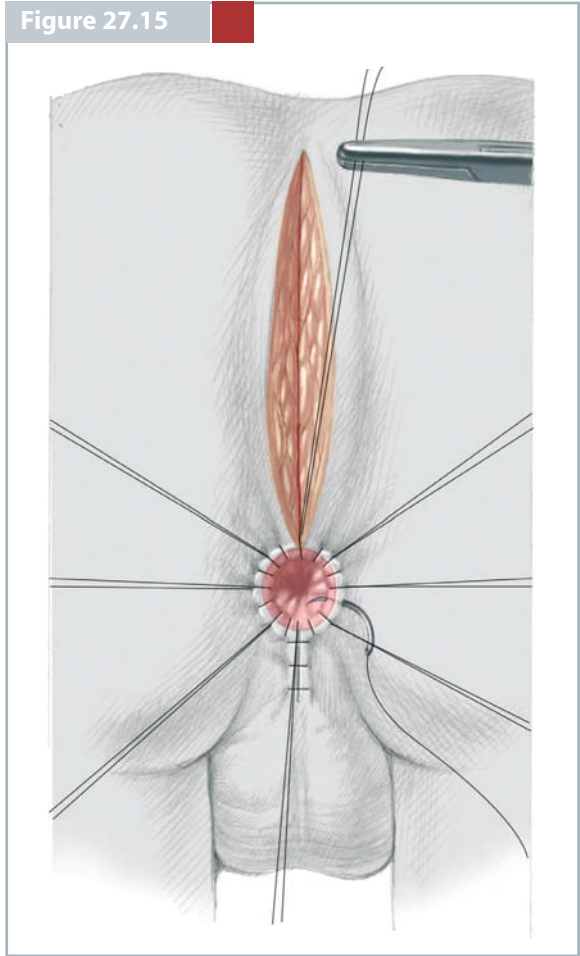
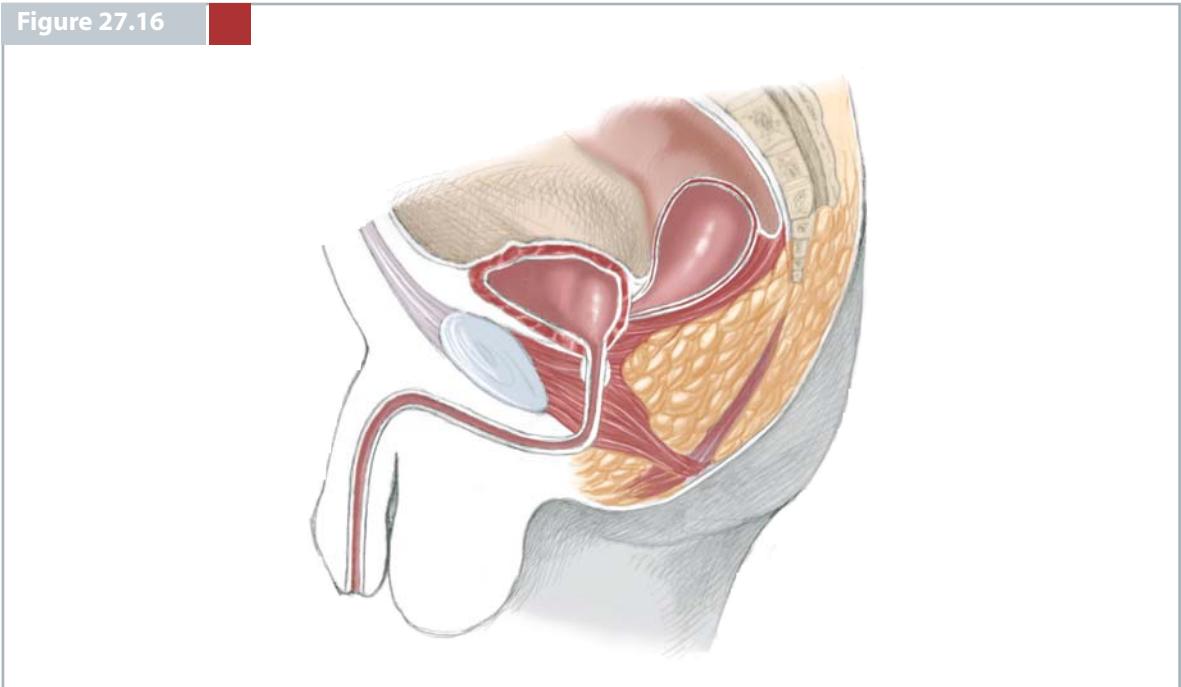


Figure 27.16



### Figure 27.17, 27.18

When we operate on these patients, we perform what we call a total body preparation. The purpose is to have access to the perineum and to the abdomen, when necessary. The operation is started via a posterior sagittal approach. All the sphincter mechanisms are divided in the midline. No attempt should be made to find the rectum through this approach. A rubber tube is placed in the presacral space behind the urethra and located, following the tract the rectum will subsequently occupy. The perineal body, the posterior edge of the levator muscle as well as the muscle complex are reconstructed around the rubber tube that represent the rectum. The patient is then turned onto a supine position and a laparotomy is performed. The bladder is pulled anteriorly and the rectosigmoid is found. In these very high defects, the rectobladderneck fistula is usually located within 1 to 2 cm below the peritoneal reflection and, therefore,

the pelvic dissection necessary to mobilize it is minimal. Ureters and vas deferens run very close to the rectum to approach the trigone of the bladder. This should be kept in mind to avoid any damage. The dissection of the rectosigmoid must be performed while staying in direct contact with the bowel wall itself. The rectum opens into the bladderneck in a T fashion. This means that there is no common wall above the fistula as described in lower malformations. The fistula is divided and the bladder end is sutured with interrupted long-term absorbable sutures. The rubber tube is easily found in the presacral space. The decision is made to taper the rectum when necessary and then to anchor the rectum to the rubber tube. The legs are lifted up and the rubber tube is pulled down, pulling together the rectum that will be placed in the desired location. The anoplasty is performed as previously described and the abdomen is closed.

### Figure 27.19

■ **Imperforate Anus Without Fistula.** This particular malformation is unique. When we say imperforated anus without fistula, we do not have to refer to the height of the defect because in all cases the rectum is located approximately 1–2 cm above the perineal skin, at the level of bulbar urethra. This malformation only happens in 5% of all cases and half of these have Down's syndrome. The patients with these defects have good prognosis, good sacrum and good sphincters. Ninety percent of our patients with this

defect without Down's syndrome have bowel control and 80% of our Down's syndrome patients have bowel control. The technique to repair this malformation is not necessarily simpler than the one for rectourethral bulbar fistula since the rectum is intimately attached to the posterior urethra. The surgeon has to open the posterior rectal wall and still has to create a plane of dissection between the anterior rectal wall and the urethra, a manoeuvre that requires a meticulous dissection.

Figure 27.17

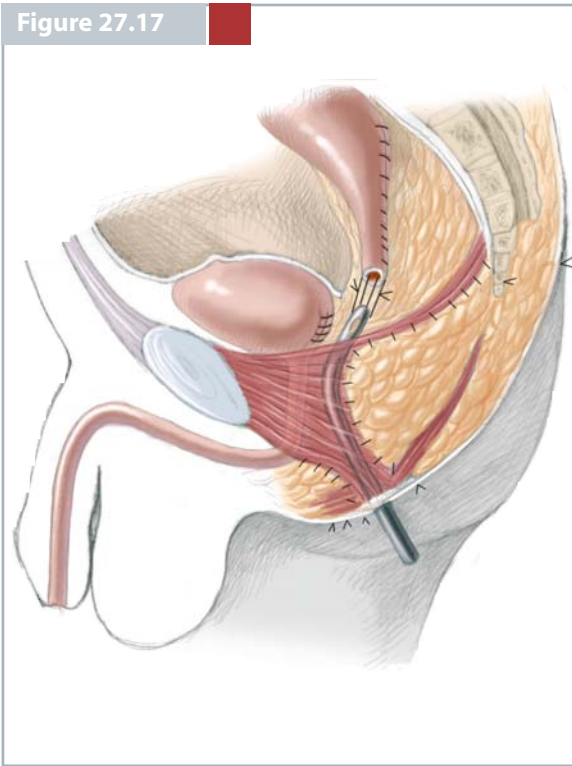


Figure 27.18

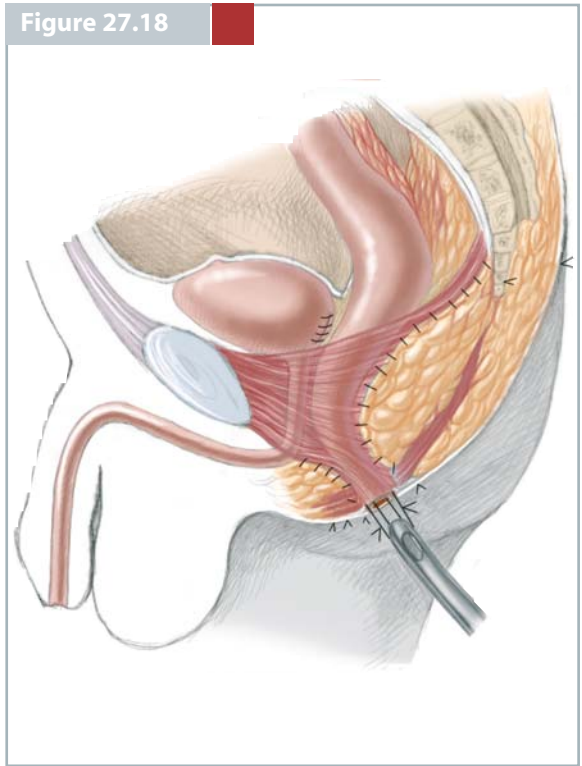
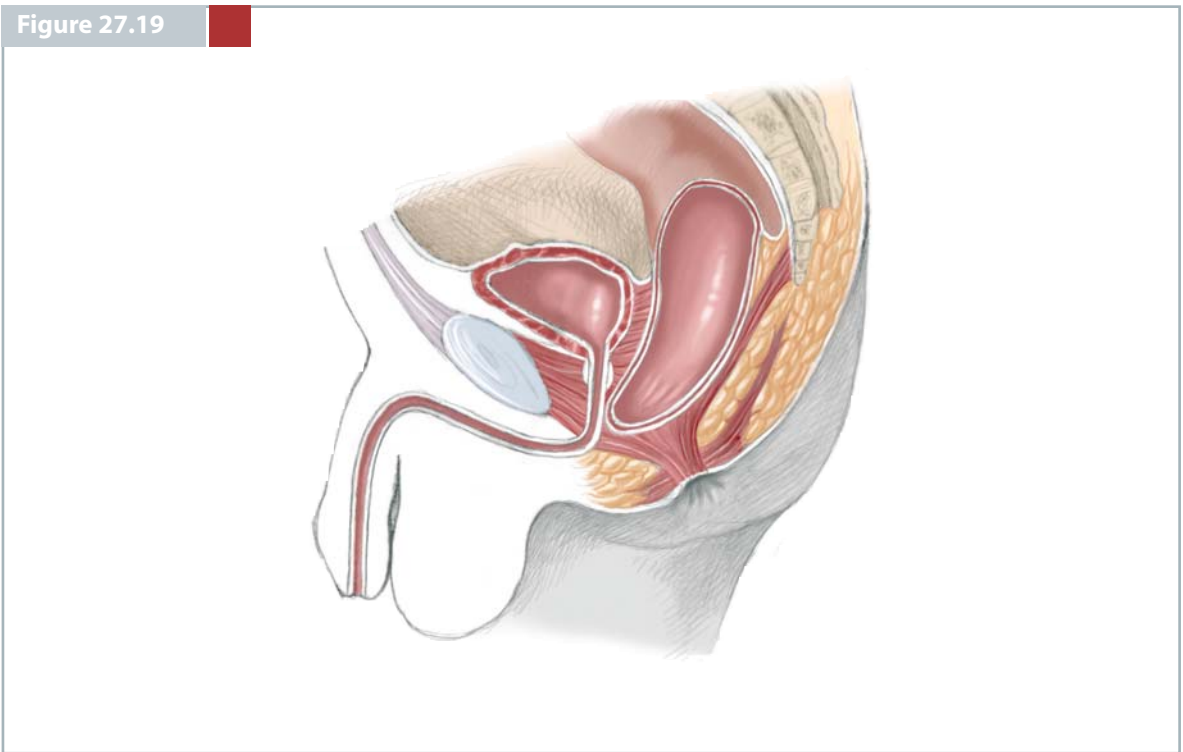


Figure 27.19



## FEMALE DEFECTS

## Figure 27.20

Female defects are represented by a similar spectrum. However, over the last 22 years, we have been learning a great deal about these defects, particularly with regard to cloacas. We have learned, for instance, that the so-called rectovaginal fistula is an almost nonexistent defect. Most of the patients that were referred to us after having an operation to repair a “rectovaginal fistula”, actually never suffered from that particular defect. Most of them suffered originally from a cloaca that was misdiagnosed; the surgeon repaired the rectal component of the defect and left the patient with a persistent urogenital sinus. In other more unfortunate cases, the babies were born with rectovestibular fistulas, the surgeons mislabelled and misdiagnosed it as a rectovaginal fistula and performed an abdominal perineal procedure for a malformation that could otherwise have been repaired posterior sagittally with good results, leaving the patient totally incontinent for faeces.

■ **Rectoperineal Fistula.** This defect is equivalent to the recto-perineal fistula in males already described. Bowel control exists in 100% of our patients and less than 10% of them have associated defects. The patients are faecally continent with and without an operation. Constipation is a constant sequela and should be treated energetically. This is true also for the male patients with perineal fistulas. We have learned that the lower the defect the more there is a chance of constipation. We have also learned that constipation is a self-perpetuating and self-aggravating condition that eventually produces severe megacolon, chronic faecal impaction and overflow pseudo-incontinence, and must vigilantly be avoided.

At our institution, the operation to repair this defect is performed at birth. We offer this operation to our patients mainly to avoid cosmetic, psychological and potential obstetric sequelae in the future. We perform this operation before the baby leaves the hospital during the newborn period.

The patient is placed in prone position with the pelvis elevated. Multiple 6/0 silk stitches are placed around the fistula site. The incision is about 1.5–2 cm long and divides the entire sphincter mechanism in the posterior midline. We dissect the rectum as previously described in the case of perineal fistulas in male patients. The perineal body is reconstructed as shown and the rectum is anchored to the posterior edge of the muscle complex. An anoplasty is performed.

These patients can eat on the same day of the surgery, and since they are only passing non-colonized meconium, we give antibiotics for 48 h.

## Figure 27.21

■ **Rectovestibular Fistula.** This defect is perhaps the most important anorectal malformation in females. This is because it is by far the most common defect seen in the females. It is also a malformation that has an excellent functional prognosis when managed correctly. Also, paradoxically and unfortunately, girls with these defects are the ones that we have seen suffer from more complications after a failed attempt to repair. For many years, it has been very controversial whether this malformation should be treated with a previous protective colostomy or should be operated primarily at birth. Again, we believe that this depends very much on the experience of the surgeon. When a baby is born with this malformation at our institution and the baby is otherwise healthy, we repair this malformation during the newborn period. If the baby is premature or has associated defects, it is always safer to open a protective colostomy. The surgeon must keep in mind that dehiscence and infection in patients with anorectal malformations not only represent a few more days in the hospital and an ugly scar but also represents the possibility of changing the prognosis for bowel control.

Patients with a vestibular fistula have an excellent prognosis. Bowel control exists in 93% of our patients; 70% of them have constipation that is incurable but manageable and it should be treated aggressively.

The most important anatomical feature that should be recognized by the surgeon is that the rectum and vagina share a long common wall that must be separated, creating a plane of dissection where it does not exist, in order to mobilize the rectum and put it in the right place.

We believe that most of the complications that we have seen from treatment of this malformation originate from the lack of separation of these two structures, or the defective separation of these two structures.



Figure 27.20

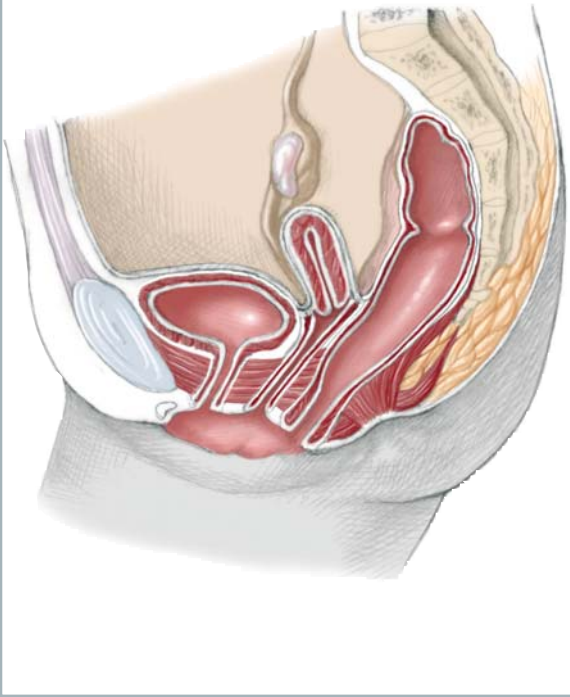
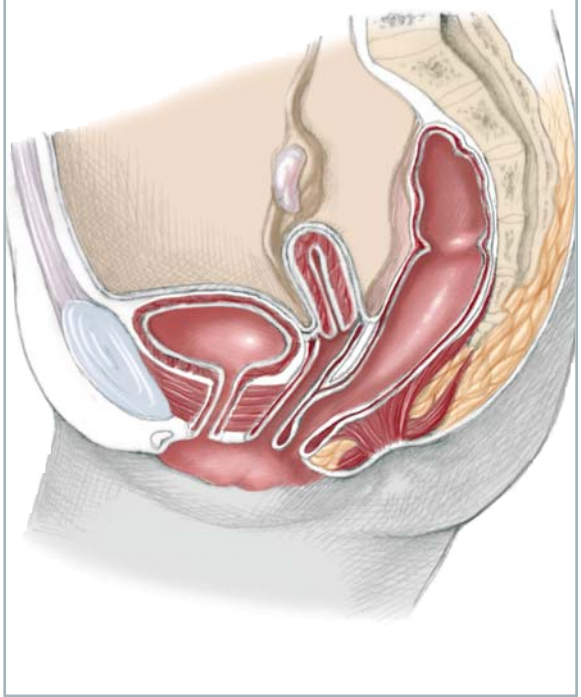


Figure 27.21



**Figure 27.22, 27.23**

These patients are also placed in prone position with the pelvis elevated. The incision runs usually from the coccyx down to the fistula site. Again, multiple 6/0 sutures are placed in a circumferential manner in the fistula opening. Traction always facilitates the dissections of these delicate structures. The entire sphincter mechanism is divided posteriorly until we identify the posterior rectal wall, and then the plane of dissection is established removing the fascia that covers the rectum. The dissection then continues laterally. The surgeon must put a special emphasis on a very meticulous separation of the rectum from the vagina. The purpose of this dissection is to make two walls out of one. He or she should try at all costs to avoid making perforations in the rectal wall or the vaginal wall. Once the rectum has been completely separated from the vagina, the surgeon determines the limits of the sphincter electrically and reconstructs the perineal body, bringing together the anterior limits of the sphincter.

The rectum is then placed within the limits of the sphincter as well as the muscle complex. We can see only the lower part of the levator because the incision is rather limited in this operation. The rectum is anchored to the posterior edge of the muscle complex and the anoplasty is performed like we discussed in the previous cases.

When the patient is a newborn, we keep the baby 2 or 3 days with nothing by mouth post-operatively, while receiving intravenous antibiotics. Occasionally, we see patients that come later in life without a colostomy; in those cases, we clean the bowel meticulously the day before surgery with a balanced electrolyte solution, insert a central line in the operating room and keep the patients 10 days with nothing by mouth, while receiving parenteral nutrition. Following this routine, we have never had a case of a wound infection.

Figure 27.22

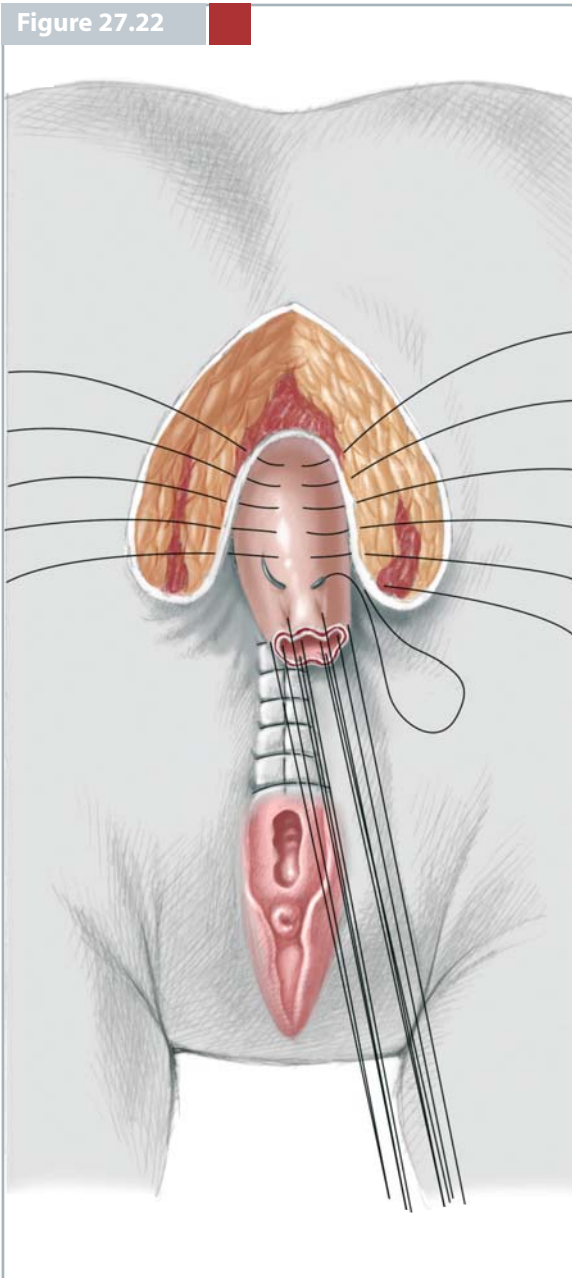
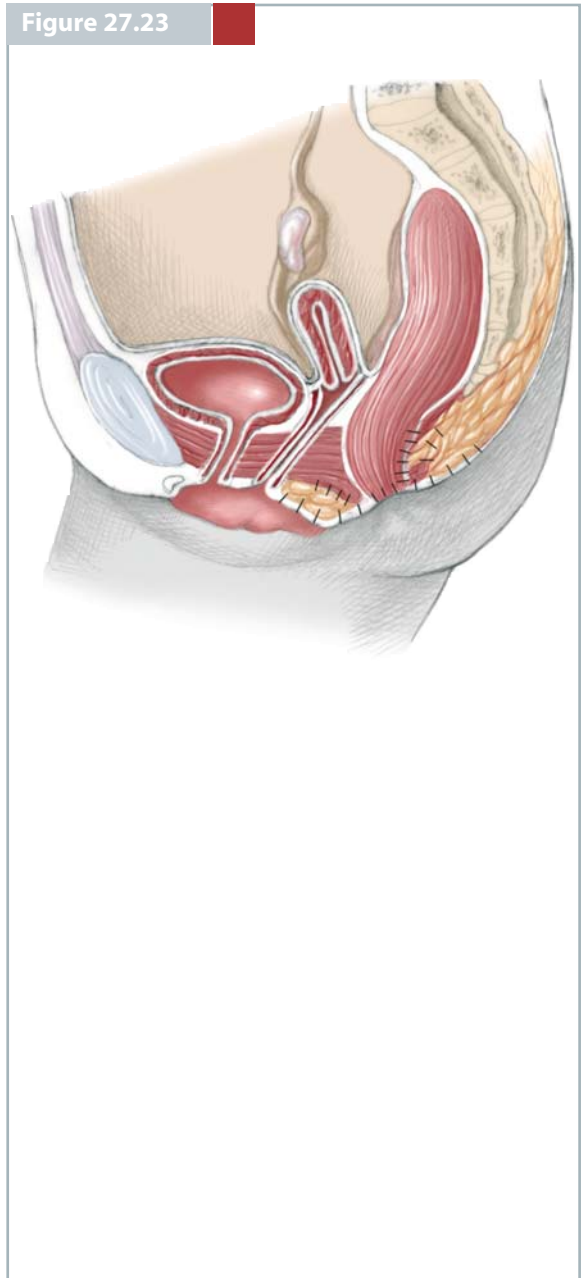


Figure 27.23



## Figure 27.24

■ **Cloaca.** It was 1982 when we operated on the first patient with a cloaca using the posterior sagittal approach. Since that time, until the writing of this chapter, we have operated on 342 patients with cloaca. Cloacas represent a spectrum of malformations. We have been learning many important lessons about the treatment of these malformations. Based on that experience, we now believe that there are two distant groups of cloaca. This separation, we think is important for the pediatric surgeon and pediatric urologist to recognize. In the first group are patients with a common channel shorter than 3 cm, and the second group comprises patients with a common channel longer than 3 cm.

A cloaca is defined as a malformation in which the rectum, vagina and urethra are congenitally fused, forming a common channel and opening in a single perineal orifice at the same location where the normal female urethra is located. These three structures share common walls that are very difficult to separate. We have learned that the length of the common channel has important therapeutic and prognostic implications.

The group of cloacas with a short common channel (<3 cm) represents 68% of all our cloaca patients and, therefore, we believe that perhaps there are enough cloacas of this type in the world for the general pediatric surgeons to learn to repair them successfully. On the other hand, 32% of all cloaca have a common channel longer than 3 cm, and we believe that because of their complexity and rarity, they should be repaired by individuals with special training that includes a special dedication to pediatric urology.

Patients suffering from cloaca with a short common channel (<3 cm), have a relatively low incidence of associated urologic, spinal, and vertebral defects, whereas patients with long cloacas have a very high frequency of association with complex pelvic anomalies, mainly urologic, as well as vertebral. That is what makes the repair of this group very challenging.

Patients with a short common channel can be repaired posteriorly sagittally only, without opening of the abdomen.

When a baby is born with cloaca, the surgeon must keep in mind that approximately 50% of these patients suffer from a very giant vagina full of fluid called "hydrocolpos". The hydrocolpos may compress the trigone interfering with the drainage of the ureters and therefore provoke bilateral megaureters and hydronephrosis. It is imperative that the surgeon to keep this in mind.

All babies with cloaca should have a complete urological evaluation at birth, as well as an ultrasound of the kidneys and ultrasound of the pelvis. The baby should not be taken to the operating room without this evaluation. If the baby suffers from hydrocolpos, it is mandatory that the surgeon drain the hydrocolpos at the same time that he or she opens a colostomy. Not draining a hydrocolpos may produce persistent hydronephrosis and induce an inexperienced pediatric urologist to perform ureterostomies or nephrostomies when they are not indicated. The drainage of the vagina most frequently takes care of the problem of hydronephrosis. Also, the lack of drainage of a tense hydrocolpos may produce infection of the vagina (pyocolpos), perforation and sepsis.

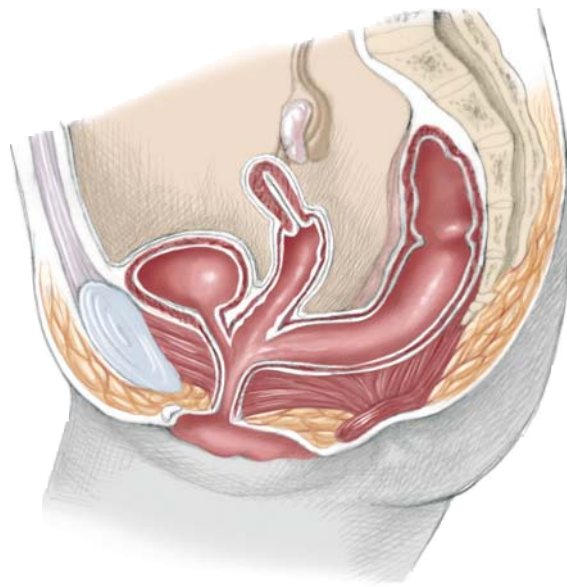
The colostomies must be completely diverting (separated stomas) to avoid contamination of the urinary tract. We now repair cloacas when the babies are 1-month-old, provided they are growing and developing normally.

About 30% of the patients also have duplicated Mullerian structures. In other words, they have different degrees of septation and separation of the hemi-vaginas and two hemi-uterii. These have significant potential obstetric implications.

Before we begin this operation, the patients are placed in lithotomy position and a cystoscopy is performed. If the surgeon finds that the patient has a cloaca with a common channel shorter than 3 cm, it may be assumed that he or she will be able to repair the malformation posteriorly sagittally only. Surgeons may assume that they do not have to open the abdomen and that the final functional prognosis, both for urinary and faecal function, is going to be reasonably good. On the other hand, if the patient has a longer common channel, she must be operated on by a highly experienced and skilled surgeon or team of surgeons.

In cases of a short common channel, the patient is placed in a prone position with the pelvis elevated and the incision runs from the middle portion of the sacrum all the way down to the single perineal orifice. The entire sphincter mechanism is divided posteriorly and then the visceral structure (usually the rectum) is exposed. For many years, the way we repaired these cloacas consisted of separating the rectum from the vagina and then separating the vagina from the urinary tract, reconstructing what used to be the common channel as a neourethra and then placing the vagina behind the neourethra and the rectum within the limits of the sphincter mechanism.

Figure 27.24



### Figure 27.25, 27.26

In the last 125 patients, we introduced a technical variant called total urogenital mobilization. The rectum is separated from the vagina in the same way that they were separated in the cases of rectovestibular fistula. Once we expose the malformation, multiple 6/0 silk stitches are placed taking the edges of the common channel and the edges of the vaginal walls. We use those stitches to exert a uniform traction. Then urethra and vagina together are mobilized in what we call total urogenital mobilization. Another set of sutures is placed in a transverse fashion taking the mucosa of the common channel 5 mm proximal to the clitoris and then the entire common channel is divided, full thickness, creating a plane of dissection between the pubis and the common channel. This is a natural plane of dissection and therefore it is very easy to dissect. We reach the upper part of the pubis and there we can identify avascular fibrous structures that fix the genitourinary structures to the pelvis. These are divided and that allows an immediate gain of length of the urogenital structures of approximately 2–4 cm, which is enough to repair the malformations with short common channels.

The goal of this mobilization is to move what used to be a urethral meatus all the way down, to be placed immediately behind the clitoris to be visible and accessible for future urethral catheterizations when indicated. The vagina comes down together with the urethra and the edges of the vagina are sutured to the skin of the perineum forming the new labia. What used to be the common channel is divided in the midline creating two flaps that are preserved and sutured to the new labia to enrich that tissue. All this reconstruction is performed with interrupted 6/0 long-term, absorbable sutures. With these kinds of techniques, in patients with a good sacrum, 80% of them have bowel control and approximately 80% of them can empty the bladder voluntarily without intermittent catheterization, and remain dry of urine; 20% of them require intermittent catheterization to empty the bladder. Fortunately, they have a good bladder neck and they remain dry between catheterizations. When the sacrum is very abnormal, the results are not as good.

The repair of patients suffering from cloacas with longer common channels (>3 cm) represents a real technical challenge and requires a great deal of expe-

rience in the management of these cases. For that kind of patient, the surgeon should have experience in the management of the urinary structures including bladder reconstructions, bladderneck reconstructions, ureteral reimplantations, bladder augmentation and Mitrofanoff procedures.

In cases with long common channels, if the pediatric surgeon and/or pediatric urologist both have experience with these malformations they continue with the repair, performing first what we call a total body preparation in order to have access both to the perineum and the abdomen.

If the common channel is longer than 5 cm, we recommend opening the abdomen directly in the midline because, in that particular case, rectum and vaginas are not accessible posteriorly sagittally and are more easily accessed through the abdomen.

If the common channel is between 3 and 5 cm, the surgeon can open posteriorly sagittally, still will find the vagina or vaginas and can try to repair them by performing the total urogenital mobilization. If the total urogenital mobilization proves not to be enough to repair the malformation then the operation must be completed through a laparotomy. The separation of the rectum from the vagina is not difficult in very high malformations since it is similar to what we described in the separation of the rectum from the bladder neck in male patients. On the other hand, the separation of the vagina from the urinary tract in a case of a cloaca with a long common channel is a very delicate manoeuvre that requires expertise and finesse. Once the vagina has been completely separated, which is a manoeuvre that may take several hours, the surgeon then has to make important decisions considering the way to repair the vagina. The separation of the vagina from the urinary tract should be performed with the bladder open in the midline and with ureteral catheters. The ureters run through the common wall that separates the vagina from the bladder and therefore, the surgeon should be ready to deal with the fact that the ureters may be right in the plane of separation. Once the vagina has been separated, the surgeon should evaluate the size of the mobilized vaginas and the length that he needs to bring the vagina down. It may be that the patient has a very large vagina that reaches the perineum.

Figure 27.25

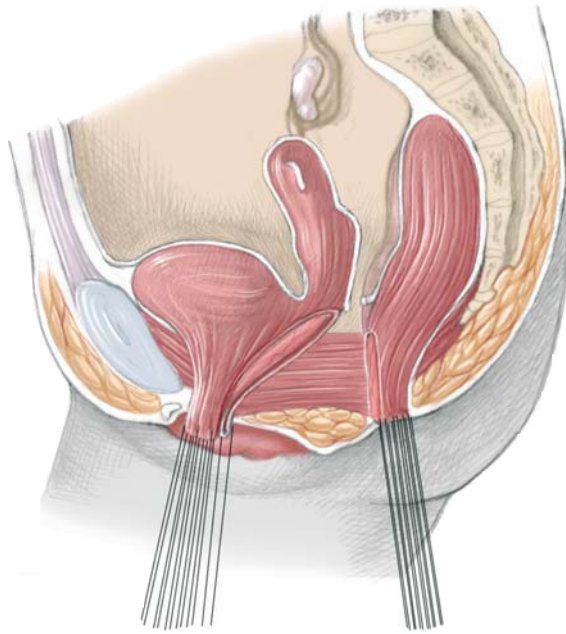
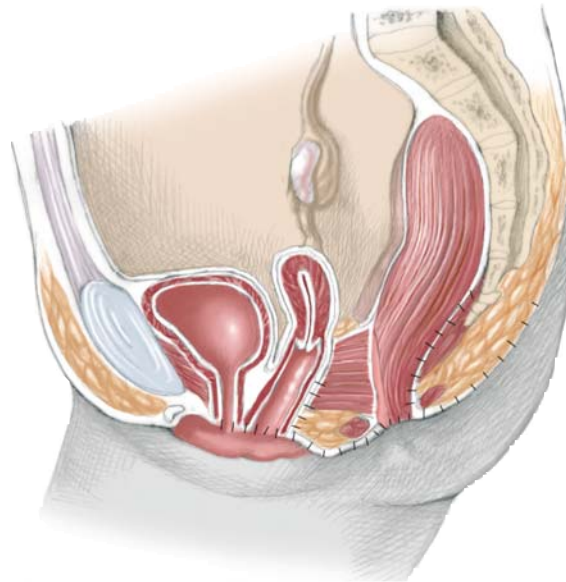


Figure 27.26



## CONCLUSION

Clinical results are different for each type of the malformations. A recent review of the authors' series showed that 100% of patients with rectal atresia and perineal fistula had voluntary bowel movements, those with vestibular fistula 93.8%, bulbar urethral fistula 87.5%, imperforate anus without fistula 85%, cloaca 83.3%, rectourethral prostatic fistula 76.5%, and bladderneck fistula 28.6%. Soiling in patients who enjoy voluntary bowel movements usually represents a manifestation of faecal impaction and when the constipation is treated properly, the soiling usually disappears. Patients who enjoy voluntary bowel movements and never soil are considered "totally continent".

Constipation is a common sequela seen after the repair of an anorectal malformation. Interestingly, patients with lower defects, and therefore with better prognosis for bowel control, suffer a higher incidence of constipation and vice versa. Constipation correlates directly with the degree of rectosigmoid dilation at the time of colostomy closure. Therefore, eve-

ry effort should be made to try to keep the rectosigmoid empty and decompressed from day 1 in these patients.

Urinary control can be expected in the overwhelming majority of male patients after repair of imperforate anus provided a good surgical technique was performed. Urinary incontinence is a concern only in male patients with absent sacrum or in some female patients with cloaca. In this last defect, when the common channel is shorter than 3 cm, approximately 20% of patients require intermittent catheterization to empty the bladder. The remaining 80% enjoy urinary control. When the common channel is longer than 3 cm it was observed that 68% of the patients require intermittent catheterization to empty the bladder. Fortunately, after the repair of a cloaca, patients have a good bladderneck; they have the capacity to empty the bladder. Thus, when the bladder becomes completely full, the patients start suffering from overflow urinary incontinence. Intermittent catheterization keeps these patients completely dry.

## SELECTED BIBLIOGRAPHY

- Hong AR, Rosen N, Acuña MF, Peña A, Chaves L, Rodriguez G (2002) Urological injuries associated with the repair of anorectal malformations in male patients. *J Pediatr Surg* 37:339-344
- Levitt MA, Stein DM, Peña A (1998) Gynecological concerns in the treatment of teenagers with cloaca. *J Pediatr Surg* 33:188-193
- Peña A (1995) Anorectal malformations. *Semin Pediatr Surg* 4:35-47
- Peña A (1997) Total urogenital mobilization-an easier way to repair cloacas. *J Pediatr Surg* 32:263-268
- Peña A (2003) Anorectal malformations. In: Ziegler M, Azizkhan R, Gauderer M, Weber TR (eds) *Operative pediatric surgery*. Appleton & Lange, Norwalk CT
- Peña, A (2003) Anorectal anomalies. In: Puri P (ed) *Newborn surgery*. Arnold, London, pp 535-552