



Surgical Management of Common Canine Prostatic Conditions

Thurid Freitag, DVM, PhD^{a,b}

Richard M. Jerram, BVSc, DACVS

Alex M. Walker, BVSc (Dist), MAVS

Chris G. A. Warman, BVSc, MAVS^c

Veterinary Specialist Group, Auckland, New Zealand

ABSTRACT: Prostatic diseases commonly warrant surgical intervention. Early castration may prevent the development of benign prostatic hyperplasia, prostatitis, and cavitory lesions (prostatic abscesses or cysts). In intact dogs that present with these disorders, castration should always be part of the specific surgical treatment because it enhances treatment success and may prevent recurrence. The current treatment of choice for cavitory lesions is prostatic omentalization, which results in lower postoperative mortality, faster recovery, and fewer incidences of recurrence than other prostatic drainage techniques. Prostatic neoplasia without evidence of metastasis may be managed with total prostatectomy, subtotal prostatectomy in conjunction with intraoperative radiotherapy, or postoperative chemotherapy. Understanding the neurovascular supply of the prostate and surrounding tissues is essential to decrease the risk for urinary incontinence, severe hemorrhage, and avascular necrosis. Postoperative management includes analgesia, appropriate antibiotic therapy, and in cases of subtotal or total prostatectomy, temporary urinary catheterization.

Prostatitis, prostatic abscesses, prostatic cysts, and prostatic neoplasia are uncommon presenting conditions in dogs.¹ Conversely, benign prostatic hyperplasia (BPH) affects more than 80% of intact male dogs that are older than 6 years.² BPH may predispose intact male dogs to the development of abscesses and cysts.^{3,4} Prostatic neoplasia develops independently from BPH and can affect

intact or castrated dogs.^{5,6} Prostatic disorders in dogs may be treated with medical therapy, surgery, or a combination of both. This article focuses on prostatic disorders that are commonly treated surgically and prostatic surgical procedures.

ANATOMY OF THE PROSTATE

The prostate, the only accessory sex gland in male dogs, is a bilobate, fibromuscular organ



- Take CE tests
- See full-text articles

CompendiumVet.com

^aDr. Freitag is currently affiliated with University College Dublin, in Dublin, Ireland.

^bDr. Freitag discloses that she has received financial support from Hill's Pet Nutrition and Pfizer Animal Health.

^cMr. Warman discloses that he has received financial support from Pfizer and Nestlé Purina Petcare Company.

that is typically located at the cranial aspect of the pelvic floor or just cranial to the pubic rim.⁷ The location of the prostate varies with the size of the gland, the fullness of the bladder, and the dog's breed, age, and body weight.⁷ The prostate surrounds the proximal portion of the urethra and lies ventral to the rectum. Cranially, it ends close to the neck of the bladder. The ventral aspect of the prostate lies outside the peritoneum and is covered by periprostatic fat, while the dorsal and lateral aspects are enveloped by peritoneum.

Blood vessels and nerves supplying the prostate are encountered bilaterally at the dorsolateral surface of the prostate. The prostatic arteries originate from the internal pudendal arteries. Before they enter the dorsolateral prostate, they give rise to branches supplying the rectum, the ductus deferens, the caudal portions of the bladder and ureters, and the pelvic part of the urethra (Figure 1). Venous blood drains via the prostatic and urethral veins into the internal iliac vein. Prostatic lymph drains into the medial iliac (sublumbar) lymph nodes.

The hypogastric and pelvic nerves supply the sympathetic and parasympathetic innervation of the prostate, respectively. These nerves also innervate the bladder and urethra. The hypogastric nerve arises from the mesenteric ganglion and runs alongside the arteries of the deferent ducts. The pelvic nerve descends from the first, second, and third sacral nerves and follows the prostatic arteries, joining the hypogastric nerve to form the pelvic plexus. Sympathetic stimulation of the prostate causes ejection of prostatic fluid, while parasympathetic stimu-

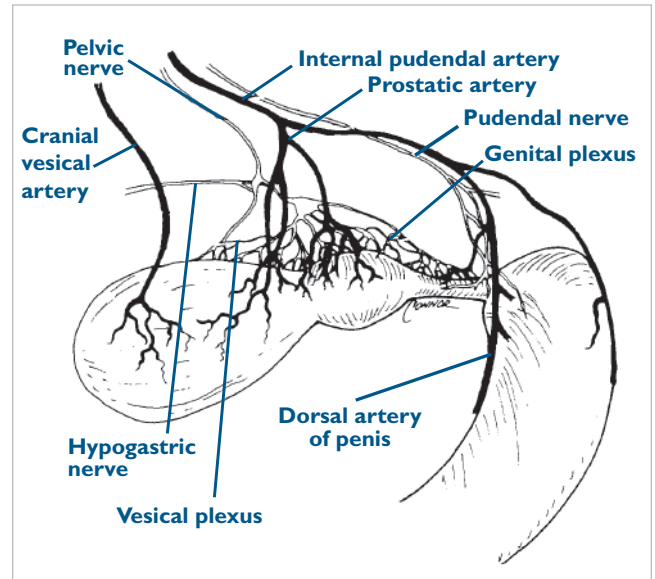


Figure 1. Vascular and neuronal supply of the canine prostate, bladder, and urethra. (Reprinted with permission from Robertson JJ, Bojrab MJ: Subtotal intracapsular prostatectomy results in normal dogs. *Vet Surg* 13[2]:6–10, 1984.)

difficulty defecating (e.g., tenesmus, constipation, ribbon-shaped stool).⁸ However, some patients with prostatic disease have no clinical signs. Signs of systemic illness (e.g., inappetence, lethargy, weight loss) may be observed in approximately 30% of patients.⁸ Pyrexia, peritonitis, endotoxemia, and shock may be associated with prostatic infection, particularly with ruptured prostatic abscesses.

Prostatic diseases are most common in older, intact male dogs.

lation causes an increase in glandular secretion. Parasympathetic innervation of the bladder is important in maintaining the function of the detrusor muscle. The internal urethral sphincter and the smooth muscle tone of the urethra are controlled by sympathetic innervation. Innervation of the external urethral sphincter is supplied by the pudendal nerve, which is also located close to the cranial prostate and bladder neck.

HISTORY, PHYSICAL EXAMINATION, AND DIAGNOSIS

Most patients with prostatic disease present with signs of urinary tract disease (e.g., hematuria, urethral discharge, dysuria, stranguria, urinary incontinence) or

During physical examination, pain on palpation of the caudal abdomen may be evident. A change in prostatic size, consistency, and symmetry may be observed on rectal examination. Gait abnormalities and pain responses on palpation of the hindlimbs, pelvis, and lumbar vertebrae are most common in patients with prostatic neoplasia and may be present in patients with other prostatic disease processes.^{8,9} Infrequently, abdominal enlargement, perineal hernias, or perineal swelling may be noted. Rarely, dogs present with renal failure due to obstruction of the urethra and ureters.

A serum biochemistry panel, complete blood count, and urinalysis should be conducted to determine whether infectious disease processes or electrolyte abnormalities

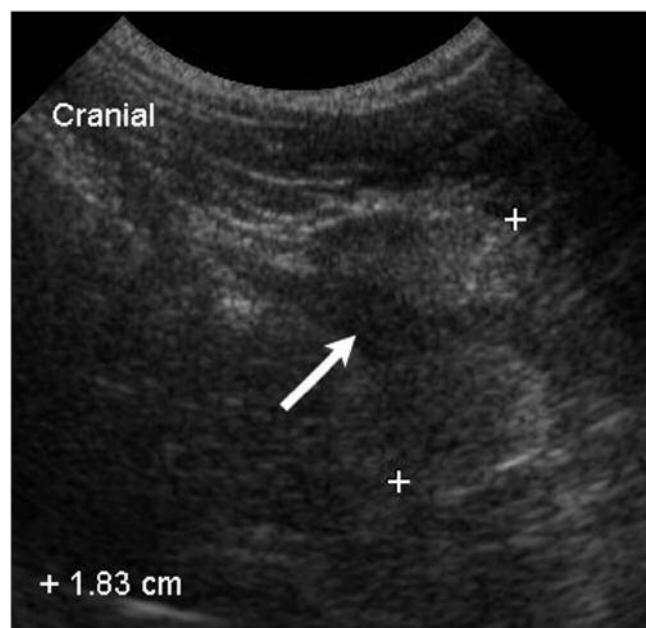


Figure 2. Sagittal ultrasonographic image of the normal prostate of a 10-month-old intact French bulldog. The prostate is bilobate and of homogenous echogenicity. The prostatic urethra is imaged as a hypoechoic longitudinal structure (arrow) surrounded by prostatic tissue.

are present and to evaluate renal and hepatic function status. A urine sample should be obtained by cystocentesis and cultured because microorganisms that infect the prostate often cause concurrent urinary tract infection.^{3,10}

Abdominal ultrasonography is particularly useful for diagnosing prostatic disorders. It allows good visualization of the prostate, draining lymph nodes, surrounding tissues, and distant abdominal organs. The normal prostate appears as a round or bilobate organ caudal to the bladder (Figure 2).¹¹ It has a homogenous appearance with a fine to medium texture and similar echogenicity to that of the spleen.^{11,12} Depending on the plane of ultrasonographic evaluation, the urethra may appear as a round or linear hypoechoic structure within the prostate. The size of the prostate may be measured and evaluated in relation to the dog's body weight and age using established formulas (Table 1).^{13,14} Changes in prostatic echogenicity, size, symmetry, position, or outline indicate a prostatic disorder.

Abdominal radiography provides valuable information about the location, struc-

ture, and size of the prostate.¹² Surrounding structures, particularly the urinary tract, medial iliac lymph nodes, femurs, pelvic bones, and lumbar vertebrae, should be evaluated for any abnormalities that may be indicative of metastasis or space-occupying mass effects. Contrast cystography should be considered when ultrasonography is unavailable and when urethral obstruction, prostaticourethral fistulas, or large cysts that cannot be differentiated from the bladder by other means are suspected.

A definitive diagnosis of prostatic disease is based on cytologic, histopathologic, or microbiologic assessment of prostatic tissue or fluid. Fluid samples for microbiologic and cytologic evaluation are best obtained by ejaculation.^{1,15} Alternatively, a prostatic wash may be used. However, this technique is associated with the risk for spreading bacteria from the prostate if acute prostatitis or a prostatic abscess is present.¹⁶ Furthermore, fluid samples obtained by the prostatic wash technique may be inadequate, and test results may be difficult to interpret, particularly if the dog has a urinary tract infection.¹ Fluid from discrete cavitory lesions may be aspirated. Ultrasound-guided fine-needle aspiration or needle core biopsy can be used to sample focal areas of abnormal prostatic tissue before surgical exploration. Different prostatic disease processes may be present simultaneously and may be the reason for persistence of clinical signs despite therapy.^{3,17} Therefore, samples of prostatic tissue should be obtained for histopathologic and microbiologic evaluation whenever the prostate is treated surgically.

BENIGN PROSTATIC HYPERPLASIA

BPH may be viewed as a normal aging change of the prostate. It is induced by changes in the androgen:estrogen

Table 1. Ultrasonographic Evaluation of Prostatic Dimensions: Formulas for the Calculation of Maximum Physiologic Measurements in Intact Male Dogs^{13,14}

Dimension	Formula
Length (craniocaudal diameter)	$(0.055 \times BW) + (0.143 \times A) + 3.31$
Width (laterolateral diameter)	$(0.047 \times BW) + (0.089 \times A) + 3.45$
Height in sagittal view (H^S)	$(0.046 \times BW) + (0.069 \times A) + 2.68$
Height in transverse view (H^T)	$(0.044 \times BW) + (0.083 \times A) + 2.25$
Volume	$(0.867 \times BW) + (1.885 \times A) + 15.88$ or $(1 \div 2.6 \times [\text{Length} \times \text{Width} \times ([H^S + H^T] \div 2)]) + 1.8 \text{ cm}^3$

BW = body weight; *A* = age.

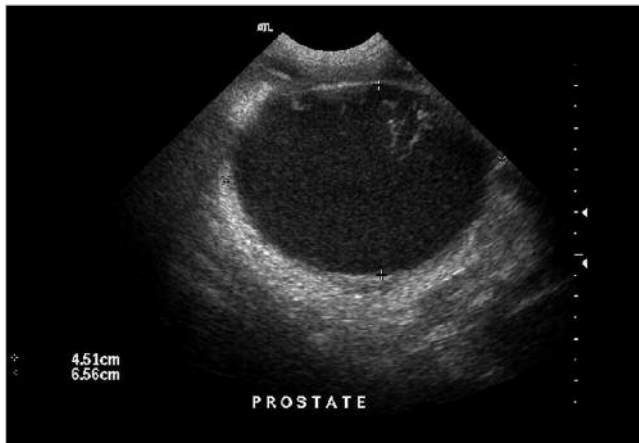


Figure 3. Transverse ultrasonographic view of a prostatic abscess.

gen ratio during aging and affects nearly all intact male dogs older than 9 years.^{2,5,18,19} BPH, which has recently been reviewed in detail,^{4,20} is usually asymptomatic. Rarely, tenesmus and hematuria may be observed.²¹ However, dogs with BPH may be predisposed to developing prostatic diseases (e.g., prostatitis, prostatic abscesses/cysts).^{3,4} The onset of BPH and these associated diseases may be prevented by early castration.²² Uncomplicated BPH rarely requires surgical treatment. Most cases that require treatment resolve after castration. The prostatic size usually decreases by 50% within 3 weeks of surgery, and clinical signs commonly abate within 2 to 3 months.²³ When prostatic disease is concurrent with BPH, castration is used in conjunction with treatment for the specific disease.

CAVITARY LESIONS

Cysts

Microcysts often occur concurrently with BPH and are rarely of clinical importance; however, prostatic

the size and location of the cyst can cause abnormal urination, abnormal defecation, or perineal swellings.^{8,24} A caudal abdominal or pelvic mass may be palpated on clinical examination. On abdominal ultrasonography, cystic changes of the prostate appear as anechoic or hypoechoic structures with smooth margins.¹¹ Mineralization (hyperechogenicity associated with a distal acoustic shadow) may be seen in some cases.²⁵ Cysts may coexist with abscesses and may become infected in nearly 50% of cases.^{3,26} Thus, routine bacterial culture of collected fluid or tissue is warranted. Early removal of detected cysts may decrease the risk for secondary infection and abscessation.

Prostatic Abscesses

Prostatic abscesses may develop subsequent to suppurative prostatitis.²⁷ Alternatively, they may develop due to secondary infection of prostatic cysts.³ *Escherichia coli* is the most common agent of prostatic infections.⁹ *Proteus* spp, *Klebsiella* spp, *Streptococcus* spp, *Staphylococcus* spp, *Pseudomonas* spp, *Mycoplasma* spp, and *Brucella* spp have also been isolated from prostatic abscesses.^{1,3} Dogs with prostatic abscesses may present with signs of systemic illness (e.g., pyrexia, anorexia, lethargy) and may show moderate to severe pain during defecation, urination, and abdominal palpation. A doughy, asymmetric enlargement of the prostate may be felt on rectal examination. Inflammatory leukograms are common laboratory findings. Serum biochemical changes are inconsistent, except for hypoglycemia when severe sepsis is present. The presence of concurrent urinary tract infection raises the index of suspicion for prostatic abscesses caused by the same organism.^{3,28} On abdominal ultrasonography, prostatic abscesses present as hypoechoic or anechoic lesions surrounded by an ill-defined capsule¹¹ (Figure 3). Hyperechoic focal areas suggestive of necrotic debris may be

Benign prostatic hyperplasia and prostatic infections and cysts may be prevented by castration.

retention cysts and paraprostatic cysts require treatment. Prostatic retention cysts are thought to develop from microcysts secondary to increased production or decreased drainage of prostatic secretions.²⁴ Paraprostatic cysts are fluid-filled vesicles found adjacent to the prostate. Except for a connective stalk, they communicate little with the prostate.²⁴ Both types of cysts are uncommon.^{3,8} Although clinical signs are often absent,

observed within the abscess.

Prostatic abscesses require drainage and adequate antibiotic therapy. Intact dogs should be castrated to decrease prostatic fluid secretion and speed up the resolution of the bacterial infection.²⁹ Antibiotic therapy alone is considered noncurative because ischemia often hinders penetration of antibiotics into abscesses. Furthermore, most antibiotics diffuse poorly from the

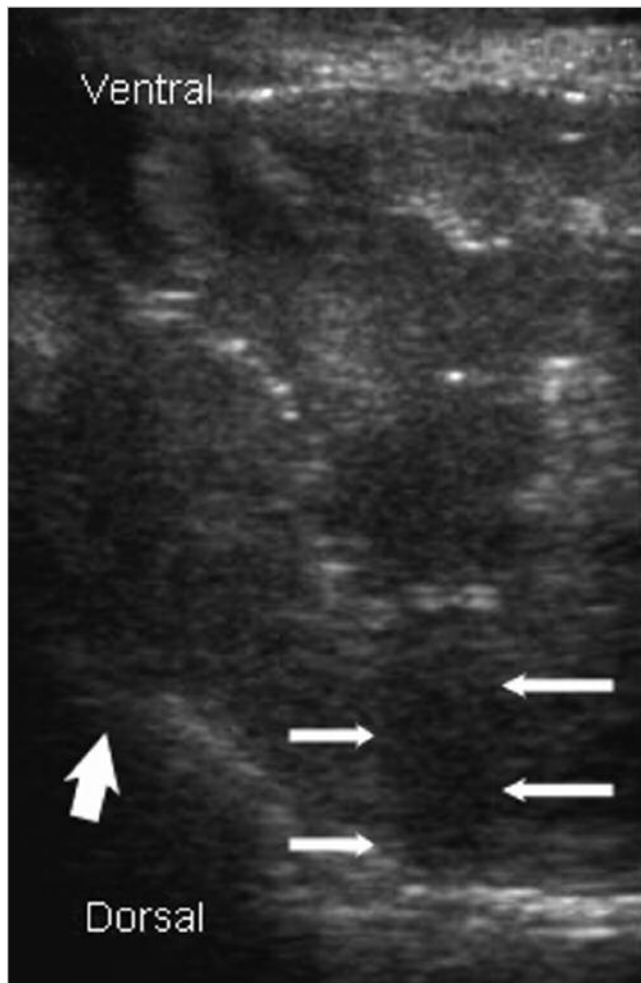


Figure 4. Longitudinal ultrasonographic image of a canine prostate with changes indicative of prostatic neoplasia. The image shows a heteroechogenic appearance, focal hyperechogenicity with distal acoustic shadowing indicative of parenchymal mineralization (*thin arrows*), and loss of capsular outline (*thick arrow*).

bloodstream through intact epithelial barriers into the more acidic prostatic fluid.¹⁶ While the prostate–blood barrier may be disrupted in acute infections, it must be assumed that the barrier is intact in chronic infections and prostatic abscesses. Thus, antibiotics that readily cross the prostate–blood barrier should be given for up to 6 weeks following abscess drainage. For infections caused by gram-positive organisms, trimethoprim–sulfamethoxazole, erythromycin, clindamycin, or chloramphenicol is recommended.³⁰ Infections caused by gram-negative organisms may be treated with trimethoprim–sulfamethoxazole, enrofloxacin, marbofloxacin, or chloramphenicol.^{31,32} Three to 7 days and 30 days after

discontinuation of the antibiotic, the prostate should be reassessed and prostatic fluid cultured to ensure the abscess has resolved.

Prostatic abscesses and cysts may be drained surgically or, as described recently, by percutaneous aspiration.^{33,34} Aspiration of fluid from prostatic abscesses is associated with the risk for causing iatrogenic peritonitis. However, the risk for abscess leakage can be reduced by draining abscesses as completely as possible. In fact, ultrasound-guided percutaneous drainage of abscesses or cysts may replace surgical drainage if the cavitory lesions are well circumscribed and neither concurrent systemic illness nor prostatic neoplasia is suspected.³³ Aspirated abscesses or cysts recur in more than 50% of cases.³³ Recently, instillation of 95% ethanol into the drained abscess cavity was used to resolve a recurrent prostatic abscess in one dog.³⁴

The current surgical treatment of choice for cavitory lesions that are not amenable to complete resection is drainage of the lesion and omentalization.^{35,36} Compared with other drainage techniques (drain placement and marsupialization), omentalization results in fewer recurrences of abscesses or cysts, a lower mortality rate, and fewer incidences of postoperative urinary incontinence.³⁵ Omentalization minimizes the need for long-term antibiotic therapy, and hospitalization periods are generally short. When omentalization is not possible, cysts or abscesses may be resected or drained by other means.

PROSTATIC NEOPLASIA

Prostatic neoplasia is rare in dogs, and only malignant tumors have been reported.³⁷ However, prostatic neoplasia is the most commonly diagnosed prostatic disorder in castrated dogs, which may have a slightly greater risk of developing prostatic neoplasia than intact dogs.^{37,38} Middle-aged to old dogs are more often affected by prostatic neoplasia than young dogs.³⁸ Medium- to large-breed dogs may be predisposed.³⁷ Prostatic neoplasia commonly presents with clinical signs similar to those of other prostatic diseases, with which it may be concurrent. An asymmetric, firm, nodular, painful prostate and concurrent lameness or neurologic deficits in the hindlimbs is highly suggestive of prostatic neoplasia, particularly in castrated dogs.^{9,39} Anorexia, weight loss, or stranguria due to urethral obstruction may also be present.^{39,40} The most common prostatic tumors are prostatic adenocarcinoma and undifferentiated carcinoma.^{37,41} Transitional cell carcinoma, squamous cell carcinoma, and leiomyosarcoma are diagnosed less frequently.

Prostatic tumors present ultrasonographically as solitary or multiple hyperechoic lesions with asymmetrically

enlarged, irregular margins.¹² Evidence of mineralization greatly raises the index of suspicion for prostatic neoplasia (Figure 4). The urethra, bladder, and surrounding tissues and vessels may be invaded. Lymphadenomegaly of the medial iliac lymph nodes or other regional lymph nodes may be present. The diagnosis is confirmed by histopathologic evaluation. Biopsy procedures are associated with the risk for tumor cell implantation along the biopsy tract or surgical site.^{42,43} However, the incidence of tumor cell implantation is considered low.⁴² In all confirmed cases of prostatic neoplasia, radiographs of the thorax, pelvis, lumbar vertebrae, and femurs and aspirates of the medial iliac lymph nodes should be obtained to search for metastasis, which is present in up to 89% of cases at the time of diagnosis^{37,41} (Figure 5).

The prognosis for prostatic neoplasia is poor to grave, depending on the stage of the tumor at the time of diagnosis. Left untreated, most animals die or are euthanized within 1 month of the initial diagnosis.⁴⁴ Surgical exposure of the tumor and intraoperative radiotherapy is currently considered the treatment of choice in patients without evidence of metastasis and may considerably prolong the life of these patients, achieving a median survival time of 9 months.^{1,45} External beam radiation has been applied with limited success and often leads to long-term complications such as colitis.⁴⁶ Surgical treatment by total prostatectomy may be curative in patients without evidence of metastasis.⁴⁷ However, microscopic metastasis is often present at the time of surgery. Furthermore, total prostatectomy is commonly associated with postoperative urinary incontinence.^{48–50} More radi-

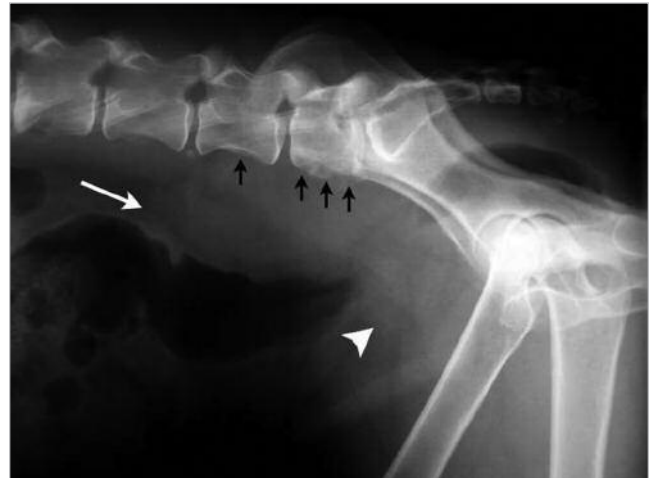

Figure 5. Radiograph of the caudal abdomen of a German wirehaired pointer with prostatic neoplasia. The enlarged prostate appears as a heterogenous mass effect of soft tissue density (arrowhead). Ventral displacement of the descending colon is caused by a mass effect of soft tissue density consistent with enlarged medial iliac lymph nodes (white arrow). Periosteal new bone production (indicative of prostatic metastasis) is identified on the ventral surface of the sixth and seventh lumbar vertebrae (black arrows).

cyclooxygenase [COX]-2).⁴⁴ The survival time of eight dogs that underwent this treatment protocol ranged from 5 to 239 days (median: 103 days), and postoperative urinary incontinence did not develop in any dog. Medical treatment with COX inhibitors alone has also been advocated in dogs with prostatic carcinoma.⁵³ Inhibition of COX-2, which is expressed by 88% of prostatic

Tissue biopsy to obtain samples for histopathologic and microbiologic evaluation should be part of every prostatic surgery.

cal procedures, such as cystoprostatourethrectomy with ureterocolonic anastomosis, are also associated with severe side effects, such as ascending pyelonephritis and urosepsis, and are therefore rarely performed.^{51,52}

Recently, subtotal prostatectomy with a neodymium:yttrium-aluminum-garnet laser has been suggested as palliative treatment for prostatic neoplasia with and without metastasis.⁴⁴ Subtotal prostatectomy was followed by a one-time injection of interleukin-2 (4.5 million IU in 1 ml normal saline) into the remaining prostate and ongoing once-daily administration of 0.1 mg/kg meloxicam (an NSAID that primarily inhibits

carcinomas,⁵³ is thought to result in a decrease in tumor cell proliferation, an increase in apoptosis of tumor cells, and inhibition of tumor angiogenesis. Dogs treated with COX inhibitors (e.g., piroxicam, carprofen) survived significantly longer than dogs that did not receive NSAIDs, with a median survival time of 6.9 months and 0.7 month, respectively.⁵³

Little published information is available about chemotherapy for prostatic neoplasia. Based on data extrapolated from chemotherapy for epithelial tumors of the urinary bladder, cisplatin, carboplatin, or doxorubicin may be used alone or in conjunction with NSAIDs and

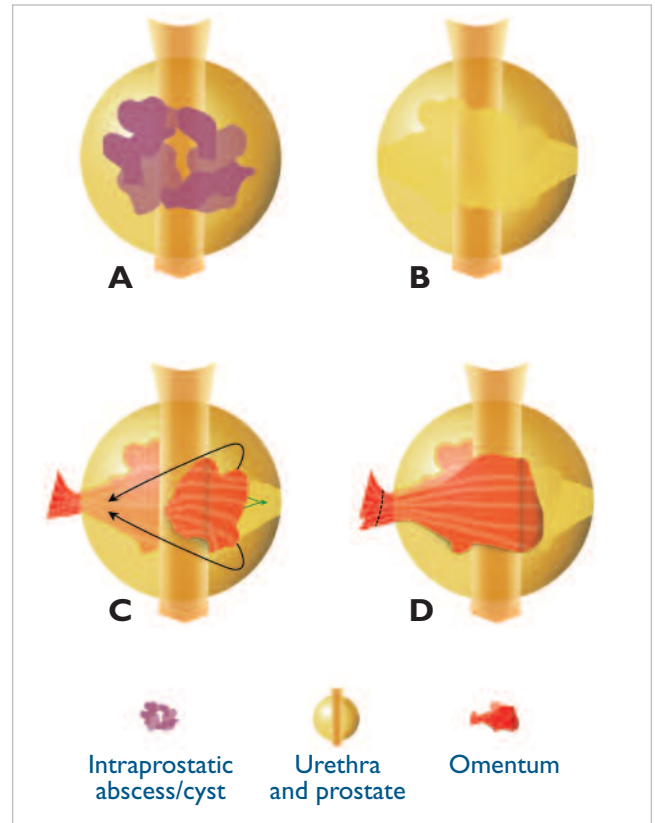


Figure 6. Intracapsular omentalization technique. (A) Schematic representation of the prostate with intraparenchymal abscesses or cysts (ventrodorsal view). (B) Two lateral incisions are made in the prostatic capsule. Abnormal prostatic tissue is removed, avoiding damage to the urethra. (C) The omentum is introduced into the prostate dorsal to the urethra. A tissue forceps may be used to pull the omentum from the contralateral side (green arrow). The omentum is then pulled around the urethra (black arrows). (D) The omentum is sutured to itself outside the prostate to secure it in place.

radiotherapy.^{46,54} Photodynamic therapy has been suggested as an alternative treatment modality in dogs with prostatic carcinoma.⁵⁵ Palliative surgical treatment involving cystostomy, extrapelvic urethral anastomosis, placement of a retained catheter in the urethra, or transurethral resection may be indicated in patients with subtotal or total urethral obstruction.^{43,56} Although prostatic neoplasms are generally not hormone dependent,^{5,41} castration is thought to be beneficial in intact dogs with neoplasia and concurrent BPH.

PRESURGICAL ASSESSMENT AND PREPARATION

Unstable patients should receive appropriate care

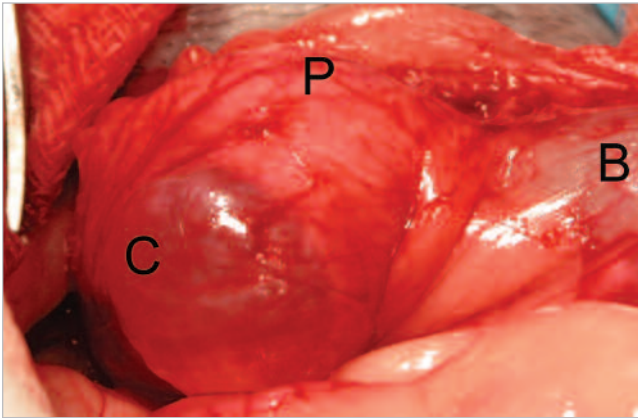


Figure 7. Intraoperative photograph of a prostatic cyst (C) before drainage and omentalization. The bladder (B) and prostatic tissue (P) are also visible.

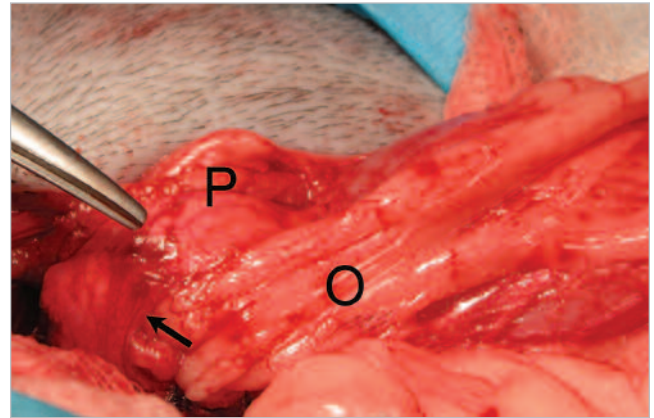


Figure 8. Intraoperative photograph of a prostatic cyst after drainage and omentalization (same dog as in Figure 7). The omentum (O) has been introduced into the cyst cavity after partial resection of the cyst capsule. The remainder of the cyst capsule (arrow) and the prostatic tissue (P) can be seen.

before anesthesia is initiated. This may include (1) correction of electrolyte abnormalities and dehydration with intravenous crystalloid fluids, (2) correction of hypoproteinemia with colloids, and (3) aggressive antibiotic therapy when bacteremia, endotoxemia, or prostatic or periprostatic infection is suspected. The anesthetic protocol chosen should be based on the dog's condition, the anesthetic risk, and the duration of the surgical procedure. Preoperative and perioperative analgesia (e.g., opioids) may reduce postoperative complications associated with pain and reduce surgical recovery time.⁵⁷ Epidural opioids or local anesthetics can be particularly effective.⁵⁸ Standard surgical preparation of the midline and the caudal abdomen, including the

pubic osteotomy will improve exposure. The prostate may be elevated by passing a Penrose drain or umbilical tape around the urethra.²⁷ In all cases, the prostatic tissue or fluid is sampled and submitted for histopathologic and microbiologic evaluation. Intact dogs should be castrated if BPH and cavitory lesions are treated surgically.

Prostatic Omentalization

Omentalization—the placement of omentum in prostatic lesions—makes use of omental angiogenic and phagocytic properties.^{35,36} In theory, the omentum also provides an egress for residual secretions from remaining

Omentalization of prostatic abscesses or cysts is commonly associated with a shorter hospitalization period and fewer recurrences than marsupialization or Penrose drain placement.

periscrotal area (for castration) and prepuce, should be conducted. A urinary catheter placed aseptically before surgery may facilitate perioperative localization of the urethra. Alternatively, a urinary catheter may be placed intraoperatively through a cystotomy incision.⁵⁹

SURGICAL TREATMENT

Access to the prostate is usually achieved through a midline incision of the caudoventral abdomen.²⁷ A perineal approach has also been described.⁶⁰ Following celiotomy, the prostate is exposed and isolated from surrounding tissue using moist laparotomy sponges. In some instances,

pathogenic tissue, provides lymphatic drainage, and minimizes the formation of postoperative adhesions by covering surgically created lesions. Omentalization is the current treatment of choice for cavitory lesions and urethral lacerations.²⁷ Prostatic omentalization may be intracapsular³⁵ or extracapsular after partial resection.³⁶ With intracapsular omentalization, the omentum is placed into the prostate around or along the prostatic urethra²⁷ (Figure 6). After caudal celiotomy and exposure of the prostate, intracapsular abscesses or cysts are approached through a bilateral stab incision into the ventral prostatic capsule. The dorsolateral prostatic tissue should be

avoided to minimize the risk for damage to the neurovascular supply. The lesions are debrided by digital manipulation, suction, and lavage. During debridement, damage to the prostatic urethra may be avoided by palpation of the preoperatively placed catheter. After debridement, the prostatic capsule is unilaterally resected to create an opening for the omentum. A tissue forceps is passed through the contralateral incision to grasp the omentum. The omentum is drawn through the capsulectomy site and around the urethra. The surgeon should aim to loosely fill the debrided cavity with omentum while maintaining omental blood supply. The omental pedicle is then grasped and sutured to the omentum at the entry site.

Adequate omental placement is thought to be important in preventing the recurrence of abscesses or cysts.³⁵ If urethral laceration is present, the omentum is placed along the urethral defect and sutured to the prostatic capsule.²⁷ A urinary catheter is left in place to support healing of the urethral defect. Extracapsular omentalization has been used in conjunction with partial resection of prostatic retention cysts (Figures 7 and 8). Cyst remnants communicating with the urethra or dorsal prostate are not removed in this procedure. Instead, omentum is loosely packed into the cyst cavity and sutured to the cyst remnant. In most cases, omentalization of the prostate does not require surgical lengthening of the omentum. However, an omental pedicle extension that preserves omental viability has been described.⁶¹

Drain Placement

Drain placement was once the treatment of choice for periprostatic or intraprostatic abscesses. However, since the introduction of omentalization techniques, drain placement is recommended only when omentalization is not feasible.³⁵ Following exposure and isolation of the prostate with moist laparotomy sponges, an incision is made into the ventrolateral surface of the prostatic capsule to expose the abscess without disruption of the neurovascular supply.⁶² Abscess material is removed by suction, digital debridement, and lavage, taking care not to contaminate the abdominal cavity. Multiple drains that exit the prostatic capsule ventrally and laterally may be placed in each prostatic lobe.⁶² Alternatively, a single drain that exits the prostate ventrally on both sides of the midline may be placed around the urethra.⁶³ Drains are exteriorized through the abdominal wall and skin paramedian to the celiotomy incision and secured to the skin using nonabsorbable suture material. If the abdomen becomes contaminated with abscess material, the contaminated

site should be lavaged copiously before routine closure.

The timing of drain removal depends on fluid character and volume. In most cases, drains are removed within 10 days.³⁵ After surgery, the patient should be monitored for abdominal discomfort, inguinal edema, anemia, and signs that may indicate septic shock (hypoglycemia, hypoproteinemia, hypokalemia).⁶⁴ Premature drain removal by the patient can be avoided by placement of an Elizabethan collar or side braces.⁴⁸ Urinary incontinence is a long-term complication of drain placement in 21% to 46% of patients.⁶² Urethral fistulation may be evident in up to 25% of all dogs and may require placement of a urinary catheter or surgical intervention.⁶⁴ Abscess recurrence is reported in approximately 20% to 35% of all cases treated with drains.^{35,64}

Marsupialization

Marsupialization is the surgical creation of a large drainage fistula between a prostatic abscess or cyst and the ventral external body wall.^{65,66} Marsupialization of perineal prostatic lesions has also been described.⁶⁷ Abdominal marsupialization is now rarely performed because it often requires extensive postoperative management. Furthermore, it may be associated with long-term complications that necessitate further surgical treatment, such as persistence or recurrence of abscessation and persistence of a continuously draining stoma.⁴⁸ In brief, marsupialization involves (1) performance of caudal celiotomy to gain access to the prostate, (2) creation of an opening (stoma) in the abdominal wall, (3) prolapse of the abscess or cyst through the opening, (4) suturing of the cyst or abscess to the abdominal rectus muscle, (5) incision of the prolapsed cyst or abscess wall and debridement of the cavity, and (6) suturing of the capsule to the skin before closing the celiotomy wound.⁶⁶

Subtotal Prostatectomy

The prostate can be partially resected to treat stable patients with prostatic abscesses, cysts, localized trauma of the prostatic parenchyma, or BPH that is nonresponsive to medical treatment or castration. Subtotal prostatectomy with or without medical treatment or radiotherapy may also be used as palliative treatment for prostatic neoplasia.^{43,44} Compared with Penrose drain placement and marsupialization, surgical resection of abscesses is technically more difficult; however, it results in more rapid recuperation.^{48,68} Abnormal prostatic tissue may be resected by sharp and blunt dissection through a ventral or ventrolateral capsular incision. The

use of electrocoagulation equipment, electroscalpels, or surgical lasers can simplify hemostasis and allows more precise tissue resection.⁶⁹ Severe hemorrhage may be controlled by extracapsular ligation of major blood vessels supplying the prostate and placement of a temporary tourniquet around the terminal aorta.⁵⁹ However, dissection dorsolateral to the prostate should be avoided because it risks neurovascular injury to the bladder and urethra and subsequent incontinence.

Abnormal prostatic parenchyma can be removed by ultrasonic aspiration.⁵⁹ This technique is based on the discrimination of tissues by their water content. Cells with a high water content (the prostatic parenchymal cells) are emulsified by ultrasonic impulse and aspirated, while cells with a low water content (nerves, blood vessels, and connective tissue) are spared. Thus, up to 85% of the prostatic parenchyma may be removed without disruption of the neurovascular supply.⁵⁹ Disruption of the prostatic urethra may be prevented by palpating the urinary catheter and by leaving a small layer of prostatic tissue around the urethra.^{59,69} After aspiration, urethral continuity is confirmed

Total Prostatectomy

Complete surgical removal of the prostate is a technically difficult procedure that commonly results in postoperative complications, particularly urinary incontinence. Urinary incontinence has been reported in 33% to 100% of all cases treated with total prostatectomy.⁴⁸⁻⁵⁰ Other complications seen with total prostatectomy are necrosis of the bladder neck and urethral stricture at the anastomosis. Thus, total prostatectomy is reserved for treatment of prostatic tumors when no metastasis is seen. It may be considered as a “last-resort” procedure in patients with severe trauma to the prostate or severe recurrent abscessation or cyst formation.⁷²

Pubic osteotomy or symphysis splitting may be required to gain optimal access to the caudal prostate. Lateral reflection of the ventral periprostatic fat exposes the vascular supply of the prostate and the vasa deferens. The vasa deferens are ligated, and blood vessels should be ligated or cauterized as close to the prostatic capsule as possible. To minimize nerve damage and subsequent urinary incontinence, cauterization at the dorsal aspect

Urinary incontinence and recurrent or persistent prostatic disease are undesirable long-term complications of prostatic surgery.

by inflating the urethra with fluids (e.g., isotonic saline, lactated Ringer's solution, methylene blue dye solution).⁶⁹ Lacerations may be closed using 4-0 monofilament absorbable suture material. Maintaining a catheter in the urethra during healing provides a stent and facilitates urethral epithelialization. Urethral stricture formation may be absent or minimal as long as a longitudinal strip of urethral epithelium is present.⁷⁰ Omentalization is recommended in conjunction with partial prostatic resection, particularly in cases of incomplete excision of infected tissue or urethral laceration.²⁷ The remaining capsule is partially closed over the residual tissue and omentum using monofilament absorbable suture material.

Noninvasive subtotal prostatic ablation has been reported in a small number of dogs.⁷¹ This procedure uses high-intensity focused ultrasound delivered via a transrectal probe to selectively destroy prostatic tissue.⁷¹

Transurethral resection has been reported to provide temporary relief of urine outflow obstructions in dogs with prostatic neoplasia.⁴³ Transurethral resection requires special cystoscopic equipment and technical skills and is feasible only in medium- to large-breed dogs.

of the prostate should be kept to a minimum. The prostate is then bluntly dissected from the urethra, working alternately from the cranial and caudal ends toward the middle of the prostate. Final removal of the prostate is achieved by transurethral resection. Before resection, stay sutures are placed in the ventral urethral wall cranial and caudal to the resection site to facilitate the orientation of the urethral ends after excision. After the prostate is removed, the ends of the urethra are sutured in a single interrupted pattern, using fine monofilament absorbable suture material (e.g., 4-0 poliglecaprone 25, 4-0 polydioxanone). A Foley catheter left in the urethra for up to 10 days postoperatively provides decompression of the bladder, reduces tension on the anastomosis site, and minimizes urethral stricture formation.^{73,74} Additional decompression of the bladder may be achieved by placing a cystostomy tube.

POSTOPERATIVE CARE

During the recovery period, the patient's vital functions and urine production should be monitored. Urine output should exceed 1 to 2 ml/kg in nonsepticemic patients and

2 to 4 ml/kg in septicemic patients that receive intravenous fluid support. Multimodal analgesia (opioids and NSAIDs) should continue for up to 2 weeks. The duration of pain management depends on the procedure and the response of the patient. The opioid is tapered first.⁷⁵ Urinary catheters and cystostomy tubes may be removed 2 days after subtotal prostatectomy or 7 to 10 days after total prostatectomy. Drains and marsupialization stomata need regular attention, including assessment of drainage fluid quality and quantity, confirmation of drain position, and cleaning of the skin surrounding the drainage opening. Drains may be removed when significant drainage ceases. Removal of catheters or drains by the dog may be avoided by using an Elizabethan collar or side braces.

Postoperative urinary incontinence is common and may resolve spontaneously in the weeks following surgery. If urinary incontinence persists, it may be due to disruption of the neuronal supply to the bladder, the internal urethral sphincter and urethral muscle, or the external urethral sphincter. Urethral pressure profiles and electromyography may help identify the underlying cause of urinary incontinence.⁷⁶ Medical treatment may restore urinary continence in some cases. Bladder detrusor muscle contraction may be enhanced medically with cholinergics (e.g., bethanechol 2.5 to 25 mg tid). α -Agonists (e.g., phenylpropanolamine 1.5 mg/kg tid) are used to improve the internal urinary sphincter tone. Following surgery for a prostatic abscess, antibiotic therapy may need to be continued for 6 weeks or more. Prostatic abscesses treated with omentalization generally do not require postoperative antibiotic treatment, unless a major breach in aseptic technique is encountered.²⁷ A repeat bacterial culture of the urine or prostatic fluid is indicated, particularly in infectious disease processes. Samples should be collected 3 to 7 days and 30 days after cessation of antimicrobial therapy. Ultrasonographic evaluation of the prostate 1 month postoperatively may be considered after treatment of cavitory lesions. Clinical evaluation of the patient at 4 weeks, 3 and 6 months, and 1 year after surgery is recommended.

ACKNOWLEDGMENT

The authors thank Pfizer Animal Health New Zealand for kindly providing support for Dr. Freitag.

REFERENCES

1. Kutzler M, Yeager A: Prostatic diseases, in Ettinger SJ, Feldman EC (eds): *Textbook of Veterinary Internal Medicine*, ed 6. St. Louis, Elsevier Saunders, 2005, pp 1809–1819.
2. Berry S, Strandberg J, Saunders W, et al: Development of canine benign prostatic hyperplasia with age. *Prostate* 9:363–373, 1986.
3. Black GM, Ling GV, Nyland TG, et al: Prevalence of prostatic cysts in adult, large-breed dogs. *JAAHA* 34(2):177–180, 1998.
4. Barsanti JA, Finco DR: Medical management of canine prostatic hyperplasia, in Bonagura J (ed): *Kirk's Current Veterinary Therapy XII*. Philadelphia, WB Saunders, 1995, pp 1033–1034.
5. Leav I, Schelling KH, Adams JY, et al: Role of canine basal cells in postnatal prostatic development, induction of hyperplasia, and sex hormone-stimulated growth; and the ductal origin of carcinoma. *Prostate* 48(3):210–224, 2001.
6. Obradovich J, Walshaw R, Goullaud E: The influence of castration on the development of prostatic carcinoma in the dog. 43 cases (1978–1985). *J Vet Intern Med* 1(4):183–187, 1987.
7. Miller ME: *Miller's Anatomy of the Dog*, ed 3. Philadelphia, WB Saunders, 1993.
8. Krawiec DR, Heflin D: Study of prostatic disease in dogs: 177 cases (1981–1986). *JAVMA* 200(8):1119–1122, 1992.
9. Hornbuckle WE, MacCoy DM, Allan GS, et al: Prostatic disease in the dog. *Cornell Vet* 68 (suppl 7):284–305, 1978.
10. Barsanti JA, Prasse KW, Crowell WA, et al: Evaluation of various techniques for diagnosis of chronic bacterial prostatitis in the dog. *JAVMA* 183(2):219–224, 1983.
11. Burk RL, Feeney DA: *Small Animal Radiology and Ultrasonography: A Diagnostic Atlas and Text*. St. Louis, Elsevier Science, 2003.
12. Mattoon J, Nyland TG: Prostate and testes, in Mattoon J, Nyland TG (eds): *Small Animal Diagnostic Ultrasound*, ed 2. Philadelphia, WB Saunders, 2002, pp 250–266.
13. Kamolpatana K, Johnston GR, Johnston SG: Determination of canine prostatic volume using transabdominal ultrasonography. *Vet Radiol Ultrasound* 41(1):73–77, 2000.
14. Ruel Y, Barthez PY, Mailles A, et al: Ultrasonographic evaluation of the prostate in healthy intact dogs. *Vet Radiol Ultrasound* 39(3):212–216, 1998.
15. Barsanti JA, Shotts Jr EB, Prasse K, et al: Evaluation of diagnostic techniques for canine prostatic diseases. *JAVMA* 177(2):160–163, 1980.
16. Barsanti J, Finco DR: Canine bacterial prostatitis. *Vet Clin North Am Small Anim Pract* 9:679–700, 1979.
17. Rohleder JJ, Jones JC: Emphysematous prostatitis and carcinoma in a dog. *JAAHA* 38(5):478–481, 2002.
18. Brendler CB, Berry SJ, Ewing LL, et al: Spontaneous benign prostatic hyperplasia in the beagle. Age-associated changes in serum hormone levels, and the morphology and secretory function of the canine prostate. *J Clin Invest* 71(5):1114–1123, 1983.
19. Ewing LL, Thompson Jr DL, Cochran RC, et al: Testicular androgen and estrogen secretion and benign prostatic hyperplasia in the beagle. *Endocrinology* 114(4):1308–1314, 1984.
20. Gobello C, Corrada Y: Noninfectious prostatic diseases in dogs. *Compend Contin Educ Pract Vet* 24(2):99–107, 2002.
21. Read RA, Bryden S: Urethral bleeding as a presenting sign of benign prostatic hyperplasia in the dog: A retrospective study (1979–1993). *JAAHA* 31(3):261–267, 1995.
22. Huggins C, Clark PJ: Quantitative studies of prostatic secretion: II. The effect of castration and of estrogen injection on the normal and on the hyperplastic prostate glands of dogs. *J Exp Med* 72:747–762, 1940.
23. Barsanti JA, Finco DR: Canine prostatic diseases. *Vet Clin North Am Small Anim Pract* 16:587–599, 1986.
24. White RA, Herrtage ME, Dennis R: The diagnosis and management of paraprostatic and prostatic retention cysts in the dog. *J Small Anim Pract* 28:551–574, 1987.
25. Head LL, Francis DA: Mineralized paraprostatic cyst as a potential contributing factor in the development of perineal hernias in a dog. *JAVMA* 221(4):500, 533–535, 2002.
26. Penwick RC, Clark DM: Prostatic cyst and abscess with subsequent prostatic neoplasia in a Doberman pinscher. *JAAHA* 26:489–493, 1990.

27. White RA: Prostatic surgery in the dog. *Clin Tech Small Anim Pract* 15(1): 46–51, 2000.
28. Barsanti JA, Finco DR: Evaluation of techniques for diagnosis of canine prostatic diseases. *JAVMA* 185(2):198–200, 1984.
29. Cowan LA, Barsanti JA, Crowell W, et al: Effects of castration on chronic bacterial prostatitis in dogs. *JAVMA* 199(3):346–350, 1991.
30. Baummueller A, Kjaer TB, Madsen PO: Prostatic tissue and secretion concentrations of rosamycin and erythromycin. Experimental studies in the dog. *Invest Urol* 15(2):158–160, 1977.
31. Dorfman M, Barsanti J, Budsberg SC: Enrofloxacin concentrations in dogs with normal prostate and dogs with chronic bacterial prostatitis. *Am J Vet Res* 56(3):386–390, 1995.
32. Baummueller A, Madsen PO: Secretion of various antimicrobial substances in dogs with experimental bacterial prostatitis. *Urol Res* 5(4):215–218, 1977.
33. Boland LE, Hardie RJ, Gregory SP, et al: Ultrasound-guided percutaneous drainage as the primary treatment for prostatic abscesses and cysts in dogs. *JAAHA* 39(2):151–159, 2003.
34. Bussadori C, Bigliardi E, D'Agno G, et al: The percutaneous drainage of prostatic abscesses in the dog [in Italian]. *Radiol Med (Torino)* 98(5): 391–394, 1999.
35. White RA, Williams JM: Intracapsular prostatic omentalization: A new technique for management of prostatic abscesses in dogs. *Vet Surg* 24(5): 390–395, 1995.
36. Bray JP, White RA, Williams JM: Partial resection and omentalization: A new technique for management of prostatic retention cysts in dogs. *Vet Surg* 26(3):202–209, 1997.
37. Bell FW, Klausner JS, Hayden DW, et al: Clinical and pathologic features of prostatic adenocarcinoma in sexually intact and castrated dogs: 31 cases (1970–1987). *JAVMA* 199(11):1623–1630, 1991.
38. Teske E, Naan EC, van Dijk EM, et al: Canine prostate carcinoma: Epidemiological evidence of an increased risk in castrated dogs. *Mol Cell Endocrinol* 197(1–2):251–255, 2002.
39. Leav I, Ling GV: Adenocarcinoma of the canine prostate. *Cancer* 22(6): 1329–1345, 1968.
40. Durham SK, Dietze AE: Prostatic adenocarcinoma with and without metastasis to bone in dogs. *JAVMA* 188(12):1432–1436, 1986.
41. Cornell KK, Bostwick DG, Cooley DM, et al: Clinical and pathologic aspects of spontaneous canine prostate carcinoma: A retrospective analysis of 76 cases. *Prostate* 45(2):173–183, 2000.
42. Nyland TG, Wallack ST, Wisner ER: Needle-tract implantation following US-guided fine-needle aspiration biopsy of transitional cell carcinoma of the bladder, urethra, and prostate. *Vet Radiol Ultrasound* 43(1):50–53, 2002.
43. Liptak JM, Brutscher SP, Monnet E, et al: Transurethral resection in the management of urethral and prostatic neoplasia in 6 dogs. *Vet Surg* 33(5):505–516, 2004.
44. L'Eplattenier HF, van Nimwegen SA, van Sluijs FJ, et al: Partial prostatectomy using Nd:YAG laser for management of canine prostate carcinoma. *Vet Surg* 35(4):406–411, 2006.
45. Turrel JM: Intraoperative radiotherapy of carcinoma of the prostate gland in ten dogs. *JAVMA* 190(1):48–52, 1987.
46. Anderson CR, McNiel EA, Gillette EL, et al: Late complications of pelvic irradiation in 16 dogs. *Vet Radiol Ultrasound* 43(2):187–192, 2002.
47. Peter AT, Steiner JM, Adams LG: Diagnosis and medical management of prostate disease in the dog. *Semin Vet Med Surg (Small Anim)* 10(1):35–42, 1995.
48. Hardie EM: Complications of prostatic surgery. *JAAHA* 20:50–56, 1984.
49. Basinger RR, Rawlings CA, Barsanti JA, et al: Urodynamic alterations associated with clinical prostatic diseases and prostatic surgery in 23 dogs. *JAAHA* 25(4):385–392, 1989.
50. Goldsmit SE, Bellenger CR: Urinary incontinence after prostatectomy in dogs. *Vet Surg* 20(4):253–256, 1991.
51. Stone EA, Withrow SJ, Page RL, et al: Ureterocolonic anastomosis in ten dogs with transitional cell carcinoma. *Vet Surg* 17(3):147–153, 1988.
52. Henderson RA, Smith AN, Higginbotham ML: Prostatic neoplasia: In search of a treatment. *Vet Comp Oncol* 3(1):39–40, 2005.
53. Sorenmo KU, Goldschmidt MH, Shofer FS, et al: Evaluation of cyclooxygenase-1 and cyclooxygenase-2 expression and the effect of cyclooxygenase inhibitors in canine prostatic carcinoma. *Vet Comp Oncol* 2(1):13–23, 2004.
54. Knapp DW, Glickman NW, Widmer WR, et al: Cisplatin versus cisplatin combined with piroxicam in a canine model of human invasive urinary bladder cancer. *Cancer Chemother Pharmacol* 46(3):221–226, 2000.
55. Lucroy MD, Bowles MH, Higbee RG, et al: Photodynamic therapy for prostatic carcinoma in a dog. *J Vet Intern Med* 17(2):235–237, 2003.
56. Mann FA, Barrett RJ, Henderson RA: Use of a retained urethral catheter in three dogs with prostatic neoplasia. *Vet Surg* 21(5):342–347, 1992.
57. Hellyer PW, Fails AD: Pain management for the surgical patient, in Slatter DH (ed): *Textbook of Small Animal Surgery*, ed 3. Philadelphia, WB Saunders, 2003, pp 2503–2515.
58. Quandt JE, Rawlings CA: Reducing postoperative pain for dogs: Local anaesthetic and analgesic techniques. *Compend Contin Educ Pract Vet* 18(2):101–111, 1996.
59. Rawlings CA, Crowell WA, Barsanti JA, et al: Intracapsular subtotal prostatectomy in normal dogs: Use of an ultrasonic surgical aspirator. *Vet Surg* 23(3):182–189, 1994.
60. Welsh EM, Kirby BM, Simpson JW, et al: Surgical management of perineal paraprostatic cysts in three dogs. *J Small Anim Pract* 41(8):358–361, 2000.
61. Ross WE, Pardo AD: Evaluation of an omental pedicle extension technique in the dog. *Vet Surg* 22(1):37–43, 1993.
62. Glennon JC, Flanders JA: Decreased incidence of postoperative urinary incontinence with a modified penrose drain technique for treatment of prostatic abscesses in dogs. *Cornell Vet* 83(3):189–198, 1993.
63. Basinger RR, Rawlings CA: Surgical management of prostatic diseases. *Compend Contin Educ Pract Vet* 9(10):993–1000, 1987.
64. Mullen H, Matthiesen DT, Scavelli TD: Results of surgery and postoperative complications in 92 dogs treated for prostatic abscessation by a multiple Penrose drain technique. *JAAHA* 26:369–379, 1990.
65. Gourley I, Osborne CA: Marsupialization—A treatment for prostatic abscesses in the dog. *Anim Hosp* 2:100, 1966.
66. Hoffer R, Dykes N, Greiner T: Marsupialization as a treatment for prostatic disease. *JAAHA* 13:98–104, 1977.
67. McLain D: Surgical treatment of perineal prostatic abscesses. *JAAHA* 18:794–798, 1982.
68. Rawlings CA, Mahaffey MB, Barsanti JA, et al: Use of partial prostatectomy for treatment of prostatic abscesses and cysts in dogs. *JAVMA* 211(7):868–871, 1997.
69. Hardie EM, Stone EA, Spaulding KA, et al: Subtotal canine prostatectomy with the neodymium: yttrium-aluminum-garnet laser. *Vet Surg* 19(5):348–355, 1990.
70. Roberston JJ, Bojrab MJ: Subtotal intracapsular prostatectomy results in normal dogs. *Vet Surg* 13(2):6–10, 1984.
71. Kincaide LF, Sanghvi NT, Cummings O, et al: Noninvasive ultrasonic subtotal ablation of the prostate in dogs. *Am J Vet Res* 57(8):1225–1227, 1996.
72. Harari J, Dupuis J: Surgical treatments for prostatic diseases in dogs. *Semin Vet Med Surg (Small Anim)* 10(1):43–47, 1995.
73. Cooley AJ, Waldron DR, Smith MM, et al: The effects of indwelling transurethral catheterization and tube cystostomy on urethral anastomoses in dogs. *JAAHA* 35(4):341–347, 1999.
74. Layton CE, Ferguson HR, Cook JE, et al: Intrapelvic urethral anastomosis. A comparison of three techniques. *Vet Surg* 16(2):175–182, 1987.
75. Pascoe PJ: Perioperative pain management. *Vet Clin North Am Small Anim Pract* 30(4):917–932, 2000.
76. Gookin JL, Stone EA, Sharp NJ: Urinary incontinence in dogs and cats. Part II. Diagnosis and management. *Compend Contin Educ Pract Vet* 18(5): 525–540, 1996.

ARTICLE #1 CE TEST

*This article qualifies for 2 contact hours of continuing education credit from the Auburn University College of Veterinary Medicine. **Subscribers may purchase individual CE tests or sign up for our annual CE program.** Those who wish to apply this credit to fulfill state relicensure requirements should consult their respective state authorities regarding the applicability of this program. CE subscribers can take CE tests online and get real-time scores at **CompendiumVet.com**.*

1. The prostate is situated

- a. dorsal to the rectum.
- b. peritoneally and retroperitoneally.
- c. ventral to the bladder.
- d. retroperitoneally only.

2. Disruption of the _____ nerve causes dysfunction of the bladder detrusor muscle.

- a. hypogastric
- b. pelvic
- c. pudendal
- d. sciatic

3. The direction from which most blood vessels enter the prostate is

- a. cranial.
- b. lateral and ventral.
- c. ventral.
- d. dorsal.

4. The most common prostatic disease in castrated dogs is

- a. BPH.
- b. prostatitis.
- c. prostatic abscess.
- d. prostatic neoplasia.

5. Prostatic abscesses are most commonly caused by

- a. microorganisms that cause concurrent orchitis.
- b. microorganisms causing a concurrent urinary tract infection.
- c. hematogenous spread of bacteria.
- d. lymphatic spread of bacteria.

6. Prostatic neoplasia

- a. is common.
- b. often metastasizes.
- c. rarely metastasizes.
- d. is usually benign.

7. _____ is the most common reported postoperative complication associated with total prostatectomy.

- a. Urinary incontinence
- b. Urethral stricture
- c. Urinary tract infection
- d. Death

8. Ultrasound-guided percutaneous drainage is performed in patients with

- a. concurrent severe systemic disease.
- b. well-circumscribed cysts.
- c. multifocal small abscesses.
- d. cyst(s) and concurrent prostatic neoplasia.

9. Which is a benefit of the omentalization technique?

- a. Abscess debridement is not necessary.
- b. Penrose drains can be removed more quickly than in procedures performed without omentalization.
- c. The hospitalization period is commonly shorter than for other drainage procedures.
- d. The prostatic size decreases by 50% within the first 3 days after omentalization.

10. Which of the following statements about long-term antibiotic therapy is true?

- a. It is curative in prostatic abscessation.
- b. It is always indicated when paraprostatic cysts are seen during abdominal ultrasonography.
- c. It may not be needed after abscess removal and omentalization.
- d. It should precede any surgical procedure.