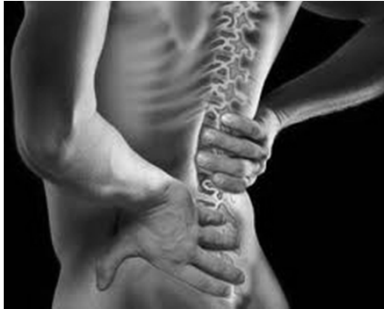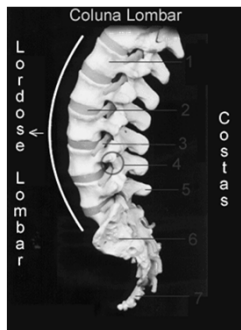


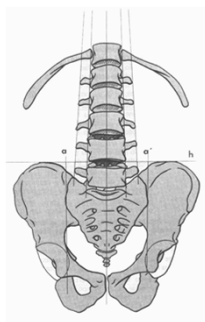
CINESIOLOGIA E BIOMECÂNICA DA COLUNA LOMBAR



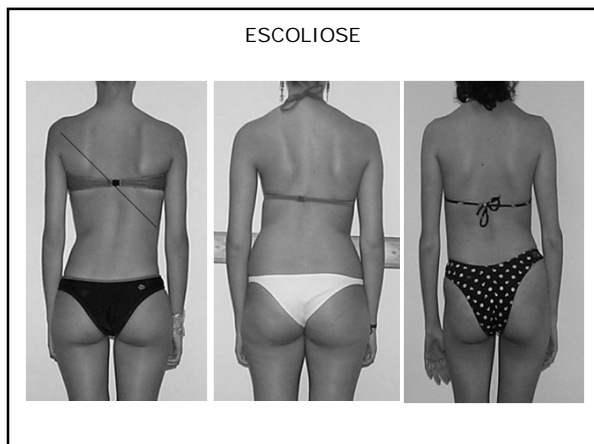
CURSO DE FISIOTERAPIA F.M.U.S.P. FT. ROBERTA F. FONTANA – 2012

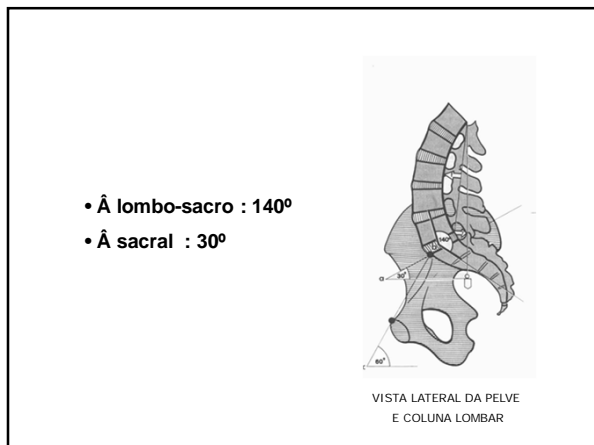
- 5 vértebras lombares
- Curva : lordose
- L1 – limite superior
- L5 – Limite inferior
- L3 – ápice da lordose (mais horizontal)

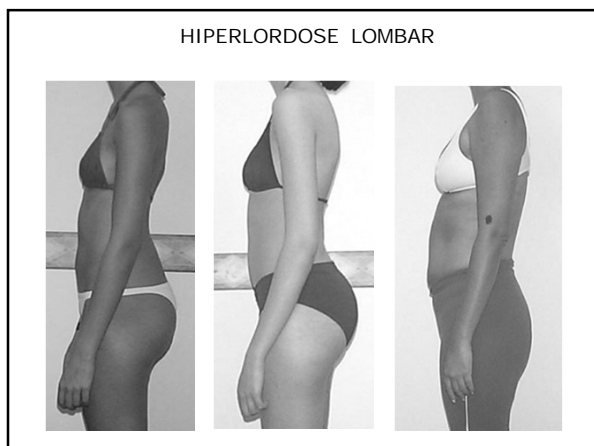


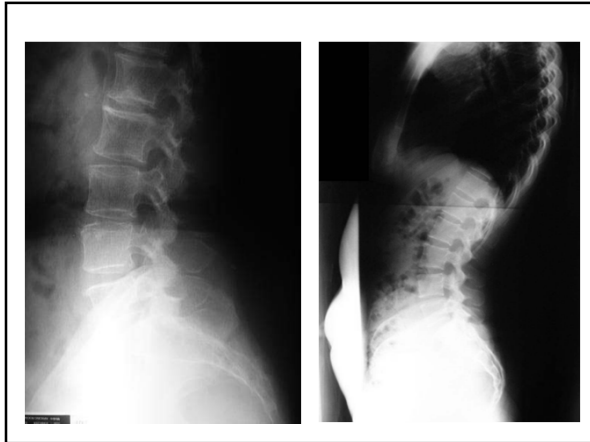


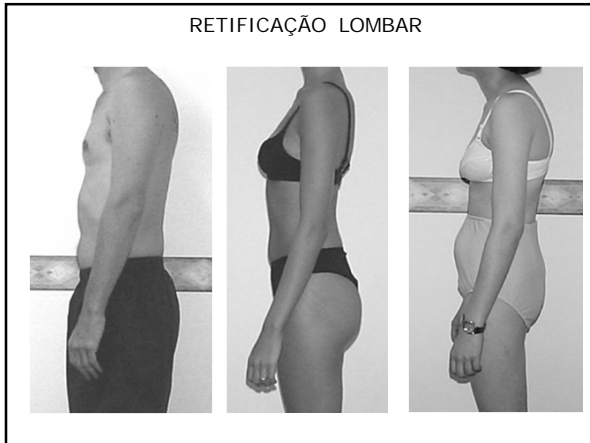
VISTA ANTERIOR DA PELVE E COLUNA LOMBAR

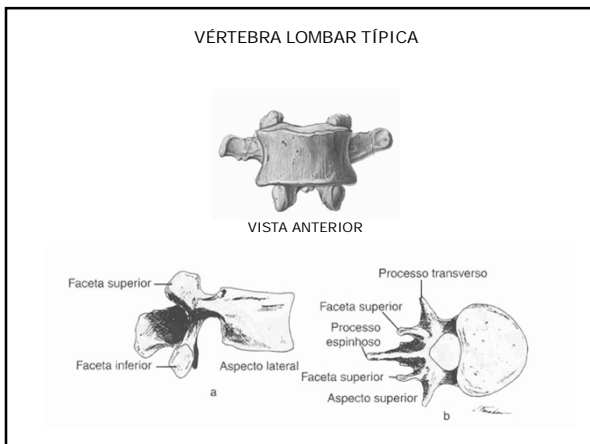


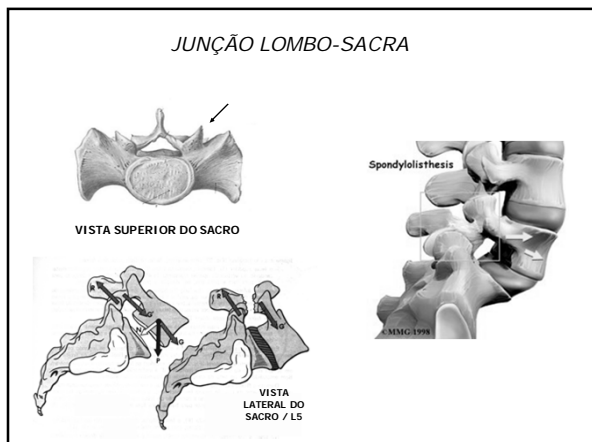


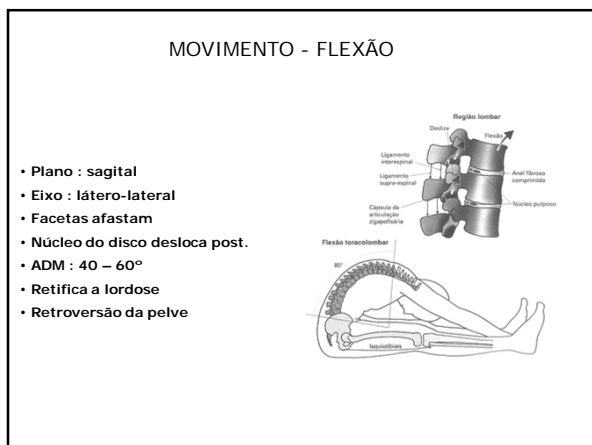


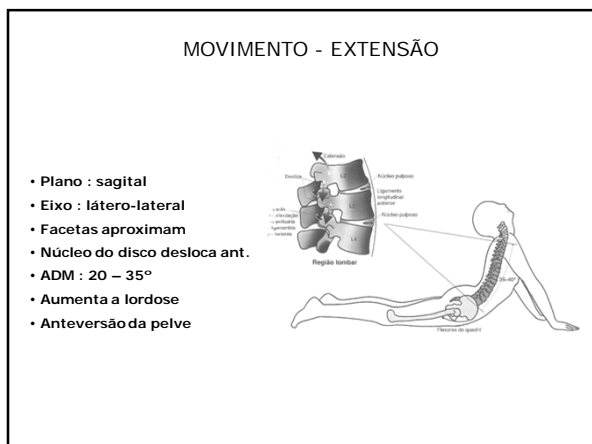




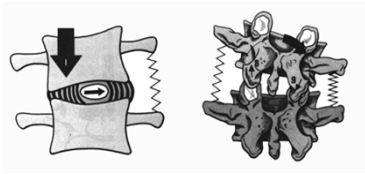






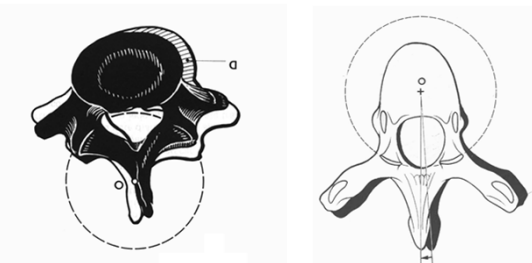


MOVIMENTO - INCLINAÇÃO



- Plano : frontal
- Eixo : ântero-posterior
- Facetas da concavidade se aproximam e da convexidades se afastam
- Núcleo do disco desloca para a convexidade
- ADM : 15 – 30°
- Inclinação da pelve

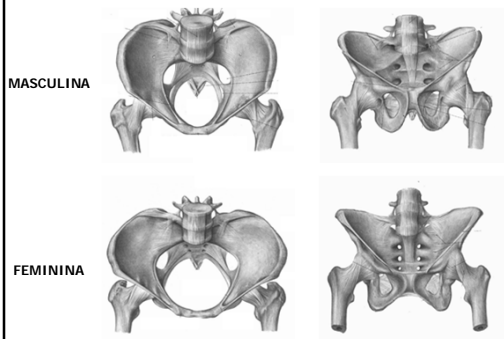
MOVIMENTO - ROTAÇÃO



VÉRTEBRA LOMBAR

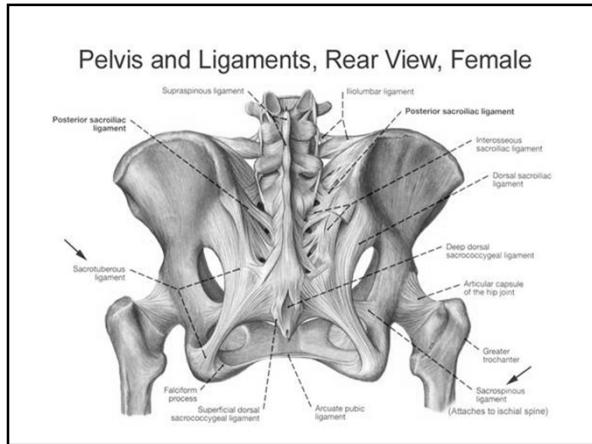
VÉRTEBRA TORÁCICA

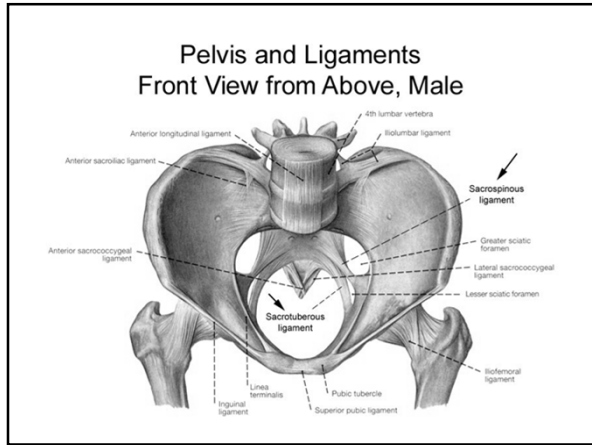
PELVE MASCULINA X FEMININA

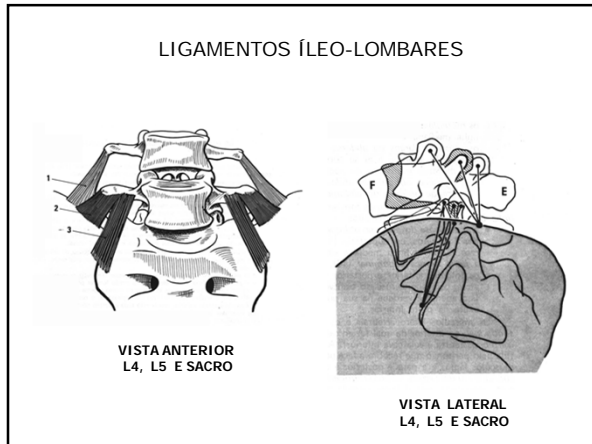


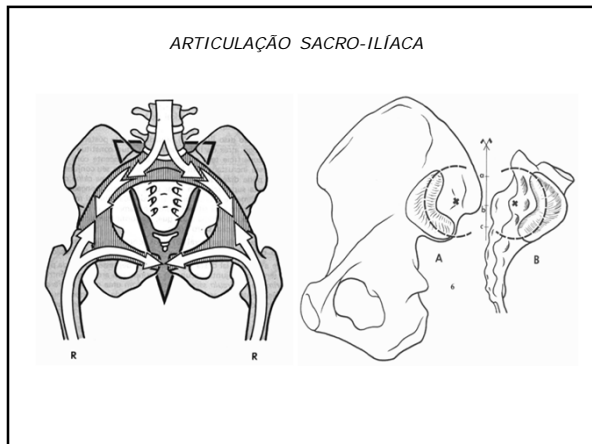
MASCULINA

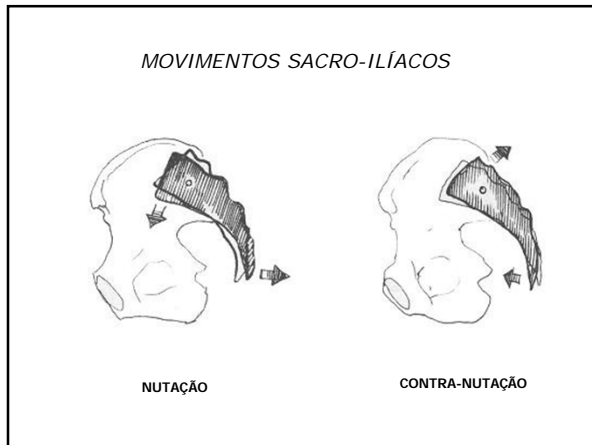
FEMININA






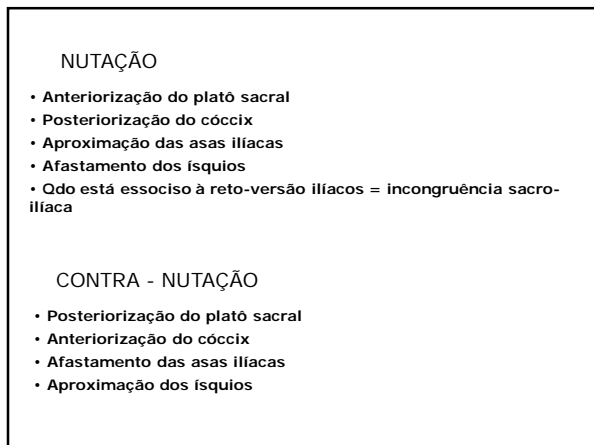


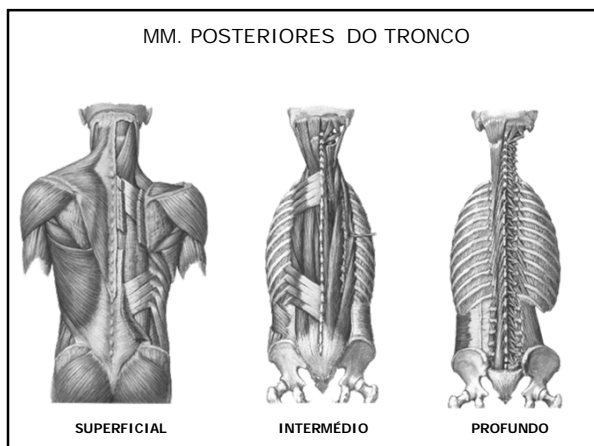


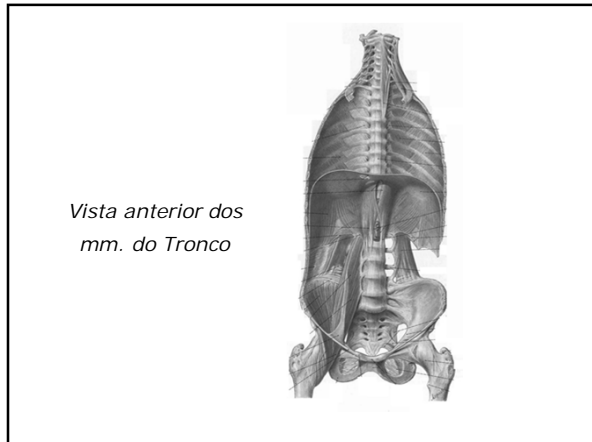


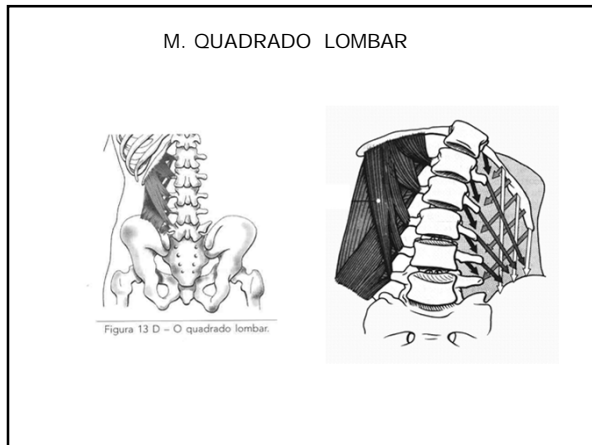


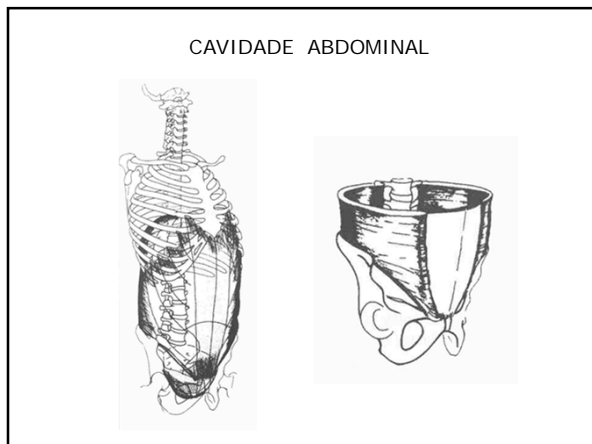


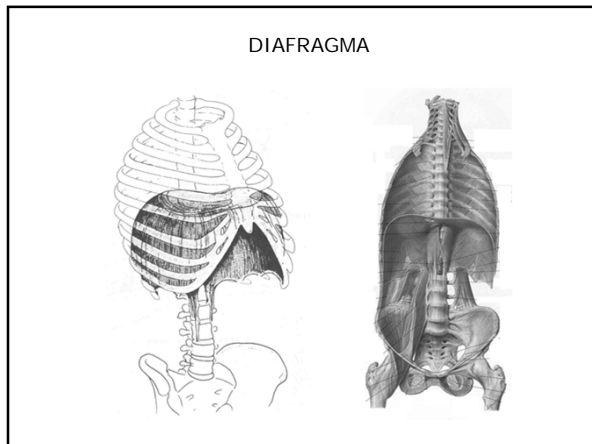


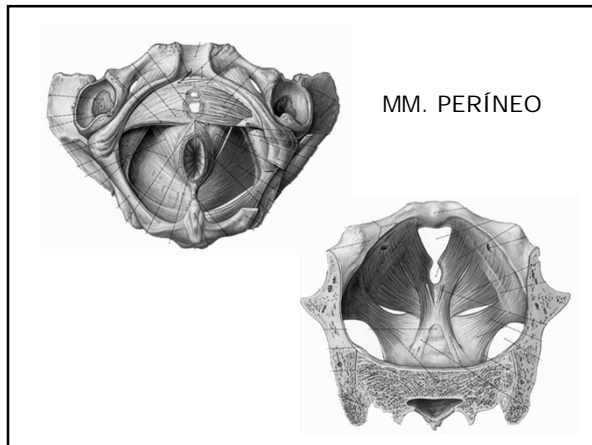


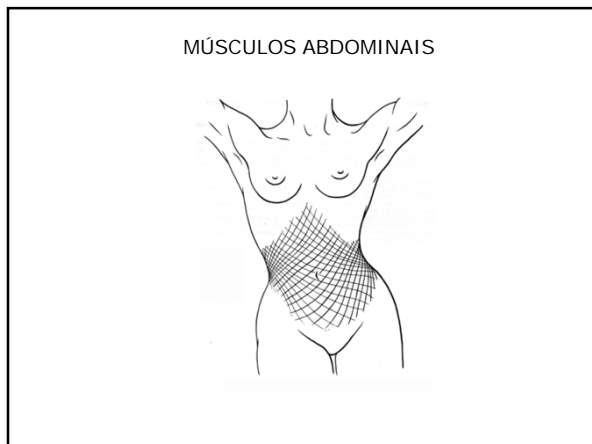




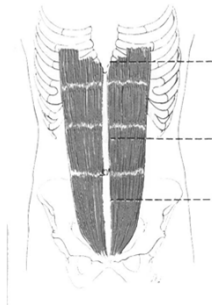




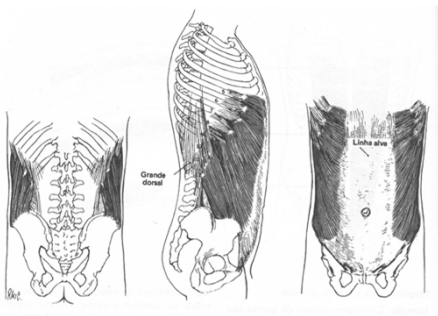




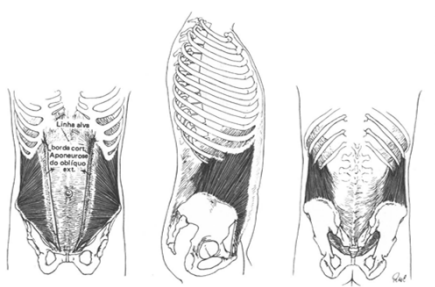
MÚSCULO RETO-ABDOMINAL

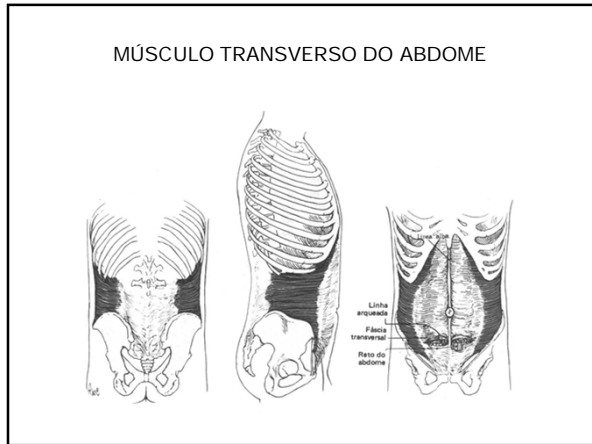


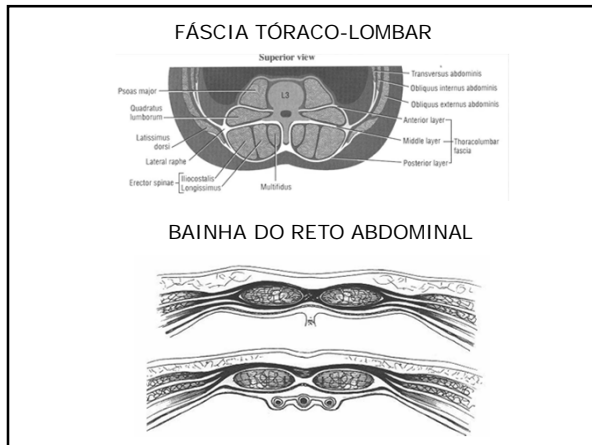
MÚSCULO OBLÍQUO EXTERNO

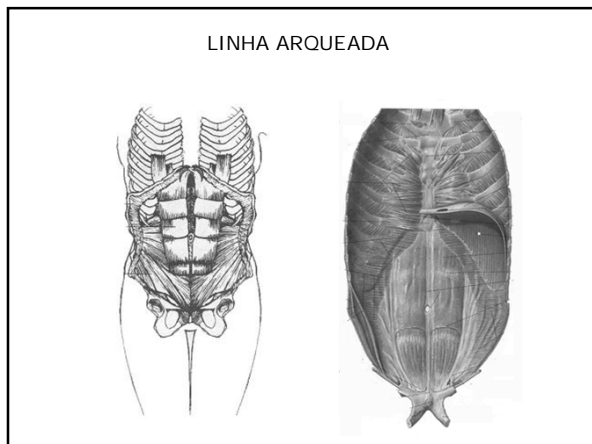


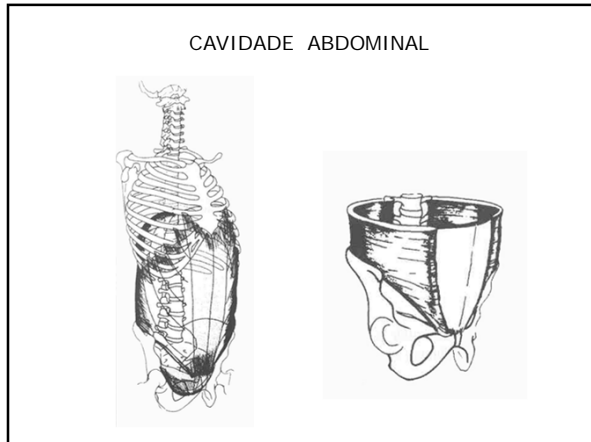
MÚSCULO OBLÍQUO INTERNO

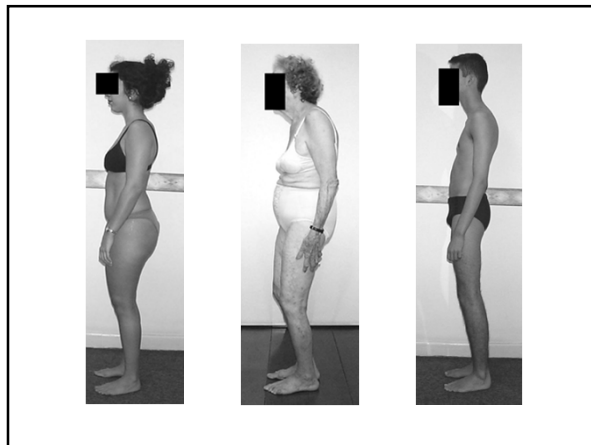






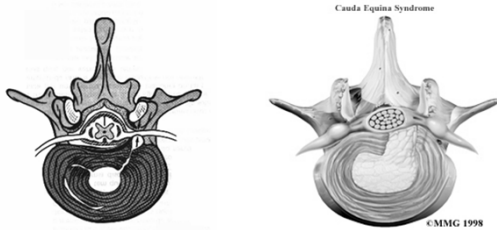




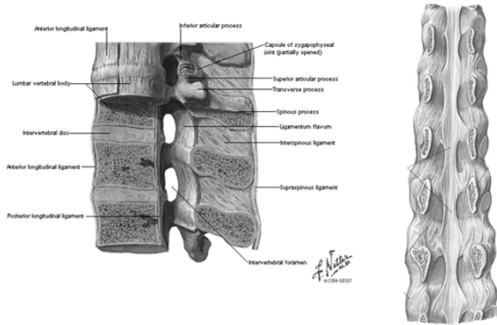


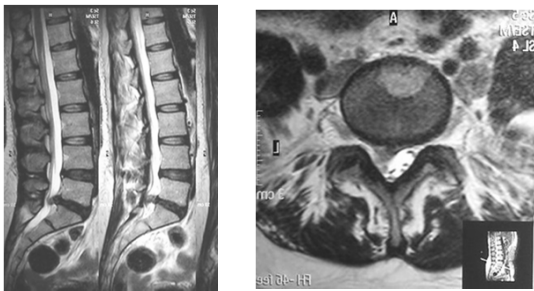


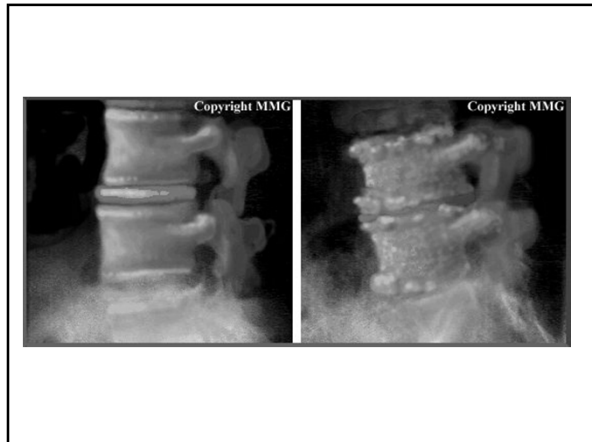
DOR IRRADIADA - CIATALGIA




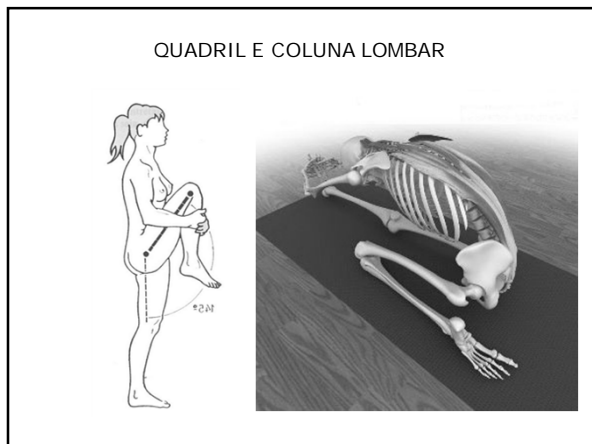
LIGAMENTOS VERTEBRAIS

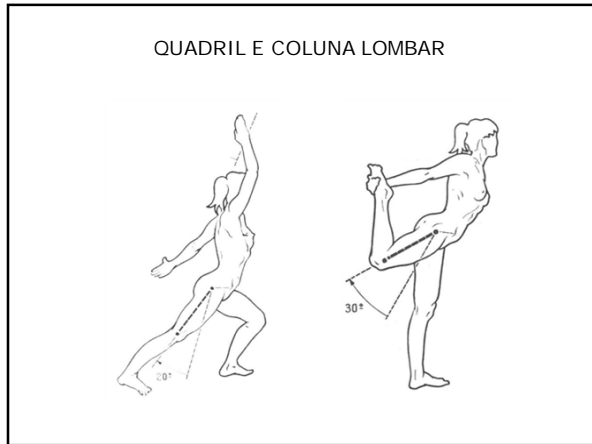


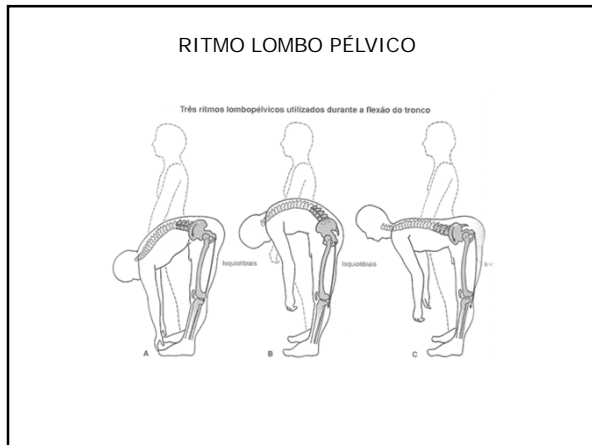


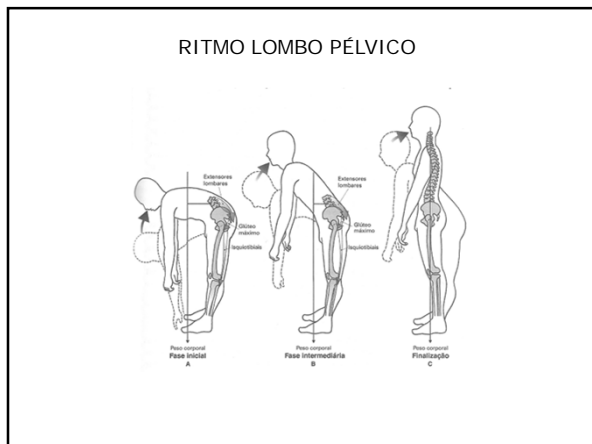


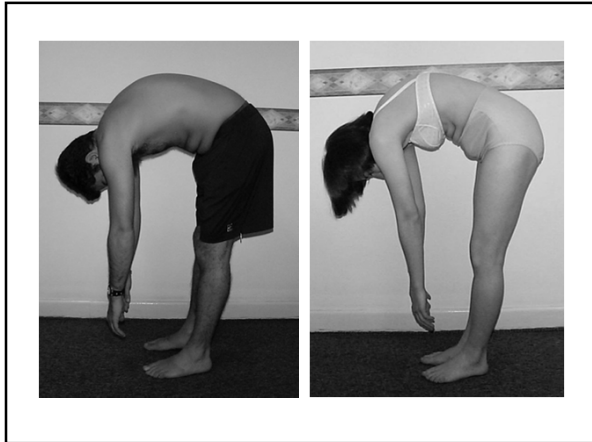


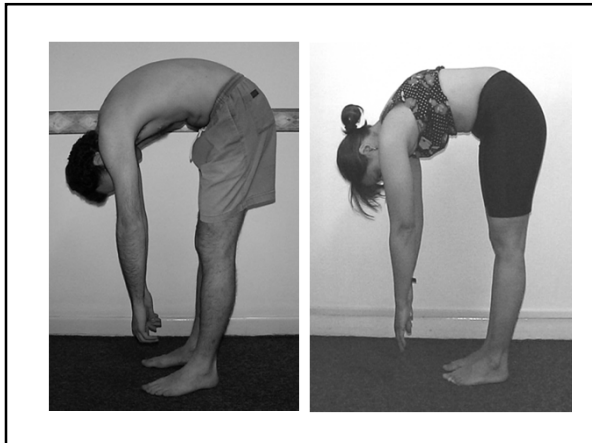


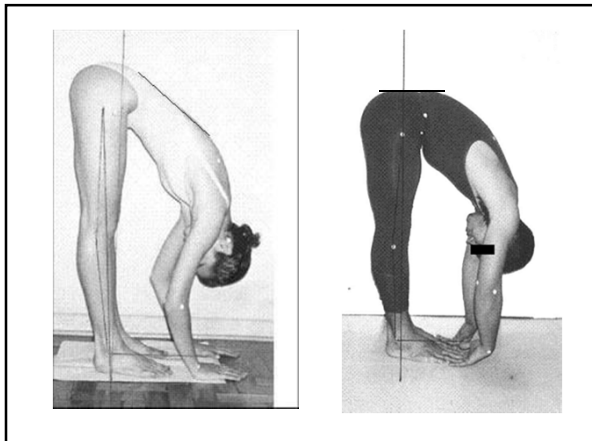





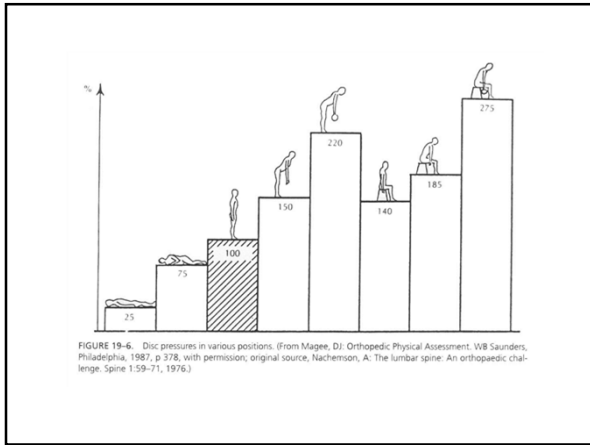












<http://youtu.be/f3rciqzHMmM>