

Toxoplasma in Animals, Food, and Humans: An Old Parasite of New Concern

Beniamino T. Cenci-Goga,¹ Paul V. Rossitto,² Paola Sechi,¹ Cheryl M.E. McCrindle,³ and James S. Cullor²

Abstract

All hosts, including humans, can be infected by any one of the three forms of the parasite *Toxoplasma gondii* that correspond to three morphological stages: tachyzoite, bradyzoite, and sporozoite form. Felids are definitive hosts for *T. gondii*, which is an intracellular pathogen that infects a wide range of warm-blooded intermediate hosts. Toxoplasmosis is a disease where the interest of the diverse medical and veterinary specialties converge. Awareness needs to be increased that toxoplasmosis can induce clinical disease not only in immunocompromised patients or through congenital infections, but also in healthy patients. This is a review article that aims at illustrating why toxoplasmosis should be regarded a veterinary public health issue and how veterinary practitioners can contribute in controlling the infection.

Introduction

TOXOPLASMA GONDII is an obligate intracellular protozoon with a wide range of warm-blooded intermediate hosts, including humans. Cats are the definitive hosts. *T. gondii* can cause subclinical infections or clinical disease with a wide range of clinical signs in intermediate or definitive hosts. Since the introduction of the methylene blue dye test by Sabin and Feldman, seroepidemiological studies in humans provided evidence that up to one-third of the world human population has been exposed to the parasite (Jackson and Hutchison, 1989). In Europe the 2003/99 EC directive stipulates that member countries report seroprevalence results in humans, every year or every other year, according to their epidemiological status (Anonymous, 2003). Despite this, accurate information on Toxoplasma infections in humans and animals is incomplete and the European Commission applied to the European Food Safety Authority (EFSA) in 2007 for recommendations on the surveillance and control methods for humans, animals, and food. Toward the end of 2007, EFSA published an opinion in the *EFSA Journal* (Anonymous, 2007) that concluded that the analytic methods to be used to detect and identify Toxoplasma in food and animals should be listed according to their sensitivity, specificity, and other parameters associated with reliability and repeatability. In the United States, according to Centers for Disease Control and Prevention, "Toxoplasmosis is considered to be the third leading

cause of death attributed to foodborne illness in the United States" (Anonymous, 2009c). Given that Toxoplasma in its asexual stage can parasitize all homeotherms, veterinarians play a very important role in clinical veterinary diagnosis but also in the protection of public health. World-wide epidemiological investigations with collaboration between veterinary and human health institutions are required to further elucidate the complex epidemiology of toxoplasmosis in its definitive and intermediate hosts. This review article aims at illustrating why toxoplasmosis should be regarded a veterinary public health issue and how veterinary practitioners can contribute in controlling the infection.

Etiology and Pathogenesis

T. gondii—from the Greek, to'xon: bow and plasma: shape, whereas gundi, *Ctenodactylus gundi*, is the North African rodent from which Toxoplasma was first isolated in 1908 (Weiss and Kami, 2007)—is a cosmopolitan protozoon (Anonymous, 2009b) with no host specificity in the asexual stage (it can parasitize all mammals, including humans and felids), whereas in the sexual stage it is specific to felids where it becomes localized in the intestine. Toxoplasma can become systemic via the blood stream and localize in vital organs, muscle tissue, and the nervous system. All hosts, including humans, can be infected by any one of the three forms of the parasite that correspond to three morphological stages: tachyzoites (in pseudocysts and free in exudates, blood,

¹Sezione di Ispezione degli Alimenti di Origine Animale, Facoltà di Medicina Veterinaria, Università degli Studi di Perugia, Perugia, Italy.

²Veterinary Medicine Teaching and Research Center, UC Davis School of Veterinary Medicine, Tulare, California.

³Department of Paraclinical Sciences, Faculty of Veterinary Science, University of Pretoria, Onderstepoort, South Africa.

secretions, and excretions), bradyzoites (in tissue and organ cysts) (Fig. 1), or sporozoites (in oocysts in cat feces) (Dubey, 2008; Innes, 2010).

The sexual stage takes place in the intestinal epithelium of a felid (Fig. 2). The epithelial cells are infected with tachyzoites or bradyzoites present in ingested tissue or by sporozoites (in oocysts in cat feces) eliminated in another felid's feces that have contaminated food (or water) or by direct transmission of oocysts. Schizogony (endopolygony) takes place in the intestinal mucosa and schizonts form in the intestinal tract, in 3 to 15 days, to give rise to gametes. After fertilization, the female gamete becomes a zygote and then an immature oocyst. Oocysts are first expelled in the intestinal lumen and then to the outside in feces: sporogony and maturation of the oocysts can take place, in 1–5 days, only in the outside environment (Lappin, 2010).

In intermediate hosts, *T. gondii* undergoes two phases of asexual development: in the first phase, tachyzoites multiply rapidly by repeated endodyogeny in many different types of host cells; in the second phase, tachyzoites of the last generation determine the formation of tissue cysts where bradyzoites multiply slowly by endodyogeny. Tissue cysts are the terminal life-cycle stage in the intermediate host and are immediately infectious (Dubey, 2008).

Tissue cysts can also be found in felids when some zoites (sporozoites, tachyzoites, or bradyzoites) break-up the intestinal *lamina propria*, get phagocytized, and multiply by endodyogeny (Anonymous, 2007).

Cats

Seroprevalence varies according to age and lifestyle, and higher values are found in strays than in house cats (Dubey *et al.*, 2008a). In Europe data made available in 2009 show results of a survey with only limited indications on how the analyses were done (Anonymous, 2009a). In the United States a prevalence of 31% in >12,000 cats that underwent serological tests has been reported (Vollaire *et al.*, 2005).

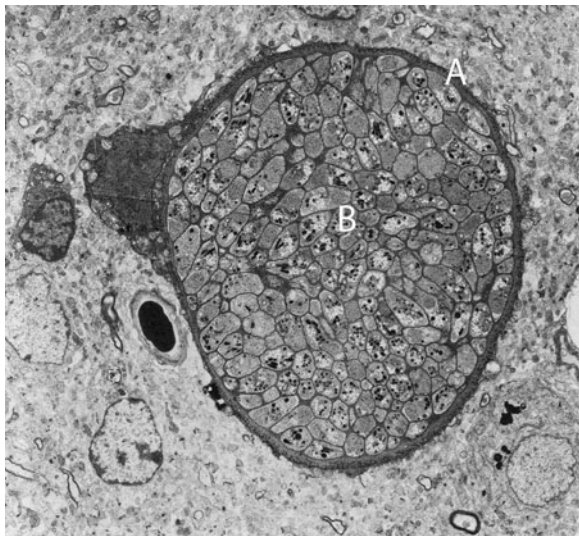


FIG. 1. Tissue cyst in mouse brain on electronic transmission microscopy (Baldelli, 1983). A, cyst wall; B, bradyzoites. Kindly supplied by Dr. Marcello Tosti, Veterinarian, Perugia.

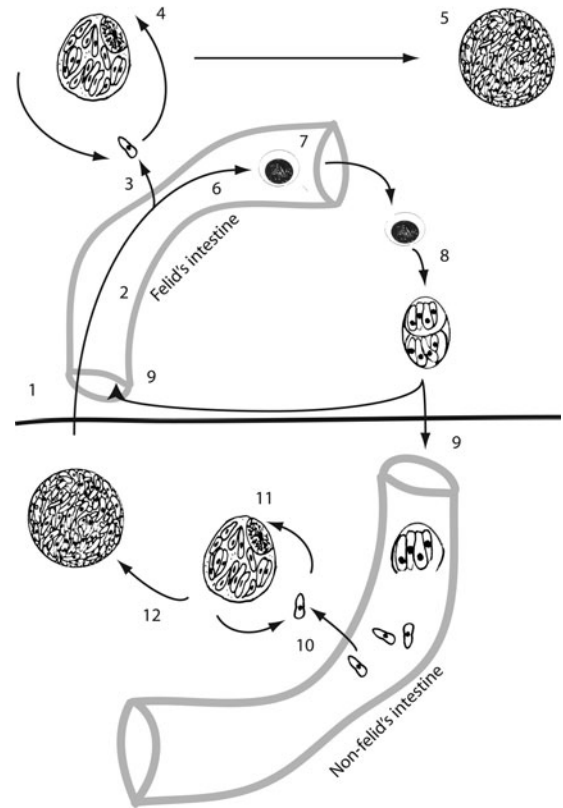


FIG. 2. Life cycle of *Toxoplasma gondii*. Development in the intermediate host is illustrated below the horizontal bar; development in the definitive host is illustrated above the horizontal bar: (1) cyst ingested by a felid, (2) schizogony in the felid's intestinal mucosa, (3) diffusion of zoites to the felid's body, (4) pseudocyst, (5) cyst, (6) gamogony, (7) oocyst formation and expulsion, (8) sporogony and maturation of the oocysts that contains two sporocysts, each containing four sporozoites, (9) oocyst ingested by hosts, (10) diffusion of zoites to the non felid's body, (11) pseudocyst, and (12) cyst.

Since the large amount of figures available to the scientific community does not come from coordinated international or national studies, a filter suited to collect data on clinical toxoplasmosis in cats could be veterinary clinics that might also play an important role in controlling this disease. It must be said that in the absence of evident symptoms, the diagnosis is never easy, even in cases where the veterinarian has included toxoplasmosis in the possible differential diagnoses, especially when there is no possible recourse to laboratory confirmatory testing, which can be very expensive and not always available in many veterinary clinics (Lappin, 2000; McConnell *et al.*, 2007; Falzone *et al.*, 2008).

Most infected cats are asymptomatic, whereas clinical toxoplasmosis is mostly manifested in pneumonia, and in cats that subsequently died the most common signs were sensory depression and anorexia (Dubey, 2008). Other consequences of the infection are hepatitis, pancreatic necrosis, myositis, myocarditis, uveitis, dermatitis, and encephalitis with the worst lesions being in kittens with congenital infections (Lappin, 2000; McConnell *et al.*, 2007). Analogously with humans, cats with immune deficiency syndrome (e.g., feline immunodeficiency virus) are found to have a predisposition

to systemic toxoplasmosis (Davidson *et al.*, 1993; Levy *et al.*, 2004).

In cases of complicated ocular disease or nervous system symptoms, it is always opportune to include a laboratory test for *Toxoplasma* (Levy *et al.*, 2004). Ocular infections give rise to retinochoroiditis, uveitis with mydriasis, and photophobia leading to blindness. When checking for clinical signs of the nervous system, the veterinarian should take note of any altered motor coordination: signs of hyperesthesia, behavioral changes (e.g., moving in circles with ears lowered, typical signs of fear or aggressiveness), difficulty in mastication or swallowing, epileptic type convulsions, and urinary incontinence (Levy *et al.*, 2004). Various studies have been carried out in the United States on the causes of uveitis in cats and the most common causative agents are *T. gondii* (>70%), feline leukaemia virus (about 6%), feline immunodeficiency virus (>20%), infective peritoneal virus (about 6%), and mycosis (Lappin, 2000).

The oocysts shed by cat in feces (millions of oocysts after 1–3 weeks from ingestion of sporulated oocysts or tissue cysts) are very resistant in the environment where they sporulate after 1–5 days, thereby becoming infective for humans and the other vertebrates. The oocyst shedding phase is followed by development of immunity in the cat for a variable period of time, lasting for up to >6 years. The relatively short oocyst shedding phase and the length of immunity explain the frequent negative results of the coprologic investigation in seropositive cats (Lappin, 1996; Dubey *et al.*, 2009).

After ingestion of the sporulated oocysts or tissue cysts, *T. gondii* penetrates the epithelial cells and spreads through the organism via the lymphatic and haematological systems. When there is a cell-mediated and humoral immune response, dissemination of the parasite in tissue does not give rise to evident clinical signs and the tissue cysts develop and persist for years after the infection. Brain, liver, lungs, skeletal muscles, and eyes are the sites of the first phases of multiplication and chronic infection (Greene, 2006). Sometimes the parasite goes through rapid phases of multiplication for no known reason, followed by the appearance of clinical symptoms (Bowman *et al.*, 2002).

Humans

The infection is the direct consequence of eating food contaminated by oocysts eliminated by felids or transported by arthropods, mollusks, or coprophagous birds; by ingestion of cysts or pseudocysts in meat; by inhalation or inoculation of zoites; or by accidental ingestion (hands to mouth for example) of zoites eliminated in secretions and excreta of infected animals (placentas from infected abortions for example) or contained in Flügg droplets (Jones *et al.*, 2009a).

Infection in adults rarely causes disease, except in immunocompromised patients (Mele *et al.*, 2002). Mention should be made here of recent cases of pneumonia attributed to strains present in the past in South America, the so-called genetically atypical strains that are highly virulent even in immunocompetent individuals (De Salvador-Guillouët *et al.*, 2006; Leal *et al.*, 2007).

Prenatal infection is the direct consequence of a primary infection of the mother during pregnancy. Congenital toxoplasmosis ranges from sub-clinical forms to extremely serious cases leading to fetal or neonatal death. In these cases the

central nervous system and the eyes are constantly infected, whereas other organs such as the liver, spleen, kidneys, and lungs are rarely involved. Infections in the first stages of pregnancy can bring about abortion, death, or serious fetal damage, such as retinochoroiditis, endocranial calcification, hydrocephaly, and microcephaly (Jones *et al.*, 2009b). In the later stages of pregnancy, on the other hand, *T. gondii* infections are sub-clinical, even though retinochoroiditis and neurological disorders are sometimes found (Bossi and Bricaire, 2004). Many reports confirm that the classic clinical manifestations (Sabin's tetrad—retinochoroiditis, intracranial calcification, hydrocephaly, and central nervous system abnormalities) are found in 5% of infected newborns, whereas in the majority of prenatal infections there is no congenital disease. Later in life, however, the disease can be re-activated due to persisting tissue cysts (SYROCOT, 2007).

There are no treatments able to eliminate these cysts from an infected organ. This is why some experts suggest that pregnant women with seroconversion documented after conception should be treated with spiramycin (Jones *et al.*, 2009b).

Ocular toxoplasmosis is a consequence of prenatal infection only in one-third of cases and it is considered a probable consequence of postnatal infections (SYROCOT, 2007). The severity of ocular lesions depends on the length of infection and inflammatory intensity. The clinical picture presents necrotizing retinitis with variations in lesion size, number, and aspect. Lesions can be either monolateral or bilateral, with re-activation occurring in 80% of cases. More rarely, but not less serious, are the manifestations of anterior uveitis, and inflammation of sclera and papilla (Hall *et al.*, 2009).

Recent epidemiologic studies indicate that infectious agents may contribute to some cases of schizophrenia. In particular, several epidemiological, behavioral, and neurochemical studies suggested the existence of an association between schizophrenia and past history of infection by *T. gondii* (da Silva and Langoni, 2009; Dion *et al.*, 2009; Gaskell *et al.*, 2009; Xiao *et al.*, 2009; Yolken *et al.*, 2009; Zhu, 2009).

Food-producing animals

The clinically manifested disease in food-producing animals is not a veterinary health problem, due to its low prevalence (Dubey and Jones, 2008). On the other hand, food-producing animals may represent a real risk for transmission of the disease to humans, either directly or through farming (Samra *et al.*, 2007; Cenci Goga, 2009).

Pigs. Clinical signs of the infection are rare in pigs but can cause premature births and pneumonia. Rare cases of myocarditis and encephalitis have been reported (Dubey and Jones, 2008). Old reports cite nervous system clinical signs (tremors and ataxia), coughing, diarrhea, and a 50% mortality rate, as well as still born and premature births, and neonatal deaths (Farrell *et al.*, 1952; Sanger and Cole, 1955). These reports, however, could have attributed cases to *Toxoplasma* infection when in reality they were complicated by other factors (Dubey and Beattie, 1988). Probably, the only case of well-documented infection followed by acute toxoplasmosis was that described in 1979 when autopsy on a 4-week-old pig, after 14 days of diarrhoea, revealed signs of lymphadenitis, pneumonia, encephalitis, and necrotising enteritis, and

tachyzoites were detected in all lesions (Dubey *et al.*, 1979). Most infections are actually sub-clinical or feature non-pathognomonic signs such as hyperthermia, anorexia, and tachypnea (Anyarat *et al.*, 2006; Poljak *et al.*, 2008). An attempt at making a summary of available data was made by Tenter *et al.* in Europe (Tenter *et al.*, 2000) and by Dubey and Jones in the United States (Dubey and Jones, 2008). Seroprevalence ranged from 0% to 64% in fattened pigs and from 3% to 31% in breeding females in Europe, whereas in the United States low prevalence was noted in companies with better management protocols (cat and rodent control). Overall, it can be said that lower prevalence (in many regions almost at zero) is found in indoor stalls with excellent management, whereas higher values, in certain cases above 60%, are found on farms where animals are not kept in enclosed and controlled spaces (for example, on free-range farms or badly managed farms) (Dubey and Jones, 2008).

Cattle. There have been no confirmed cases of clinical toxoplasmosis in cattle and probably many cases of abortion were attributed to *T. gondii* before the discovery that *Neospora caninum* can provoke abortions in cattle (Dubey *et al.*, 1988). Bovine are not an important reservoir of the parasite, and even though they can be infected by ingestion of *T. gondii* oocysts, within a few weeks the bovine host responds and reduces the parasite to unidentifiable levels in laboratory diagnostics (Dubey, 1983, 1986). Studies carried out in the 1990s demonstrated how difficult it is to diagnose the infection in cattle, even with biological testing (Dubey, 1992; Dubey and Thulliez, 1993).

Poultry. Reported clinical cases are very rare (Dubey *et al.*, 2007; Goodwin *et al.*, 1994) with the most recent describing nervous system symptoms in free-range chickens in a family run farm (Dubey *et al.*, 2007). The autopsy on one animal showed necrosis, perivascular lymphocyte cuffs, and gliosis as well as tissue cysts and tachyzoites in the lesions (Dubey *et al.*, 2007). In free-range animals, seropositivity is higher (da Silva *et al.*, 2003; Dubey *et al.*, 2004b; Lehmann *et al.*, 2006).

Sheep and goats. The prevalence of *T. gondii* in adult sheep and lambs is high and the parasite is known to cause abortions and neonatal mortality in sheep (Samra *et al.*, 2007). Lambs that survive congenital infections grow regularly and are therefore can be a source of infection for humans. A study done at in the late 1990s revealed the parasite in various tissues of lambs slaughtered 7 months after surviving a neonatal infection (Dubey and Kirkbride, 1989). In goats, apart from abortions and neonatal mortality, clinical signs may be present and the parasite can be found in organs and tissue (mainly liver, kidneys, and brain) (Dubey and Beattie, 1988).

Horses. Even though infection is possible in horses (Tassi, 2007), the complete absence of reported evident clinical disease must be mentioned.

Other animals

Sporadic cases of clinical toxoplasmosis have been reported in rabbits, squirrels, canaries, and finches. For squirrels a differential diagnosis from rabies is necessary due to the similarity of symptoms: anorexia, lethargy, taste deprivation,

breathing difficulty, and tendency to bite (Salant *et al.*, 2009). In canaries a case of blindness with complete destruction of the eye has been described (Dubey, 2002). The infection has epidemiological importance in deer, bears, and raccoons. Bears and raccoons are omnivores and infection can be explained by the presence of parasitites in the intermediate host or the diffusion of oocysts in the environment (Dubey and Jones, 2008). In deer high prevalence can be partly explained by their particular susceptibility especially when living in environments highly contaminated with oocysts (Vikøren *et al.*, 2004; Gauss *et al.*, 2006). Certain animals living in zoos, such as Central and South American monkeys (Platyrrhini, the so-called New World monkeys) (Garcia *et al.*, 2005) and kangaroos are very susceptible to the infection (Miller *et al.*, 1992). Acute toxoplasmosis has been described in lemurs, squirrel monkeys, and marmosets, and has been found to be almost always visceral, followed by cerebral lesions. Lamina propria necrotizing enteritis and lymphadenitis of the mesenteric lymph nodes suggests acquired peroral infection rather than congenital infection (Epiphanyo *et al.*, 2003). For some years now, a study is being conducted on the small remaining population of Hawaiian crows (*Corvus hawaiiensis*) following the death of four birds of toxoplasmosis: a census in 2000 showed there were fewer than 25 specimens remaining (Work *et al.*, 2000).

Population Biology

Recent research on the genetic diversity by highly discriminatory molecular techniques of *T. gondii* has shown that the parasite is more genetically diverse and not clonal as previously suspected (Lehmann *et al.*, 2006, Dubey and Su, 2009). Intercontinental differences among *T. gondii* strains have been detected by microsatellite analysis (Lehmann *et al.*, 2006) and, more recently, genotyping data from chickens, pigs, lambs, and deer have demonstrated a high-level genetic diversity (Dubey and Su, 2009). Early genotyping studies on *T. gondii* led to the description of a clonal population with three main lineages related to virulence in mouse (type I, II, and III) (Darde *et al.*, 1988; Tibayrenc *et al.*, 1991; Sibley and Boothroyd, 1992; Howe and Sibley, 1995).

Recent studies have revealed that South American strains are more genetically diverse and comprise distinct genotypes. These differences have been shaped by infrequent sexual recombination, population sweeps, and biogeography. The majority of human infections that have been studied in North America and Europe are caused by type II strains, which are also common in agricultural animals from these regions. In contrast, several diverse genotypes of *T. gondii* are associated with severe infections in humans in South America (Beck *et al.*, 2009).

Further epidemiological studies are indicated to determine the role of genetic diversity in *T. gondii* in transmission between species, pathogenicity, and immunological response (Beck *et al.*, 2009). Recently, several authors found diverse lineages in pigs and chickens and postulated recombination and efficient transmission by oocysts (Dubey and Su, 2009; Velmurugan *et al.*, 2009). Dubey *et al.* detected high prevalence and high diversity of *T. gondii* in lambs in the United States: these findings are of great importance for public health, as lamb meat can be an important source of *T. gondii* infection for humans (Dubey *et al.*, 2008b).

Epidemiology and Transmission Pathways

T. gondii can be transmitted by three routes: congenital infection, ingestion of infected tissue, and contaminated food or water.

Congenital infection

Trans-placental infection has been confirmed in <1% of animals and humans. There are no diagnostic tests available to distinguish between the possible routes of infection; hence, assessment of the role of potential sources of infection is complicated (Dubey, 2008).

Ingestion of infected tissues

Due to the varying organotropism of *T. gondii* in different host species, the number of tissue cysts produced in a certain organ, in particular in skeletal muscles, varies greatly among different animals (Dubey and Jones, 2008). Therefore, not all animals used for human consumption are of the same public health significance, even if infected with *T. gondii*. Seropositivity of meat-producing animals does not necessarily reflect the risk that those animals pose to consumers. The meat of cattle and buffaloes rarely contain tissue cysts, although in some areas >90% of these animals are seropositive for *T. gondii*, whereas seropositive pigs, sheep, and goats can be assumed to harbor large numbers of tissue cysts in their meat (Dubey and Jones, 2008). Tables 1–5 summarize data for detection of *T. gondii* cysts from animal tissues.

Pork meat. Only one case of an outbreak after consumption of under-cooked pork has been reported in the literature (Choi *et al.*, 1997). Due to the introduction of intensive farming, the infection has been practically eliminated in many countries. For this reason pork meat is no longer a major source of infection as in the past. However, the present trend to the so-called organic animal raising, or animal-friendly farming, needs to be kept in mind as it could lead to a recrudescence of infection in pigs (Kijlstra *et al.*, 2004). Recent trends in consumer habits, in fact, indicate a shift toward consumption of animal-friendly or organic pigs, which include increased exposure of the pig to the environment, and this will lead to an increased risk of *T. gondii* in products from such animals (Hill *et al.*, 2010).

Viable *T. gondii* organisms have been isolated from tissues of pigs collected from abattoirs or farms and the success of isolation varied, in part due to bioassay procedures (Dubey *et al.*, 2002; Dubey, 2009b). In a comprehensive study, the prevalence of *T. gondii* was determined in 2,094 meat samples each of pork, beef, and chicken, obtained from 698 retail meat stores from 28 geographic areas of the United States. Overall, the prevalence of viable *T. gondii* in retail pork was very low (0.3%) (Dubey *et al.*, 2005).

Lamb, mutton, and goat meat. Sheep and goats are the main source of meat in Southern European countries (Anonymous, 2007). This is of particular importance because tissue cysts have been found in many edible parts of sheep (Dubey and Kirkbride, 1989), and small ruminants are important in both milk and meat production throughout the world. Consumption of undercooked lamb meat is an important risk factor, as demonstrated by many case-control studies (Anonymous, 2005). Seropositive sheep can be assumed to harbor large numbers of tissue cysts in their meat (Dubey and Jones, 2008). Animal such as sheep and lambs are usually kept in pasture, and therefore they have an increased risk of infection due to contamination of the environment with sporulated oocysts. Sheep and lambs are particularly vulnerable and if the environment is heavily contaminated with oocysts, seroprevalence can exceed 90% (Tenter *et al.*, 2000; Samra *et al.*, 2007). Considering that goats are an important source of food in developing countries, the consumption of goat meat, milk, and cheese products can play a important role in transmission of the disease (Samra *et al.*, 2007).

Beef. Some case-control studies have demonstrated that consumption of under-cooked beef is a risk factor for *T. gondii* in humans (Baril *et al.*, 1999; Cook *et al.*, 2000). Although seroprevalence in cattle is very high (antibodies are detected in up to 92% of cattle and up to 20% of buffaloes) tissue cysts are found only rarely in beef or buffalo meat (Tenter *et al.*, 2000).

Poultry meat. The parasite has been detected in meat from up to 80% seropositive chickens (da Silva *et al.*, 2003; Lehmann *et al.*, 2006) and *T. gondii* is expected to be detected more commonly in free range chickens as opposed to intensively housed chickens (Dubey, 2009a; Dubey *et al.*, 2005). Parasite studies in muscle samples (breast) constantly give

TABLE 1. DETECTION OF *TOXOPLASMA GONDII* FROM PIG TISSUES

Country	Tissue	n tested	% positive	Reference
Argentina	Diaphragm	109	12.8	Omata <i>et al.</i> , 1994
Austria	Brain, heart, diaphragm	235	0.4	Edelhofer, 1994
Brazil	Heart, brain, tongue	28	25	de A. dos Santos <i>et al.</i> , 2005
Brazil	Brain	12	50	Frazaio-Teixeira <i>et al.</i> , 2006
Brazil	Retail sausages	149	8.7	Dias <i>et al.</i> , 2005
Czech Republic	Brain, diaphragm	2447	1.1	Hejlíček and Literák, 1993
Portugal	Heart, brain	37	40.5	de Sousa <i>et al.</i> , 2006
United States (Iowa)	Sow hearts	1000	17	Dubey <i>et al.</i> , 1995
United States (Maryland)	Diaphragms	50	24	Jacobs <i>et al.</i> , 1960
United States (Maryland)	Hearts	38	36.8	Dubey <i>et al.</i> , 2008b
United States (Massachusetts)	Hearts and tongues ^a	55	92.7	Dubey <i>et al.</i> , 2002
United States (nationwide)	Retail meat	2094	0.3	Dubey <i>et al.</i> , 2005b

^aSlaughterhouse from 1 farm.

TABLE 2. DETECTION OF *TOXOPLASMA GONDII* FROM SHEEP TISSUES

Country	Tissue	n tested	% positive	Reference
United States (Maryland)	Mixed tissues	86	9.2	Jacobs <i>et al.</i> , 1960
United States (Maryland)	Lamb hearts	68	77.9	Dubey <i>et al.</i> , 2008c
United States (nationwide)	Lamb chops (retail meat)	50	4.0	Remington, 1968

negative results even in the presence of seropositivity, in animals originating from intensive farming (Dubey *et al.*, 2007).

Horse meat. In a recent study in Italy the parasite was detected in 90% of meat samples (Tassi, 2007). In some countries horse meat is eaten raw and could play an important role in the epidemiology of *T. gondii* (Tassi, 2007).

Game meats. EFSA data estimate that >50% of the game meat eaten in Europe contains *T. gondii* cysts (Anonymous, 2007, 2009a). Meat from black bear and deer hunted in the United States had a percentage of positivity ranging from 9.8% to 70% (Dubey *et al.*, 2004a, 2008c; Lindsay *et al.*, 1991).

Milk. Tachyzoites of *T. gondii* have been detected in the milk of several intermediate hosts, including sheep, goats, and cows (Tenter, 2009). Acute toxoplasmosis in humans has only been associated with consumption of unpasteurized goat's milk (Riemann *et al.*, 1975; Sacks *et al.*, 1982; Skinner *et al.*, 1990; Meerburg *et al.*, 2006). A recent report on how sheep can eliminate *T. gondii* in their milk is of interest (Fusco *et al.*, 2007). In the past, it has often been thought that the risk of acquiring an infection with *T. gondii* by drinking cow's milk, if any, is minimal, but it cannot be excluded that any type of milk is a potential source of infection if consumed raw (Tenter *et al.*, 2000).

Eggs. There are discrepant findings in literature regarding the presence of *T. gondii* in eggs of poultry (Dubey, 2009a). An early study reported that *T. gondii* tachyzoites may be isolated from raw chicken eggs laid by hens with experimentally induced infection (Jacobs and Melton, 1966), whereas other studies demonstrated very low level or absence of viable organisms in eggs laid by hens experimentally infected (Boch *et al.*, 1966; Biancifiore *et al.*, 1986). Raw hen eggs are therefore unlikely to be a source of infection for humans (Dubey, 2009a).

Water and contaminated food and soil

Several studies have confirmed a link between toxoplasmosis outbreaks and water contamination with oocysts (Kapperud *et al.*, 1996; Bowie *et al.*, 1997; Baril *et al.*, 1999; Cook *et al.*, 2000; Dubey, 2004; Montoya and Liesenfeld, 2004; Kijlstra and Jongert, 2009). The first report dates from 1982, when authors described a waterborne outbreak in U.S. military

training in Panama (Benenson *et al.*, 1982). Outside Europe and the United States, water is an important risk factor for infection (Petersen *et al.*, 2009): in 1995 a municipal water system that used unfiltered, chloraminated surface water was the likely source of the largest and best documented community-wide outbreak of toxoplasmosis (Bowie *et al.*, 1997). Sources other than meat and water have been identified: contact with soil (Cook *et al.*, 2000), eating unwashed raw vegetables or fruit (Kapperud *et al.*, 1996), and geophagia in preschool-aged children (Stagno *et al.*, 1980). Infrequent washing of knives after preparation of raw meat was associated with an increased risk of primary infection during pregnancy (Kapperud *et al.*, 1996).

Risk factors for infection in humans and prevention strategies

The most important risk factor for *T. gondii* infection was found to be under-cooked meat (lamb, beef, and game). However, even true vegans can contract *T. gondii* infections, confirming the role of oocyst ingestion as a source of infection (Kapperud *et al.*, 1996; Baril *et al.*, 1999; Cook *et al.*, 2000). A multivariate analysis linked the risk of *T. gondii* infection with eating raw ground beef and rare lamb, eating locally produced cured, dried, or smoked meat, working with meat, drinking unpasteurized goat's milk, and having three or more kittens (Jones *et al.*, 2009a). In one European multicenter study, between 30% and 63% of infections were attributed to consumption of undercooked or cured meat products and 6%–17% to soil contact (Cook *et al.*, 2000).

Available guidelines (Lopez *et al.*, 2000; Leroy *et al.*, 2005) emphasize food hygiene, especially thorough cooking of meat and meat products, and reduced contact with soil and cat feces. Given that freezing meat for at least 2 days at temperature below -12°C can kill tissue cysts (Kotula *et al.*, 1991), people at risk should be encouraged to buy frozen meat. Tissue cysts are also killed by heat treatment: internal temperature of 56°C for 10 minutes is sufficient to guarantee a *Toxoplasma*-free meat (Dubey *et al.*, 1990). Tachyzoites are killed by pasteurization and heating; therefore, it is advisable that milk, in particular goat's milk, should be pasteurized or boiled before human consumption (Tenter *et al.*, 2000). Any type of cooking would kill tachyzoites in eggs (Tenter *et al.*, 2000).

Several epidemiological studies have identified the risk of *T. gondii* infection at farm level and preharvest prevention has

TABLE 3. DETECTION OF *TOXOPLASMA GONDII* FROM CATTLE TISSUES

Country	Tissue	n tested	% positive	Reference
United States (Maryland)	Diaphragms	60	0	Jacobs <i>et al.</i> , 1960
United States (nationwide)	Beef (retail meat)	2094	0	Dubey <i>et al.</i> , 2005b
United States (Ohio)	Mixed tissues	350	0	Dubey and Streitl, 1976

TABLE 4. DETECTION OF *TOXOPLASMA GONDII* FROM CHICKEN TISSUES

Country	Rearing	Tissue	n tested	% positive	Reference
Brazil	Confined	Heart	50	0	Brandao <i>et al.</i> , 2006
Croatia	Confined	Brain	716	0.4	Kuticic and Wikerhauser, 2000
Egypt	Confined	Muscle	235	0	El-Massry <i>et al.</i> , 2009
Italy	Confined	Brain, heart	176	4	Zardi, 1967
United States (nationwide)	Confined	Breast (retail meat)	2094	0	Dubey <i>et al.</i> , 2005b
Austria	Free range	Heart, brain	209	26.7	Dubey <i>et al.</i> , 2005a
Brazil	Free range	Heart	28	39.3	Brandao <i>et al.</i> , 2006
Czech Republic	Free range	Heart, brain, muscle	10	20	Literak and Hejlicek, 1993
Czech Republic	Free range	Brain, muscle, heart	1097	0.36	Literak and Hejlicek, 1993
Israel	Free range	Heart, brain	45	42.2	Dubey <i>et al.</i> , 2004b
Italy	Free range	Brain	176	3.9	Zardi, 1967
Portugal	Free range	Heart, brain, muscle	61	26.2	Dubey, 2009b
United States (Massachusetts)	Free range	Heart, brain, muscle	11	100	Dubey, 2009a
United States (Ohio)	Free range	Heart, brain	20	55	Dubey, 2009a
United States (Tennessee)	Free range	Brain	60	0	Eyles <i>et al.</i> , 1959

been postulated (Kijlstra and Jongert, 2008, 2009). This includes strict rodent control (especially in the pig farming, where consumption of rodent remnants could be a direct source of infection for pigs) and certification that the farm and surroundings are free of oocyst-shedding cats (Kijlstra and Jongert, 2009). The use of sterilized feed and bedding along with control measures to prevent the access of pests has led to a *Toxoplasma*-free production system in certain pig and broiler farms (Dubey and Jones, 2008).

Practicing small animals veterinarians are frequently asked to diagnose toxoplasmosis in cats because of the potential public health risk and clinical illness. The clinical diagnosis of Toxoplasmosis is dependent on a thorough understanding of the life cycle of the parasite and its relationship to mammalian hosts. Pregnant women, AIDS victims, and other immunosuppressed patients commonly ask their veterinarian about when a cat has previously shed oocysts and when will shed oocysts again in future. While fecal examination is an adequate procedure for detecting current oocysts shedding, it fails to predict whether a cat has shed oocysts in the past or will shed in the future (Schaes *et al.*, 2008). On the other hand, there is no serological assay that can accurately predict when oocysts were shed in the past (Dabritz *et al.*, 2007). For these reasons veterinarians should be prepared, in terms of both scientific knowledge and communication skills, to educate cats owners and to encourage responsible cats ownership. Key points, yet not easily accepted by all cats lovers, are spaying and neutering cats to control the size of owned cat population, keeping cats indoor, and collecting feces in litter boxes for disposal. Cat feces should not be disposed in toilets because oocysts survive treatments for raw sewage (Wainwright *et al.*, 2007a, 2007b).

From a public health perspective, the best approach would be to vaccinate cats. From the beginning of the 1990s some experiments based on administration of attenuated live bradyzoites to cats have been completed with success (Frenkel *et al.*, 1991; Mateus-Pinilla *et al.*, 1999). At the moment research in this sector is languishing due to lack of interest on the part of health authorities and therefore a lack of financing. Difficulty in producing the vaccine (a patent exists, U.S. Patent 5045313, filed on July 7, 1989), based on the multiplication of bradyzoites in mice followed by purification, and a limited economic incentive for the pharmaceutical industry could be overcome by the use of cell cultures or recombinant vaccines (McAllister, 2005).

Laboratory Diagnostics

Serological testing

Fluids that can be sampled include those present in the thoracic cavity of aborted fetuses, milk, and extracts of infected tissue or liquid drained from muscles that have been frozen and then thawed. The plethora of commercially available methods used in various laboratories makes it difficult to compare results, which is actually the most important aspect today to control the spread of the disease (Fricker-Hidalgo *et al.*, 2009).

Modified agglutination test, Immunofluorescence antibody test, enzyme-linked immunosorbent assay, and Sabin-Feldman dye test

Modified agglutination test (MAT) is the most commonly used test today for pets and wild animals due to its ease of use and safety (Shaapan *et al.*, 2008). Agglutination uses

TABLE 5. DETECTION OF *TOXOPLASMA GONDII* FROM WILD ANIMAL TISSUES

Country	Species	Tissue	n tested	% positive	Reference
United States (Pennsylvania)	Black bear	Hearts (hunted)	28	35.7	Dubey <i>et al.</i> , 2004a
United States (Pennsylvania)	Black bear	Hearts (hunted)	10	70	Dubey <i>et al.</i> , 2004a
United States (Alabama)	Deer	Hearts (hunted or died)	19	21	Lindsay <i>et al.</i> , 1991
United States (Iowa)	Deer	Fetuses	61	9.8	Dubey <i>et al.</i> , 2008d
United States (Minnesota)	Deer	Fetuses	27	33.3	Dubey <i>et al.</i> , 2008d
United States (Mississippi)	Deer	Hearts (hunted or died)	73	28.7	Dubey <i>et al.</i> , 2004a

tachyzoites inactivated with formalin and does not require species-specific reagents (Shaapan *et al.*, 2008; Macri *et al.*, 2009). A study revealed that MAT has the highest sensitivity, followed by enzyme-linked immunosorbent assay (ELISA), whereas among serological tests, immunofluorescence antibody test (IFAT) showed the lowest sensitivity. On the other hand, IFAT had the highest specificity, followed by MAT and ELISA (Shaapan *et al.*, 2008).

IFAT is the simplest test and can be easily performed even by inexpert lab technicians. IFAT also uses tachyzoite antigens treated with formalin, but species-specific conjugates are necessary (Shaapan *et al.*, 2008). The variability of the sensitivity and specificity according to the *T. gondii* strain employed, and subjectivity in interpreting the fluorescence reaction make it almost impossible to compare results from different laboratories. This is the reason for the numerous data in the literature that show extreme variability even in the same regions and in the same type of farm (Shaapan *et al.*, 2008; Macri *et al.*, 2009). A recent study has revealed that there is an extremely low proportion of accordance between IFAT and MAT in cat and dog sera (Macri *et al.*, 2009).

Many kits, based on ELISA, are commercially available to find serum antibodies in different animal species. The methodology can be automated and this makes it attractive for use in large-scale epidemiological studies. For the most recent tests introduced on the market, manufacturers declare sensitivity and specificity greater than IFAT and other serological tests (Hosseininejad *et al.*, 2009). ELISA tests to demonstrate IgG to diagnose active infections are available in the market although there is not full agreement among researchers on their sensitivity and specificity (Shaapan *et al.*, 2008; Hosseininejad *et al.*, 2009). Recently, an indirect ELISA test with purified tachyzoite surface antigen SAG1 has been proposed (Hosseininejad *et al.*, 2009). SAG1 antigen is stage-specific and only detectable in the tachyzoite stage (Pietkiewicz *et al.*, 2007).

Sabin-Feldman dye test is based on the inability of tachyzoites to absorb the dye when, tested with anti-Toxoplasma anti-serum, the immunocomplex has been formed. The test is highly sensitive and specific, has been used on humans, and can be adapted to different animal species, except for bovines where a globulin can give false-positives. The method requires live tachyzoites, is expensive, and is restricted to use in specialized laboratories and expert lab technicians (Ozkan *et al.*, 2008).

IgG versus IgM

Serological tests, for example, ELISA, can diagnose active infection (positive IgM and negative IgG tests) (Hosseininejad *et al.*, 2009). The Sabin-Feldman dye test, in cases of seroconversion (or increase in titer fourfold in 2–3 weeks), allows diagnosis of active infections (Bowman *et al.*, 2002). MAT is an ideal test in veterinary healthcare settings to detect IgG because it does not require species-specific conjugates used in serologic assays based on the immunofluorescent antibody and ELISA methods. On the other hand, performance of the MAT for detection of IgM antibodies against *T. gondii* in naturally infected animals is less clear and there have been few systematic evaluations of the assay for this purpose. IgM antibodies can be detected 1 to 2 weeks before the development of a measurable IgG antibody titer (Svobodova *et al.*, 1998). The primary problem with testing for anti-Toxoplasma IgM is lack of specificity (Lappin, 2010). In general, for ani-

mals with a positive IgM result and negative IgG on repeated follow-up examinations, *T. gondii* can be ruled out as potential etiology, whereas the detection of *T. gondii*-specific IgG antibodies on the follow-up examination conducted within 3 weeks of the initial IgM titer retrospectively confirms that the animal is infected with *T. gondii* parasites (Lappin, 2010).

Other tests

Tachyzoites and tissue cysts can be found in tissue sections and organs fixed and stained with hematoxylin and eosin and immunohistochemistry. Since tissue cysts or tachyzoites are not evenly distributed in the tissues and the body (van Maanen *et al.*, 2004), there is a low correlation between immunohistochemistry and serological tests (Moré *et al.*, 2008).

Another diagnostic tool is the cultivation of *T. gondii* in cell culture. However, the need for adequate laboratories and technical experience makes it a little-used routine diagnostic tool. The sensitivity of this test is also one of the lowest especially for samples abused during storage and transportation (James *et al.*, 1996).

Polymerase chain reaction is used for the detection of the DNA of the parasite in blood, fluid, and tissues: the specificity of this test is almost 100%, but the difficulty to extract DNA and concentrate large sample quantities results in limited sensitivity (Alfonso *et al.*, 2009). It should be considered also that cyst distribution is random and that parasite density in the cysts could be very low (Piergili Fioretti, 2004; Alfonso *et al.*, 2009).

The present trend, for obvious ethical reasons and for animal wellness, is to limit or avoid the use of biological testing for diagnosis. However, the possibility of inoculating or feeding Toxoplasma-free laboratory animals (mice and cats) to later demonstrate *T. gondii* in organs and tissues should be held in consideration, especially for the high sensitivity and specificity that, unfortunately, make this biological testing the gold standard (James *et al.*, 1996). Other tests include immunochromatographic assay, carbon immunoassay, direct agglutination test (which is also sold in kits and is used in wild animals as it does not require species-specific conjugate), latex agglutination test, and indirect hemagglutination test. Immunoblotting, even though it cannot be considered a routine test, is extremely important to study serum reactivity to many *T. gondii* antigens (Anonymous, 2007).

Acknowledgments

The authors thank all those colleagues who have helped in our ongoing research projects, in particular Prof. Barend Louis Penzhorn and Dr. Nada Abu Samra of the University of Pretoria, School of Veterinary Medicine, Onderstepoort, and Dr. Carlo Crotti and Dr. Ludovico Renda veterinary practitioners in Perugia, Italy. The authors also thank Dr. Marcello Tosti for providing the photograph and express sincere appreciation to members of Polyglot, Perugia, for a careful reading and comments on the article. The findings and conclusions in this review are those of the authors and do not necessarily represent the views of the University of Perugia, the University of California, or the University of Pretoria.

Disclosure Statement

No competing financial interests exist.

References

- Alfonso Y, Fraga J, JimÉnez N, Fonseca C, Dorta-Contreras AJ, Cox R, CapÚ V, Bandera F, Pomier O, and Ginorio D. Detection of *Toxoplasma gondii* in cerebrospinal fluid from AIDS patients by nested PCR and rapid identification of type I allele at B1 gene by RFLP analysis. *Exp Parasitol* 2009;122:203–207.
- Anonymous. Directive 2003/99/EC of the European Parliament and of the Council of 17 November 2003 on the monitoring of zoonoses and zoonotic agents, amending Council Decision 90/424/EEC and repealing Council Directive 92/117/EEC. *Official Journal of the European Union L* 325, 31–40.
- Anonymous. Toxoplasmose: état des connaissances et évaluation du risque lié à l'alimentation. In: *AFSSA—Report of the Afssa working group "Toxoplasma gondii."* 2005. Available at www.afssa.fr/Documents/MIC-Ra-Toxoplasmose.pdf, accessed January, 2011. (Online.)
- Anonymous. Scientific Opinion of the Panel on Biological Hazards (BIOHAZ) on surveillance and monitoring of *Toxoplasma* in humans, food and animals. *EFSA J* 2007;583:1–64.
- Anonymous. Community summary report on trends and sources of zoonoses, zoonotic agents, antimicrobial resistance and foodborne outbreaks in the European Union in 2006. *EFSA J* 2009a;130:2–352.
- Anonymous. NCBI—*Toxoplasma gondii*. 2009b. Available at www.ncbi.nlm.nih.gov/Taxonomy/Browser/wwwtax.cgi?mode=Info&id=5811&lvl=3&lin=f&keep=1&srchmode=1&unlock, accessed January, 2011. (Online.)
- Anonymous. Toxoplasmosis—CDC. 2009c. Available at www.cdc.gov/toxoplasmosis/prevent.html, accessed December, 2009. (Online.)
- Anyarat T, Wandee K, Umair B, Teeraphun B, and Somsak A. Toxoplasmosis in Piglets. *Ann NY Acad Sci* 2006;1081:336–338.
- Baldelli B. Ruolo degli animali e degli alimenti di origine animale nella trasmissione della toxoplasmosi all'uomo. In: *Proceedings Convegno Sugli Aspetti Diagnostici, Terapeutici e Profilattici Della Toxoplasmosi*. Firenze, May 14, 1983, pp. 83–116.
- Baril L, Ancelle T, Goulet V, Thulliez P, Tirard-Fleury V, and Carme B. Risk factors for *Toxoplasma* infection in pregnancy: a case-control study in France. *Scand J Infect Dis* 1999;31:305–309.
- Beck H-P, Blake D, DardÉ M-L, Felger I, Pedraza-Díaz S, Regidor-Cerrillo J, GÚmez-Bautista M, Ortega-Mora LM, Putignani L, Shiels B, Tait A, and Weir W. Molecular approaches to diversity of populations of apicomplexan parasites. *Int J Parasitol* 2009;39:175–189.
- Benenson MW, Takafuji ET, Lemon SM, Greenup RL, and Sulzer AJ. Oocyst-transmitted toxoplasmosis associated with ingestion of contaminated water. *N Engl J Med* 1982;307:666–669.
- Biancifiore F, Rondini C, Grelloni V, and Frescura T. Avian toxoplasmosis: experimental infection of chicken and pigeon. *Comp Immunol Microbiol Infect Dis* 1986;9:337–346.
- Boch J, Rommel M, Weiland G, Janitschke K, and Sommer R. Experimental toxoplasma infection of laying hens. *Berl Munch Tierarztl Wochenschr* 1966;79:352–356.
- Bossi P and Bricaire F. Severe acute disseminated toxoplasmosis. *Lancet* 2004;364:579–579.
- Bowie WR, King AS, Werker DH, Isaac-Renton JL, Bell A, Eng SB, Marion SA, and for the B.C.T.I.T. Outbreak of toxoplasmosis associated with municipal drinking water. *Lancet* 1997;350:173–177.
- Bowman DD, Hendrix CM, Lindsay DS, and Barr SC. *Feline Clinical Parasitology*. Iowa State University Press: Blackwell Publishing, 2002.
- Brandao GP, Ferreira AM, Melo MN, and Vitor RW. Characterization of *Toxoplasma gondii* from domestic animals from Minas Gerais, Brazil. *Parasite* 2006;13:143–149.
- Cenci Goga B. Toxoplasma negli animali, negli alimenti e nell'uomo. Una sfida per il medico veterinario. *Prax Vet* 2009;XXX:7–15.
- Choi WY, Nam HW, Kwak NH, Huh W, Kim YR, Kang MW, Cho SY, and Dubey JP. Foodborne outbreaks of human toxoplasmosis. *J Infect Dis* 1997;175:1280–1282.
- Cook AJC, Gilbert RE, Buffolano W, Zufferey J, Petersen E, Jennum PA, Foulon W, Semprini AE, and Dunn DT. Sources of *Toxoplasma* infection in pregnant women: European multicentre case-control study. *Br Med J* 2000;321:142–147.
- Dabritz HF, Miller MA, Atwill ER, Gardner IA, Leutenegger CM, Melli AC, and Conrad PA. Detection of *Toxoplasma gondii*-like oocysts in cat feces and estimates of the environmental oocyst burden. *J Am Vet Med Assoc* 2007;231:1676–1684.
- Darde ML, Bouteille B, and Pestre-Alexandre M. Isoenzymic characterization of seven strains of *Toxoplasma gondii* by isoelectrofocusing in polyacrylamide gels. *Am J Trop Med Hyg* 1988;39:551–558.
- da Silva DS, Bahia-Oliveira LMG, Shen SK, Kwok OCH, Lehman T, and Dubey JP. Prevalence of *Toxoplasma gondii* in chickens from an area in southern Brazil highly endemic to humans. *J Parasitol* 2003;89:394–396.
- da Silva R and Langoni H. *Toxoplasma gondii*: host-parasite interaction and behavior manipulation. *Parasitol Res* 2009;105:893–898.
- Davidson MG, Rottman JB, English RV, Lappin MR, and Tompkins MB. Feline immunodeficiency virus predisposes cats to acute generalized toxoplasmosis. *Am J Pathol* 1993;143:1486–1497.
- de A. dos Santos CB, de Carvalho ACFB, Ragozo AMA, et al. First isolation and molecular characterization of *Toxoplasma gondii* from finishing pigs from Sao Paulo State, Brazil. *Vet Parasitol* 2005;131:207–211.
- De Salvador-Guillouët F, Ajzenberg D, Chaillou-Opitz S, Saint-Paul M-C, Dunais B, Dellamonica P, and Marty P. Severe pneumonia during primary infection with an atypical strain of *Toxoplasma gondii* in an immunocompetent young man. *J Infect* 2006;53:e47–e50.
- Dias RAF, Navarro IT, Ruffolo BB, Bugni FM, Castro MVd, and Freire RL. *Toxoplasma gondii* in fresh pork sausage and seroprevalence in butchers from factories in Londrina, Paran State, Brazil. *Rev Inst Med Trop Sao Paulo* 2005;47:185–189.
- Dion S, Barbe PG, Leman S, Camus V, and Dimier-Poisson I. Schizophrenia and toxoplasmosis. *Med Sci (Paris)* 2009;25:687–692.
- Dubey JP. A review of toxoplasmosis in cattle. *Vet Parasitol* 1986;22:177–202.
- Dubey JP. A review of toxoplasmosis in wild birds. *Vet Parasitol* 2002;106:121–153.
- Dubey JP. Distribution of cysts and tachyzoites in calves and pregnant cows inoculated with *Toxoplasma gondii* oocysts. *Vet Parasitol* 1983;13:199–211.
- Dubey JP. Isolation of *Toxoplasma gondii* from a naturally infected beef cow. *J Parasitol* 1992;78:151–153.
- Dubey JP. The history of *Toxoplasma gondii*—The First 100 Years. *J Eukaryot Microbiol* 2008;55:467–475.
- Dubey JP. *Toxoplasma gondii* infections in chickens (*Gallus domesticus*): prevalence, clinical disease, diagnosis and public health significance. *Zoonoses Public Health* 2009a;57:60–73.
- Dubey JP. Toxoplasmosis in pigs—The last 20 years. *Vet Parasitol* 2009b;164:89–103.

- Dubey JP. Toxoplasmosis—A waterborne zoonosis. *Vet Parasitol* 2004;126:57–72.
- Dubey JP and Beattie CP. *Toxoplasmosis of Animals and Man*. Boca Raton, FL: 1988.
- Dubey JP and Jones JL. *Toxoplasma gondii* infection in humans and animals in the United States. *Int J Parasitol* 2008;38:1257–1278.
- Dubey JP and Kirkbride CA. Enzootic toxoplasmosis in sheep in North-Central United-States. *J Parasitol* 1989;75:673–676.
- Dubey JP and Streitl RH. Shedding of Sarcocystis in feces of dogs and cats fed muscles of naturally infected food animals in the midwestern United States. *J Parasitol* 1976;62:828–830.
- Dubey JP and Su C. Population biology of *Toxoplasma gondii*: what's out and where did they come from. *Mem Inst Oswaldo Cruz* 2009;104:190–195.
- Dubey JP and Thulliez P. Persistence of tissue cysts in edible tissues of cattle fed *Toxoplasma gondii* oocysts. *Am J Vet Res* 1993;54:270–273.
- Dubey JP, Bhatia C, Lappin M, Ferreira LR, Thorn A, and Kwok O. Seroprevalence of *Toxoplasma gondii* and *Bartonella* spp. antibodies in cats from Pennsylvania. *J Parasitol* 2008a;95:578–580.
- Dubey JP, Carpenter JL, Speer CA, Topper MJ, and Uggla A. Newly recognized fatal protozoan disease of dogs. *J Am Vet Med Assoc* 1988;192:1269–1285.
- Dubey JP, David SL, and Michael RL. Toxoplasmosis and other intestinal coccidial infections in cats and dogs. *The veterinary clinics of North America. Small Anim Pract* 2009;39:1009–1034.
- Dubey JP, Edelhofer R, Marcet P, Vianna MCB, Kwok OCH, and Lehmann T. Genetic and biologic characteristics of *Toxoplasma gondii* infections in free-range chickens from Austria. *Vet Parasitol* 2005a;133:299–306.
- Dubey JP, Gamble HR, Hill D, Sreekumar C, Romand S, and Thulliez P. High prevalence of viable *Toxoplasma gondii* infection in market weight pigs from a farm in Massachusetts. *J Parasitol* 2002;88:1234–1238.
- Dubey JP, Graham DH, De Young RW, Dahl E, Eberhard ML, Nace EK, Won K, Bishop H, Punkosdy G, Sreekumar C, Vianna MCB, Shen SK, Kwok OCH, Sumners JA, Demarais S, Humphreys JG, and Lehmann T. Molecular and biologic characteristics of *Toxoplasma gondii* isolates from wildlife in the United States. *J Parasitol* 2004a;90:67–71.
- Dubey JP, Hill DE, Jones JL, Hightower AW, Kirkland E, Roberts JM, Marcet PL, Lehmann T, Vianna MCB, Miska K, Sreekumar C, Kwok OCH, Shen SK, and Gamble HR. Prevalence of viable *Toxoplasma gondii* in beef, chicken, and pork from retail meat stores in the United States: risk assessment to consumers. *J Parasitol* 2005;91:1082–1093.
- Dubey JP, Kotula AW, Sharar A, Andrews CD, and Lindsay DS. Effect of high-temperature on infectivity of *Toxoplasma gondii* tissue cysts in pork. *J Parasitol* 1990;76:201–204.
- Dubey JP, Salant H, Sreekumar C, Dahl E, Vianna MCB, Shen SK, Kwok OCH, Spira D, Hamburger J, and Lehmann TV. High prevalence of *Toxoplasma gondii* in a commercial flock of chickens in Israel, and public health implications of free-range farming. *Vet Parasitol* 2004b;121:317–322.
- Dubey JP, Sundar N, Hill D, Velmurugan GV, Bandini LA, Kwok OCH, Majumdar D, and Su C. High prevalence and abundant atypical genotypes of *Toxoplasma gondii* isolated from lambs destined for human consumption in the USA. *Int J Parasitol* 2008b;38:999–1006.
- Dubey JP, Thulliez P, and Powell EC. 1995. *Toxoplasma gondii* in Iowa sows: Comparison of antibody titers to isolation of *T. gondii* by bioassays in mice and cats. *J Parasitol* 81:48.
- Dubey JP, Velmurugan GV, Ulrich V, et al. 2008d. Transplacental toxoplasmosis in naturally-infected white-tailed deer: Isolation and genetic characterisation of *Toxoplasma gondii* from foetuses of different gestational ages. *Int J Parasitol* 38:1057–1063.
- Dubey JP, Velmurugan GV, Ulrich V, Gill J, Carstensen M, Sundar N, Kwok OCH, Thulliez P, Majumdar D, and Su C. Transplacental toxoplasmosis in naturally-infected white-tailed deer: isolation and genetic characterisation of *Toxoplasma gondii* from foetuses of different gestational ages. *Int J Parasitol* 2008c;38:1057–1063.
- Dubey JP, Webb DM, Sundar N, Velmurugan GV, Bandini LA, Kwok OCH, and Su C. Endemic avian toxoplasmosis on a farm in Illinois: clinical disease, diagnosis, biologic and genetic characteristics of *Toxoplasma gondii* isolates from chickens (*Gallus domesticus*), and a goose (*Anser anser*). 2007;148:207–212.
- Dubey JP, Weisbrode SE, Sharma SP, Al-Khalidi NW, Zimmerman JL, and Gaafar SM. Porcine toxoplasmosis in Indiana. *J Am Vet Med Assoc* 1979;174:604–609.
- Edelhofer R. Prevalence of antibodies against *Toxoplasma gondii* in pigs in Austria - An evaluation of data from 1982 and 1992. *Parasitol Res* 1994;80:642–644.
- El-Massry A, Mahdy OA, El-Ghaysh A, and Dubey JP. Prevalence of *Toxoplasma gondii* antibodies in sera of turkeys, chickens, and ducks from Egypt. *J Parasitol* 2009;86:627–628.
- Epiphanyo S, Sinhoringi IL, and Catão-Dias JL. Pathology of toxoplasmosis in captive new world primates. *J Comp Pathol* 2003;129:196–204.
- Eyles DE, Gibson CL, Coleman N, Smith CS, Jumper JR, and Jones FE. The prevalence of toxoplasmosis in wild and domesticated animals of the Memphis region. *Am J Trop Med Hyg* 1959;8:505–510.
- Falzone C, Baroni M, De Lorenzi D, and Mandara M. *Toxoplasma gondii* brain granuloma in a cat: diagnosis using cytology from an intraoperative sample and sequential magnetic resonance imaging. *J Small Anim Pract* 2008;49:95–99.
- Farrell RL, Docton FL, Chamberlain DM, and Cole CR. Toxoplasmosis. I. *Toxoplasma* isolated from swine. *Am J Vet Res* 1952;13:181–184.
- Frazaio-Teixeira E, Oliveira FC, Pelissari-Sant'ana V, and Lopes CW. *Toxoplasma gondii* in brains of pigs commercialized at the Municipality of Campos dos Goytacazes in the State of Rio de Janeiro, Brazil. *Rev Bras Parasitol Vet* 2006;15:33–36.
- Frenkel JK, Pfefferkorn ER, Smith DD, and Fishback JL. Prospective vaccine prepared from a new mutant of *Toxoplasma gondii* for use in cats. *Am J Vet Res* 1991;52:759–763.
- Fricker-Hidalgo H, Bulabois C-E, Brenier-Pinchart M-P, Hamidfar R, Garban F, Brion JP, Timsit JF, Cahn J-Y, and Pelloux H. Diagnosis of Toxoplasmosis after allogeneic stem cell transplantation: results of dna detection and serological techniques. *Clin Infect Dis* 2009;48:e9–e15.
- Fusco G, Rinaldi L, Guarino A, Proroga YTR, Pesce A, Giuseppina DM, and Cringoli G. *Toxoplasma gondii* in sheep from the Campania region (Italy). *Vet Parasitol* 2007;149:271–274.
- Garcia JL, Svoboda WK, Chryssafidis AL, de Souza Malanski L, Shiozawa MM, de Moraes Aguiar L, Teixeira GM, Ludwig G, da Silva LR, Hilst C, and Navarro IT. Sero-epidemiological survey for toxoplasmosis in wild New World monkeys (*Cebus* spp.; *Alouatta caraya*) at the Paraná river basin, Paraná State, Brazil. *Vet Parasitol* 2005;133:307–311.
- Gaskell EA, Smith JE, Pinney JW, Westhead DR, and McConkey GA. A unique dual activity amino acid hydroxylase in *Toxoplasma gondii*. *PLoS ONE* 2009;4:e4801.

- Gauss CBL, Dubey JP, Vidal D, Cabezon O, Ruiz-Fons F, Vicente J, Marco I, Lavin S, Gortazar C, and Almerca S. Prevalence of *Toxoplasma gondii* antibodies in red deer (*Cervus elaphus*) and other wild ruminants from Spain. *Vet Parasitol* 2006;136:193–200.
- Goodwin MA, Dubey JP, and Hatkin J. *Toxoplasma gondii* peripheral neuritis in chickens. *J Vet Diagn Invest* 1994;6:382–385.
- Greene CE. *Infectious Diseases of the Dog and Cat*. St. Louis, MO: Elsevier Health Sciences, 2006.
- Hall BR, Oliver GE, and Wilkinson M. A presentation of long-standing toxoplasmosis chorioretinitis. *Optometry* 2009;80:23–28.
- Hejlíček K and Literák I. Prevalence of toxoplasmosis in pigs in the region of South Bohemia. *Acta Vet Brno* 1993;62:159–166.
- Hill DE, Haley C, Wagner B, Gamble HR, and Dubey JP. Seroprevalence of and risk factors for *Toxoplasma gondii* in the US swine herd using sera collected during the national animal health monitoring survey (Swine 2006). *Zoonoses Public Health* 2010;57:53–59.
- Hosseininejad M, Azizi HR, Hosseini F, and Schares G. Development of an indirect ELISA test using a purified tachyzoite surface antigen SAG1 for sero-diagnosis of canine *Toxoplasma gondii* infection. *Vet Parasitol* 2009;164:315–319.
- Howe DK and Sibley LD. *Toxoplasma gondii* comprises three clonal lineages: correlation of parasite genotype with human disease. *J Infect Dis* 1995;172:1561–1566.
- Innes EA. A brief history and overview of *Toxoplasma gondii*. *Zoonoses Public Health* 2010;57:1–7.
- Jackson MH and Hutchison WM. The prevalence and source of toxoplasma infection in the environment. In: *Advances in Parasitology*. Baker JR and Muller R (eds.). San Diego, CA: Academic Press, 1989, pp. 55–105.
- Jacobs L, Remington JS, and Melton ML. A survey of meat samples from swine, cattle, and sheep for the presence of encysted *Toxoplasma*. *J Parasitol* 1960;46:23–28.
- Jacobs L and Melton ML. Toxoplasmosis in chickens. *J Parasitol* 1966;52:1158–1162.
- James GS, Sintchenko VG, Dickeson DJ, and Gilbert GL. Comparison of cell culture, mouse inoculation, and PCR for detection of *Toxoplasma gondii*: effects of storage conditions on sensitivity. *J Clin Microbiol* 1996;34:1572–1575.
- Jones JL, Dargelas V, Roberts J, Press C, Remington JS, and Montoya JG. Risk factors for *Toxoplasma gondii* infection in the United States. *Clin Infect Dis* 2009a;49:878–884.
- Jones JL, Krueger A, Schulkin J, and Schantz PM. Toxoplasmosis prevention and testing in pregnancy, survey of obstetrician and gynaecologists. *Zoonoses Public Health* 2009b;57:27–33.
- Kapperud G, Jennum PA, StrayPedersen B, Melby KK, Eskild A, and Eng J. Risk factors for *Toxoplasma gondii* infection in pregnancy—results of a prospective case-control study in Norway. *Am J Epidemiol* 1996;144:405–412.
- Kijlstra A, Eissen OA, and Cornelissen J. *Toxoplasma gondii* infection in animal-friendly pig production systems. *Invest Ophthalmol Vis Sci* 2004;45:3165–3169.
- Kijlstra A and Jongert E. Control of the risk of human toxoplasmosis transmitted by meat. *Int J Parasitol* 2008;38:1359–1370.
- Kijlstra A and Jongert E. Toxoplasma-safe meat: close to reality? *Trends Parasitol* 2009;25:18–22.
- Kotula AW, Dubey JP, Sharar AK, Andrews CD, Shen SK, and Lindsay DS. Effect of freezing on infectivity of *Toxoplasma gondii* tissue cysts in pork. *J Food Prot* 1991;54:687–690.
- Kuticic V and Wikerhauser T. A survey of chickens for viable toxoplasms in Croatia. *Acta Vet Hung* 2000;48:183–185.
- Lappin MR. Feline toxoplasmosis: interpretation of diagnostic test results. *Clin Tech Small Anim Pract* 1996;11:154–160.
- Lappin MR. Feline infectious uveitis. *J Feline Med Surg* 2000;2:159–163.
- Lappin MR. Update on the diagnosis and management of *Toxoplasma gondii* infection in cats. *Top Companion Anim Med* 2010;25:136–141.
- Leal FE, Cavazzana CL, de Andrade HF, Galisteo AJ, de Mendonça JS, and Kallas EG. *Toxoplasma gondii* pneumonia in immunocompetent subjects: case report and review. *Clin Infect Dis* 2007;44:e62–e66.
- Lehmann T, Marcet PL, Graham DH, Dahl ER, and Dubey JP. Globalization and the population structure of *Toxoplasma gondii*. *Proc Natl Acad Sci USA* 2006;114:23–11428.
- Leroy V, Raeber PA, Petersen E, Salmi LR, Kaminski M, Villena I, Buffolano W, and Gilbert R. National public Health policies and routine programs to prevent congenital toxoplasmosis in Europe, 2005. Available at <http://eurotox.isped.u-bordeaux2.fr/>, accessed January, 2011. (Online.)
- Levy JK, Liang Y, Ritchey JW, Davidson MG, Tompkins WA, and Tompkins MB. Failure of FIV-infected cats to control *Toxoplasma gondii* correlates with reduced IL2, IL6, and IL12 and elevated IL10 expression by lymph node T cells. *Vet Immunol Immunopathol* 2004;98:101–111.
- Lindsay DS, Blagburn BL, Dubey JP, and Mason WH. Prevalence and isolation of *Toxoplasma gondii* from white-tailed deer in Alabama. *J Parasitol* 1991;77:62–64.
- Literak I and Hejlíček K. Incidence of *Toxoplasma gondii* in populations of domestic birds in the Czech republic. *Avian Pathol* 1993;22:275–281.
- Lopez A, Dietz VJ, Wilson M, Navin TR, and Jones JL. Preventing congenital toxoplasmosis. *MMWR Recomm Rep* 2000;49:59–68.
- Macrì G, Sala M, Linder A, Pettrossi N, and Scarpulla M. Comparison of indirect fluorescent antibody test and modified agglutination test for detecting *Toxoplasma gondii* immunoglobulin G antibodies in dog and cat. *Parasitol Res* 2009;105:35–40.
- Mateus-Pinilla NE, Dubey JP, and Choromanski L. A field trial of the effectiveness of a feline *Toxoplasma gondii* vaccine in reducing T. *gondii* exposure for swine. *J Parasitol* 1999;85:855–860.
- McAllister MM. A decade of discoveries in veterinary protozoology changes our concept of “subclinical” toxoplasmosis. *Vet Parasitol* 2005;132:241–247.
- McConnell JF, Sparkes AH, Blunden AS, Neath PJ, and Sansom J. Eosinophilic fibrosing gastritis and toxoplasmosis in a cat. *J Feline Med Surg* 2007;9:82–88.
- Meerburg BG, Riel JWV, Cornelissen JB, Kijlstra A, and Mul MF. Cats and goat whey associated with *Toxoplasma gondii* infection in pigs. *Vector Borne Zoonot Dis* 2006;6:266–274.
- Mele A, Paterson PJ, Prentice HG, Leoni P, and Kibbler CC. Toxoplasmosis in bone marrow transplantation: a report of two cases and systematic review of the literature. *Bone Marrow Transplant* 2002;29:691–698.
- Miller MA, Ehlers K, Dubey JP, and Van Steenberg K. Outbreak of toxoplasmosis in wallabies on an exotic animal farm. *J Vet Diagn Invest* 1992;4:480–483.
- Montoya JG and Liesenfeld O. Toxoplasmosis. *Lancet* 2004;363:1965–1976.
- Moré G, Basso W, Bacigalupe D, Venturini M, and Venturini L. Diagnosis of *Sarcocystis cruzi*, *Neospora caninum*, and *Toxoplasma gondii* infections in cattle. *Parasitol Res* 2008;102:671–675.

- Omata Y, Dilorenzo C, Venturini C, et al. Correlation between antibody levels in *Toxoplasma gondii* infected pigs and pathogenicity of the isolated parasite. *Vet Parasitol* 1994;51:205–210.
- Ozkan AT, Celebi B, Babur C, Lucio-Forster A, Bowman DD, and Lindsay DS. Investigation of anti-*Toxoplasma gondii* antibodies in cats of the Ankara region of Turkey Using the Sabin-Feldman dye test and an indirect fluorescent antibody test. *J Parasitol* 2008;94:817–820.
- Petersen E, Vesco G, Villari S, and Buffolano W. What do we know about risk factors for infection in humans with *Toxoplasma gondii* and how can we prevent infections? *Zoonoses Public Health* 2010;57:8–17.
- Pierrigli Fioretti D. [Problems and limitations of conventional and innovative methods for the diagnosis of Toxoplasmosis in humans and animals]. *Parassitologia* 2004;46:177–181.
- Pietkiewicz H, Hiszczyńska-Sawicka E, Kur J, Petersen E, Nielsen H, Paul M, Stankiewicz M, and Myjak P. Usefulness of *Toxoplasma gondii* recombinant antigens (GRA1, GRA7 and SAG1) in an immunoglobulin G avidity test for the serodiagnosis of toxoplasmosis. *Parasitol Res* 2007;100:333–337.
- Poljak Z, Dewey CE, Friendship RM, Martin SW, Christensen J, Ojkic D, Wu J, and Chow E. Pig and herd level prevalence of *Toxoplasma gondii* in Ontario finisher pigs in 2001, 2003, and 2004. *Can J Vet Res* 2008;72:303–310.
- Remington JS. Toxoplasmosis and congenital infection. *Birth Defects* 1968;4:49–56.
- Riemann HP, Meyer ME, and Theis JH. Toxoplasmosis in an infant fed unpasteurized goat milk. *J Pediatr* 1975;87:573–576.
- Sacks JJ, Roberto RR, and Brooks NF. Toxoplasmosis infection associated with raw goat's milk. *J Am Med Assoc* 1982;248:1728–1732.
- Salant H, Weingram T, Spira DT, and Eizenberg T. An outbreak of Toxoplasmosis amongst squirrel monkeys in an Israeli monkey colony. *Vet Parasitol* 2009;159:24–29.
- Samra NA, McCrindle CM, Penzhorn BL, and Cenci-Goga BT. Seroprevalence of toxoplasmosis in sheep in South Africa. *J S Afr Vet Assoc* 2007;78:116–120.
- Sanger VL and Cole CR. Toxoplasmosis. VI. Isolation of *Toxoplasma* from milk, placentas, and newborn pigs of asymptomatic carrier sow. *Am J Vet Res* 1955;16:536–539.
- Schaes G, Vrhovec MG, Pantchev N, Herrmann DC, and Conraths FJ. Occurrence of *Toxoplasma gondii* and *Hammondia hammondi* oocysts in the faeces of cats from Germany and other European countries. *Vet Parasitol* 2008;152:34–45.
- Shaapan RM, El-Nawawi FA, and Tawfik MAA. Sensitivity and specificity of various serological tests for the detection of *Toxoplasma gondii* infection in naturally infected sheep. *Vet Parasitol* 2008;153:359–362.
- Sibley LD and Boothroyd JC. Virulent strains of *Toxoplasma gondii* comprise a single clonal lineage. *Nature* 1992;359:82–85.
- Skinner LJ, Timperley AC, Wightman D, Chatterton JMW, and Hoyen DO. Simultaneous diagnosis of toxoplasmosis in goats and goatowners family. *Scand J Infect Dis* 1990;22:359–361.
- Stagno S, Dykes AC, Amos CS, Head RA, Juranek DD, and Walls K. An outbreak of toxoplasmosis linked to cats. *Pediatrics* 1980;67:706–712.
- Svobodova V, Knotek Z, and Svoboda M. Prevalence of IgG and IgM antibodies specific to *Toxoplasma gondii* in cats. *Vet Parasitol* 1998;80:173–176.
- SYROCOT. The SYROCOT (Systematic Review on Congenital Toxoplasmosis) study group—effectiveness of prenatal treatment for congenital toxoplasmosis: a meta-analysis of individual patients' data. *Lancet* 2007;13:115–122.
- Tassi P. *Toxoplasma gondii* infection in horses. A review. *Parassitologia* 2007;49:7–15.
- Tenter AM. *Toxoplasma gondii* in animals used for human consumption. *Mem Inst Oswaldo Cruz* 2009;104:364–369.
- Tenter AM, Heckeroth AR, and Weiss LM. *Toxoplasma gondii*: from animals to humans. *Int J Parasitol* 2000;30:1217–1258.
- Tibayrenc M, Kjellberg F, Arnaud J, Oury B, Brenière SF, Dardé ML, and Ayala FJ. Are eukaryotic microorganisms clonal or sexual? A population genetics vantage. *Proc Natl Acad Sci USA* 1991;88:5129–5133.
- van Maanen C, Wouda W, Schares G, von Blumröder D, Conraths FJ, Norton R, Williams DJL, Esteban-Redondo I, Innes EA, Mattsson JG, Björkman C, Fernández-García A, Ortega-Mora LM, Müller N, Sager H, and Hemphill A. An inter-laboratory comparison of immunohistochemistry and PCR methods for detection of *Neospora caninum* in bovine foetal tissues. *Vet Parasitol* 2004;126:351–364.
- Velmurugan GV, Su C, and Dubey JP. Isolate designation and characterization of *Toxoplasma gondii* isolates from pigs in the United States. *J Parasitol* 2009;95:95–99.
- Vikøren T, Tharaldsen J, Fredriksen B, and Handeland K. Prevalence of *Toxoplasma gondii* antibodies in wild red deer, roe deer, moose, and reindeer from Norway. *Vet Parasitol* 2004;120:159–169.
- Vollaire MR, Radecki SV, and Lappin MR. Seroprevalence of *Toxoplasma gondii* antibodies in clinically ill cats in the United States. *Am J Vet Res* 2005;66:874–877.
- Wainwright KE, Lagunas-Solar M, Miller MA, Barr BC, Gardner IA, Pina C, Melli AC, Packham AE, Zeng N, Truong T, and Conrad PA. Physical inactivation of *Toxoplasma gondii* oocysts in water. *Appl Environ Microbiol* 2007a;73:5663–5666.
- Wainwright KE, Miller MA, Barr BC, Gardner IA, Melli AC, Essert T, Packham AE, Truong T, Lagunas-Solar M, and Conrad PA. Chemical inactivation of *Toxoplasma gondii* oocysts in water. *J Parasitol* 2007b;93:925–931.
- Weiss LM and Kami K. *Toxoplasma gondii. The Model Apicomplexan: Perspectives and Methods*. London, UK: Academic Press, 2007.
- Work TM, Massey G, Rideout BA, Gardiner CH, Ledig DB, Kwok OCH, and Dubey JP. Fatal toxoplasmosis in free-ranging endangered 'alala from Hawaii. *J Wildl Dis* 2000;36:205–212.
- Xiao J, Buka SL, Cannon TD, Suzuki Y, Viscidi RP, Torrey EF, and Yolken RH. Serological pattern consistent with infection with type I *Toxoplasma gondii* in mothers and risk of psychosis among adult offspring. *Microbes Infect* 2009;11:1011–1018.
- Yolken RH, Dickerson FB, and Fuller Torrey E. *Toxoplasma* and schizophrenia. *Parasite Immunol* 2009;31:706–715.
- Zardi O, Gabrielli G, del Vecchio R, Adorisio E, and Drisaldi D. Correlazione tra toxoplasmosi animale ed umana. Ricerche immunobiologiche su uccelli e soggetti umani addetti al loro governo. *Ig Sanita Pubbl* 1967;23:303–317.
- Zhu S. Psychosis may be associated with toxoplasmosis. *Med Hypotheses* 2009;73:799–801.

Address correspondence to:

Beniamino T. Cenci-Goga, D.V.M., Ph.D., mECVPH
 Sezione di Ispezione degli Alimenti di Origine Animale
 Facoltà di Medicina Veterinaria
 Università degli Studi di Perugia
 via San Costanzo
 06121 Perugia
 Italy

E-mail: cencigoga@unipg.it