

Dental nerve block techniques

Proper training and practice can enhance the level of care you offer to Pets and clients.



By Gary S. Goldstein,
DVM, FAVD, DAVDC
Contributing Author

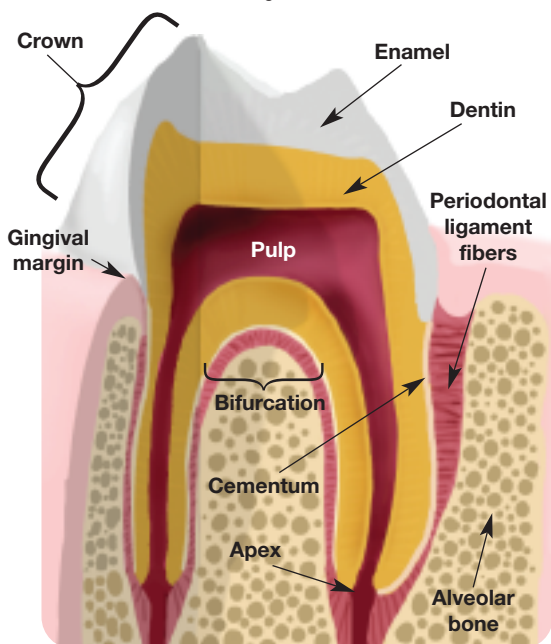
Most dental procedures produce strong sensory stimuli that affect general anesthesia requirements and postoperative recovery. Dental nerve blocks interrupt these sensory stimuli locally and should be a component of overall pain management. Regional dental nerve blocks can decrease the concentration of inhalant anesthesia required,¹ which reduces adverse side effects, such as hypotension, bradycardia and hypoventilation.¹ In addition, dental nerve blocks ease the patient's recovery from anesthesia because adverse side effects, such as hypertension, tachycardia and tachypnea, are also minimized postoperatively because of decreased oral pain.²

Local anesthetics completely block sensory nerve transmission and prevent secondary (central) pain sensitization. For this reason, local blocks are often used in conjunction with other injectable and systemic pain medications.³

Perioperative pain management is required for tissue injury resulting from noxious stimuli and a subsequent decreased pain threshold at the surgical site. Analgesics given preoperatively and intraoperatively are often insufficient because of the ongoing postoperative inflammatory reaction involving the injured hard and soft tissue. The resultant inflammatory mediator release can cause peripheral and central sensitization.⁴ Practitioners should consider a multimodal pain management approach to prevent pain hypersensitivity.⁴

The benefits of implementing multimodal pain management for dental and oral surgery, specifically dental blocks, include:

- Owners expect effective pain management.
- Pets often are discharged the same day after dental procedures, and owners want their Pets to be as alert and pain-free as possible.



Anatomy of a tooth

- Pets recover faster and with fewer complications.⁵
- The minimum alveolar concentration required for inhalant anesthetics is decreased, therefore reducing anesthesia complications and improving safety.¹
- They eliminate the pain perception, decrease anesthesia levels and result in a smoother anesthesia experience.⁶
- Local blocks continue to provide analgesia in the postoperative period, keeping the Pet comfortable while using fewer systemic pain medications.^{7,8}
- Signs of pain after dental procedures, such as rough recoveries, vocalization, restlessness, pawing at the mouth, behavior changes, inappetence and depression, are minimized when regional oral nerve blocks are used.⁹

Many dental surgical procedures produce strong stimulation, and Pets undergoing them often manifest variable depths of general anesthesia due to poor or inadequate analgesic administration.¹⁰

Common dental and oral surgical procedures for which dental nerve blocks are indicated include:

- Surgical and nonsurgical extractions
- Advanced periodontal treatments, such as root planing, periodontal debridement and periodontal flap surgery
- Oral trauma that involves lacerations of the lips, gums and tongue; foreign bodies; and jaw fractures that require soft and hard tissue surgical intervention
- Incisional and excisional biopsies
- Soft- and hard-tissue oral surgery, such as oronasal fistula repair, palatal surgery, maxillectomies, mandibulectomies and reconstruction surgery.

Anatomy of oral nerves

Sensory innervation to the oral structures

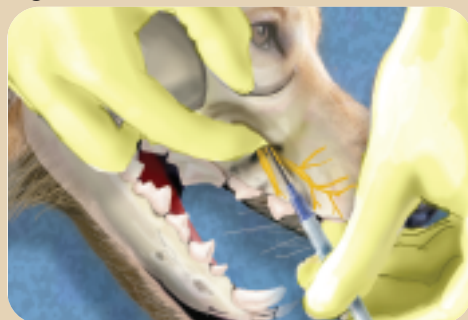
arises from the trigeminal nerve. In the maxilla, the upper teeth, soft and hard tissue and palate are innervated by the maxillary nerve that enters the maxillary foramen and infraorbital canal from the sphenopalatine fossa. The maxillary nerve branches into the infraorbital nerve, which in turn branches into the caudal, middle and rostral superior alveolar nerves. In the mandible, the lower teeth and soft and hard tissues are innervated by the mandibular nerve. The mandibular nerve branches into the lingual nerve just before it enters the mandibular foramen and provides sensory innervation to the tongue and the inferior alveolar nerve; this nerve branches into the rostral, middle and caudal mental nerves, which provide sensory innervation to the lower molars, premolars, canines, incisors and soft and hard tissues of the rostral mandible.

The infraorbital, maxillary, middle mental foramen and inferior alveolar (mandibular) blocks are the most common regional dental nerve blocks used in veterinary medicine. There are several variations on the technique, including intraoral and extraoral positioning of the needle. Gentle insertion of the needle into the soft tissue or foramen will minimize tissue trauma. Once inserted in the proper location, aspirate to ensure that there is no vascular access and then inject slowly. If aspiration yields blood, remove the needle and syringe and start over with a clean needle and syringe. This article will emphasize only intraoral techniques.

Administration of nerve blocks

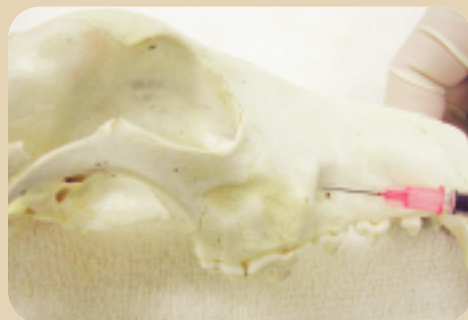
Materials and equipment needed for dental nerve blocks are minimal and include bupivacaine (0.5 percent); 1 ml syringes; 25 gauge, 5/8 inch needles; surgical scrub; and a dog and cat skull to help you locate the foramina.

Figure 1



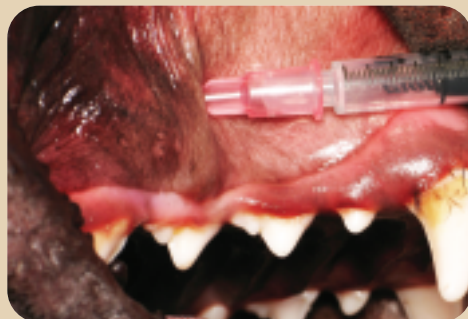Location of the infraorbital nerve block

Figure 2



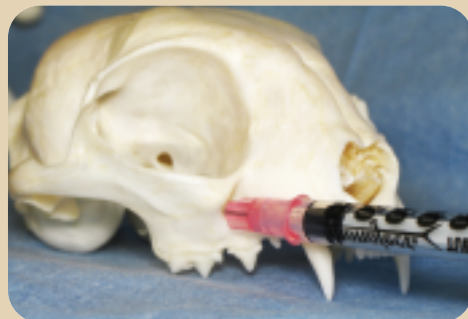Infraorbital nerve block on a dog skull

Figure 3



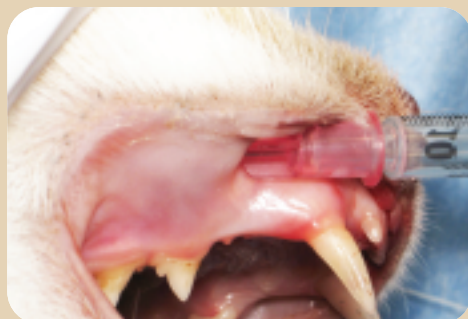Infraorbital nerve block in a dog

Figure 4



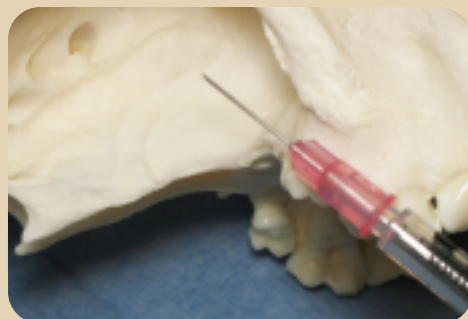Infraorbital nerve block on a cat skull

Figure 5



Infraorbital nerve block in a cat

Figure 6

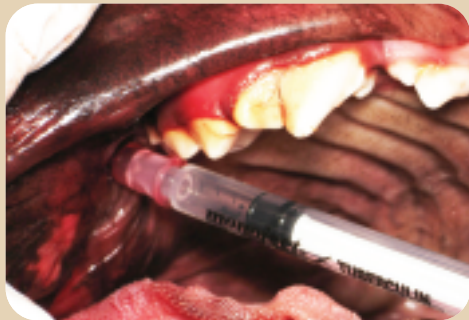


Maxillary nerve block on a dog skull

Bupivacaine (0.5 percent) is the agent of choice for these procedures. Its onset of action is 10 to 15 minutes, and the duration of action is three to eight hours.^{1,2} It offers a higher degree of sensory block than other injectable agents, such as lidocaine (which is ideal for sensory nerves of the head) with less tissue irritation.⁹ Epinephrine (1:200,000) can be added to the bupivacaine to counteract the vasodilation effects; it causes vasoconstriction and,

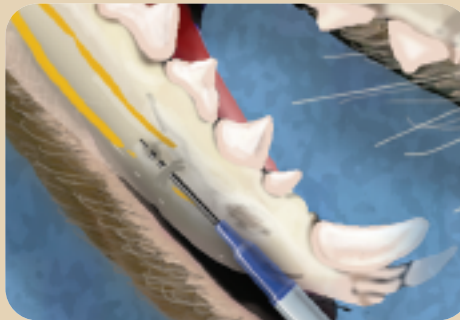therefore, aids in homeostasis and prolongs the dental block's effect.³⁻⁵ Bupivacaine is more toxic than lidocaine to the heart, so the lowest possible dose is used (*i.e.*, do not exceed 2 mg/kg for a total cumulative dose in dogs and 1 mg/kg for a total cumulative dose in cats during any given procedure).^{1,2,4} Generally, the dose per site is 0.5 to 1.0 ml in dogs and 0.2 to 0.3 ml in cats. Keep in mind that in a small dog (*e.g.*, 3 kg), you will need to reduce the

Figure 7



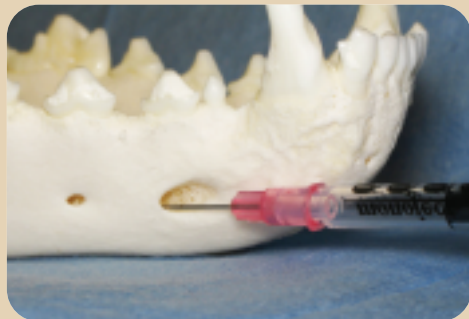
Maxillary nerve block in a dog

Figure 8



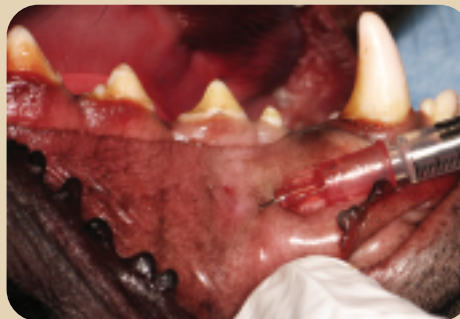Location of the middle mental nerve block

Figure 9



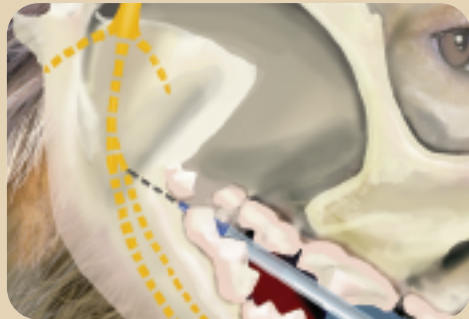Middle mental nerve block on a dog skull

Figure 10



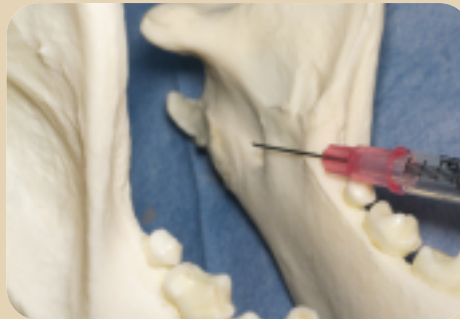Middle mental nerve block in a dog

Figure 11



Location of the inferior alveolar nerve block

Figure 12



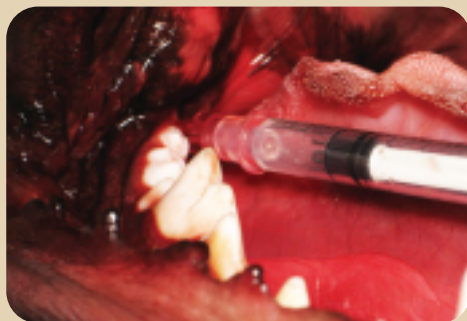Inferior alveolar nerve block on a dog skull

recommended dose of 0.5 ml per site so you don't exceed the total cumulative dose. Some veterinary hospitals have developed charts with weight ranges correlating to the total cumulative dose.

Infraorbital nerve block. Infraorbital nerve blocks affect the maxillary incisors; canines; and the first, second and third premolars as well as the soft and hard tissues rostral to the upper fourth premolars. The nerve can be palpated as an indentation at

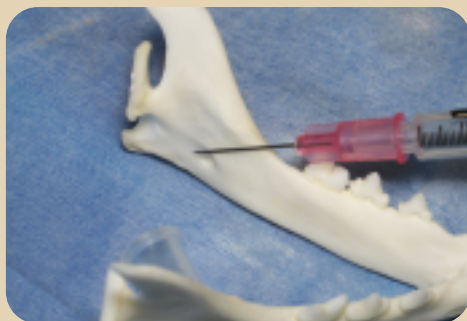the bony ridge in the maxilla dorsal to the distal root of the third maxillary premolar in dogs. It is halfway between a line drawn from the apex of the canine tooth to the dorsal border of the zygomatic arch. In cats, the infraorbital foramen is palpated as a bony ridge dorsal to the second premolar just ventral to the eye, where the zygomatic arch meets the maxilla. In cats, the infraorbital block affects all the teeth on the ipsilateral side where the block is done.

Figure 13



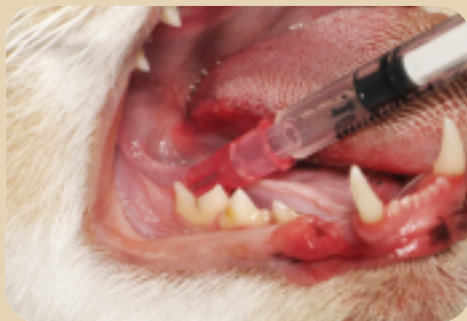Inferior alveolar nerve block in a dog

Figure 14



Inferior alveolar nerve block on a cat skull

Figure 15



Inferior alveolar nerve block in a cat

Once the location is identified, clean the area with surgical scrub and palpate the infraorbital foramen. Insert the needle to the hub through the buccal mucosa in a caudal direction parallel to the dental arcade, into the entrance of the foramen. Aspirate and then inject slowly (*Figures 1 to 5*, page 26).

Maxillary nerve block. This block affects the maxillary fourth premolar, upper molars and the soft and hard tissue caudal to the maxillary fourth premolars, including

the hard and soft palate. This block mimics a splash block—you are not actually entering a foramen as you do with the infraorbital block, but you rely on anatomical direction to affect the maxillary nerve by injecting in the area where the nerve branches around the upper molars and fourth premolar. This block is only used in dogs.

Clean the area with surgical scrub and insert the needle to the hub into the area of soft tissue just caudal to the last molar at a 30 to 45 degree angle with the dental arcade. Aspirate and then inject slowly (*Figures 6 and 7*, pages 26 to 27).

Middle mental nerve block. The middle mental block affects primarily the mandibular incisors and surrounding soft tissue.^{11,12} The middle mental foramen is the largest of the three mental foramina and is the one used most often. It is located and can be palpated ventral to the mesial root of the lower second premolar, just caudal to the mandibular labial frenulum. In cats and small-breed dogs, the middle mental foramen is difficult to palpate; therefore, the inferior alveolar nerve block is used in those cases.

Once identified, clean the area with surgical scrub, insert the needle into the submucosa in a rostral to caudal direction and advance it into the middle mental foramen. Aspirate and inject slowly. In most dogs, the needle will not penetrate completely to the hub as it does with the infraorbital dental block (*Figures 8 to 10*, page 27).

Inferior alveolar nerve block. The inferior alveolar, or mandibular, block affects all the teeth in the mandible, including the soft and hard tissues. If the local anesthetic infiltrates in a more lingual caudal direction, the tongue may be affected; therefore, it is important to make sure the needle is directed towards the caudal

ramus of the mandible when inserting to prevent the bupivacaine from anesthetizing the tongue.

The mandibular foramen is located two-thirds of the distance from the last molar to the angular process. The foramen is 1/2 to 1 inch from the ventral surface of the mandible in dogs and 1/4 inch from the ventral surface of the mandible in cats. Palpate the angular process extraorally (as the most caudal and ventral projection of the mandible) and the mandibular foramen intraorally with a forefinger. Insert the needle just caudal to the last molar in a direction towards the angular process, and advance the needle along the lingual surface of the mandible adjacent to the mandibular foramen. Aspirate and inject slowly (*Figures 11 to 15, pages 27 to 28*).

Discussion

Regional dental nerve blocks are relatively safe when used correctly. Complications resulting from oral nerve blocks have been described in human dentistry; however, the incidence is extremely low.¹³ Toxic doses of bupivacaine have been reported to cause cardiovascular toxicity and death in people, although this is also very rare.¹⁴

Even though these complications are uncommon in Pets, practitioners still need to ensure correct dosing, choose an appropriate needle size and length, identify appropriate locations, insert and advance the needle gently to avoid unnecessary soft tissue trauma and aspirate before injecting the bupivacaine. With practice and proper training, dental nerve blocks are inexpensive to perform and easy to learn. They will significantly improve Pet care and be a valuable addition to your pain management armamentarium for your dental and oral surgical procedures. 🐾

References

1. Holmstrom SE, Frost P, Eisner ER. *Veterinary dental techniques*. Philadelphia, Pa: W.B. Saunders, 1998:492-493.
2. Rochette J. Local anesthetic nerve blocks and oral analgesia, in *Proceedings*. 26th World Congress World Small Anim Vet Assoc 2001.
3. Lemke KA, Dawson SD. Local and regional anesthesia. *Vet Clin North Am Small Anim Prac* 2000;30:839-842.
4. Beckman BW. Pathophysiology and management of surgical and chronic oral pain in dogs and cats. *J Vet Dent* 2006;23:50-59.
5. Lantz G. Regional anesthesia for dentistry and oral surgery. *J Vet Dent* 2003;20:81-86.
6. Ruess-Lamky, H. Administering dental nerve blocks. *J Am Anim Hosp Assoc* 2007;43:298-305.
7. Haws IJ. Local dental anesthesia, in *Proceedings*. 13th Annual Vet Dental Forum, October 1999.
8. Kaurich MJ, Otomo-Corgel J, Nagy FJ. Comparison of postoperative bupivacaine with lidocaine on pain and analgesic use following periodontal surgery. *J West Soc Periodontal Abstr* 1997;45:5-8.
9. Robinson, Elaine P. Pain management for dentistry and oral surgery: Pain management symposium, in *Proceedings*. Am Anim Hosp Assoc Conf, March 2002.
10. Duke T. Dental anaesthesia and special care of the dental patient. In: Crossley DA, Penman S, eds. *BSAVA manual of small animal dentistry*. 2nd ed. BSAVA, Cheltenham UK, 1995:27-34.
11. Klima L, Hansen D, Goldstein G. University of Minnesota Veterinary Medical Center. Unpublished data, 2007.
12. Robinson E. University of Minnesota College of Veterinary Medicine. Personal communication, 2002.
13. Pogrel MA, Thamby S. Permanent nerve involvement resulting from inferior alveolar nerve blocks. *J Am Dent Assoc* 2000;131:901-907.
14. Younessi OJ, Punnia-Moorth A. Cardiovascular effects of bupivacaine and the role of this agent in preemptive dental analgesia. *Anesth Prog* 1999;46:56-62.

Gary S. Goldstein, DVM, FAVD, DAVDC, is associate clinical professor, director of the Veterinary Dental Service and associate medical director of the University of Minnesota Veterinary Medical Center. He graduated from the University of Minnesota School of Veterinary Medicine in 1984. He then joined Gulf Coast Veterinary Specialists. Dr. Goldstein became a Charter Fellow in the Academy of Veterinary Dentistry. He has a half-time position as medical director of small animal specialties at the specialty hospital.