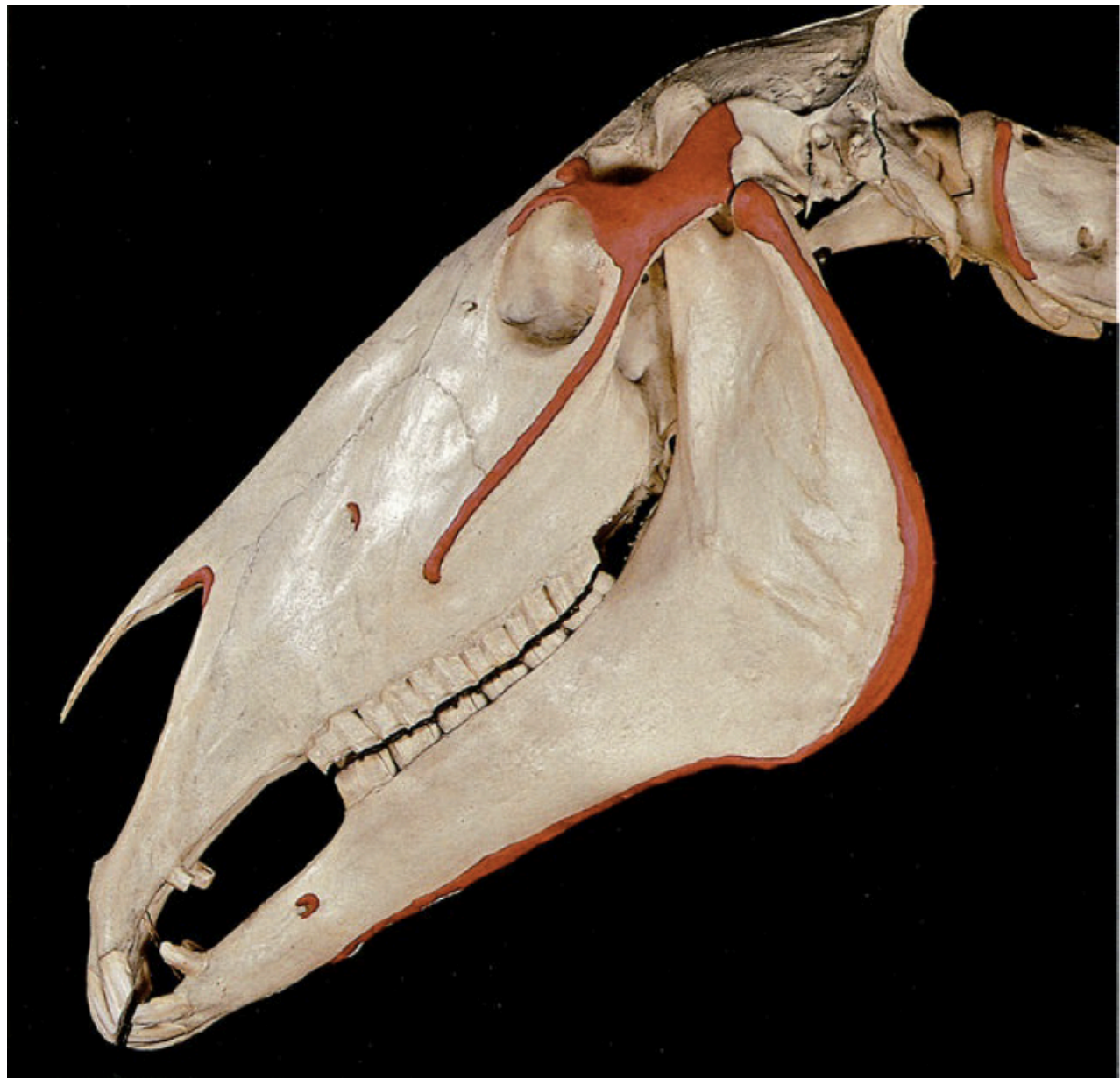


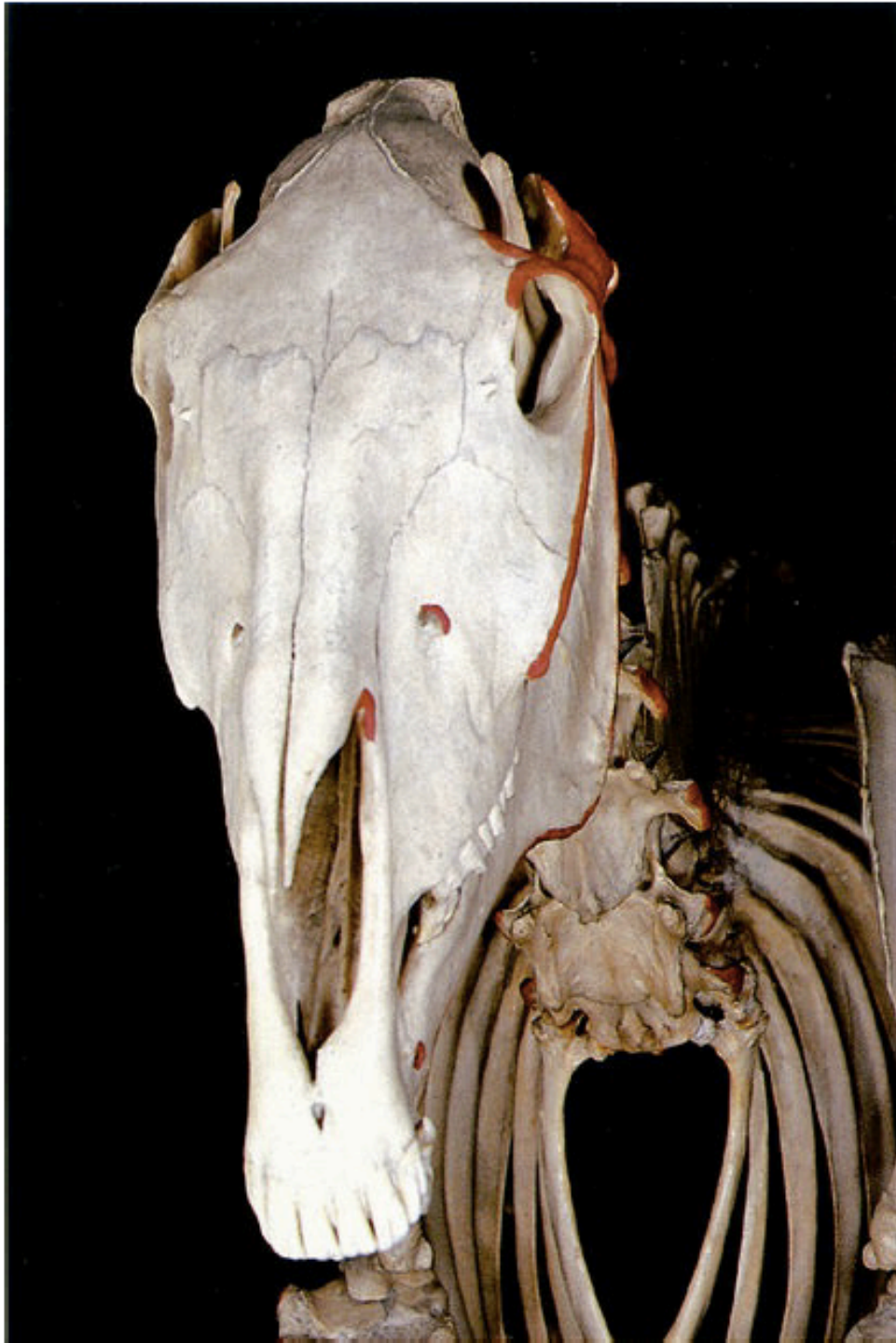LZT 0313 Anatomia e Fisiologia Animal  
2020/02

# Osteologia

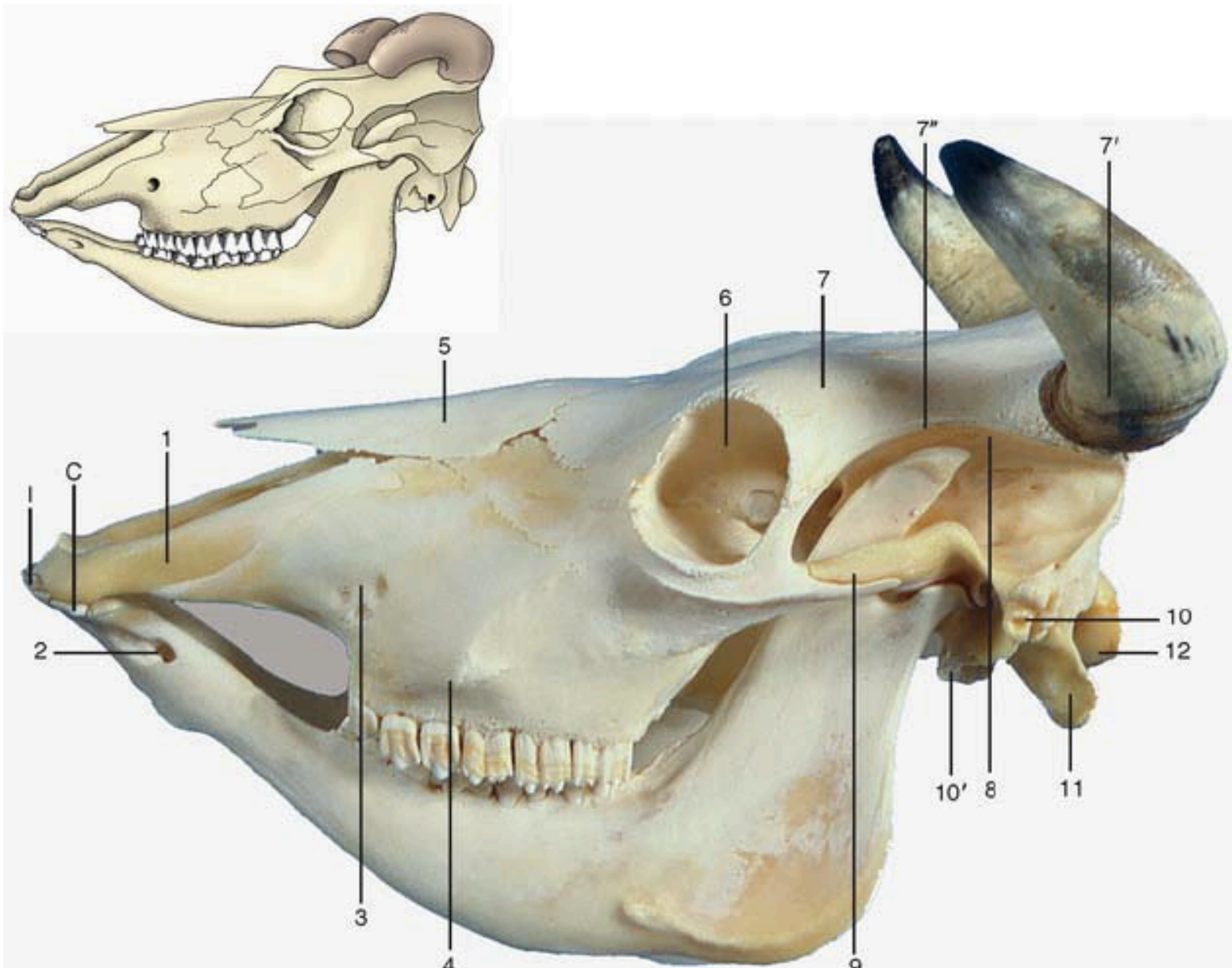
# Crânio



Ossos da cabeça: vista lateral esquerda (Equino).



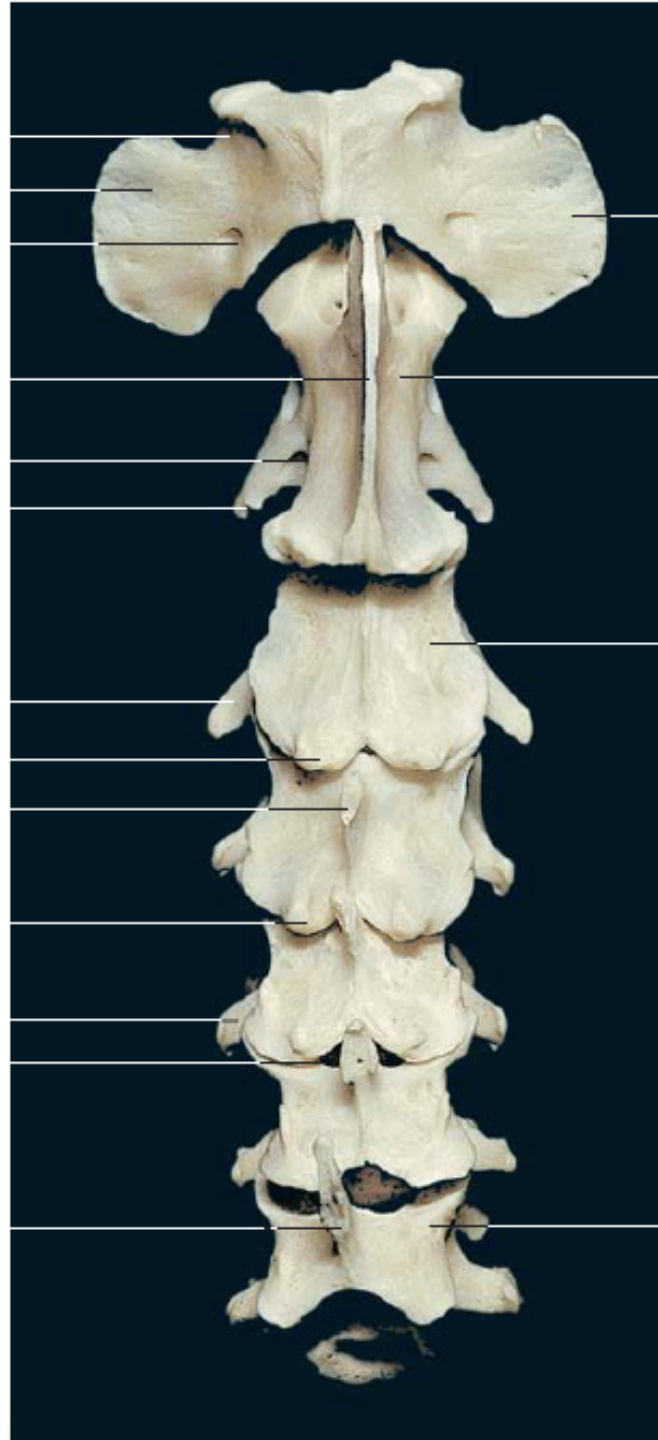
Ossos da cabeça: vista rostral.



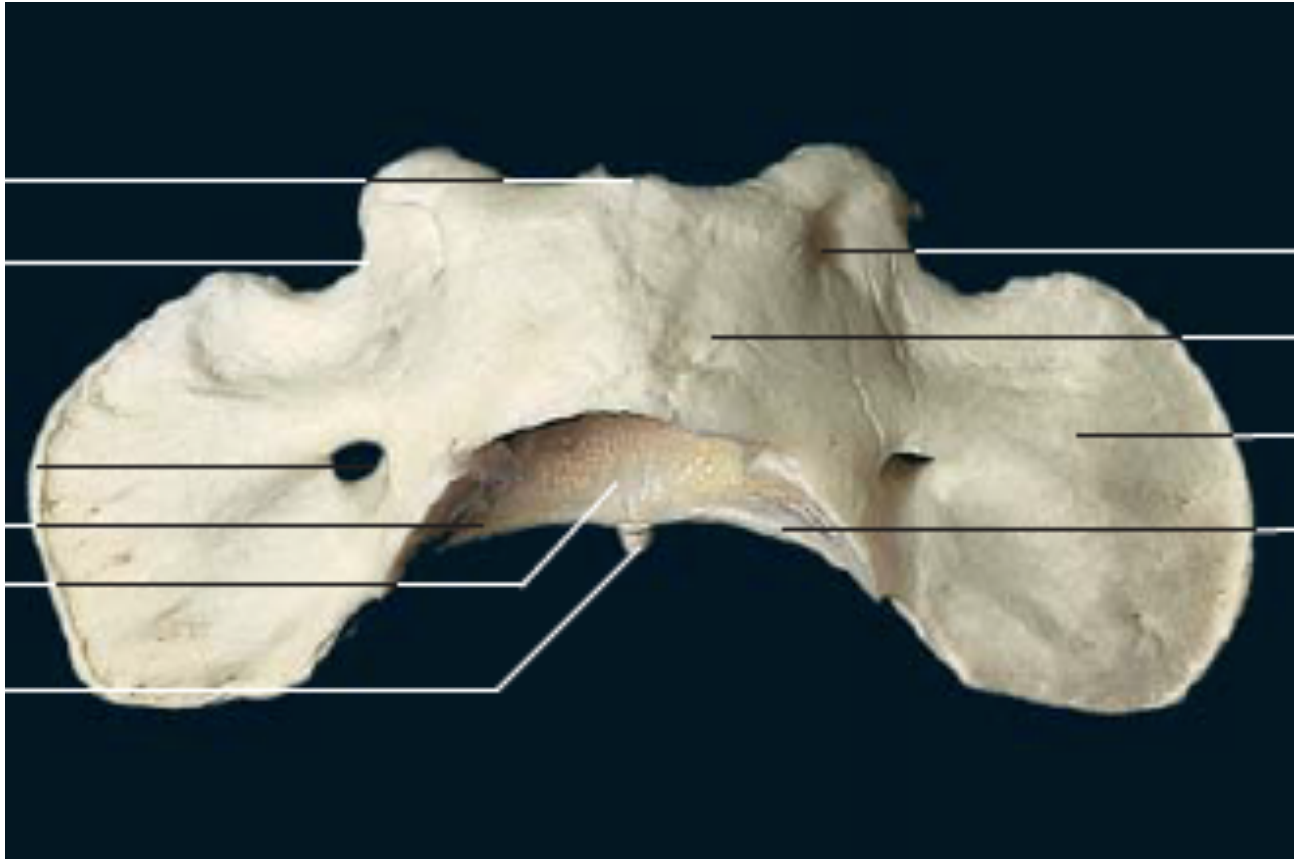
Crânio bovino



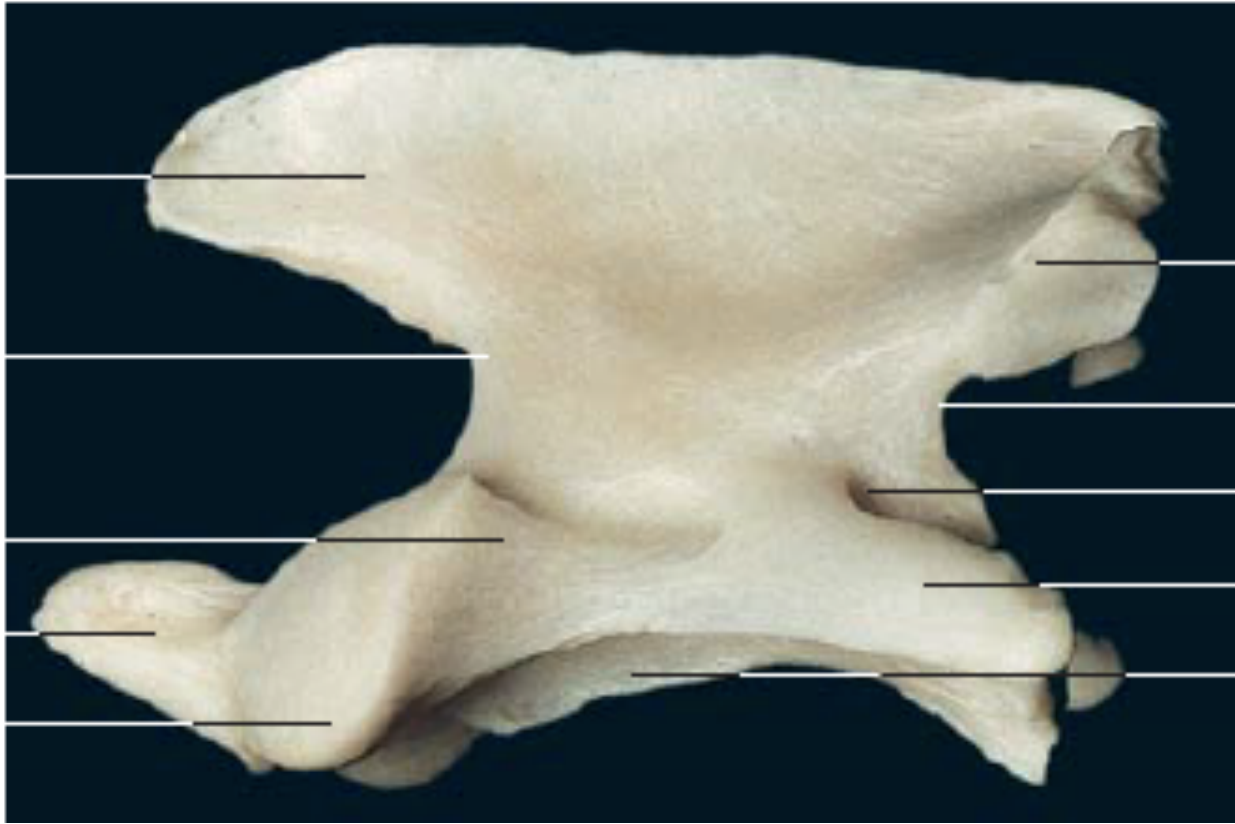
# Vértebras



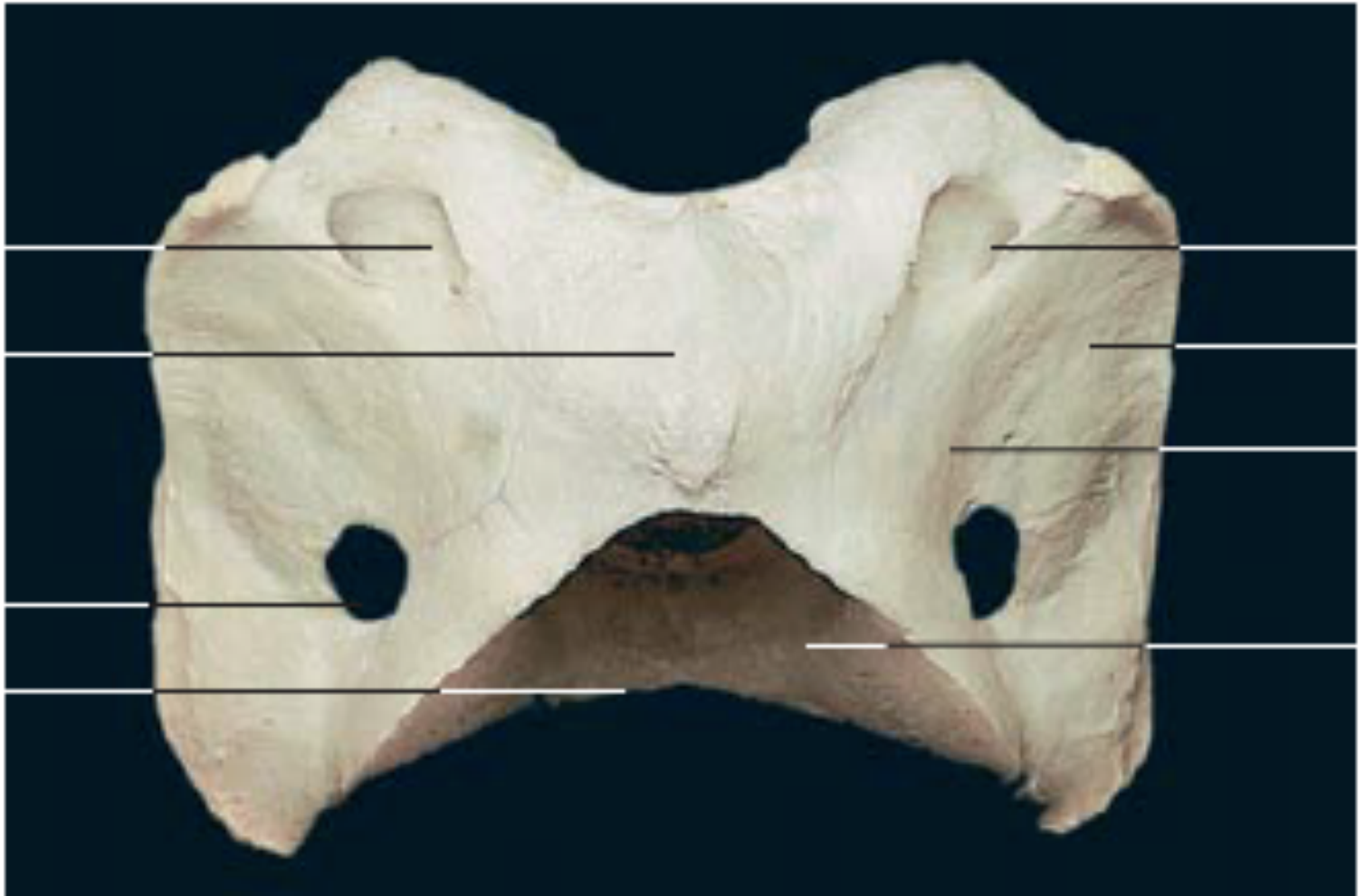Coluna cervical  
(vista dorsal)



Primeira vértebra cervical (atlas) (vista dorsal).  
Primeira vértebra cervical (atlas) (vista dorsal).

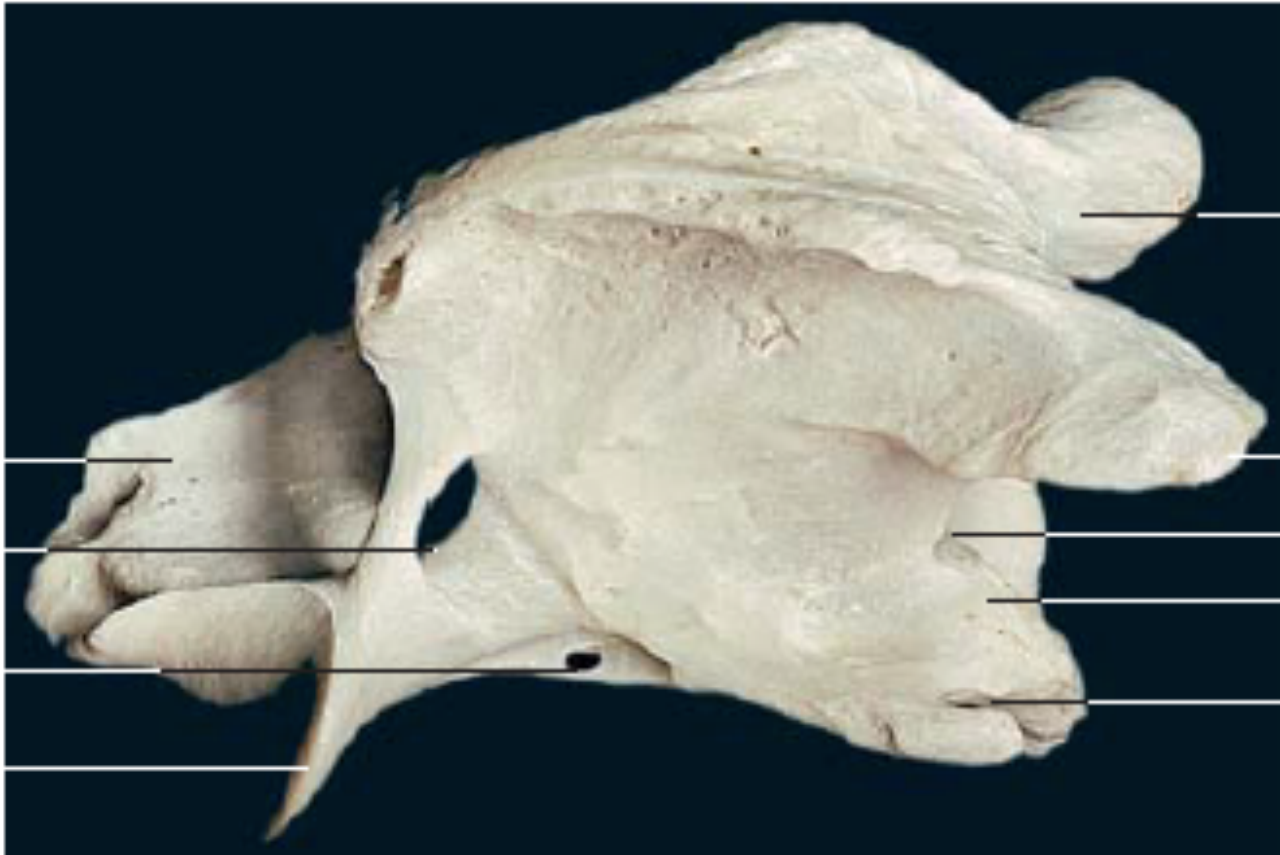


Segunda vértebra cervical (áxis) (vista lateral).

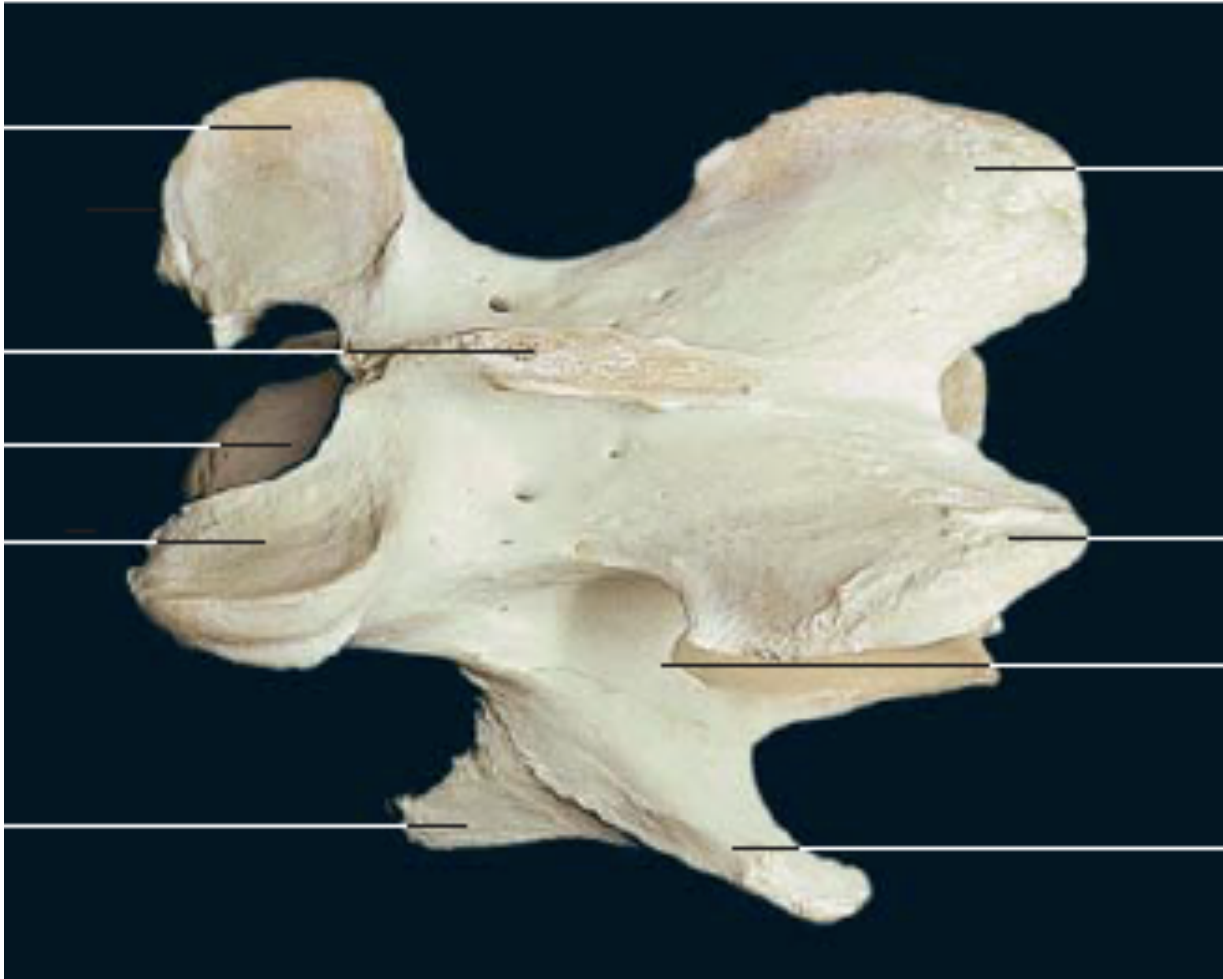


Primeira vértebra cervical (atlas) (vista dorsal).

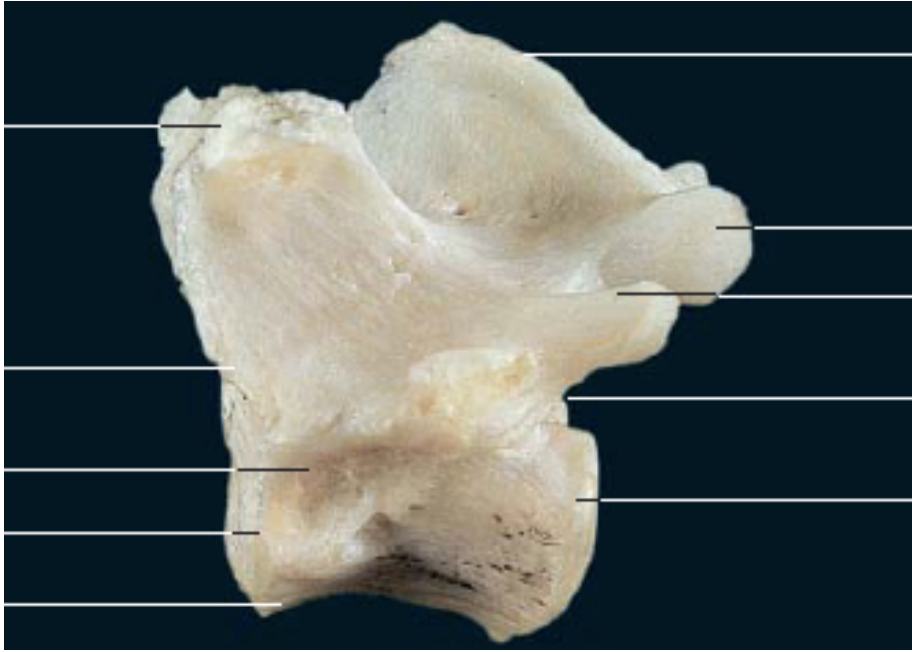




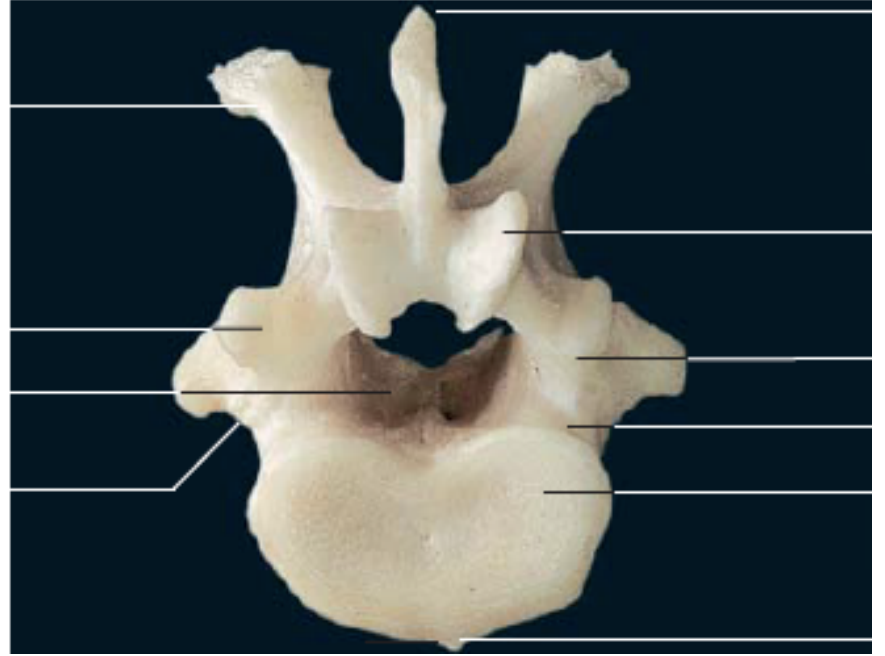
Segunda vértebra cervical (áxis) (vista lateral).



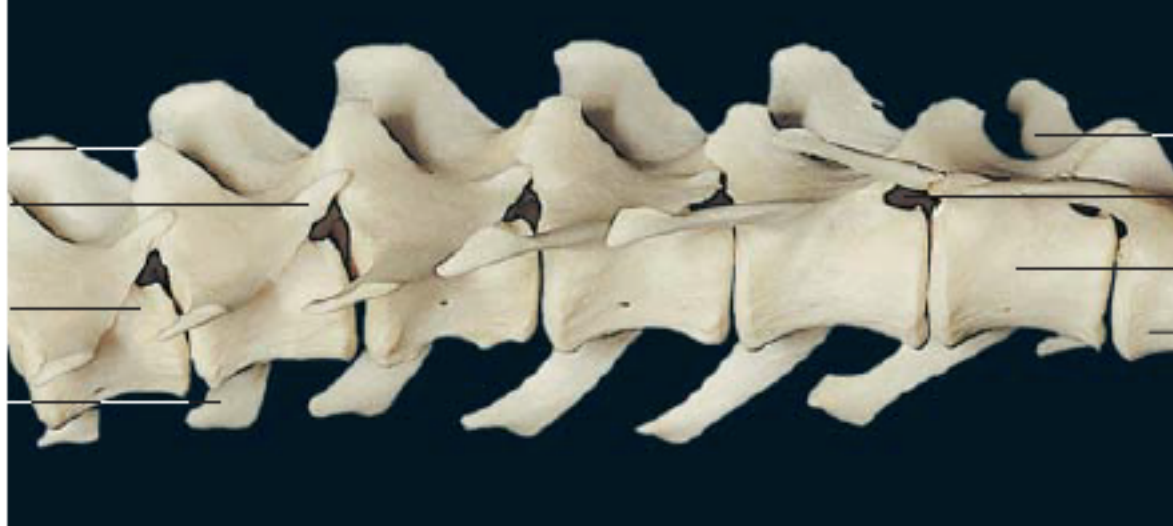
Terceira vértebra cervical (vista dorsolateral).



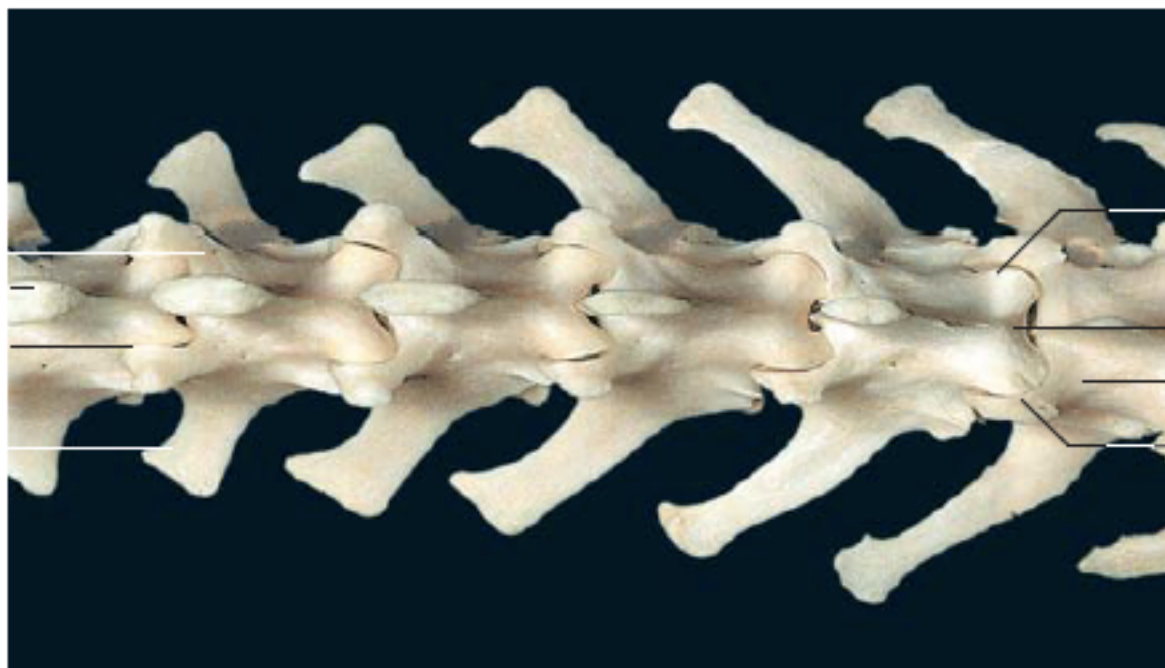
13<sup>a</sup> vértebra torácica (vista lateral).



13<sup>a</sup> vértebra torácica (vista caudal).

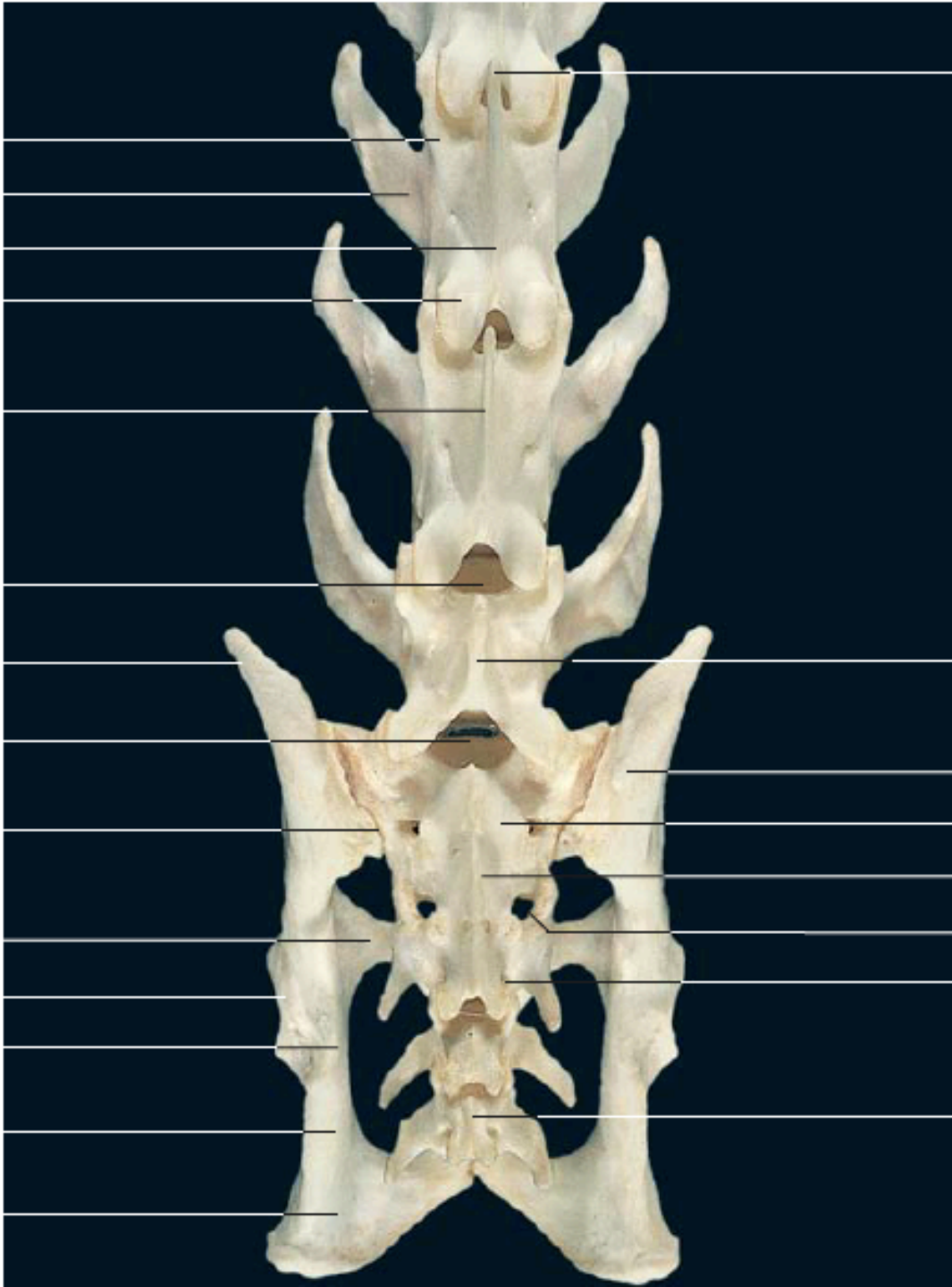


Coluna lombar (vista lateroventral).

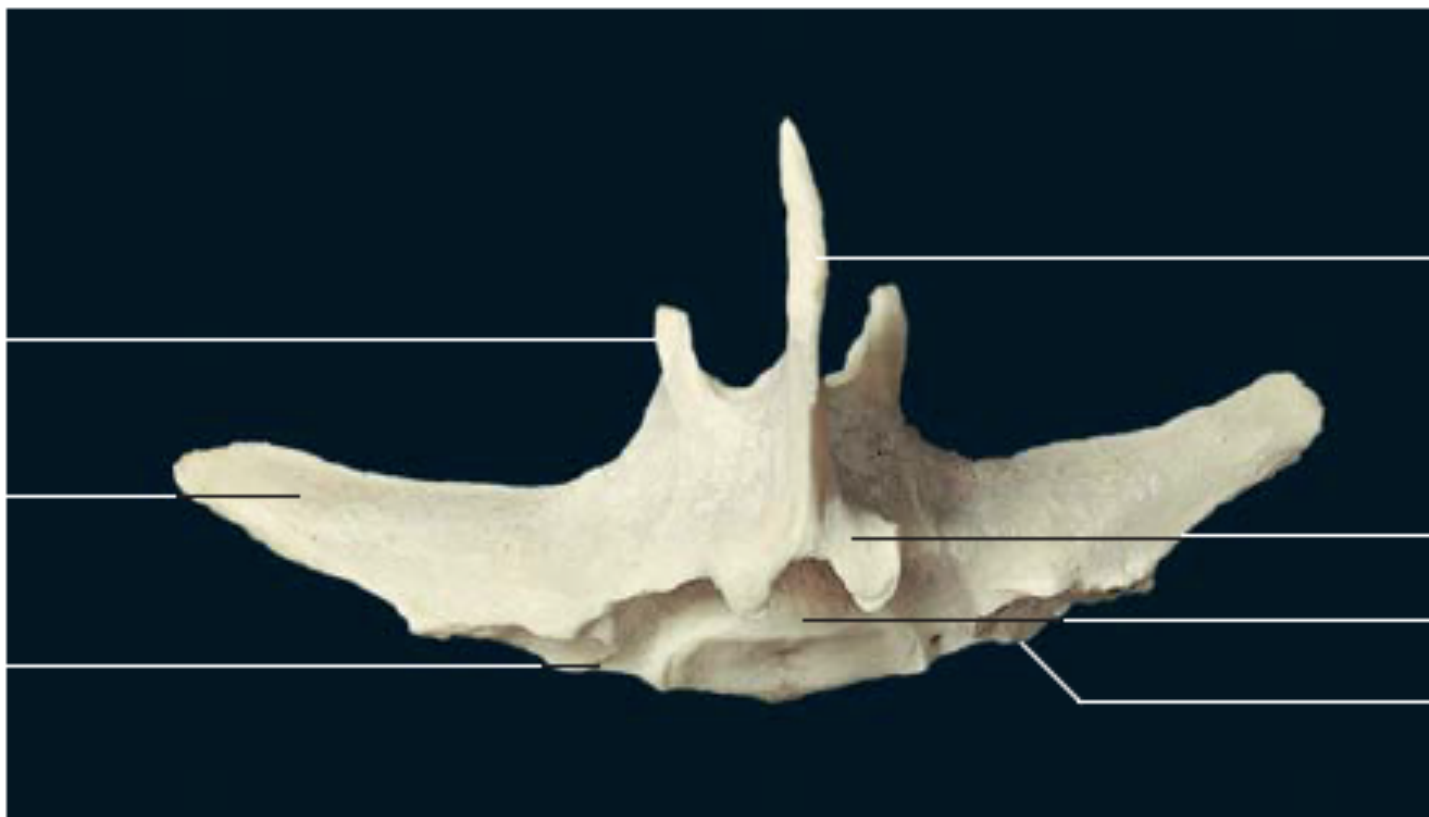

Coluna lombar (vista dorsal).

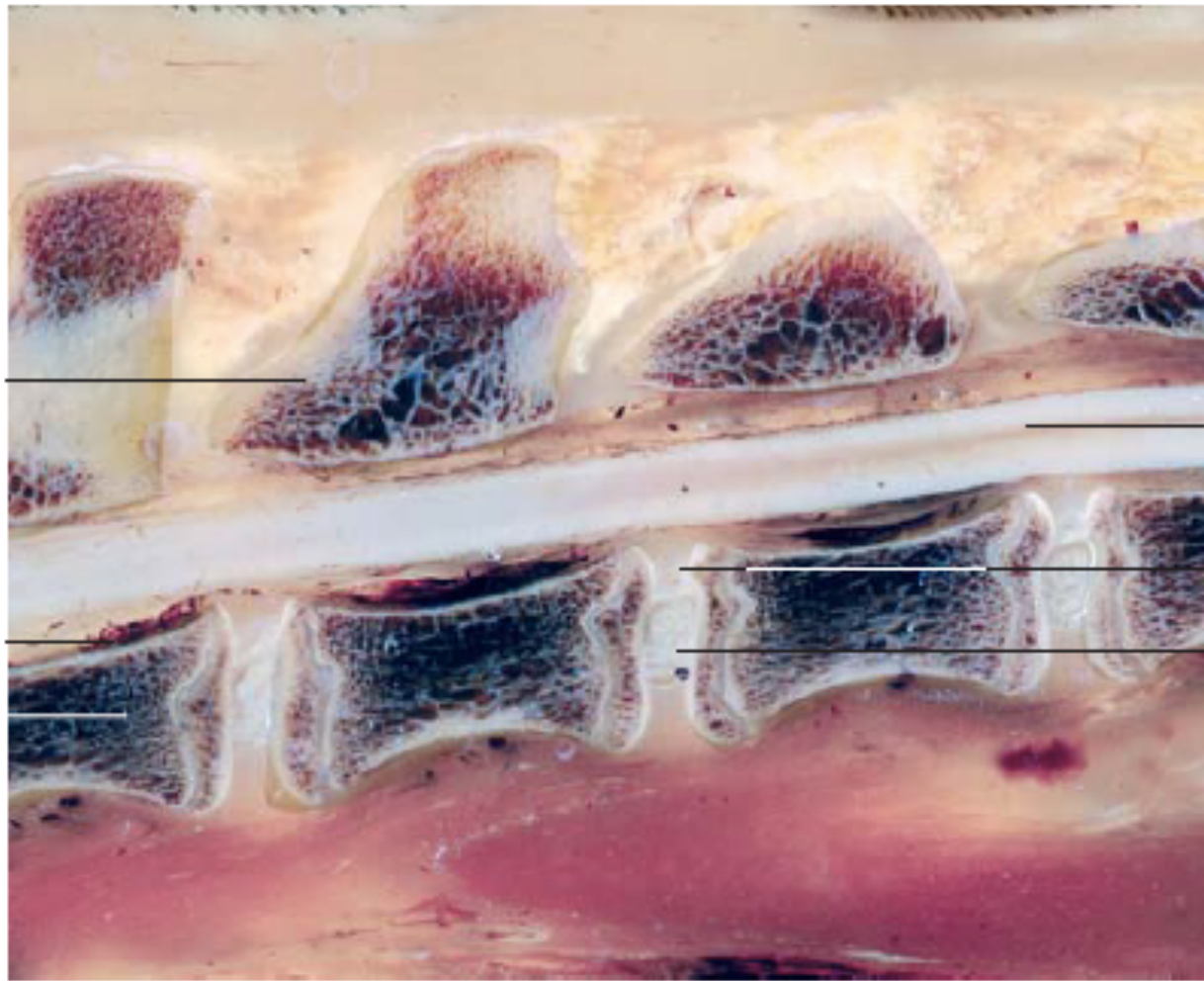



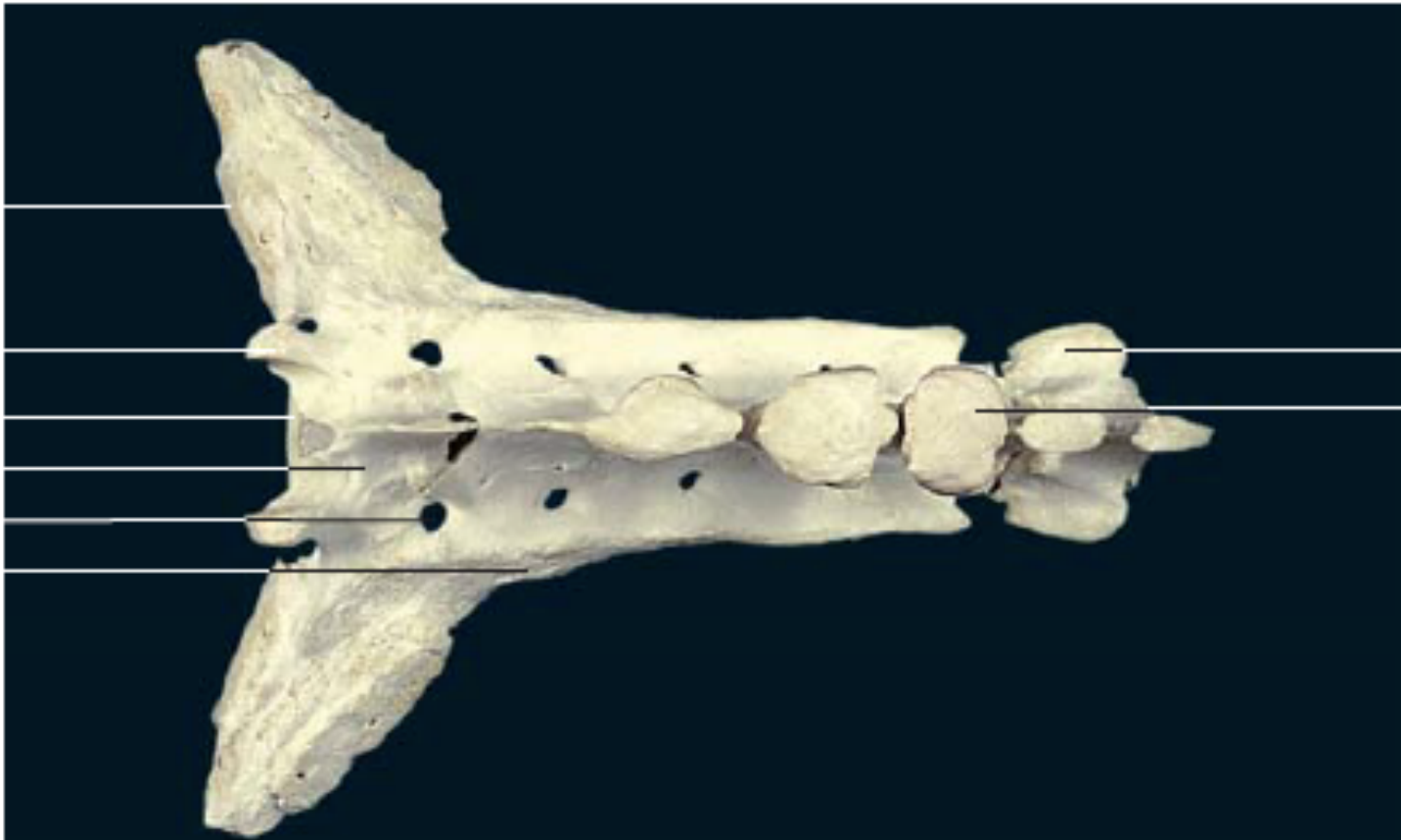
Últimas vértebras lombares, sacro e pelve de um gato (vista dorsal).



5<sup>a</sup> vértebra lombar (vista dorsal).



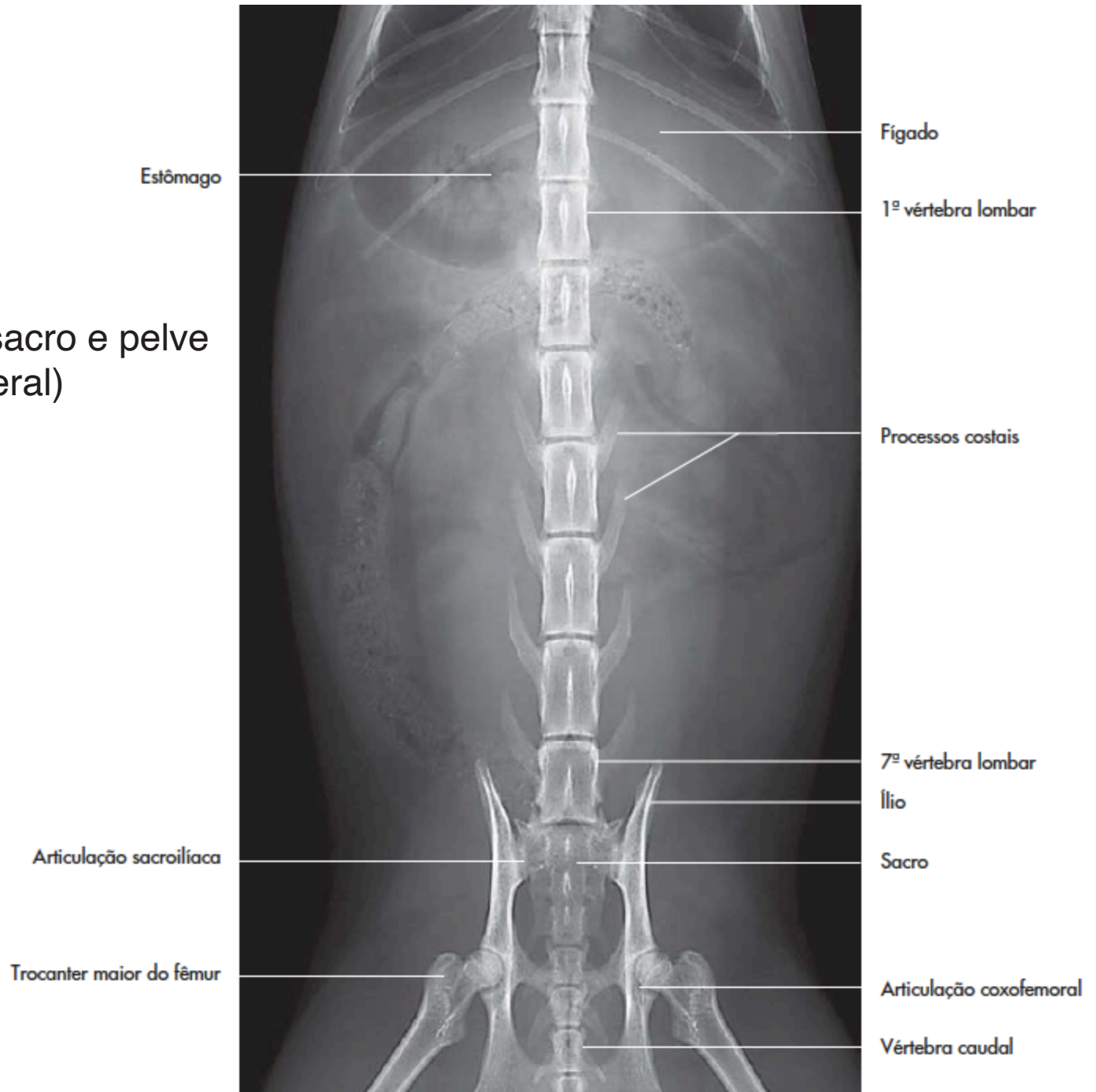
Discos intervertebrais da região lombar (secção mediano)



Sacro (vista dorsal).




# Vértebras lombares, sacro e pelve (projeção ventrolateral)



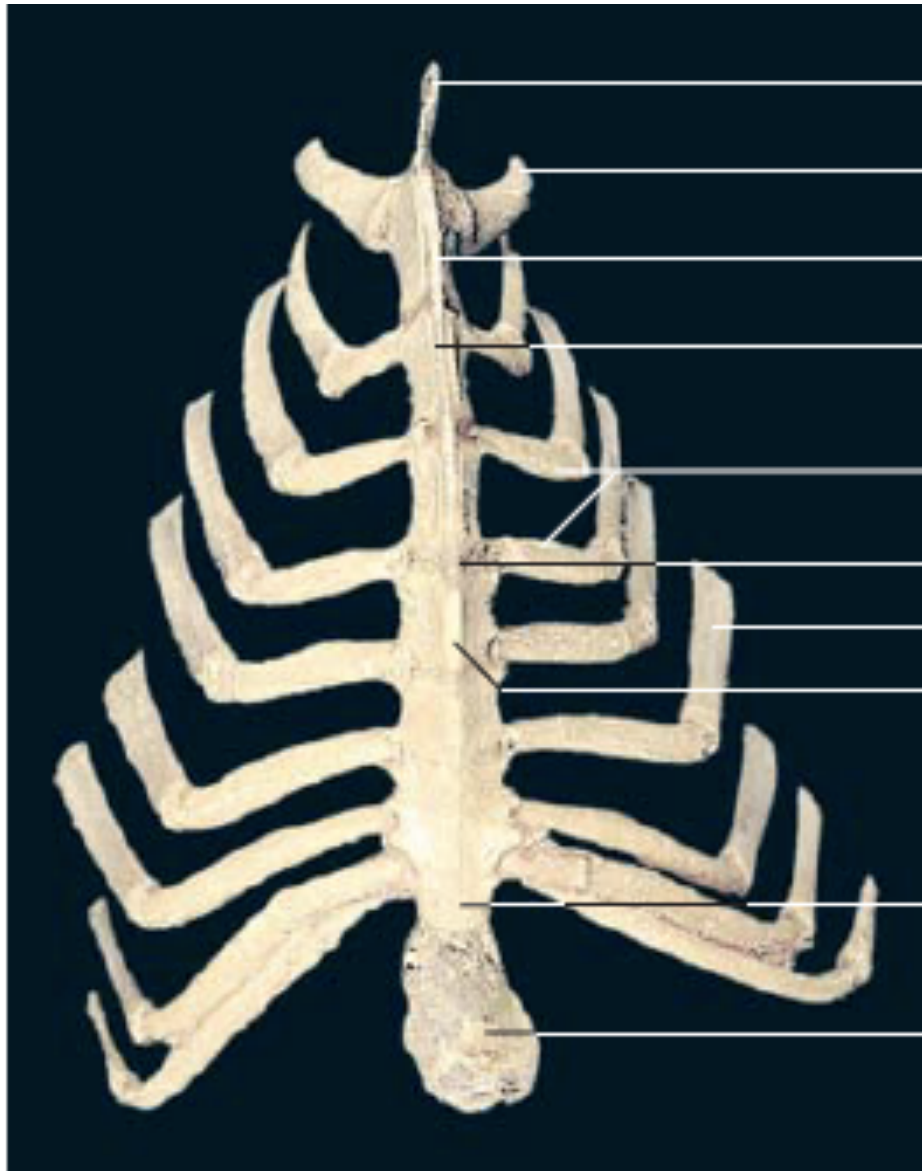




Costela (vista caudal).

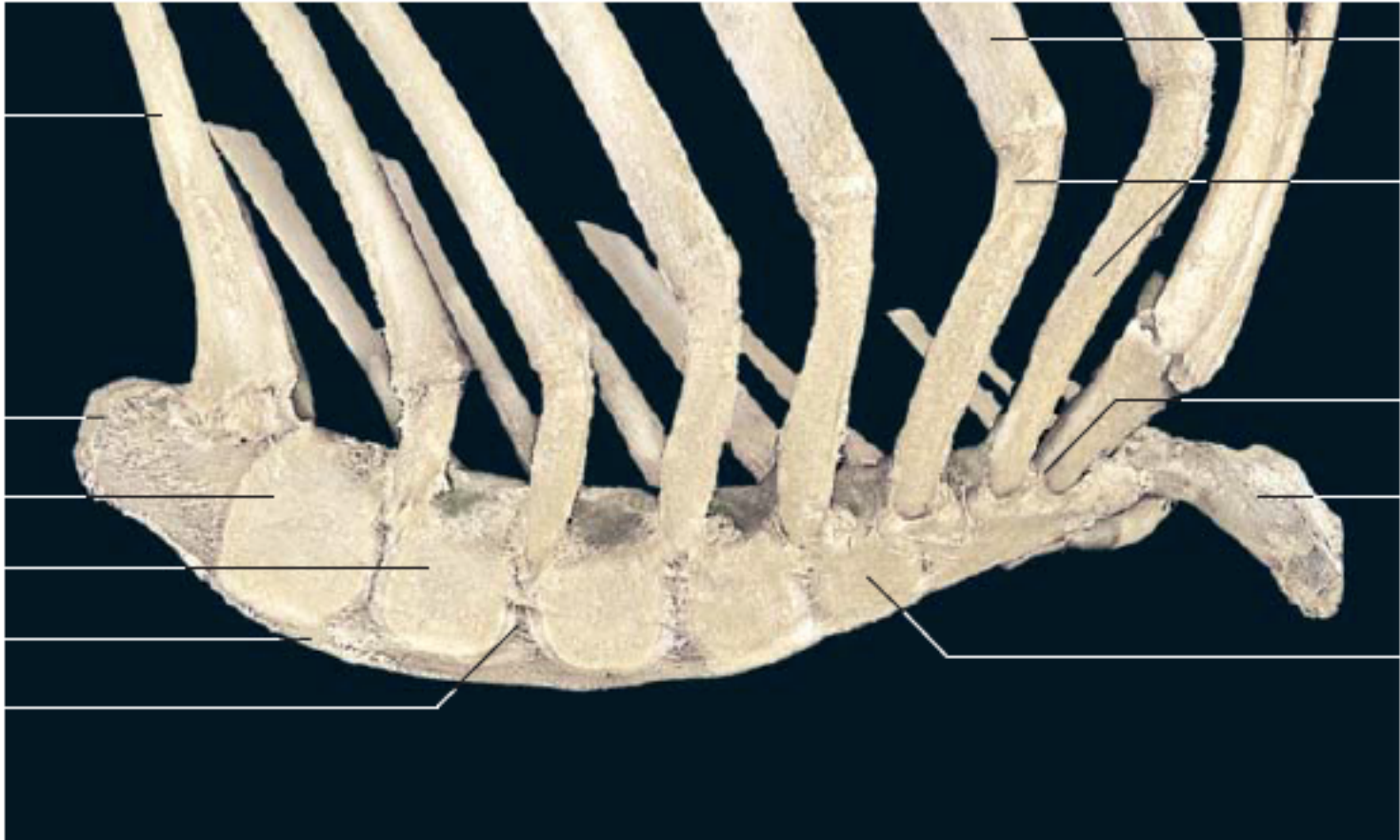


Costela (vista caudal).



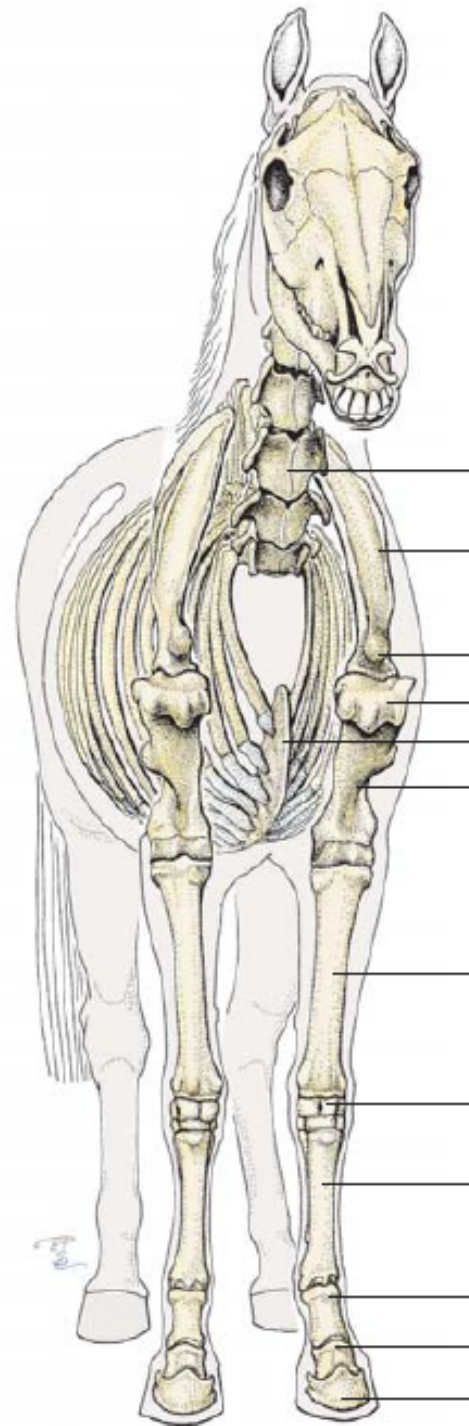
Esterno (vista ventral).

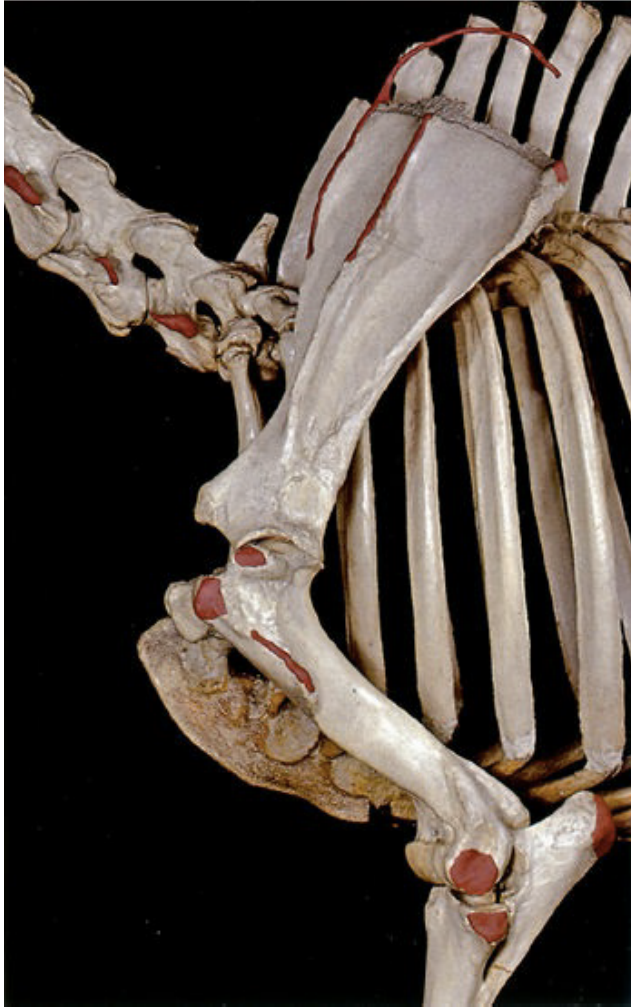



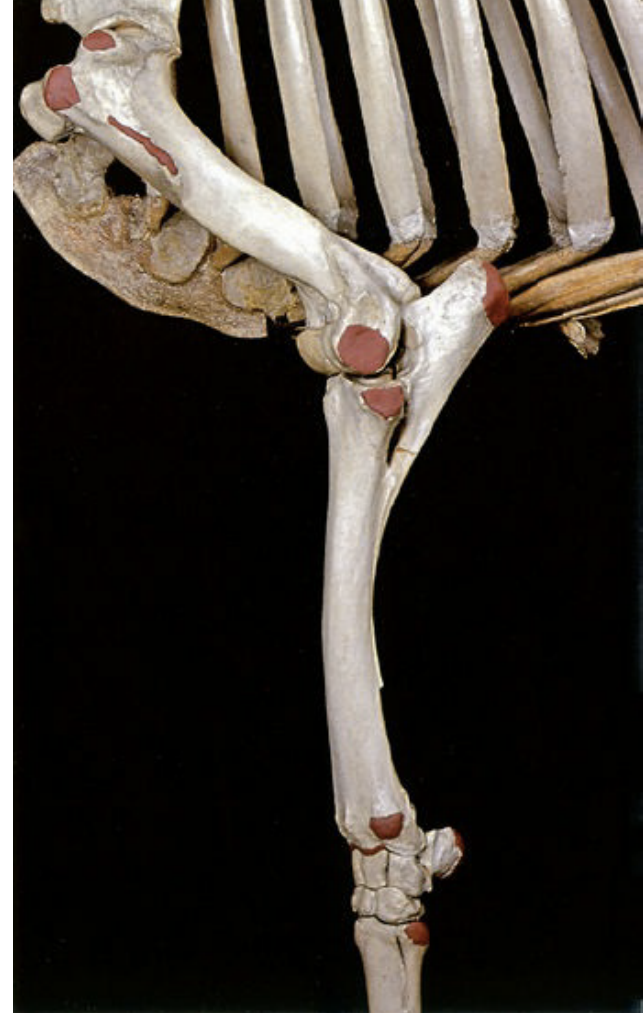Esterno (vista lateral).

# Membro Torácico

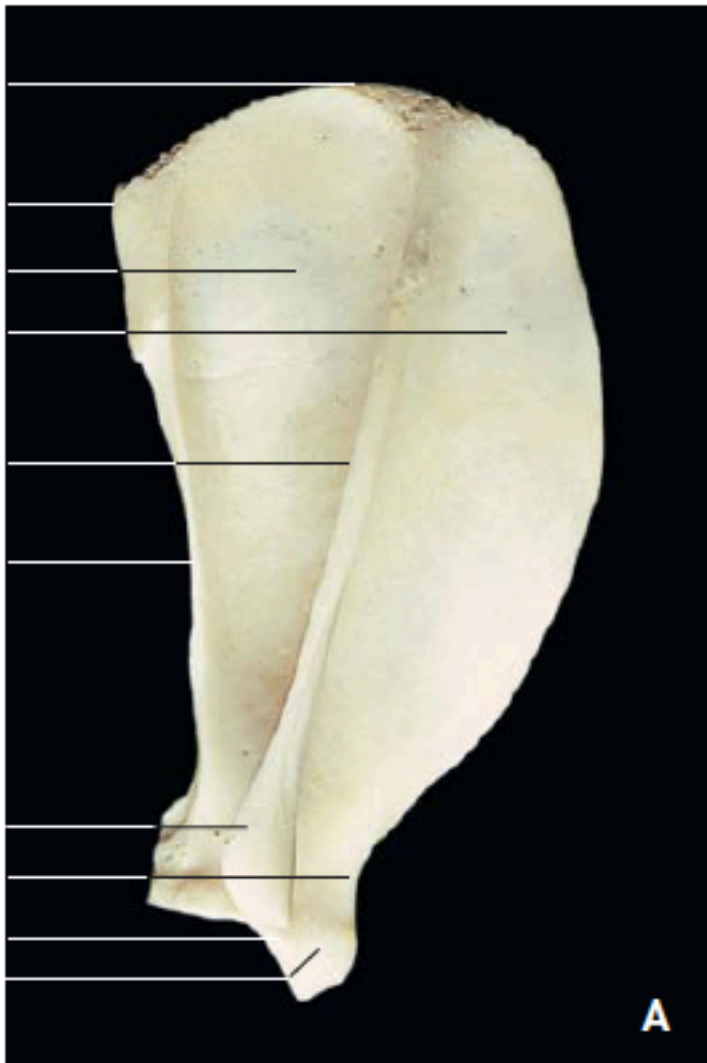




Ossos do membro torácico.  
Regiões escapular e braquial:  
vista lateral esquerda.



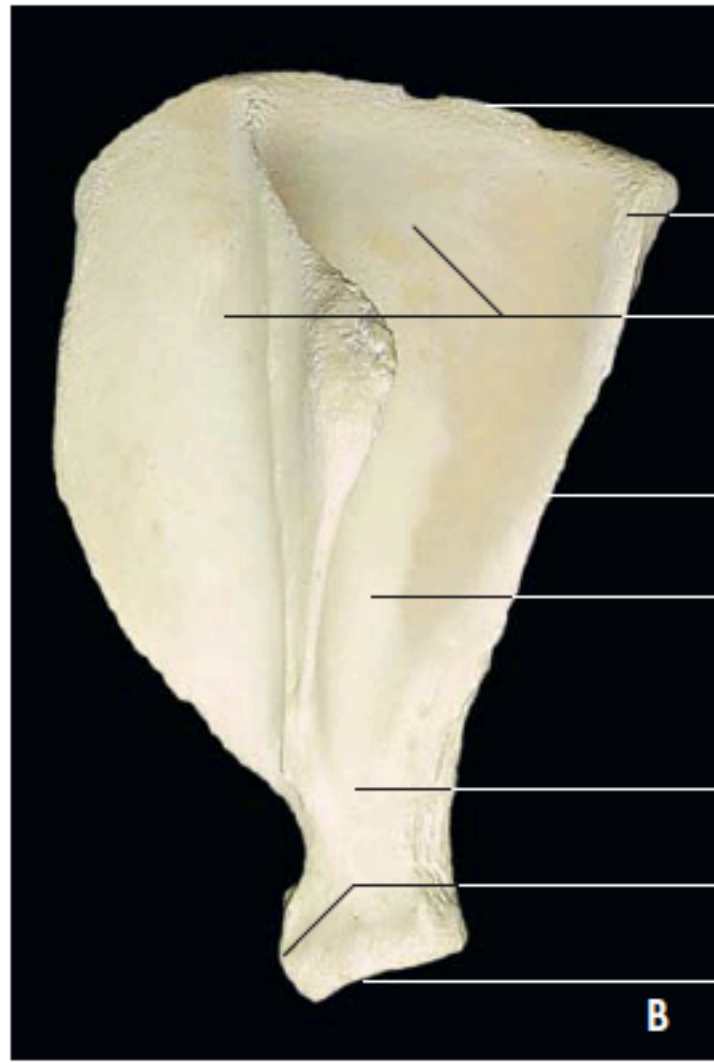
Ossos do membro torácico.  
Regiões braquial, antebraquial e  
do carpo: vista lateral esquerda.



**A**

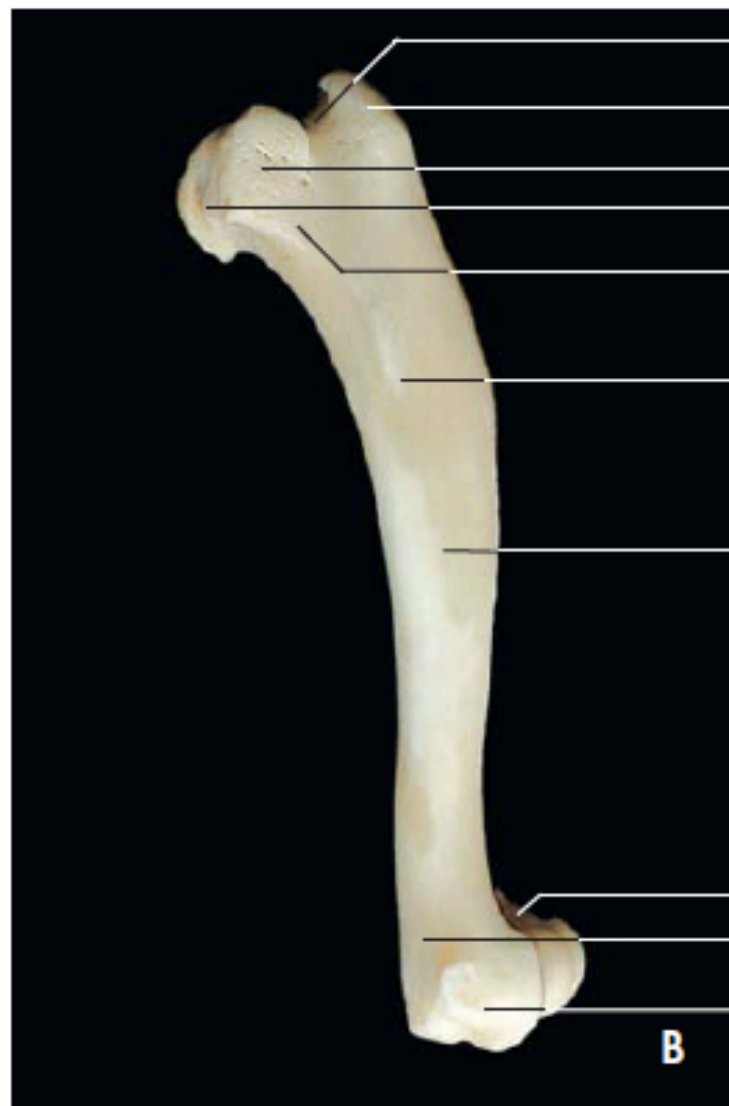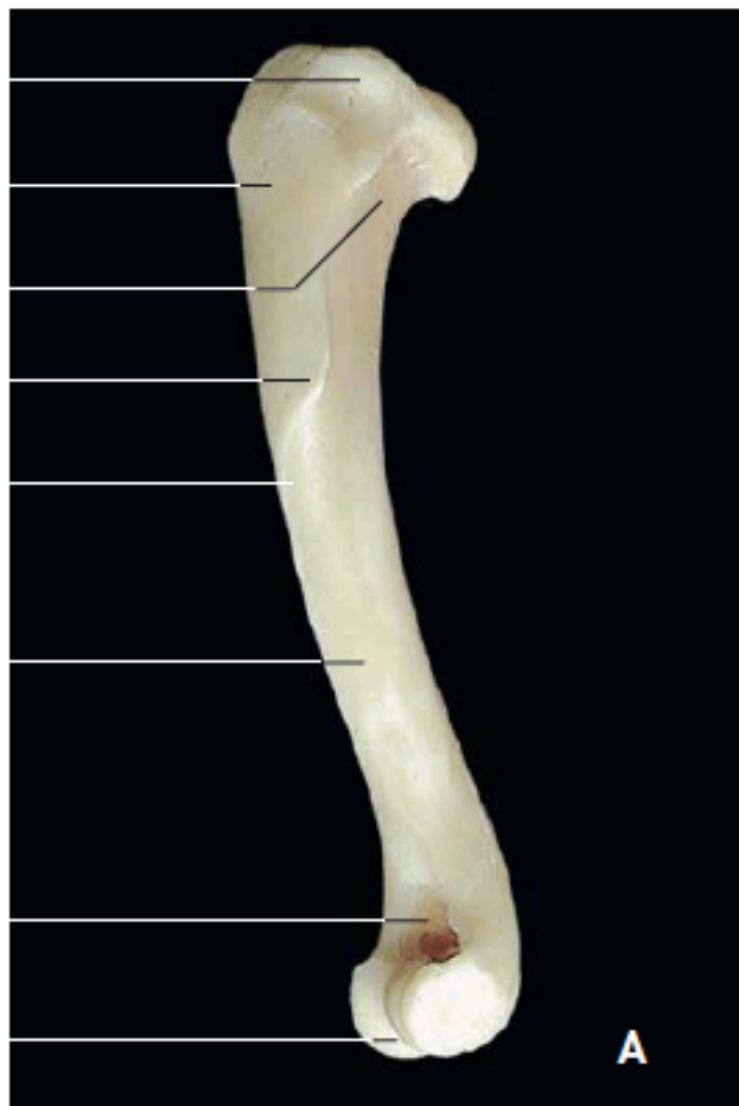
Escápula esquerda (A)

e

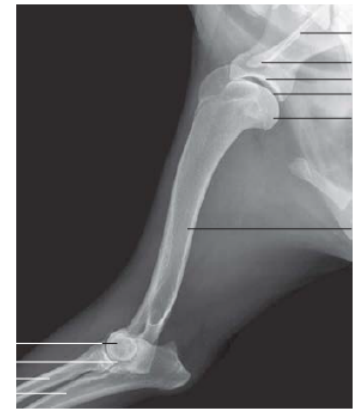

**B**

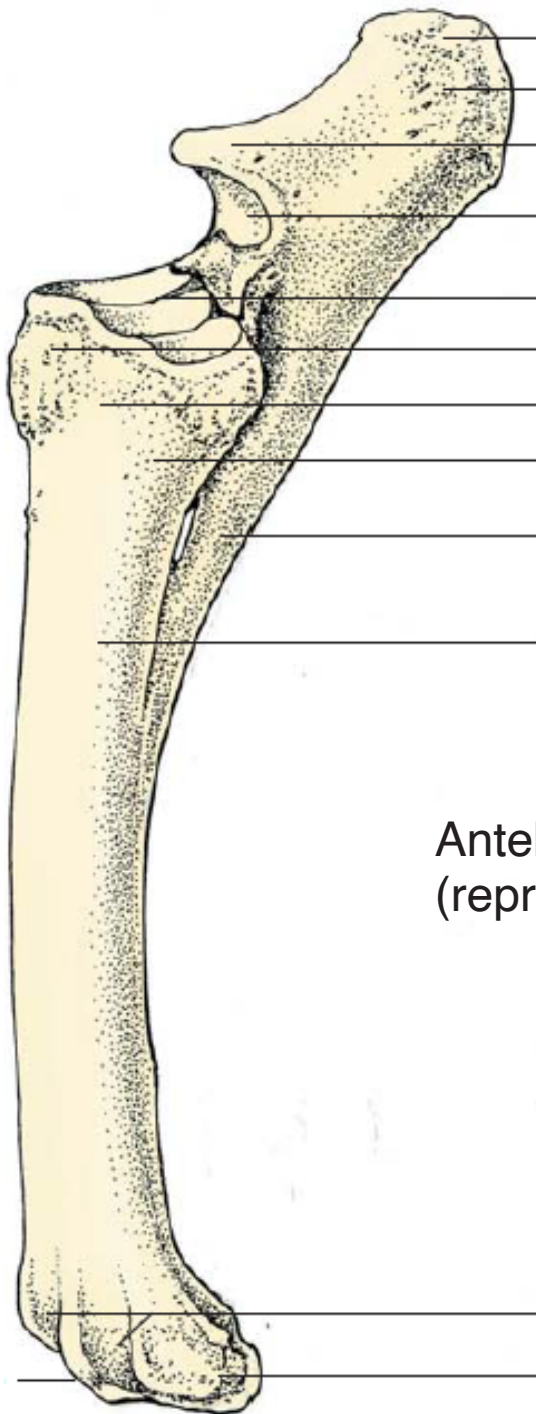
(B) (vista lateral).



Úmero izquierdo (A: vista lateral; B: vista medial).

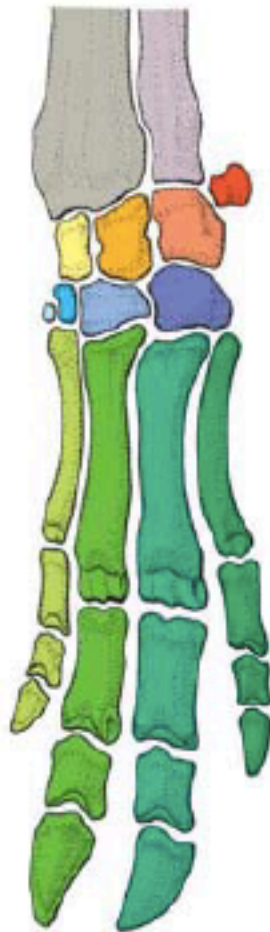



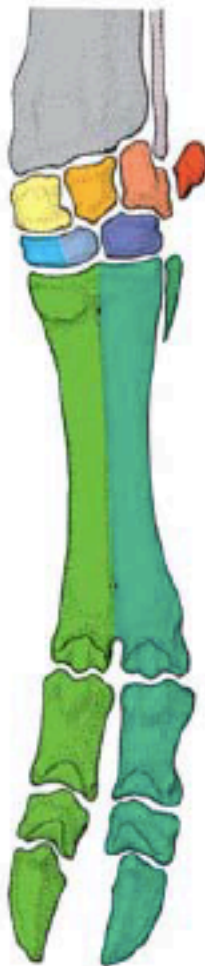


Antebraço esquerdo (rádio e ulna)  
(representação esquemática, vista craniolateral).

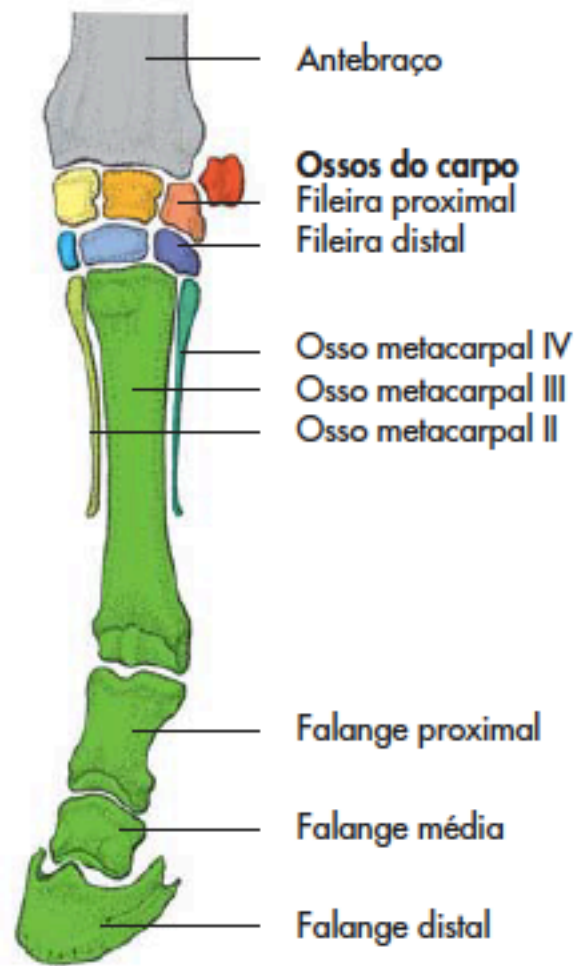




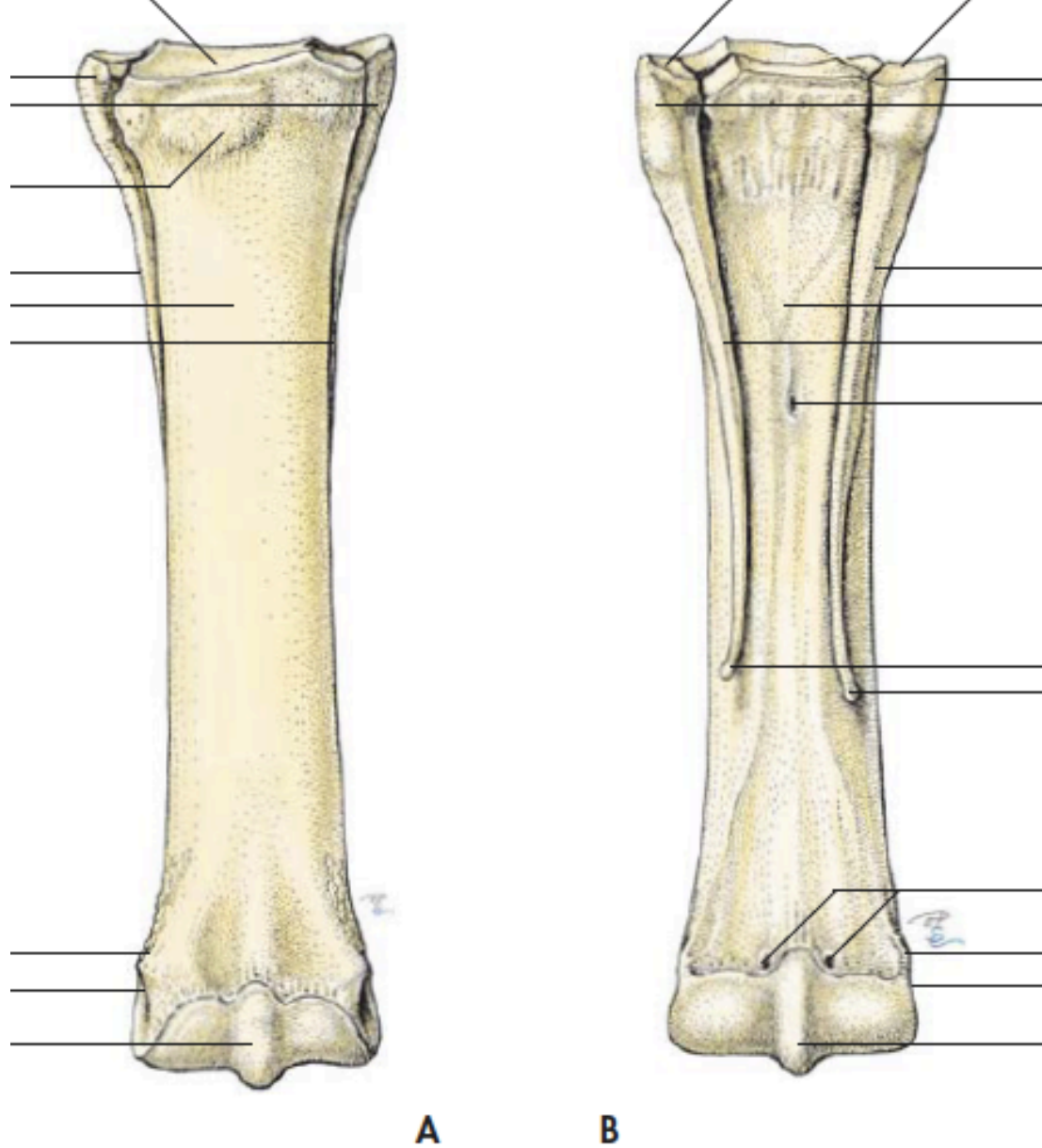
Suíno



Bovino

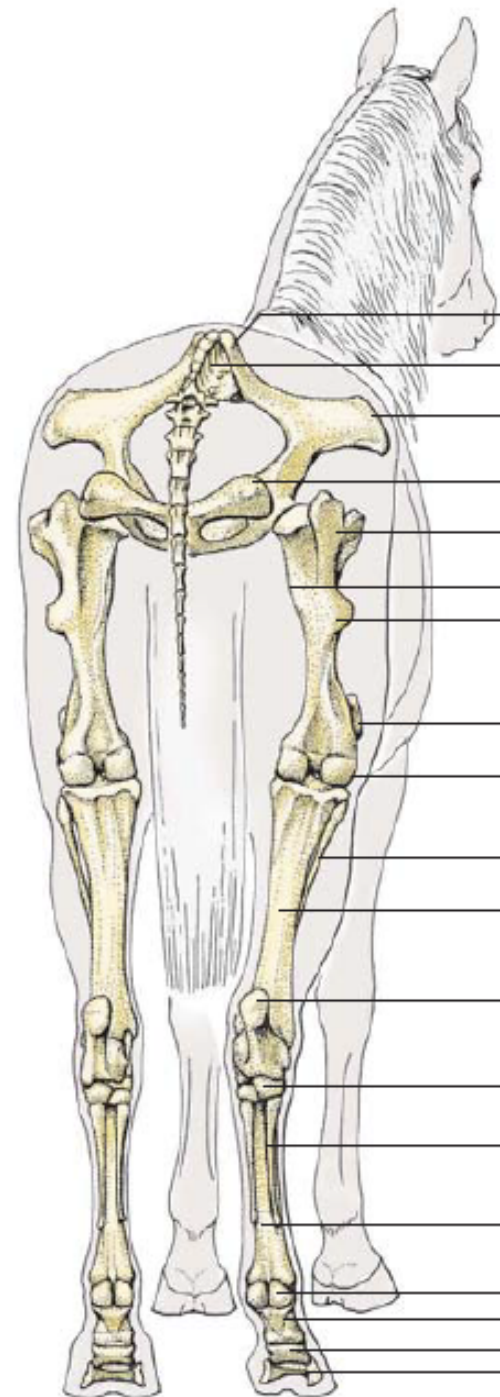


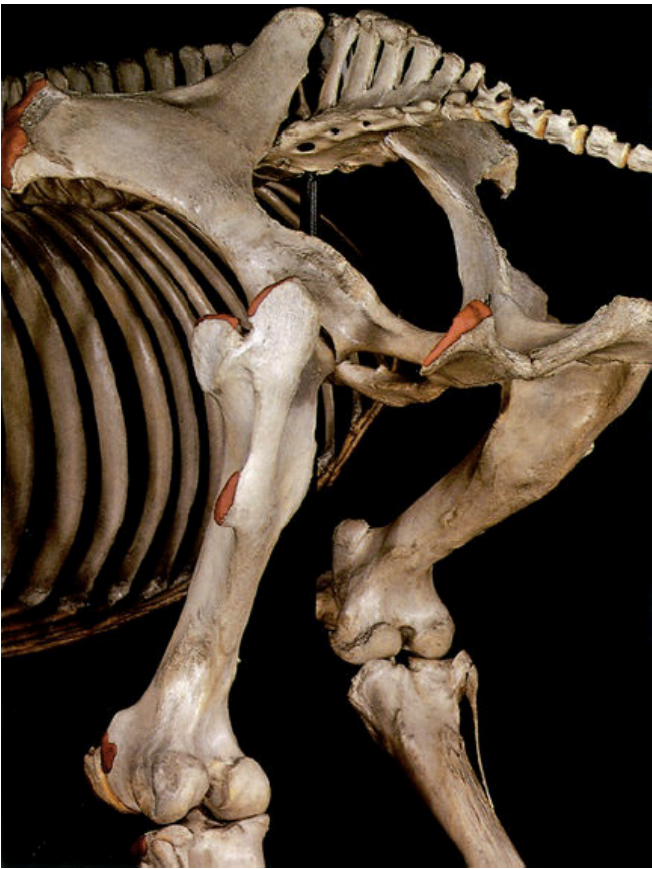Equino



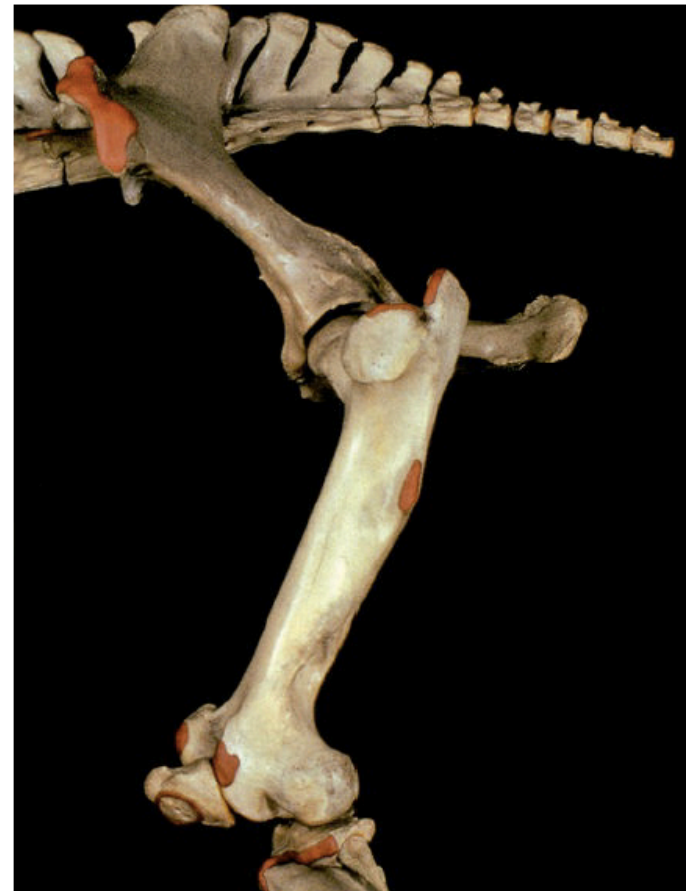Ossos metacarpais esquerdos (representação esquemática, A: vista dorsal; B: vista palmar).

# Membro Pélvico

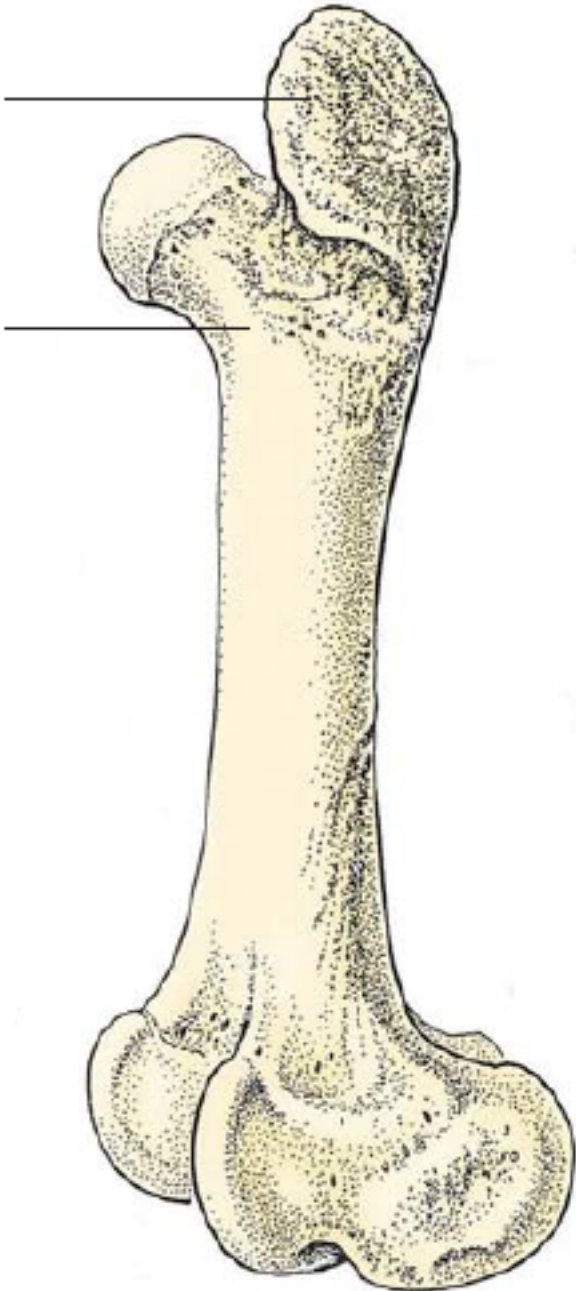




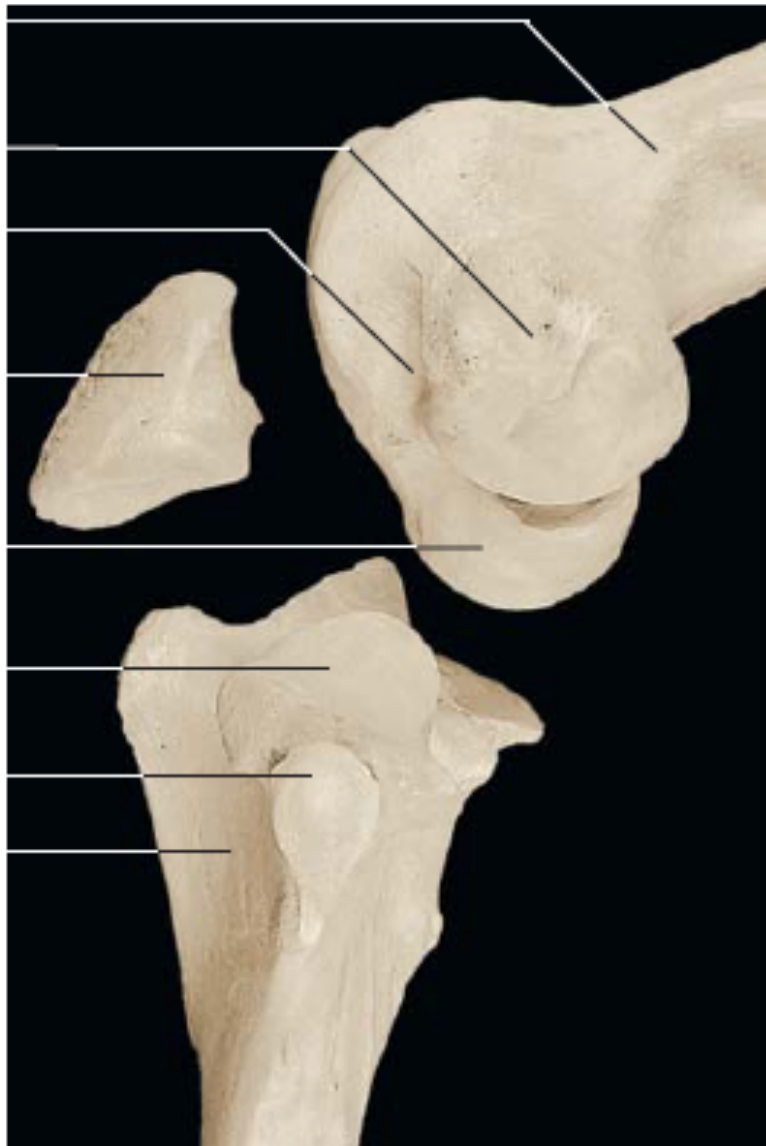Ossos das regiões da pelve e do fêmur: vista caudolateral esquerda.



Ossos das regiões da pelve e do fêmur: vista lateral esquerda.

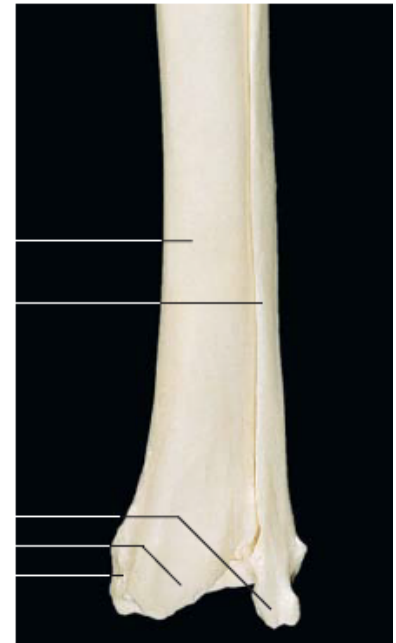
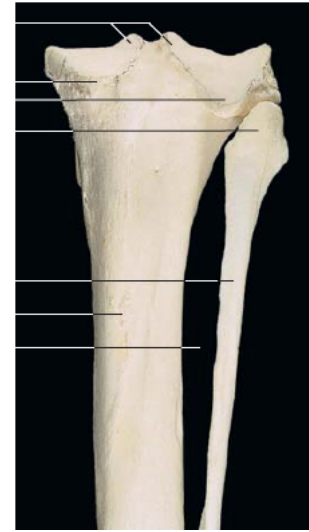
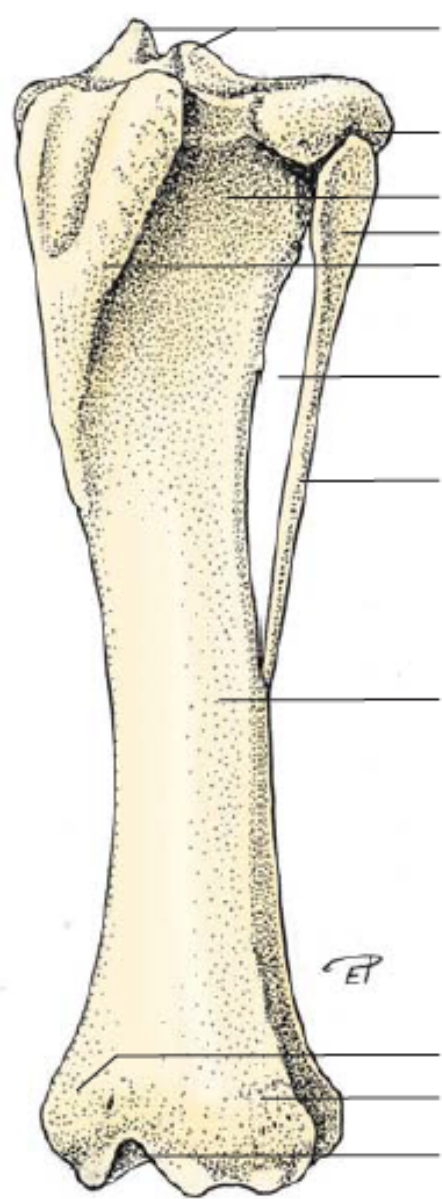


Fêmur (representação esquemática, vista craniolateral).

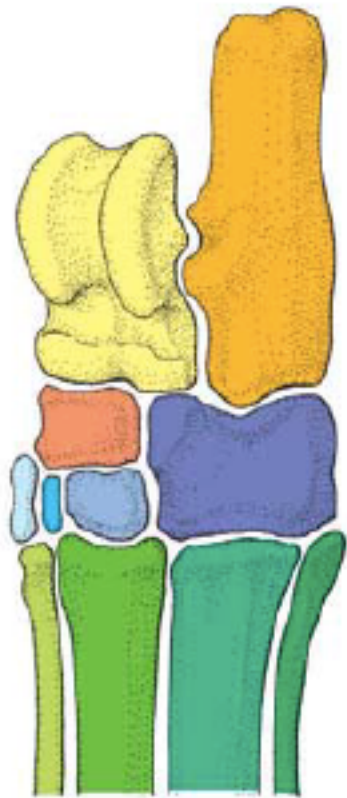


Extremidade distal do fêmur esquerdo, patela e extremidade proximal da tíbia (vista lateral).

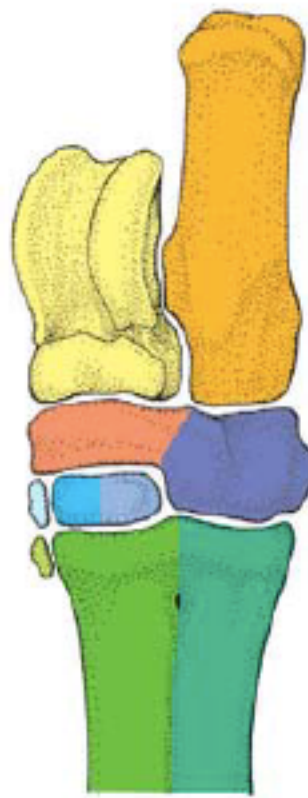



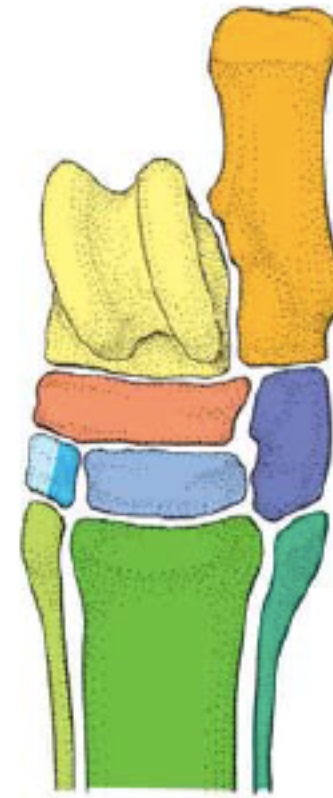Tíbia e fíbula esquerdas (representação esquemática, vista craniolateral).



Suíno

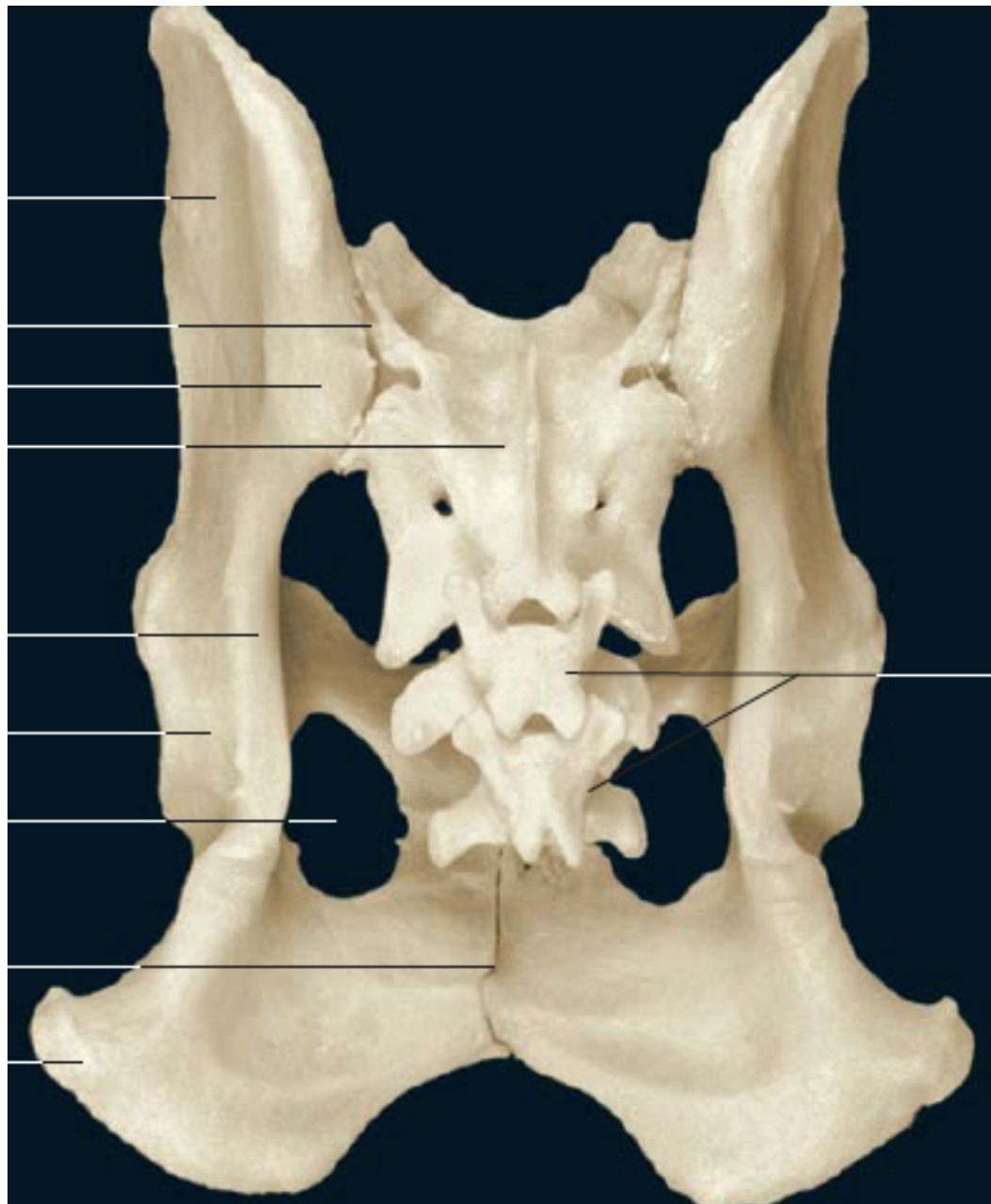


Bovino

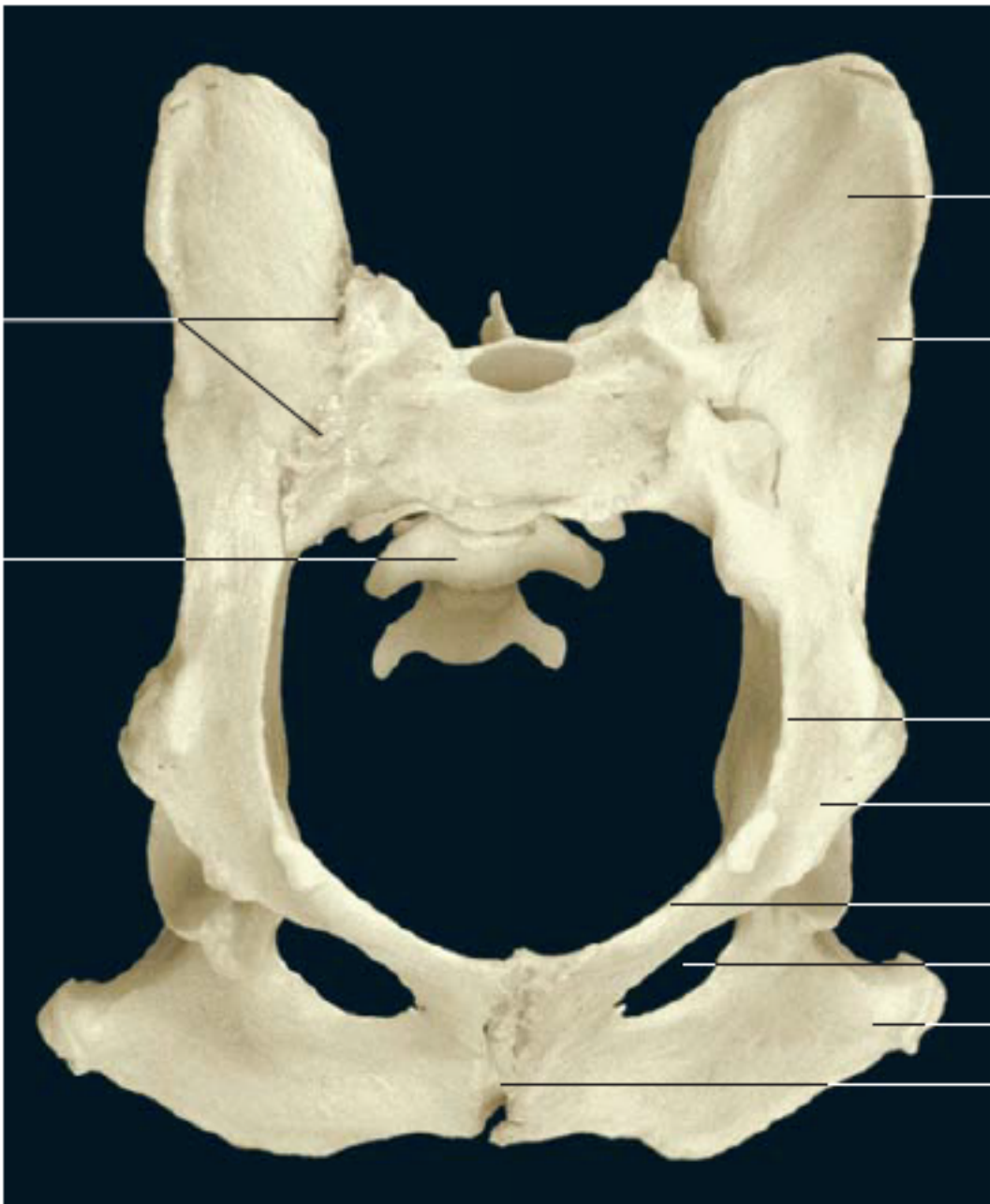

Equino

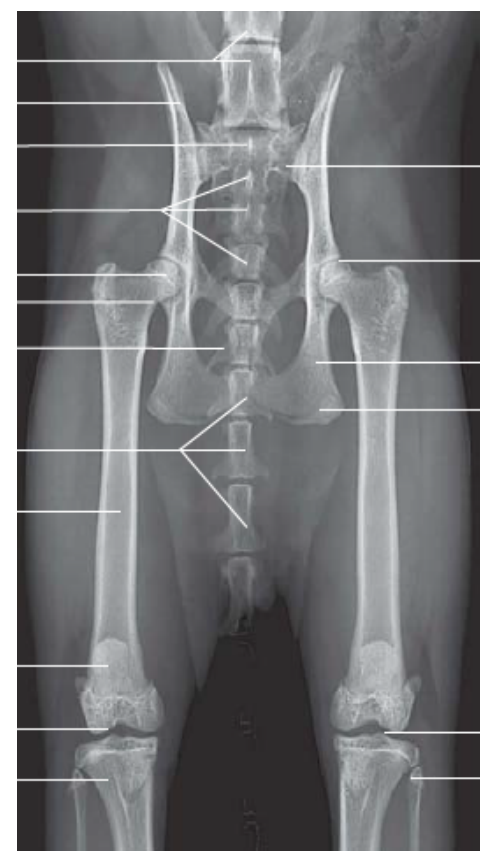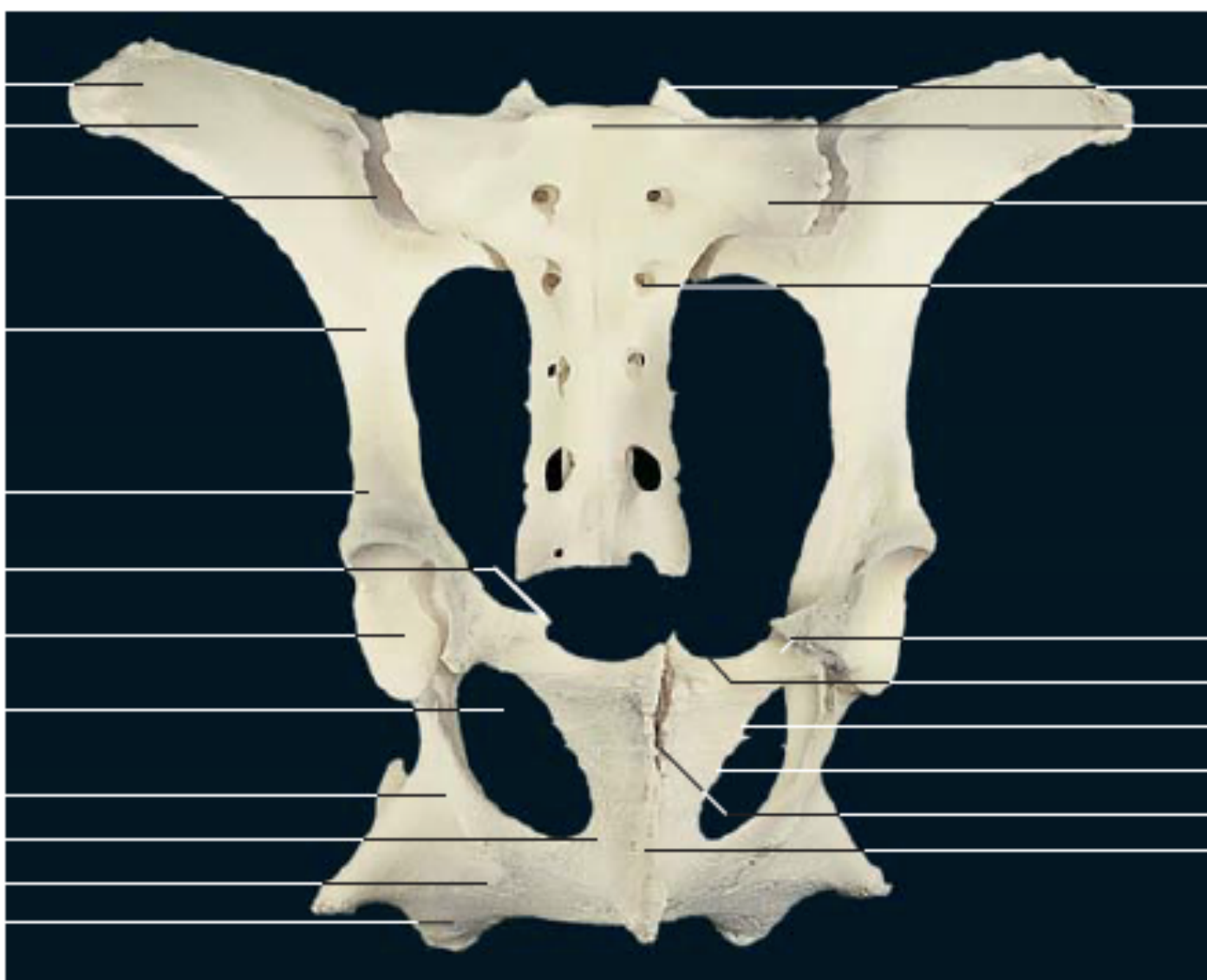
Esqueleto do tarso nos mamíferos domésticos (representação esquemática),



Ossos coxais (vista caudodorsal).



Ossos coxais (vista cranioventral).



Ossos coxais e sacro (vista ventrocranial).