



Faculdade de Odontologia de Ribeirão Preto
Universidade de São Paulo

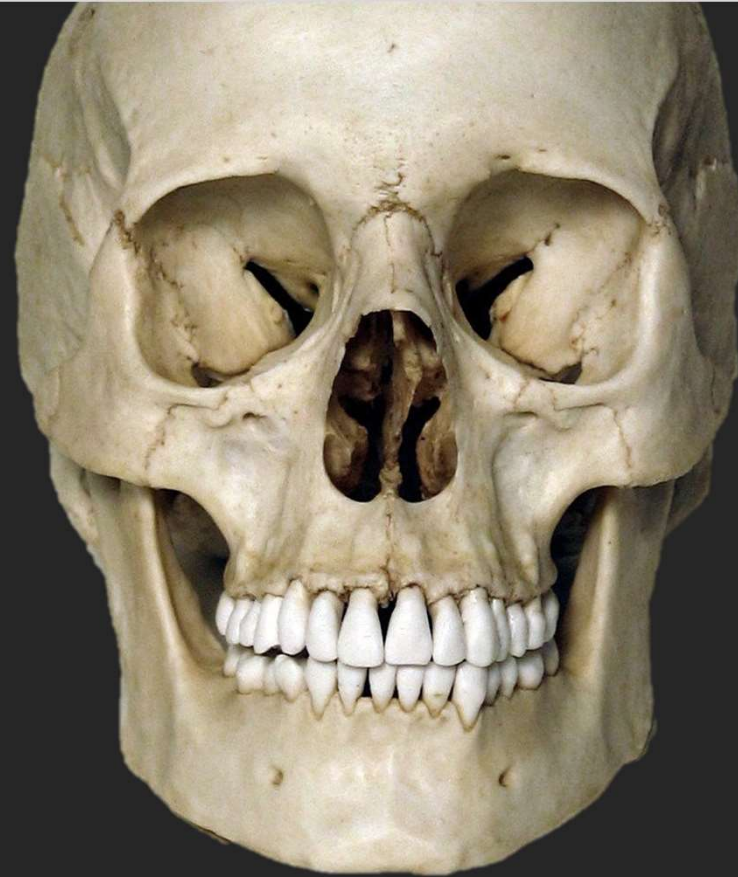

Radiologia Básica

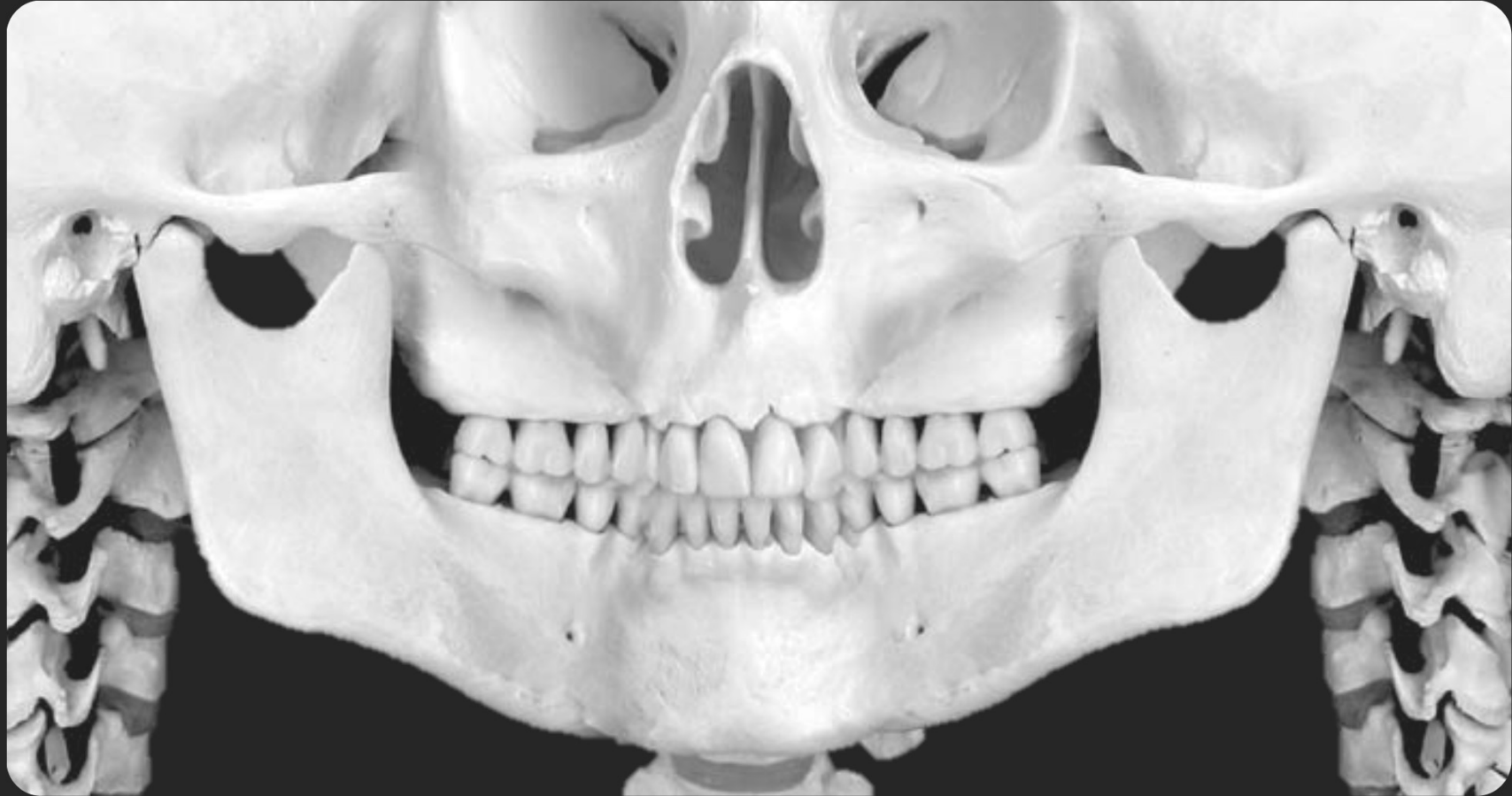ANATOMIA RADIOGRÁFICA PANORÂMICA

Hugo Gaêta Araujo

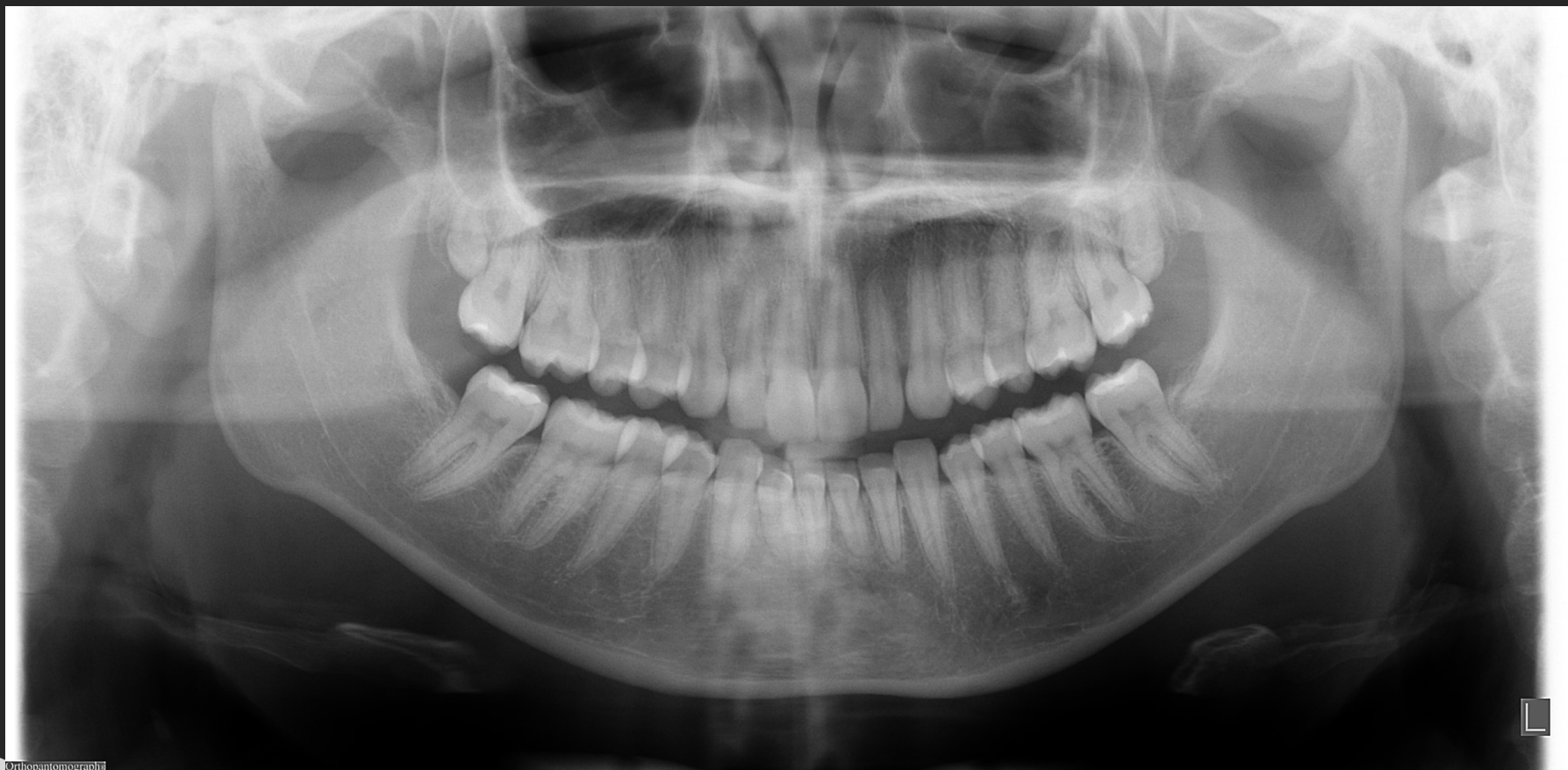RADIOGRAFIA PANORÂMICA



RADIOGRAFIA PANORÂMICA



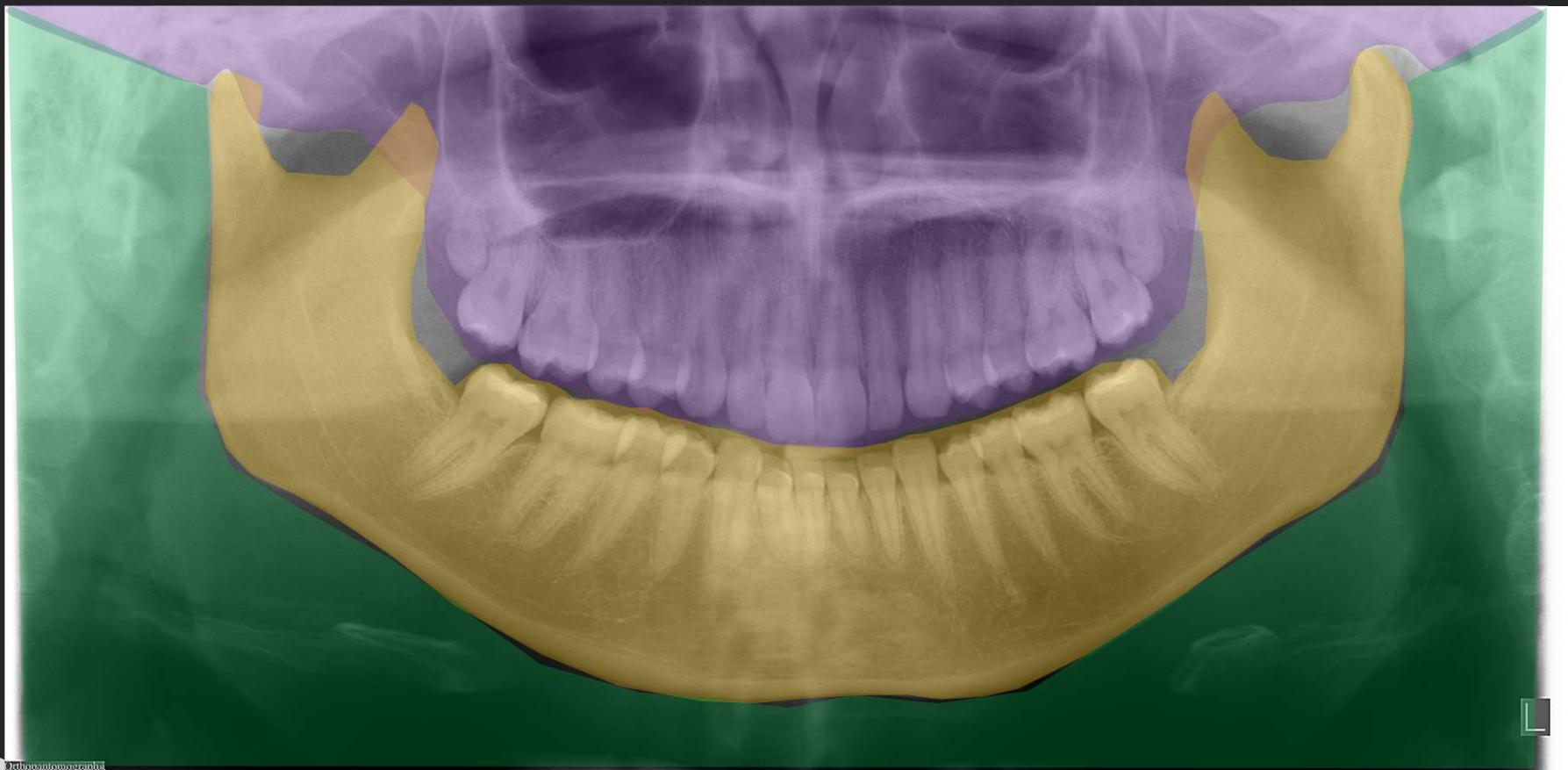
RADIOGRAFIA PANORÂMICA



Orthopantomograph

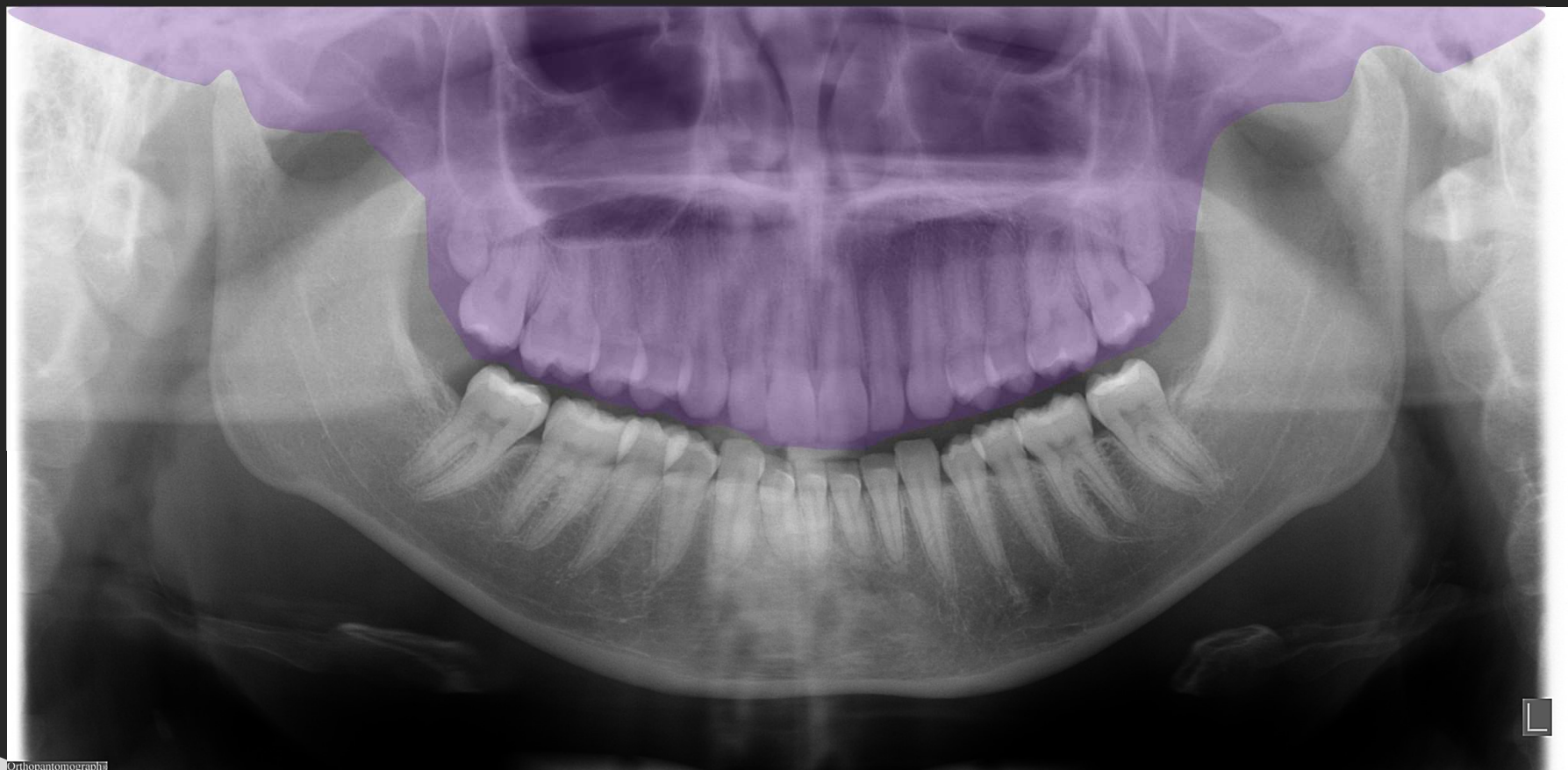

RADIOGRAFIA PANORÂMICA



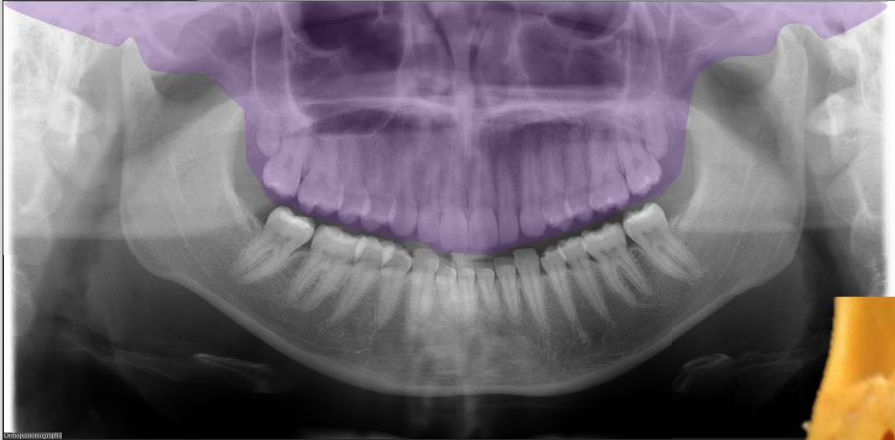02/05/2023 10:00:00

RADIOGRAFIA PANORÂMICA

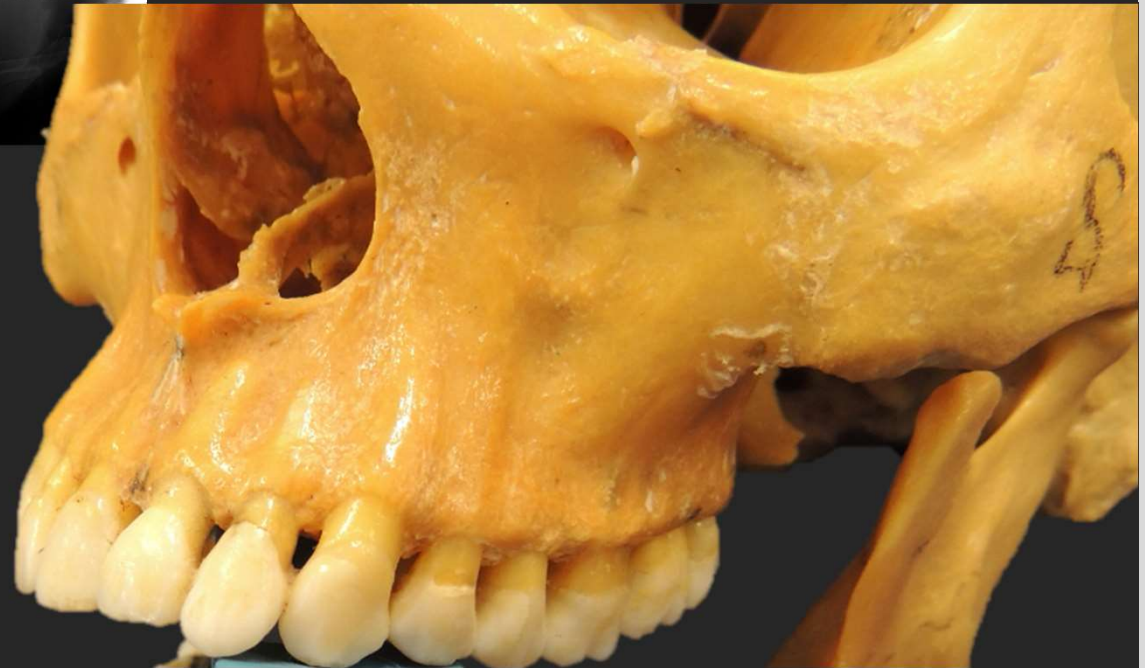

Orthopantomograph

RADIOGRAFIA PANORÂMICA

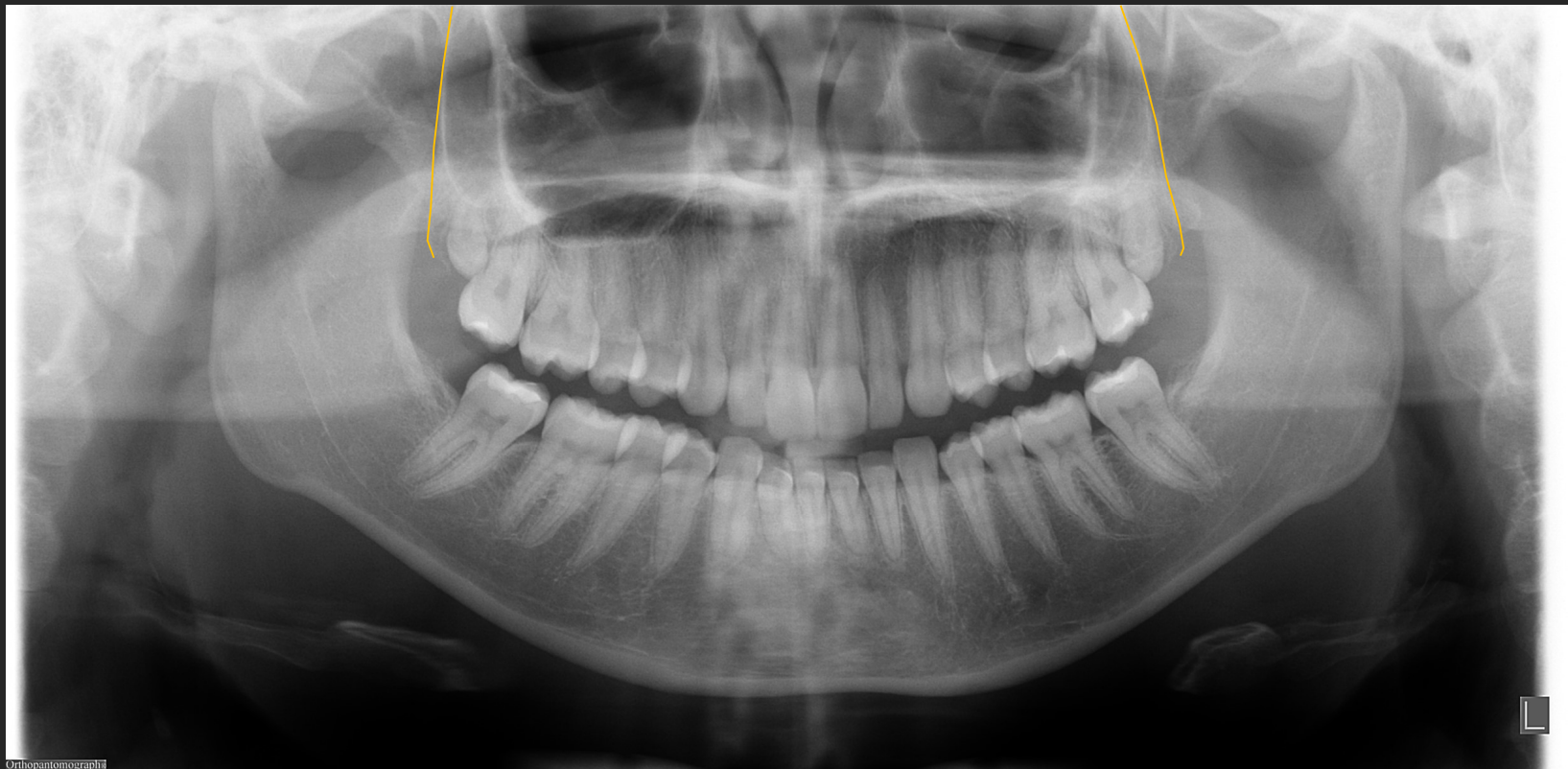


Terço Médio da Face



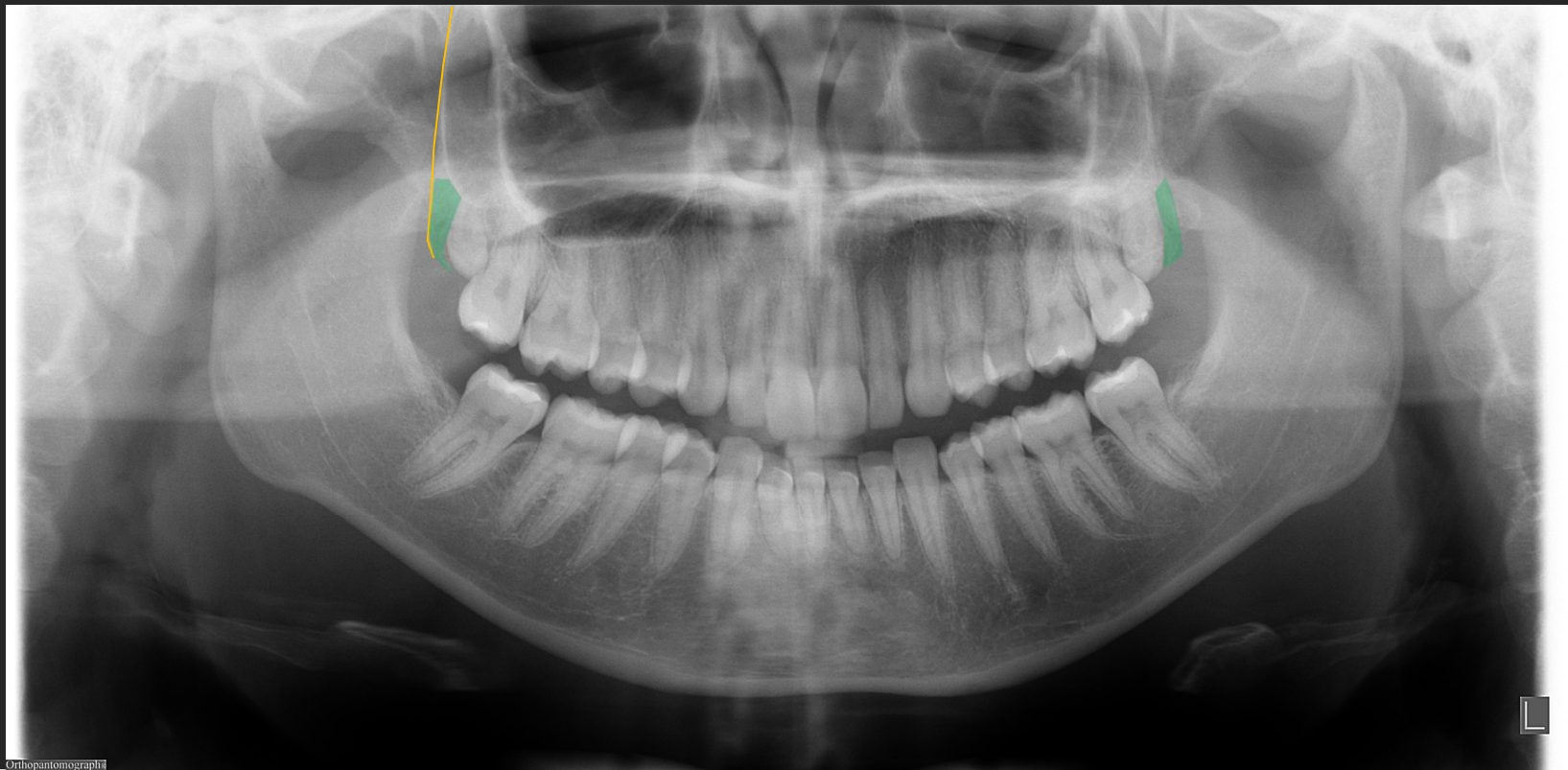
RADIOGRAFIA PANORÂMICA

- Borda posterior da maxila



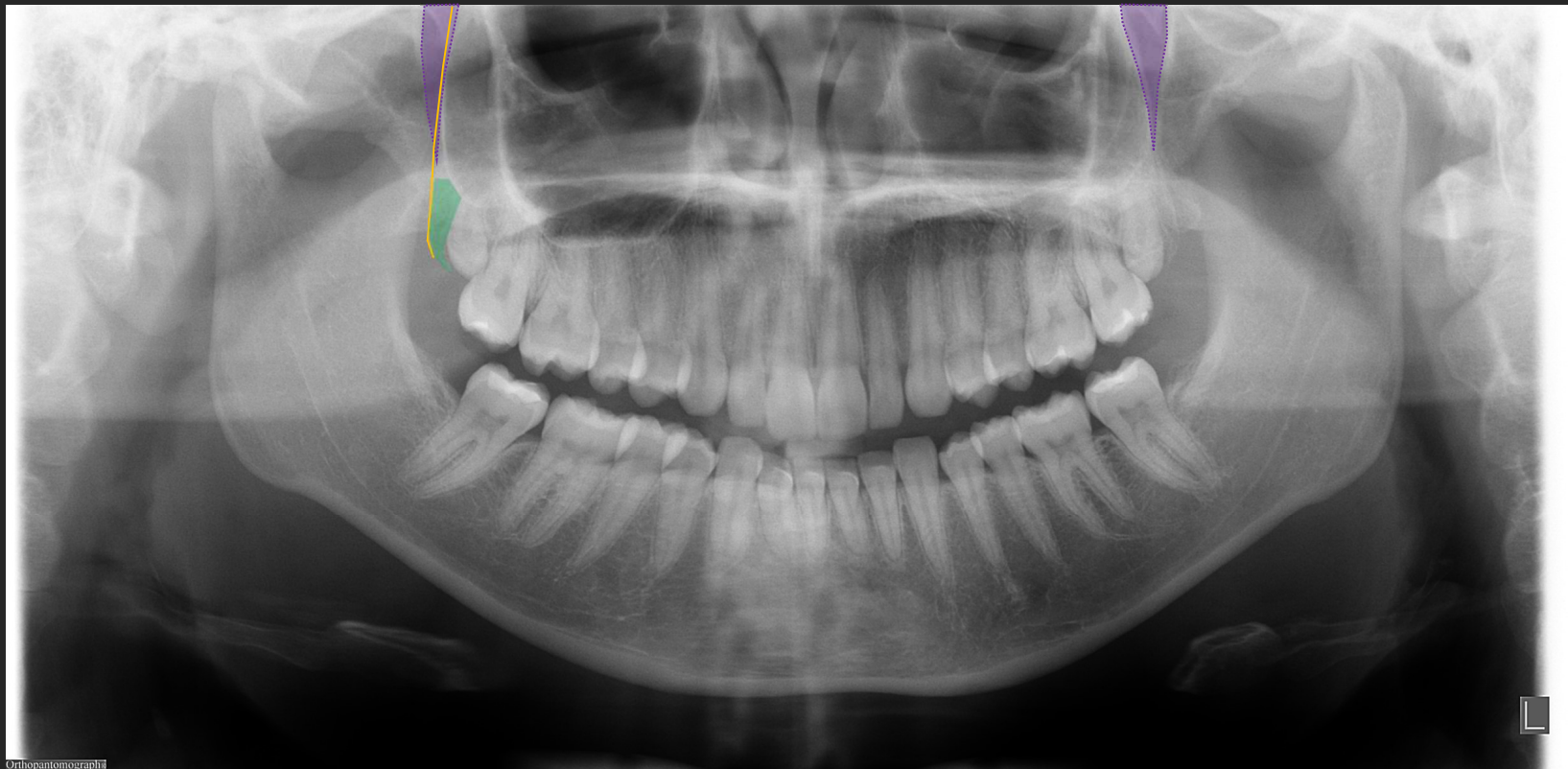
RADIOGRAFIA PANORÂMICA

- Borda posterior da maxila
- Túber/tuberosidade da maxila



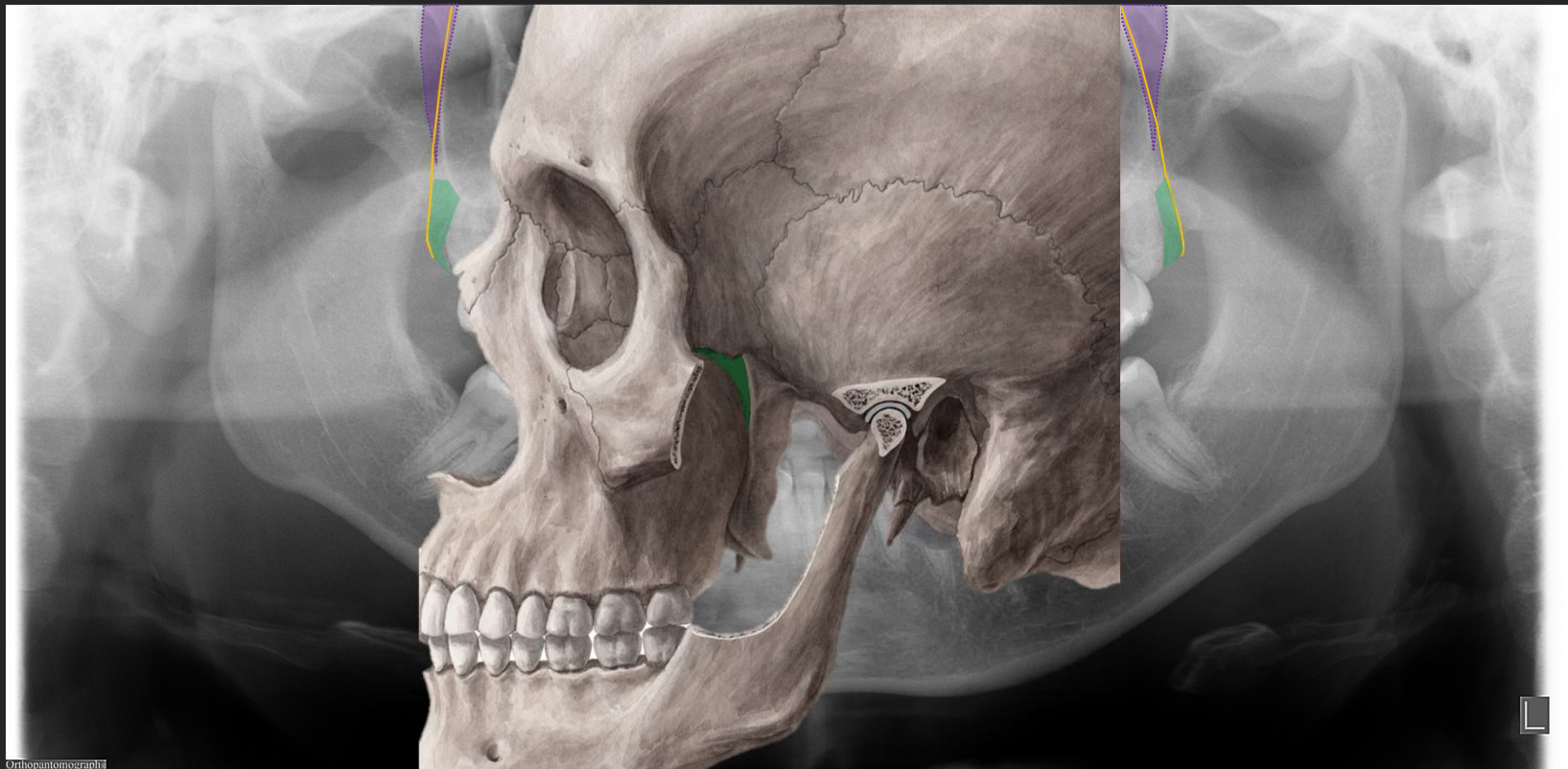
RADIOGRAFIA PANORÂMICA

- Borda posterior da maxila
- Túber/tuberosidade da maxila
- Fissura pterigomaxilar



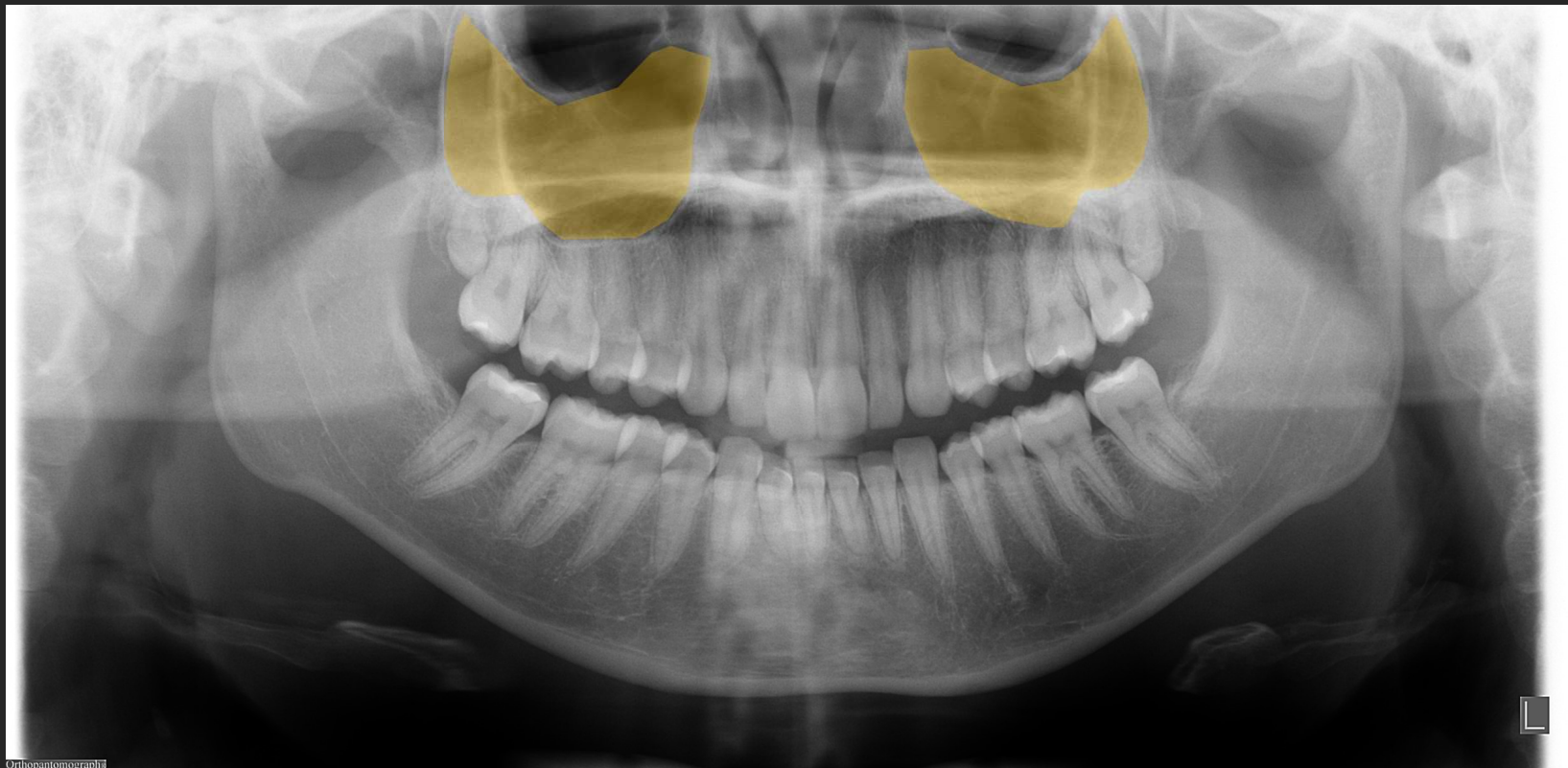
RADIOGRAFIA PANORÂMICA

- Borda posterior da maxila
- Túber/tuberosidade da maxila
- Fissura pterigomaxilar



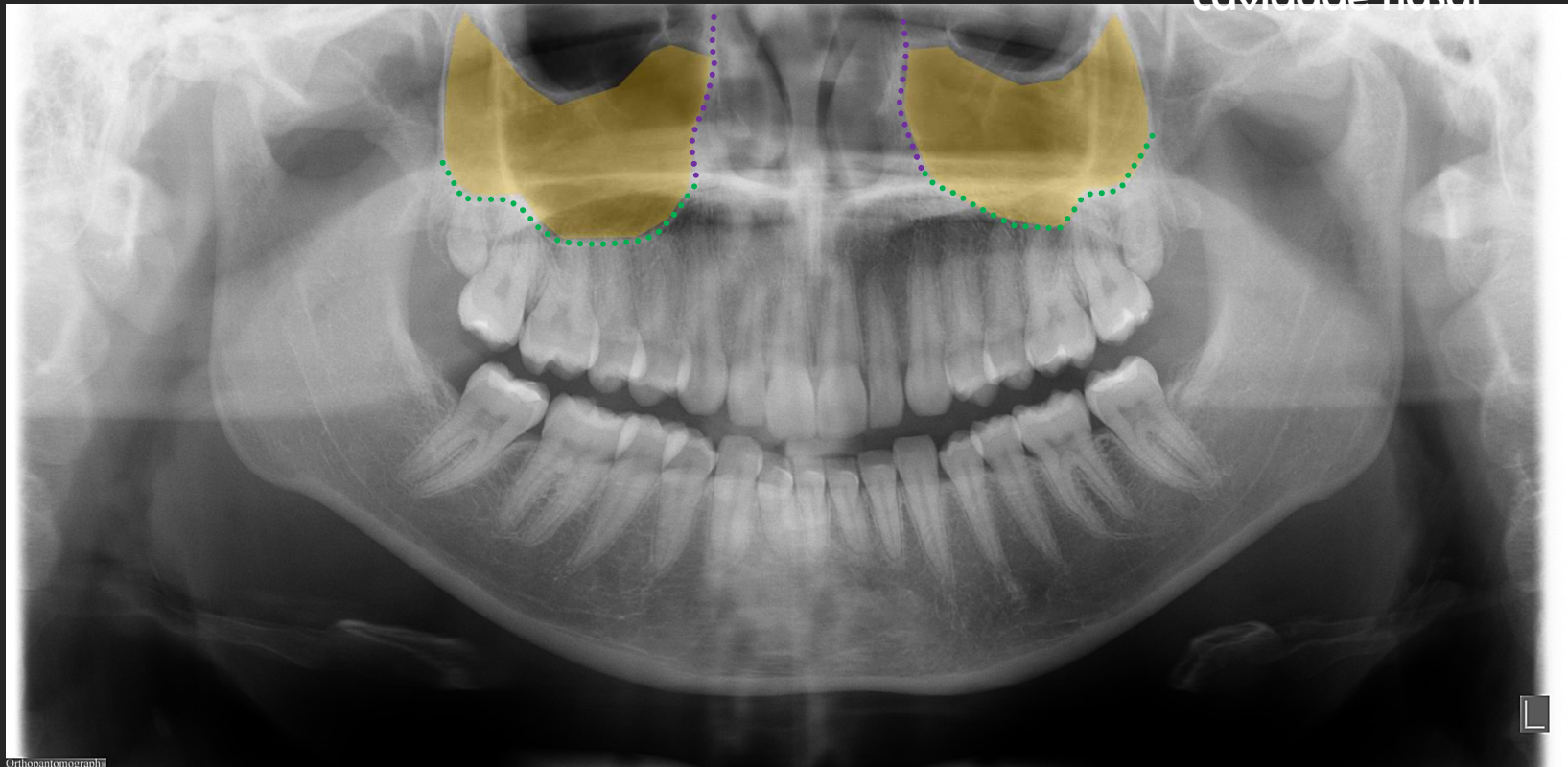
RADIOGRAFIA PANORÂMICA

- Seios maxilares



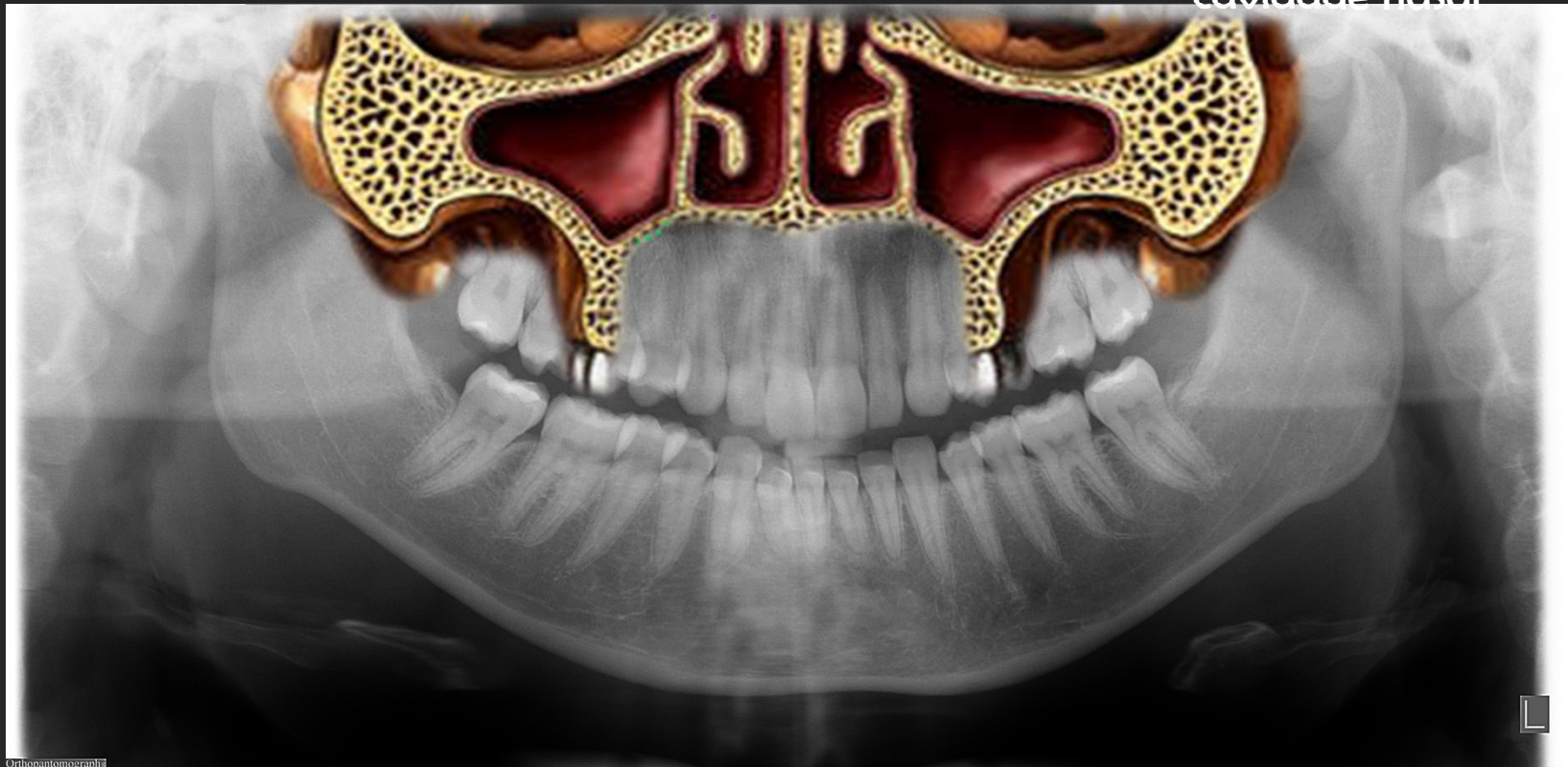RADIOGRAFIA PANORÂMICA

- Seios maxilares
- Assoalho do seio maxilar
- Parede medial do seio maxilar/lateral da cavidade nasal



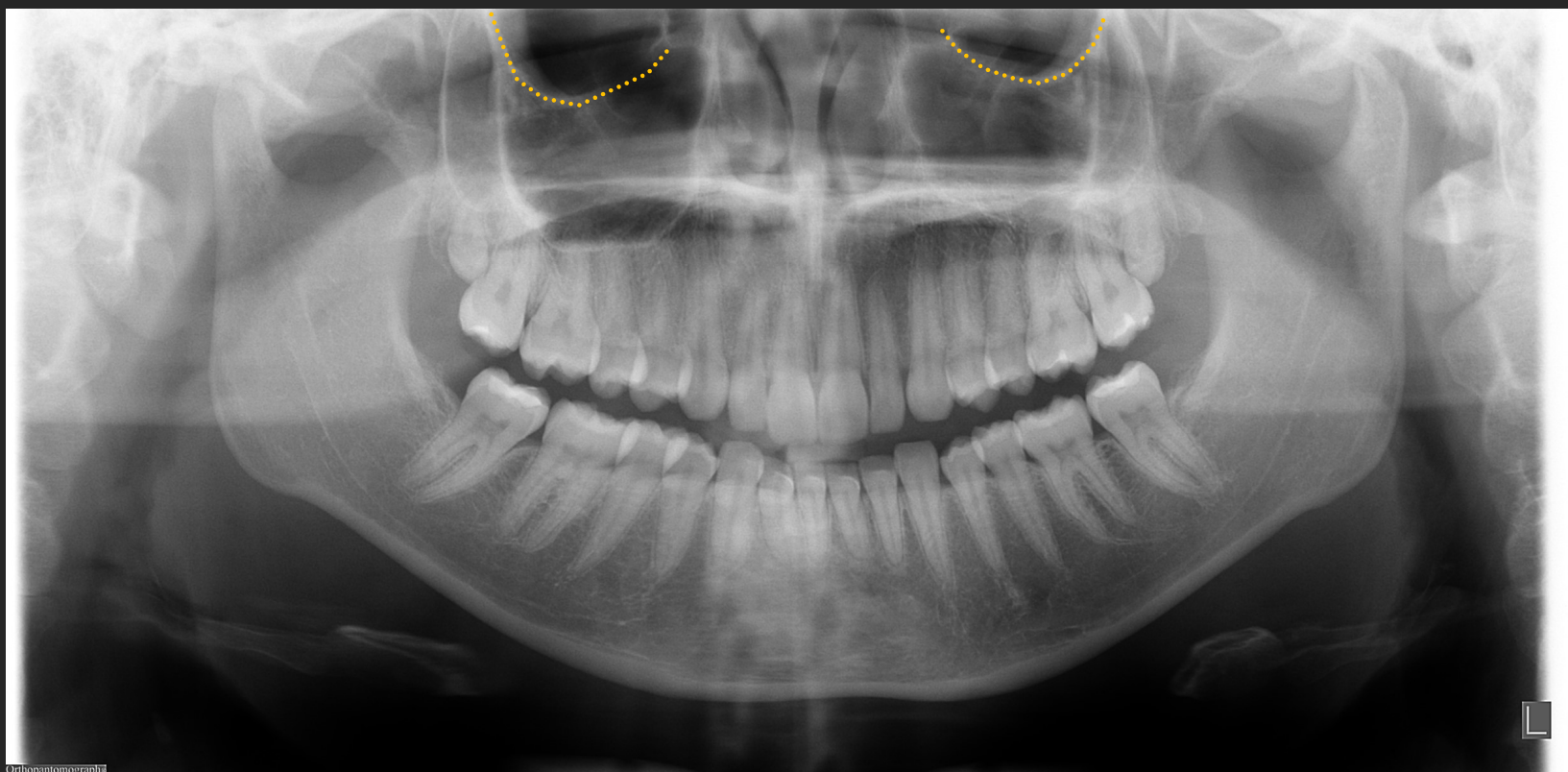
RADIOGRAFIA PANORÂMICA

- Seios maxilares
- Assoalho do seio maxilar
- Parede medial do seio maxilar/lateral da cavidade nasal



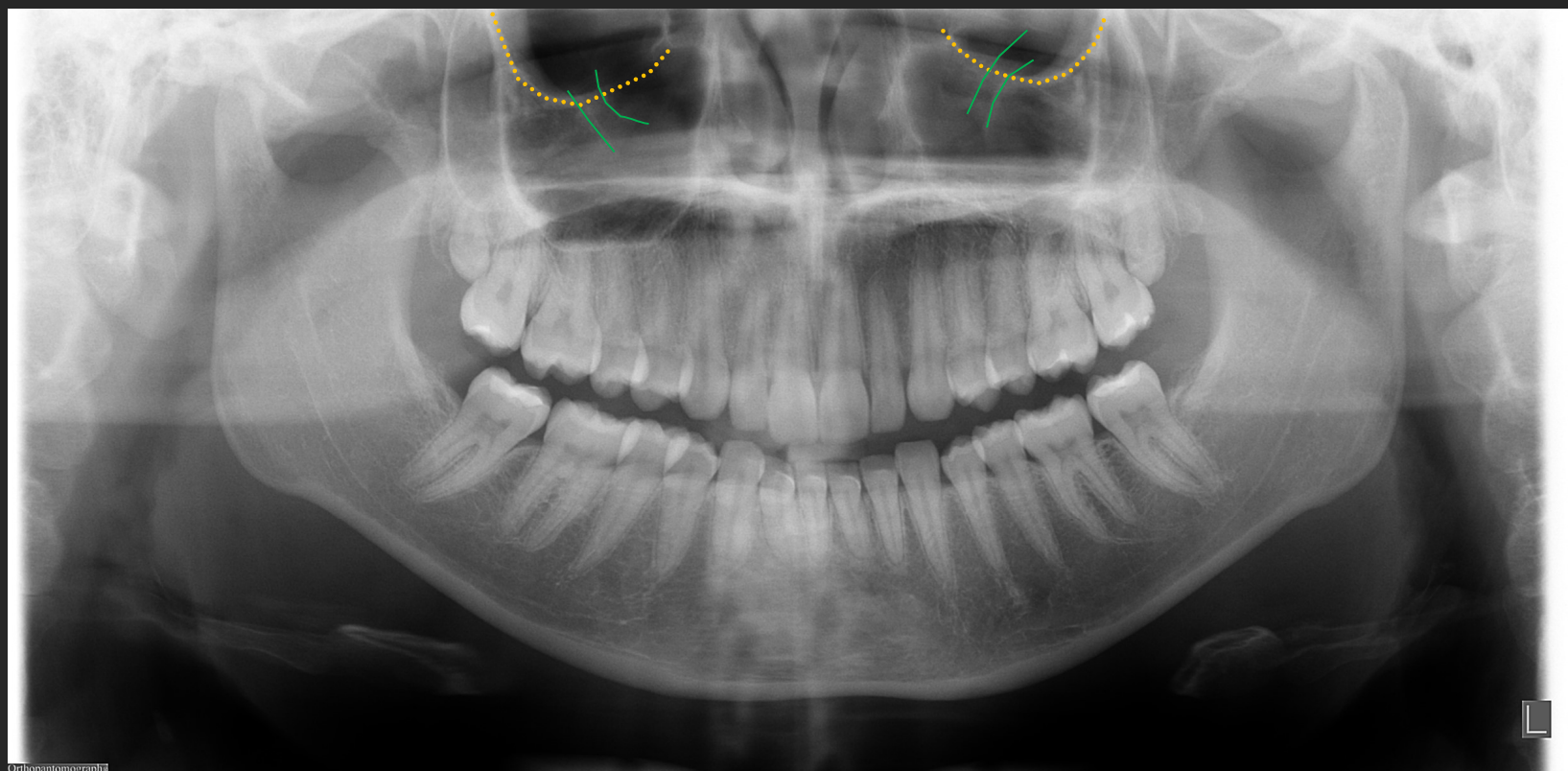
RADIOGRAFIA PANORÂMICA

- Assoalho da órbita



RADIOGRAFIA PANORÂMICA

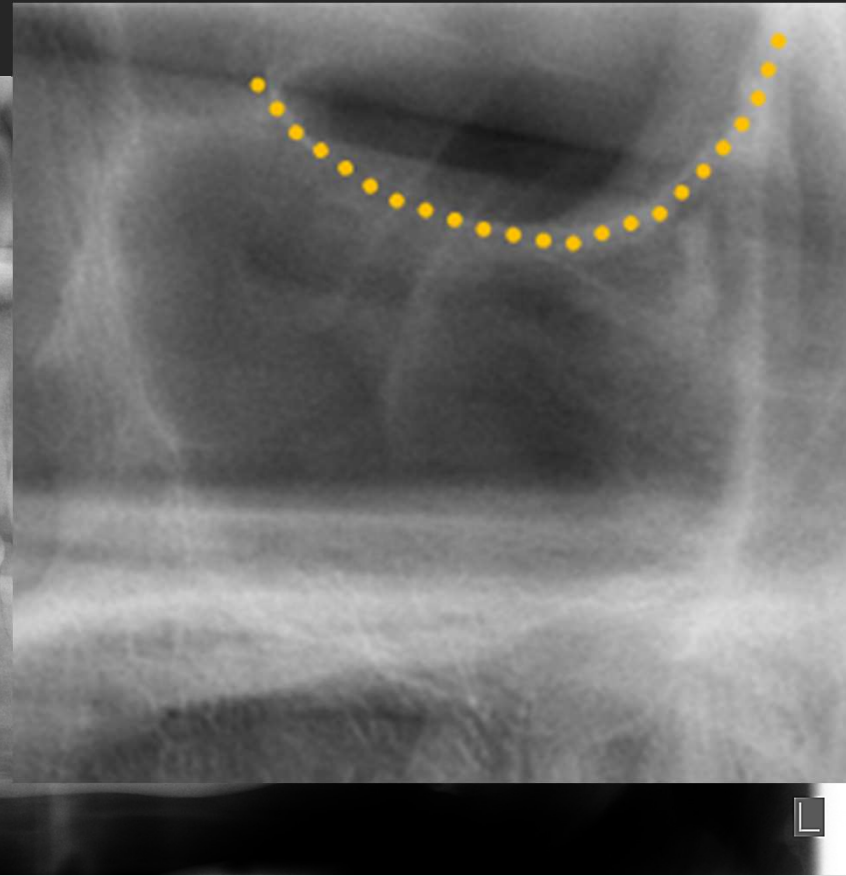
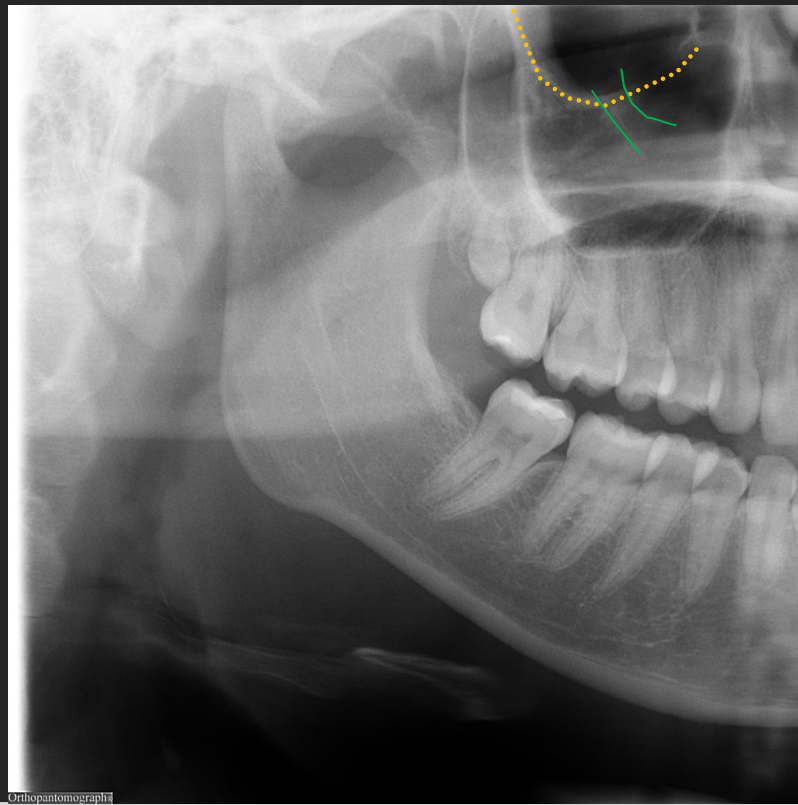
- Assoalho da órbita
- Canal infraorbital



RADIOGRAFIA PANORÂMICA

- Assoalho da órbita

- Canal infraorbital

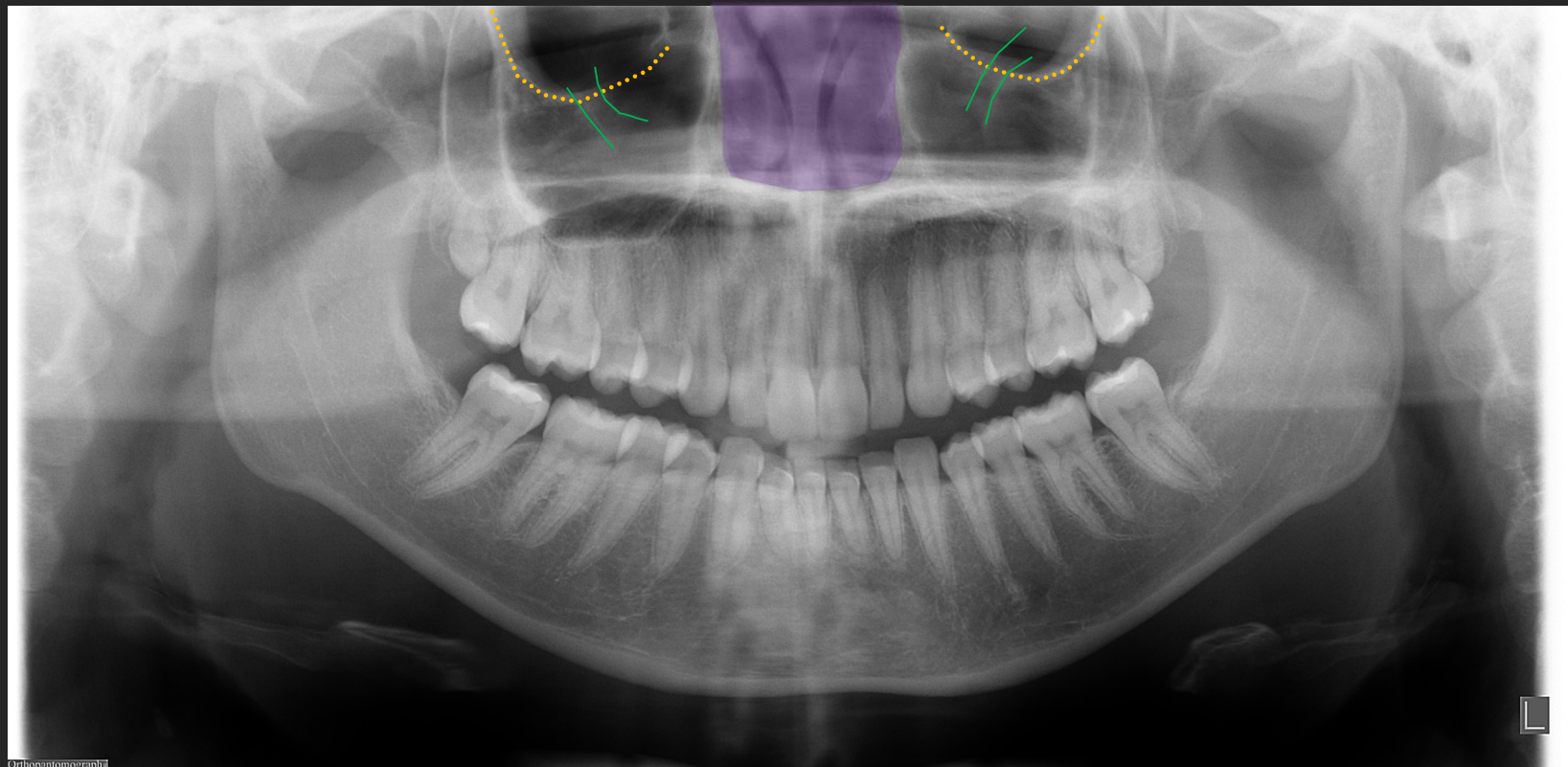


Orthopantomograph



RADIOGRAFIA PANORÂMICA

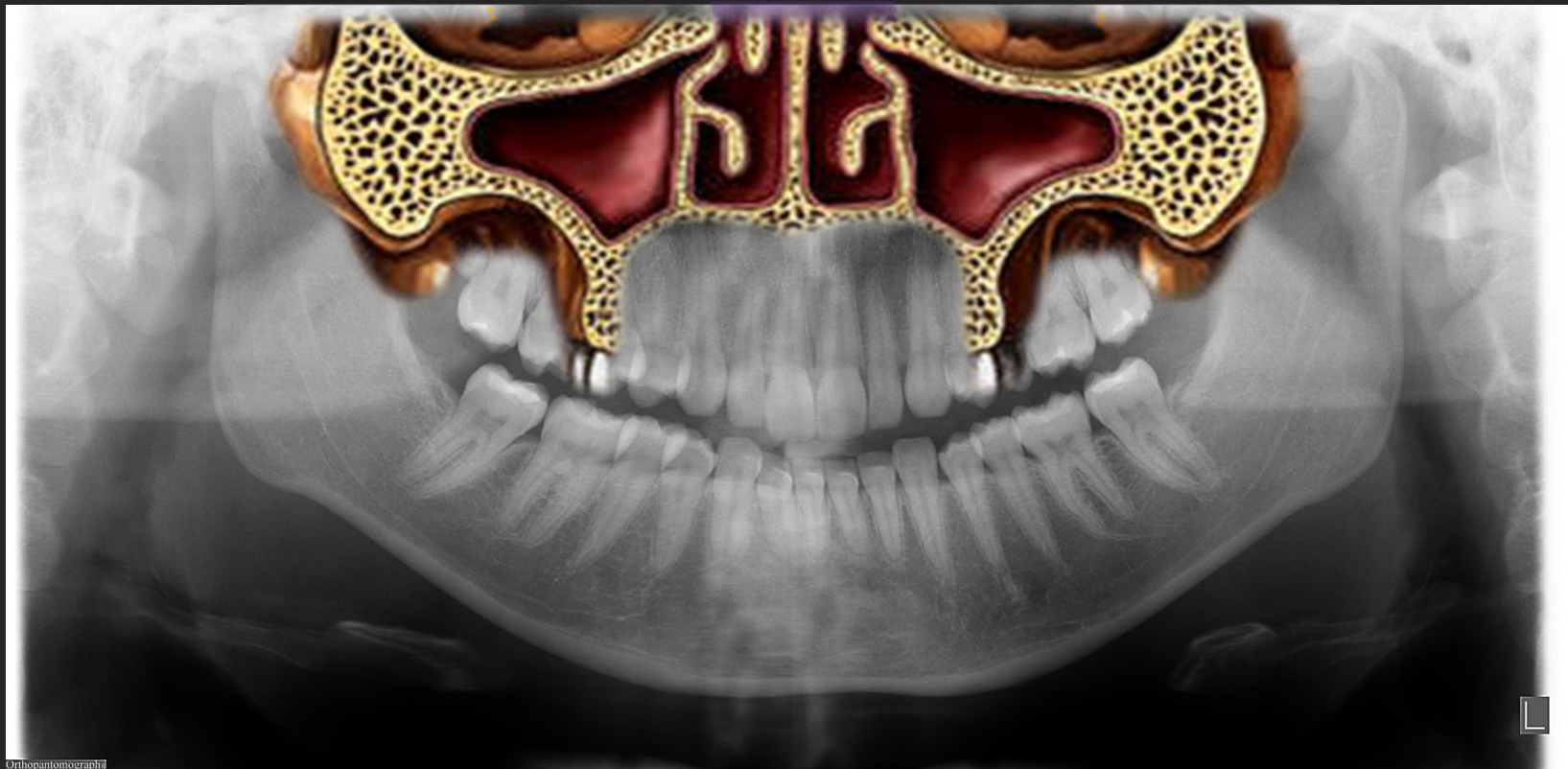- Assoalho da órbita
- Canal infraorbital
- Cavidade/fossa nasal



Orthopantomograph

RADIOGRAFIA PANORÂMICA

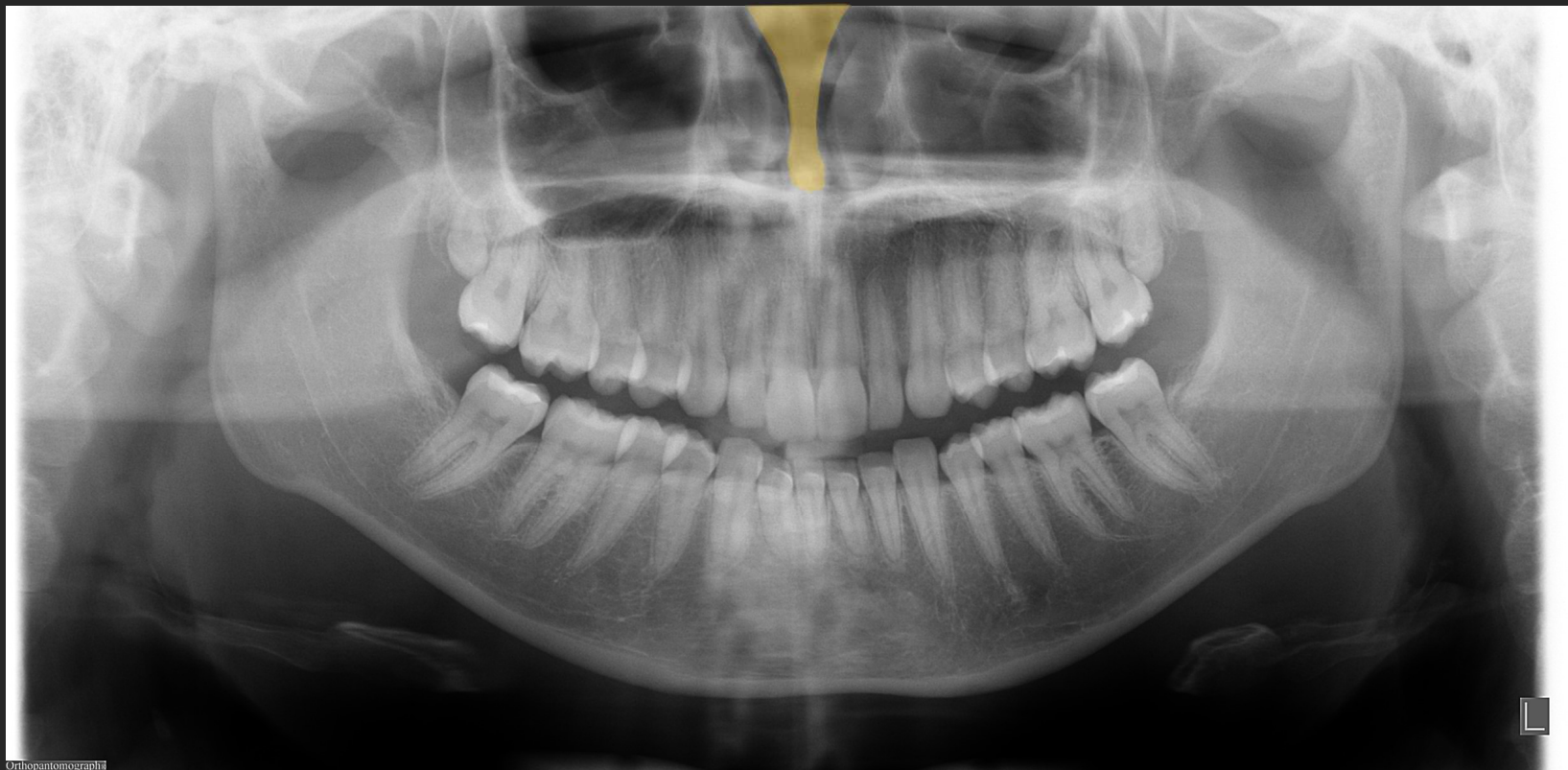
- Assoalho da órbita
- Canal infraorbital
- Cavidade/fossa nasal



Orthopantomograph

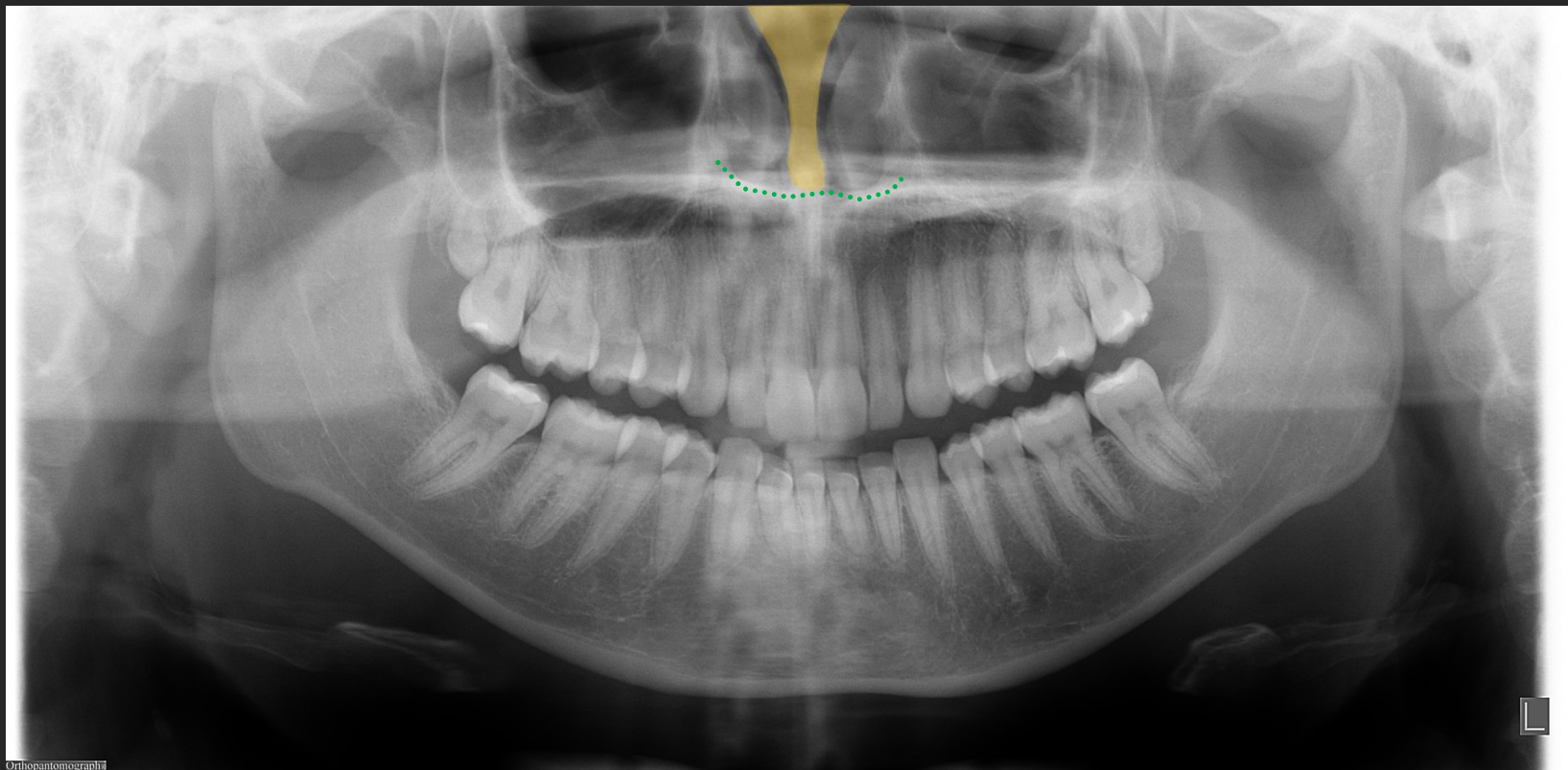
RADIOGRAFIA PANORÂMICA

- Septo nasal



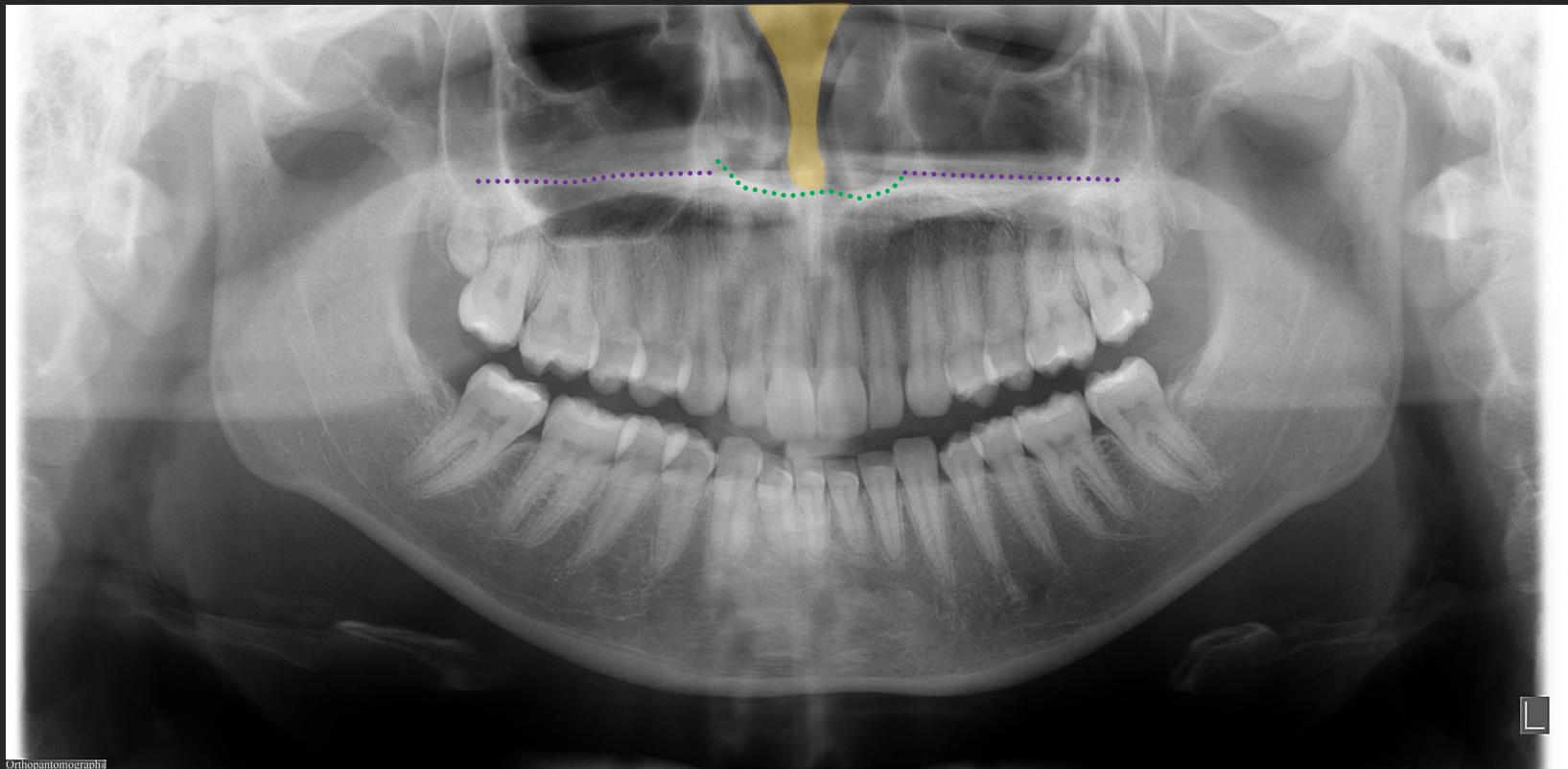
RADIOGRAFIA PANORÂMICA

- Septo nasal
- Assoalho da cavidade nasal



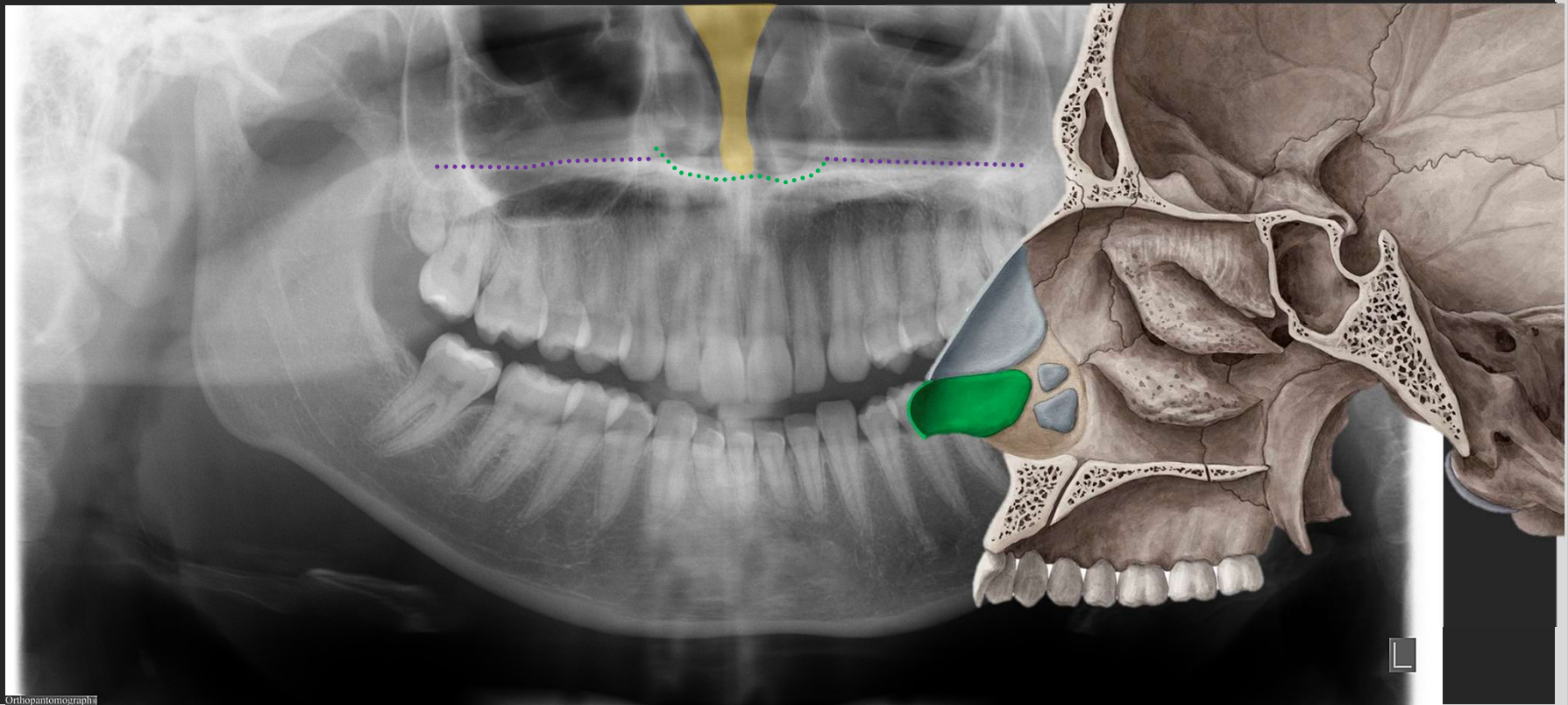
RADIOGRAFIA PANORÂMICA

- Septo nasal
- Assoalho da cavidade nasal
- Assoalho da cavidade nasal/Palato duro



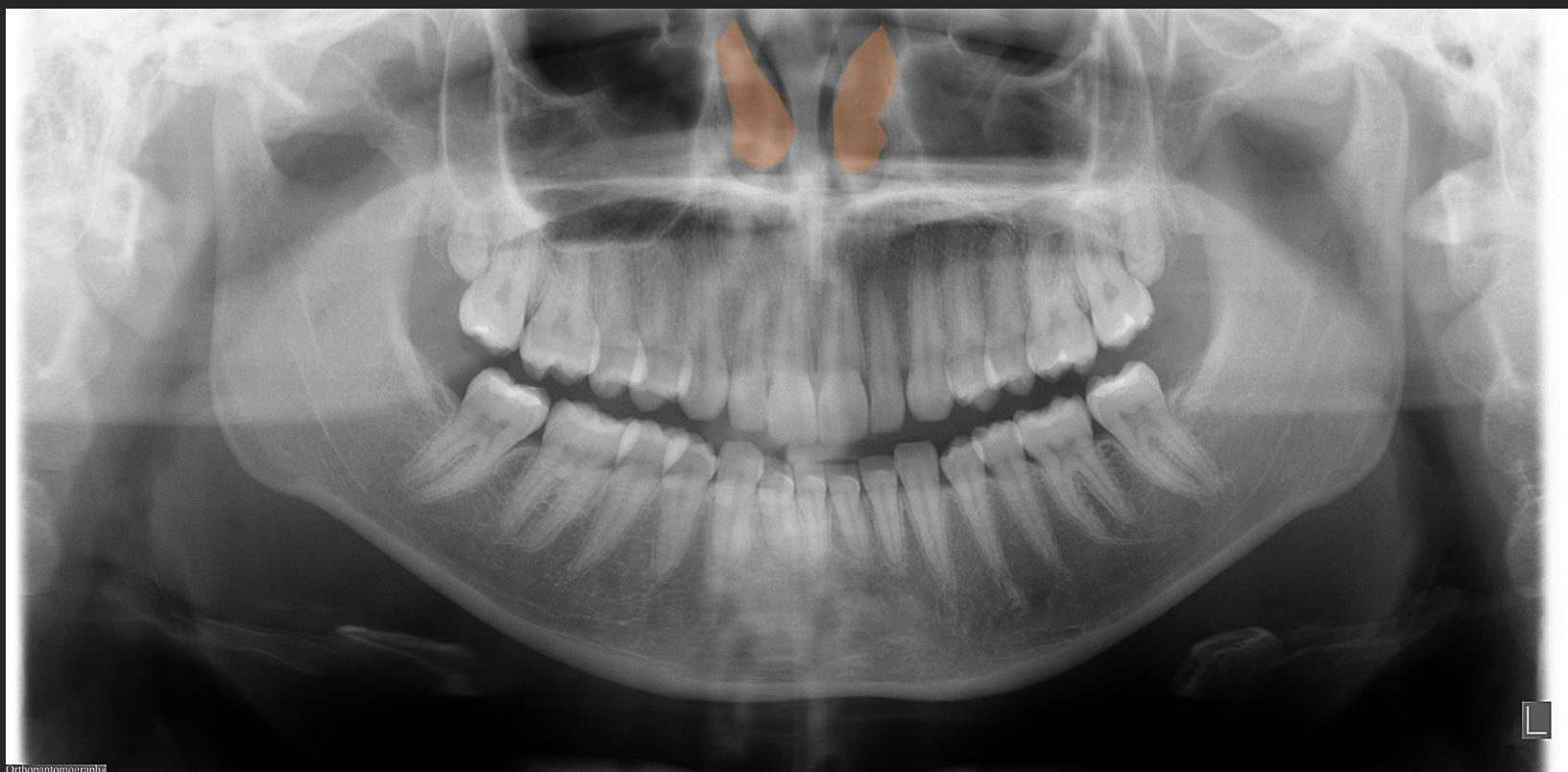RADIOGRAFIA PANORÂMICA

- Septo nasal
- Assoalho da cavidade nasal
- Assoalho da cavidade nasal/Palato duro



RADIOGRAFIA PANORÂMICA

- Conchas nasais inferiores

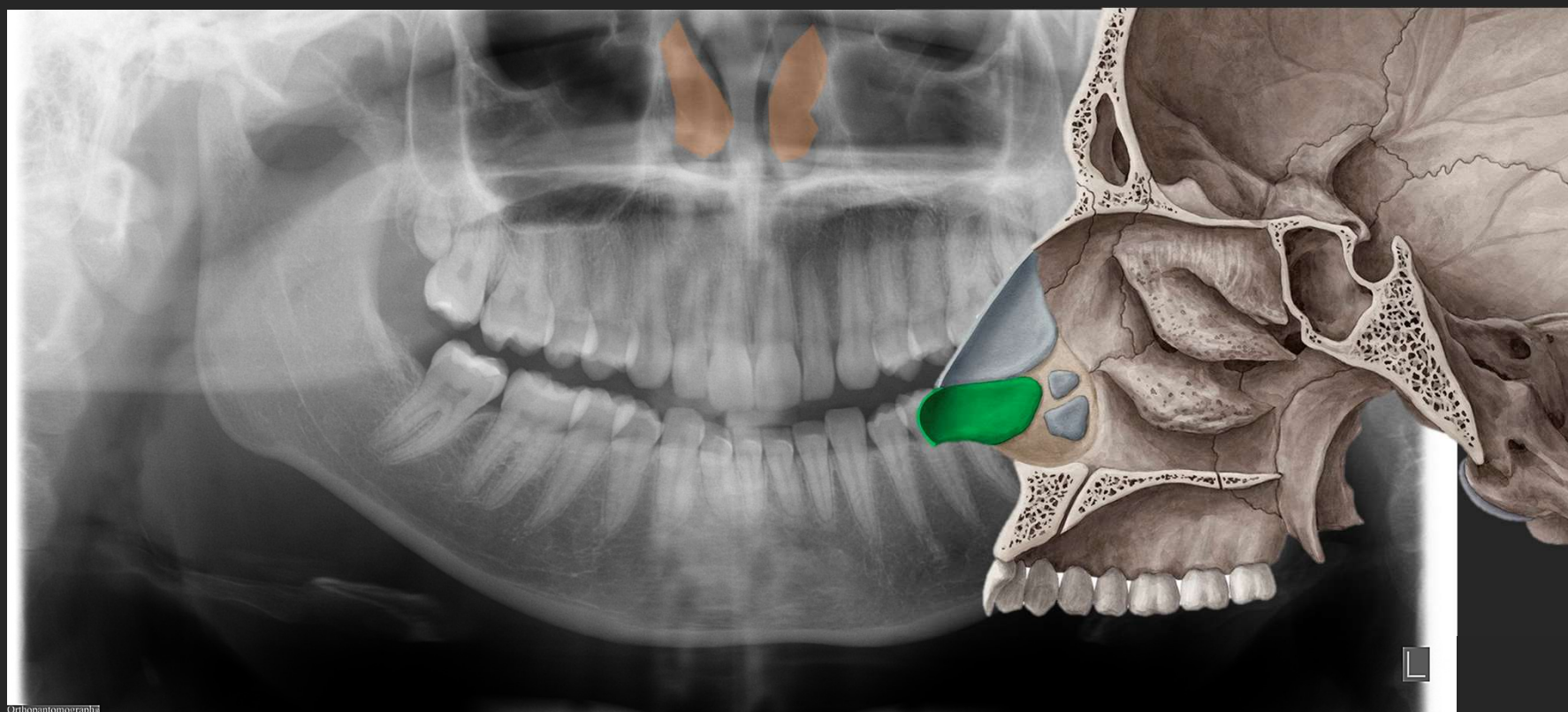


Orthopantomograph



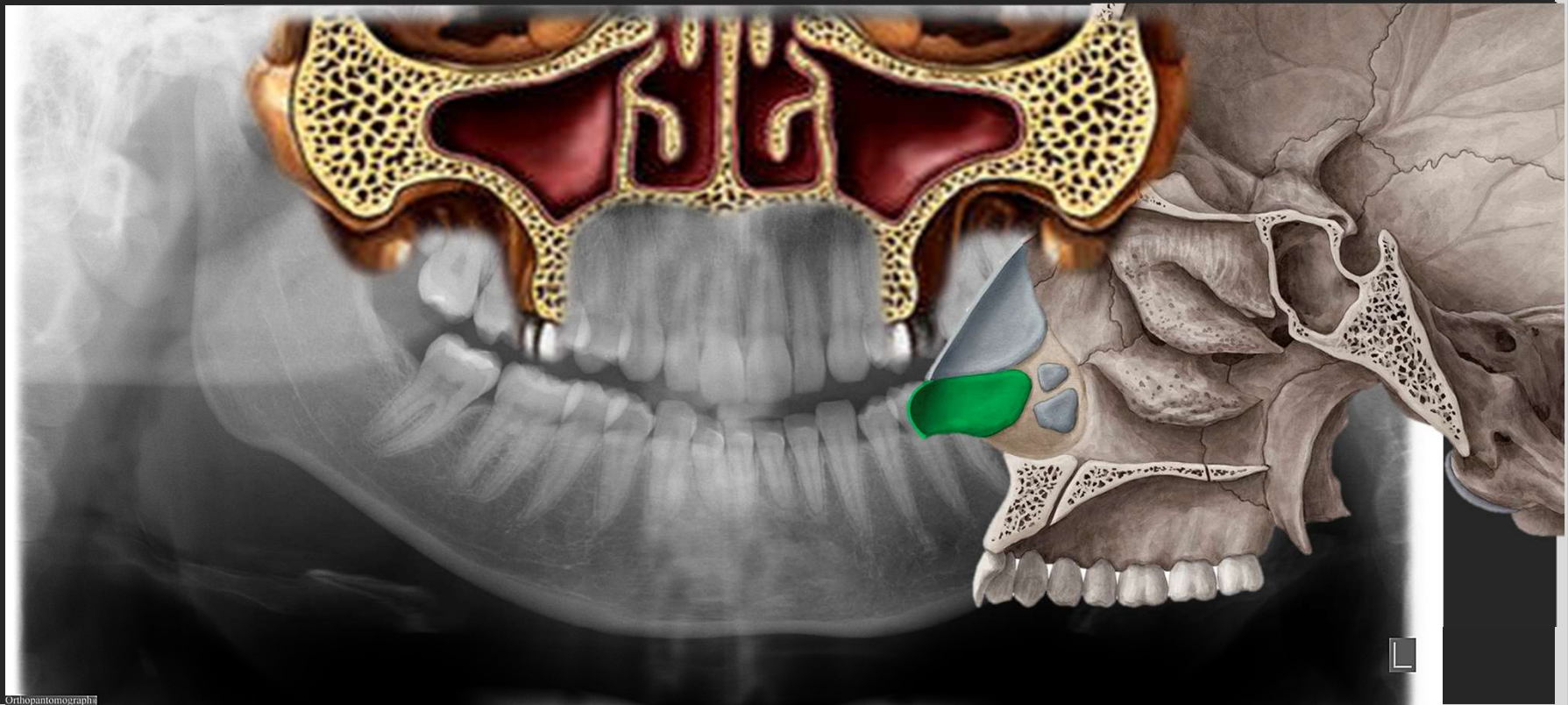
RADIOGRAFIA PANORÂMICA

- Conchas nasais inferiores



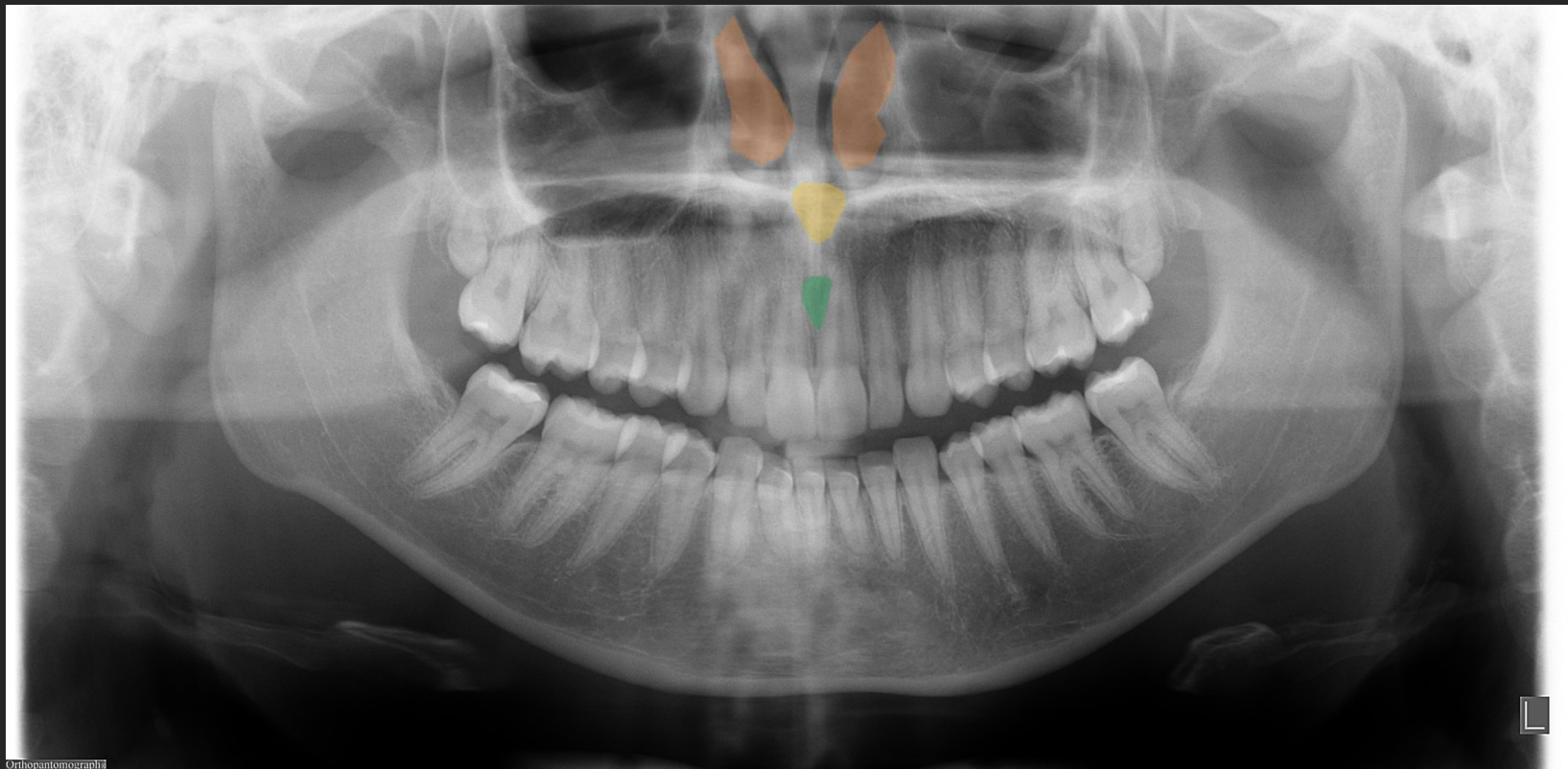
RADIOGRAFIA PANORÂMICA

- Conchas nasais inferiores



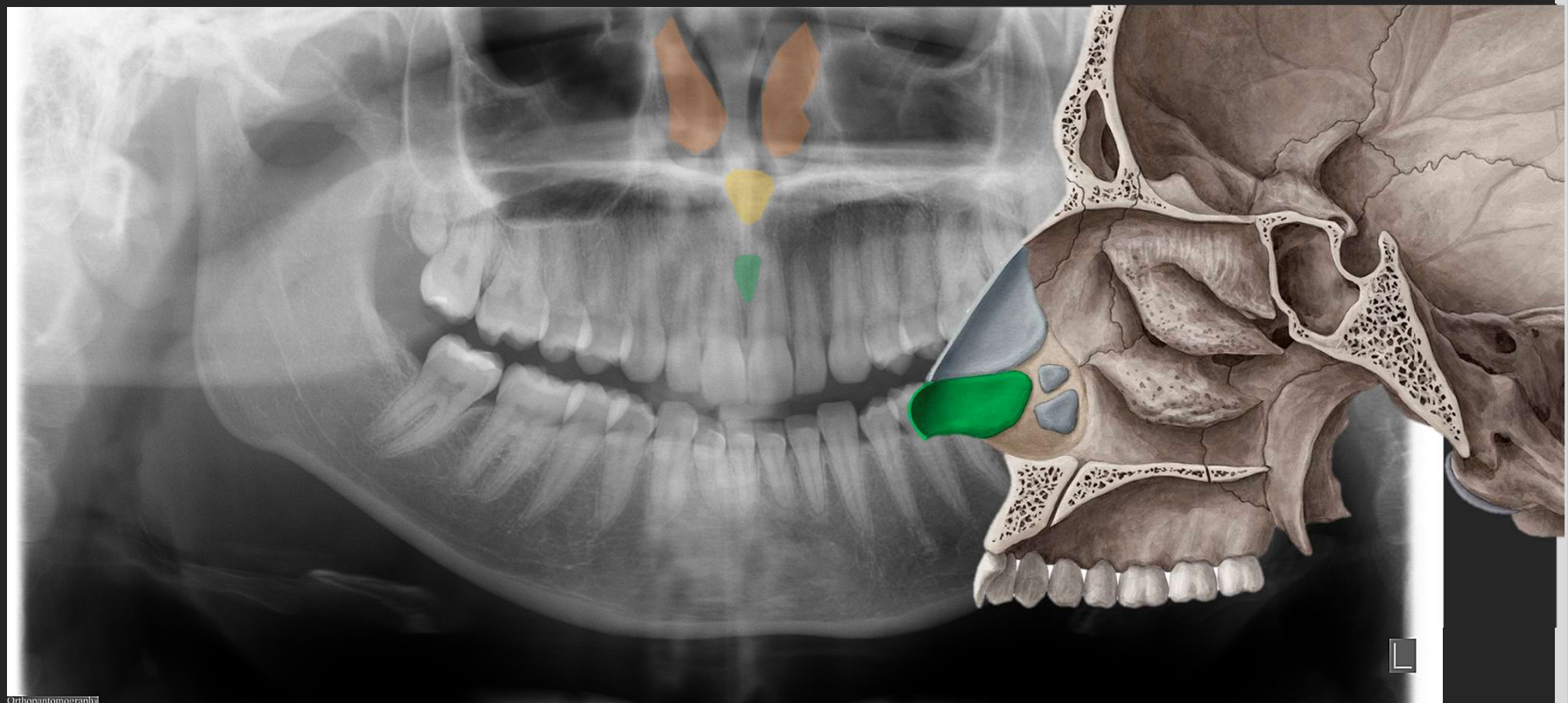
RADIOGRAFIA PANORÂMICA

- Espinha nasal anterior
- Forame incisivo
- Conchas nasais inferiores



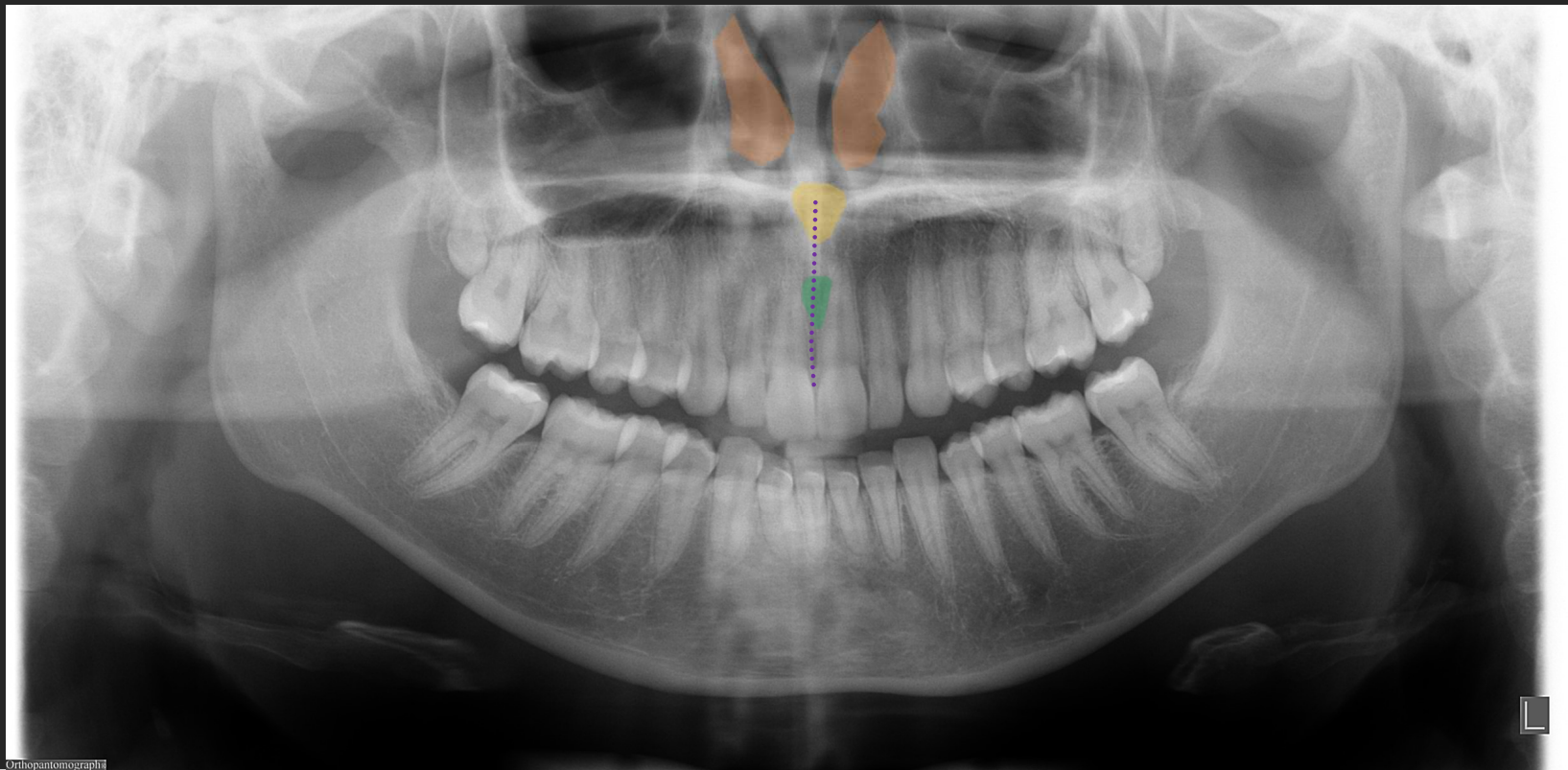
RADIOGRAFIA PANORÂMICA

- Espinha nasal anterior
- Forame incisivo
- Conchas nasais inferiores



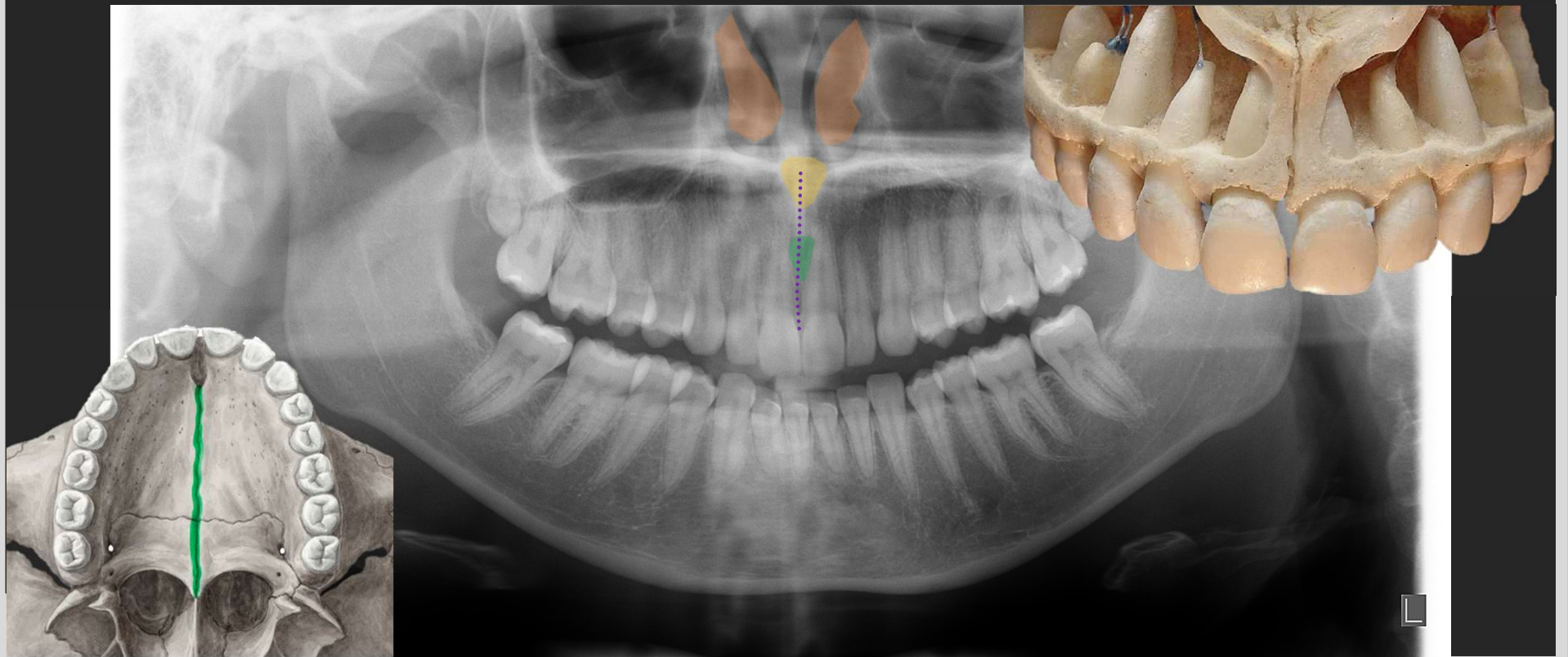
RADIOGRAFIA PANORÂMICA

- Espinha nasal anterior
- Forame incisivo
- Sutura intermaxilar
- Conchas nasais inferiores



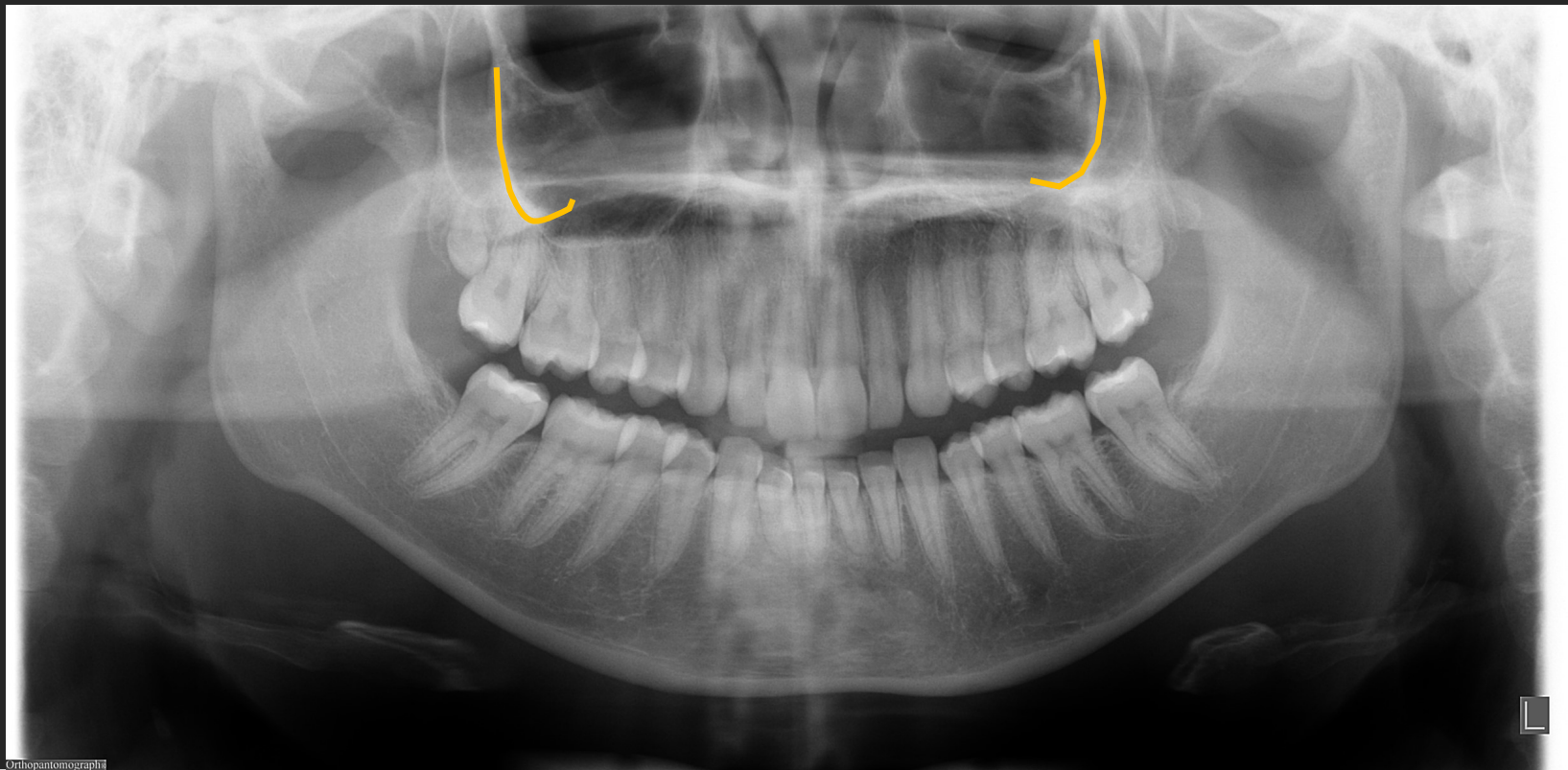
RADIOGRAFIA PANORÂMICA

- Espinha nasal anterior
- Forame incisivo
- Sutura intermaxilar
- Conchas nasais inferiores



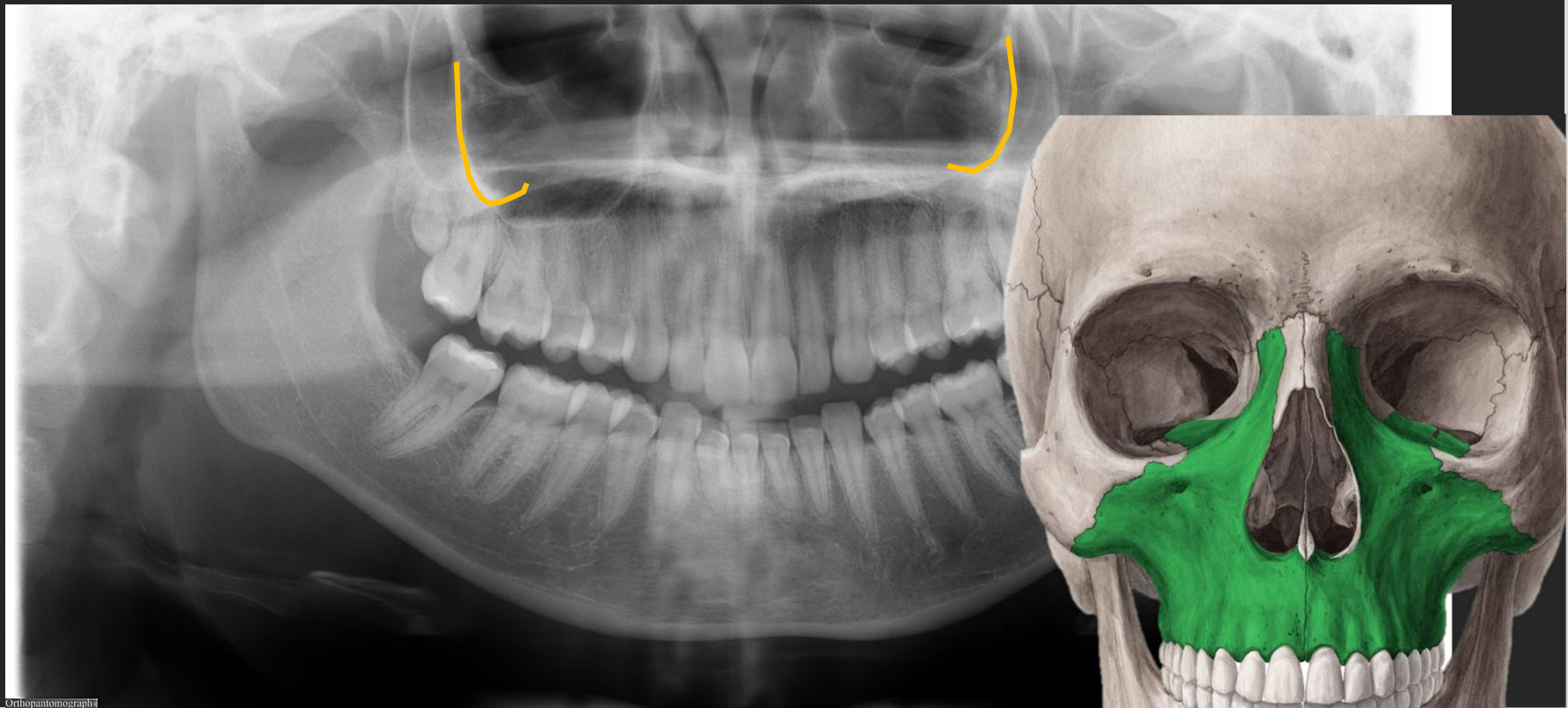
RADIOGRAFIA PANORÂMICA

- Processo zigomático da maxila



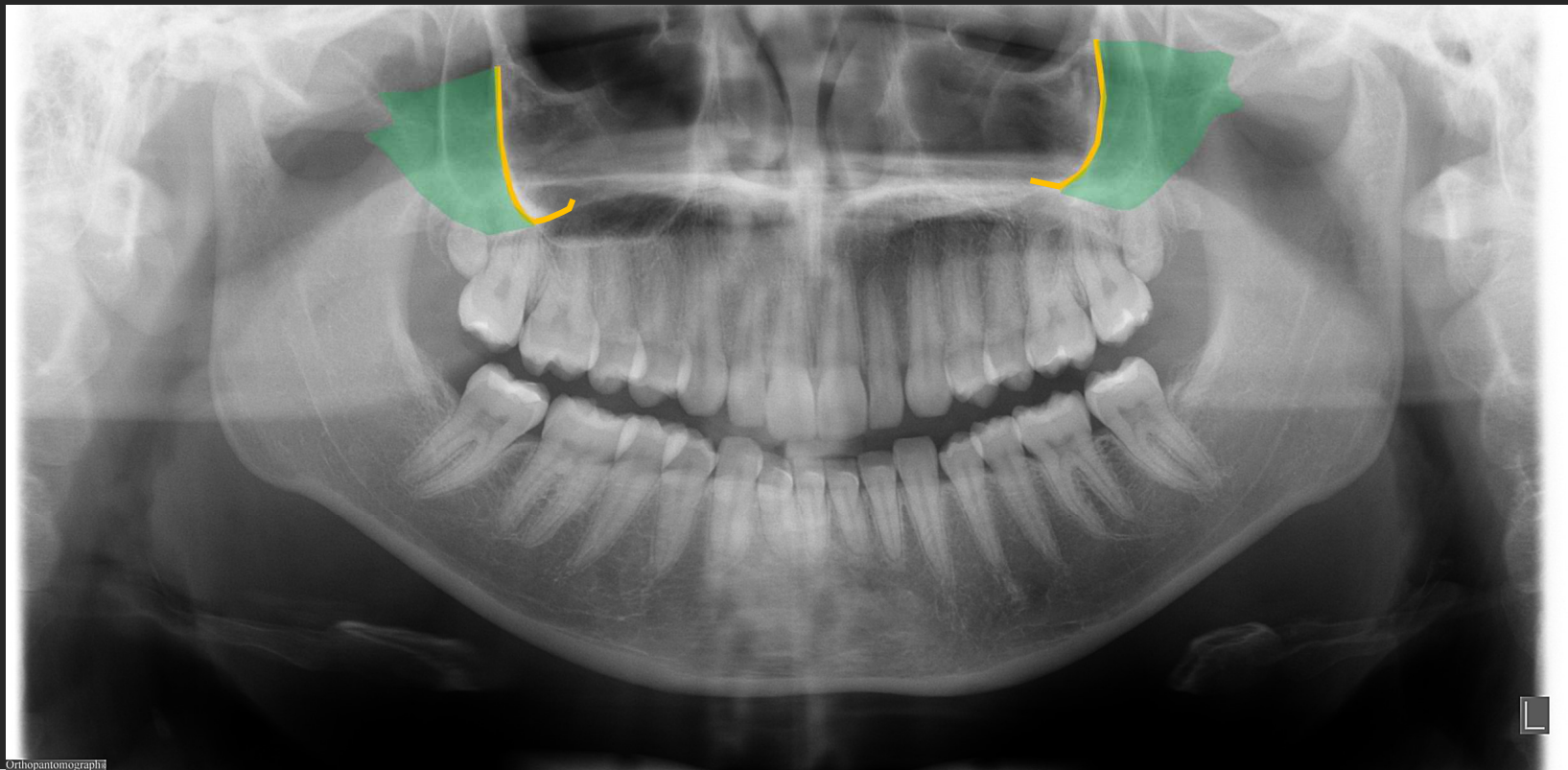
RADIOGRAFIA PANORÂMICA

- Processo zigomático da maxila



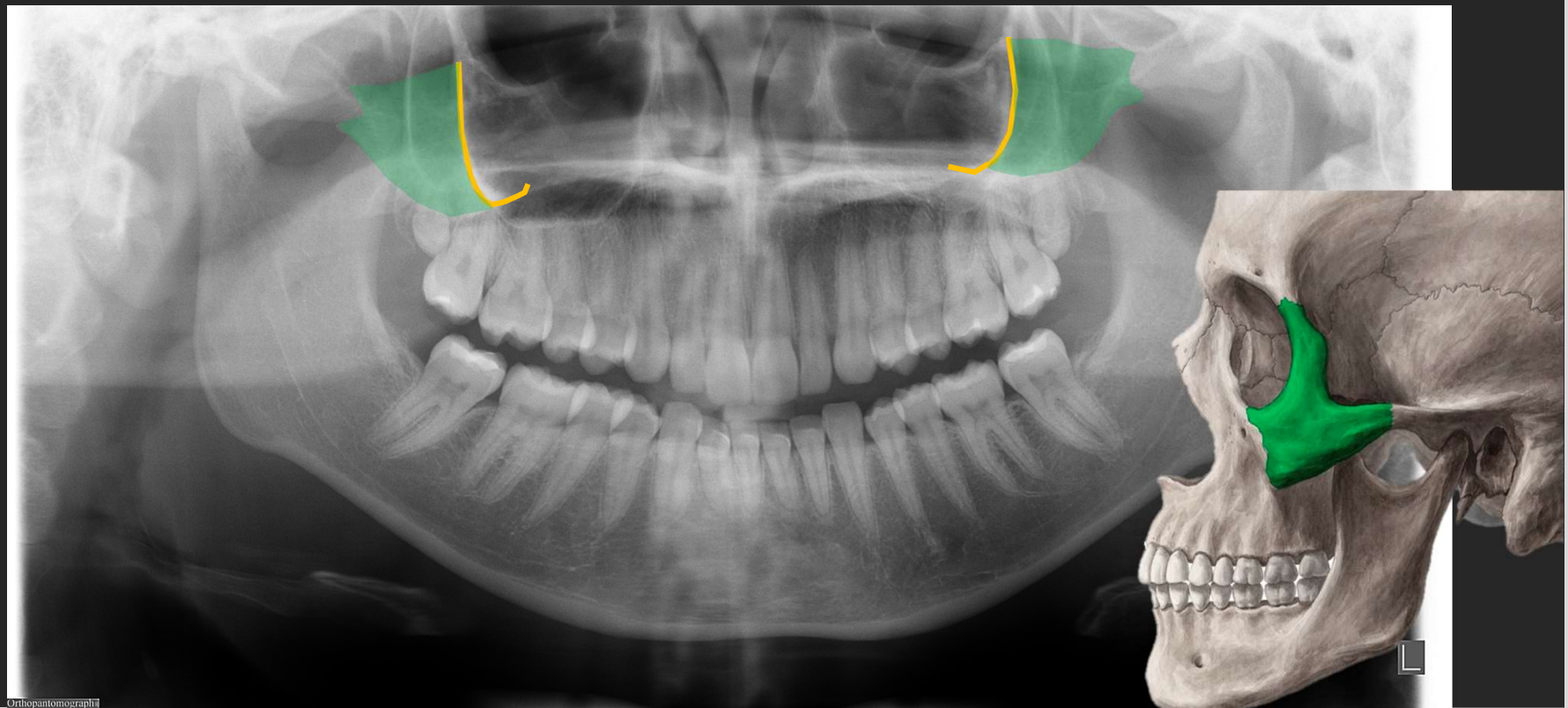
RADIOGRAFIA PANORÂMICA

- Processo zigomático da maxila
- Osso zigomático



RADIOGRAFIA PANORÂMICA

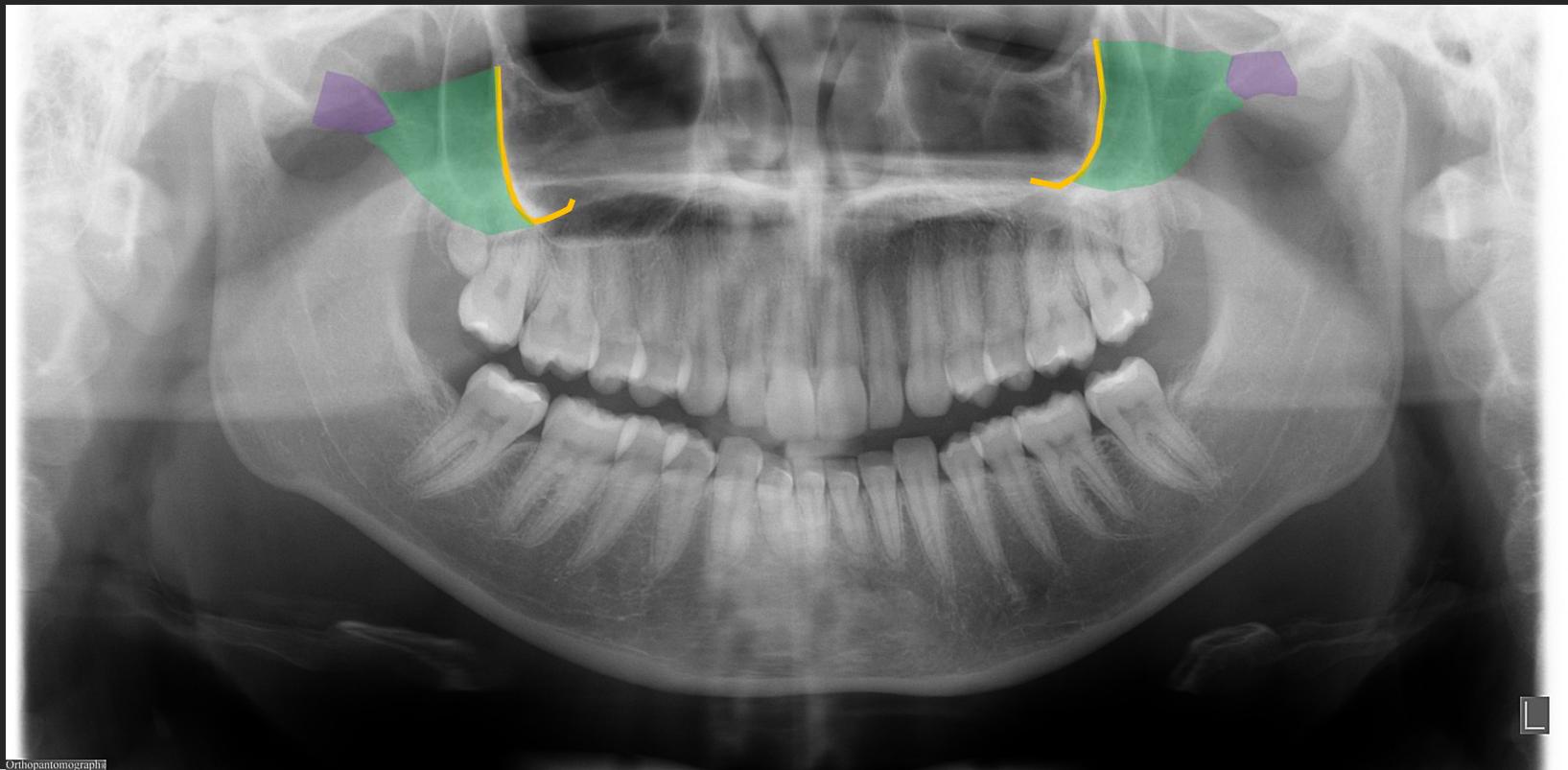
- Processo zigomático da maxila
- Osso zigomático



Orthopantomograph

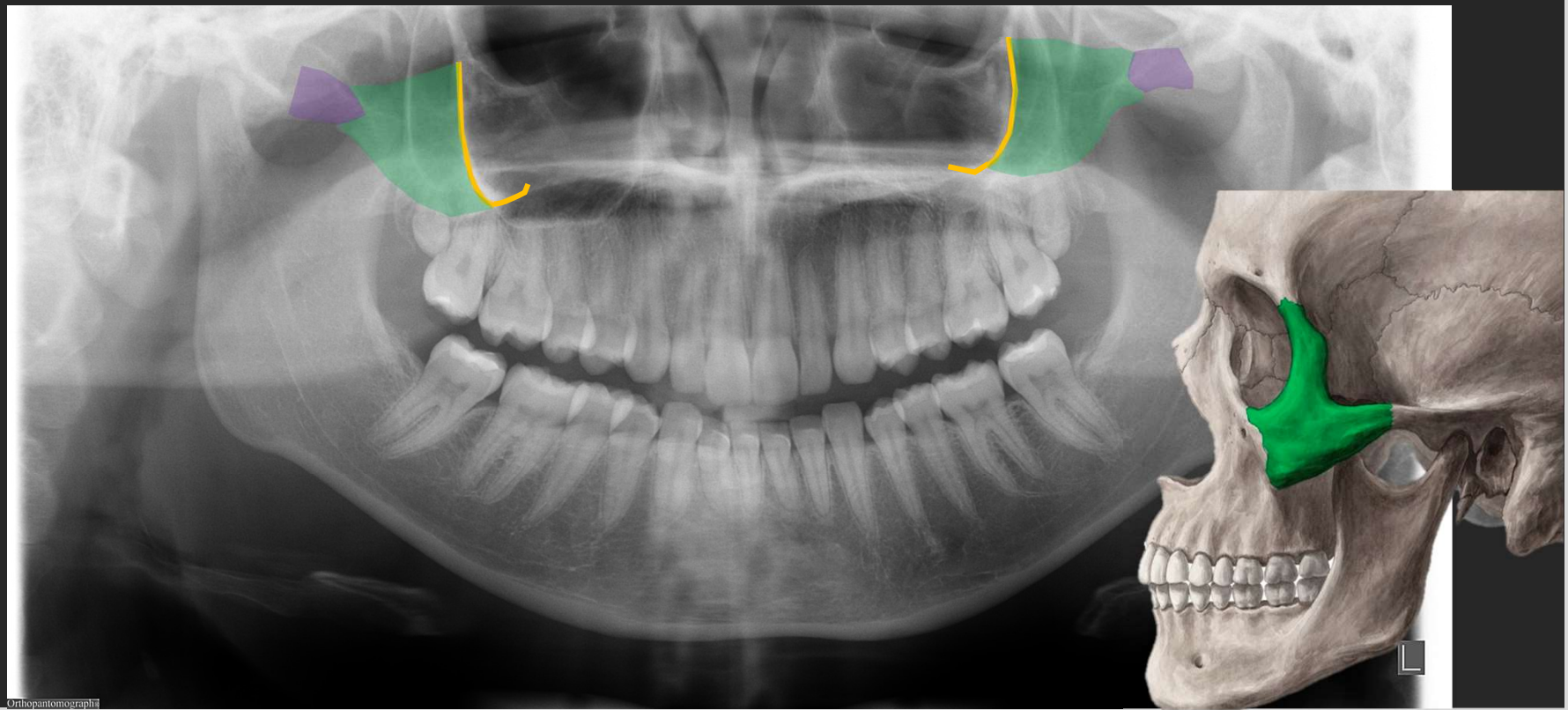
RADIOGRAFIA PANORÂMICA

- Processo zigomático da maxila
- Osso zigomático
- Arco zigomático



RADIOGRAFIA PANORÂMICA

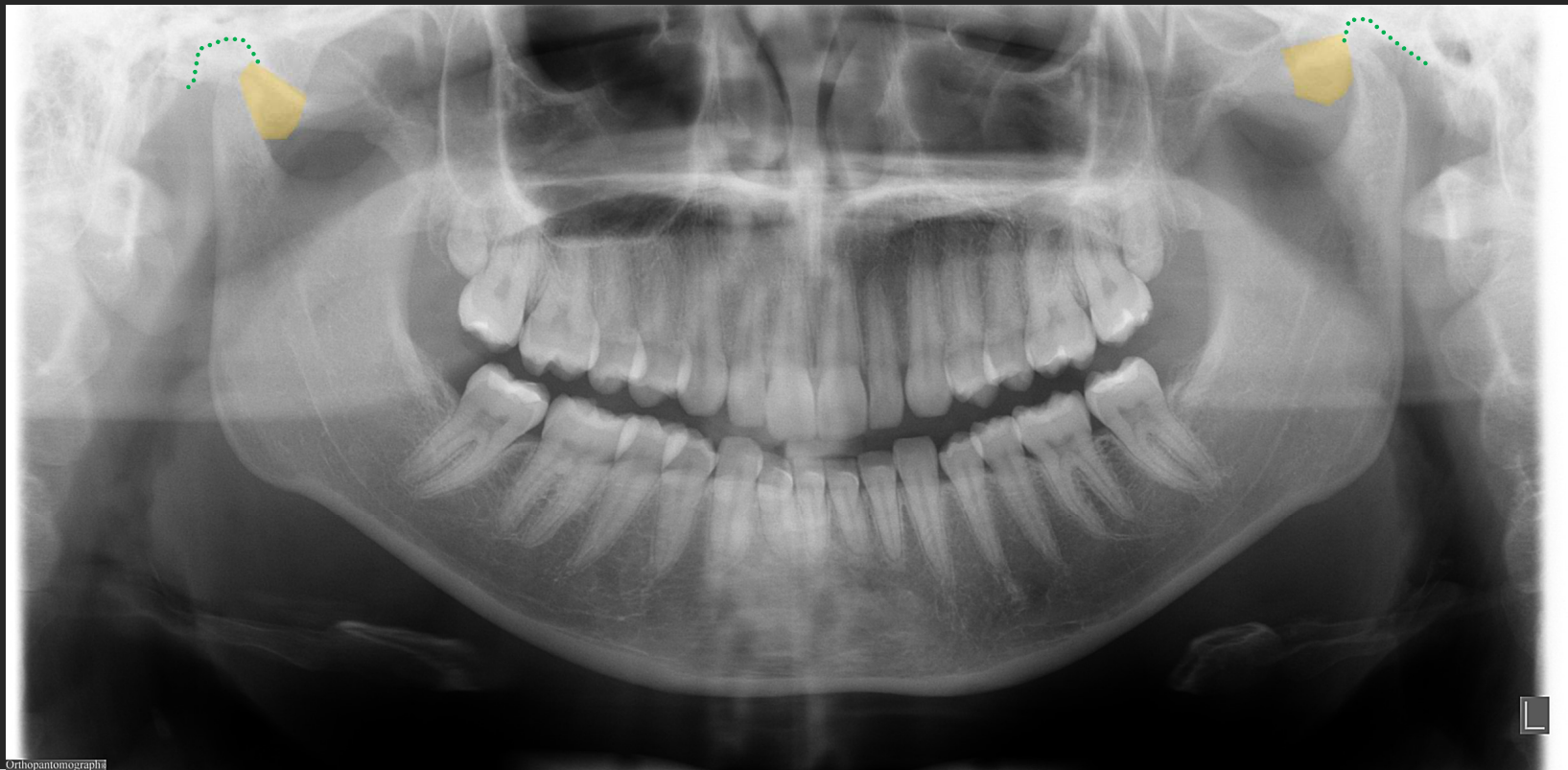- Processo zigomático da maxila
- Osso zigomático
- Arco zigomático



Orthopantomograph

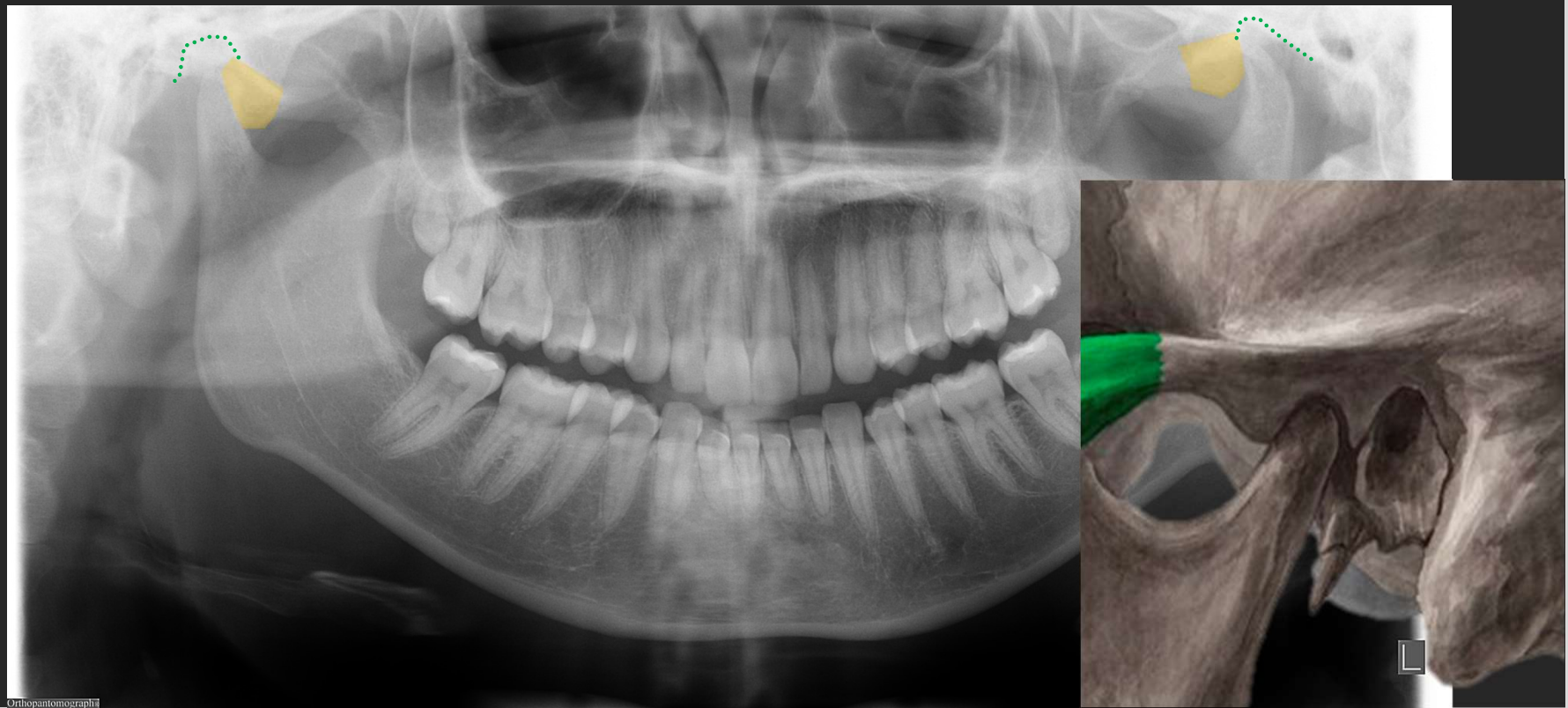
RADIOGRAFIA PANORÂMICA

- Eminência articular
- Fossa articular



RADIOGRAFIA PANORÂMICA

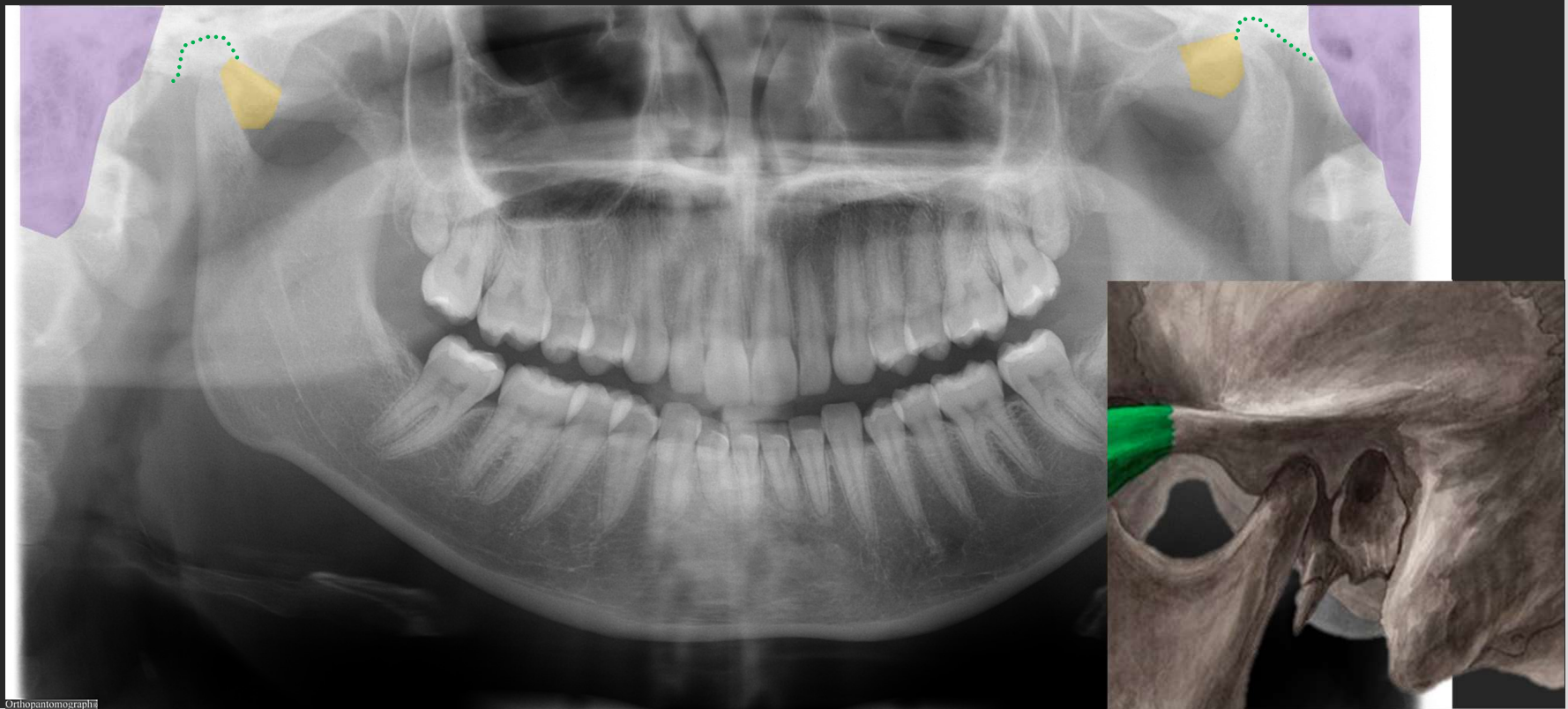- Eminência articular
- Fossa articular



Orthopantomograph

RADIOGRAFIA PANORÂMICA

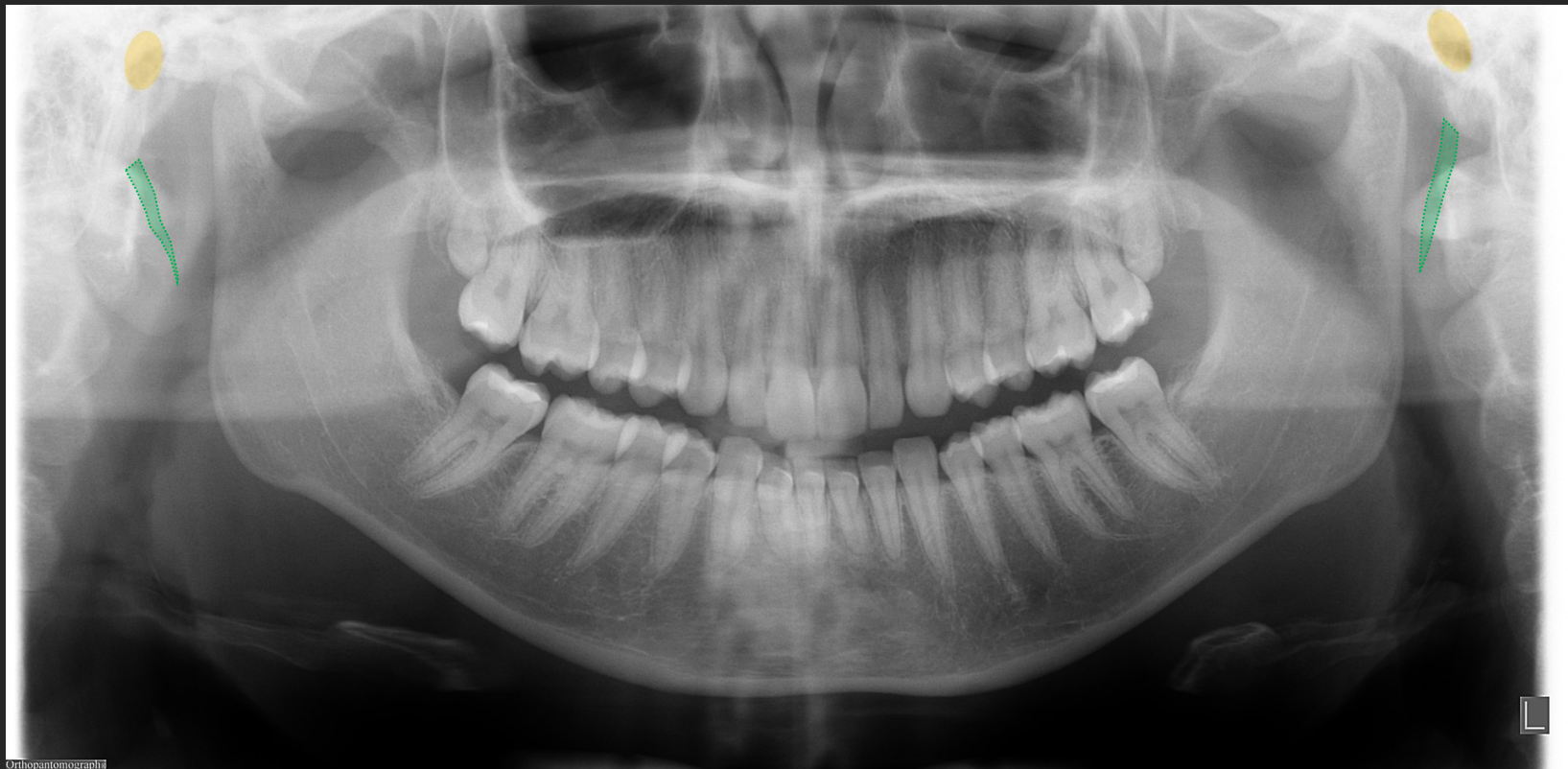- Eminência articular
- Fossa articular
- Processo mastoide/células mastoideas



Orthopantomograph

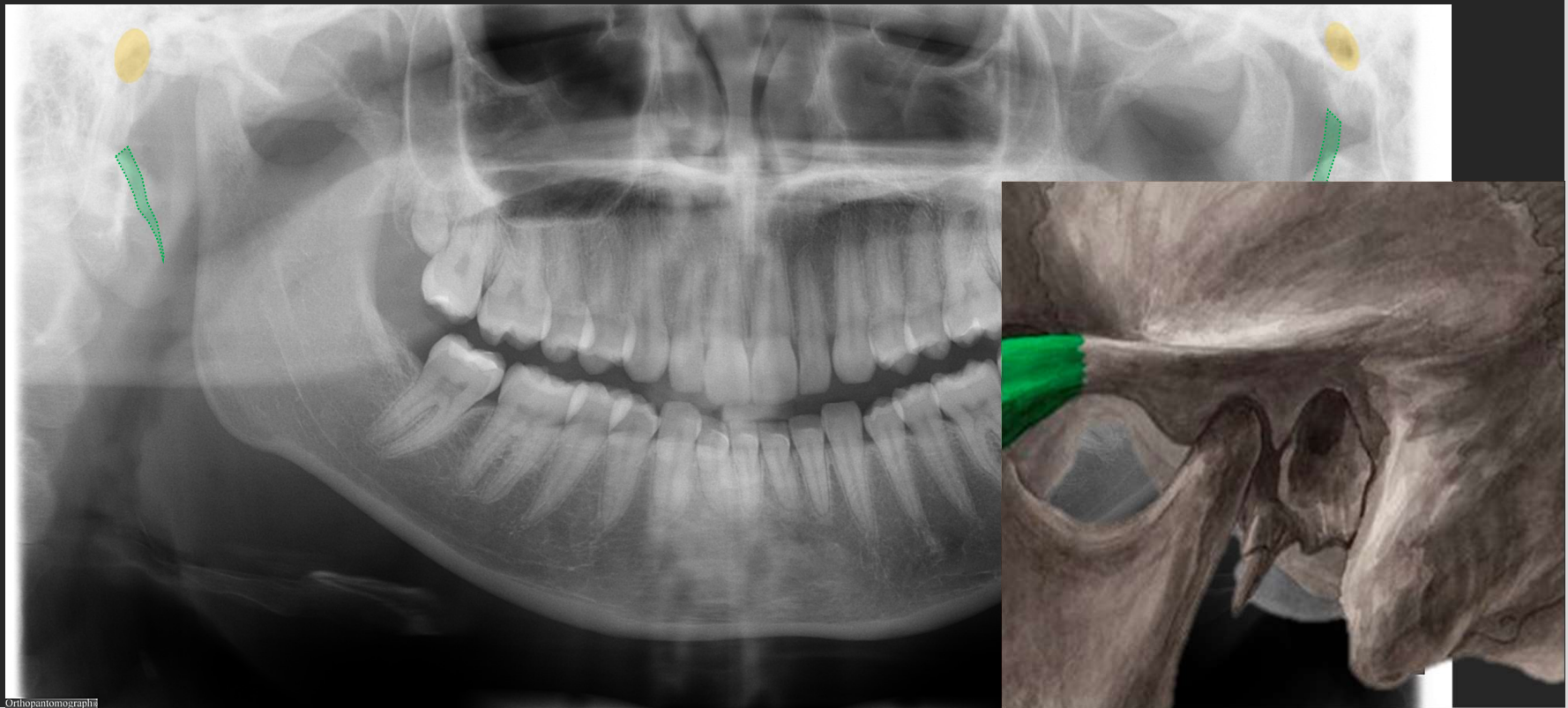
RADIOGRAFIA PANORÂMICA

- Meato acústico externo
- Processo estilóide

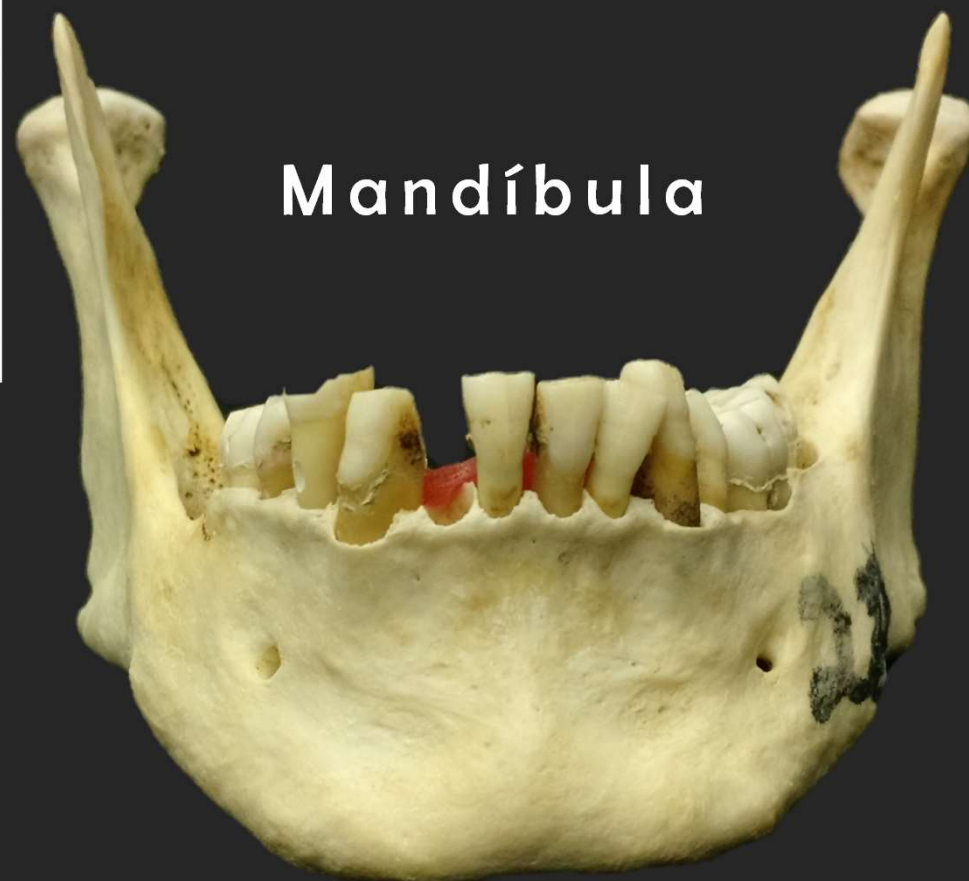
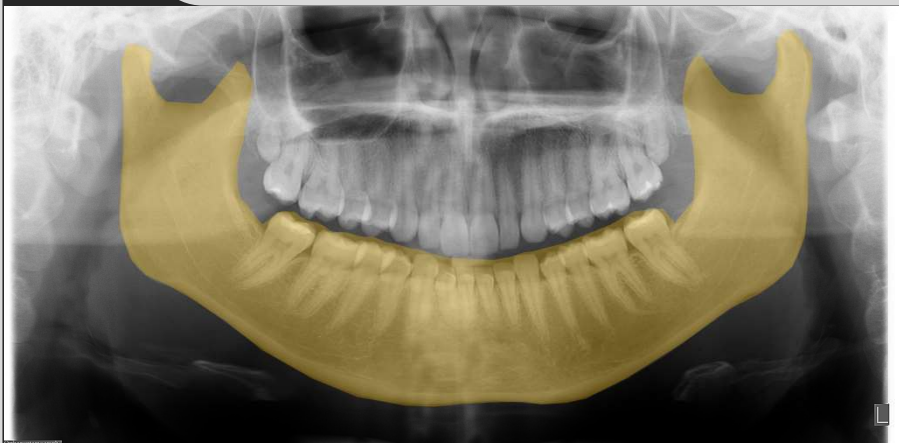

RADIOGRAFIA PANORÂMICA

- Meato acústico externo
- Processo estilóide

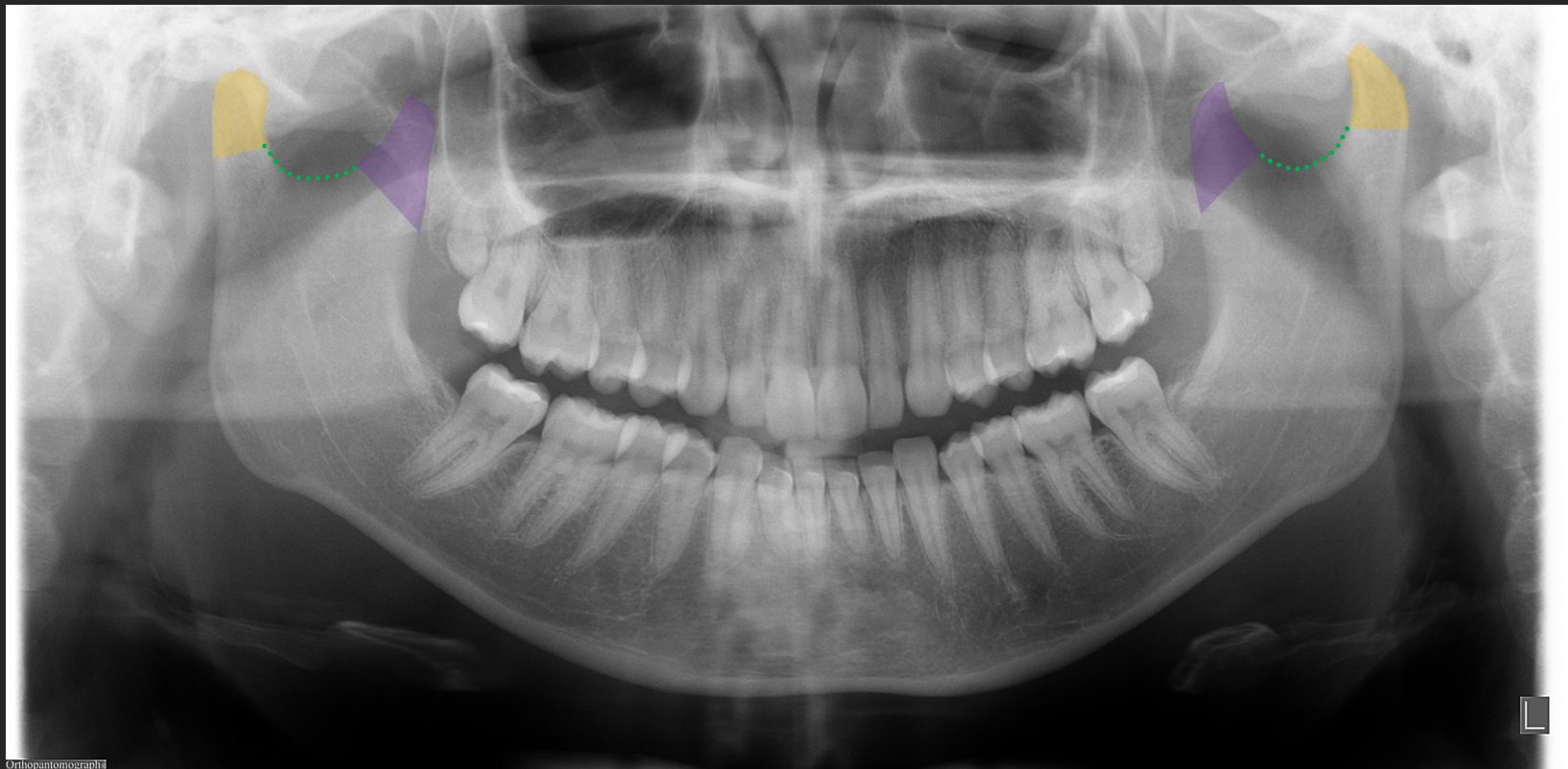

RADIOGRAFIA PANORÂMICA



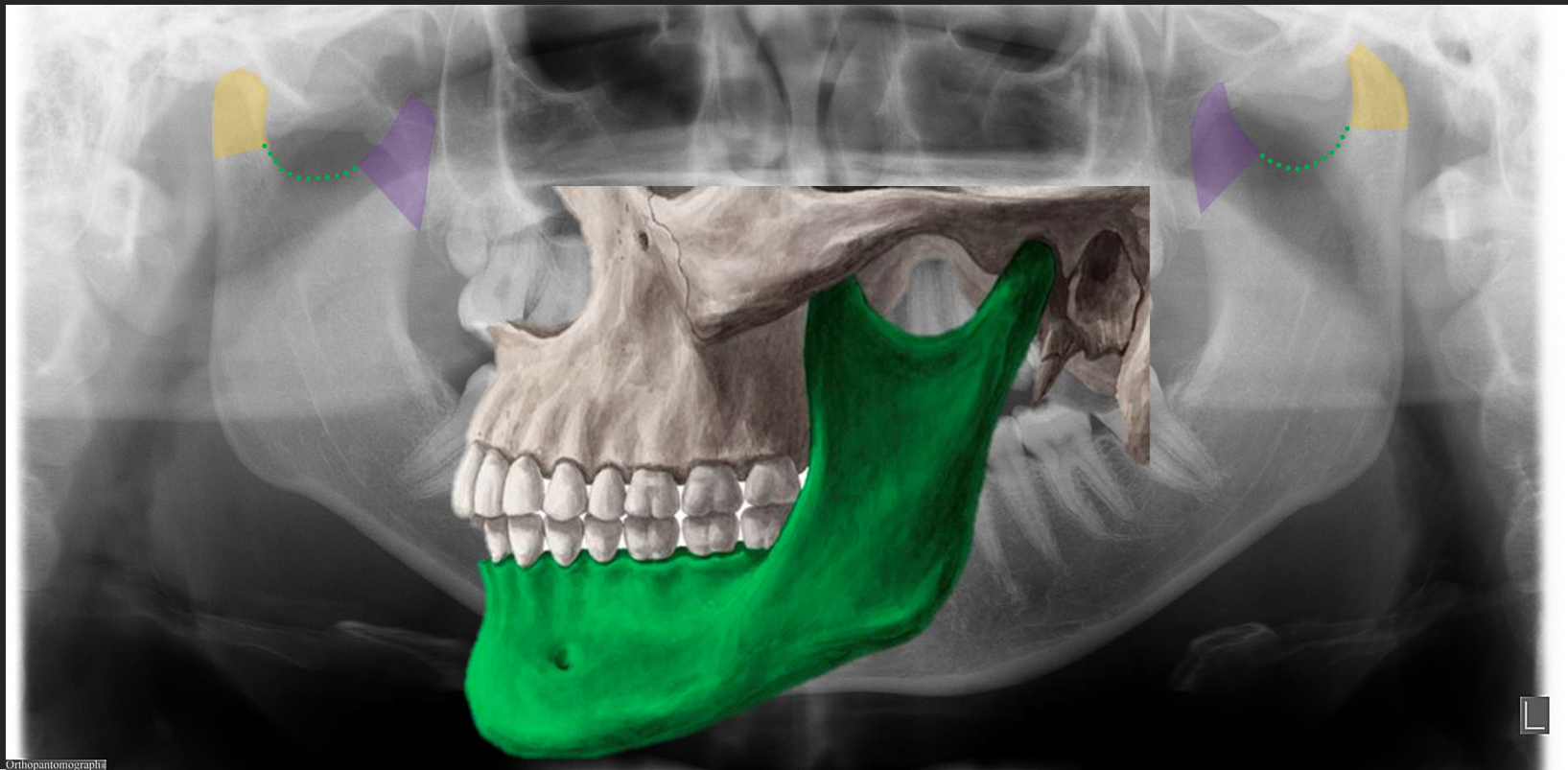
RADIOGRAFIA PANORÂMICA

- Cabeça da mandíbula
- Incisura da mandíbula
- Processo coronoide



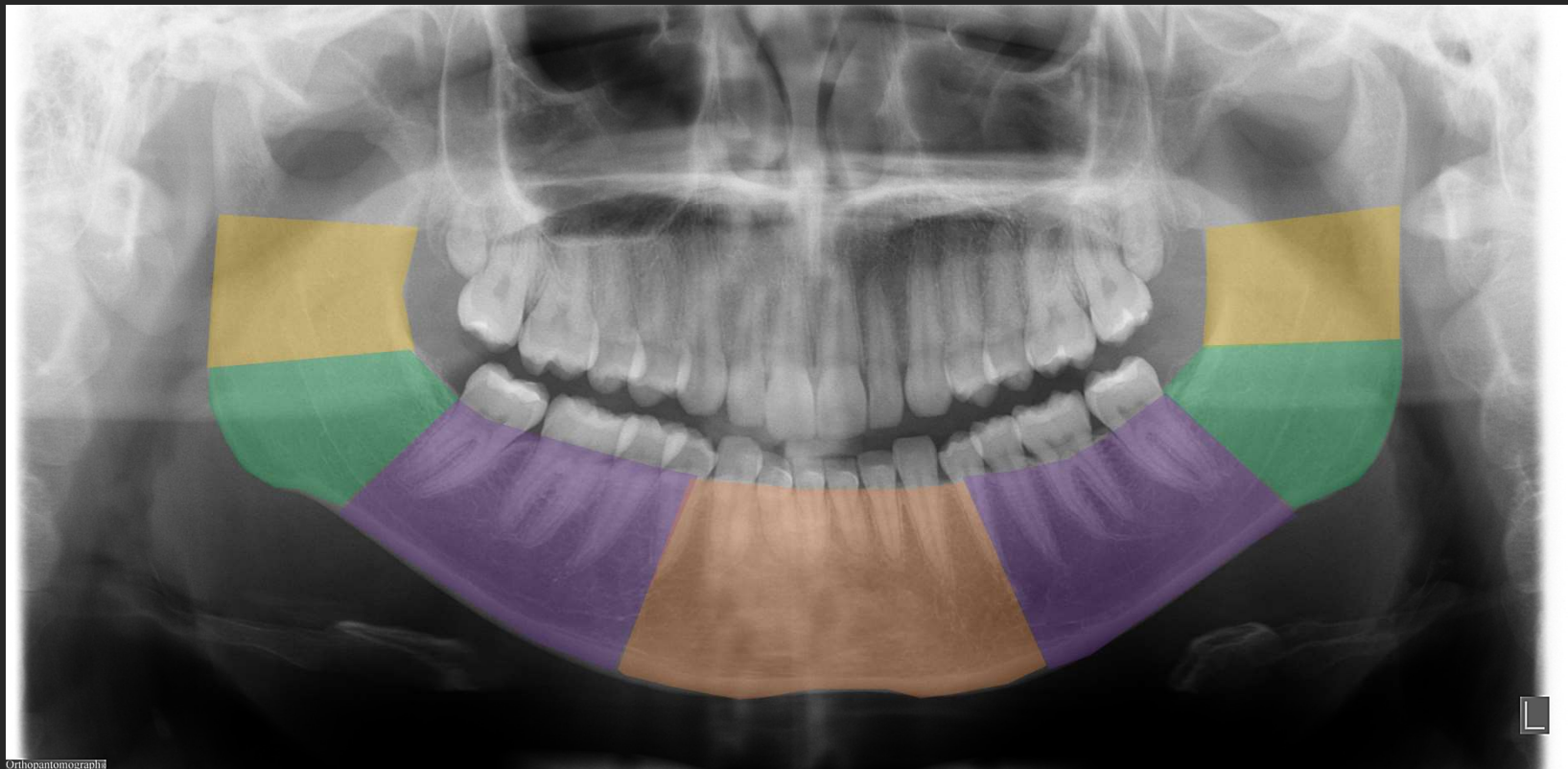
RADIOGRAFIA PANORÂMICA

- Cabeça da mandíbula
- Incisura da mandíbula
- Processo coronoide



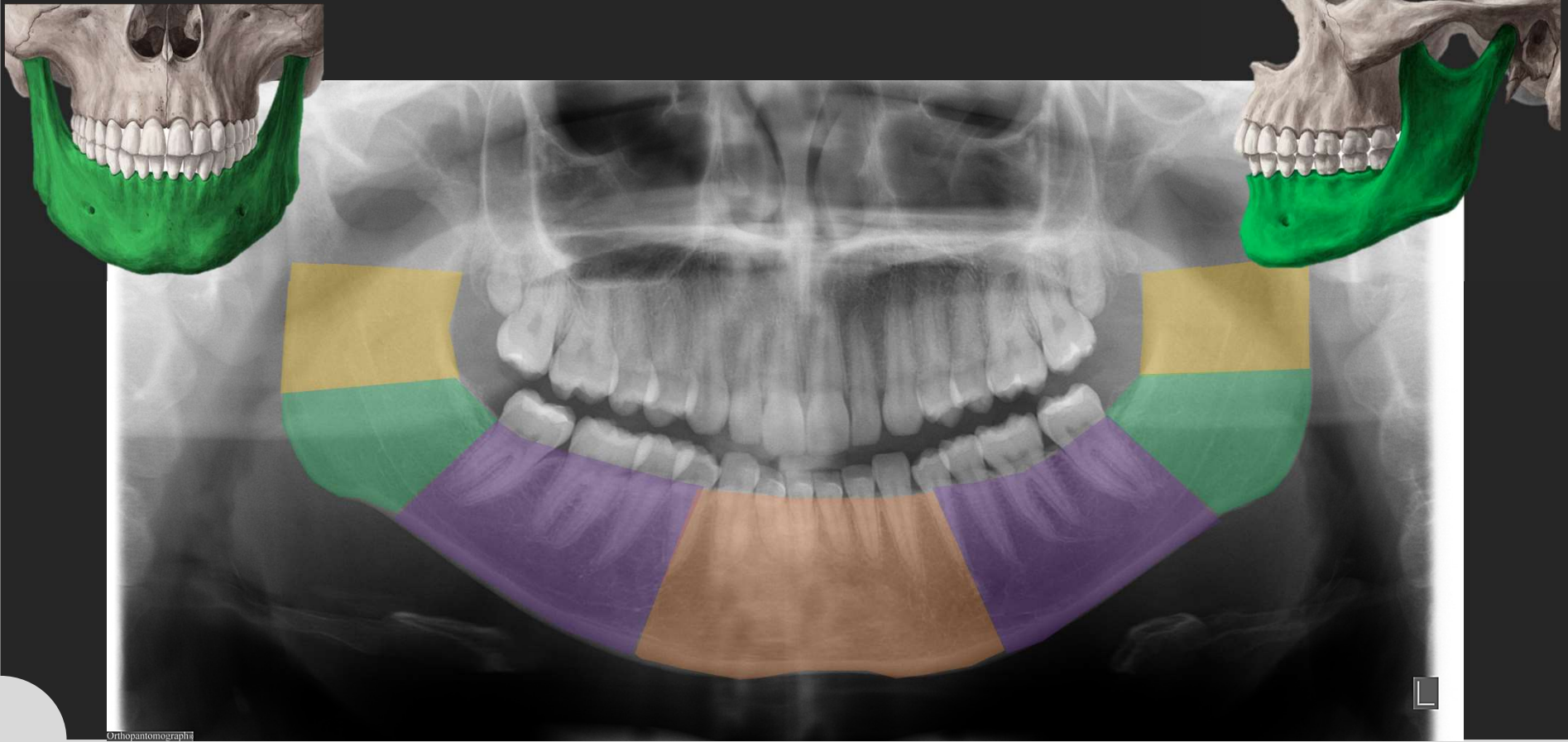
RADIOGRAFIA PANORÂMICA

- Ramo da mandíbula
- Ângulo da mandíbula
- Corpo da mandíbula
- Sínfise



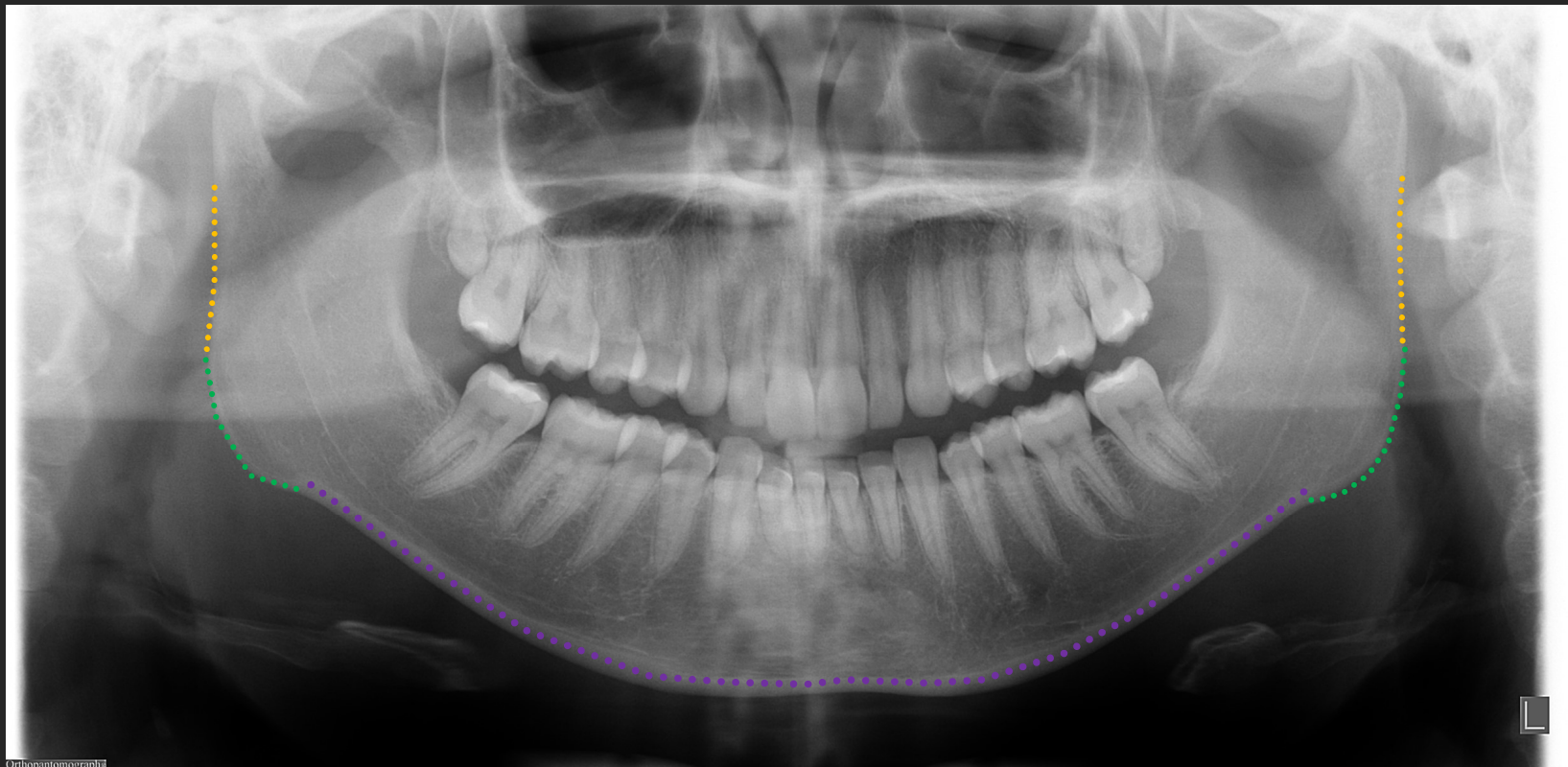RADIOGRAFIA PANORÂMICA

- Ramo da mandíbula
- Ângulo da mandíbula
- Corpo da mandíbula
- Sínfise



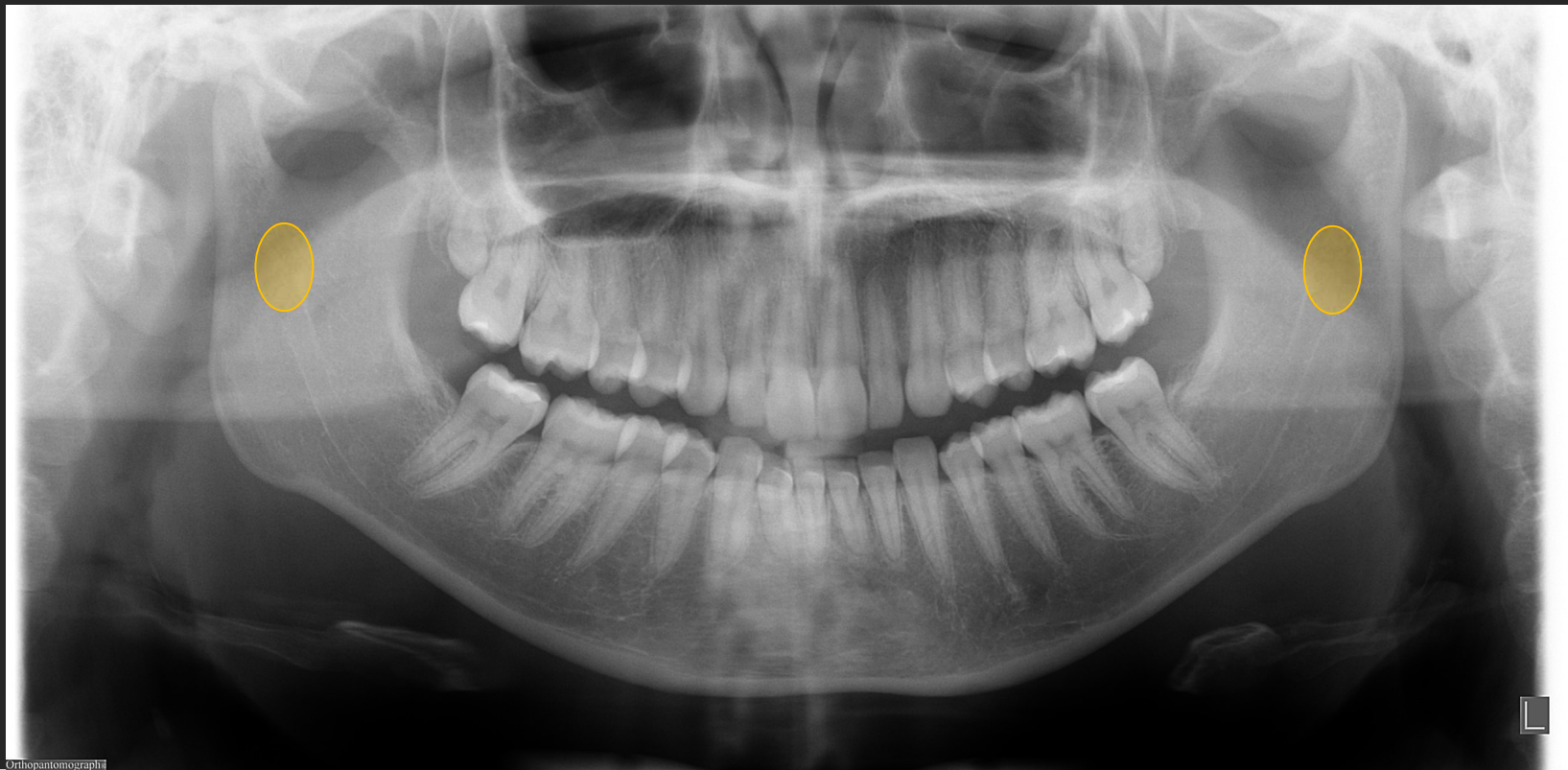RADIOGRAFIA PANORÂMICA

- Borda posterior do ramo da mandíbula
- Ângulo da mandíbula
- Borda/cortical inferior da mandíbula



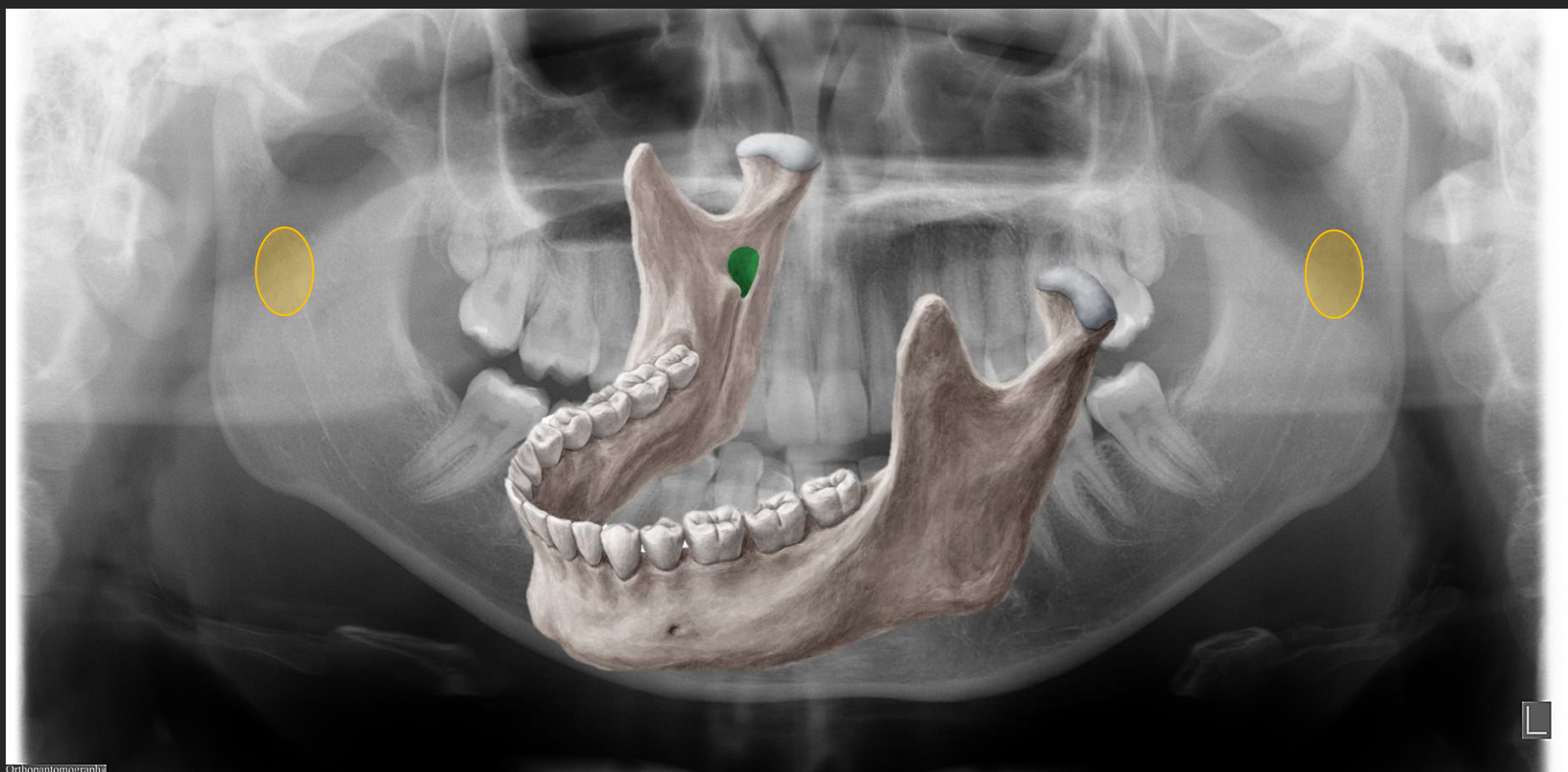
RADIOGRAFIA PANORÂMICA

- Forame da mandíbula



RADIOGRAFIA PANORÂMICA

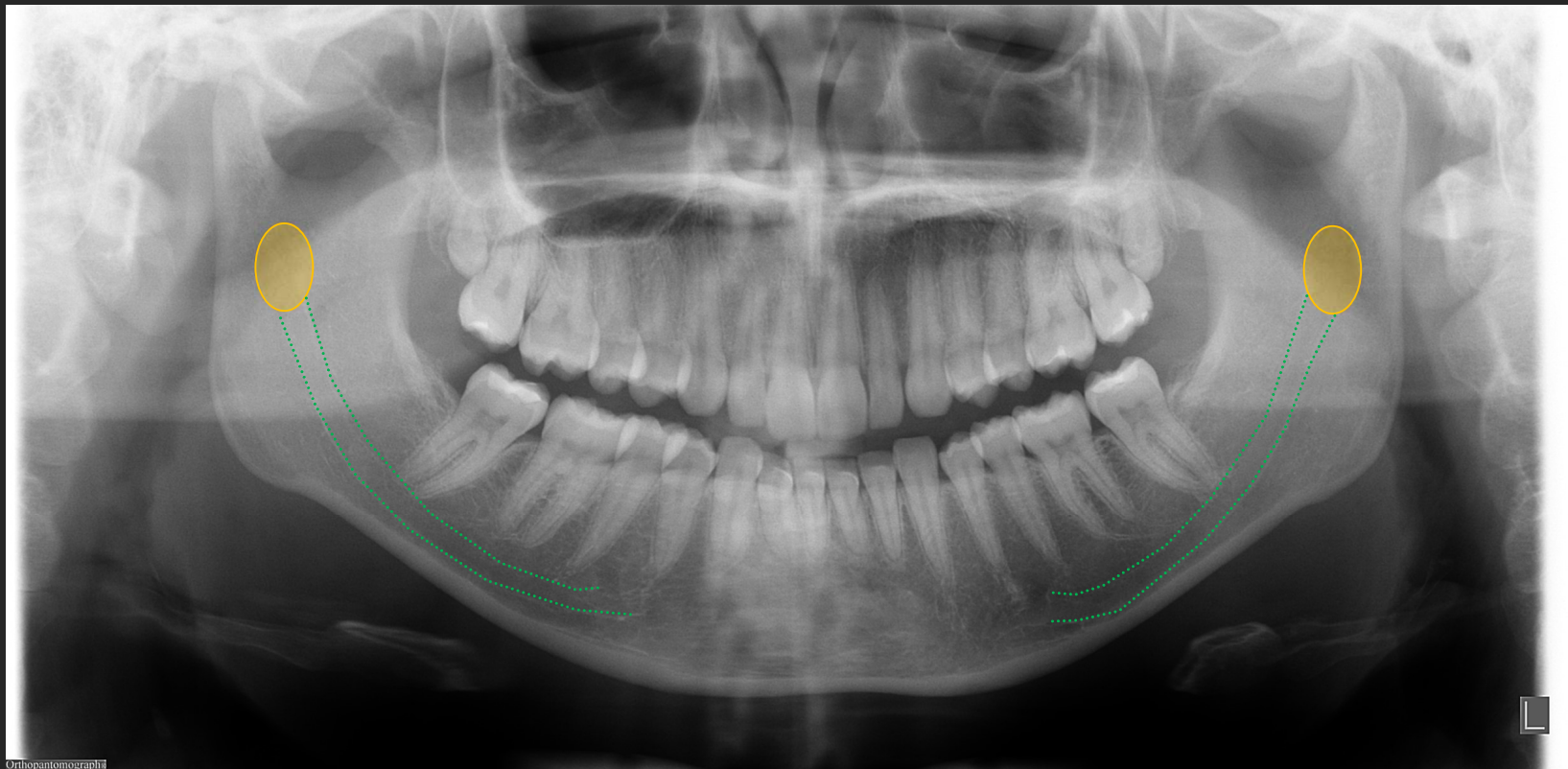
- Forame da mandíbula



RADIOGRAFIA PANORÂMICA

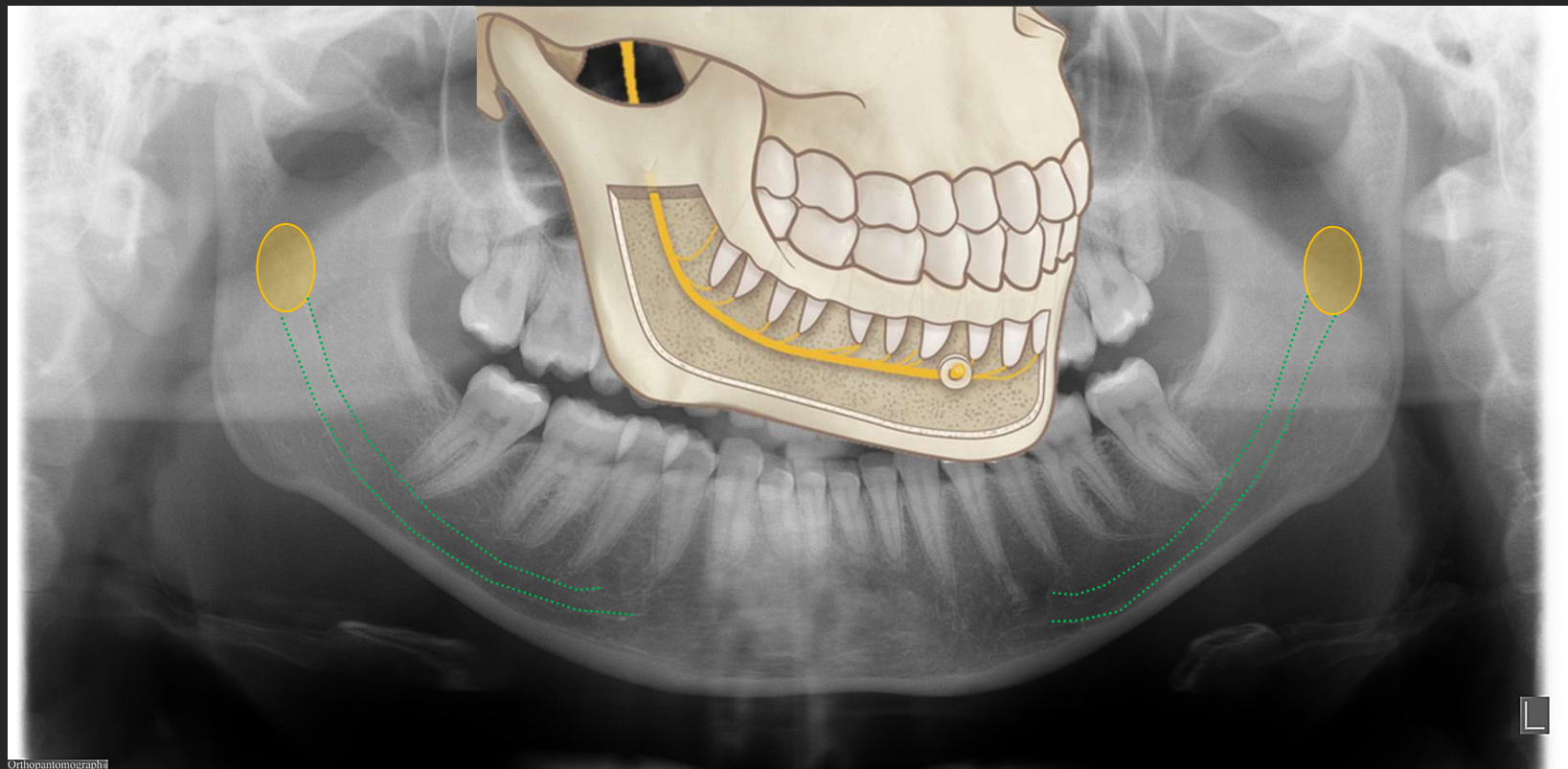
- Forame da mandíbula

- Canal da mandíbula



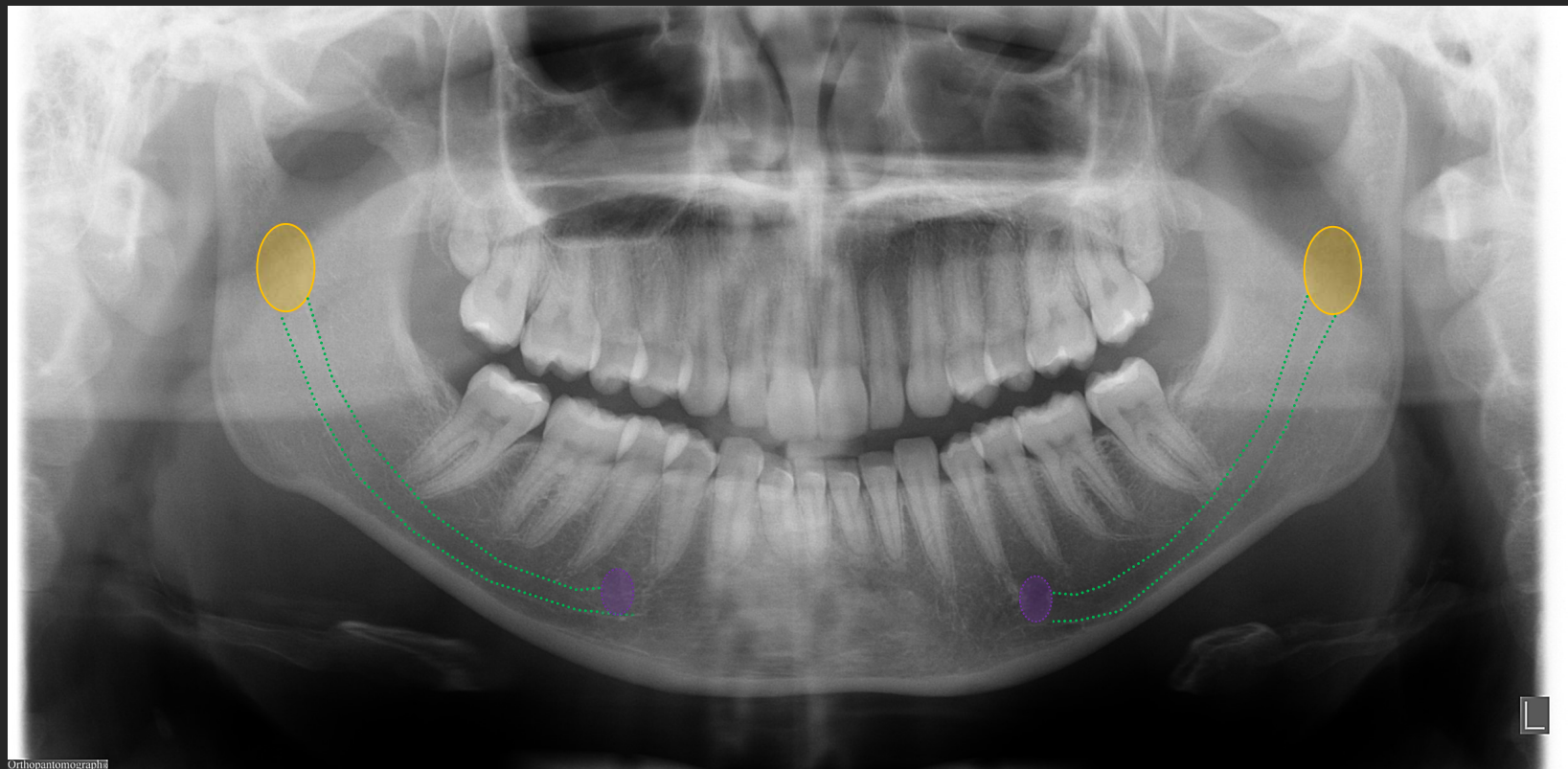
RADIOGRAFIA PANORÂMICA

- Forame da mandíbula
- Canal da mandíbula



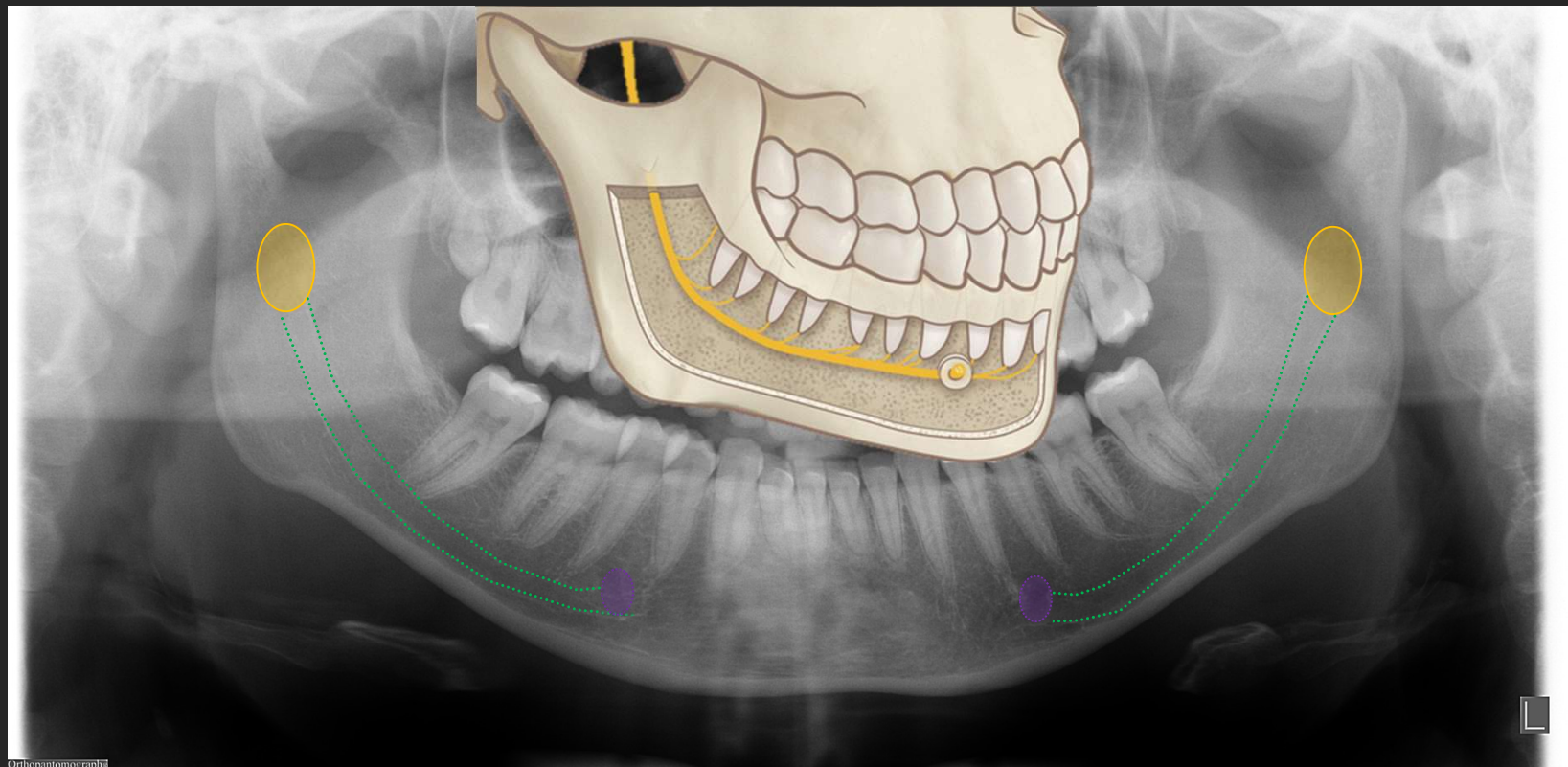
RADIOGRAFIA PANORÂMICA

- Forame da mandíbula
- Canal da mandíbula
- Forame mentoniano



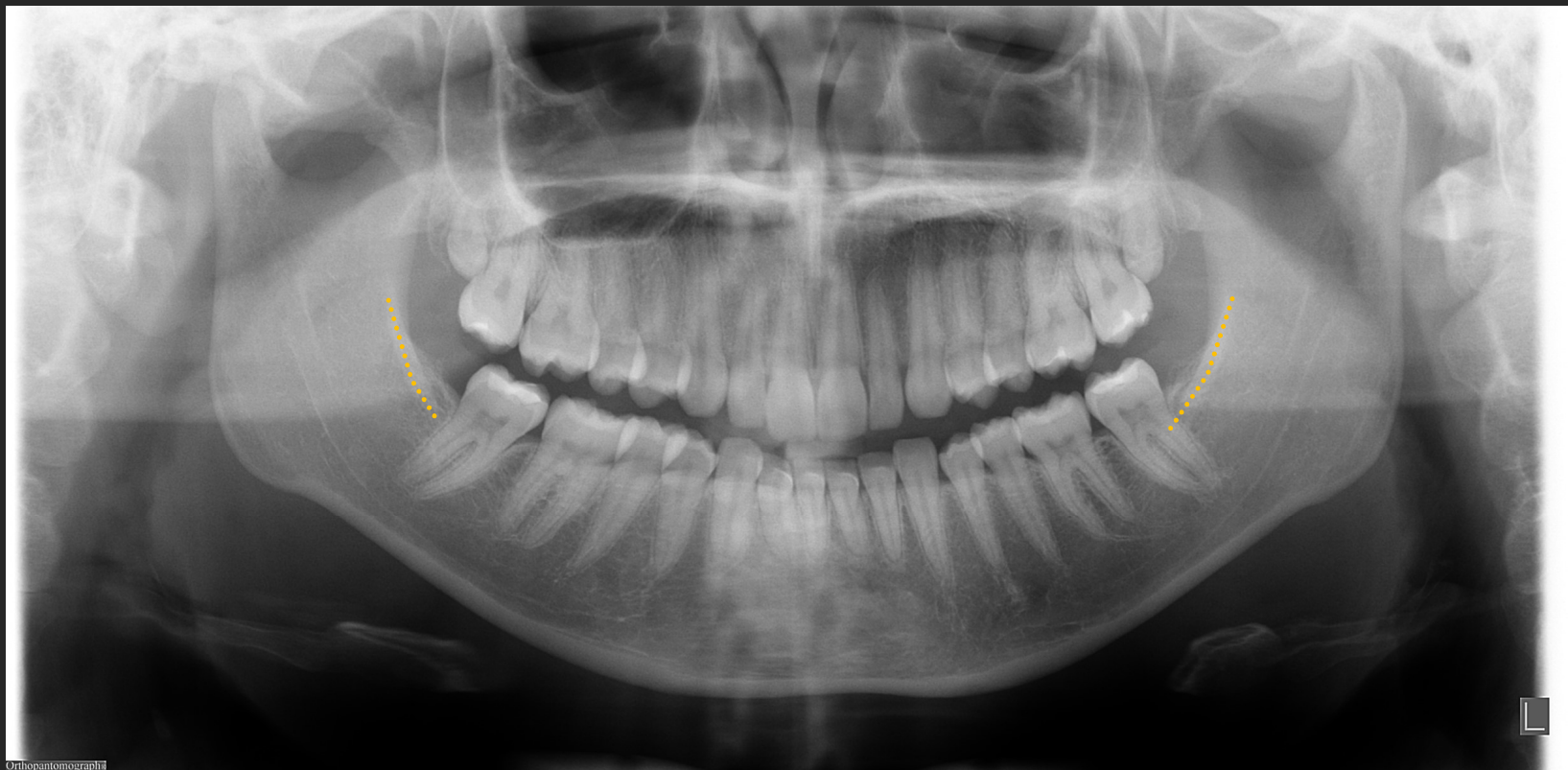
RADIOGRAFIA PANORÂMICA

- Forame da mandíbula
- Canal da mandíbula
- Forame mentoniano



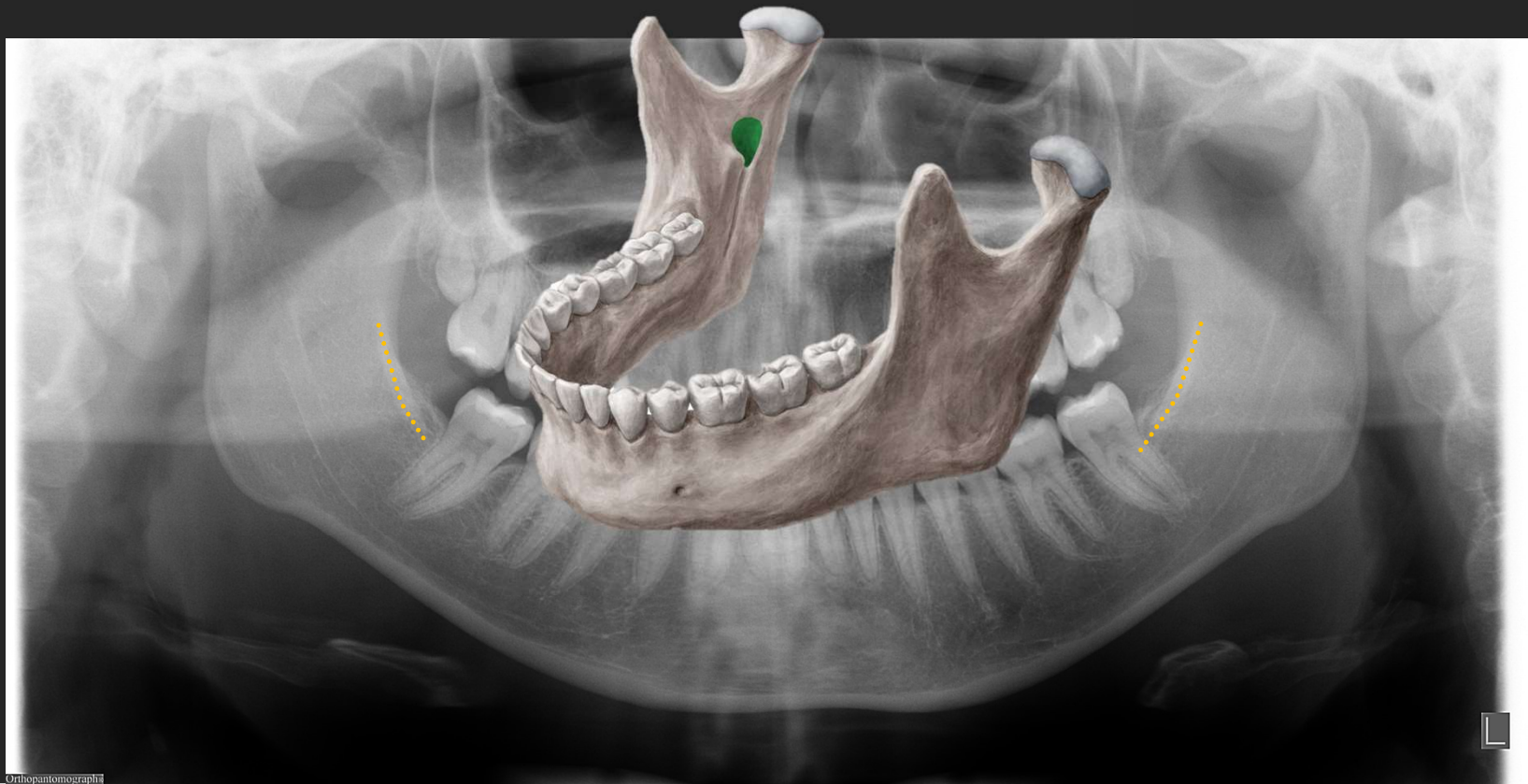RADIOGRAFIA PANORÂMICA

- Linha oblíqua



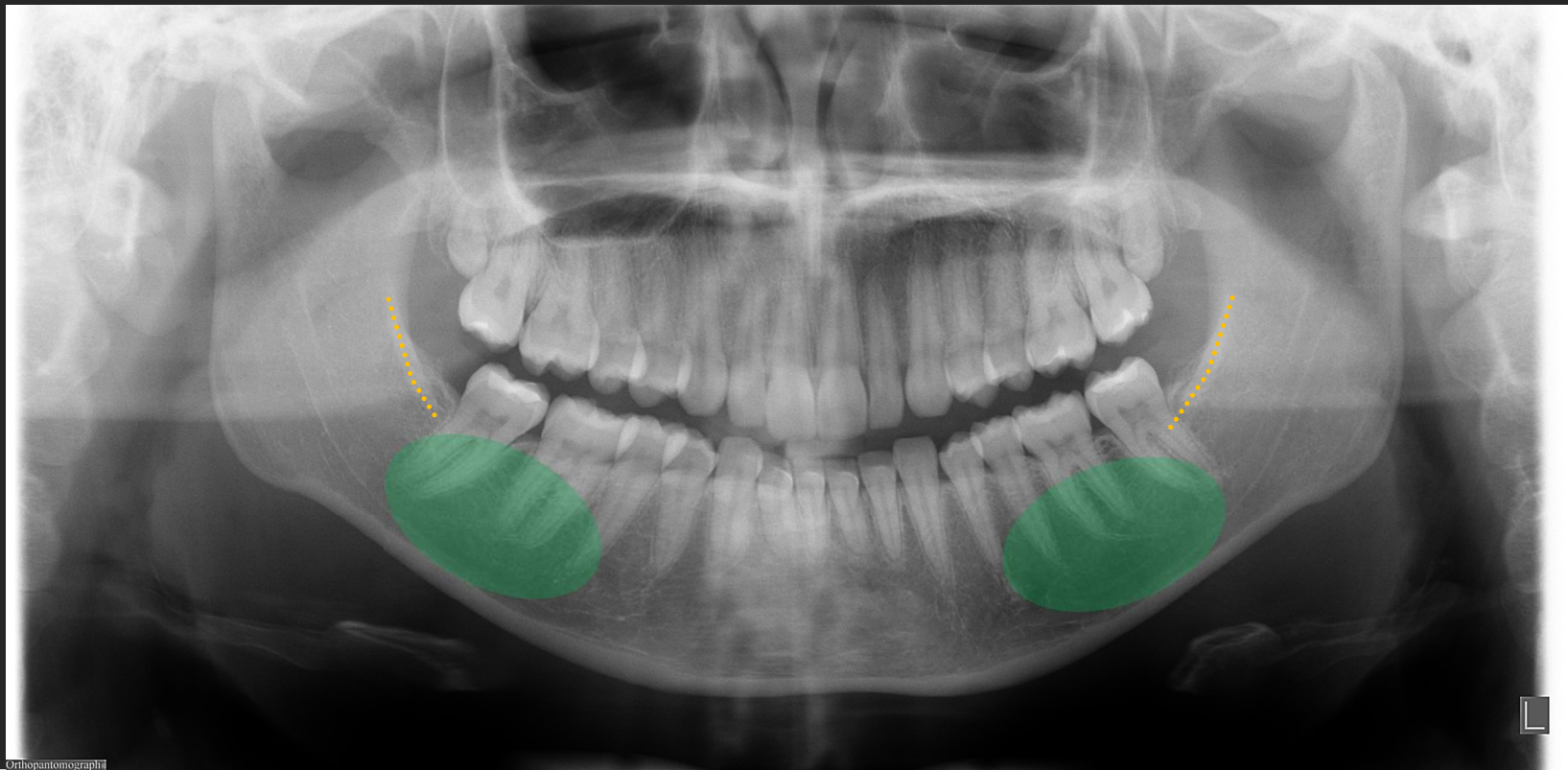
RADIOGRAFIA PANORÂMICA

- Linha oblíqua



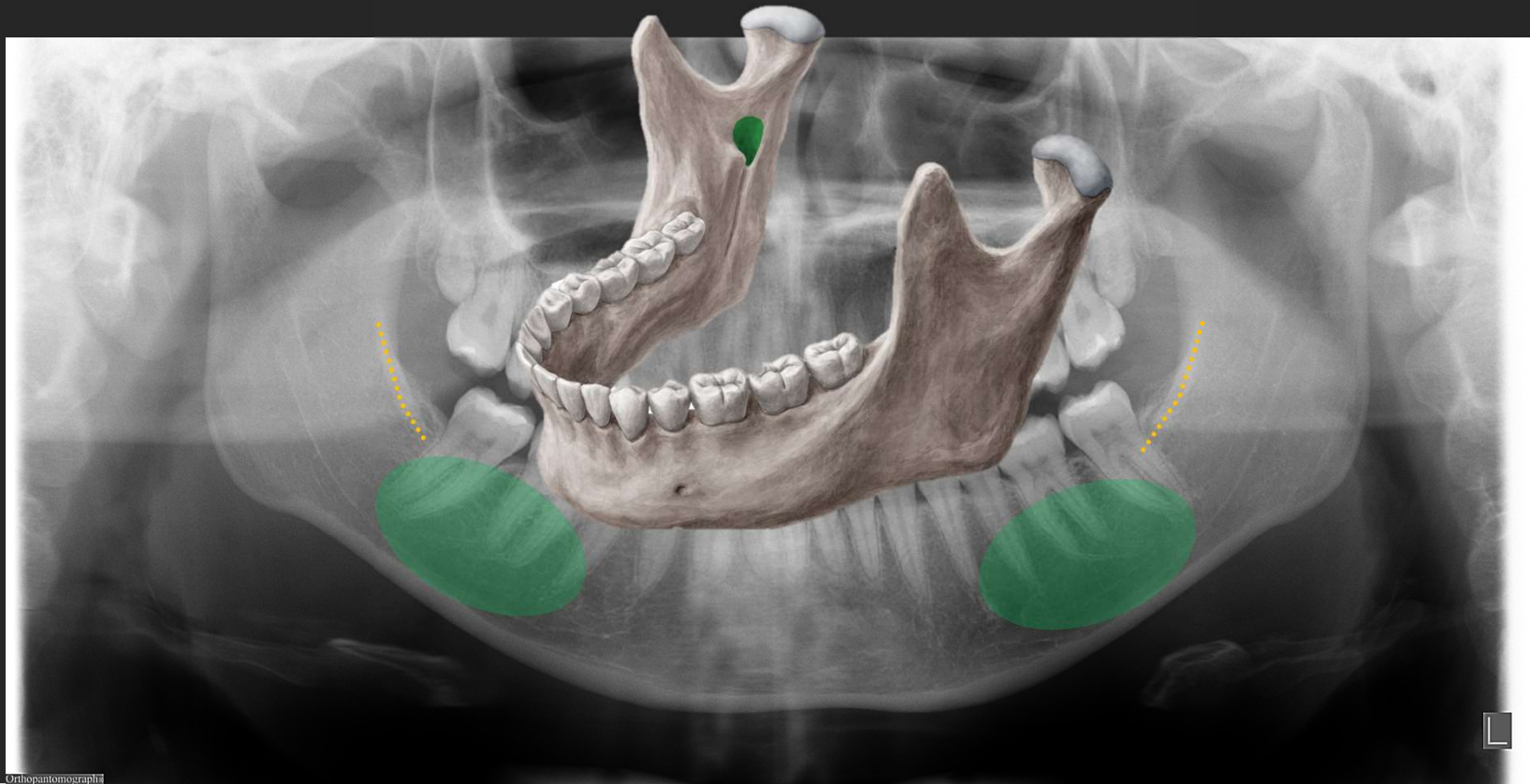
RADIOGRAFIA PANORÂMICA

- Linha oblíqua
- Fóvea submandibular

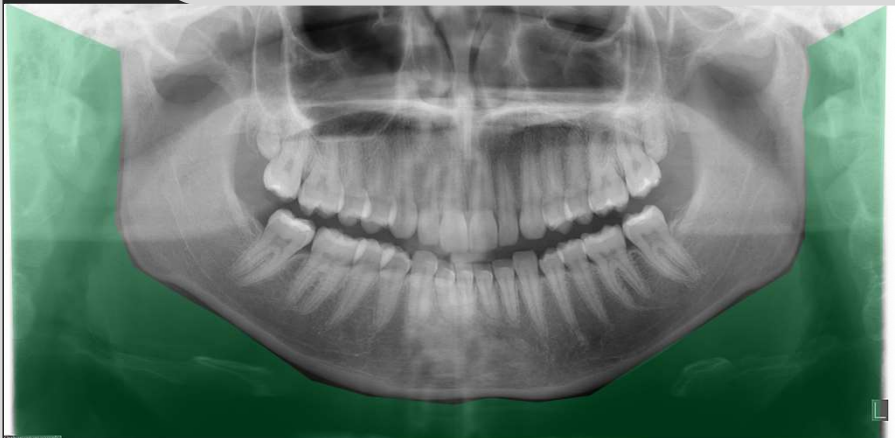

RADIOGRAFIA PANORÂMICA

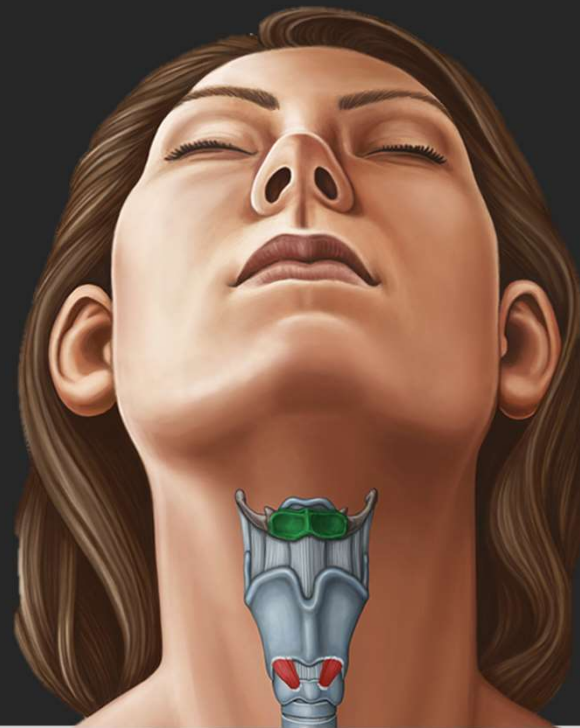
- Linha oblíqua
- Fóvea submandibular



RADIOGRAFIA PANORÂMICA

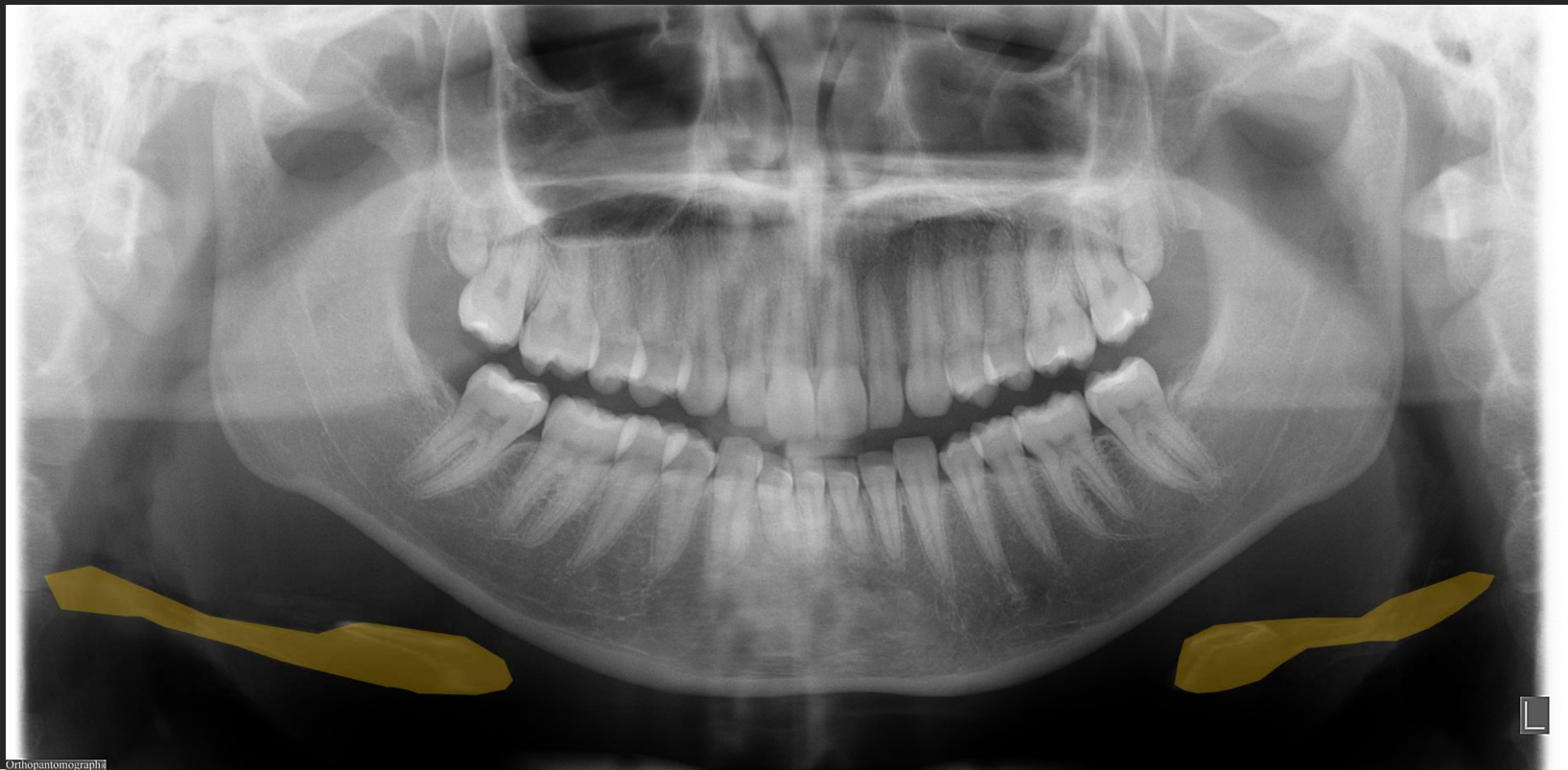

Espaço paravertebral



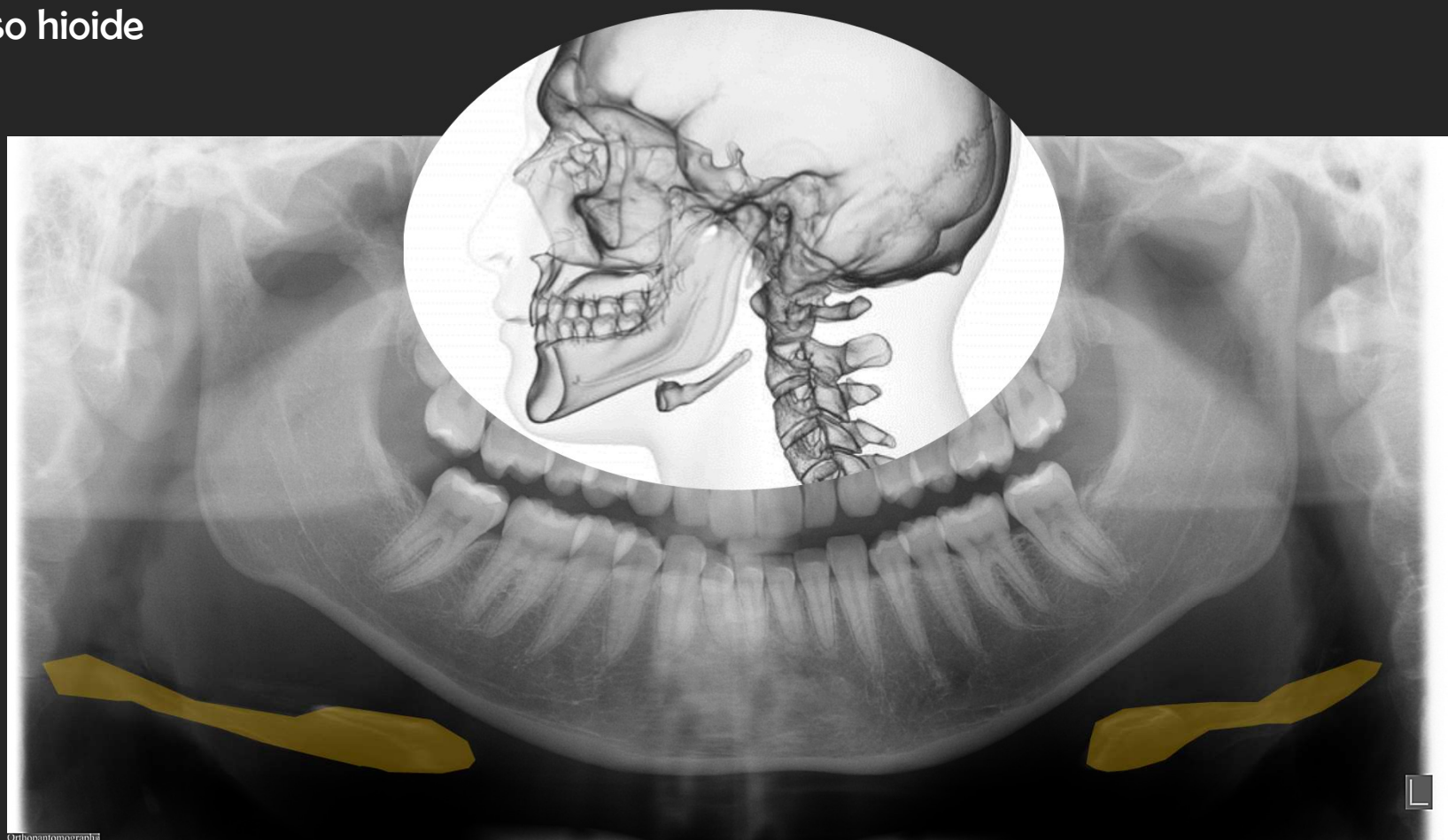
RADIOGRAFIA PANORÂMICA

- Osso hioide



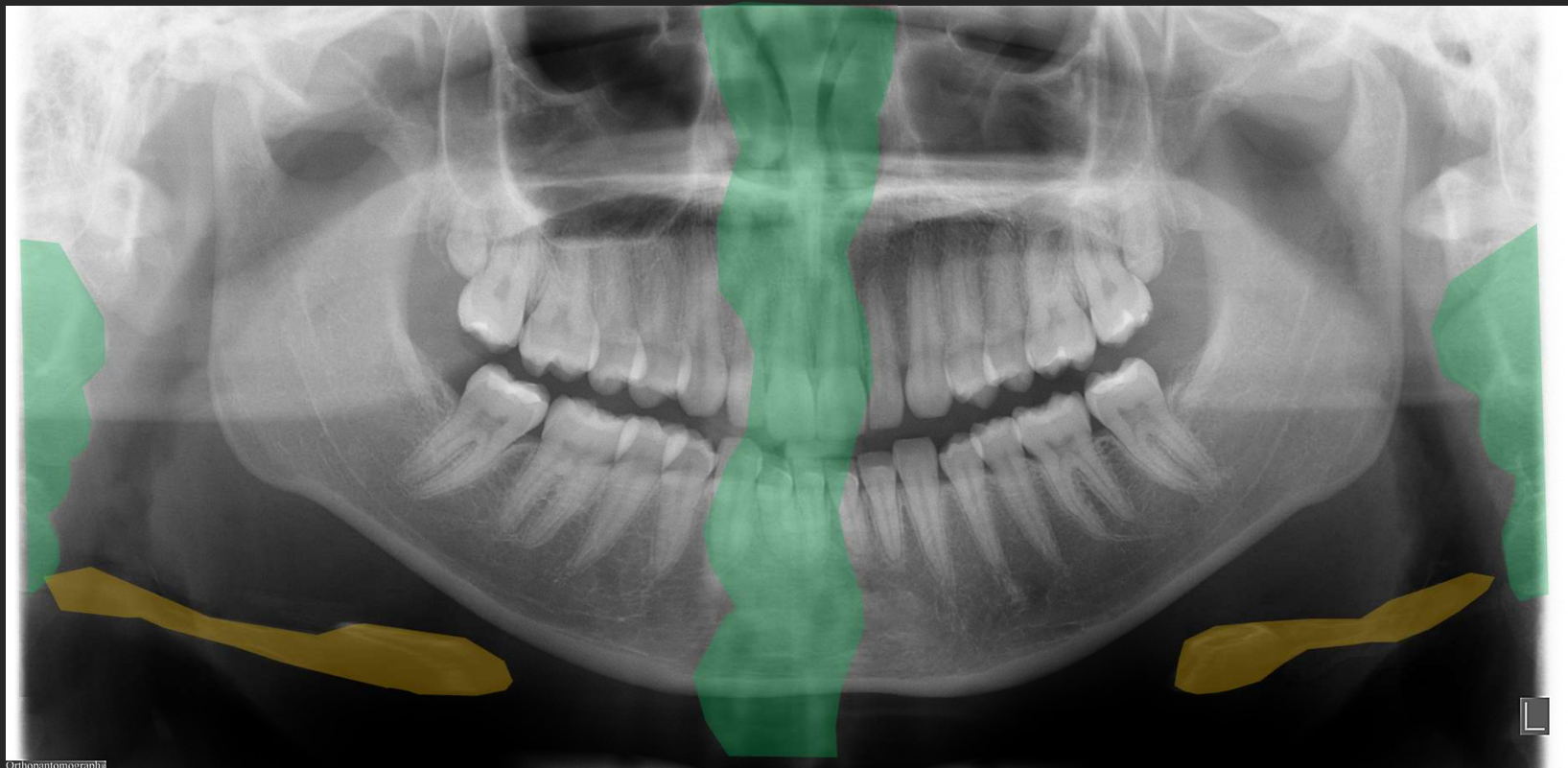
RADIOGRAFIA PANORÂMICA

- Osso hioide



RADIOGRAFIA PANORÂMICA

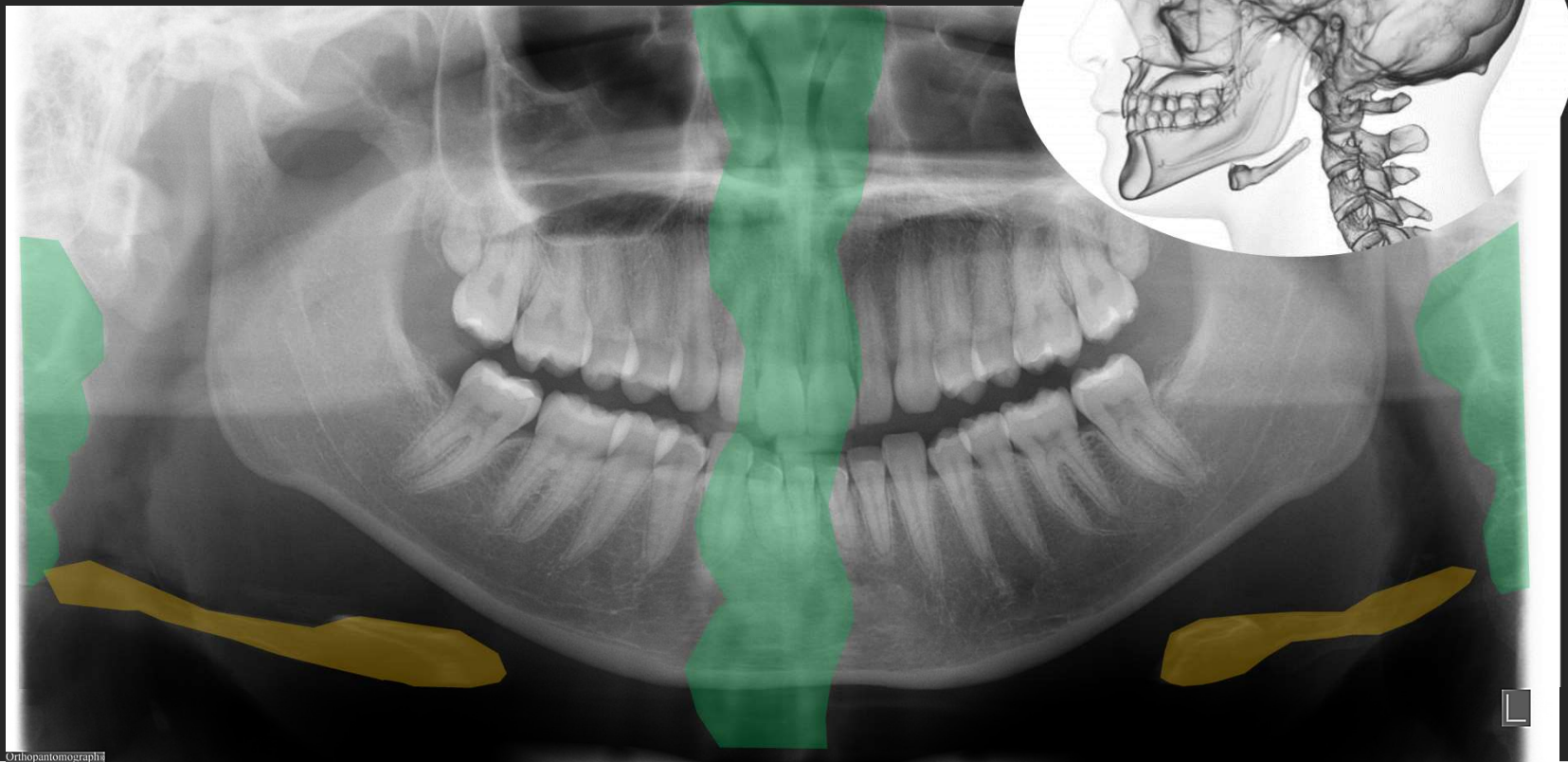
- Osso hioide
- Vértebras cervicais



RADIOGRAFIA PANORÂMICA

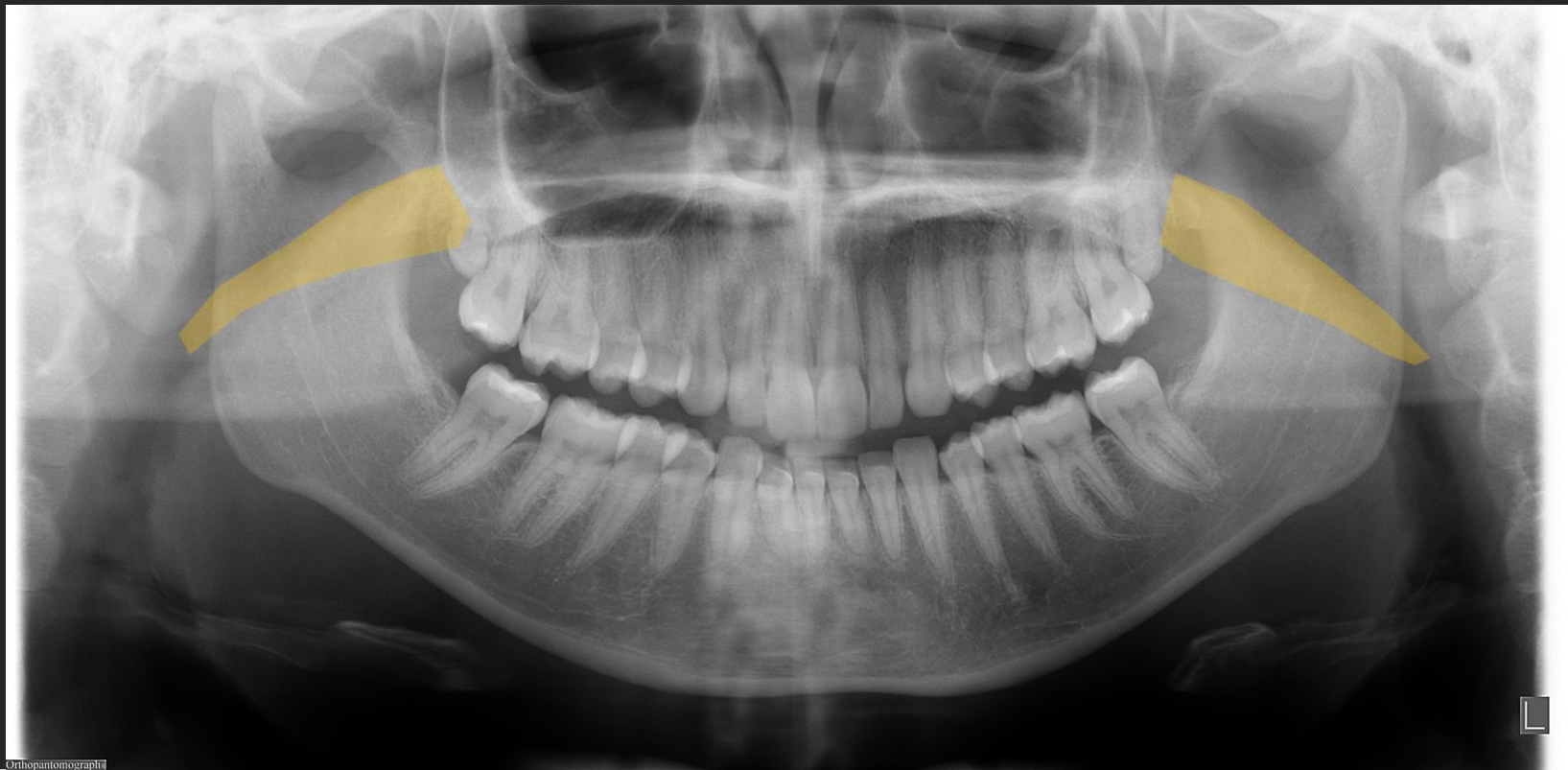
- Osso hioide

- Vértebras cervicais



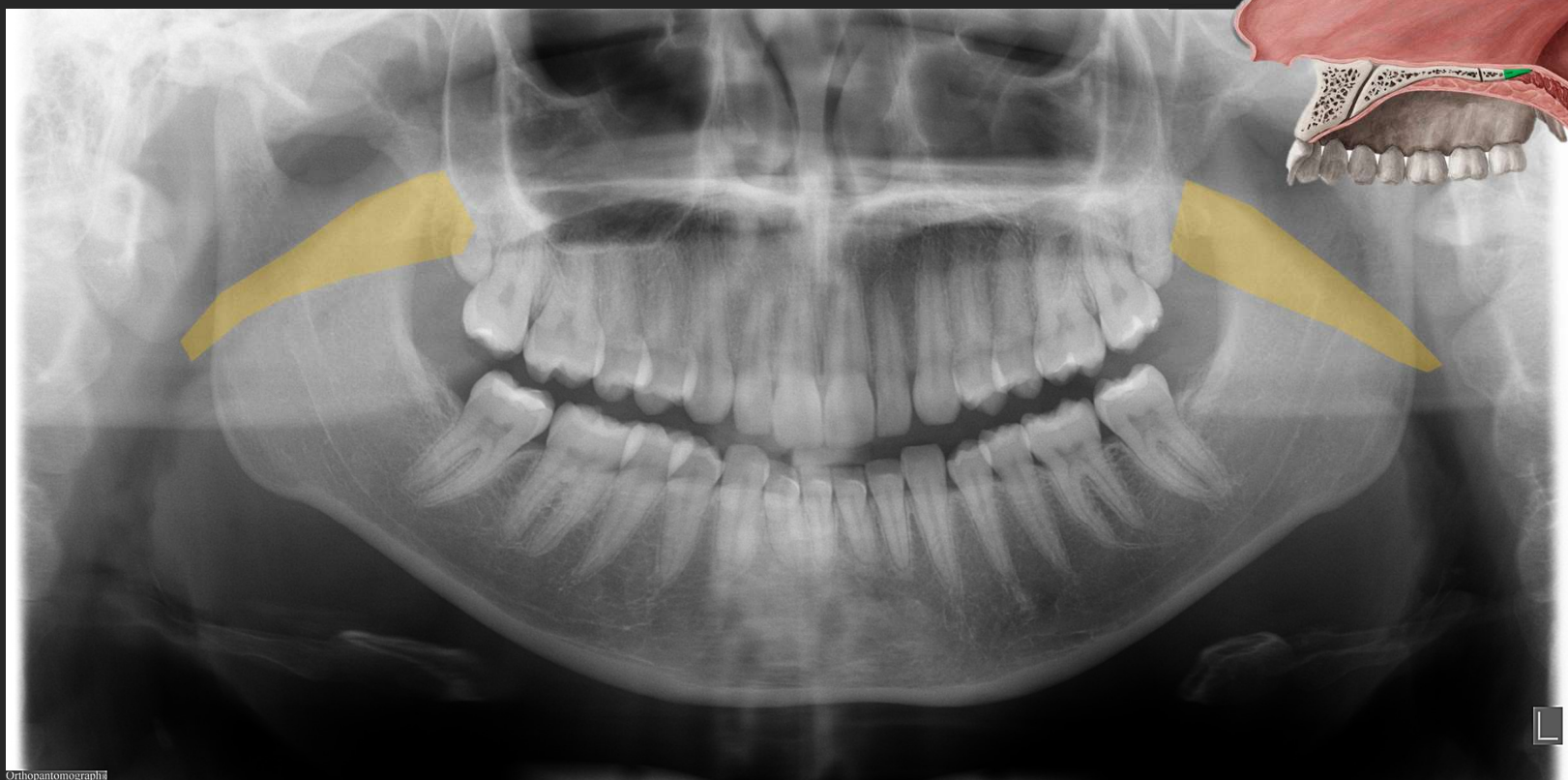
RADIOGRAFIA PANORÂMICA

- Palato mole



RADIOGRAFIA PANORÂMICA

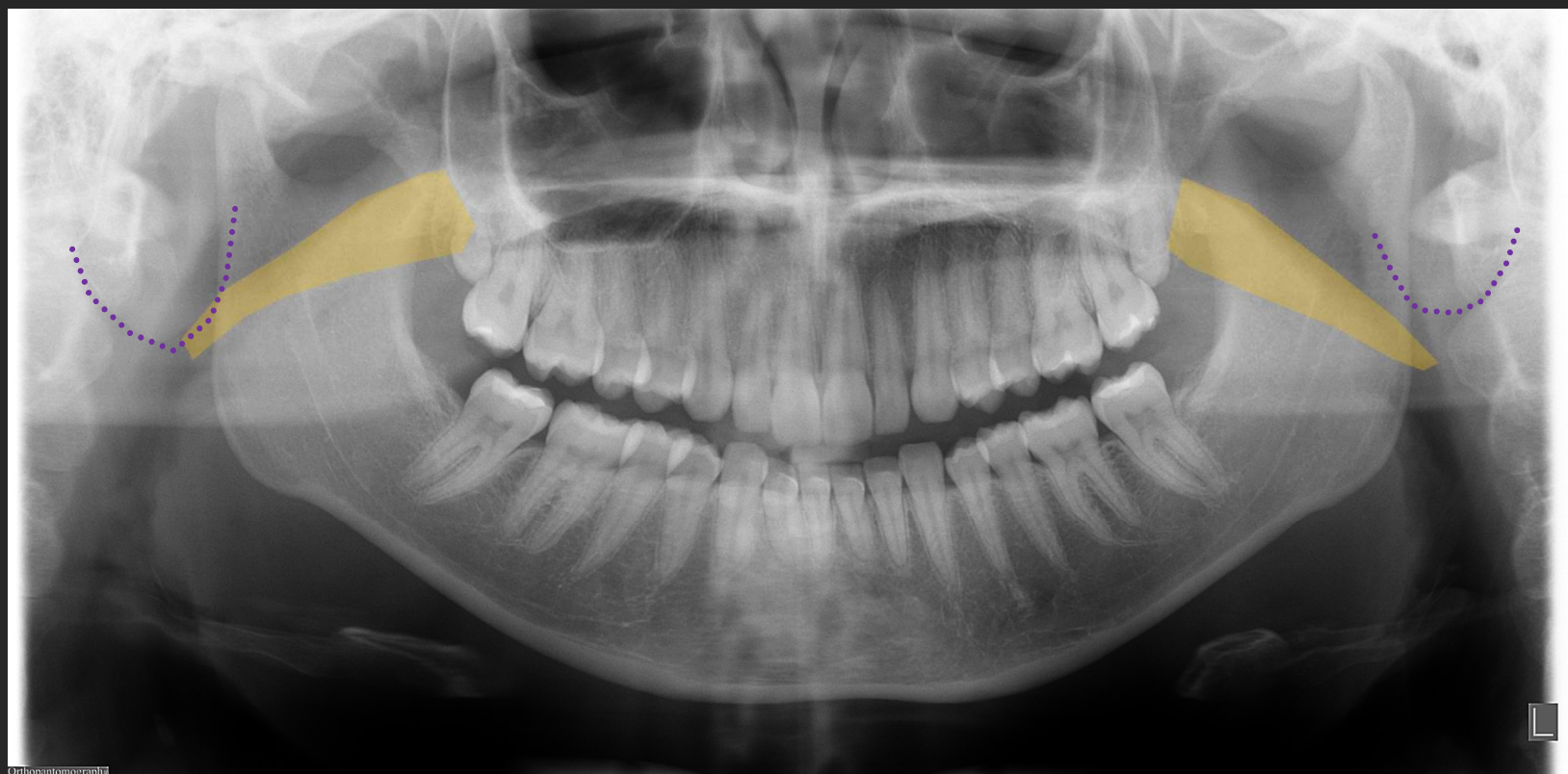
- Palato mole



RADIOGRAFIA PANORÂMICA

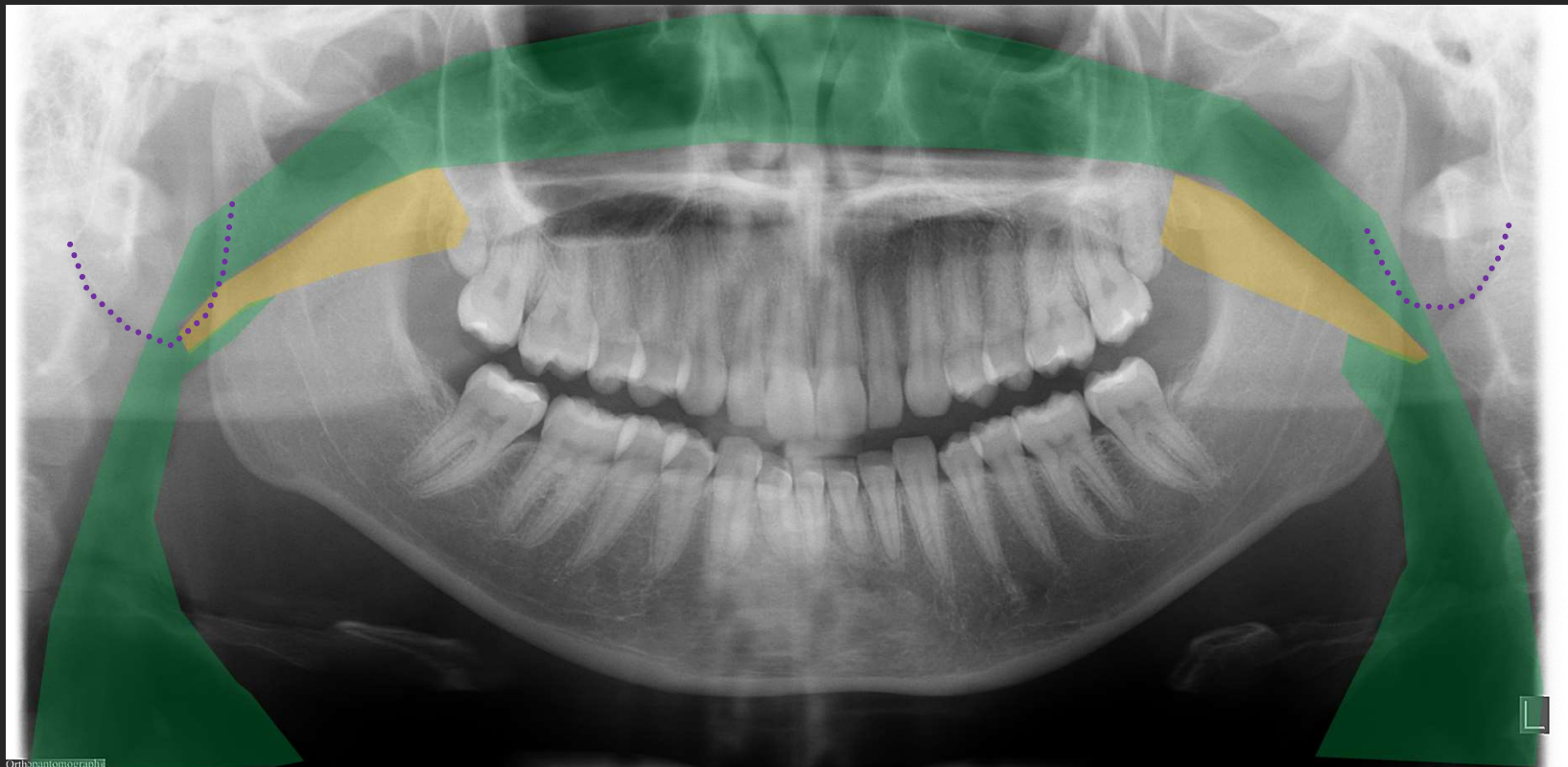
- Palato mole

- Lóbulo da orelha



RADIOGRAFIA PANORÂMICA

- Palato mole
- Espaço aéreo
- Lóbulo da orelha

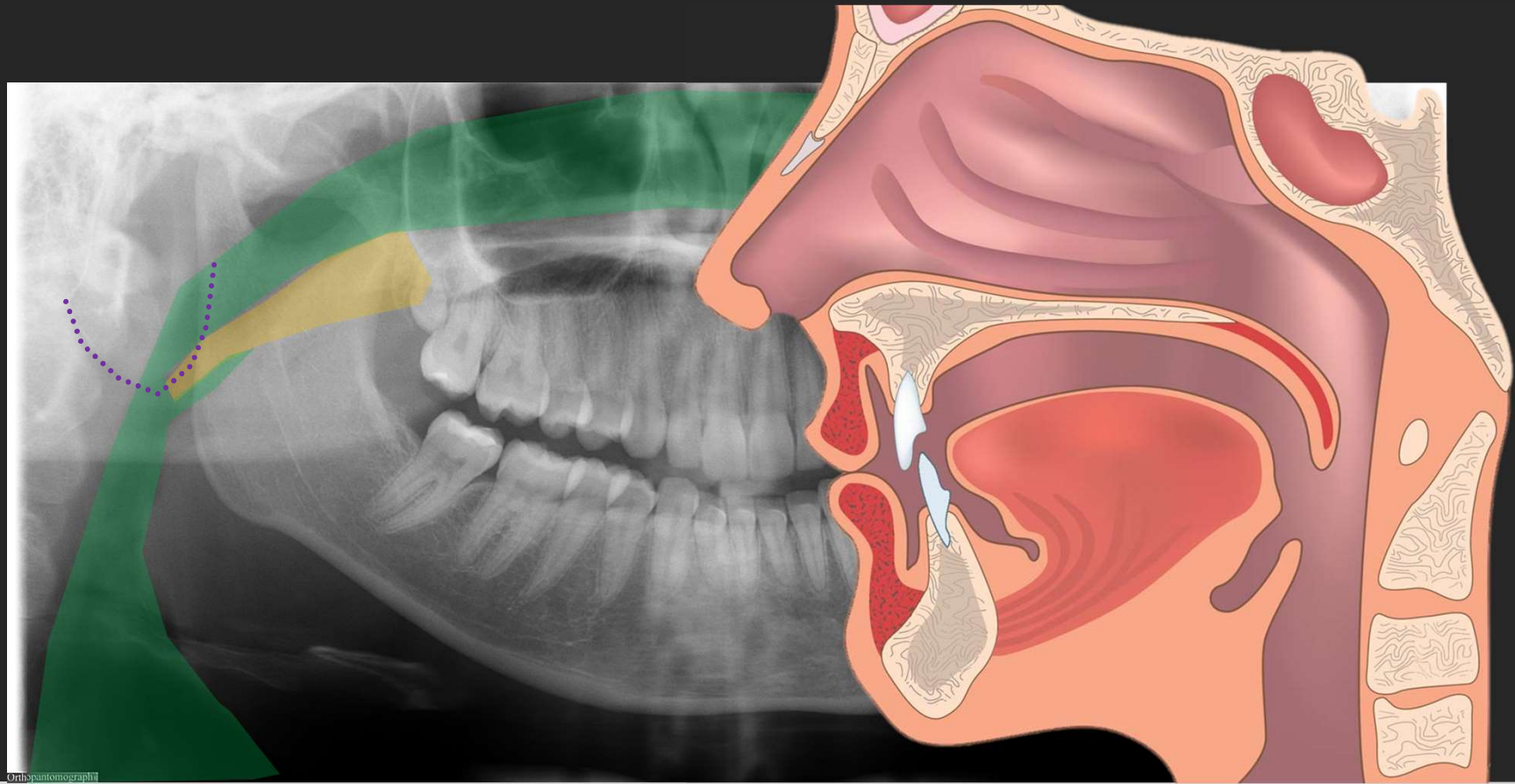


RADIOGRAFIA PANORÂMICA

• Palato mole

• Espaço aéreo

• Lóbulo da orelha



Orthopantomographi

RADIOGRAFIA PANORÂMICA

- Palato mole

- Espaço aéreo

- Lóbulo da orelha

