



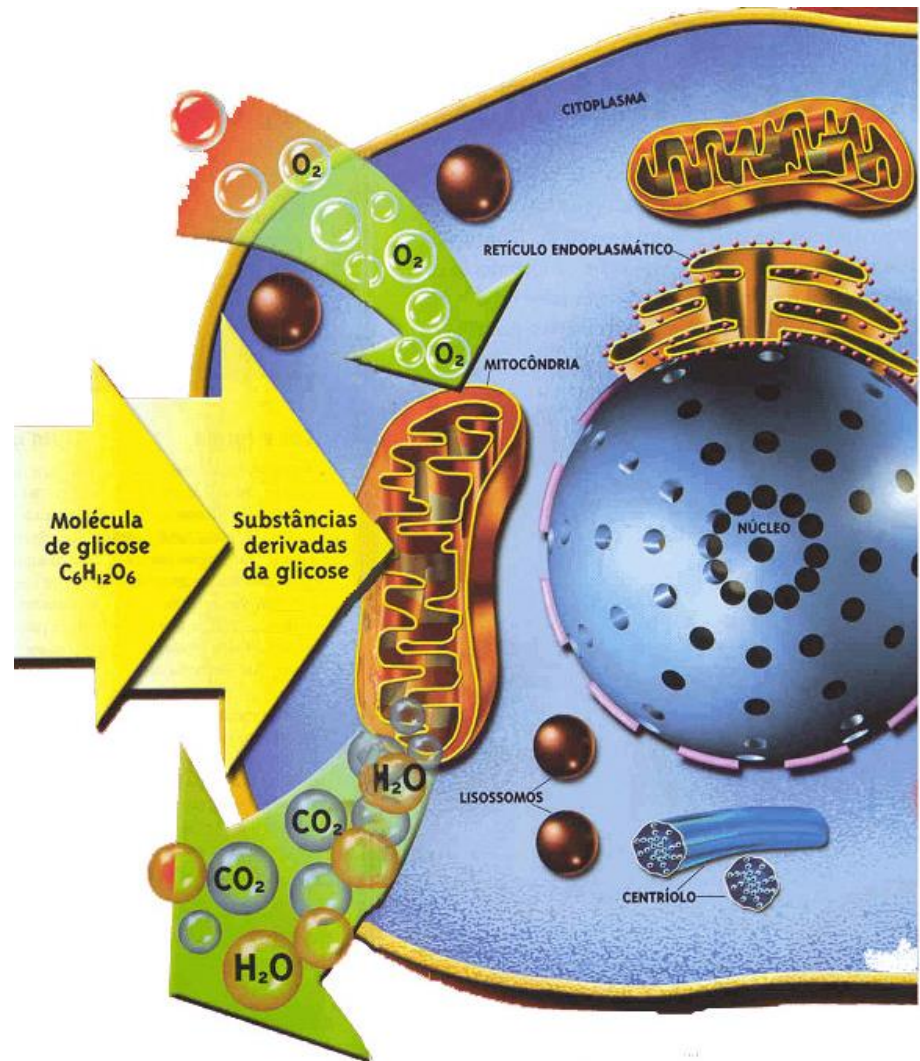
Sistema Cardiovascular

VCI – 1201 – Anatomia Descritiva dos Animais Domésticos II

Profa. Dra. Tais Harumi de Castro Sasahara
Depto de Cirurgia – Setor de Anatomia
FMVZ-USP

- Transporte de **oxigênio** e **substâncias nutritivas** para as células.
- **Remoção** de **dióxido de carbono** e de **substâncias tóxicas** das células.

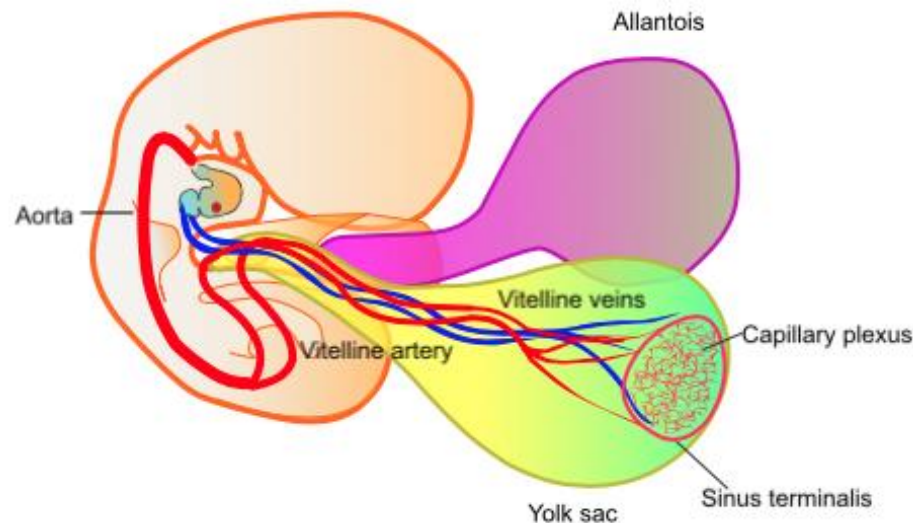
Atividade vital



Circulação

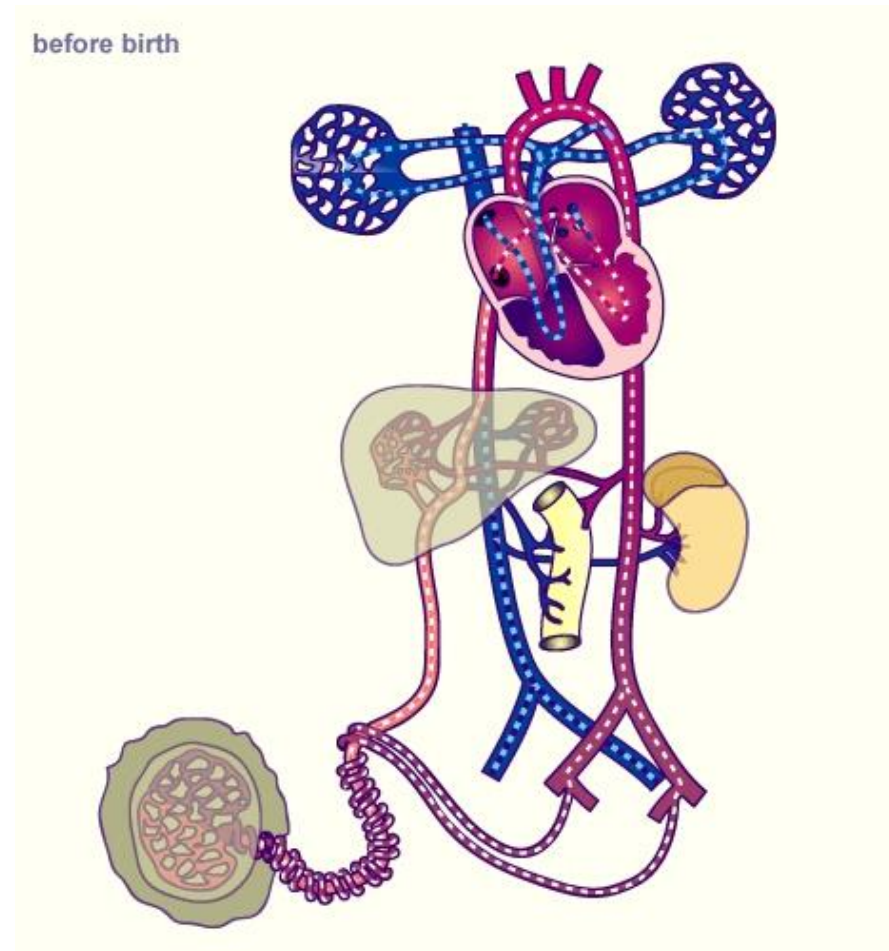
Circulação vitelina

- Com a formação do embrião se estabelece a **circulação vitelina**, a nutrição passa a ser realizada pelo **SACO VITELINO**.



Circulação fetal

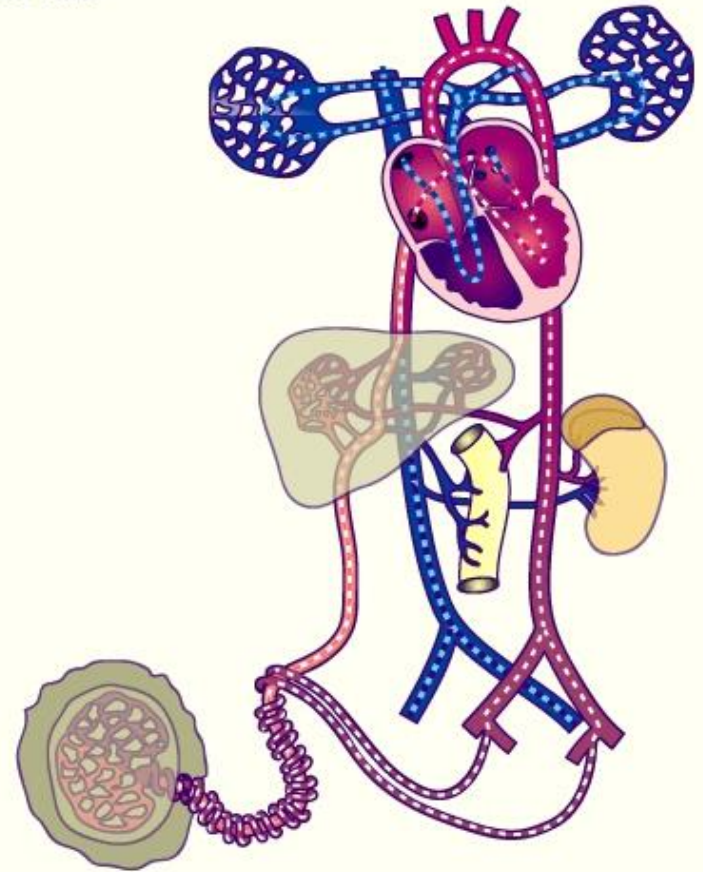
- Com o desenvolvimento embrionário e a formação do feto surge a **CIRCULAÇÃO FETAL**, o feto então passa a se nutrir, de agora em diante, dos elementos que vem da própria mãe e essa **nutrição** é feita pela **placenta** a qual une o organismo fetal à mãe.



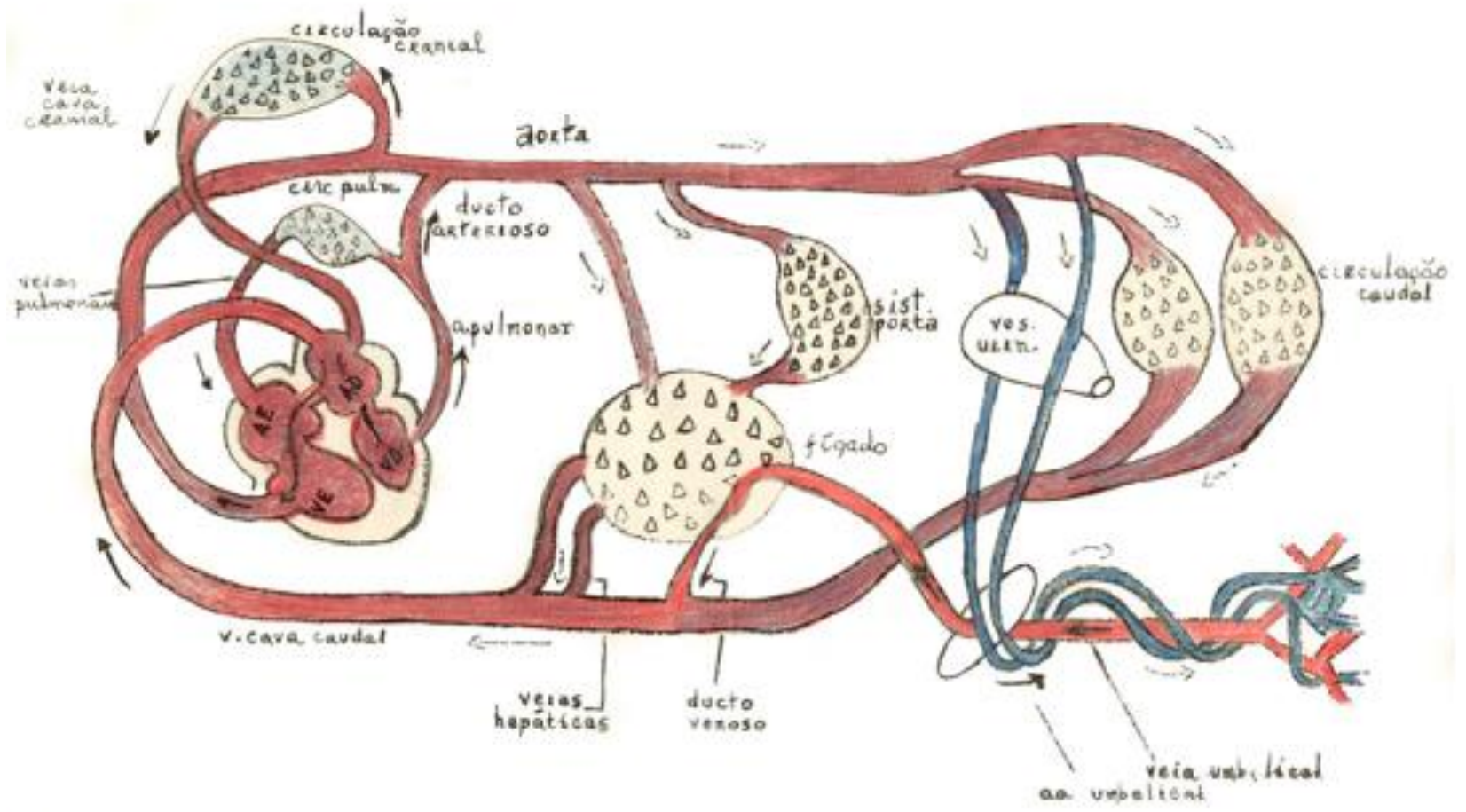
Circulação fetal

- Nutrientes e oxigênio – **v. umbilical**
- Remoção de resíduos do metabolismo – **aa umbilicais**

before birth

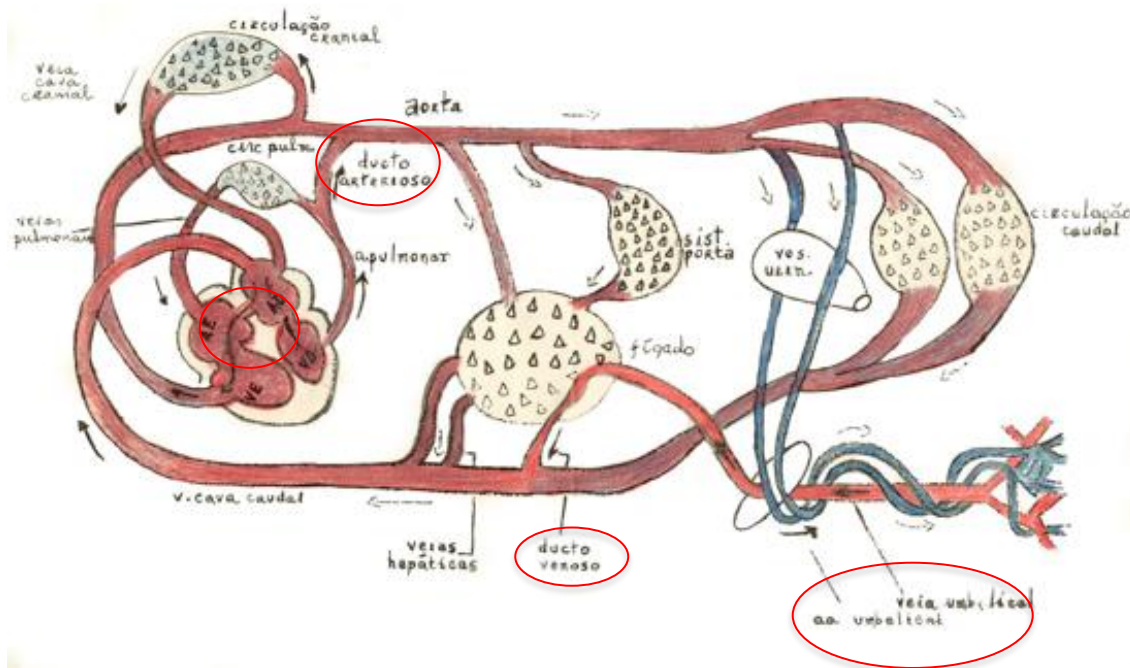


Introdução



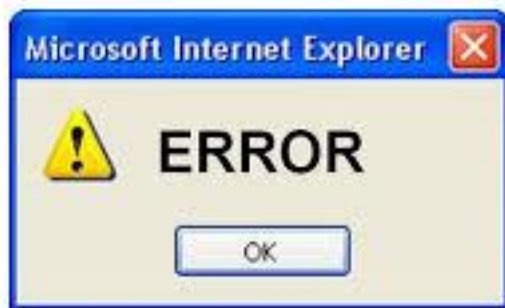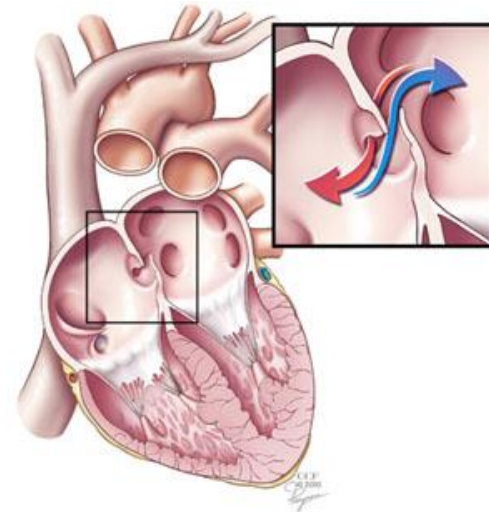
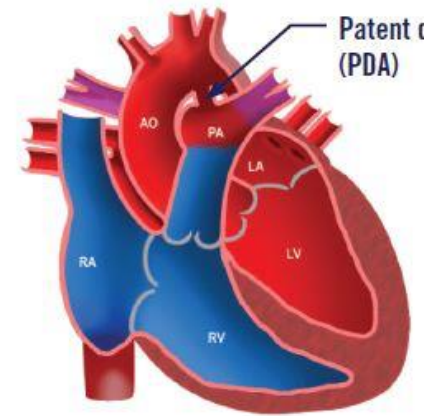
Transição - circulação fetal para a definitiva

- **Artérias umbilicais** – ligamento redondo da bexiga
- **Veia umbilical** – Ligamento redondo do fígado
- **Ducto arterioso** – Ligamento arterioso
- **Forame oval** – fossa oval
- **Ducto venoso** – Ligamento venoso do fígado



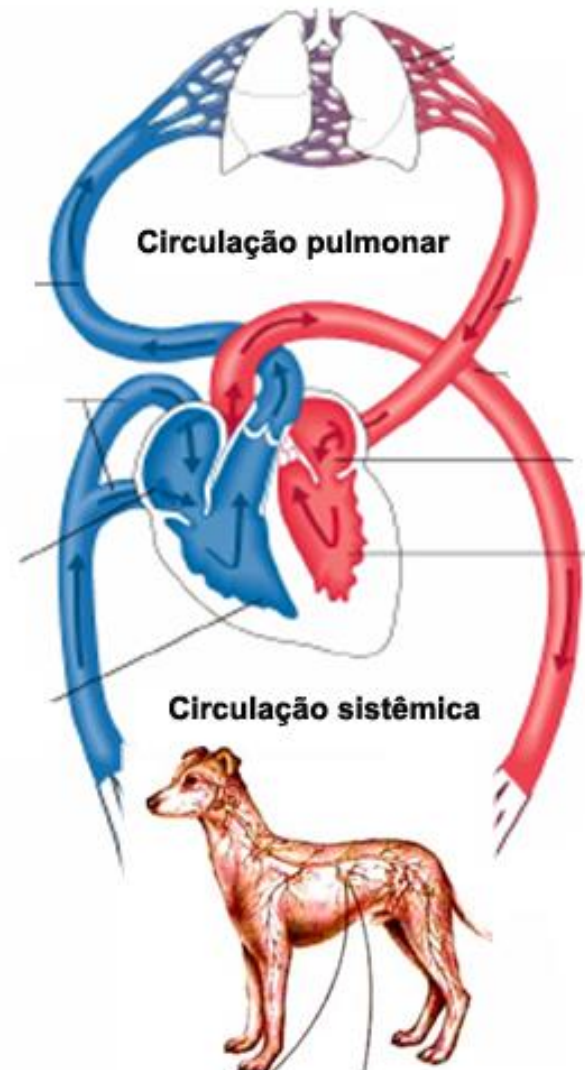
Anormalidades congênitas cardiovasculares

- Persistência do ducto arterioso – cães
- Persistência do forame oval



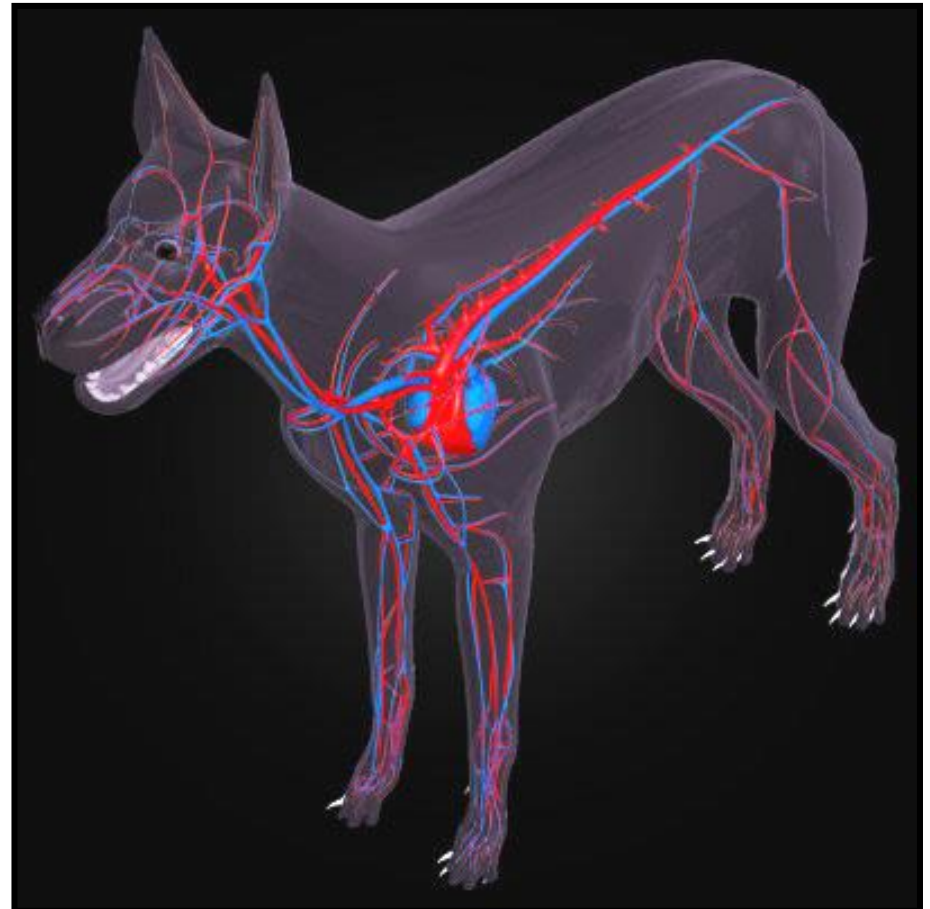
Circulação definitiva

- Circulação fechada, dupla e completa (não há mistura de sangue)
- **Duas bombas:** **direita** e **esquerda** que mantêm o sangue circulante pelo organismo por meio dos vasos sanguíneos.

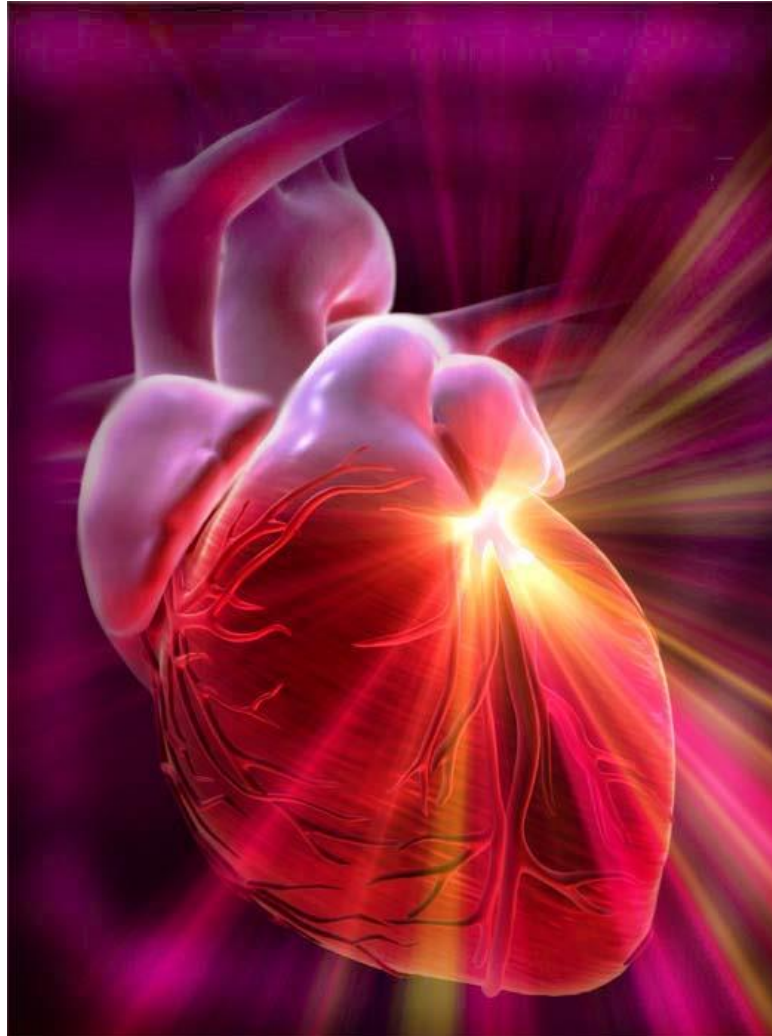

COMPONENTES DO SISTEMA CARDIOVASCULAR

- **Coração**
- **Vasos sanguíneos**
 - Artérias
 - Arteríolas
 - Veias
 - Vênulas
 - Capilares
- **Vasos linfáticos**
- **Sangue**
- **Linha**

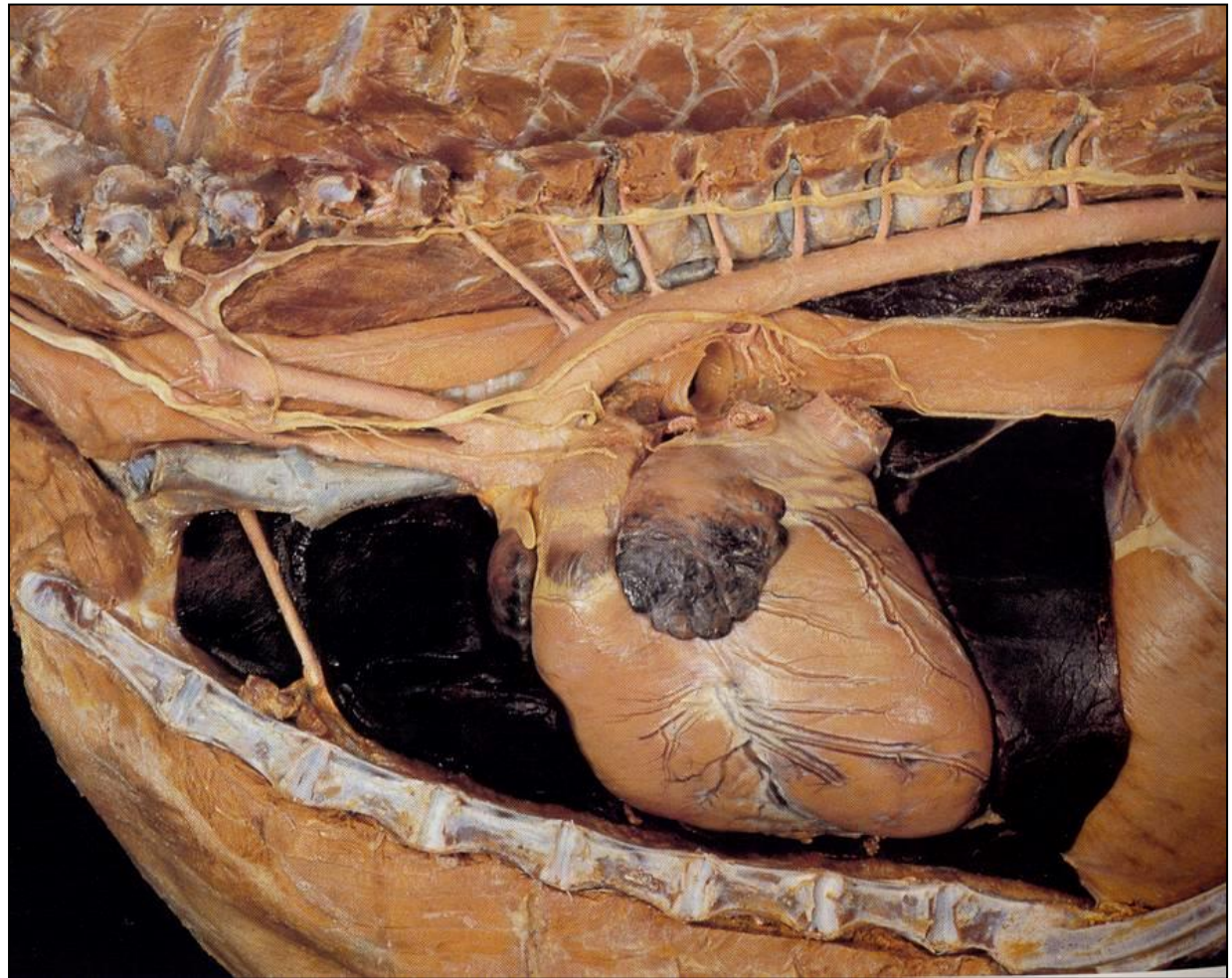


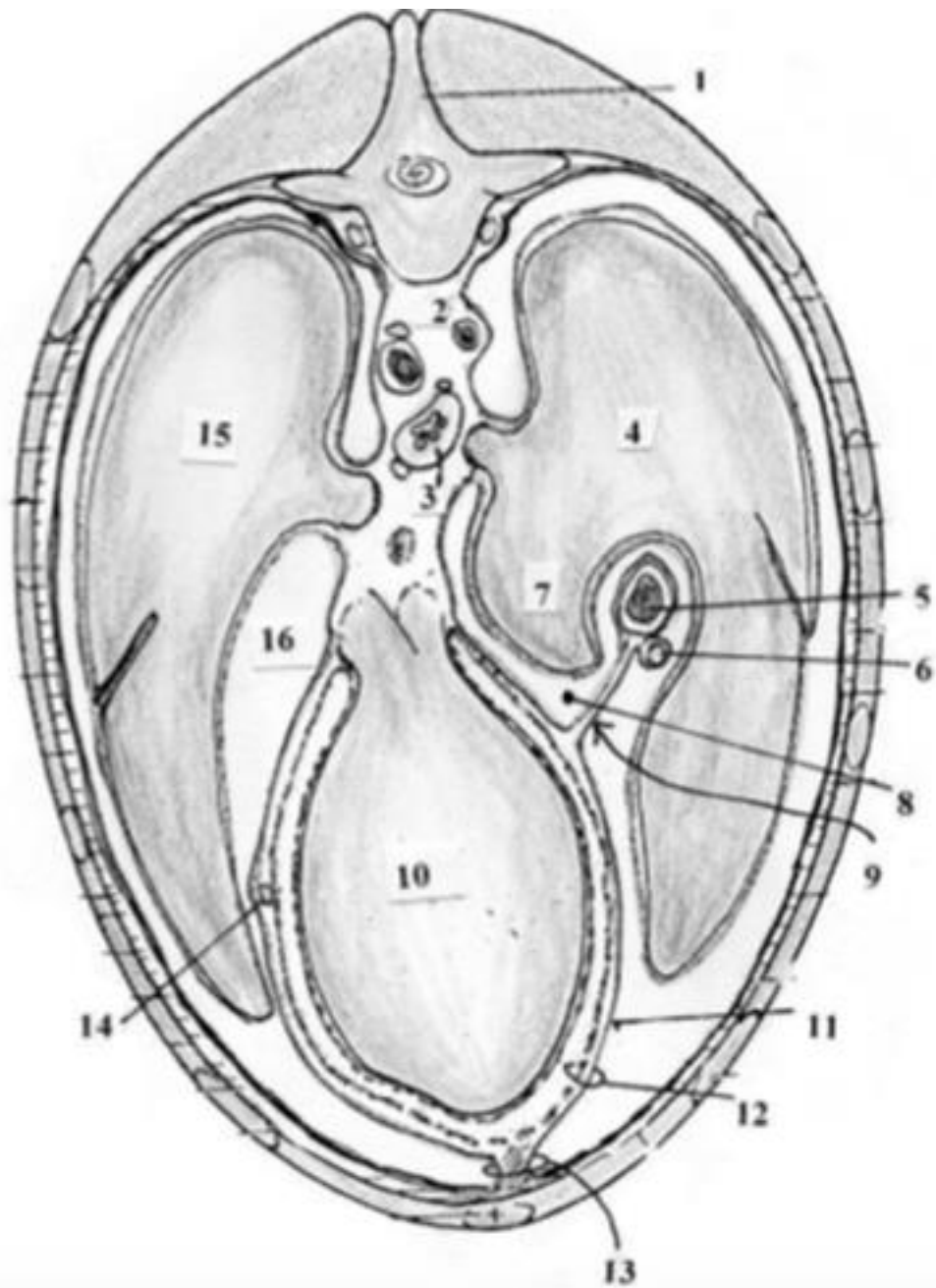
Coração

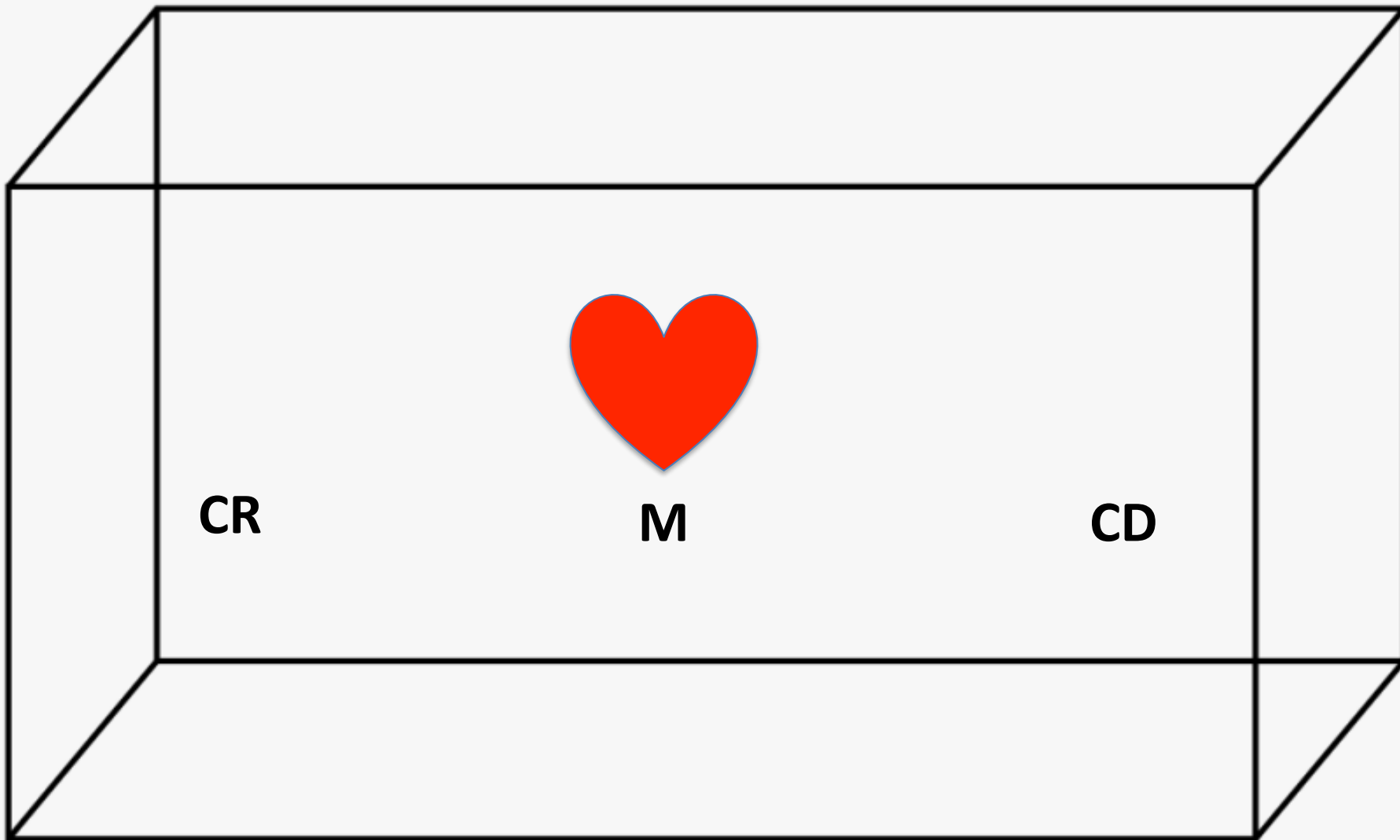


Localização e sintopia

- Cavidade torácica
- Situado no mediastino médio entre os dois pulmões.
- Cranialmente ao diafragma.







CR

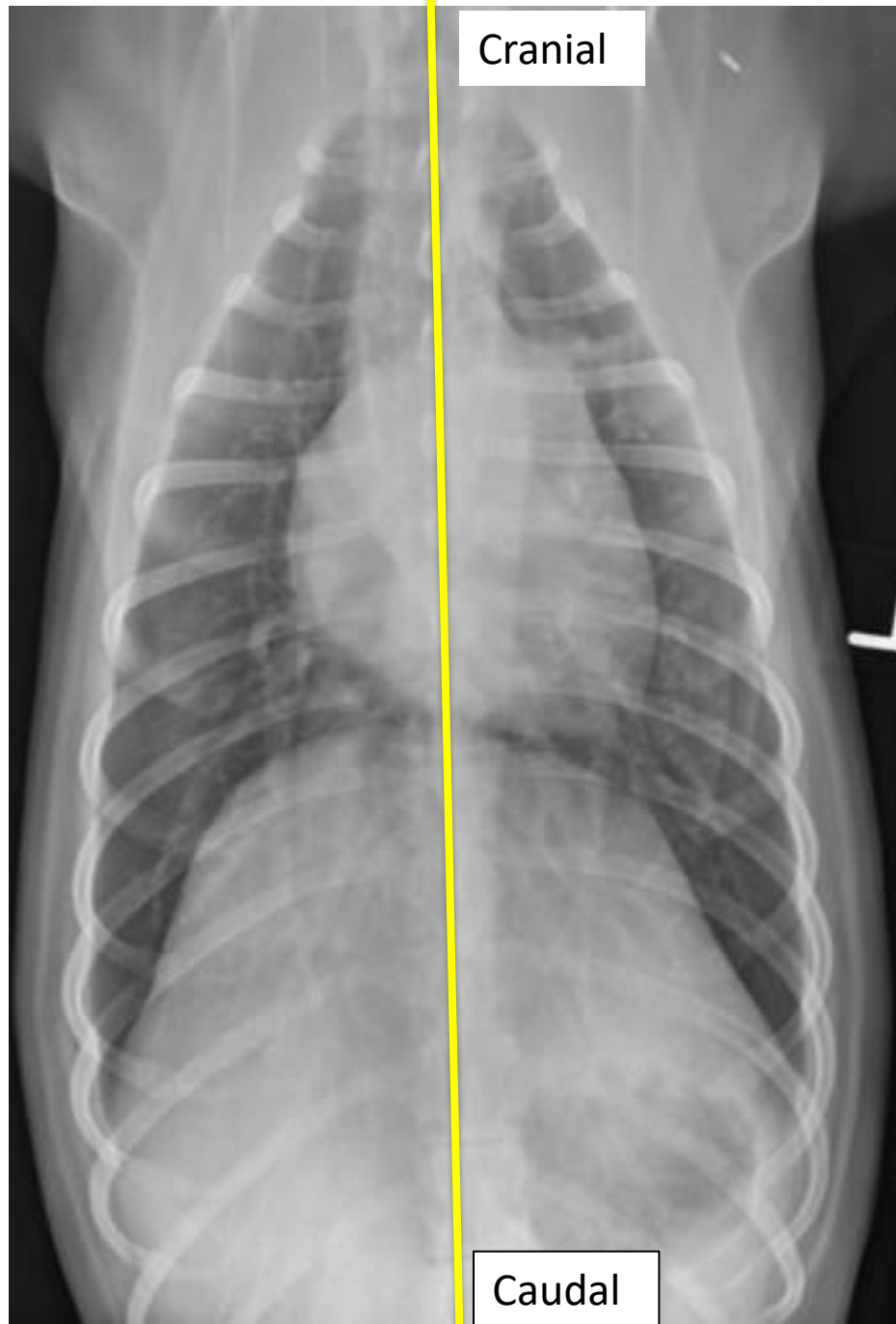
M

CD

CR – cranial

M – médio

CD - caudal



Cranial

Direita

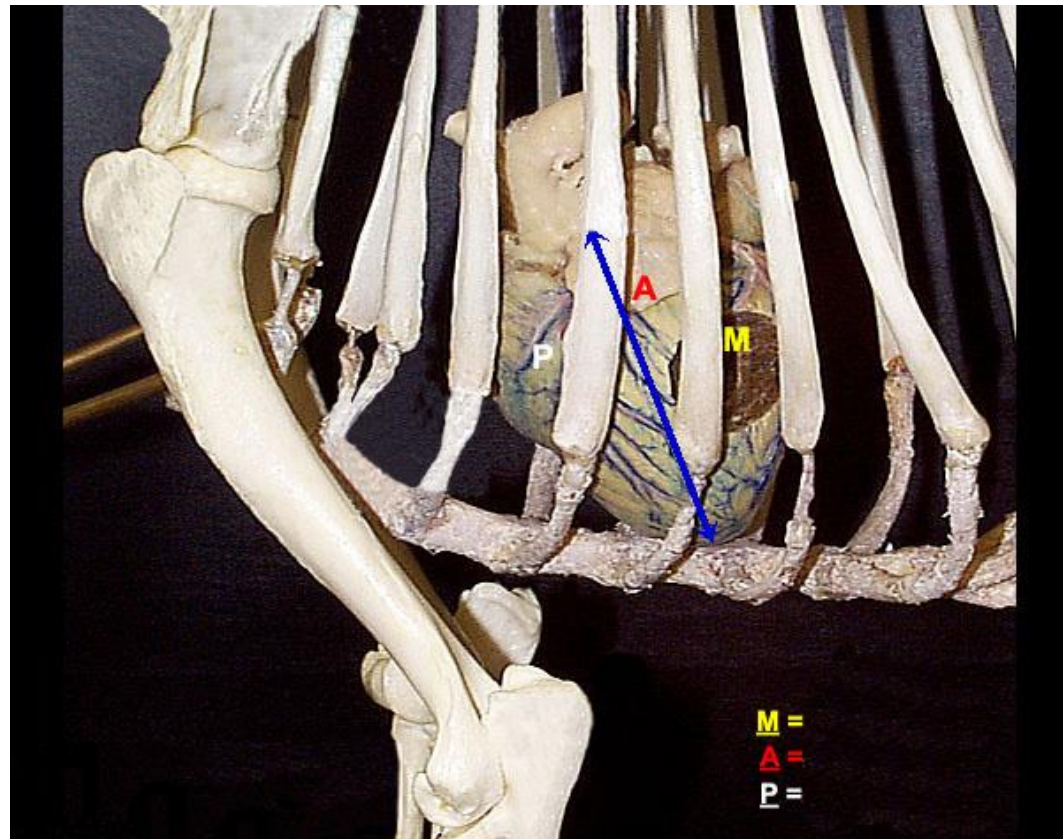
Esquerda

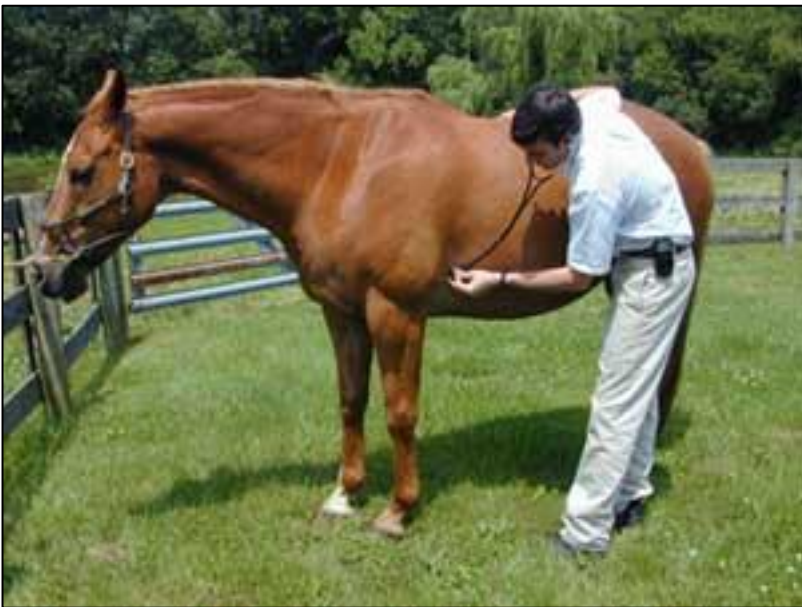Maior parte encontra-se a esquerda do plano mediano.

Caudal

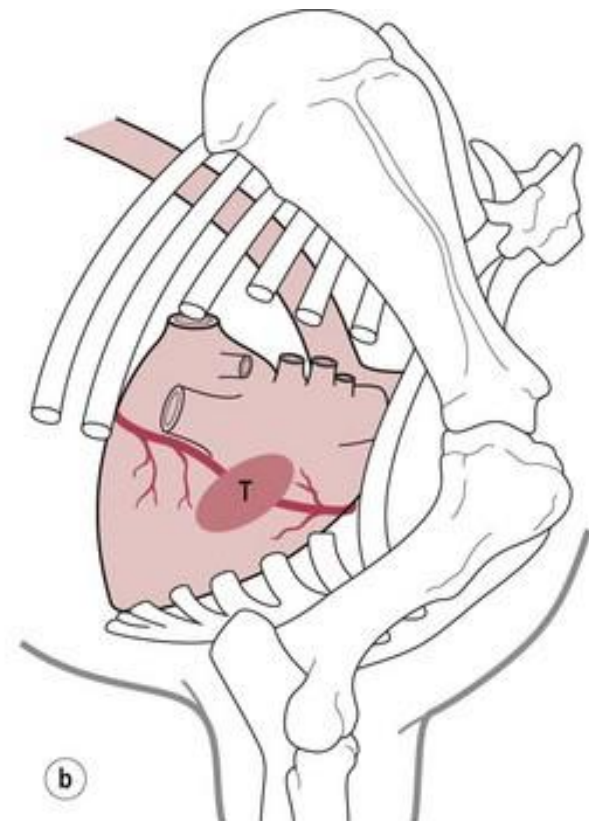
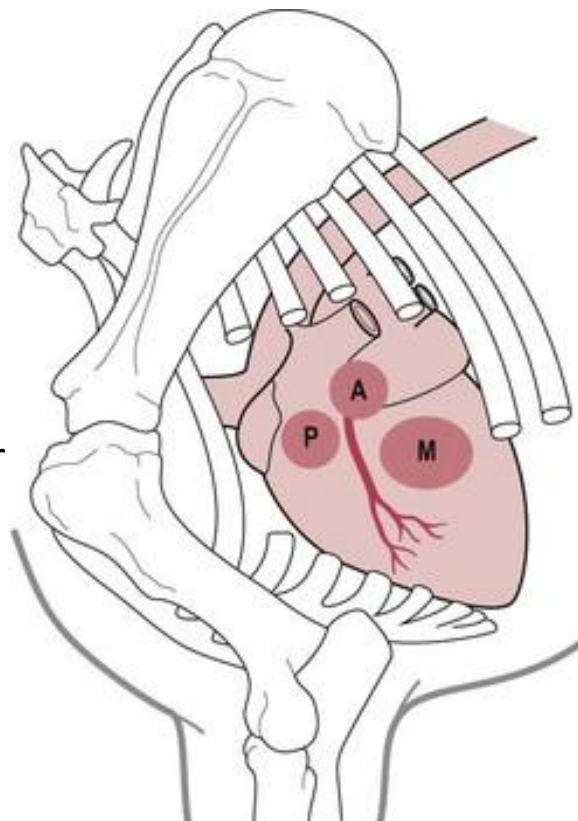
Esqueletopia

- Equino – 2º ao 6º espaço intercostal.
- Bovino - 2º ao 5º espaço intercostal.
- Suíno – 2ª a 5ª costela.
- Cão - 3ª costela ao 6ª espaço intercostal.
- Gato - 3ª - 7ª costela





Auscultação cardíaca

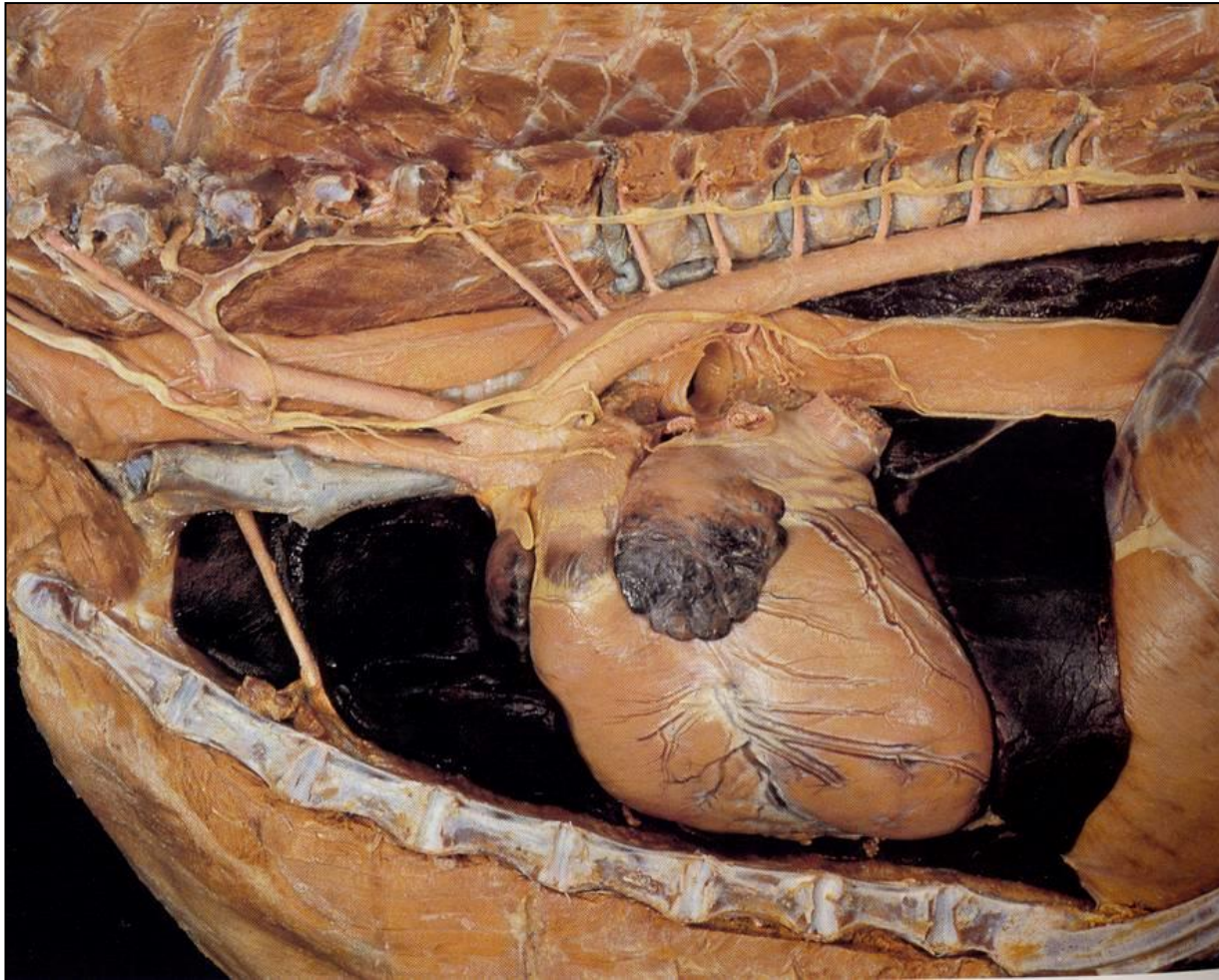


P – Valva tronco pulmonar
A - Valva aórtica
M – Valva mitral
T – Valva tricúspide

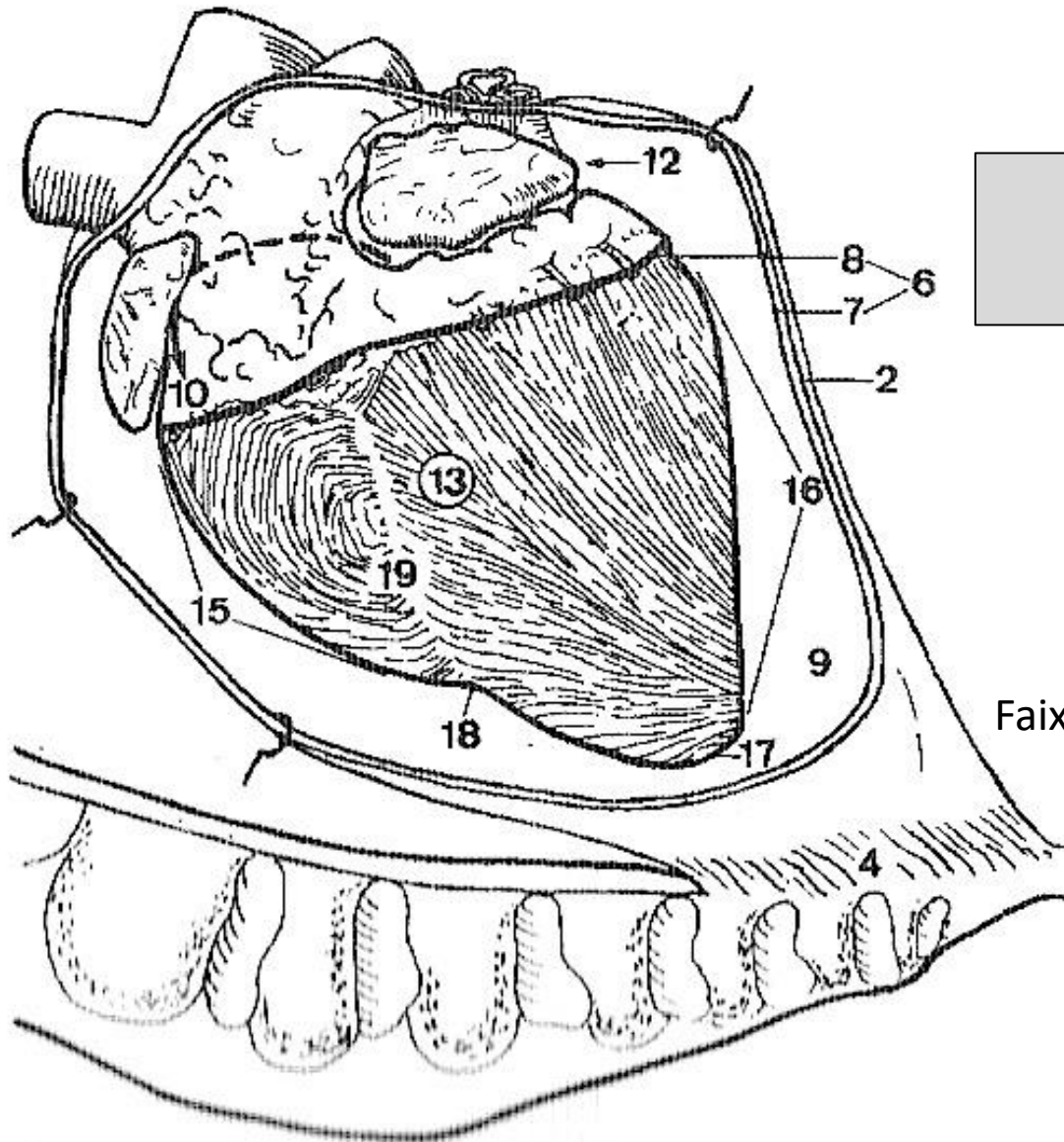
a

b

Fixação do coração na cavidade torácica



Fixação do coração na cavidade torácica



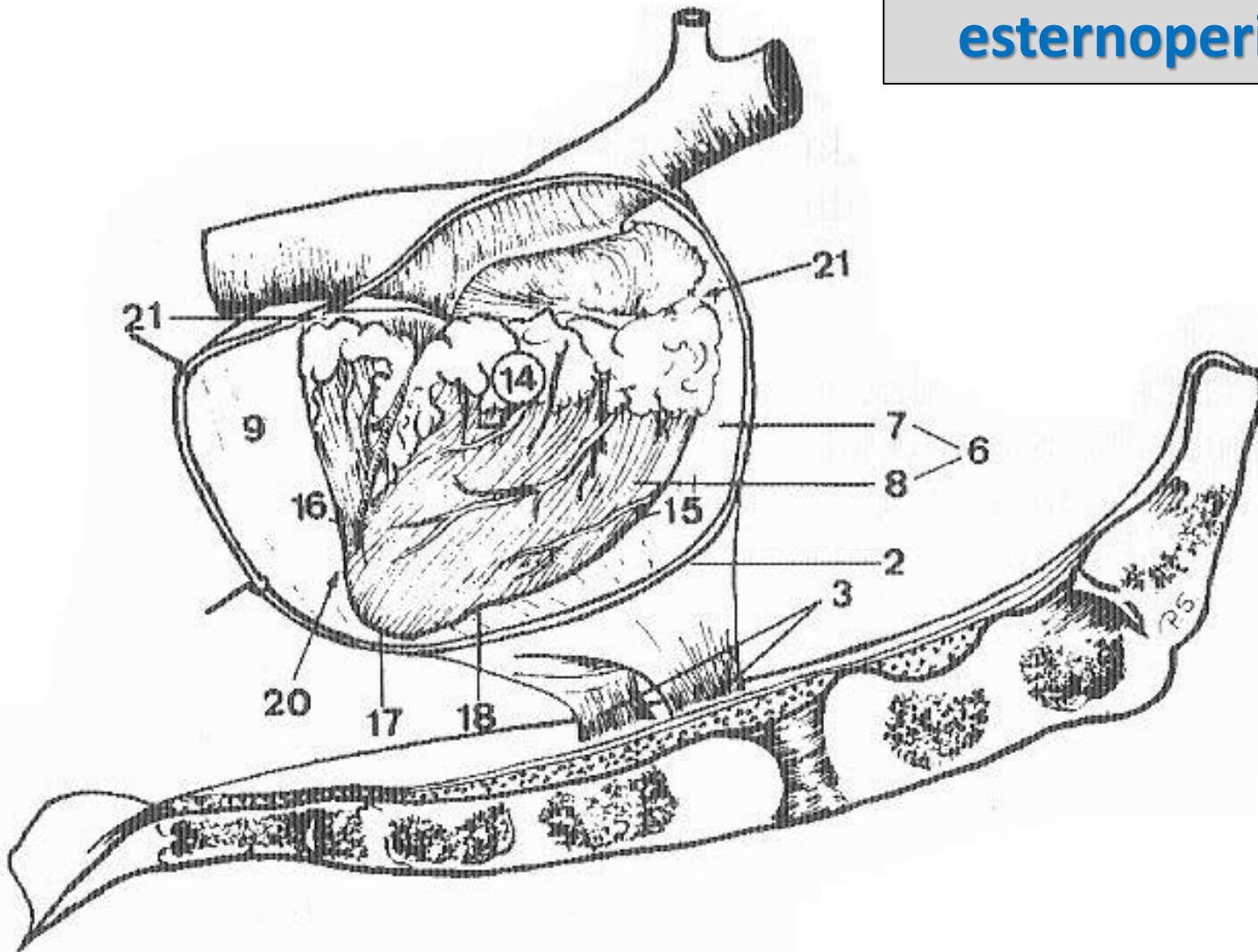
**Ligamento
esternopericárdico**

Faixa conjuntiva simples

Equino

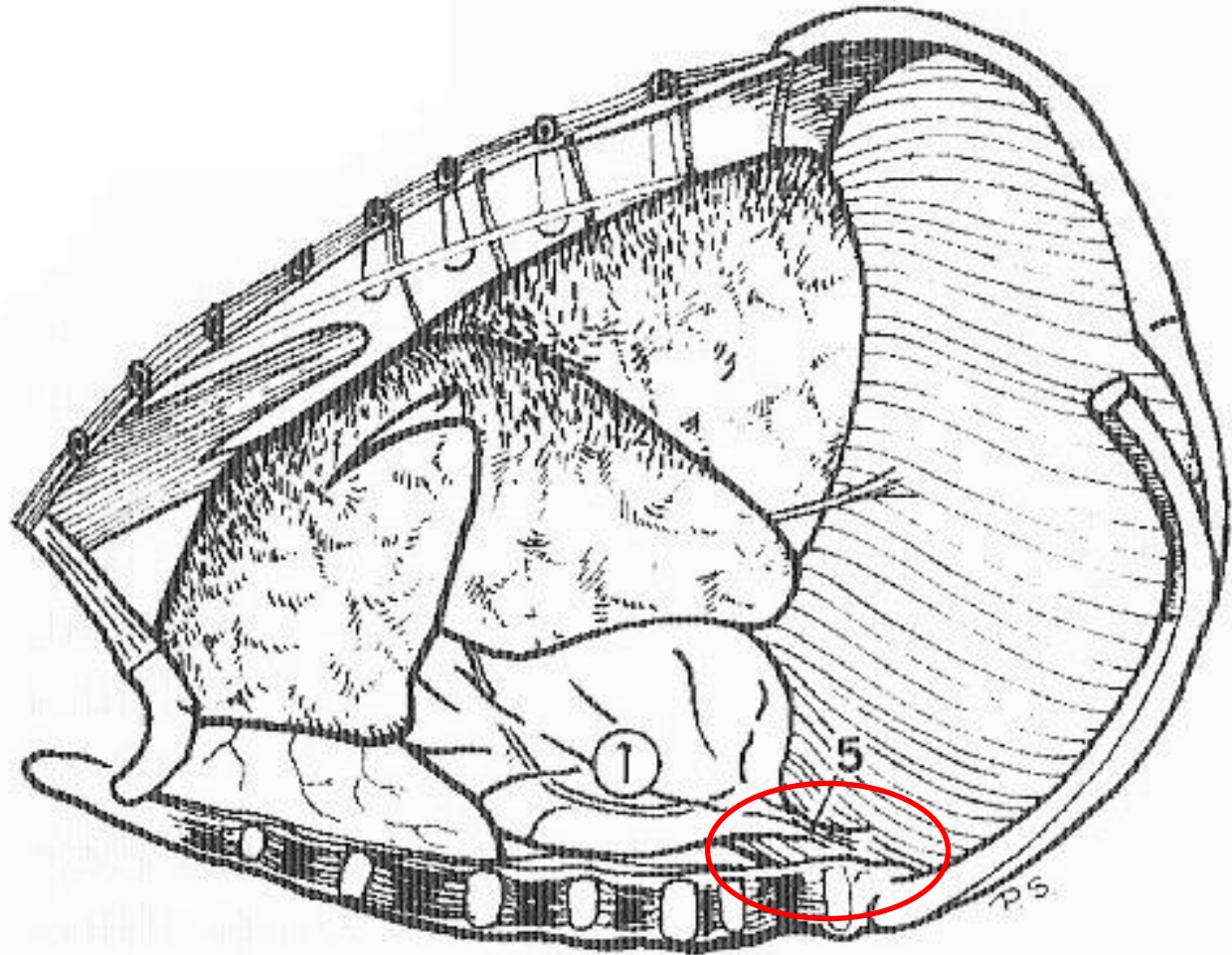
Ruminantes

Ligamentos esternopericárdicos



Faixa conjuntiva bilateral

Ligamento frenopericárdico

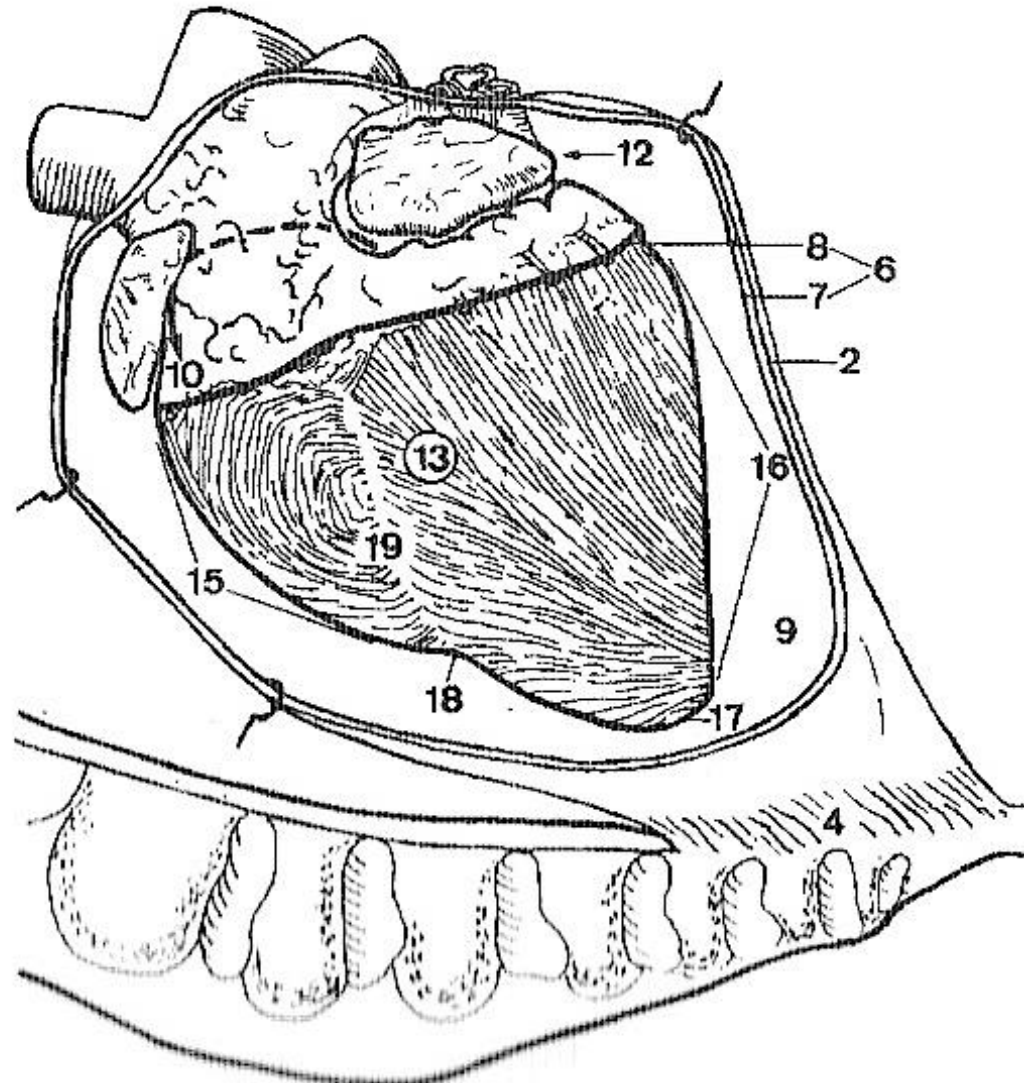


Carnívoros e suínos

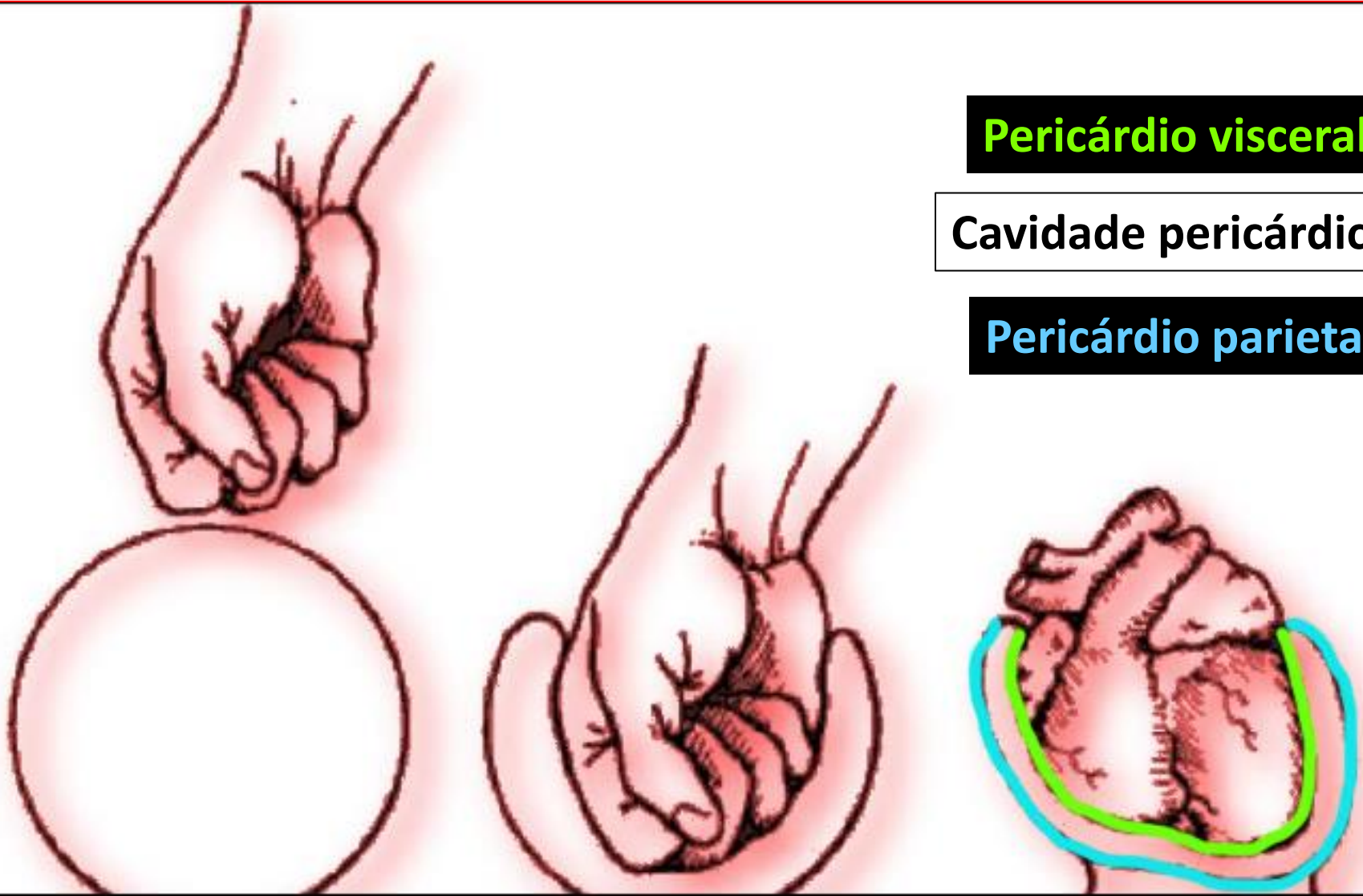
Animais com eixo cardíaco mais oblíquo

Pericárdio

- Pericárdio:
- Fibroso (2)
- Seroso (6)
 - Parietal (7)
 - Visceral (8)



Pericárdio seroso

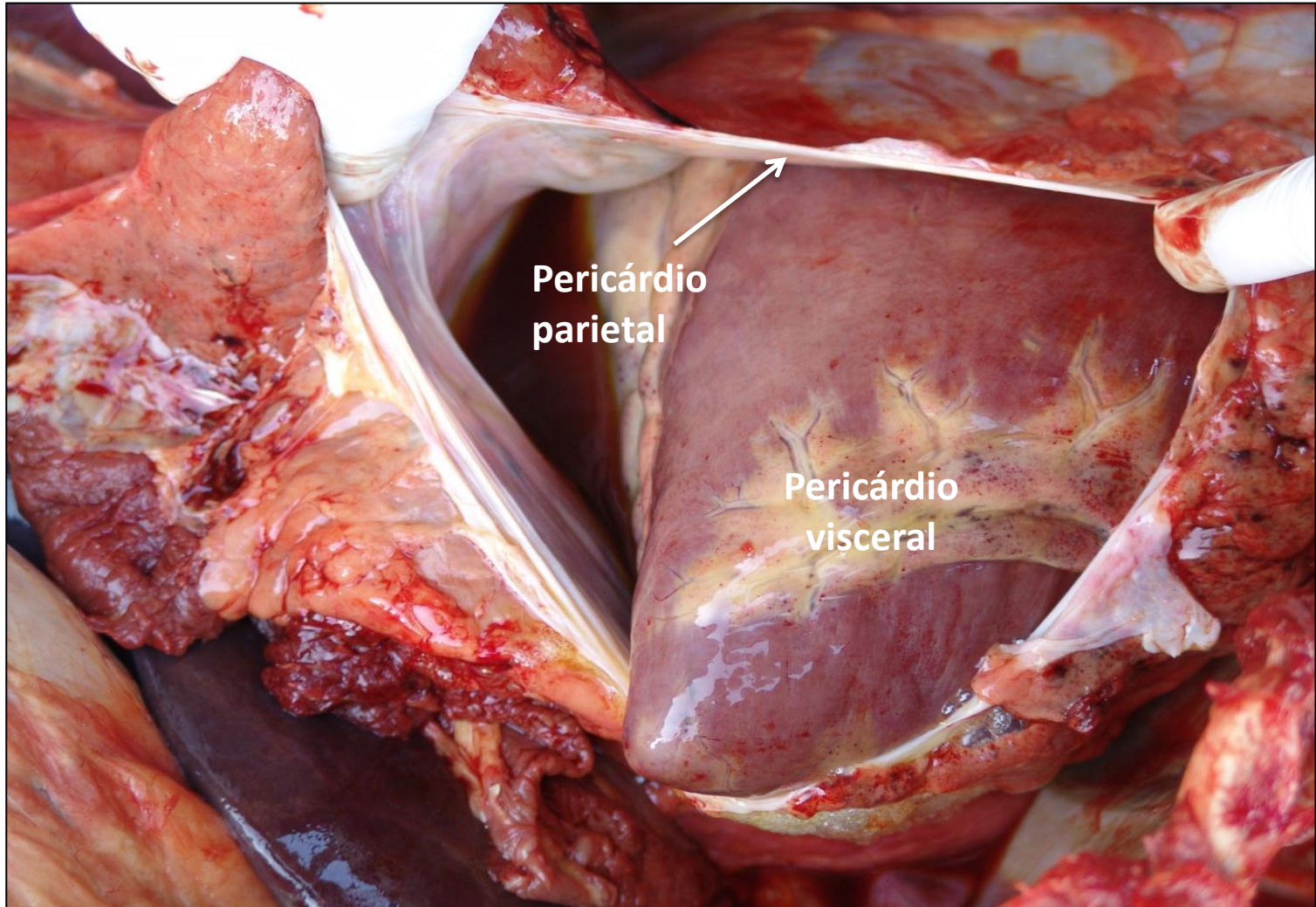


Pericárdio visceral

Cavidade pericárdica

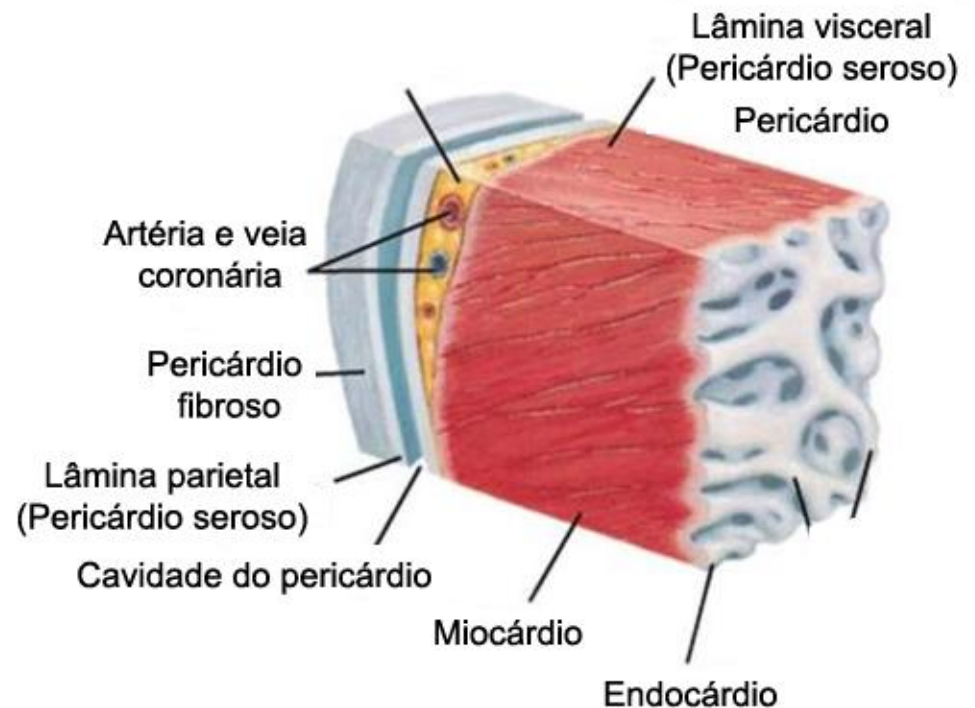
Pericárdio parietal

Pericárdio visceral = Epicárdio

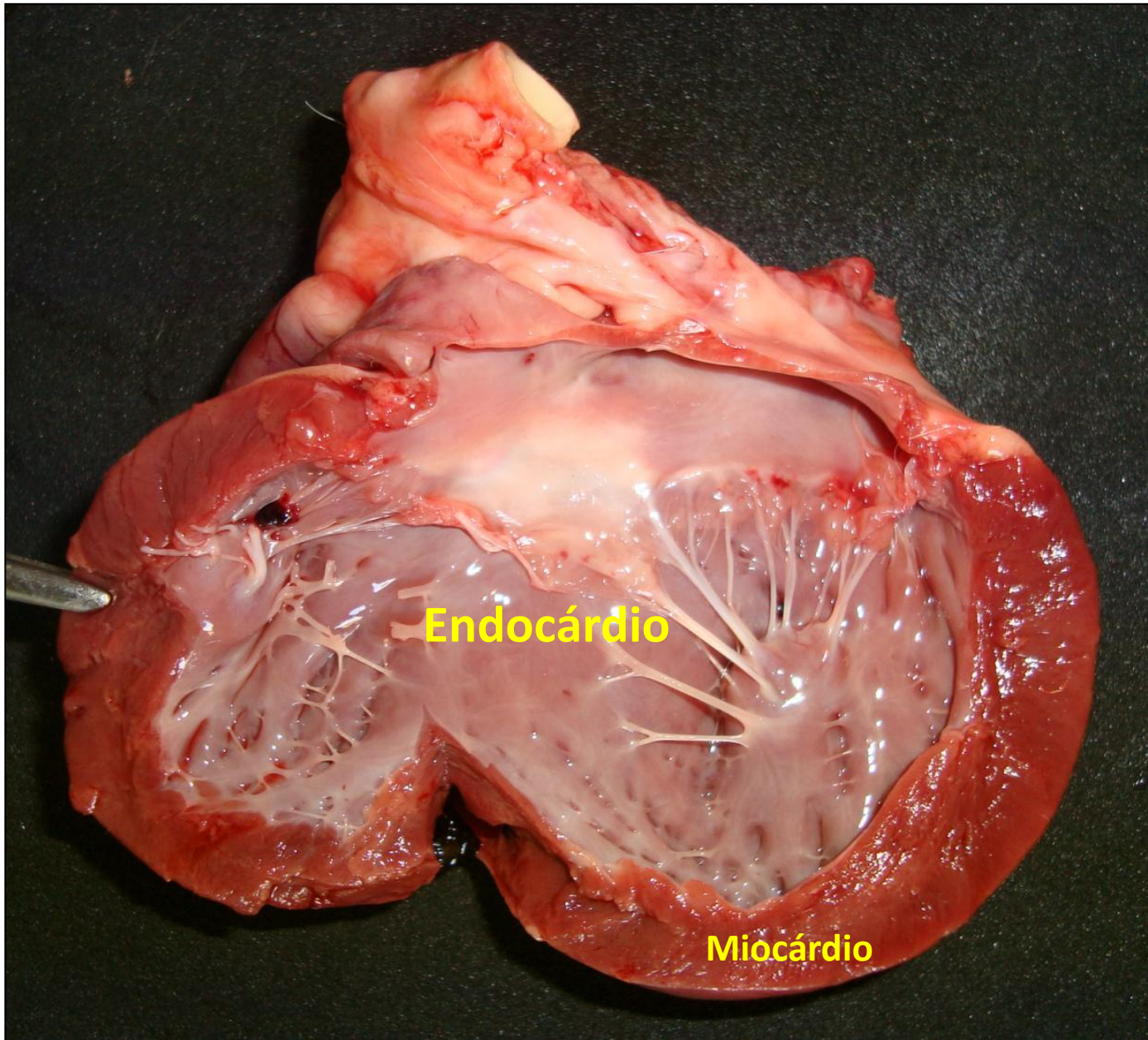


Camadas do coração

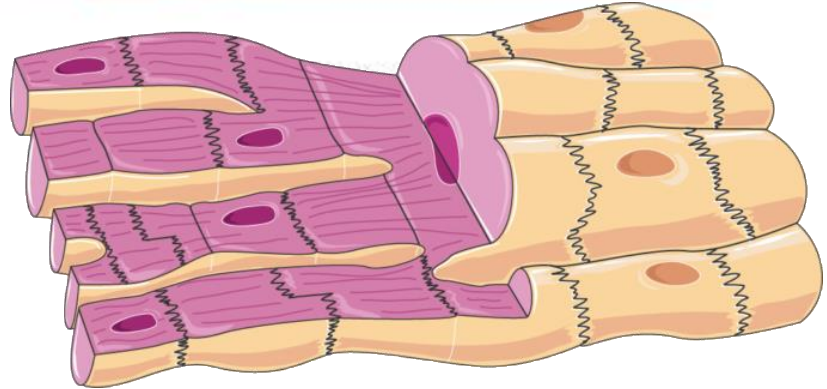
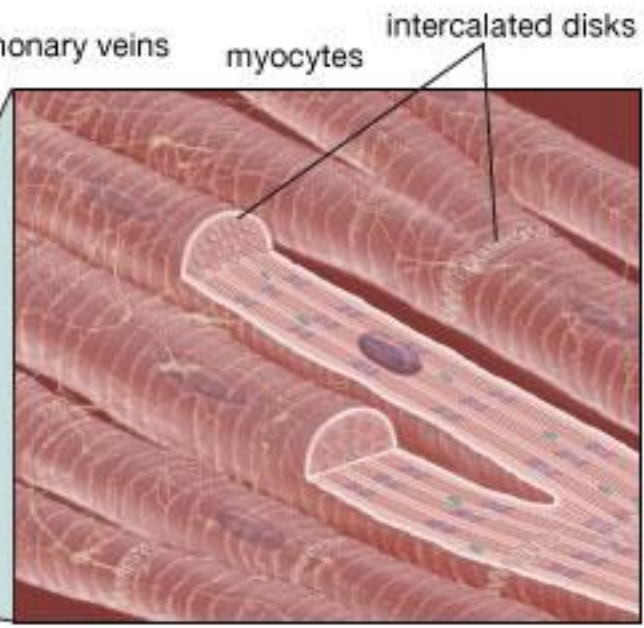
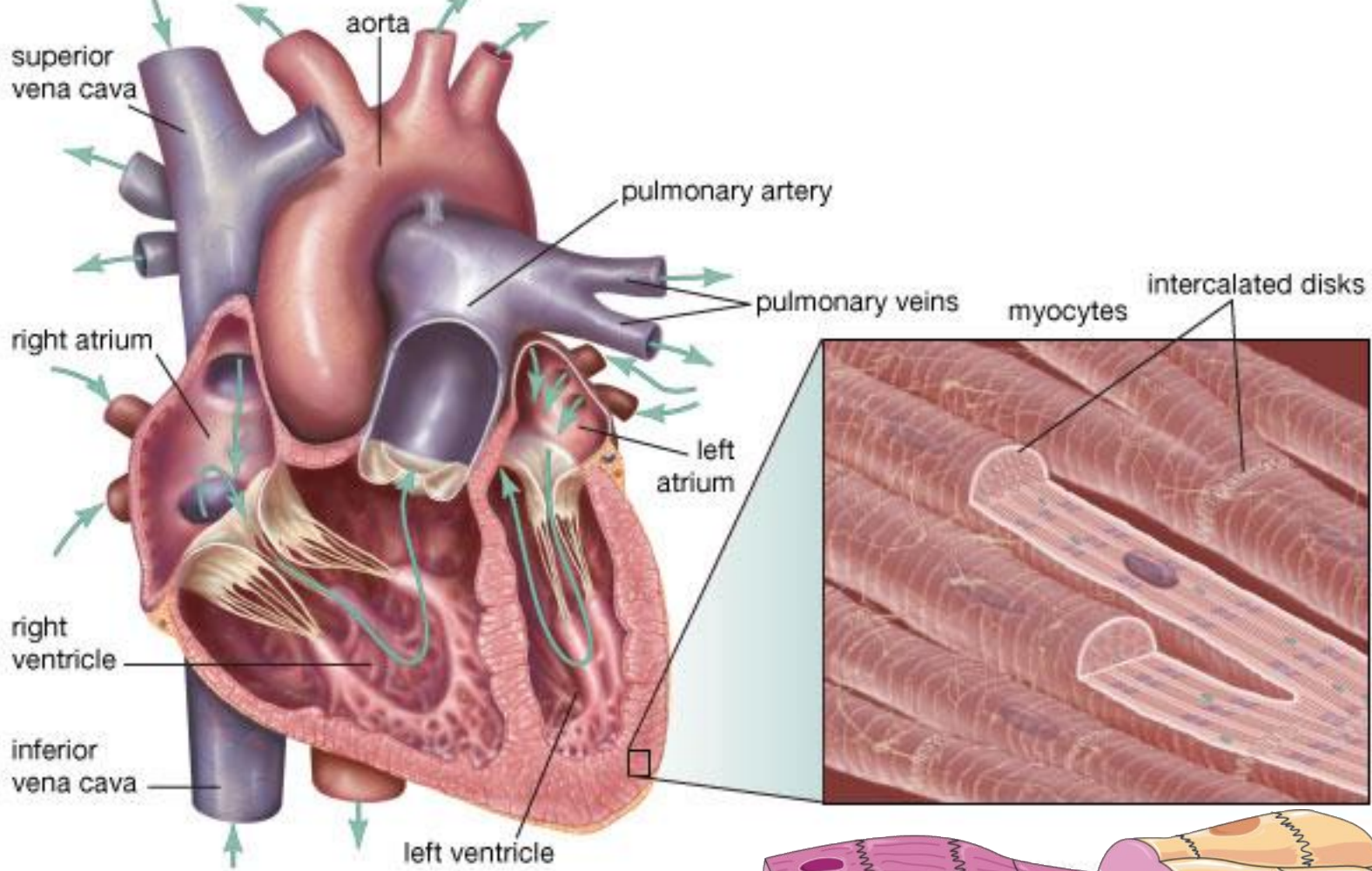
- É formado por três camadas:
 - Endocárdio
 - Miocárdio
 - Epicárdio (pericárdio visceral)



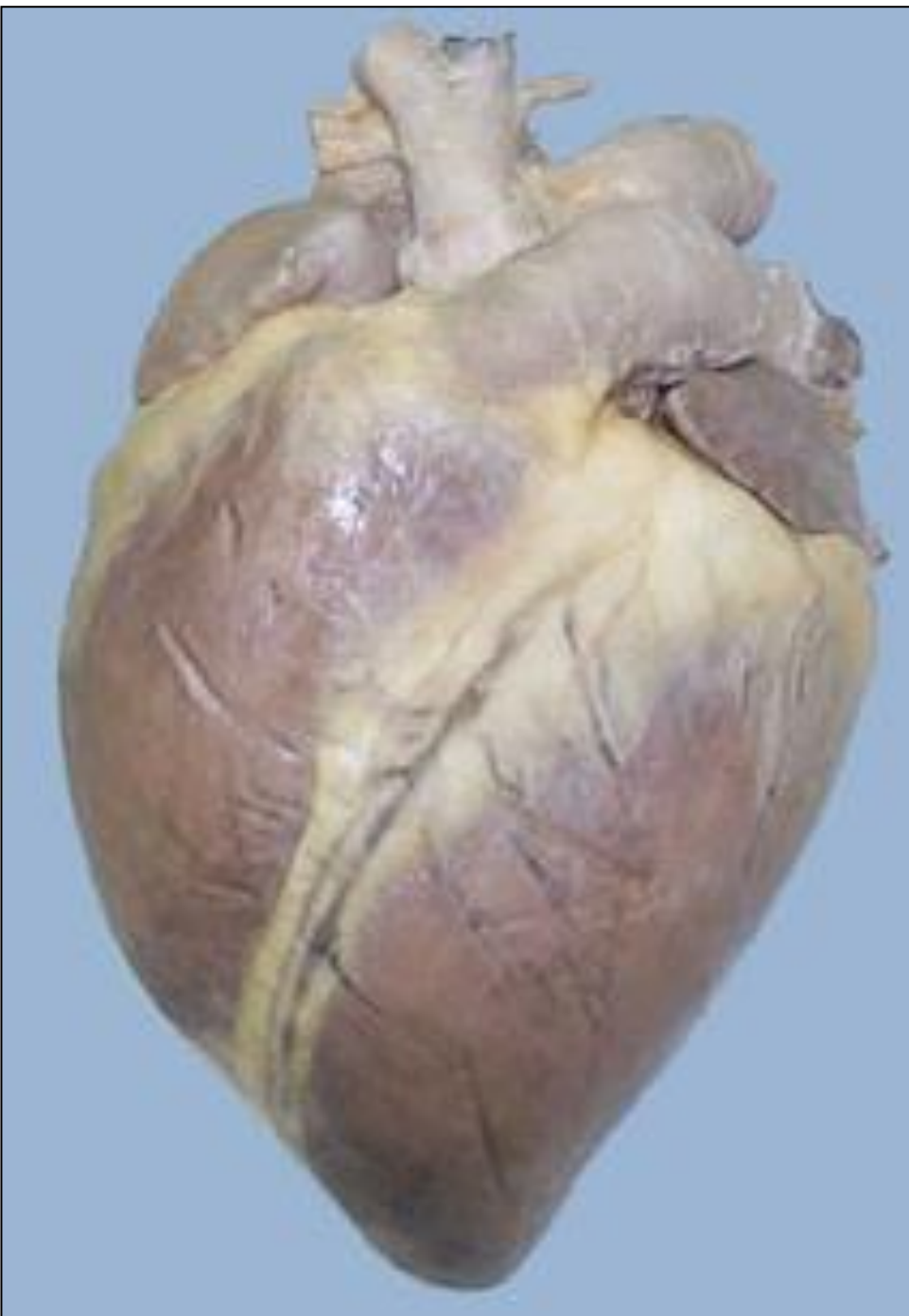(From Thibodeau GA, Patton KT: *Anatomy & physiology*, ed 5, St Louis, 2003, Mosby.)



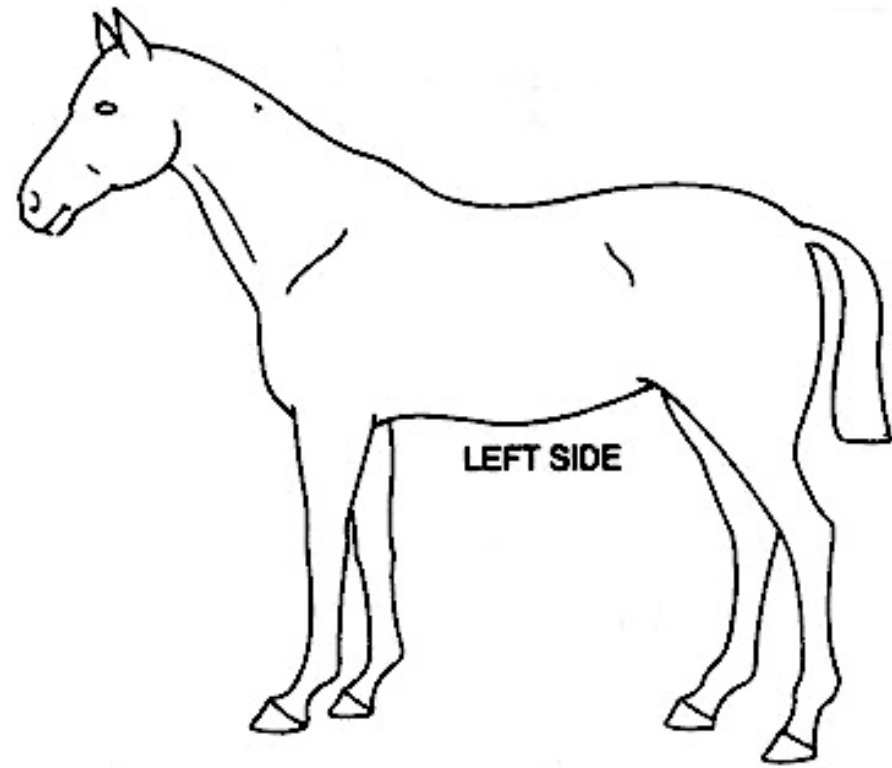
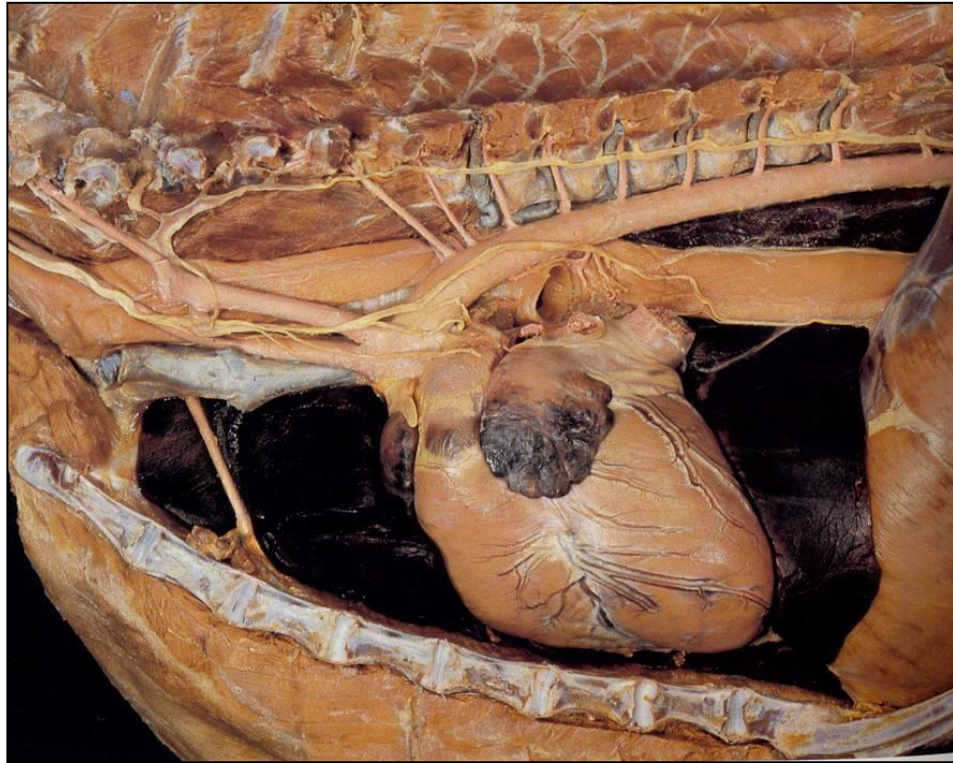
Fonte: Arquivo pessoal



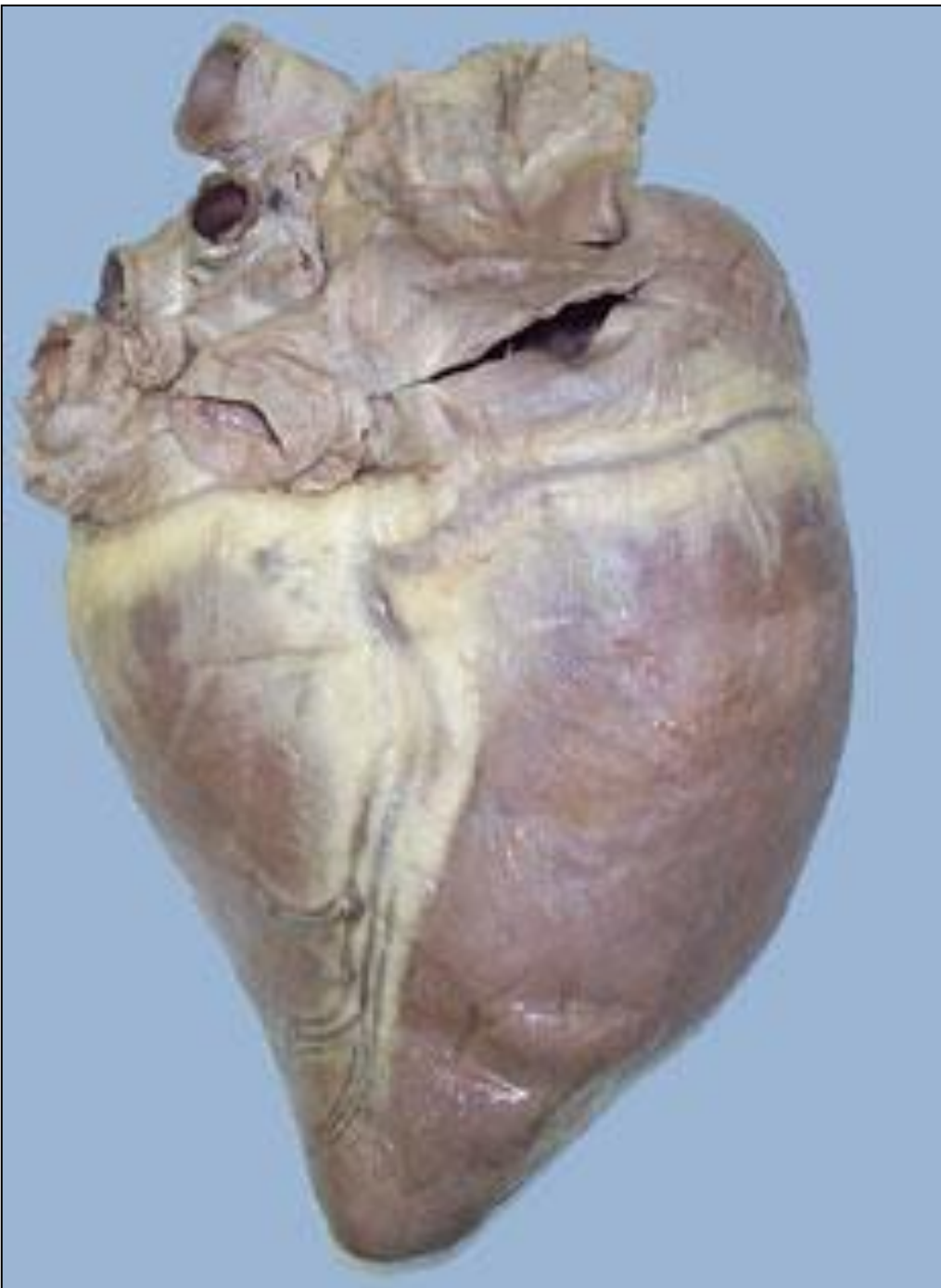Morfologia externa



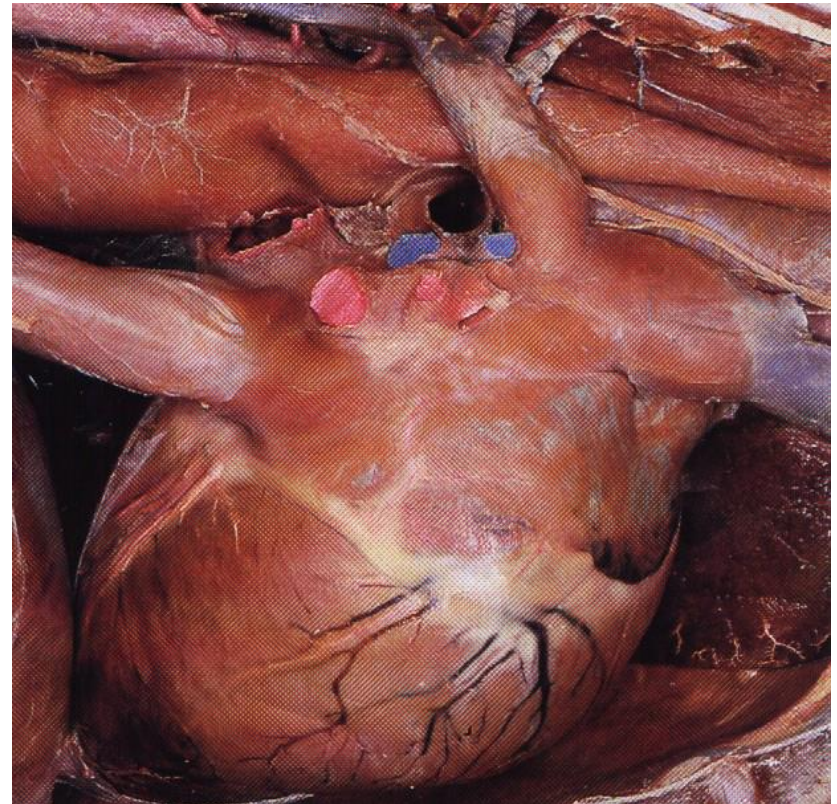
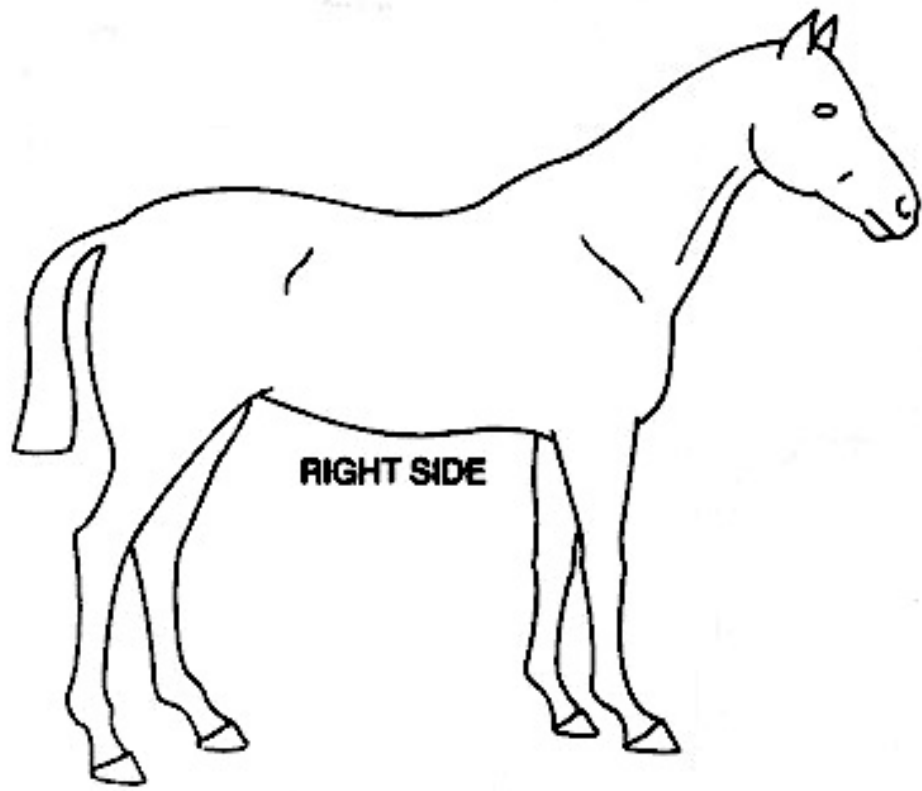
Face esquerda
ou
Face auricular

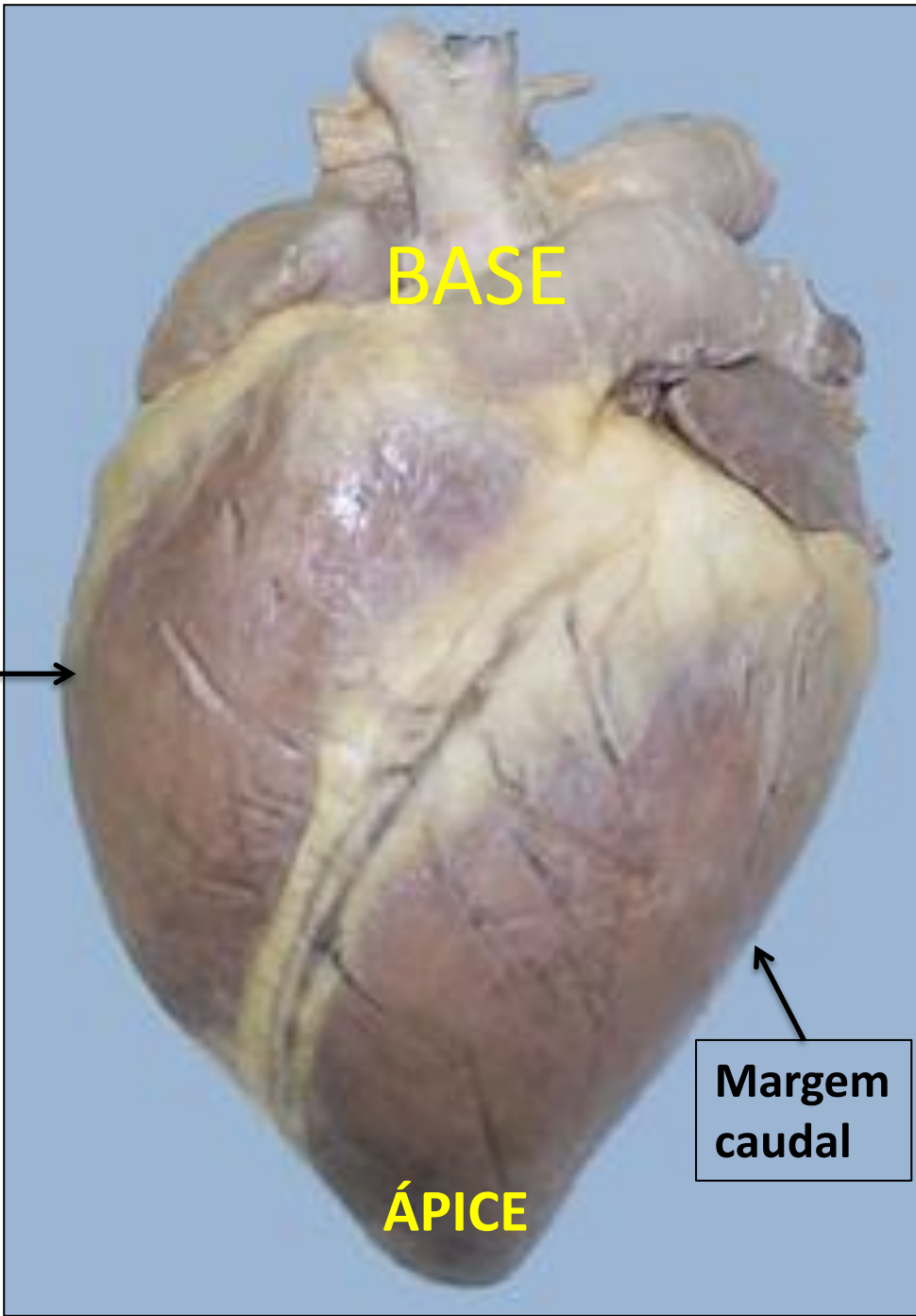


Morfologia externa



Face direita
ou
Face atrial



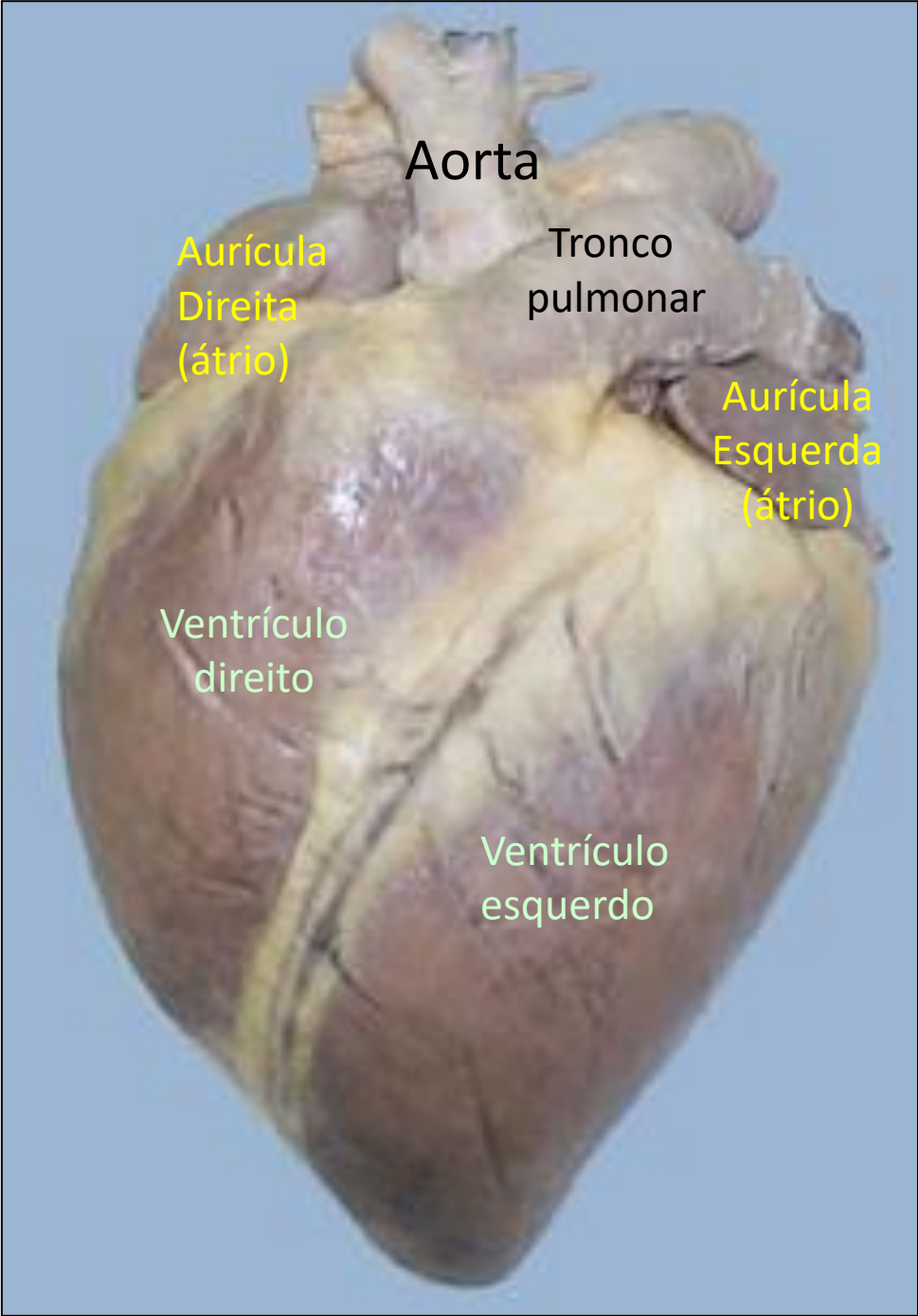


BASE

**Margem
cranial**

**Margem
caudal**

ÁPICE



Aorta

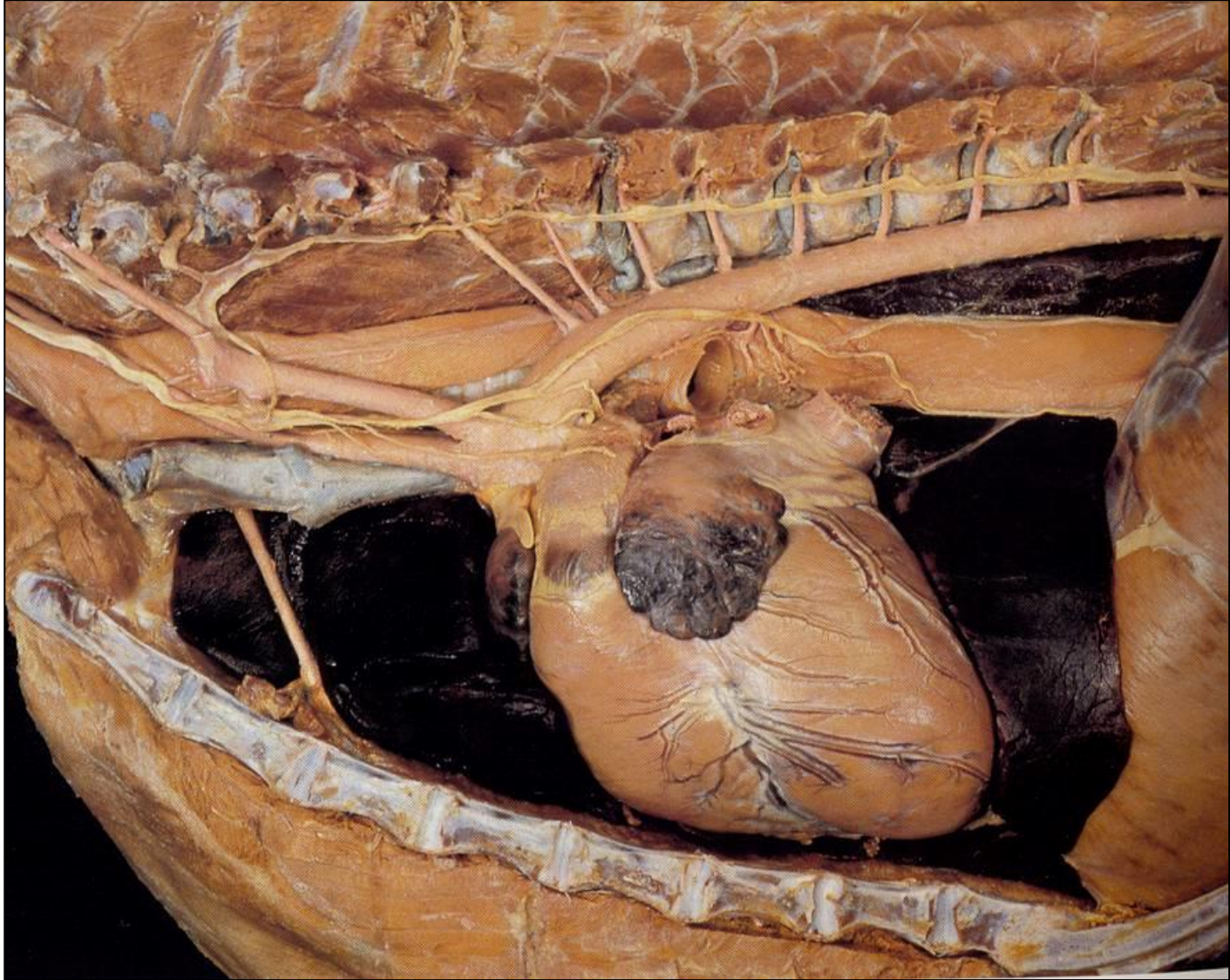
Aurícula
Direita
(átrio)

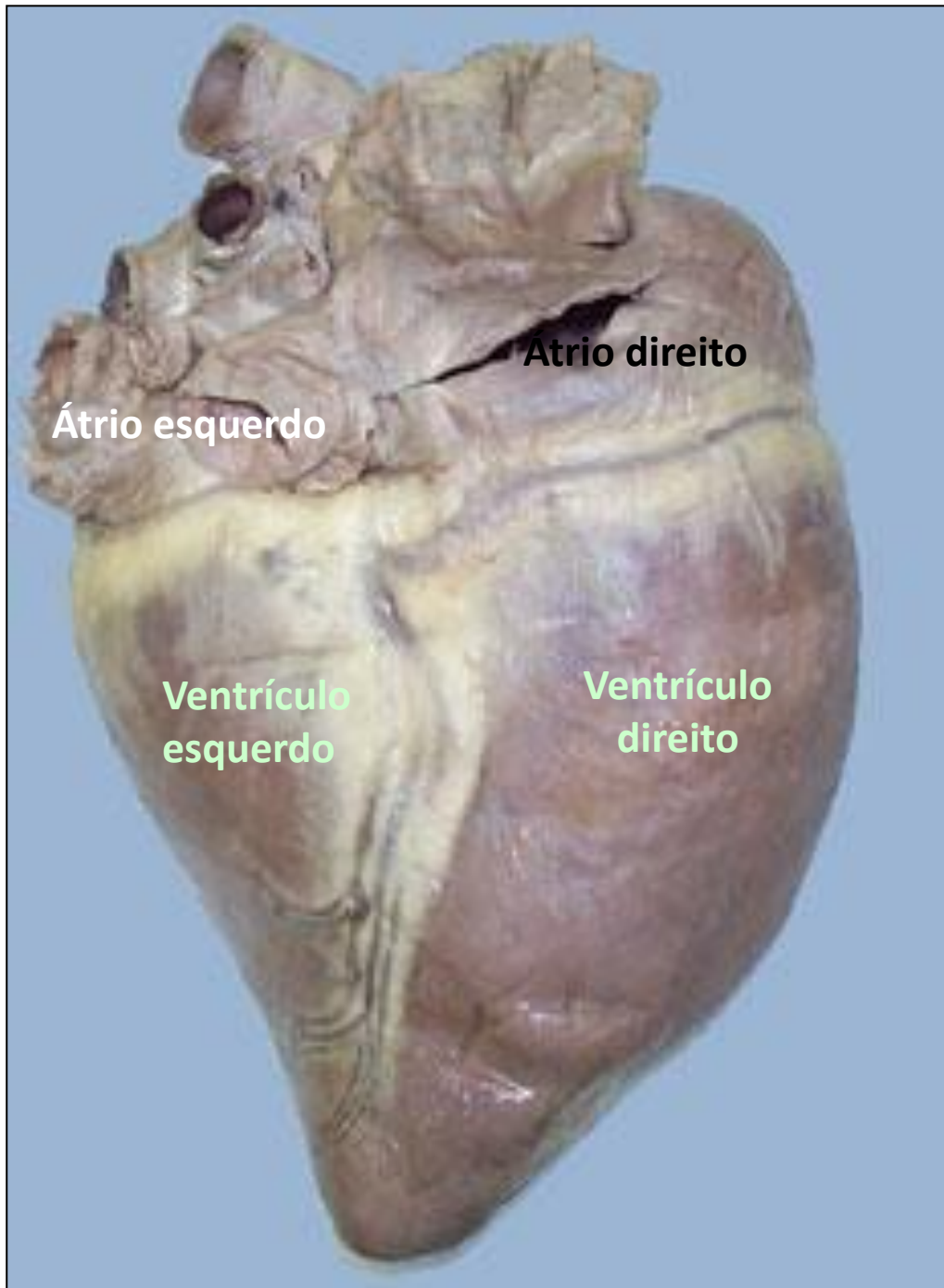
Tronco
pulmonar

Aurícula
Esquerda
(átrio)

Ventrículo
direito

Ventrículo
esquerdo



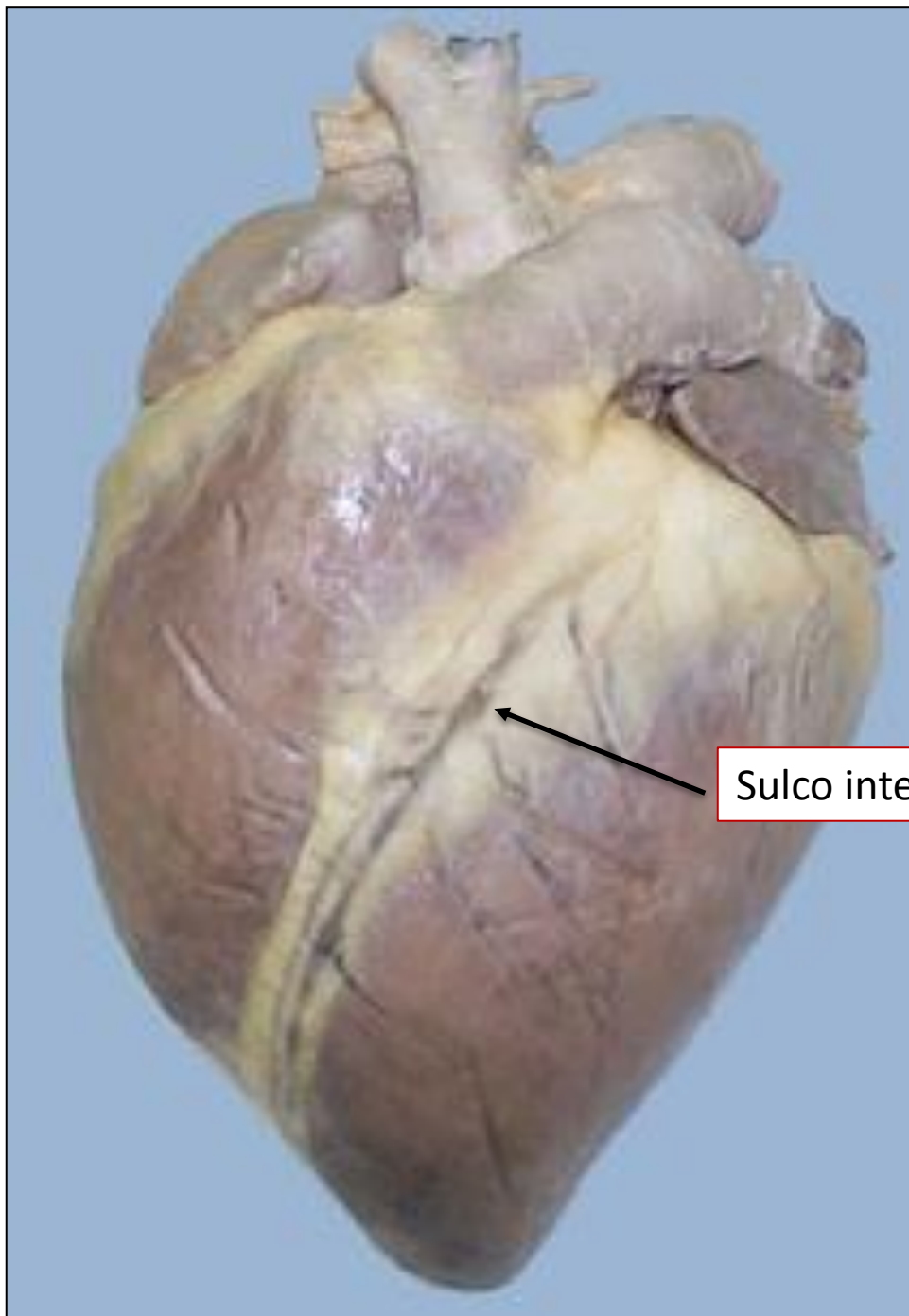


Atrio direito

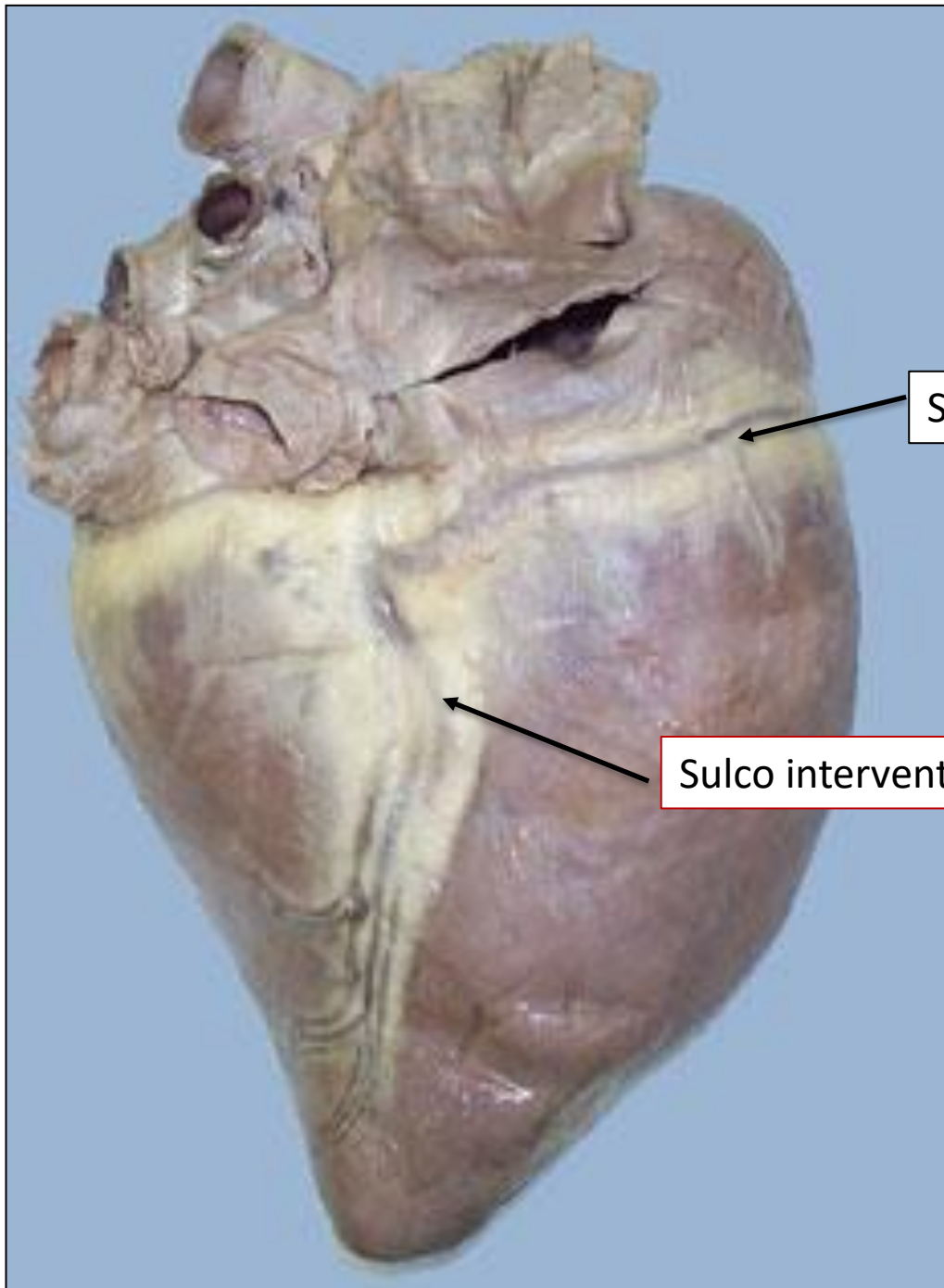
Átrio esquerdo

**Ventrículo
esquerdo**

**Ventrículo
direito**

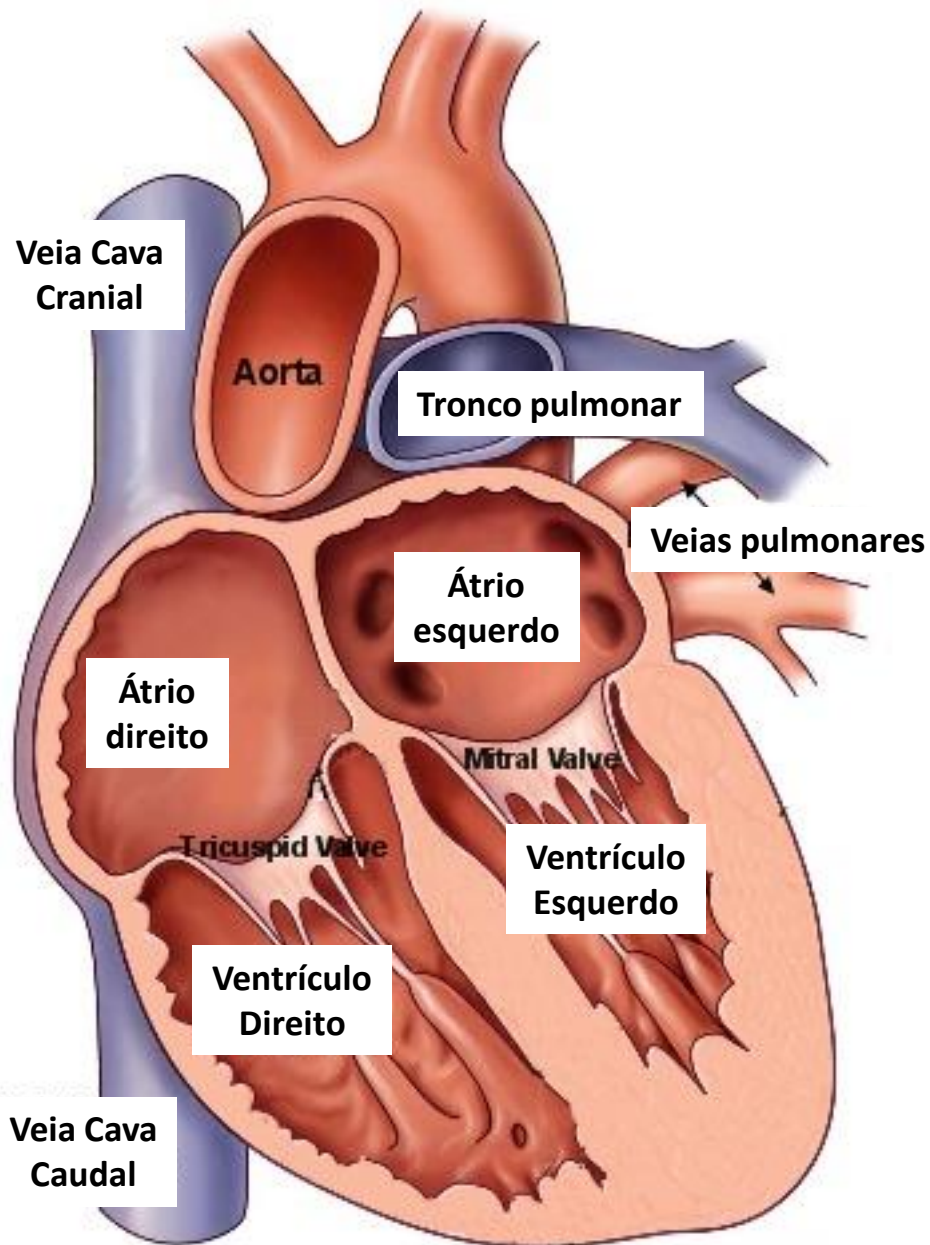


Sulco interventricular paraconal

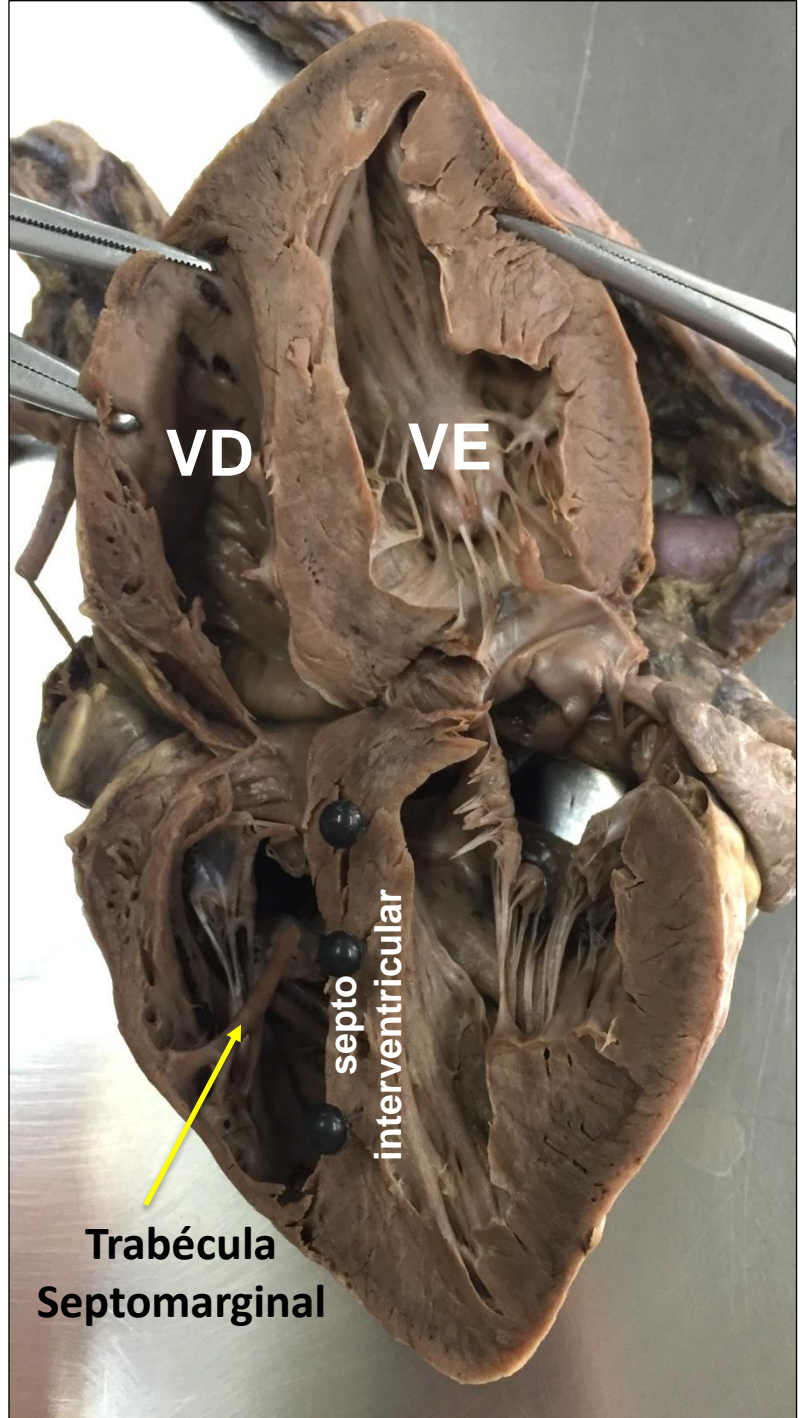


Sulco coronário

Sulco interventricular subsinuoso



Morfologia interna



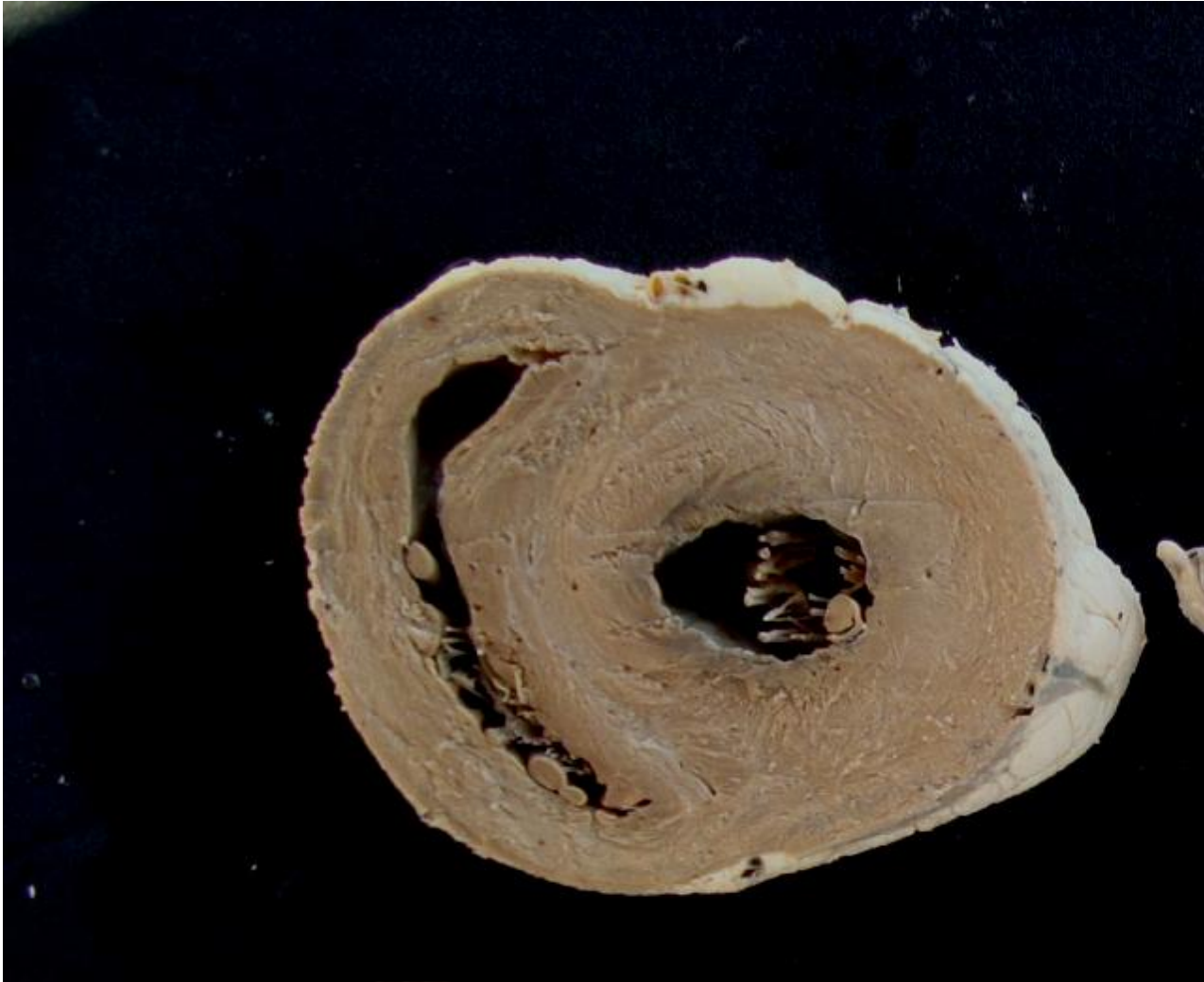
VD

VE

septo
interventricular

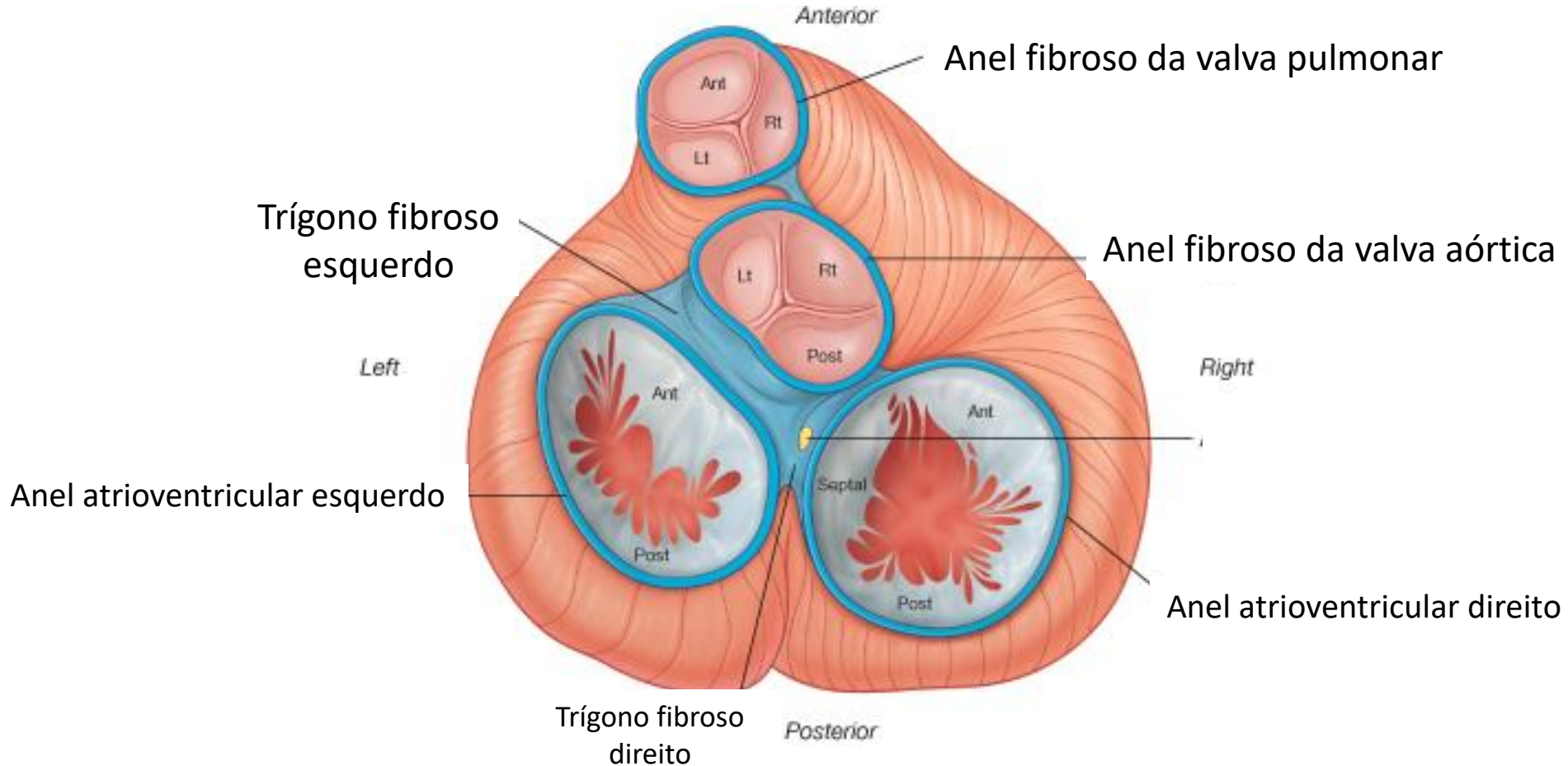
Trabécula
Septomarginal

Morfologia interna

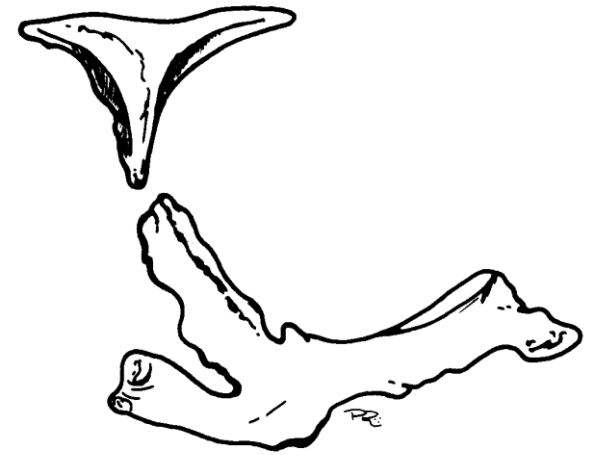
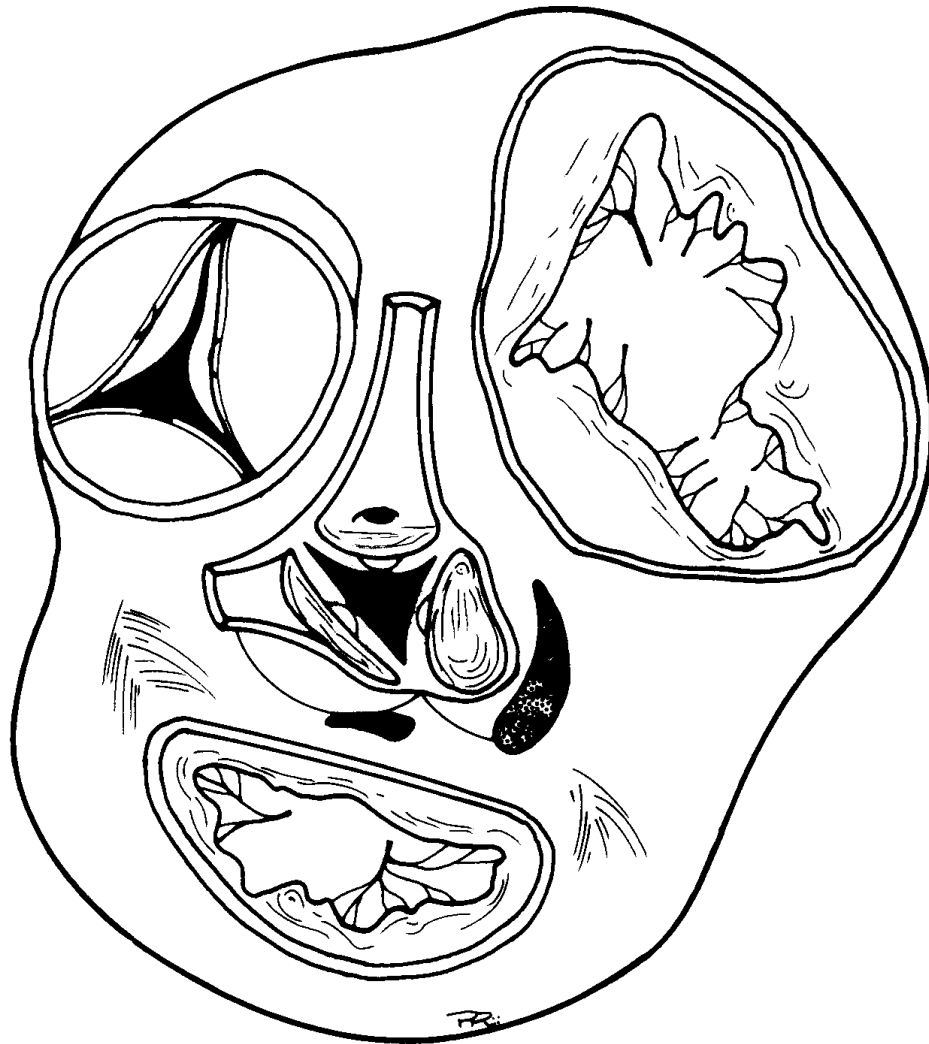

Esqueleto cardíaco
composto por tecido
conjuntivo denso

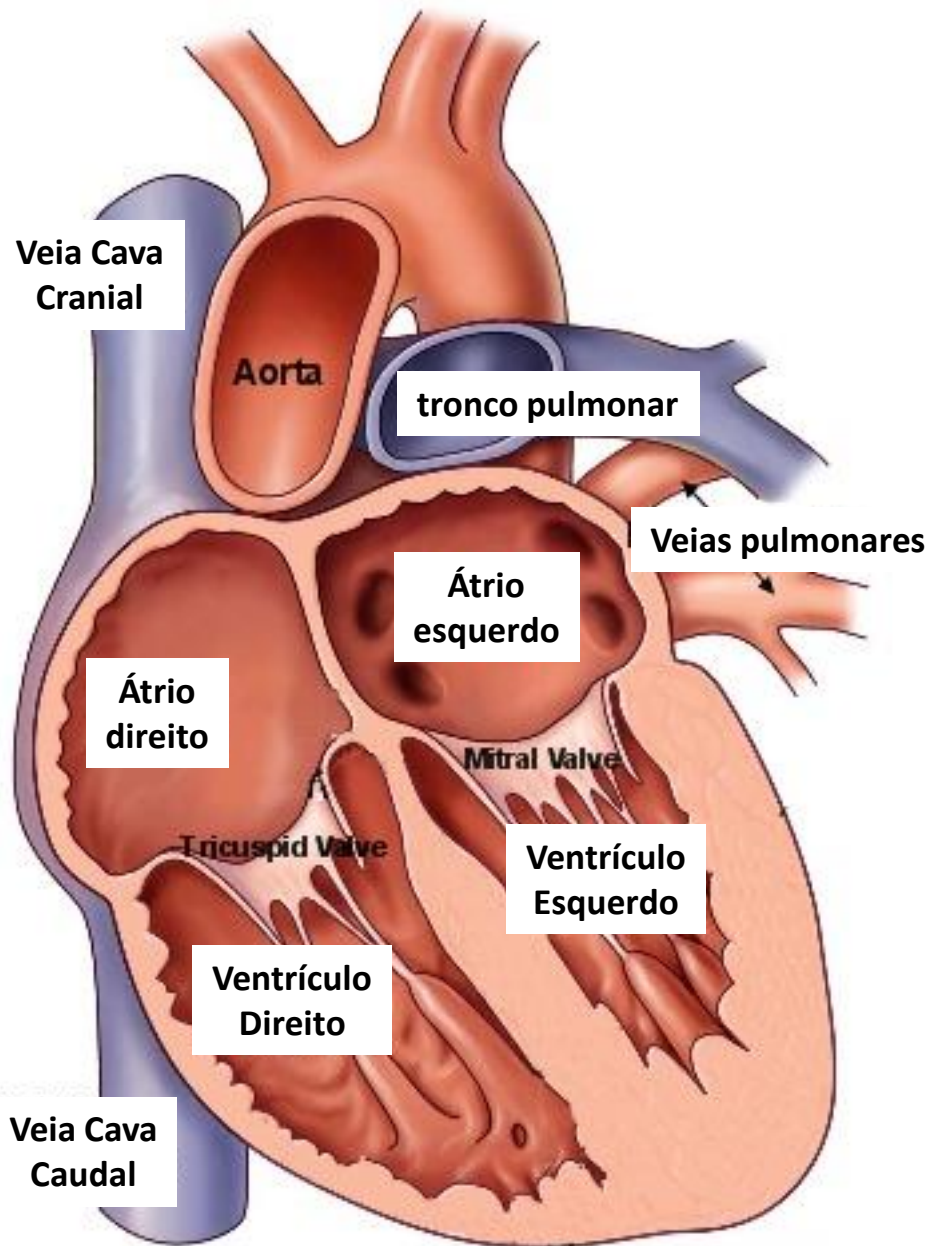
Arquitetura do coração



Coração - ruminante

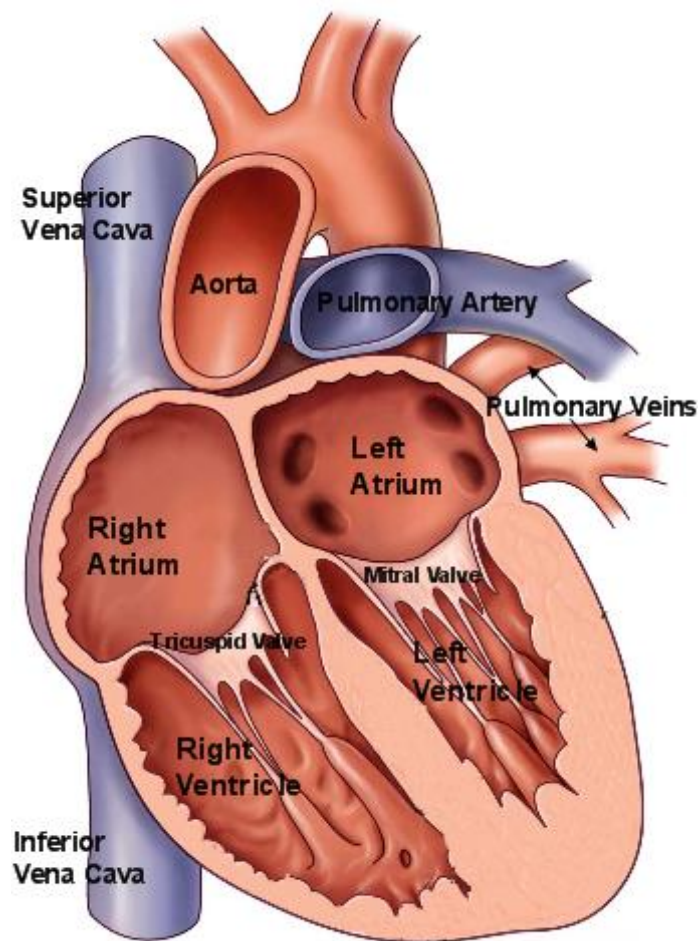
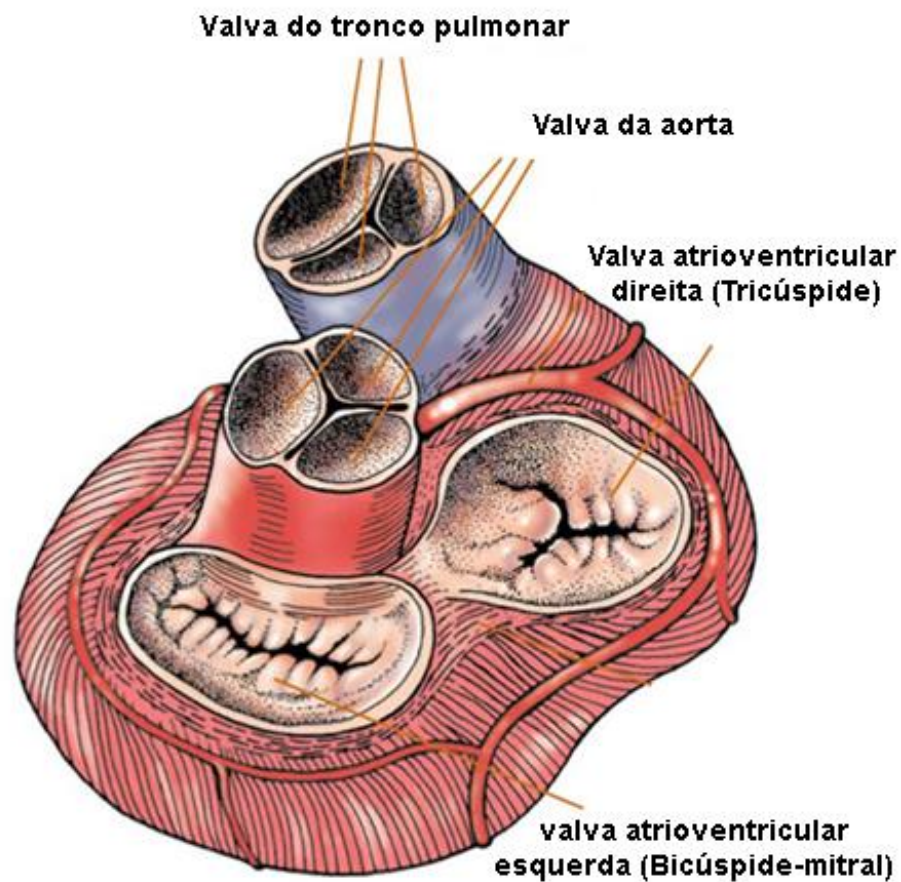


Ossificação



Morfologia interna

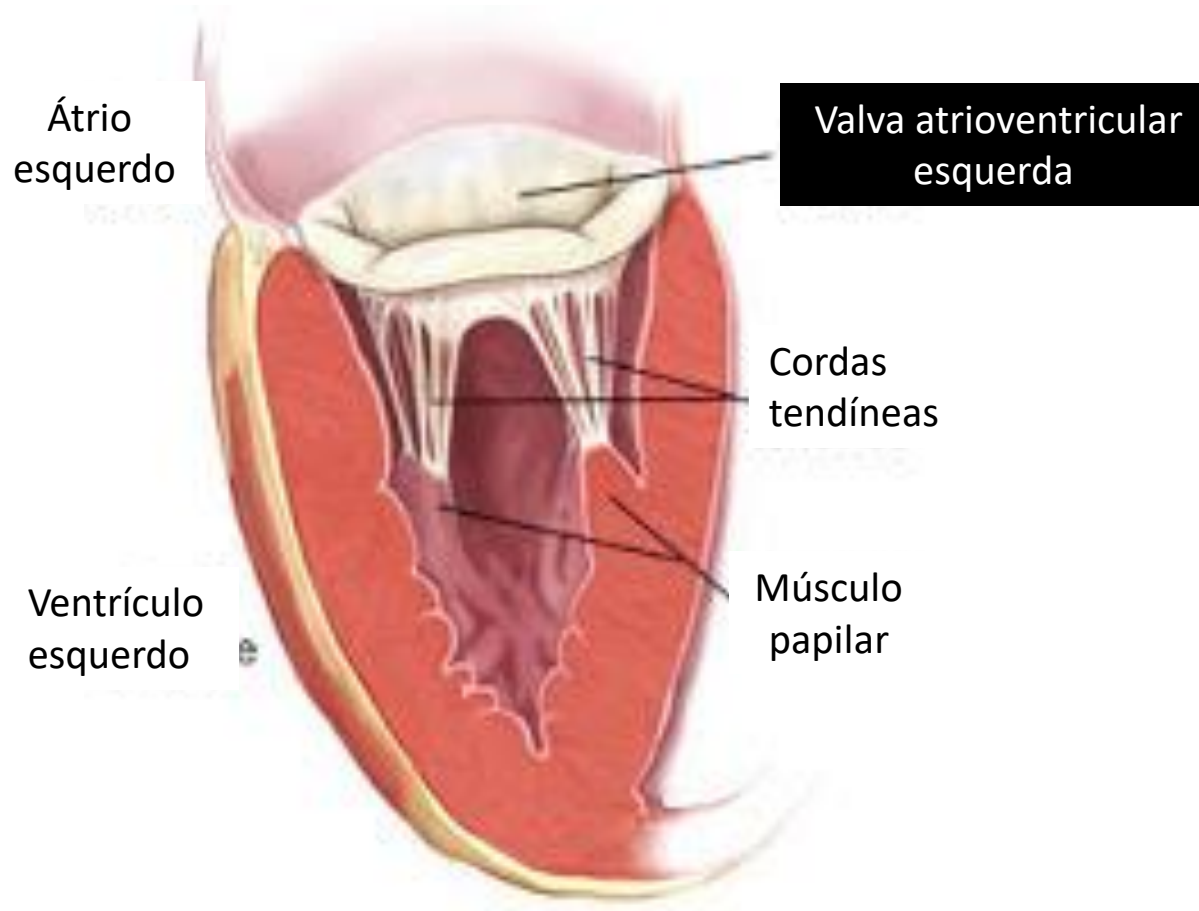
Valvas cardíacas



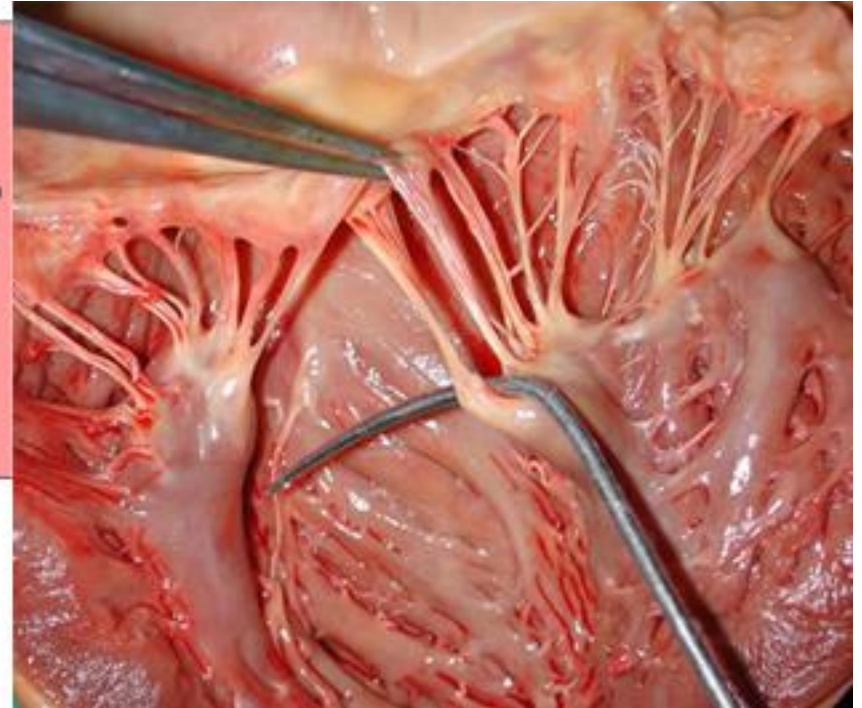
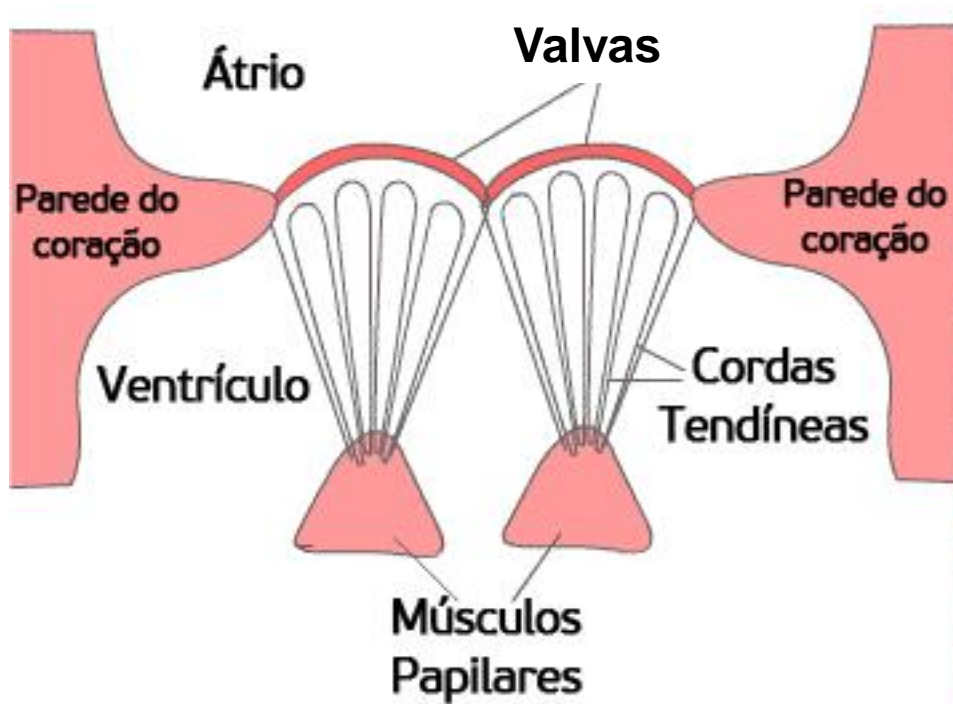
Valvas cardíacas

- Valva do tronco pulmonar
- Valva da aorta
- Valva atrioventricular direita (Tricúspide)
- Valva atrioventricular esquerda (Bicúspide/mitral)

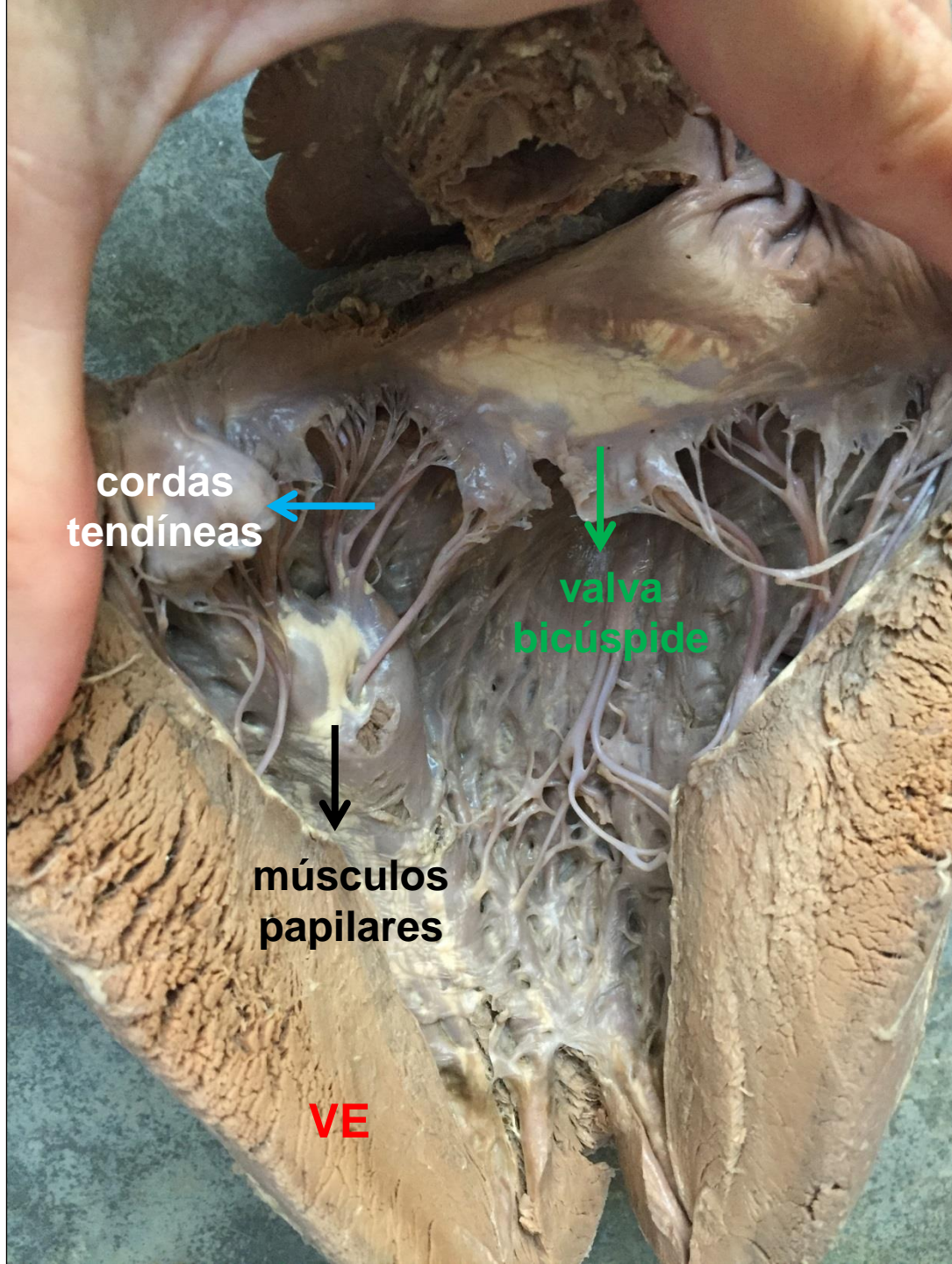
Valvas cardíacas



Valvas cardíacas



Valvas se fixam nos músculos papilares por meio das cordas tendíneas



**cordas
tendíneas**



**valva
bicúspide**



**músculos
papilares**

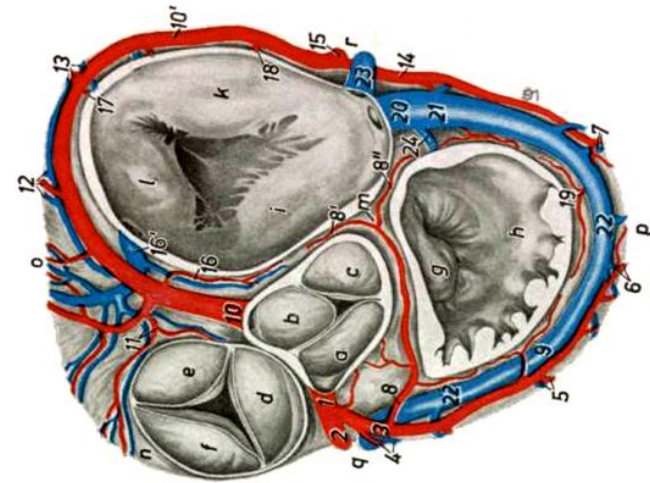
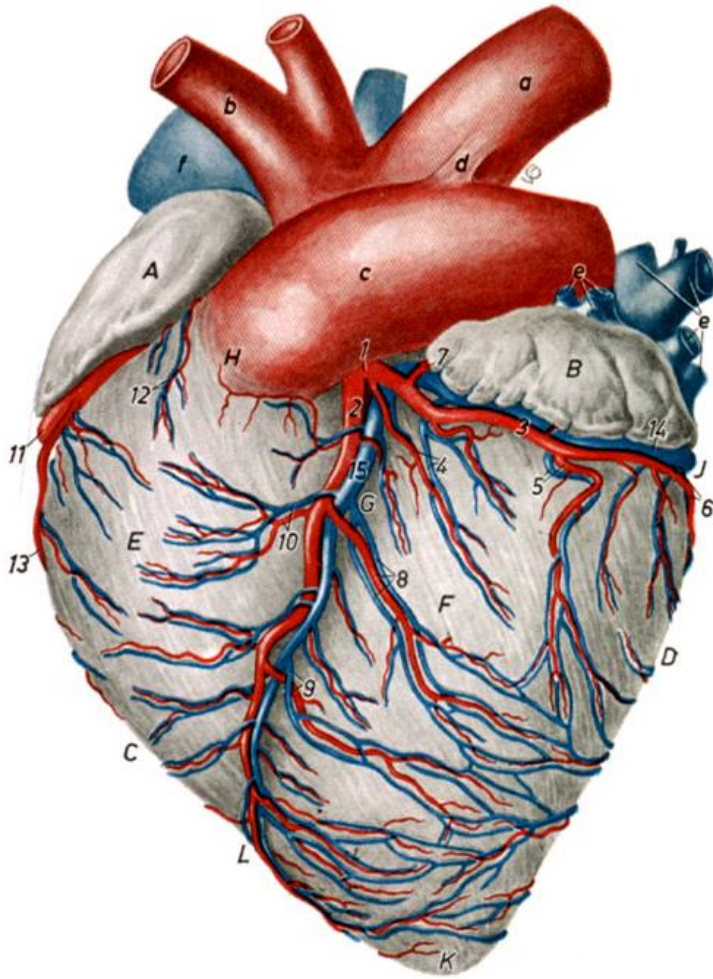


VE

Vascularização cardíaca

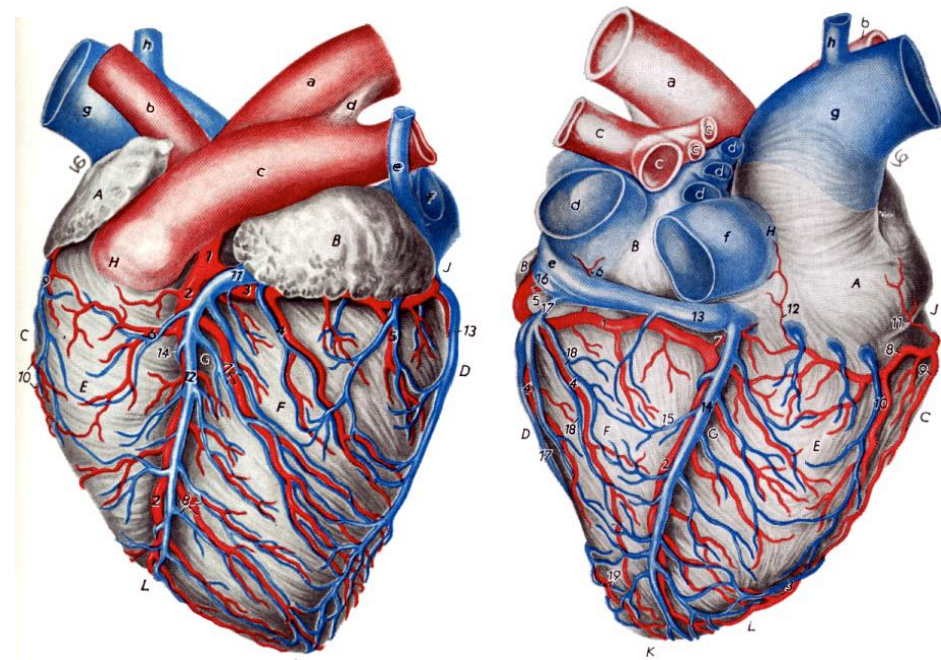


Artérias coronárias



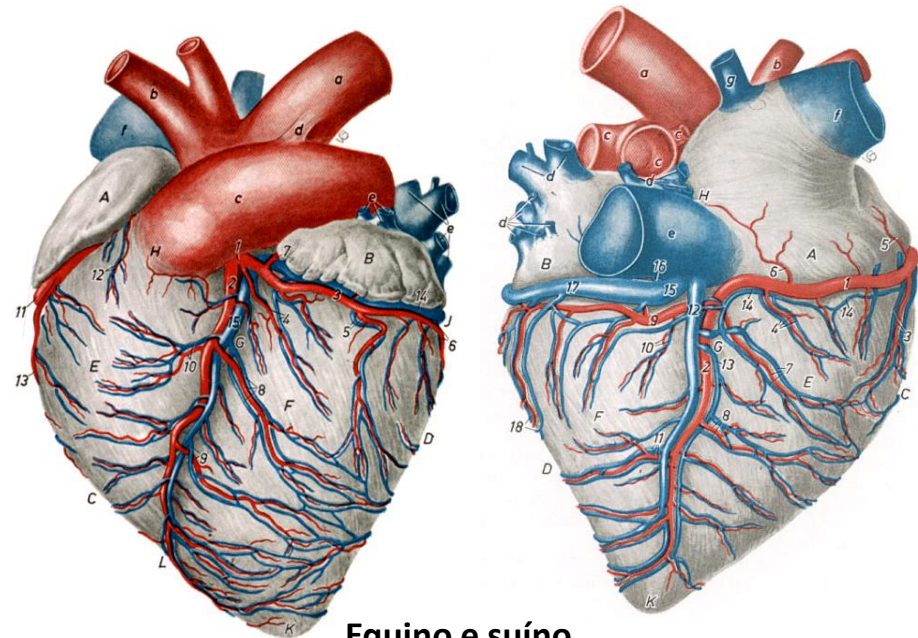
Vascularização do Coração

- **Artéria Coronária Esquerda**
 - Ramo paraconal (interventricular esquerdo)
 - Ramo circunflexo
 - Ramo subsinuoso (interventricular direito)
 - Carnívoros e Ruminantes



Ruminantes e carnívoros

- **Artéria Coronária Direita**
 - Ramo circunflexo
 - Ramo subsinuoso (interventricular direito)
 - Equino e Suíno



Equino e suíno

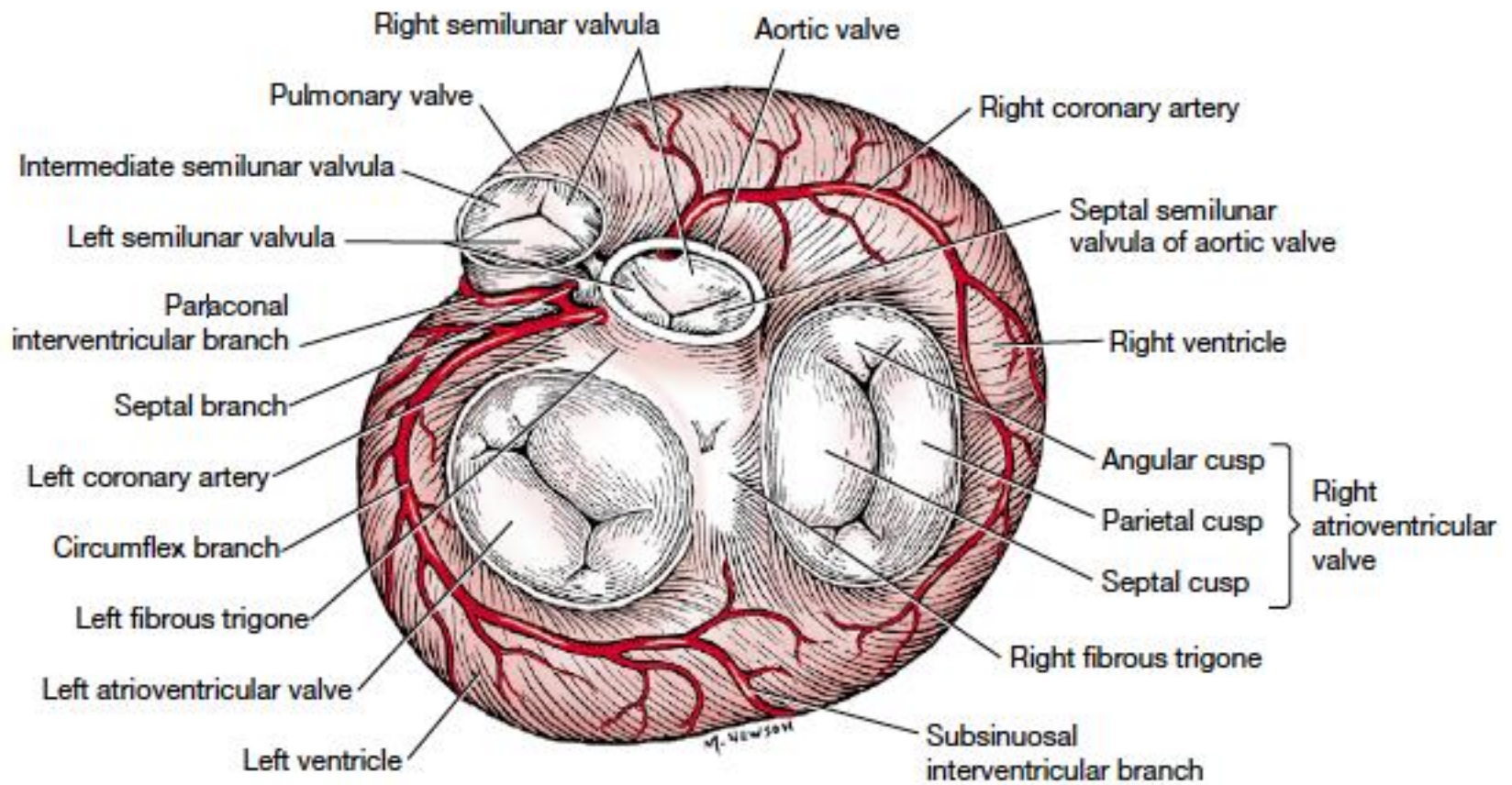
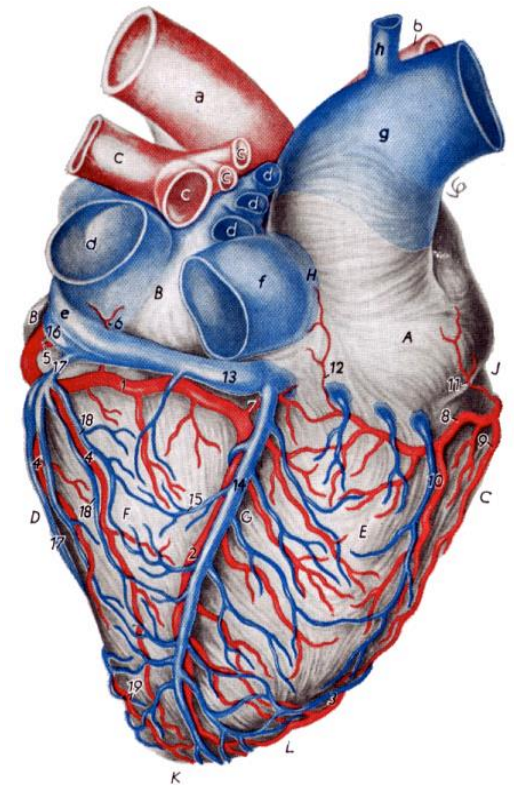
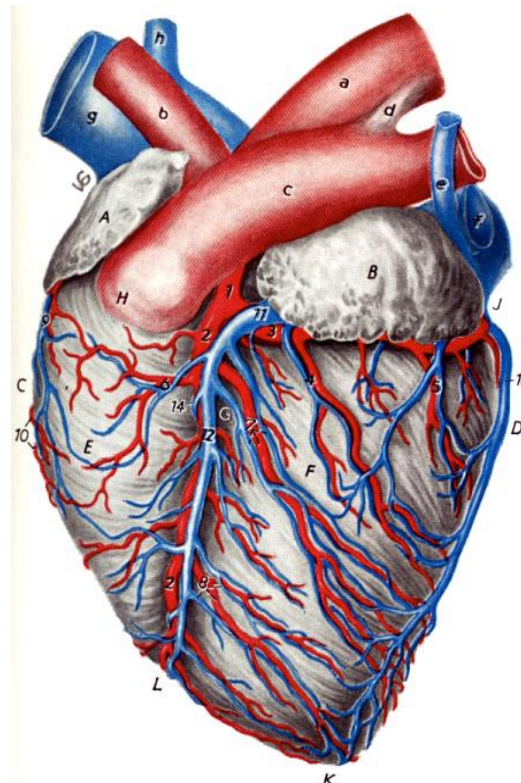
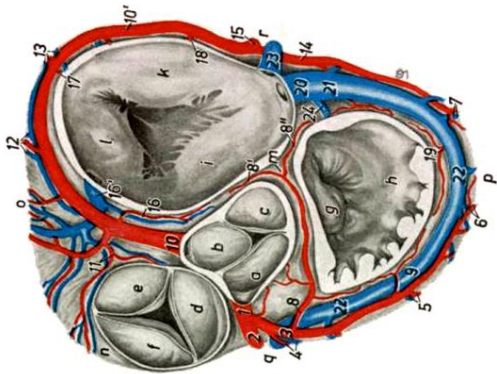
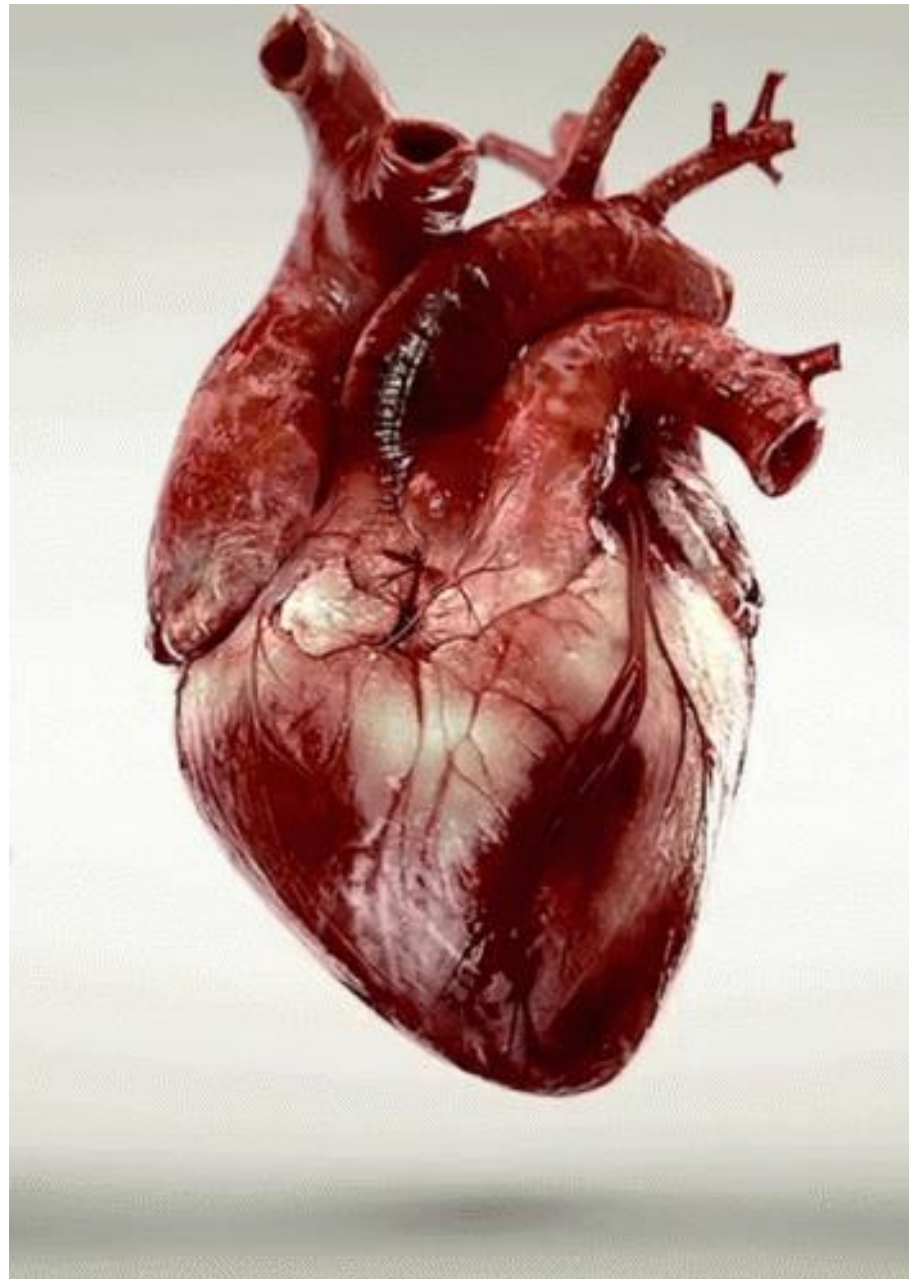


Fig. 3-25 Atrioventricular, aortic, and pulmonary valves, dorsoventral view.

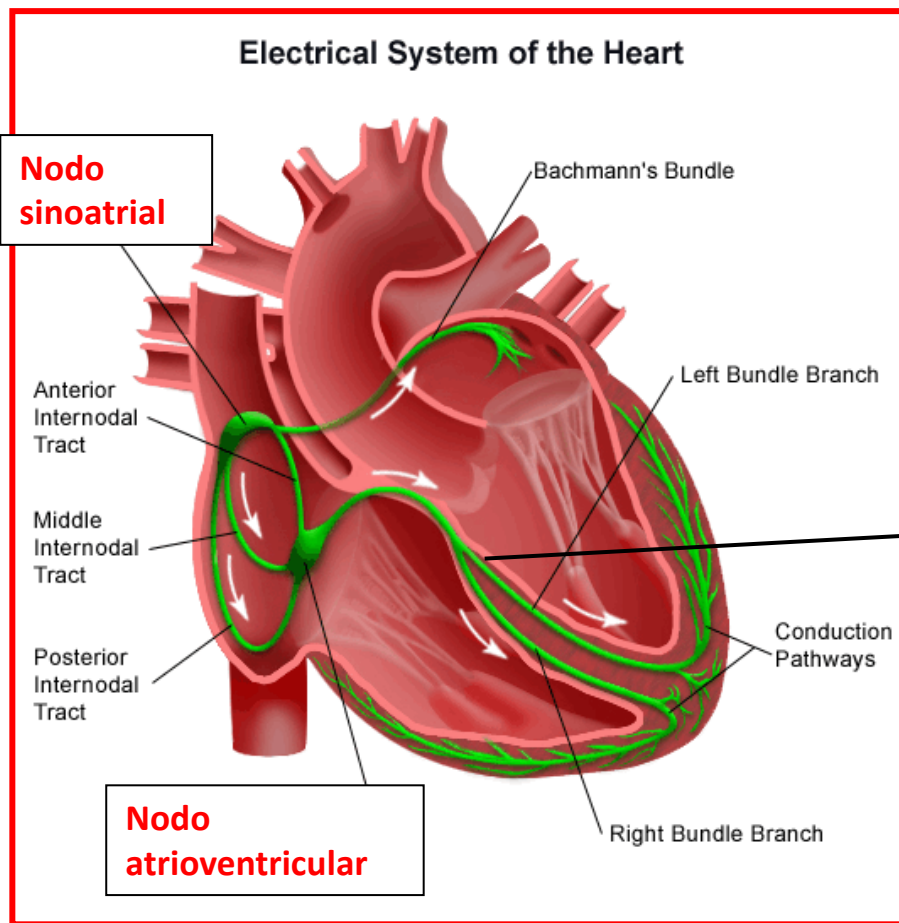
Retorno venoso

- Veia cardíaca magna – no sulco interventricular paraconal
- Veia cardíaca média – no sulco interventricular subsinuoso





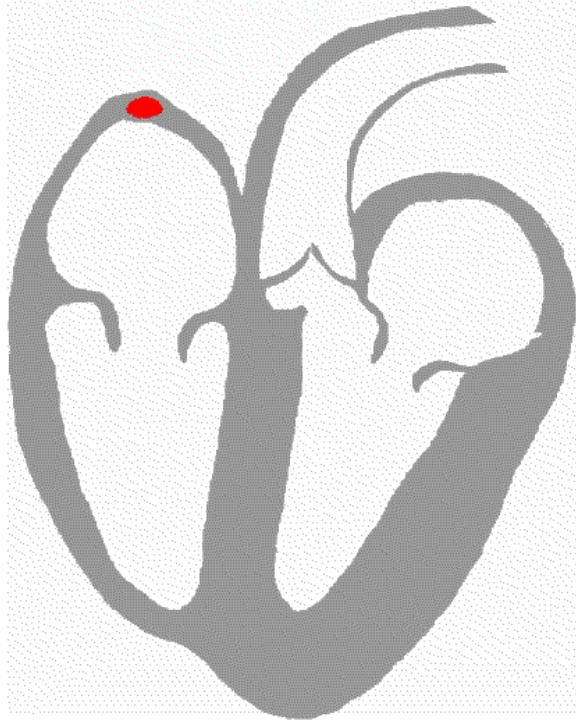
Sistema de condução elétrica



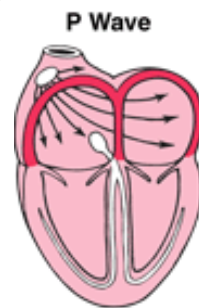
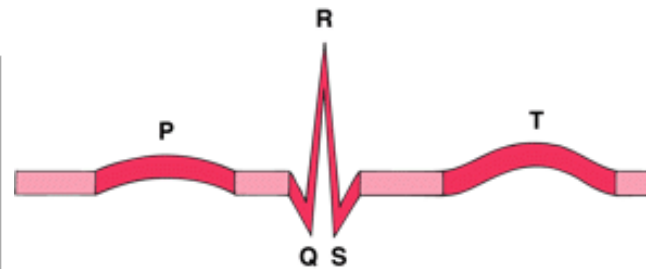

Sob influência do sistema Nervoso Autônomo

Fascículo atrioventricular

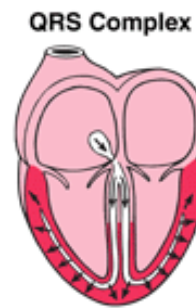
Atividade elétrica do coração



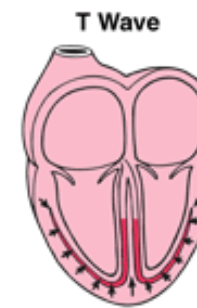
- 1- Nodo sinoatrial
- 2- despolarização atrial
- 3- Nodo atrioventricular
- 4- despolarização ventricular



Activation of the atria

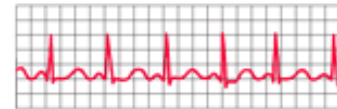


Activation of the ventricles

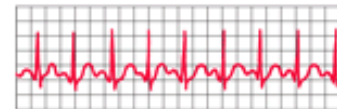


Recovery wave

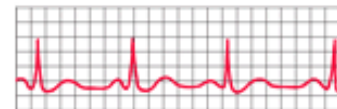
Normal Heartbeat



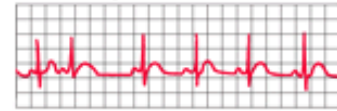
Fast Heartbeat



Slow Heartbeat

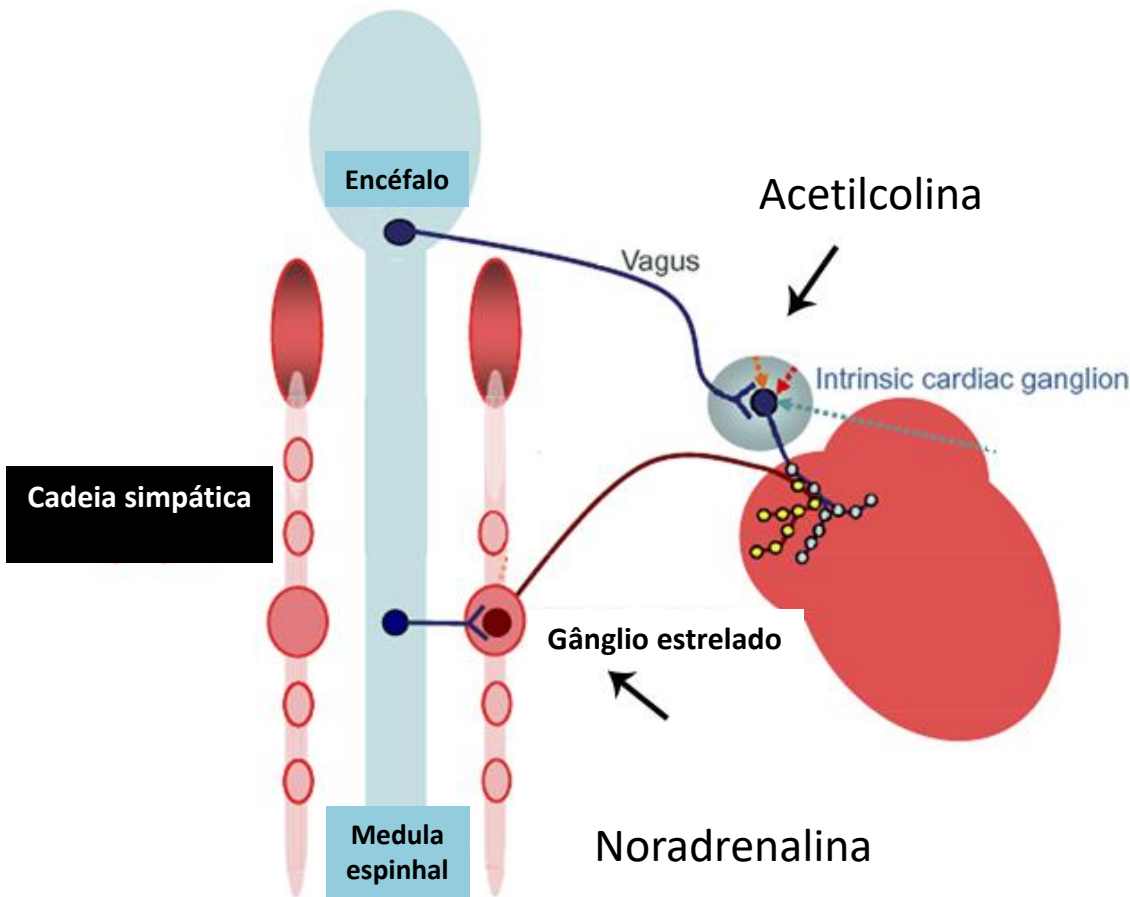


Irregular Heartbeat



Inervação autônoma do Coração

J. L. Hoard et al. / Neuroscience 156 (2008) 129–142

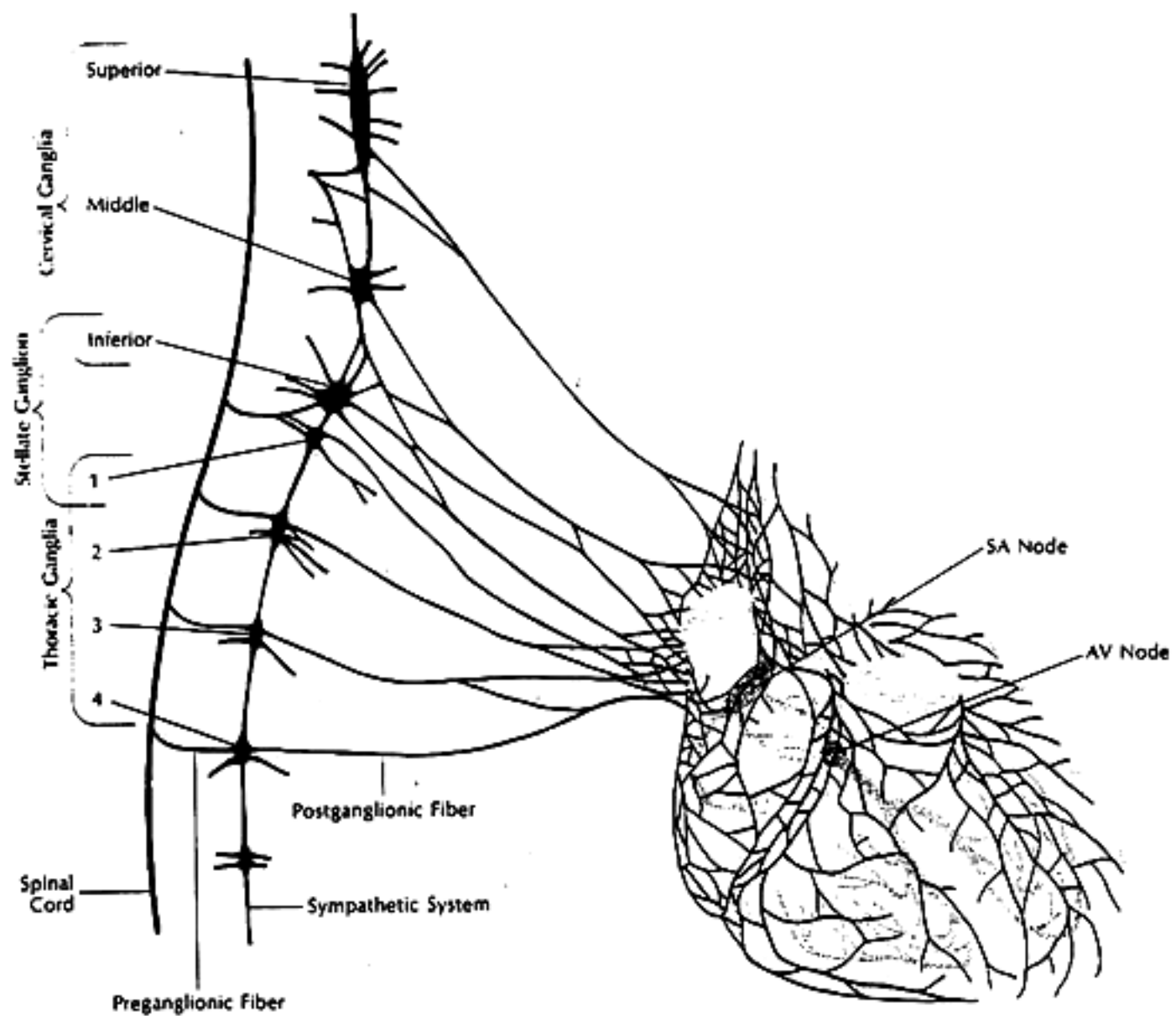


Inervação parassimpática

Inervação simpática

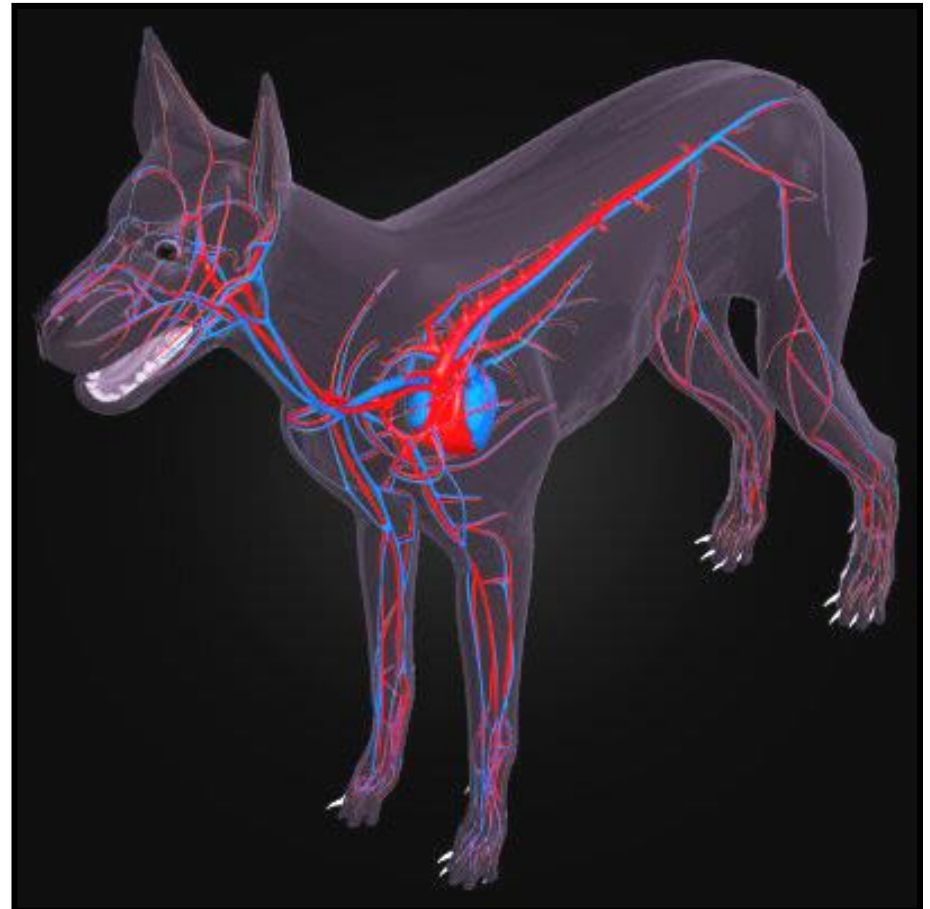
**Frequência cardíaca e
força de contração
Inervação Colinérgica**

**Frequência cardíaca e
força de contração
Inervação
Adrenérgica**

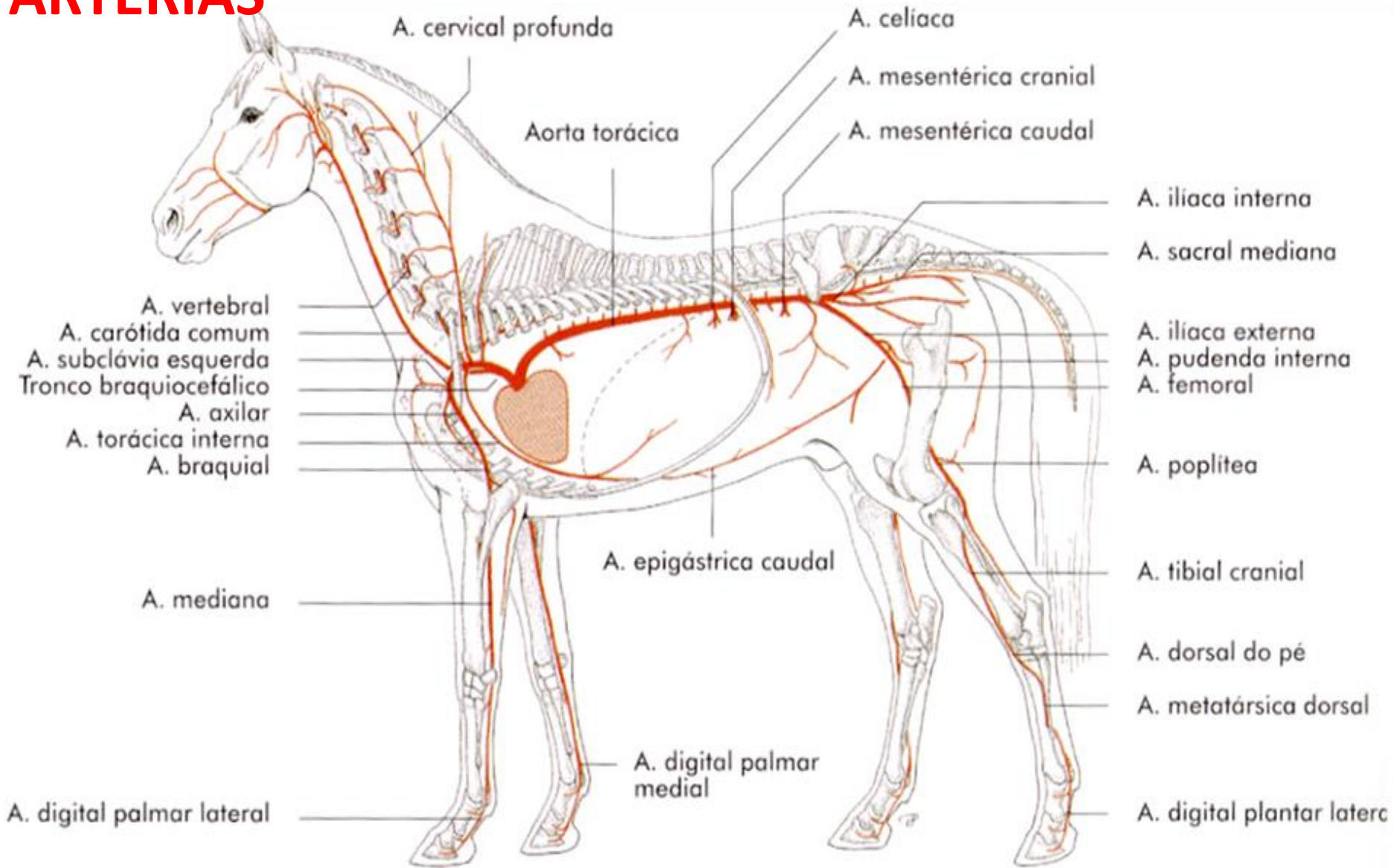


COMPONENTES DO SISTEMA CARDIOVASCULAR

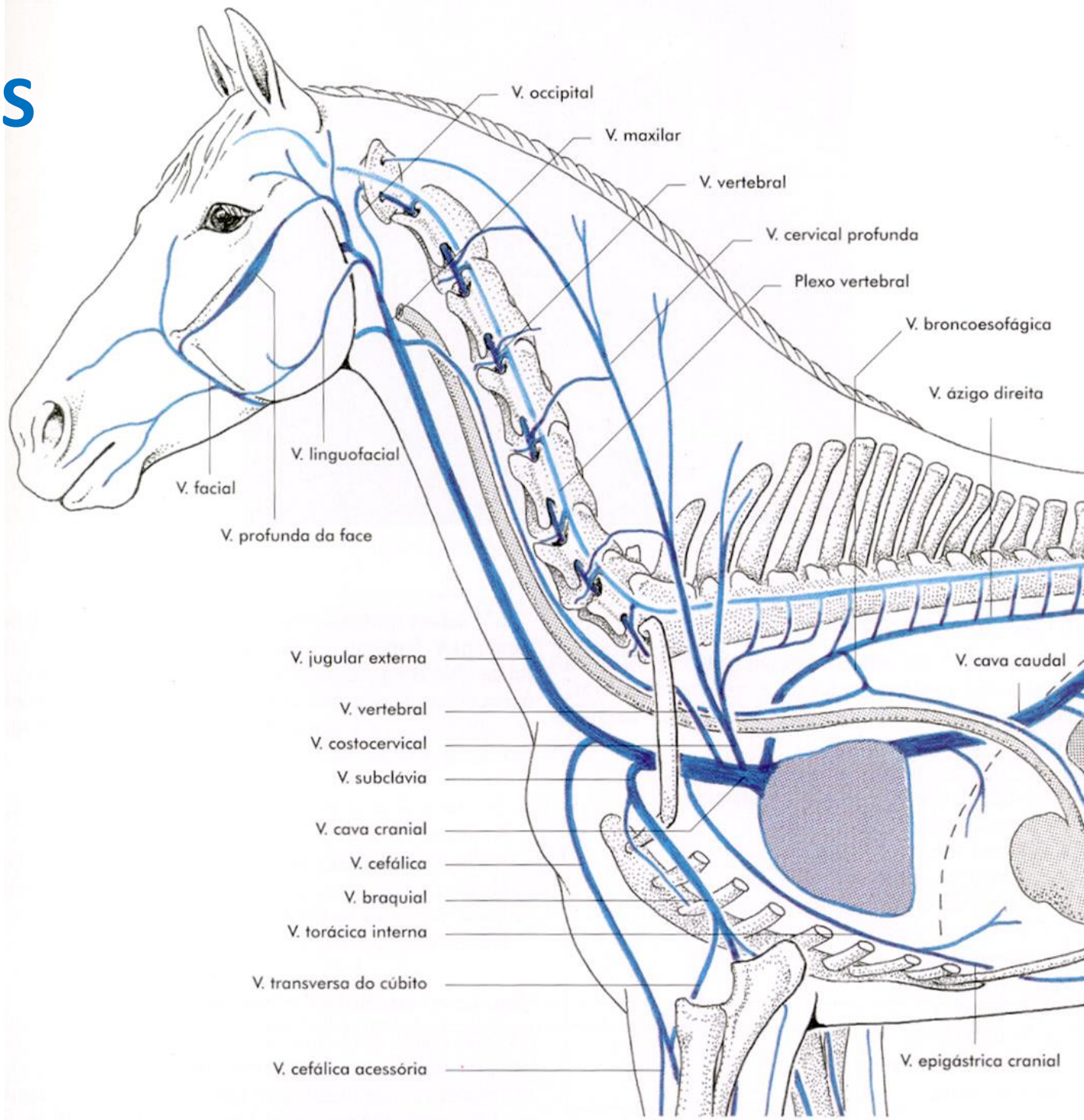
- **Coração**
- **Vasos sanguíneos**
 - Artérias
 - Arteríolas
 - Veias
 - Vênulas
 - Capilares
- **Vasos linfáticos**



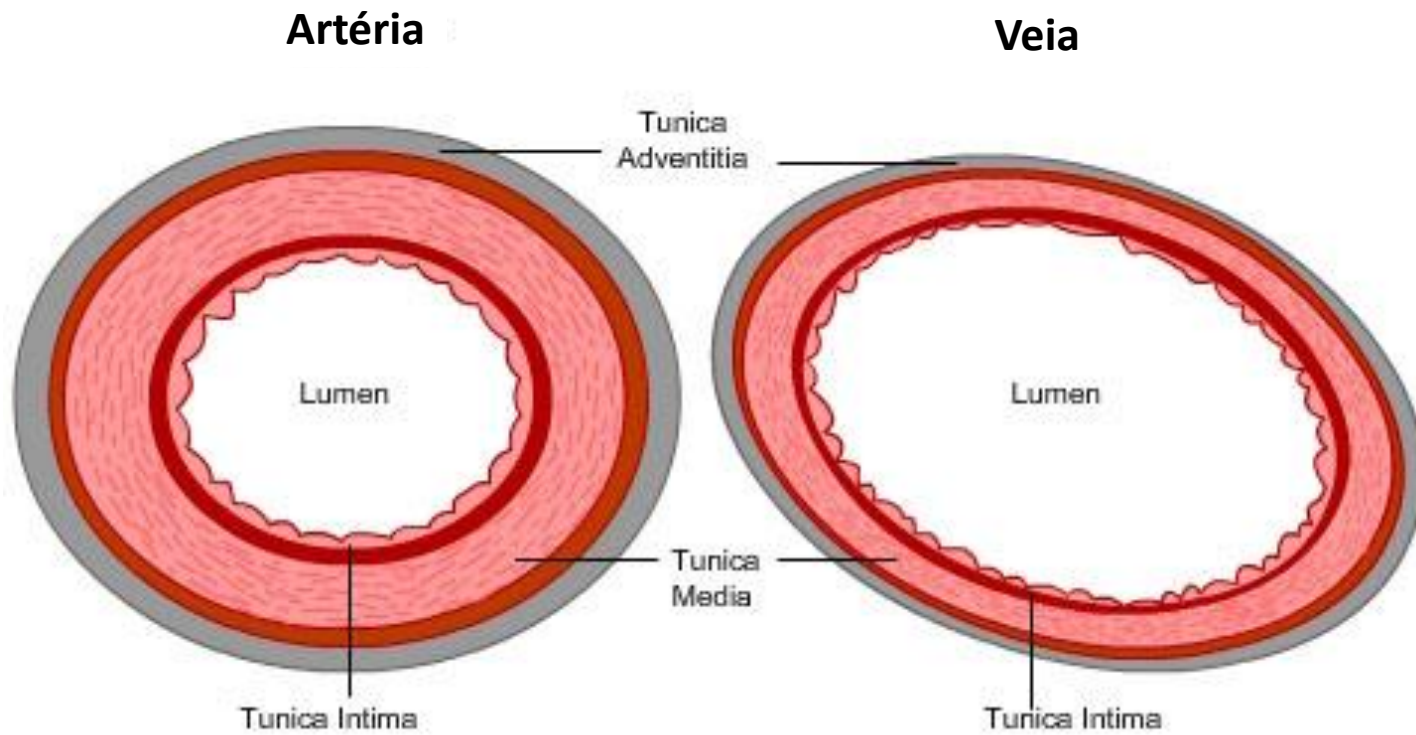
ARTÉRIAS

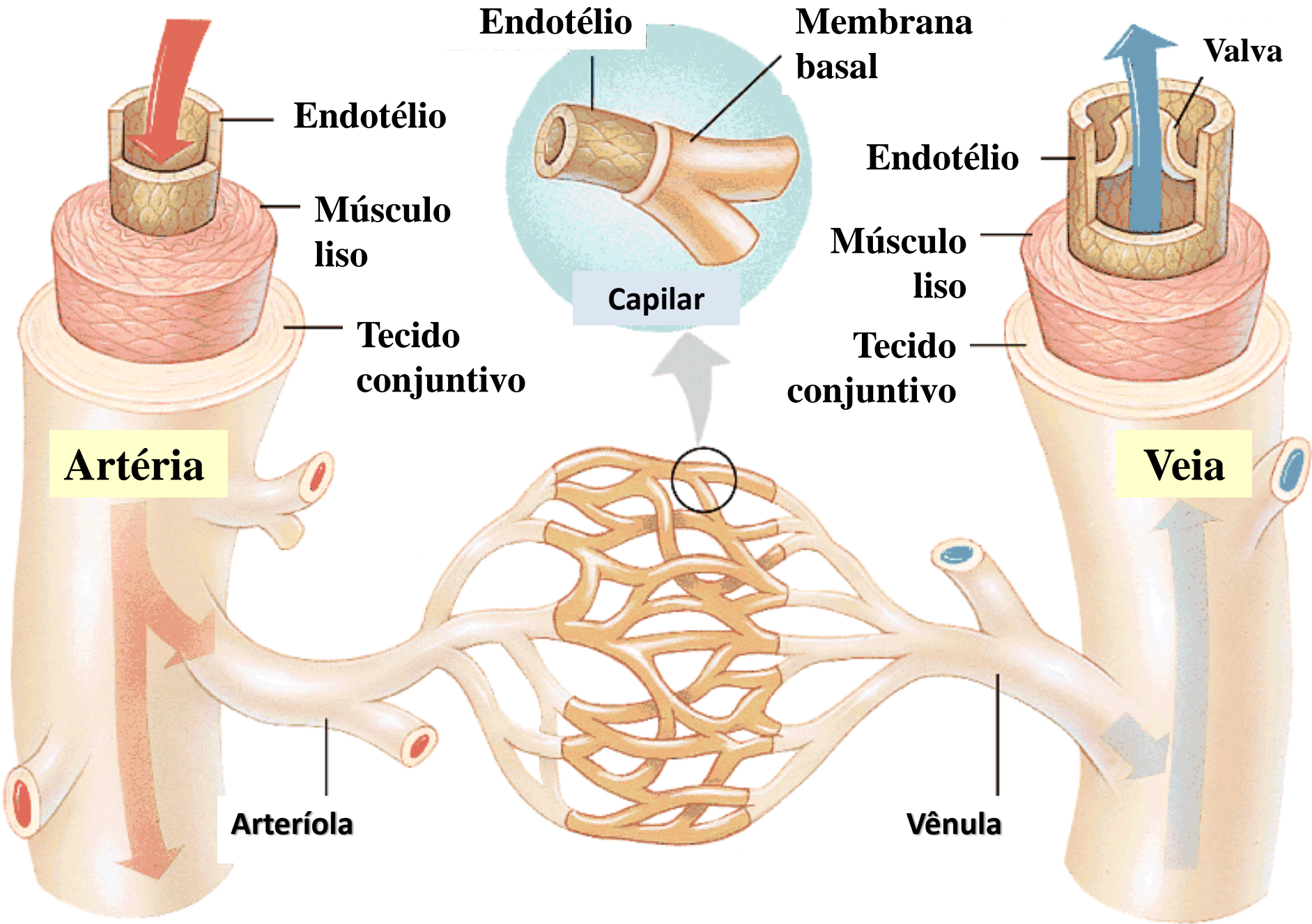


VEIAS



Artéria x veia





Endotélio

Membrana basal

Valva

Endotélio

Músculo liso

Tecido conjuntivo

Artéria

Capilar

Endotélio

Músculo liso

Tecido conjuntivo

Veia

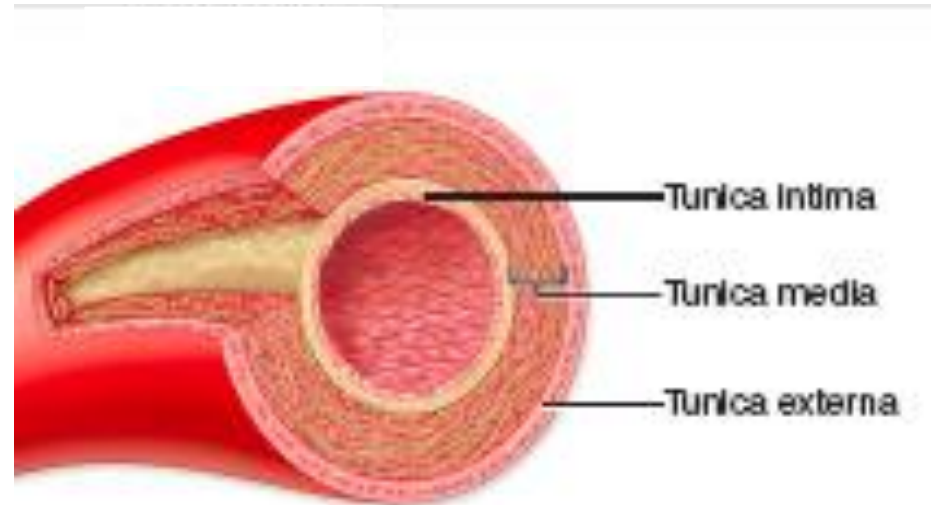
Arteriola

Vênula

Vasos sanguíneos

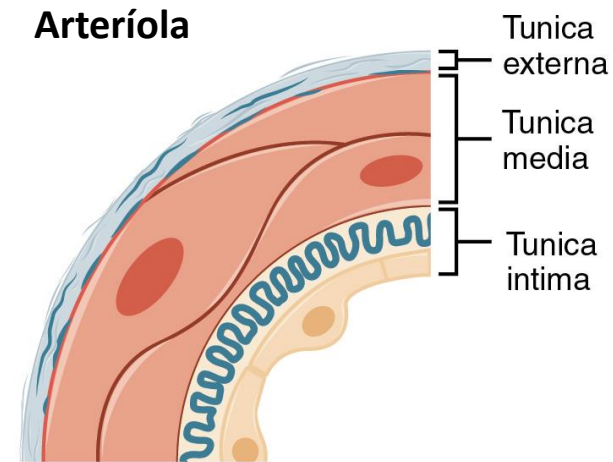
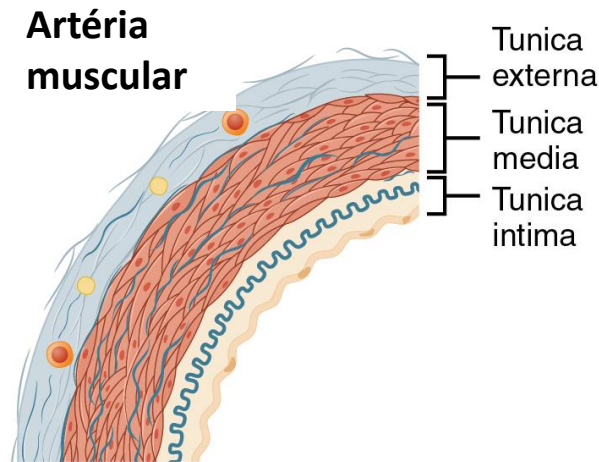
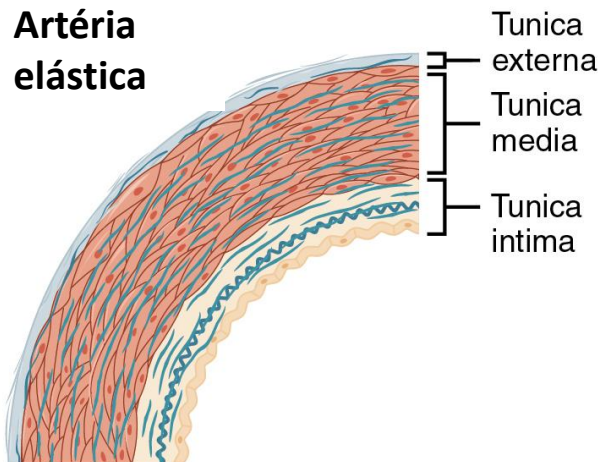
ORGANIZAÇÃO GERAL DOS VASOS SANGUÍNEOS

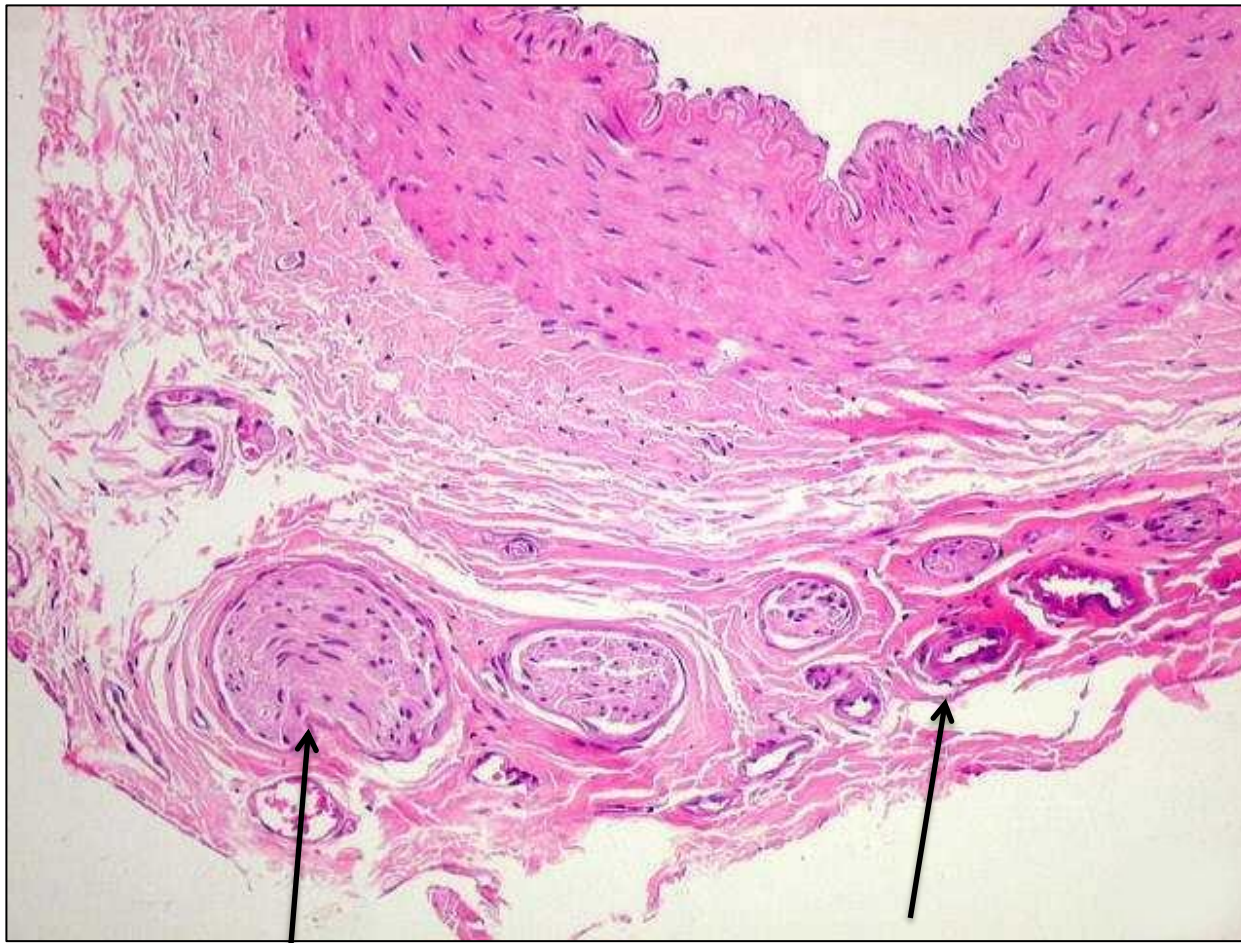
- **Túnica íntima**
- **Túnica média**
- **Túnica adventícia**



Sistema de alta pressão

- Artérias elásticas (maiores artérias)
- Artérias musculares (médio e pequeno calibre)
- Arteriolas





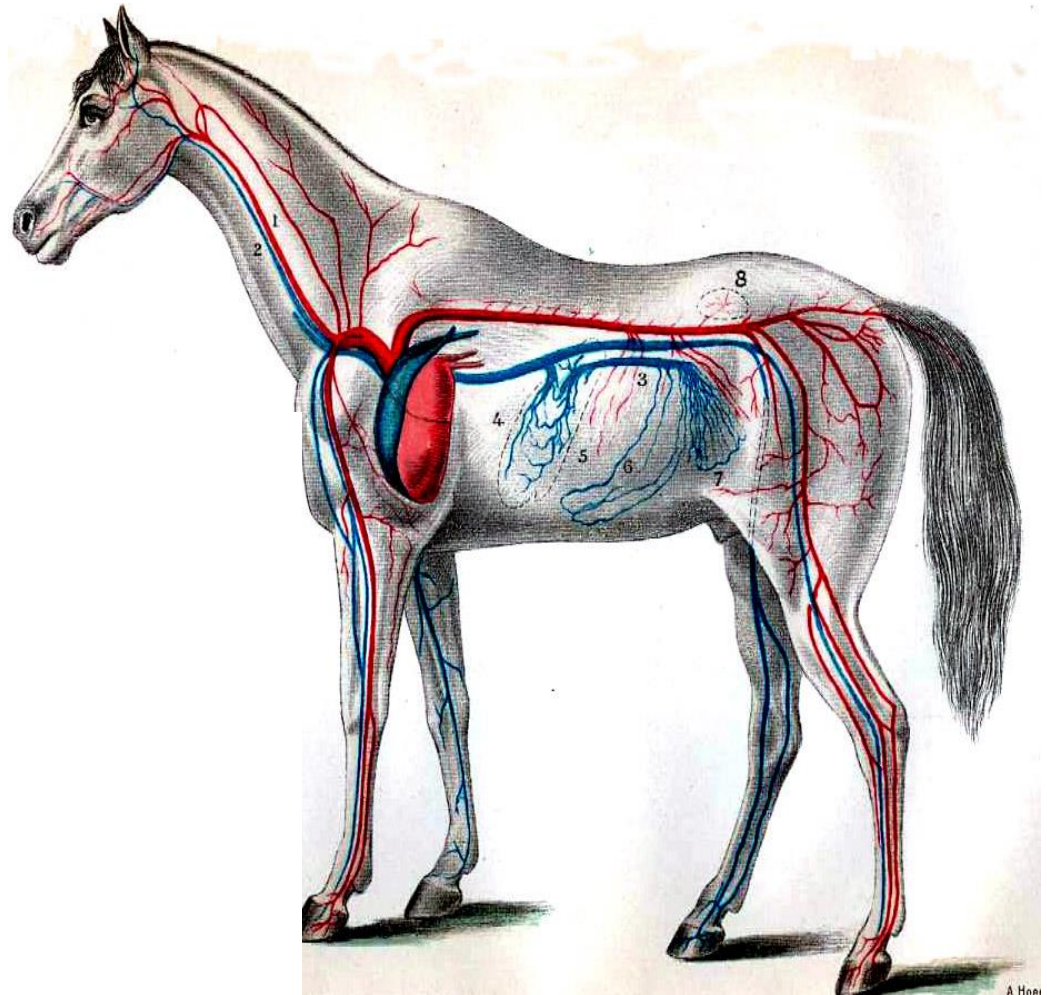
Túnica adventícia

Nervi vasorum

Vasa vasorum

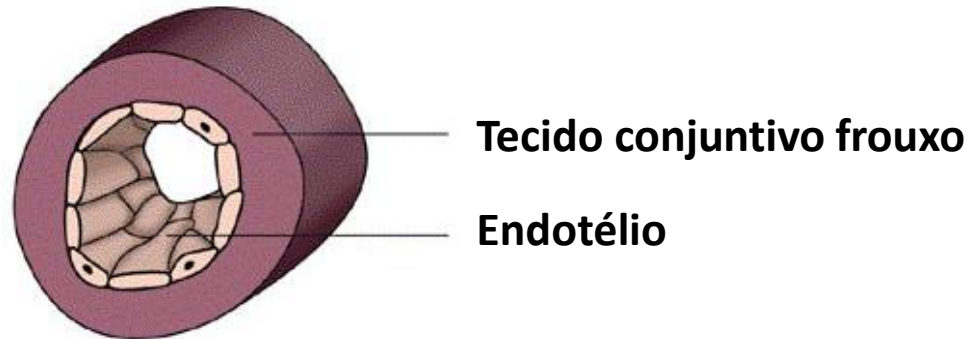
Sistema de baixa pressão

- Vênulas
- Veias
 - Pequenas veias
 - Veias médias
 - Grandes veias



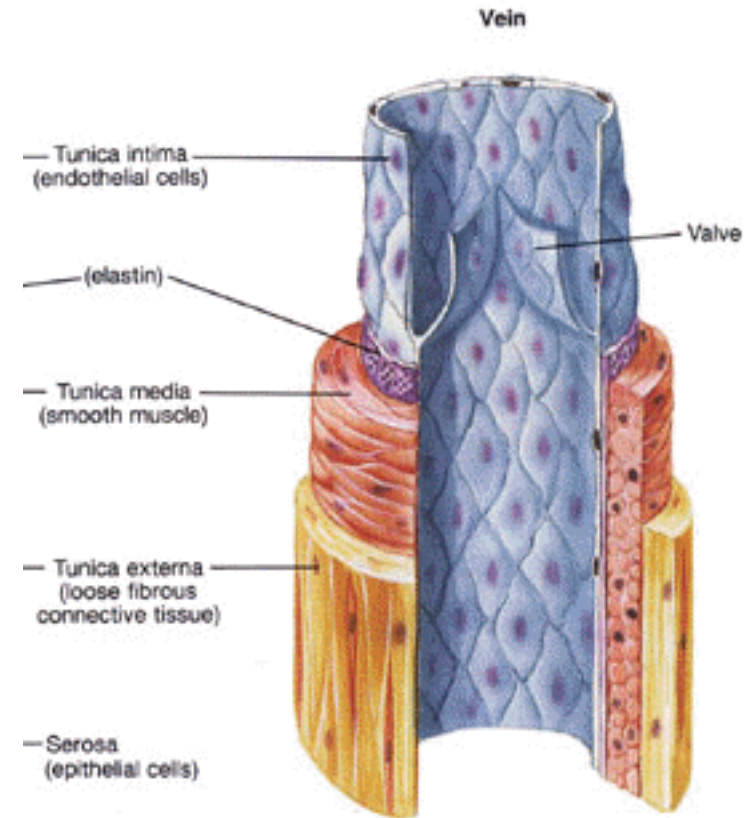
Vênulas

- Tubo endotelial simples envolto por tecido conjuntivo frouxo.



Veias de pequeno e médio calibre

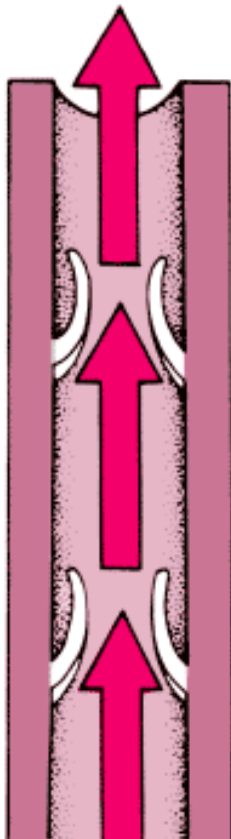
- **Presença de válvulas:** invaginações da túnica íntima para a luz do vaso.



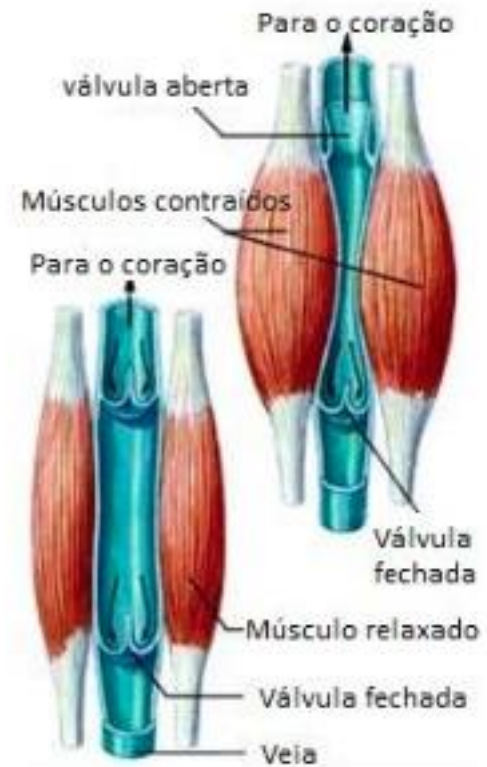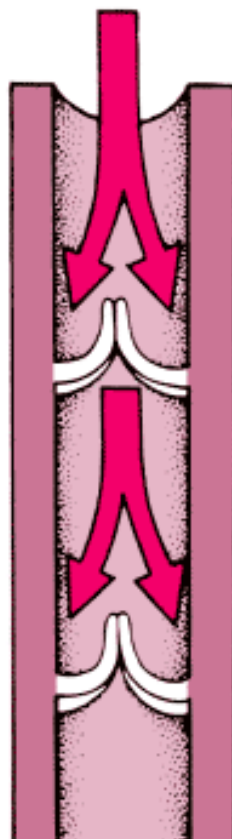
Fox, Stuart I.
Human Physiology 4th
Brown Publishers

Fluxo de sangue venoso

Válvulas Abertas



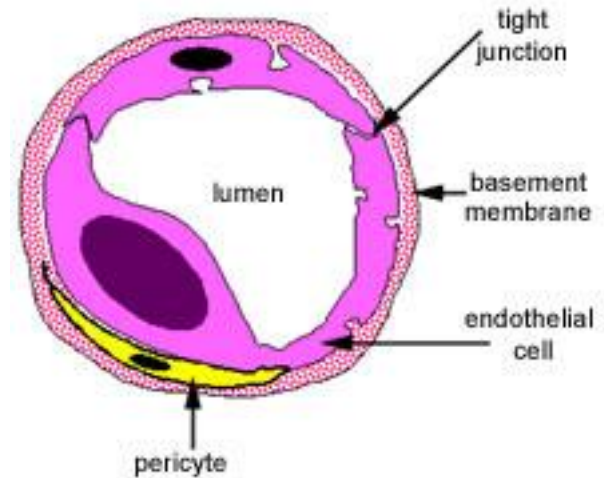
Válvulas Fechadas



Fonte: ennioss.wordpress.com

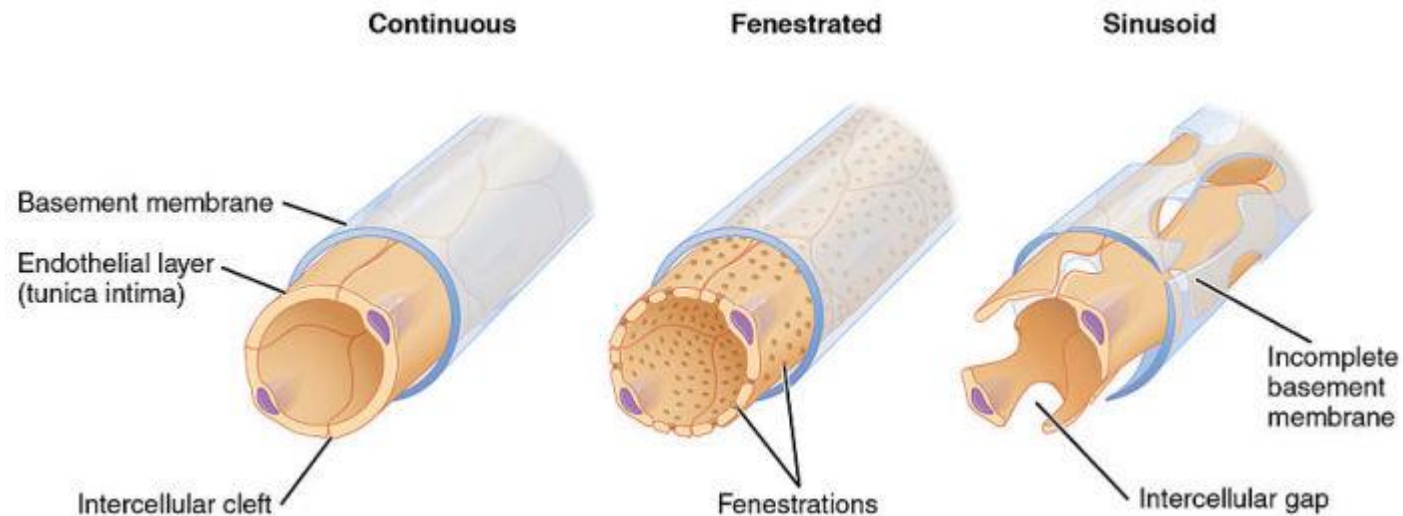
Capilares

- Única camada: células endoteliais.
- Essas células repousam em uma lâmina basal
- Pericitos
 - Participam na formação de novos vasos sanguíneos.

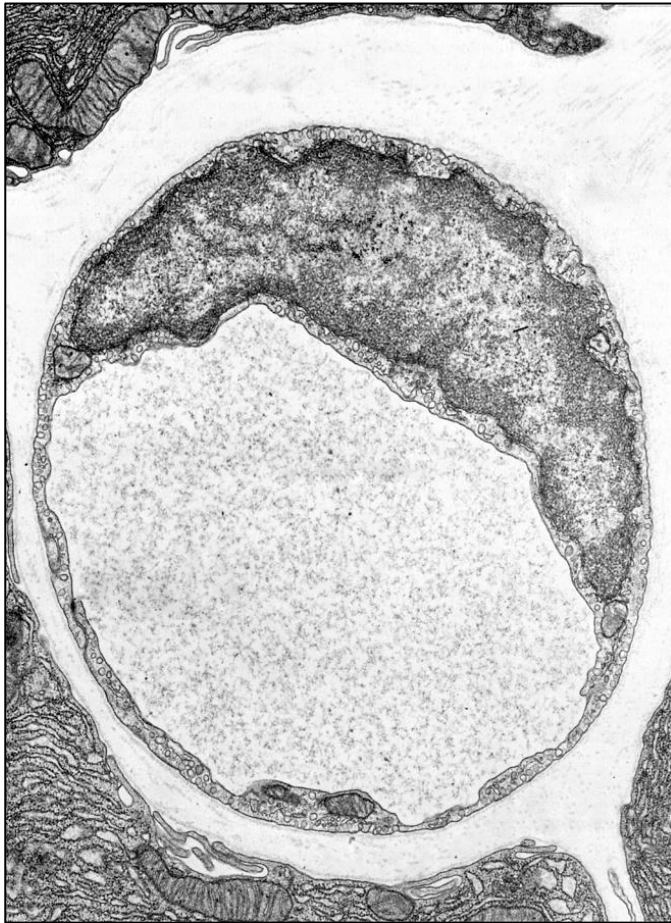


Tipos de capilares

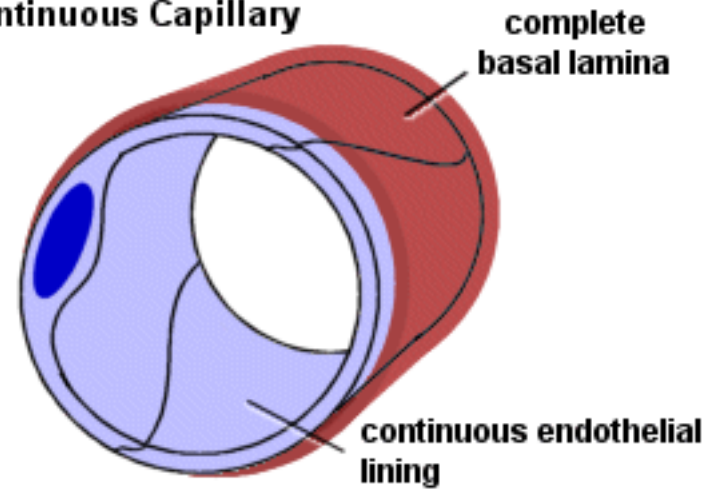
- Endotélio
 - Contínuo ou somático
 - Fenestrado ou visceral
 - Sinusóide



Capilar contínuo

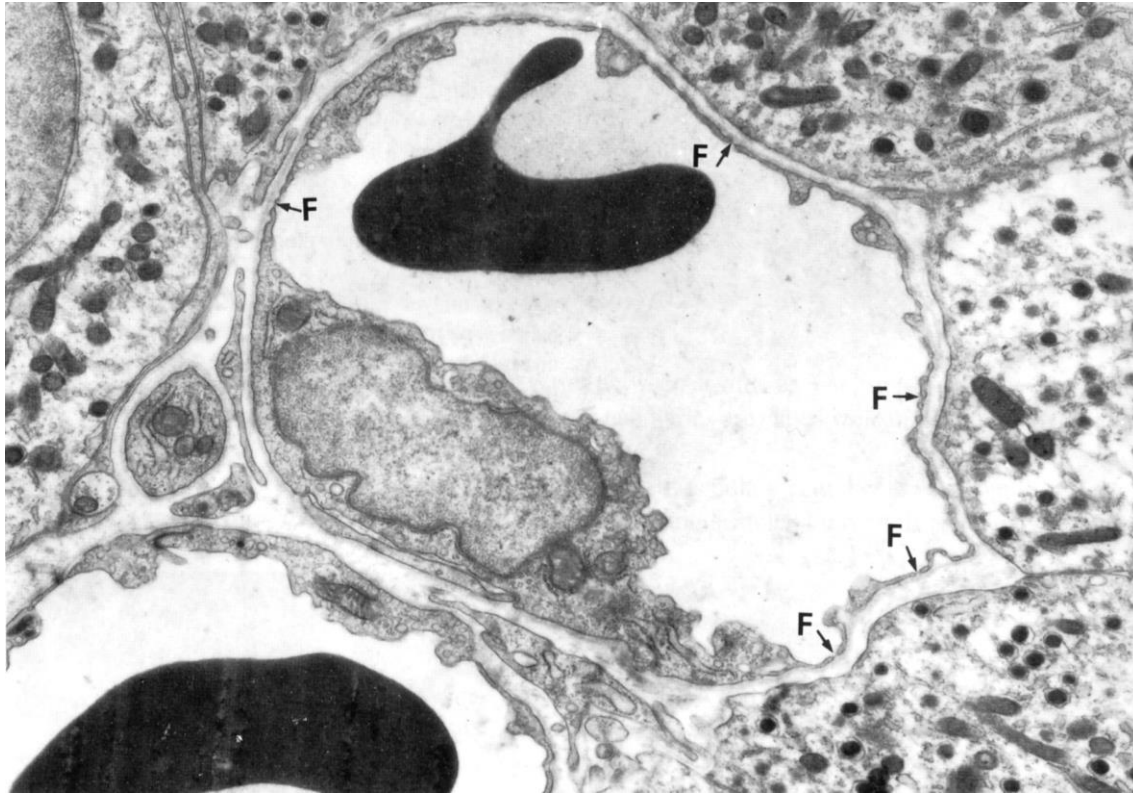


Continuous Capillary

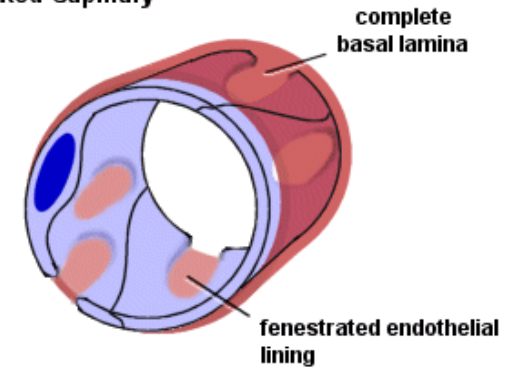


Tecido muscular
Tecido conjuntivo

Capilar fenestrado



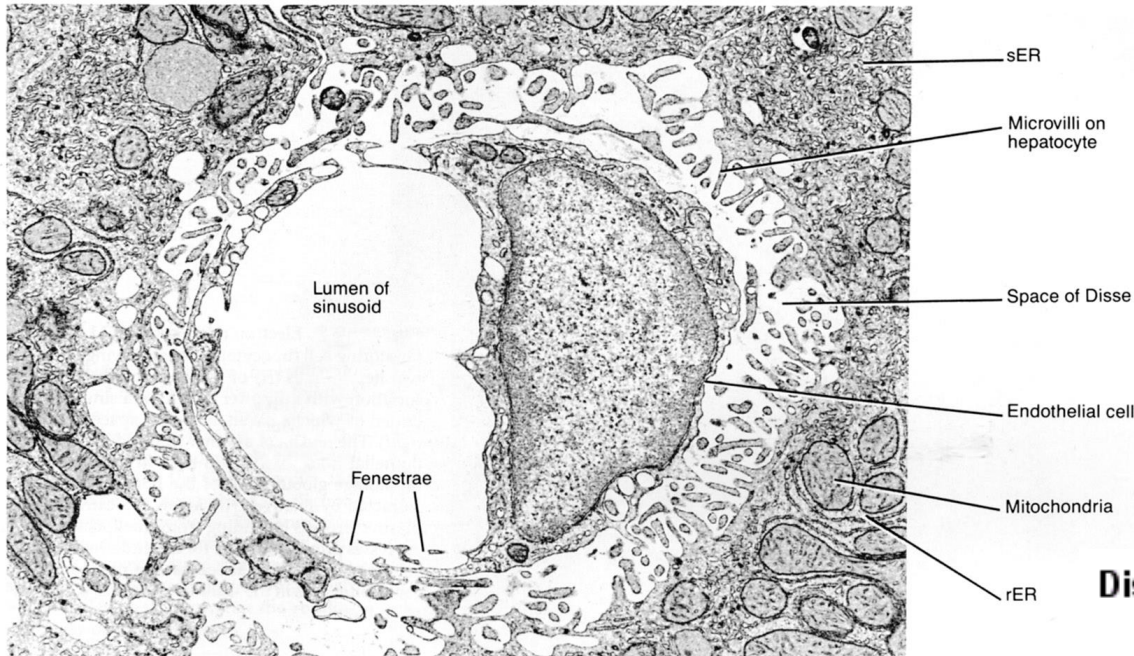
Fenestrated Capillary



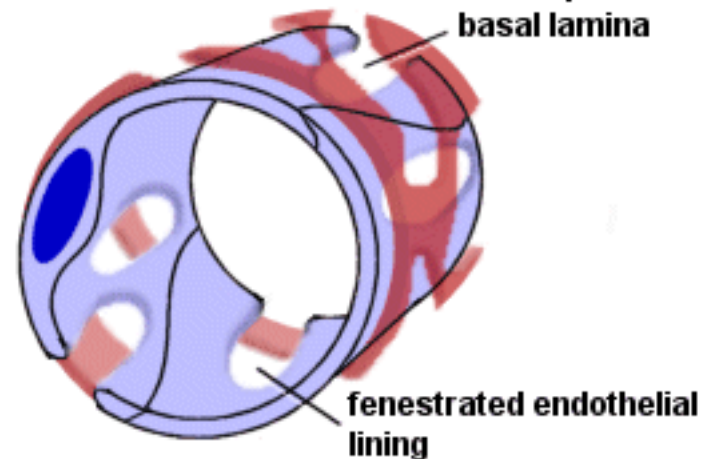
Intestino

Rim

Capilar sinusóide

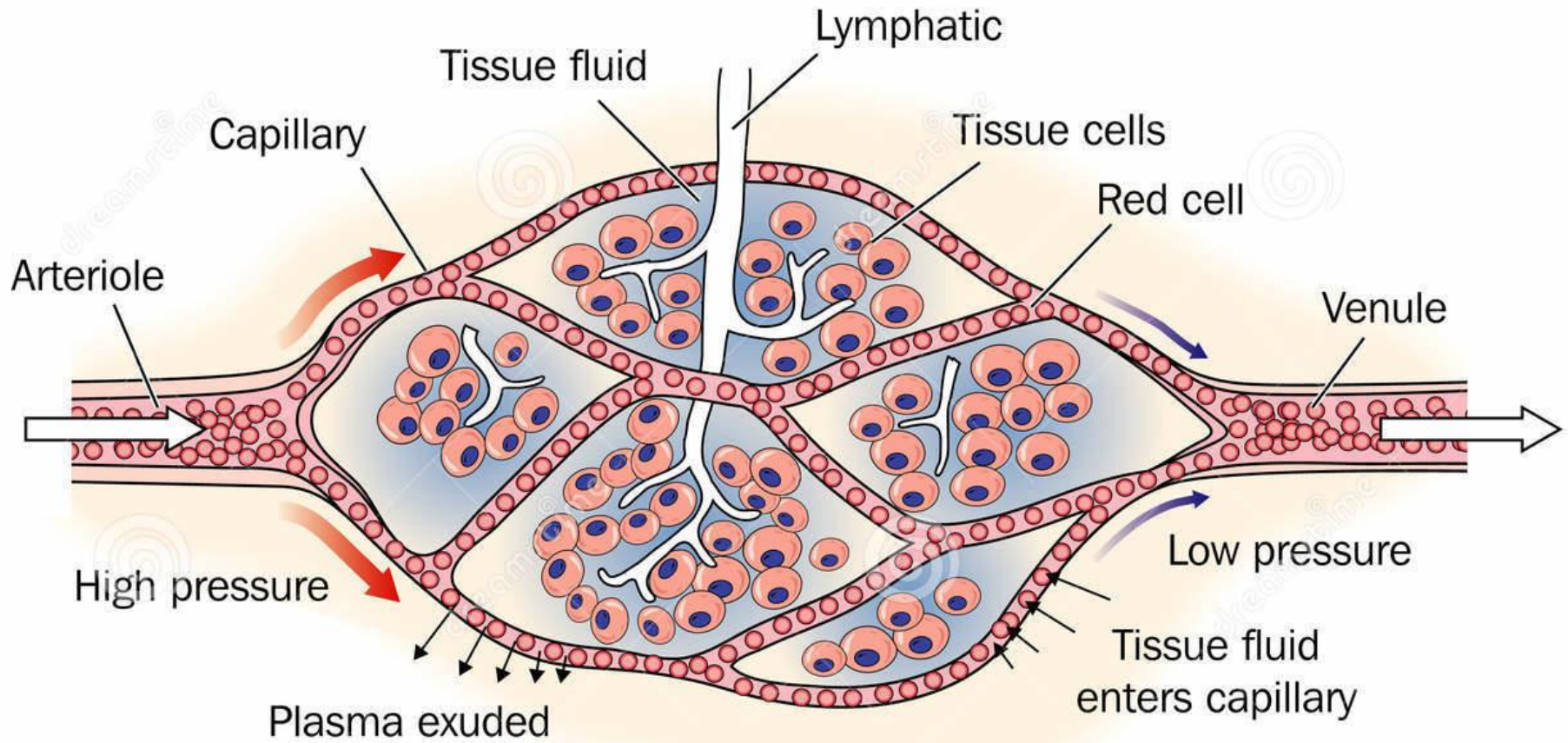


Discontinuous Capillary

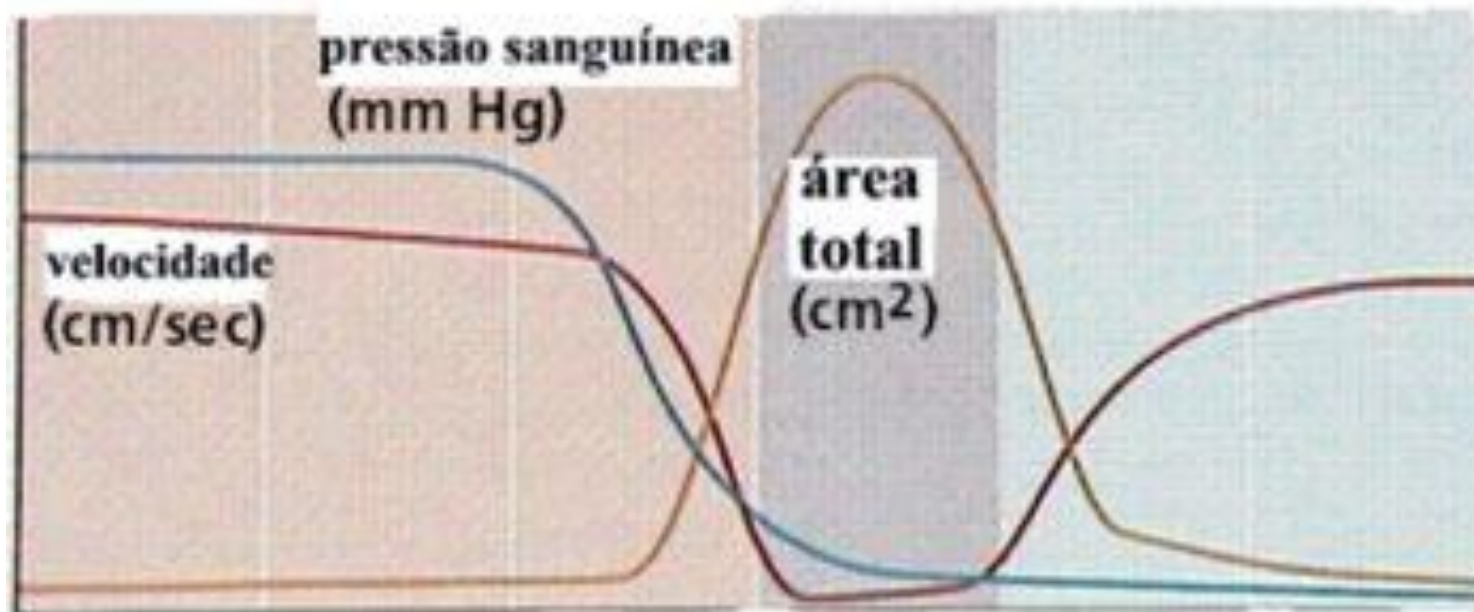
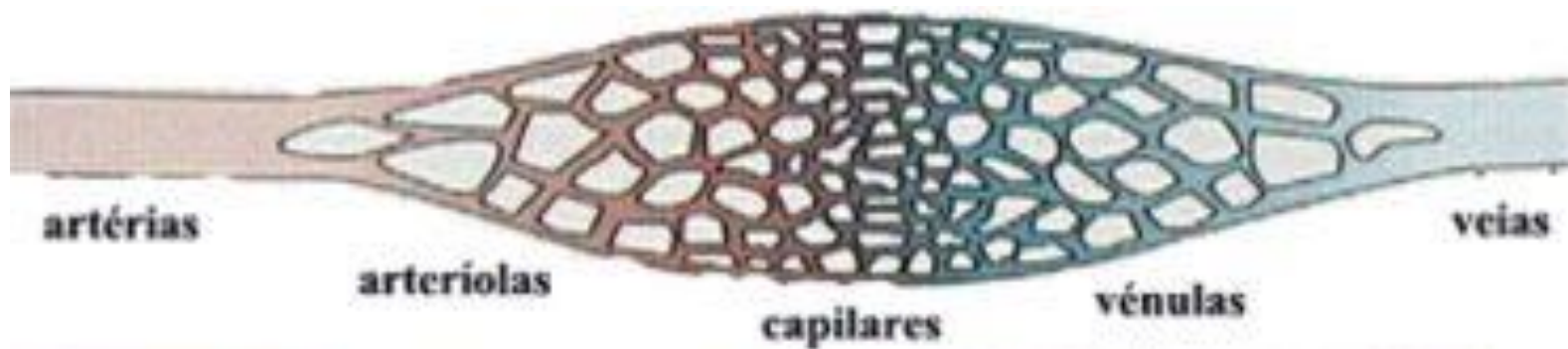


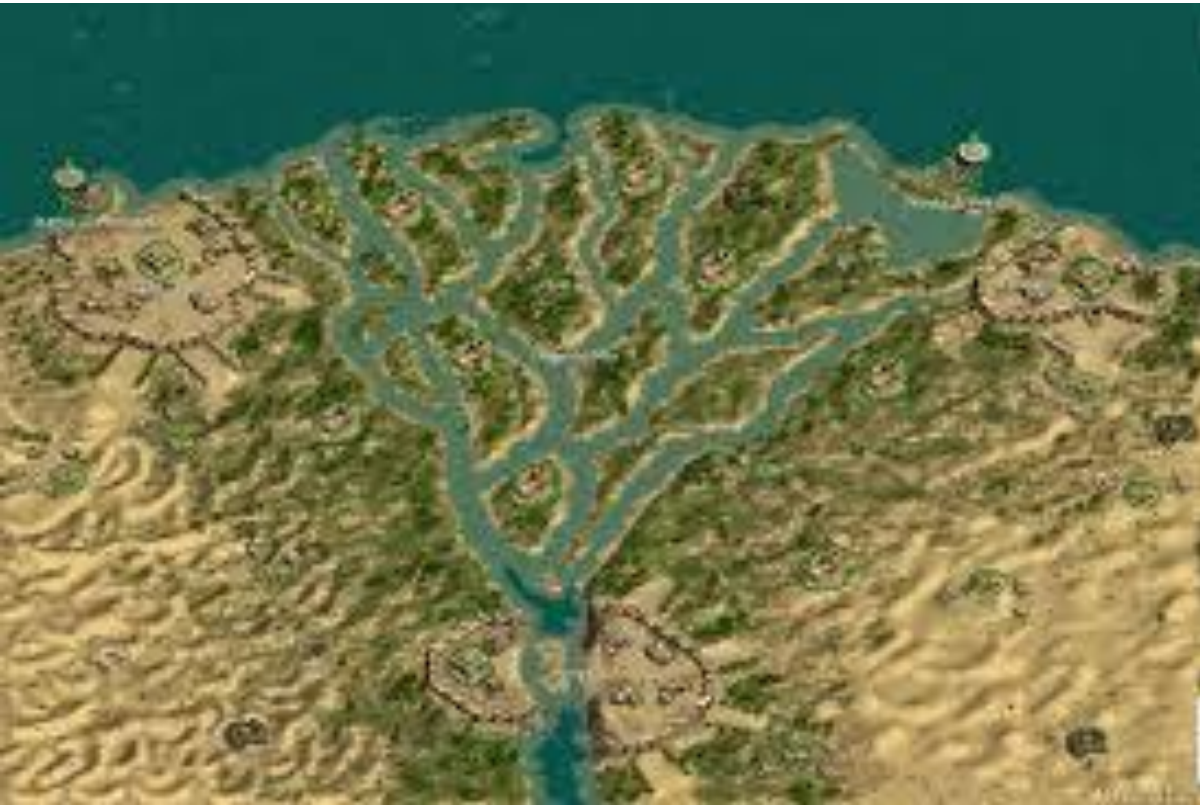Fígado
Medula óssea
Baço

Sistema de troca



Vasos sanguíneos – hemodinâmica

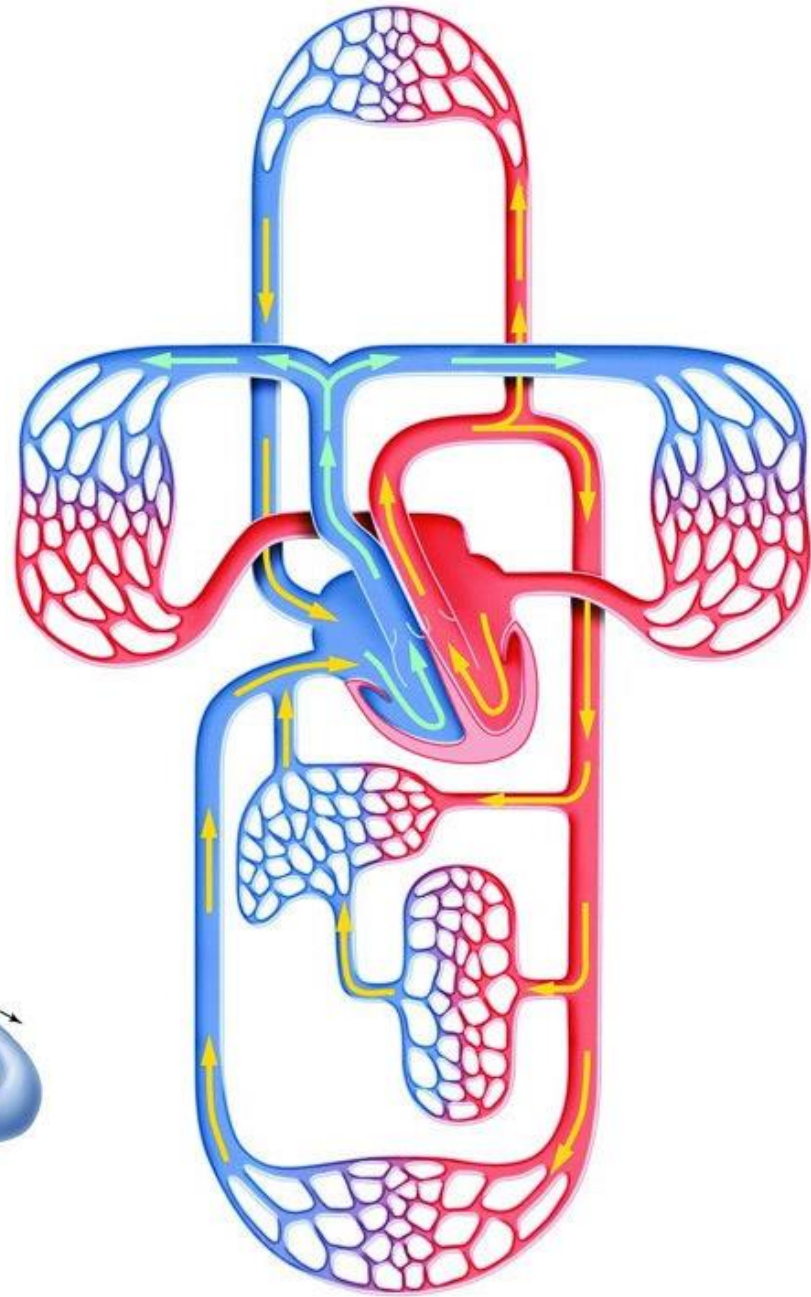
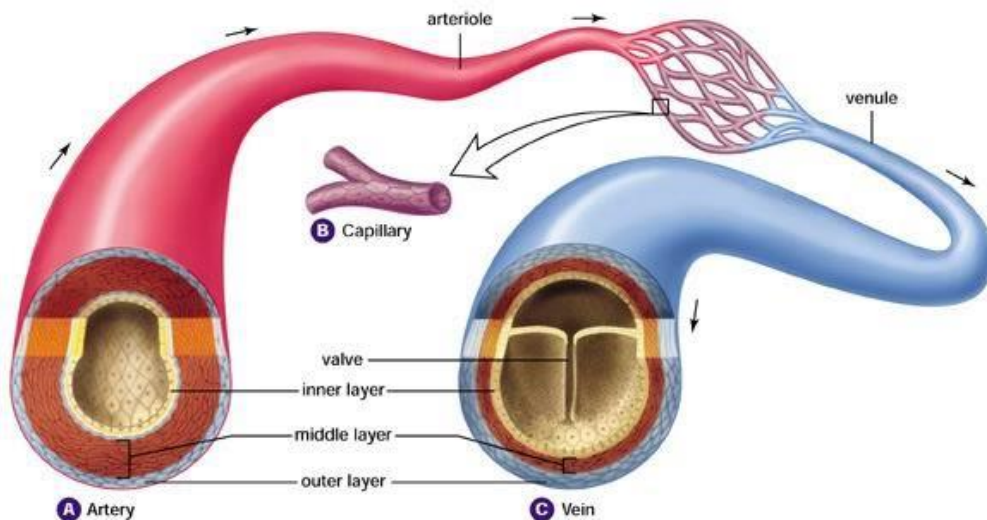




Circulação sanguínea

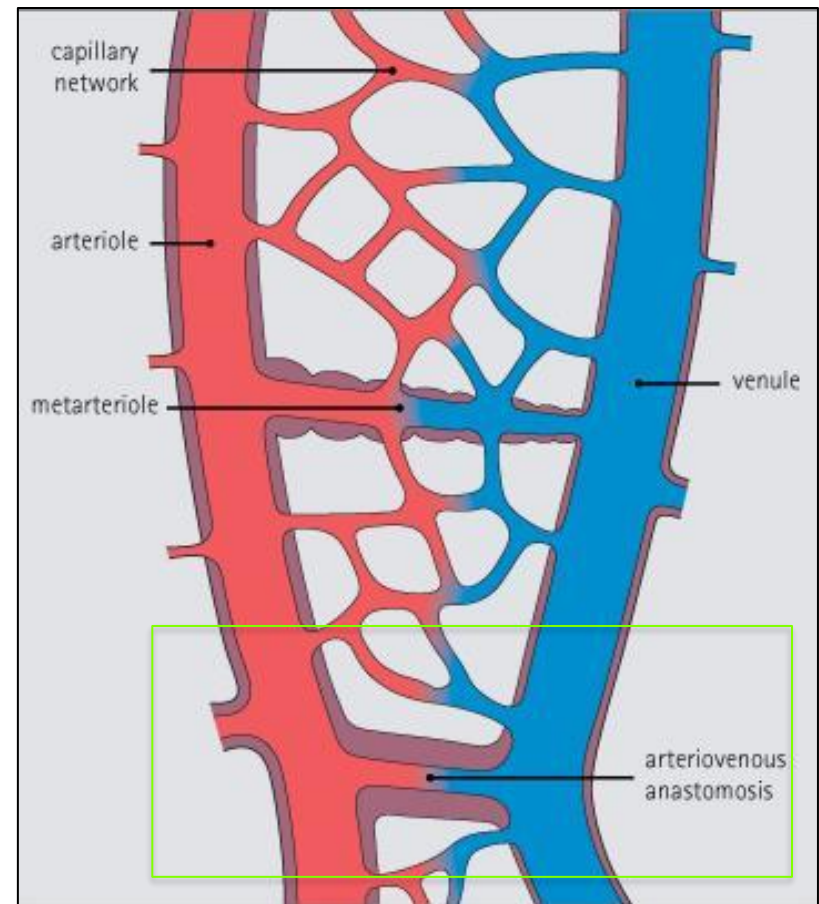
Artérias → Arteríolas → Leitos capilares

Veias ← Vênulas

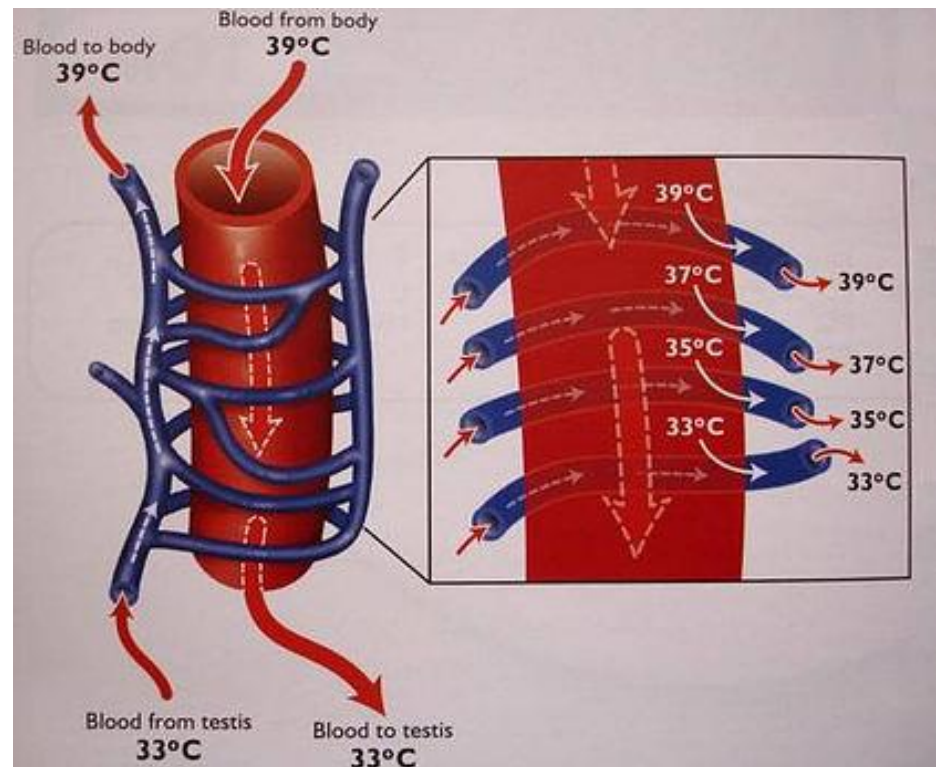
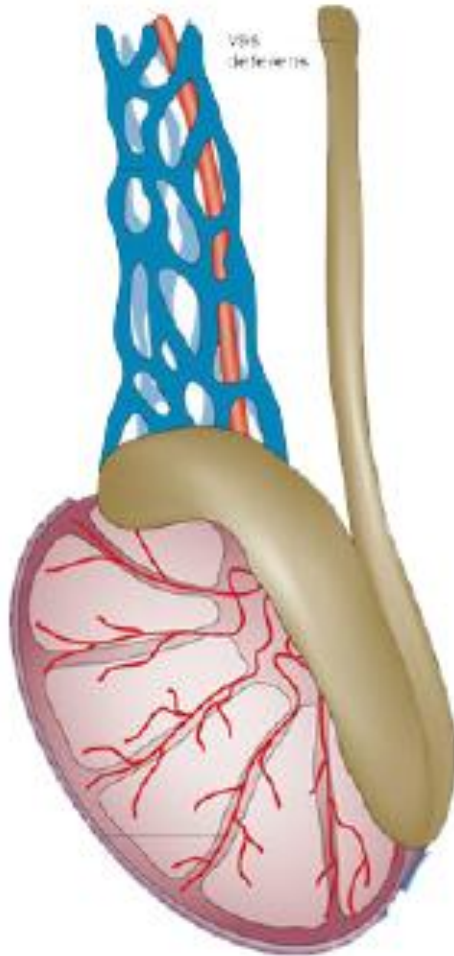


Anastomose arteriovenosa

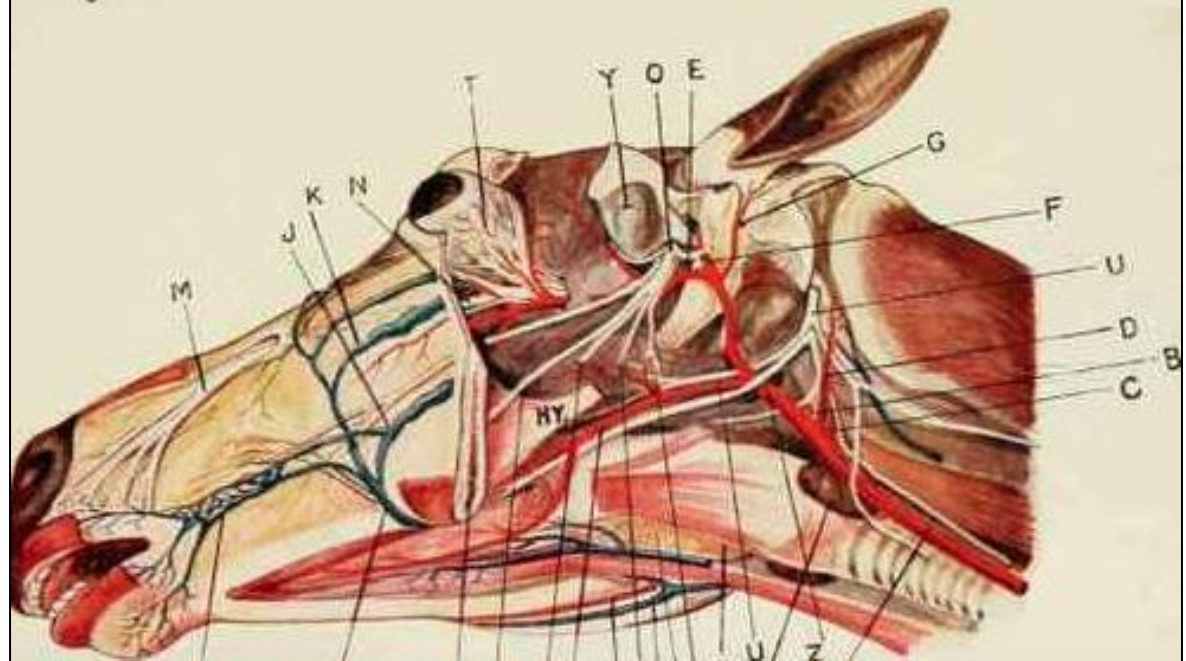
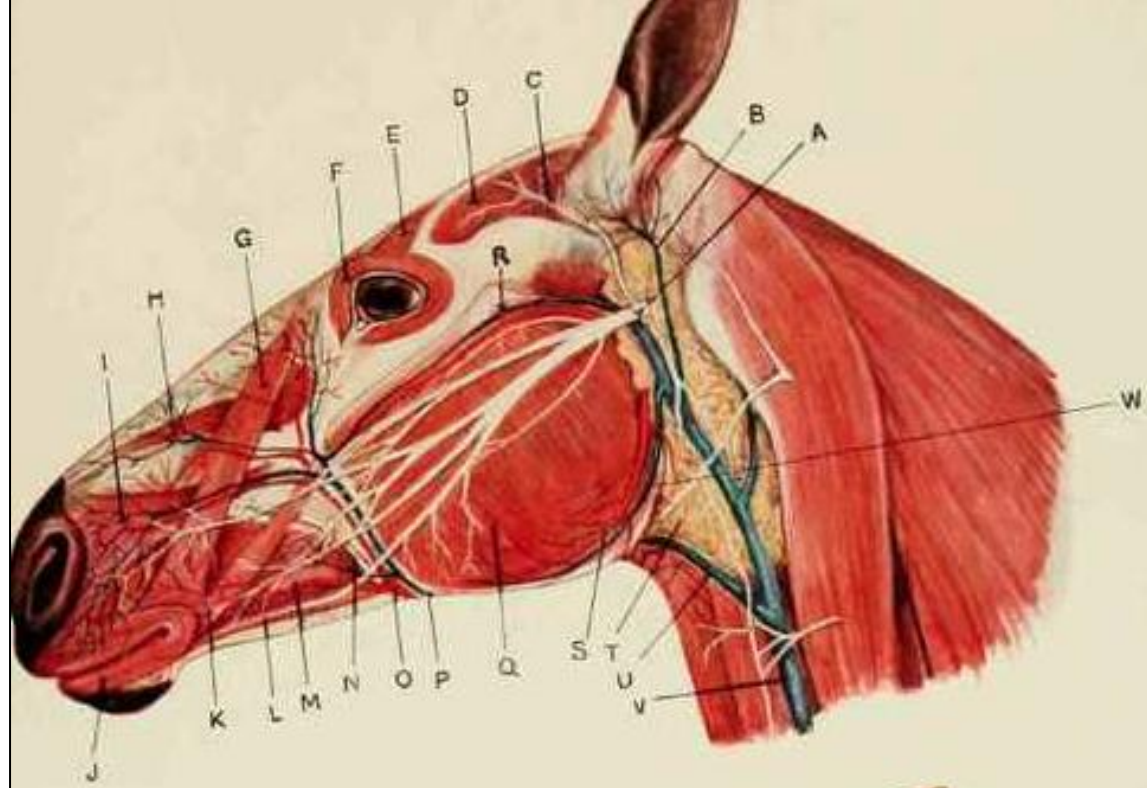
- Conexão direta entre arteríolas e vênulas.
- Regulação da pressão sanguínea e do fluxo sanguíneo para os leitos capilares.
- Termorregulação.
- Lábios, intestino, mucosa nasal, trato reprodutivo machos e fêmeas.

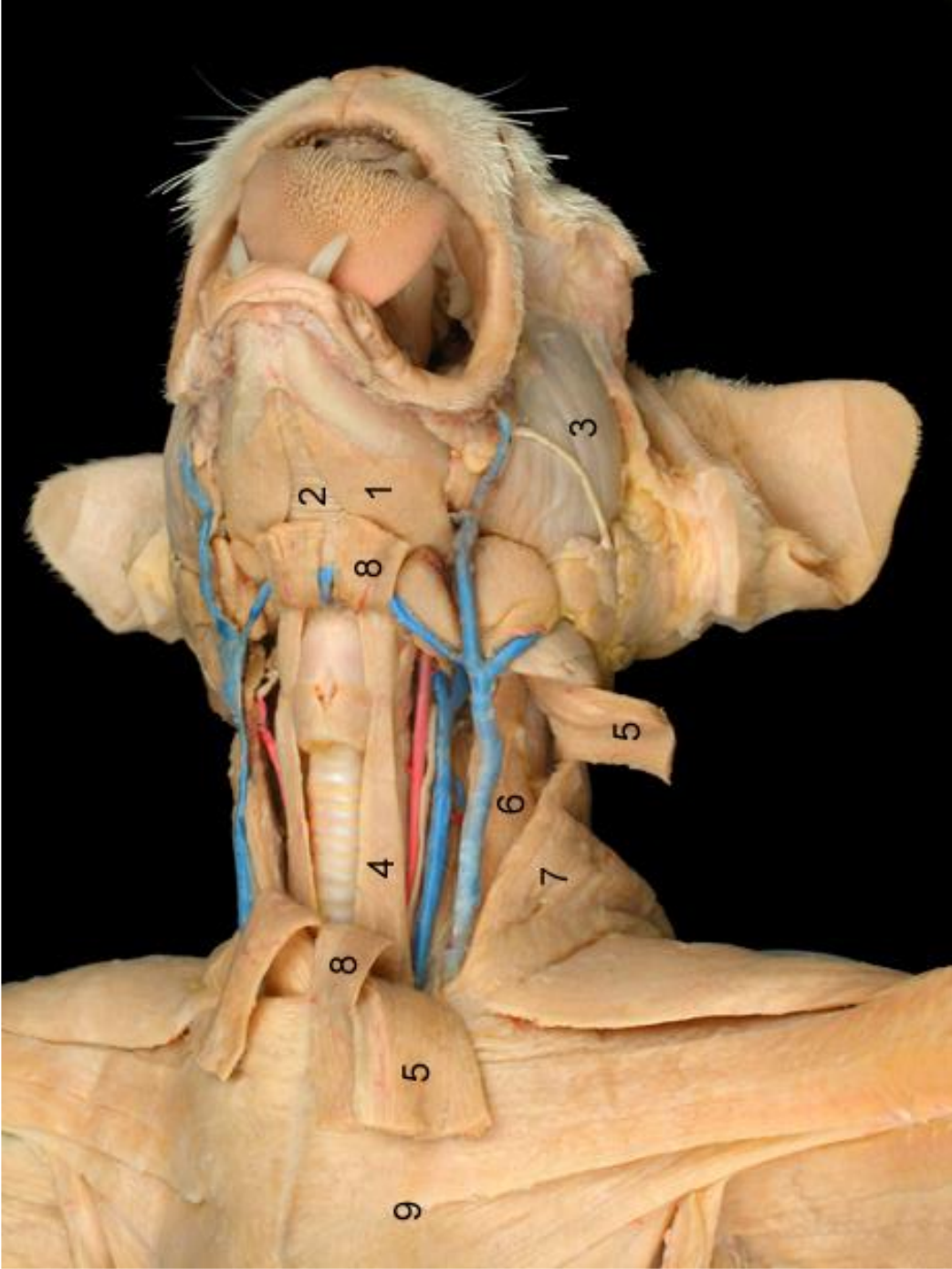


Anastomose arteriovenosa




Plexo pampiniforme





Punção veia jugular externa



Diferenças entre artérias e veias

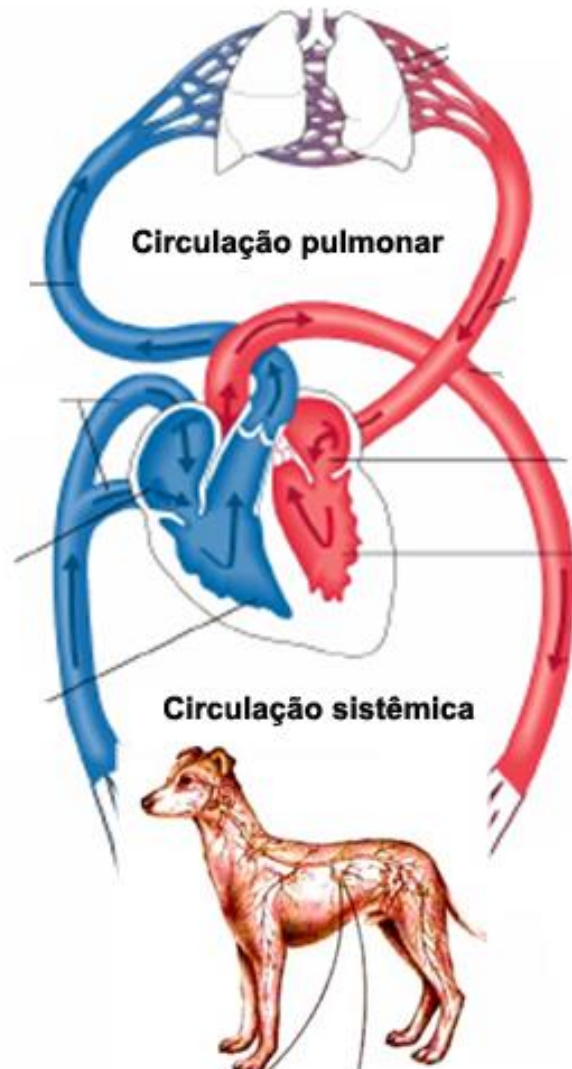
ARTÉRIAS

- não possuem válvulas
- profundas
- na morte contém ar
- coloração rósea
- trajeto retilíneo
- parede mais grossa
- pressão sanguínea maior
- menor lume

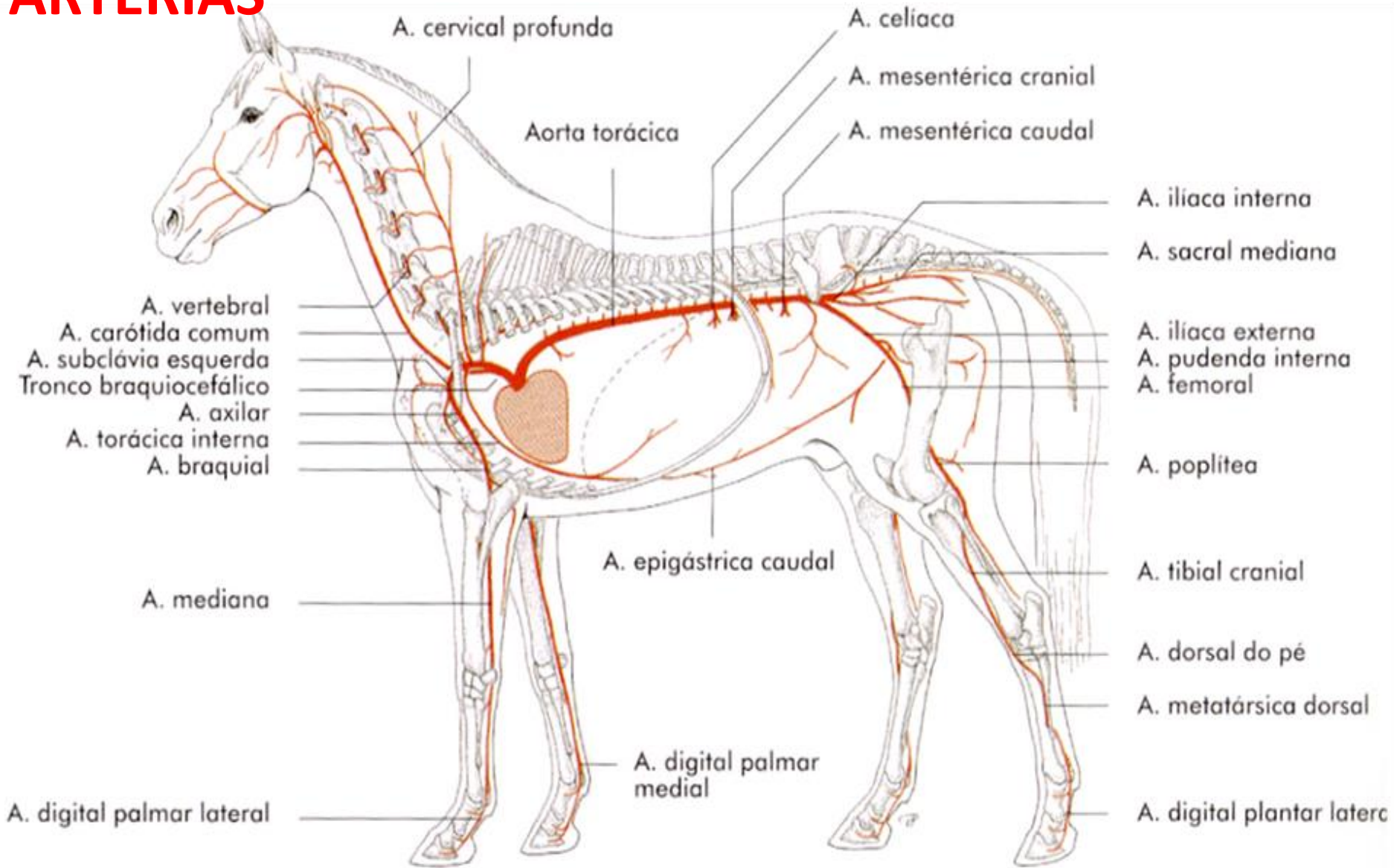
VEIAS

- possuem válvulas
- superficiais
- na morte contém sangue
- coloração azulada
- trajeto sinuoso
- parede fina
- pressão sanguínea menor
- Maior lume

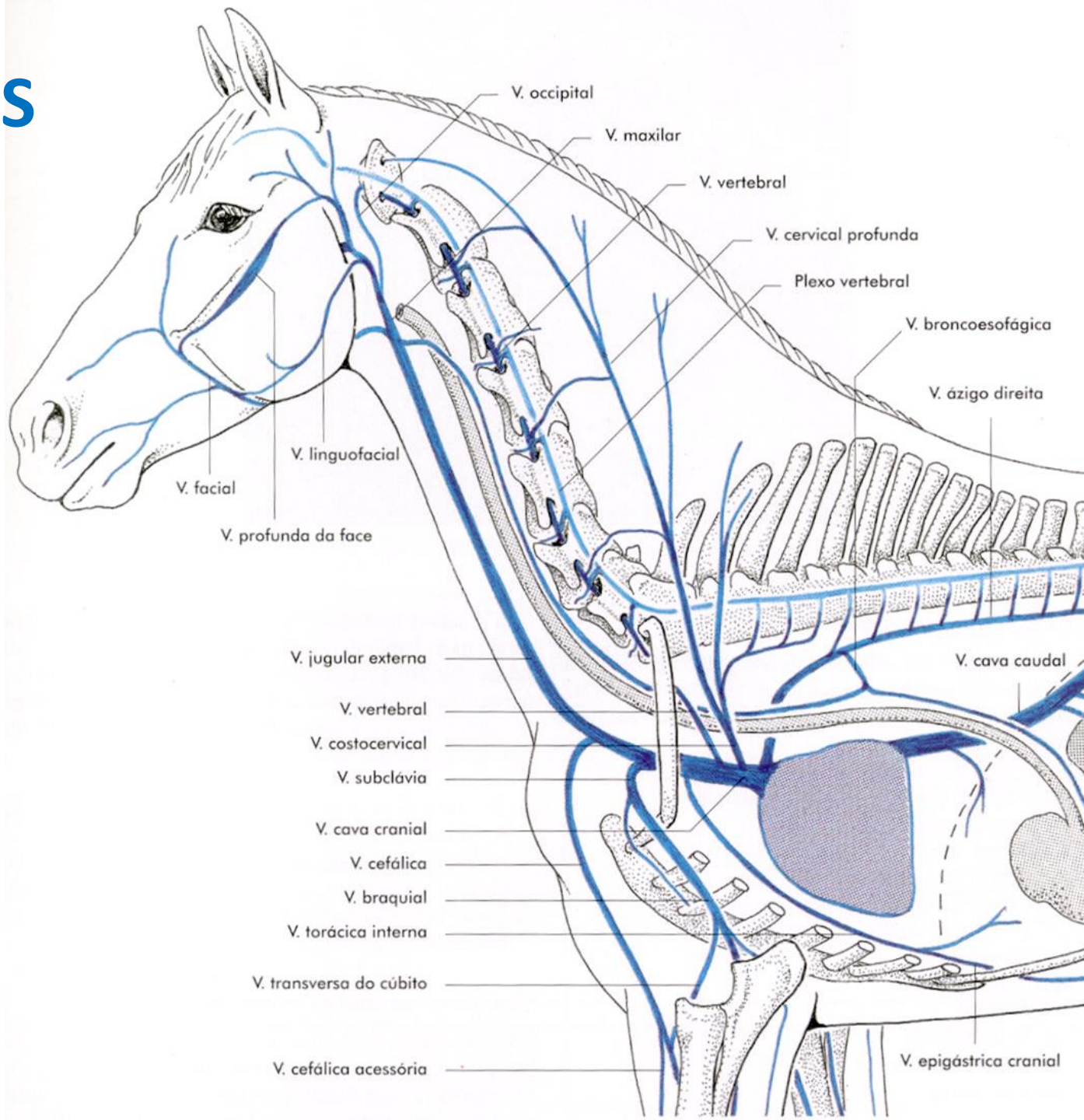
Circulação pulmonar e sistêmica



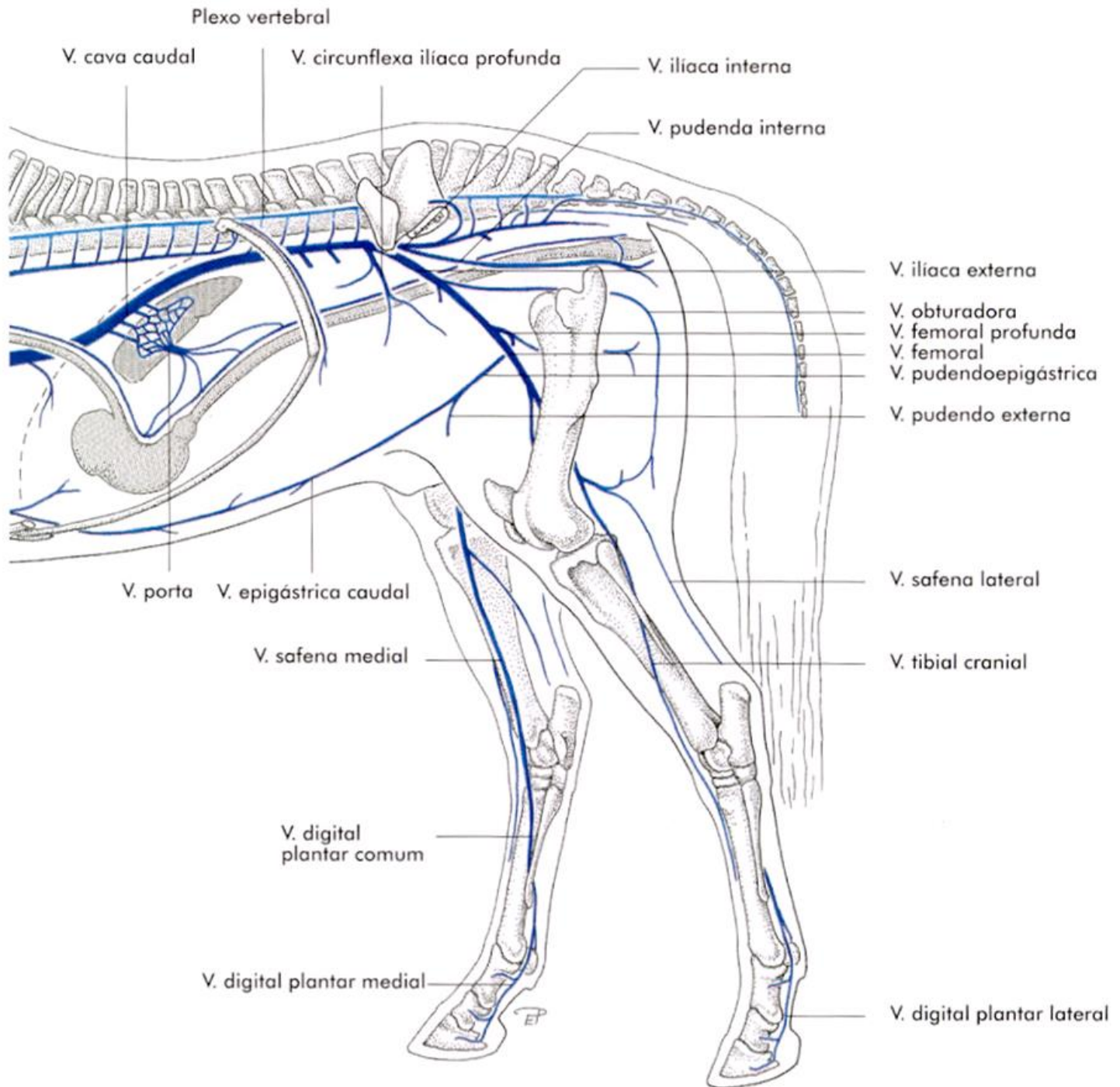
ARTÉRIAS

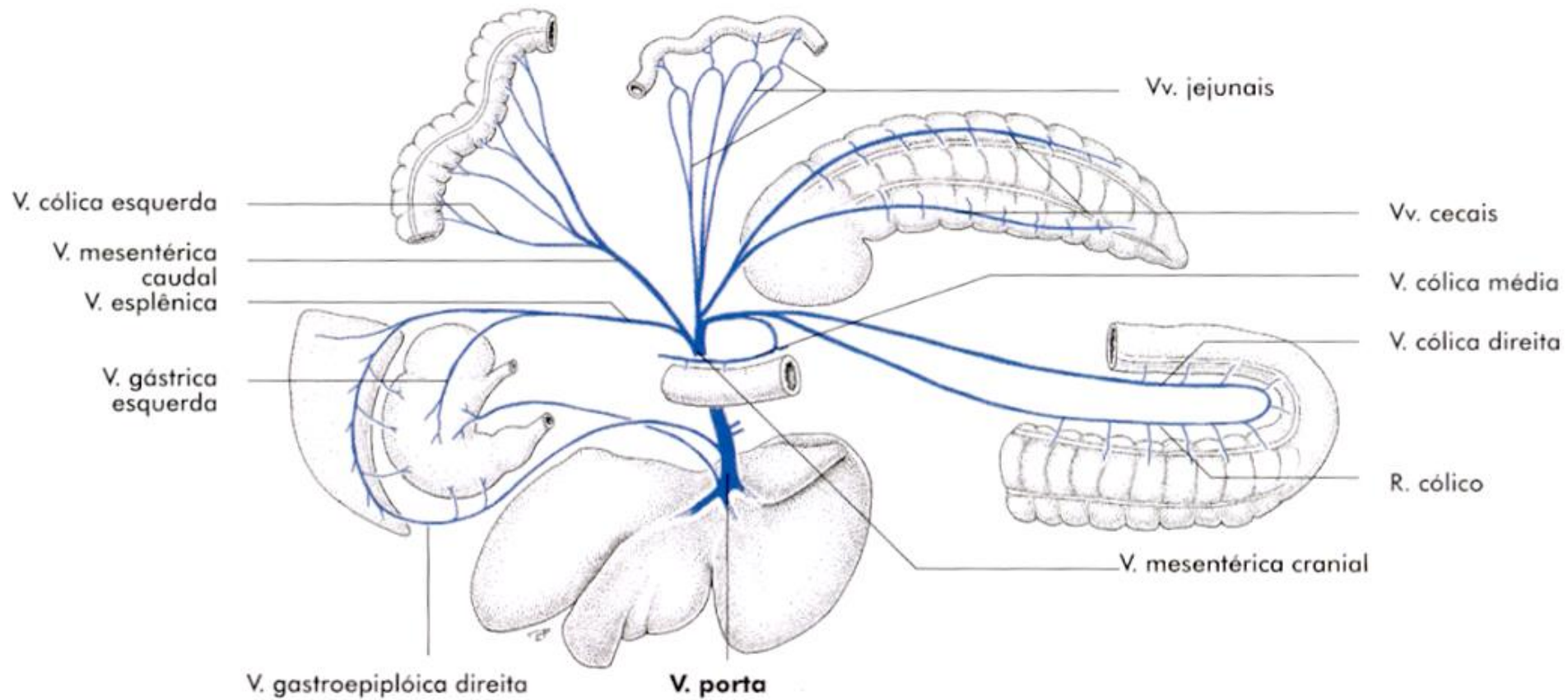


VEIAS




VEIAS





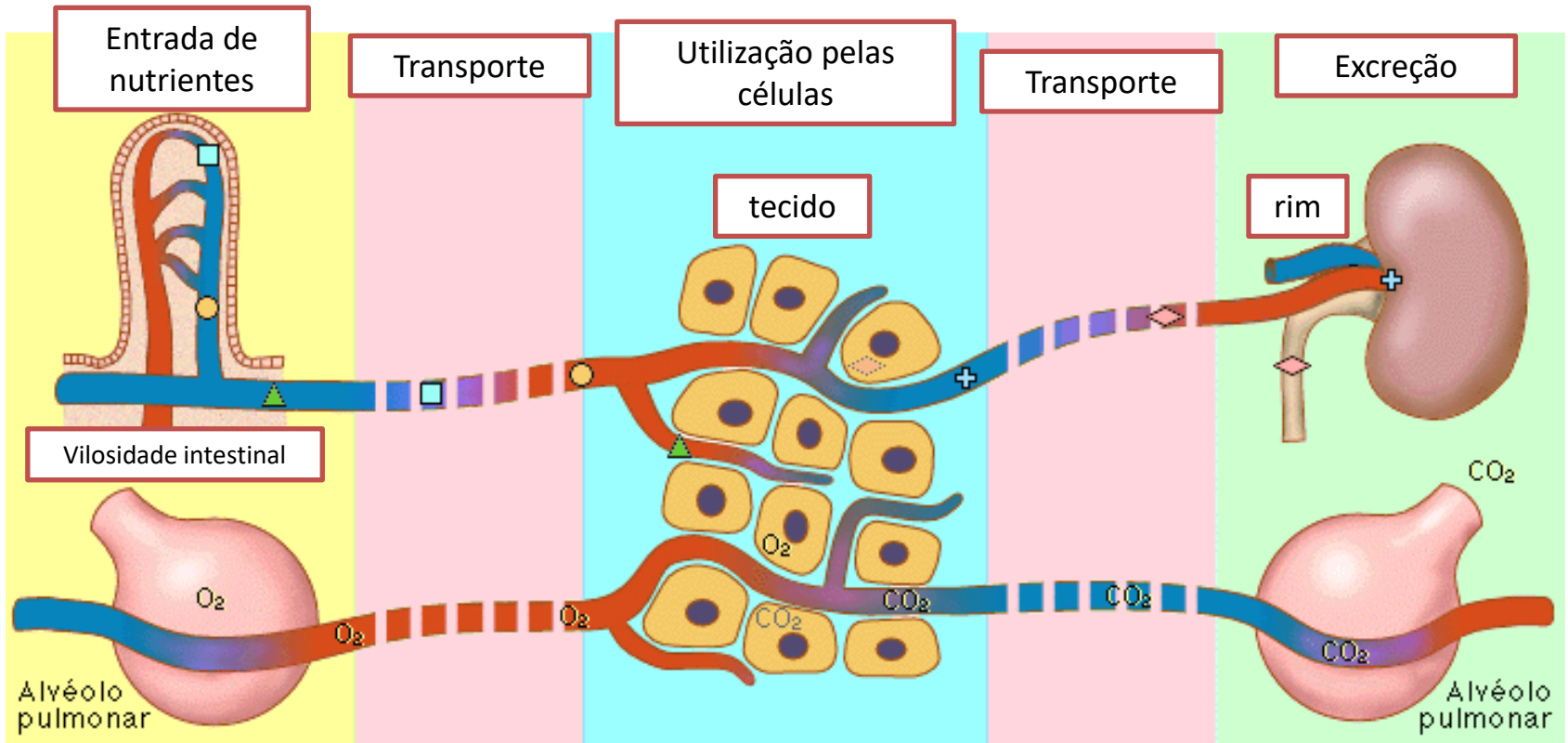
SANGUE

- Eritrócitos (hemácias)
- plaquetas
- leucócitos
- Plasma (água, proteínas, sais, vitaminas)



Funções do sistema cardiovascular

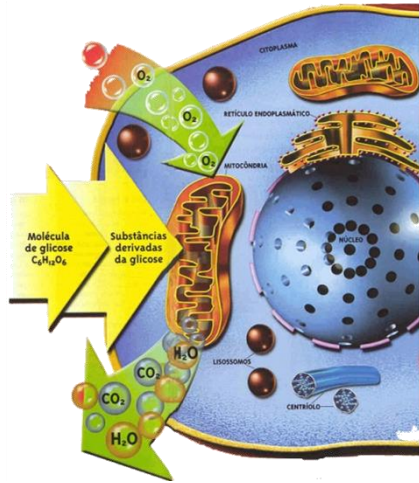
Meio de transporte



Nutrientes, oxigênio, hormônios

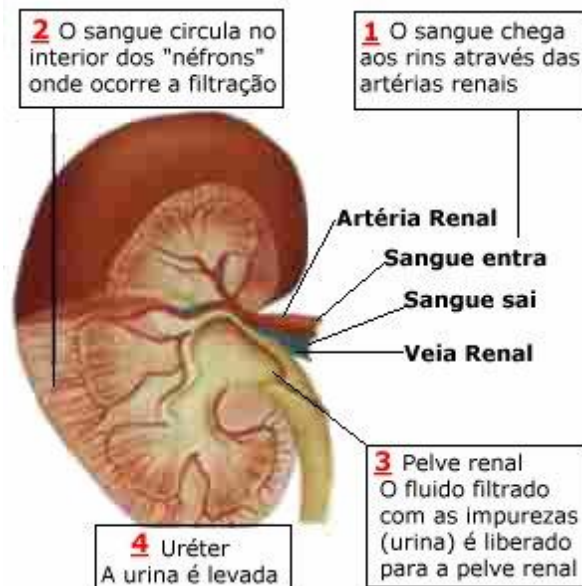
Excreção e dióxido de carbono

Funções do sistema circulatório



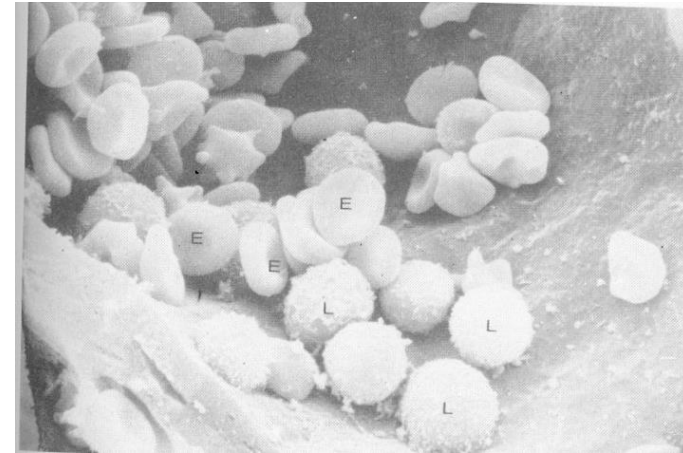
Nutrição: Oxigênio e elementos nutritivos e endócrinos

Fornece aos órgãos e tecidos, elementos nutritivos e oxigênio, secreções endócrinas



Excreção

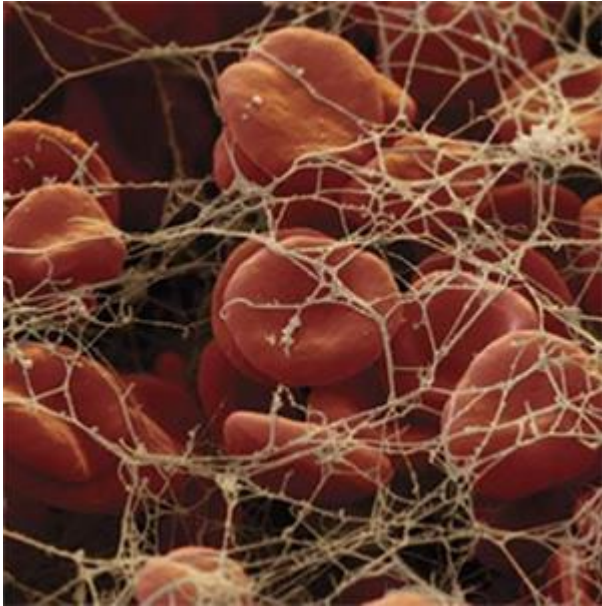
conduz aos órgãos excretores (rins) os resíduos do metabolismo.



Imunidade

Transporta leucócitos, linfócitos, anticorpos.

Funções do sistema circulatório



Sistema hemostático

Sistema hemostático: plaquetas
proteínas da coagulação, fibrina.



Regulação temperatura corporal

anastomoses arteriovenosas

Referências

- GETTY, R. **Sisson/Grossman. Anatomia dos Animais Domésticos.** 5 ed. Rio de Janeiro, Interamericana, 1986. v 1-2.
-
- INTERNATIONAL COMMITTEE ON VETERINARY GROSS ANATOMICAL NOMENCLATURE. **Nomina anatomica veterinaria.** 5.ed. Editorial Committee Hannover, Columbia, USA, Hannover, 2005. 166 p.
-
- LIEBICH, H.G.; KÖNIG, H.E. **Anatomia dos animais domésticos.** 1.ed. São Paulo: Artmed, 2004. V.1 e 2.
-
- MACHADO A. **Neuroanatomia funcional.** 2 ed. Rio de Janeiro: Atheneu, 2000. 363p.
-
- NICKEL, R.; SCHUMMER, A.; SEIFERLE, E. **The viscera of the domestic mammals.** 2. ed. Berlin: Paul Parey, 1979.
-
- NICKEL, R.; SCHUMMER, A.; SEIFERLE, E. **The circulatory system, the skin and the cutaneous organs of the domestic mammals.** Berlin – Hamburg: Verlag Paul Parey, 1981.
-
- NICKEL R, SCHUMMER A, SEIFERLE E, et al. **The Locomotor System of the Domestic Animals,** Vol 1. Berlin-Hamburg: Paul Parey, 1986
-
- ROMER, A. S. & PARSONS, T. S. **Anatomia Comparada dos Vertebrados.** São Paulo: Atheneu, 1985, 560p.
-
- SCHALLER. O. **Nomenclatura Anatômica Veterinária Ilustrada.** São Paulo: Manole, 1999. 614 p