



ELSEVIER

International Journal for Parasitology 28 (1998) 1473–1478



RAPID COMMUNICATION

Dogs are definitive hosts of *Neospora caninum*

Milton M. McAllister^{a,*}, J. P. Dubey^b, David S. Lindsay^c, William R. Jolley^a,
Rebecca A. Wills^a, Angela M. McGuire^a

^aUniversity of Wyoming, College of Agriculture, Department of Veterinary Sciences, 1174 Snowy Range Rd., Laramie, WY 82070, U.S.A.

^bUnited States Department of Agriculture, Agriculture Research Service, Livestock and Poultry Sciences Institute, and Parasite Biology and Epidemiology Laboratory, BARC-East, Bldg. 1001, Beltsville, MD 20705-2350, U.S.A.

^cCenter for Molecular Medicine and Infectious Diseases, Department of Biomedical Sciences and Pathobiology, Virginia–Maryland College of Veterinary Medicine, Virginia Tech, 1410 Prices Ford Rd., Blacksburg, VA 24061-0342, U.S.A.

(Received 15 July 1998; accepted 20 July 1998)

Abstract

Dogs were investigated to determine if they are definitive hosts of *Neospora caninum*. Four dogs were fed *N. caninum* tissue cysts in infected mouse tissue, and two negative control dogs were fed uninfected mouse tissue. Dog faeces were examined daily for 30 days using a sucrose flotation technique. Three challenged dogs shed spherical to subspherical unsporulated oocysts, measuring 10 to 11 μm in diameter. Oocysts sporulated within 3 days and contained two sporocysts, each with four sporozoites. Outbred, inbred, and gamma-interferon knockout mice were inoculated with canine faecal extracts and monitored for evidence of neosporosis using a variety of morphologic, immunohistologic, serologic, and genetic analyses. Mice that received faeces from each dog observed to shed oocysts were demonstrated to have neosporosis by two or more techniques. One mouse was demonstrated to be infected with *N. caninum* by immunohistochemistry, ultrastructural analysis, and a species-specific PCR test. No evidence of neosporosis was observed in control animals. Based on this study, dogs are a definitive host of *Neospora caninum*. © 1998 Australian Society for Parasitology. Published by Elsevier Science Ltd. All rights reserved.

Keywords: *Neospora caninum*; Neosporosis; Life cycle; Definitive host; Dog; Canine; Oocyst.

Neospora caninum (Apicomplexa: Sarcocystidae) is a protozoan that infects domestic and wild canids, ruminants, and horses [1–3]. Neosporosis is economically important in cattle, and is the most commonly diagnosed cause of bovine abortion in California, the Netherlands, and New Zealand [1,

4, 5]. The parasite exists on at least six continents [1–3]. To date, *N. caninum* is the only recognised species in the genus; canine and bovine isolates appear to be identical [6].

Prior to its description in 1988, *N. caninum* was frequently misidentified as *Toxoplasma gondii* [7]. *Toxoplasma*-like parasites have a heteroxenous life cycle with sexual stages occurring in the intestine of a definitive host [8]. Until now, the definitive host of *N. caninum* was unknown. Cats, dogs, coyotes, and several species of carnivorous birds have been tested with negative results [1, 9–11]. The number

*Present address of corresponding author: University of Illinois, Department of Veterinary Pathobiology, 2522 VMBSB, 2001 S. Lincoln Ave., Urbana, IL 61802, U.S.A. Tel.: 217-333-2449; fax: 217-244-7421; e-mail: mcallister@cvm.uiuc.edu.

of tissue cysts consumed, the number of animals, and other aspects of the experimental design varied widely among these investigations. We wished to further test the hypothesis that dogs are a definitive host of *N. caninum*.

Four, 8-week-old beagle dogs (Harlan Sprague Dawley, Indianapolis, Indiana) were housed in separate cages. Two age-matched, same-source beagles were similarly housed in a separate room, to serve as negative controls. Dogs had never consumed uncooked meat or meat by-products. Dogs were fed dry dog food and were released into the room for several h each day to permit socialisation and exercise. Blood samples were obtained prior to and 37 days after consuming infected mice, and IFAT serology was performed using *N. caninum* tachyzoites as antigen [12].

Tissue cysts of the NC-2 [13], NC-Liverpool [14], and NC-beef strains of *N. caninum* were produced in outbred white mice that were immunosuppressed with corticosteroids according to previously described protocols [15, 16]. The NC-beef strain, previously undocumented, was isolated *in vitro* in our laboratories from a naturally-infected beef calf, approximately 1 month prior to inoculating the mice used in the present study. After 1 or more months, mice were killed by cervical dislocation, blood was collected for IFAT serology, and tissue cysts were enumerated by examination of brain squashes [17]. Portions of brain homogenates were inoculated onto tissue cultures in order to verify viability of organisms, after digestion in an acid-pepsin solution [17]. Brains and the skinned, eviscerated, blended carcasses of infected mice were fed to four dogs on three consecutive days (days p.i. 0, 1, and 2). Seronegative, uninfected mice were processed identically and fed to two dogs on the same dates, as a negative control.

The faeces in each dog's cage were collected daily and examined using a sucrose flotation procedure described for *Toxoplasma gondii* oocysts [18], modified to permit flotation of the entire faecal mass. The flotation supernatant was diluted in approximately five volumes of water and centrifuged for 10 min at 650 g. The sediment was mixed with 2% H₂SO₄ and aerated on a shaker for 3 to 7 days. For bioassay, acidified faecal extracts were neutralised with 3.3% NaOH and inoculated orally and s.c. into mice [18].

Bioassays were performed in gamma-interferon knockout mice (BALB/c-Ifng^{tm1ITs}, Jackson Laboratories, Bar Harbor, Maine) and in corticosteroid-treated outbred mice. Mice that became ill were euthanised and attempts were made to isolate protozoa in tissue culture from liver, lung, and spleen, and touch preparations of these organs were stained with Giemsa and examined microscopically for tachyzoites. In addition, tissues from the first knockout mouse to die were examined histologically, immunohistologically, ultrastructurally, and by a PCR procedure. Specimens of lung, liver, and spleen were fixed in 10% neutral buffered formalin prior to routine histologic processing, and 5 µm thick sections were prepared. Some histologic sections were stained with H and E. Other sections were immunohistochemically stained using *N. caninum*-specific mAb 6G7 or with *N. caninum* anti-serum, using reagents and methods previously described [19, 20]; the specificity of these reagents has been tested extensively. Portions of spleen were processed for EM by fixing in 3% glutaraldehyde in Millonig's phosphate buffer (pH 7.4), post-fixing in 1% osmium tetroxide, dehydrating in a series of ethanols, passing through two changes of propylene oxide, and embedding in Poly/Bed 812 (Polysciences Inc., Pennsylvania). Thin sections were stained with uranyl acetate and lead citrate and examined with a JEOL-100CX II TEM operating at 80 KV. A previously described PCR procedure was used to detect an *N. caninum*-specific DNA sequence [21] in an extract of splenic tissue.

In addition to the bioassay methods already mentioned, six seronegative, corticosteroid-treated BALB/c mice (Harlan Sprague Dawley) per dog were inoculated orally with aerated faecal extracts, collected between 8 and 14 days after dogs consumed infected mice. Blood samples were collected 14 days later, and sera were tested for *N. caninum* antibodies at a 1:50 dilution using the IFAT.

The results of examination of the oral inocula fed to dogs, parasitologic examinations of dog faeces, serology of dogs, and an interpretive summary of mouse bioassays are presented in Table 1. Unsporulated, spherical to subspherical oocysts, measuring 10 to 11 µm in diameter and containing a central sporont, were observed to be shed by three dogs that consumed *N. caninum*-infected mice, but not by

Table 1
Summary of *Neospora caninum* oral inoculation of dogs and bioassay in mice

Dog ID	<i>N. caninum</i> strain in mice fed to dogs	Number of tissue cysts fed to dogs	Tissue culture results of mouse brains fed to dogs	Dog Ab titre at 37 days p.i. (reciprocal)	Days p.i. oocysts observed in dog faeces	Evidence of neosporosis in mouse bioassay
A	NC-2	300	positive	800	8–27	yes
B	NC-beef	150	negative	< 50	13–20	yes
C	NC-2	150	positive	≥ 1600	13–23	yes
"	NC-beef	25	negative	"	"	"
"	NC-Liverpool	75	positive	"	"	"
D	NC-2	100	positive	≥ 1600	none observed	no
"	NC-Liverpool	25	positive	"	"	"
E	none	0	negative	< 50	none observed	no
F	none	0	negative	< 50	none observed	no

either dog that consumed uninfected mice. Oocysts sporulated within 3 days and contained two sporocysts, each with four sporozoites. The oocysts were morphologically similar to *T. gondii*, *Hammondia hammondi*, and *Hammondia heydorni* (Fig. 1 A, B) [22].

The first mouse that died in the bioassay was a gamma-interferon knockout mouse inoculated s.c. with a faecal extract containing oocysts from dog B, which had consumed NC-beef-infected mice. Touch preparations revealed large numbers of tachyzoites in liver, spleen, and lung that were morphologically identical to those of *N. caninum* (Fig. 1 C). Histology revealed numerous tachyzoites in these organs, with multifocal hepatic necrosis and minimal associated inflammation (Fig. 1 D). Immunohistology demonstrated positive staining of these organisms with *N. caninum*-specific mAb 6G7 and polyclonal antisera (Fig. 1 E). Intracellular and extracellular tachyzoites were observed using EM (Fig. 1 F). Intracellular tachyzoites were usually in a parasitophorous vacuole. They contained a conoid, micronemes, dense granules, a vesicular nucleus, and numerous electron dense rhoptries, but they lacked the prominent anterior vacuole characteristic of *H. heydorni* tachyzoites [23]. Analysis of a splenic extract using PCR resulted in amplification of a *N. caninum*-specific DNA sequence (Fig. 2).

Within the first 2 weeks of inoculation with faecal extracts containing unidentified oocysts, one cort-

icosteroid-treated outbred mouse and three gamma-interferon knockout mice died or were euthanatised with evidence of systemic neosporosis, as revealed by the presence of tachyzoites in touch preparations, and in one case by recovery of tachyzoites in tissue culture. One of these mice correlated with Dog A (NC-2), two mice correlated with Dog B (NC-beef), and one mouse correlated with Dog C (mixed inoculum). One of these mice had been inoculated by gavage only. The organism isolated in tissue culture was successfully transferred to uninfected cells, unlike those of *H. hammondi* or *H. heydorni*, which cannot be passaged [22].

Fourteen days after consuming faecal extracts from dogs that had consumed *N. caninum*-infected mice, two of 24 BALB/c mice developed *N. caninum* antibody titres of ≥ 1:50. One of these mice correlated with Dog A and the other with Dog C. Twelve mice, correlating with the negative control dogs, did not seroconvert.

Dogs are a definitive host of *N. caninum*. After consumption of tissue cysts in infected mouse carcasses, three of four dogs shed oocysts resembling those of *T. gondii* and *Hammondia* spp. Protozoal tachyzoites were observed in organs of mice used in bioassays of faeces from each of these dogs. Mice inoculated with faecal extracts from two of these dogs developed *N. caninum* antibody titres, and a mouse inoculated with faecal extracts from the third dog was proven to develop neosporosis by immunohistochemistry, ultrastructural examination, and

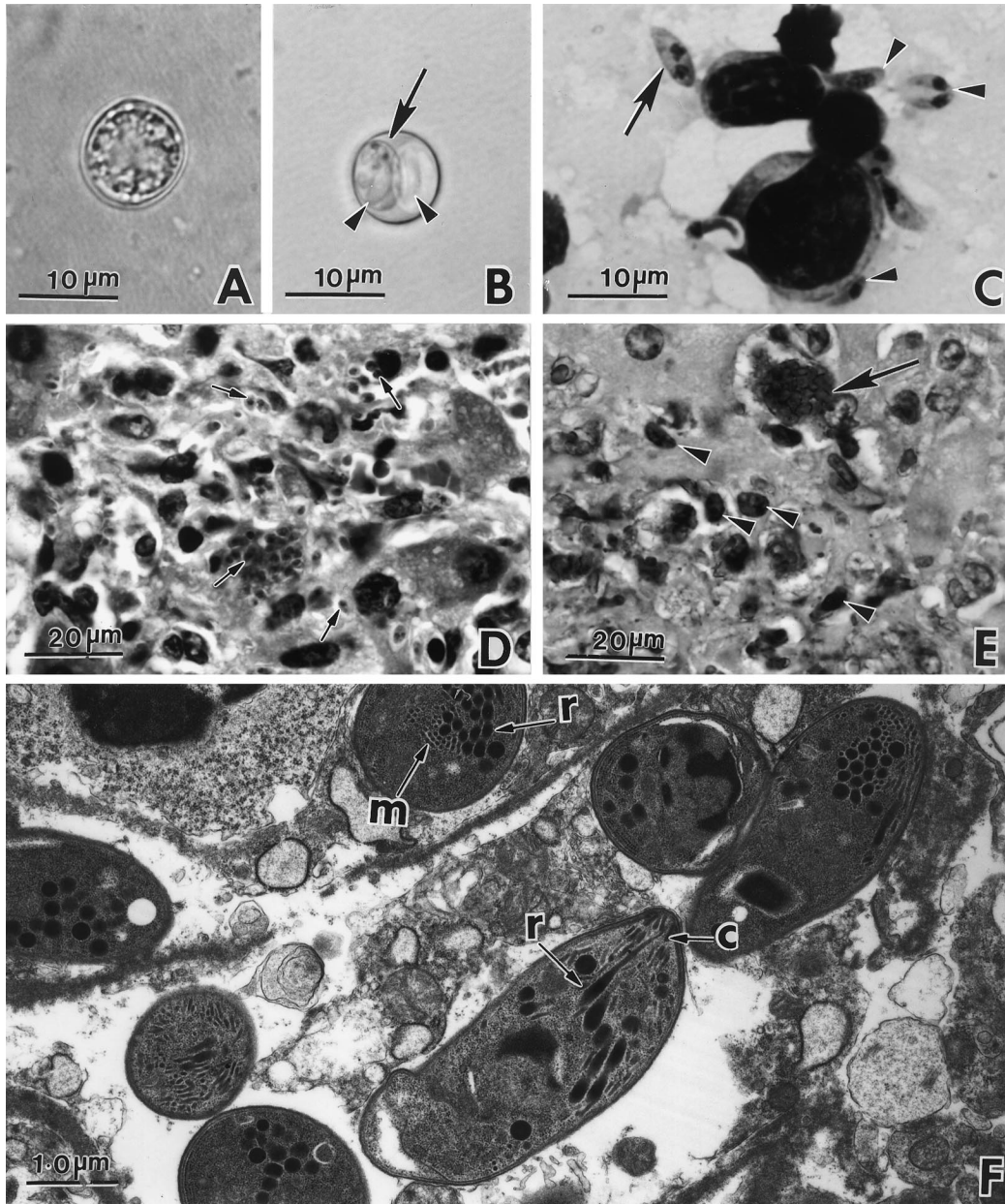


Fig. 1. *Neospora caninum* stages in dogs and mice. **A.** Unsporulated oocyst with a central mass. **B.** Sporulated oocyst with two sporocysts (arrow) and with sporozoites (arrowheads). **C.** Smear of liver from a knockout mouse inoculated with dog faeces, showing individual tachyzoites (arrowheads) and a zoite dividing by endodyogeny (arrow). Giemsa stain. **D.** Tachyzoites (arrows) in a focus of necrosis in a section of liver from the mouse in Fig. 1 C. H and E stain. **E.** Section from the same liver as in Fig. 1 C, showing individual (arrowheads) and a group (arrow) of tachyzoites. Immunohistochemical stain with *N. caninum*-specific monoclonal antibody. **F.** EM of tachyzoites in liver of mouse in Fig. 1 C. Note conoid (c), micronemes (m), and electron-dense rhoptries (r).

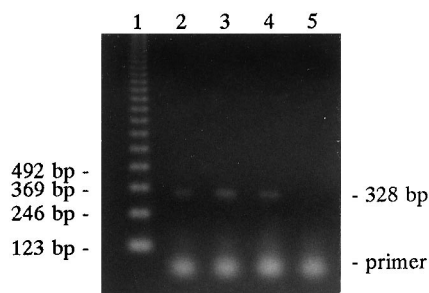


Fig. 2. Electrophoretic separation of DNA products obtained by polymerase chain reaction using *Neospora caninum*-specific primers [21]. Lane 1: marker in 123 base pair increments. Lanes 2 and 3: positive controls consisting of *in vitro* cultured *N. caninum* tachyzoites. Lane 4: splenic extract from a mouse that had been inoculated with faeces from a dog that consumed *N. caninum* tissue cysts and was shedding unidentified oocysts. Lane 5: negative control (water). The 328 bp band represents the *N. caninum* DNA sequence. The primer band represents residual primers, primer-dimers, or nonspecific amplification product.

PCR. Although this study demonstrates that *N. caninum* can be transmitted in dog faeces, the identity of the oocyst is presumptive and requires confirmation.

The concentration of oocysts in faeces was low and appeared to be roughly in proportion to the number of tissue cysts consumed by the dogs. Maximum oocyst shedding for Dog B was five per coverslip; this dog was fed 150 tissue cysts. It is possible that the number of tissue cysts fed to dogs and coyotes in previous experiments was too low to induce detectable shedding of oocysts. Presence or absence of seroconversion of test subjects may not be an indicator of an adequate or inadequate challenge inoculum (Table 1), and perhaps is influenced by the parasite strain. Future testing of wild canids is warranted to ascertain if they are also definitive hosts of this parasite. Without enumeration of tissue cysts in the oral inocula fed to test subjects, negative results should be viewed skeptically.

Neosporosis abortion outbreaks [24] may occur in cattle herds fed mixed rations if the feed is contaminated. Farmers should consider taking steps to limit opportunities for dogs to defaecate in feed intended for breeding cattle or goats. In many instances, this could be accomplished by fencing around open-faced buildings used to store feed, uncovered silage piles, and hay.

Acknowledgements—This research was supported in part by USDA-NRICGP grant 96-02532. The authors thank Jennifer D. Tranas, S. K. Shen, O. C. H. Kwok, Diane Hawkins-Cooper, Virginia Viers, Kathy Lowe and Jill Songers for technical assistance, and Catherine A. Jones and Wendi R. Wilson for animal care.

References

- [1] Dubey JP, Lindsay DS. A review of *Neospora caninum* and neosporosis. *Vet Parasitol* 1996;67:1–59.
- [2] Barber JS, Gasser RB, Ellis J, Reichel MP, McMillan S, Trees AJ. Prevalence of antibodies to *Neospora caninum* in different canid populations. *J Parasitol* 1997;83:1056–1058.
- [3] Huong LT, Ljungstrom BL, Uggla A, Björkman C. Prevalence to *Neospora caninum* and *Toxoplasma gondii* in cattle and water buffaloes in southern Vietnam. *Vet Parasitol* 1998;75:53–57.
- [4] Anderson ML, Palmer CW, Thurmond MC, Picanso JP, Blanchard PC, Breitmeyer RE, Layton AW, McAllister M, Daft B, Kinde H, Read DH, Dubey JP, Conrad PA, Barr BC. Evaluation of abortions in cattle attributable to neosporosis in selected dairies in California. *J Am Vet Med Assoc* 1995;207:1206–1210.
- [5] Thornton RN, Thompson EJ, Dubey JP. *Neospora* abortion in New Zealand cattle. *N Zeal Vet J* 1991;39:129–133.
- [6] Holmdahl J, Björkman C, Stenlund S, Uggla A, Dubey JP. Bovine *Neospora* and *Neospora caninum*: one and the same. *Parasitol Today* 1997;13:40–41.
- [7] Dubey JP, Carpenter JL, Speer CA, Topper MJ, Uggla A. Newly recognized fatal protozoan disease of dogs. *J Am Vet Med Assoc* 1988;192:1269–1283.
- [8] Current WL, Upton SJ, Long PL. Taxonomy and life cycles. In: Long PL, editor. *Coccidiosis of man and domestic animals*. Boston: CRC Press, 1990:1–16.
- [9] McAllister MM, Jolley WR, Wills RA, Lindsay DS, McGuire AM, Tranas JD. Oral inoculation of cats with tissue cysts of *Neospora caninum*. *Am J Vet Res* 1998;59:441–444.
- [10] Lindsay DS, Kelly EJ, McKown RD, Stein FJ, Plozer J, Herman J, Blagburn BL, Dubey JP. Prevalence of *Neospora caninum* and *Toxoplasma gondii* antibodies in coyotes (*Canis latrans*) and experimental infections of coyotes with *Neospora caninum*. *J Parasitol* 1996;82:657–659.
- [11] Baker DG, Morishita TY, Brooks DL, Shen SK, Lindsay DS, Dubey JP. Experimental oral infections in birds to evaluate potential definitive hosts of *Neospora caninum*. *J Parasitol* 1995;81:783–785.
- [12] Dubey JP, Hattel AL, Lindsay DS, Topper MJ. Neonatal *Neospora caninum* infection in dogs: Isolation of the causative agent and experimental transmission. *J Am Vet Med Assoc* 1988;193:1259–1263.
- [13] Hay WH, Shell LG, Lindsay DS, Dubey JP. Diagnosis and treatment of *Neospora caninum* infection in a dog. *J Am Vet Med Assoc* 1990;197:87–89.

- [14] Barber JS, Holmdahl OJM, Owen MR, Guy F, Uggla A, Trees AJ. Characterisation of the first European isolate of *Neospora caninum* (Dubey, Carpenter, Speer, Topper and Uggla.). Parasitology 1995;111:563–568.
- [15] McGuire AM, McAllister MM, Jolley WR, Anderson-Sprecher RC. A protocol for the production of *Neospora caninum* tissue cysts in mice. J Parasitol 1997;83:647–651.
- [16] Romand S, Thulliez P, Dubey JP. Direct agglutination test for serologic diagnosis of *Neospora caninum* infection. Parasitol Res 1998;60:50–53.
- [17] McGuire AM, McAllister MM, Jolley WR. Separation and cryopreservation of *Neospora caninum* tissue cysts from murine brain. J Parasitol 1997;83:319–321.
- [18] Dubey JP. Duration of immunity to shedding of *Toxoplasma gondii* oocysts by cats. J Parasitol 1995;81:410–415.
- [19] Cole RA, Lindsay DS, Dubey JP, Blagburn BL. Detection of *Neospora caninum* in tissue sections using a murine monoclonal antibody. J Vet Diagn Invest 1993;5:579–584.
- [20] Lindsay DS, Dubey JP. Immunohistochemical diagnosis of *Neospora caninum* in tissue sections. Am J Vet Res 1989;50:1981–1983.
- [21] Yamage M, Flechtner O, Gottstein B. *Neospora caninum*: specific oligonucleotide primers for the detection of brain “cyst” DNA of experimentally infected nude mice by the polymerase chain reaction (PCR). J Parasitol 1996;82:272–279.
- [22] Dubey JP. *Toxoplasma*, *Neospora*, *Sarcocystis*, and other tissue cyst forming coccidia of humans and animals. In: Kreir JP, editor. Parasitic protozoa. New York: Academic Press, 1993:1–158.
- [23] Speer CA, Dubey JP. Ultrastructure of zoites of *Hammondia heydorni*. J Protozool 1989;36:488–493.
- [24] McAllister MM, Huffman EM, Hietala SK, Conrad PA, Anderson ML, Salman MD. Evidence suggesting a point source exposure in an outbreak of bovine abortion due to neosporosis. J Vet Diagn Invest 1996;8:355–357.