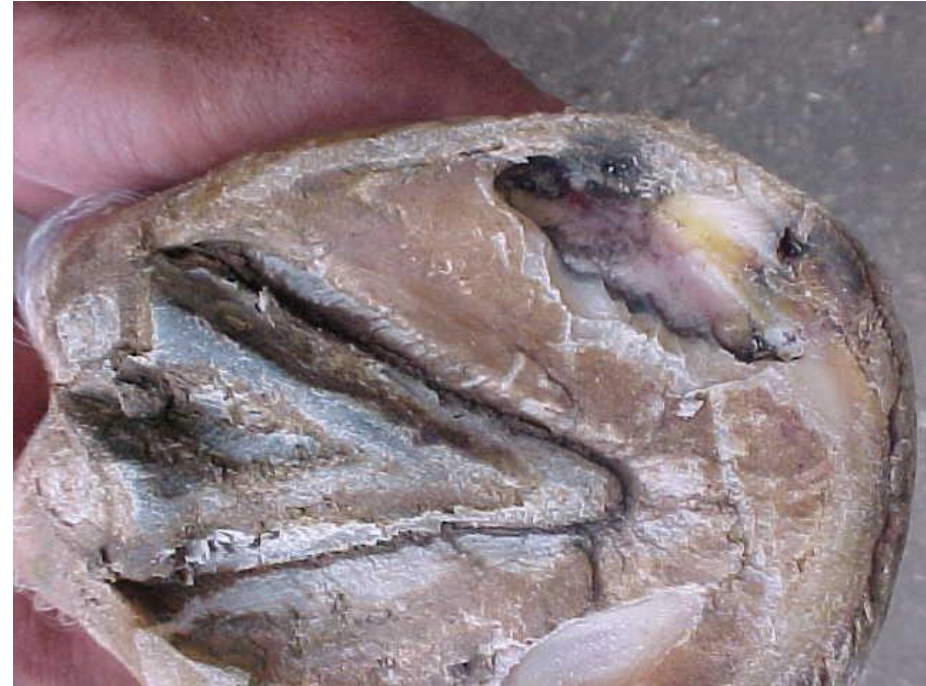
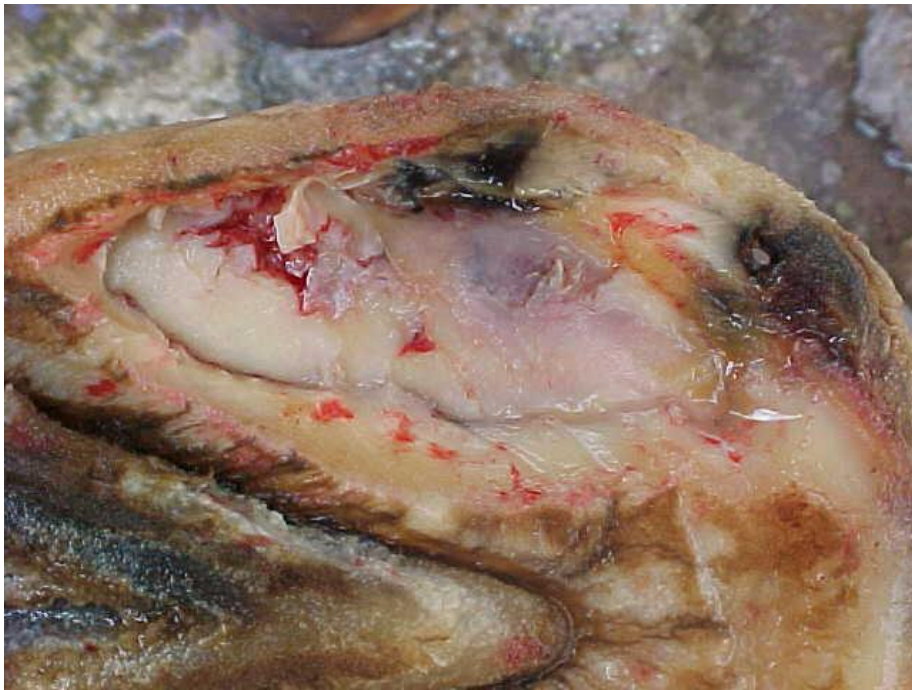
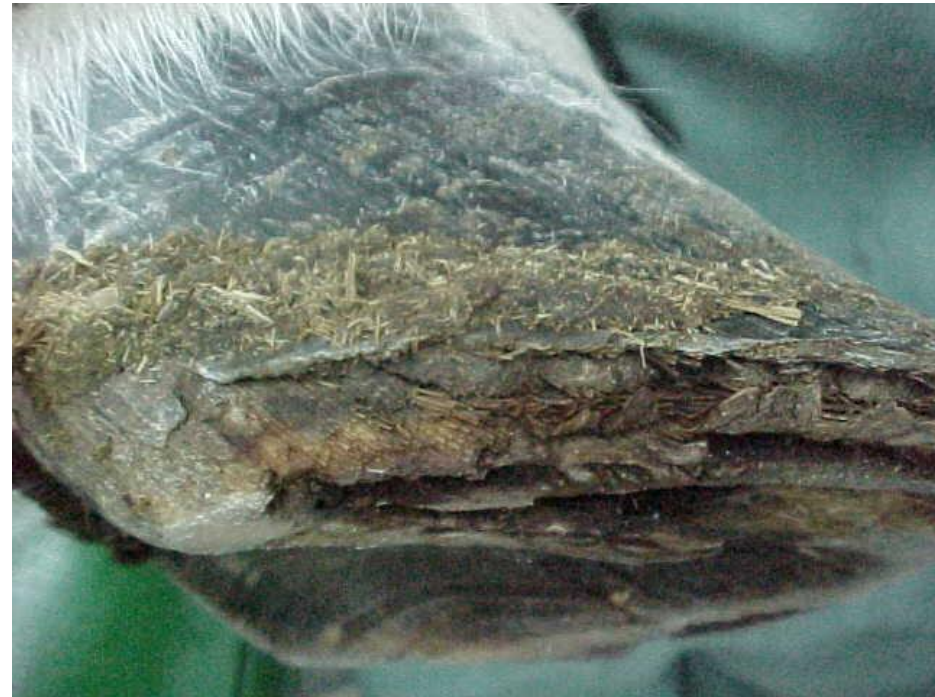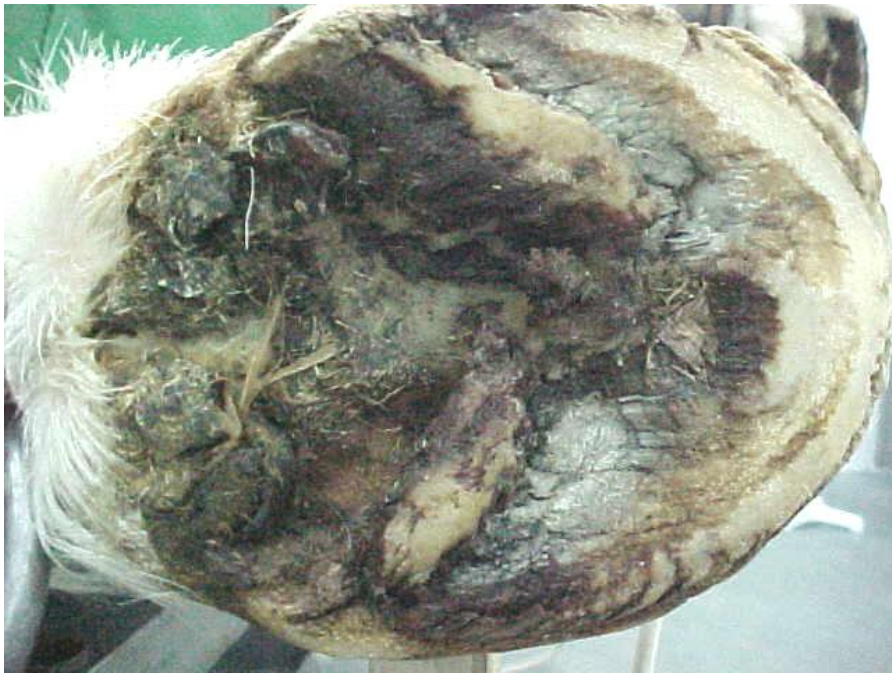Anatomia clínico-cirúrgica do dígito equino VCI0209

Luis Claudio L C Silva
Depto. de Cirurgia – FMVZ/USP

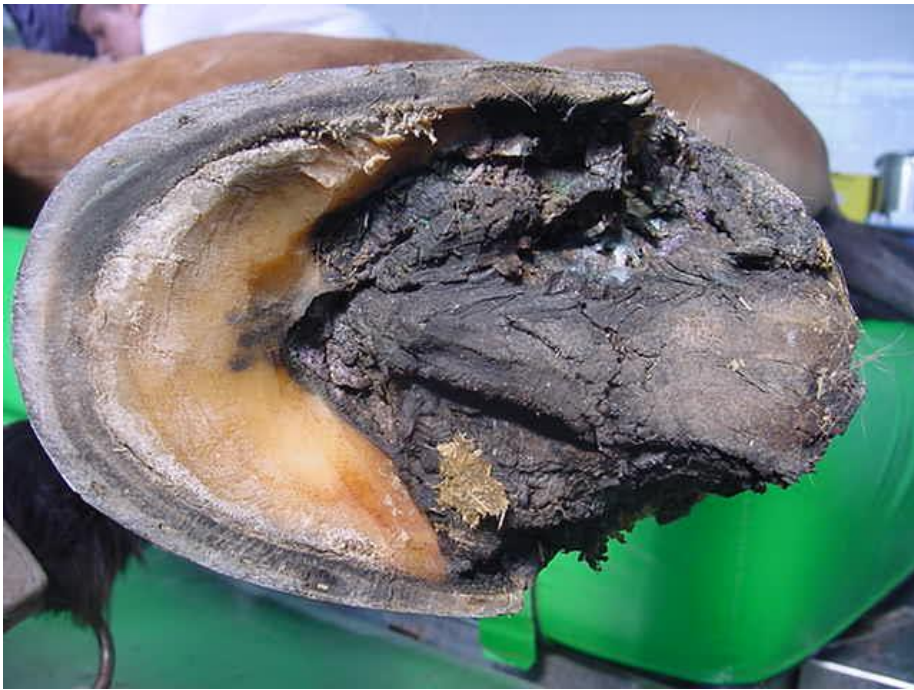Abscesso solear



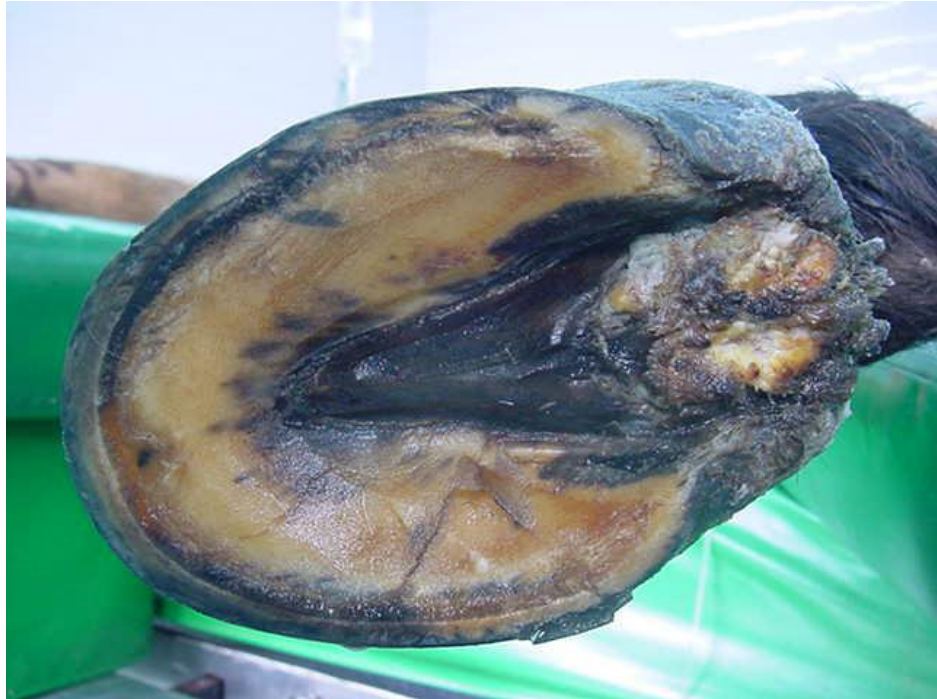Pododermatite exsudativa
(*thrush*)
fase inicial p/ cancro



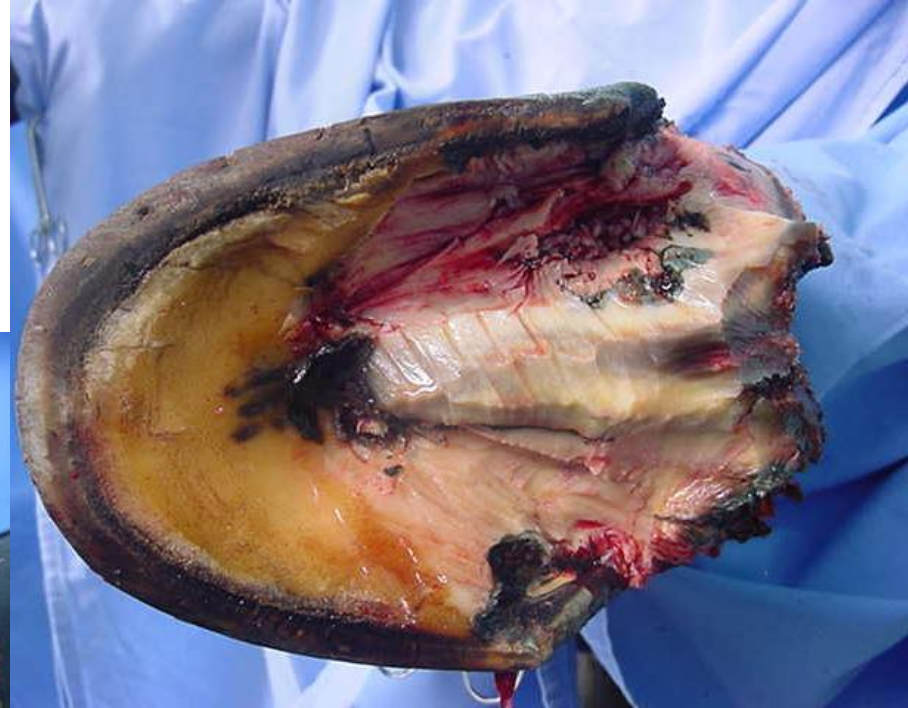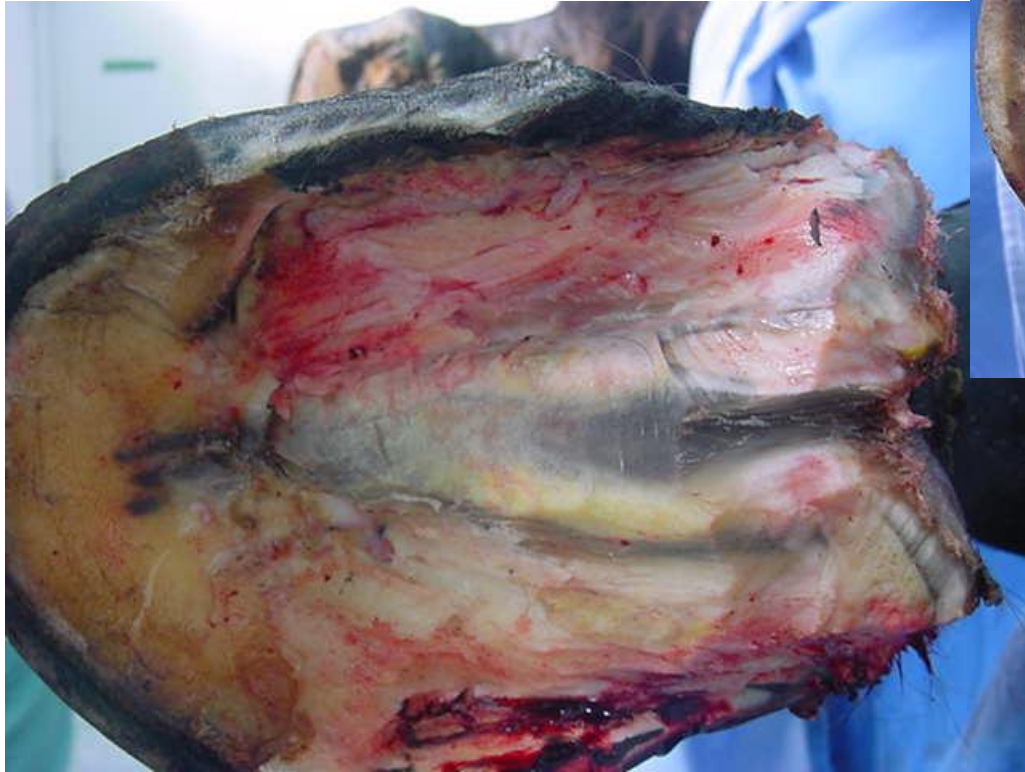Pododermatite vegetante cancro / *canker*

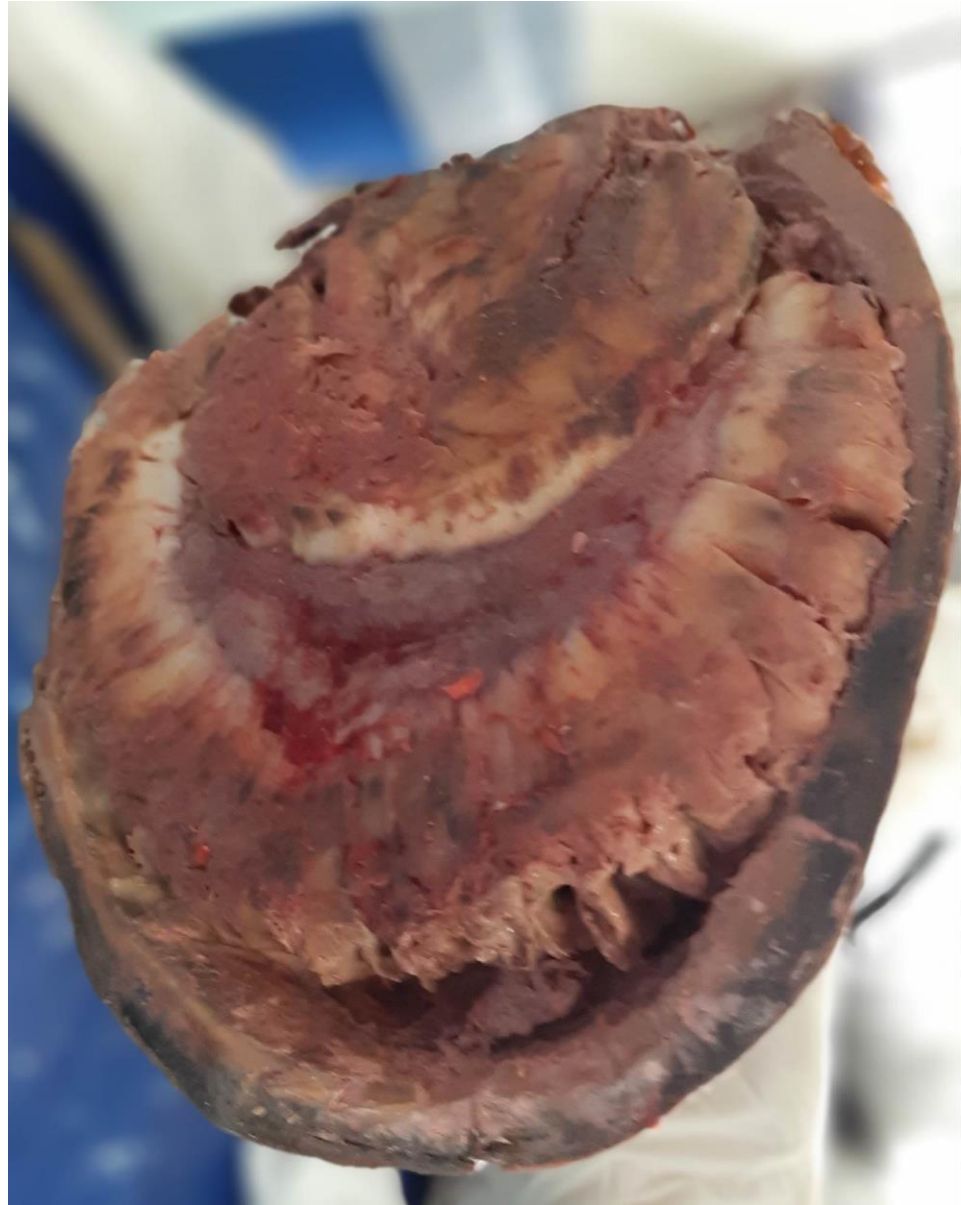
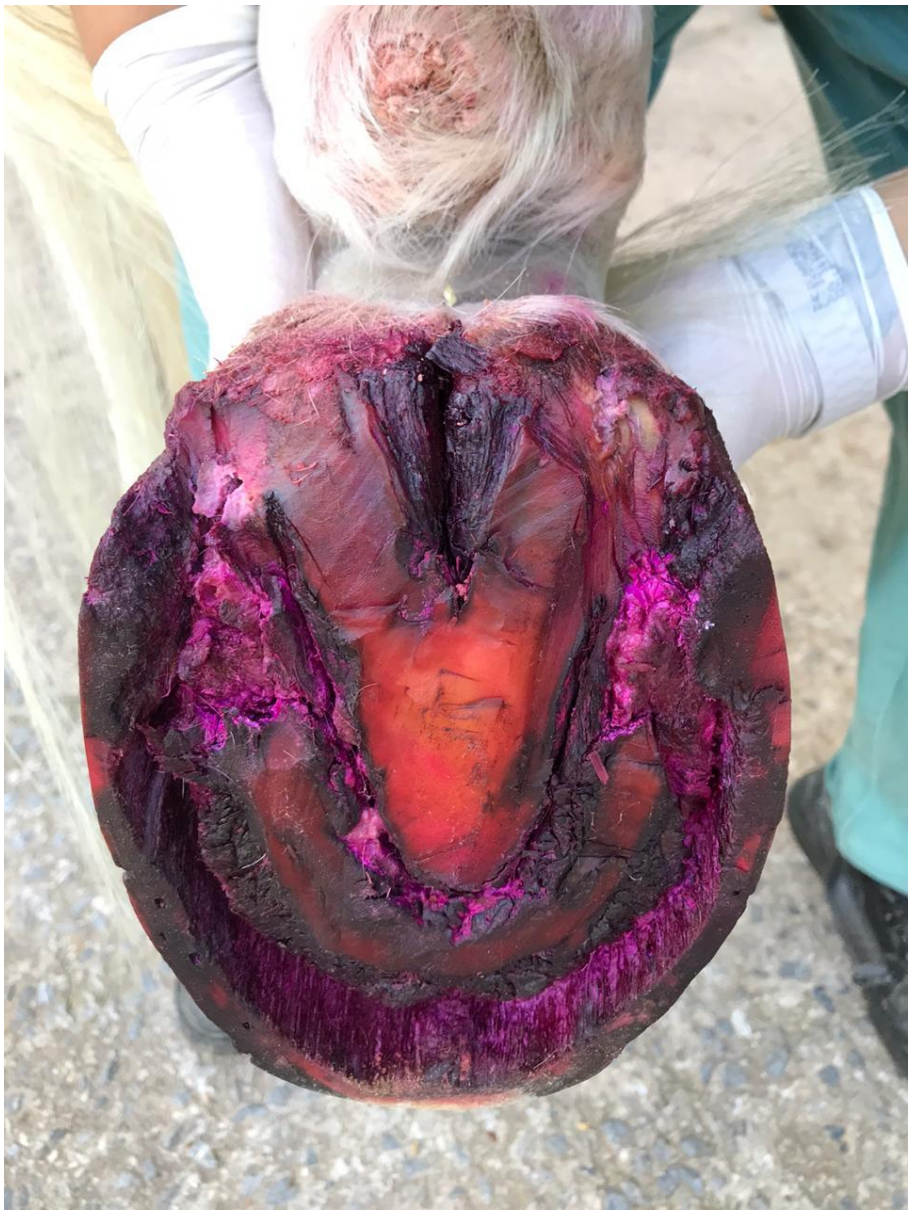
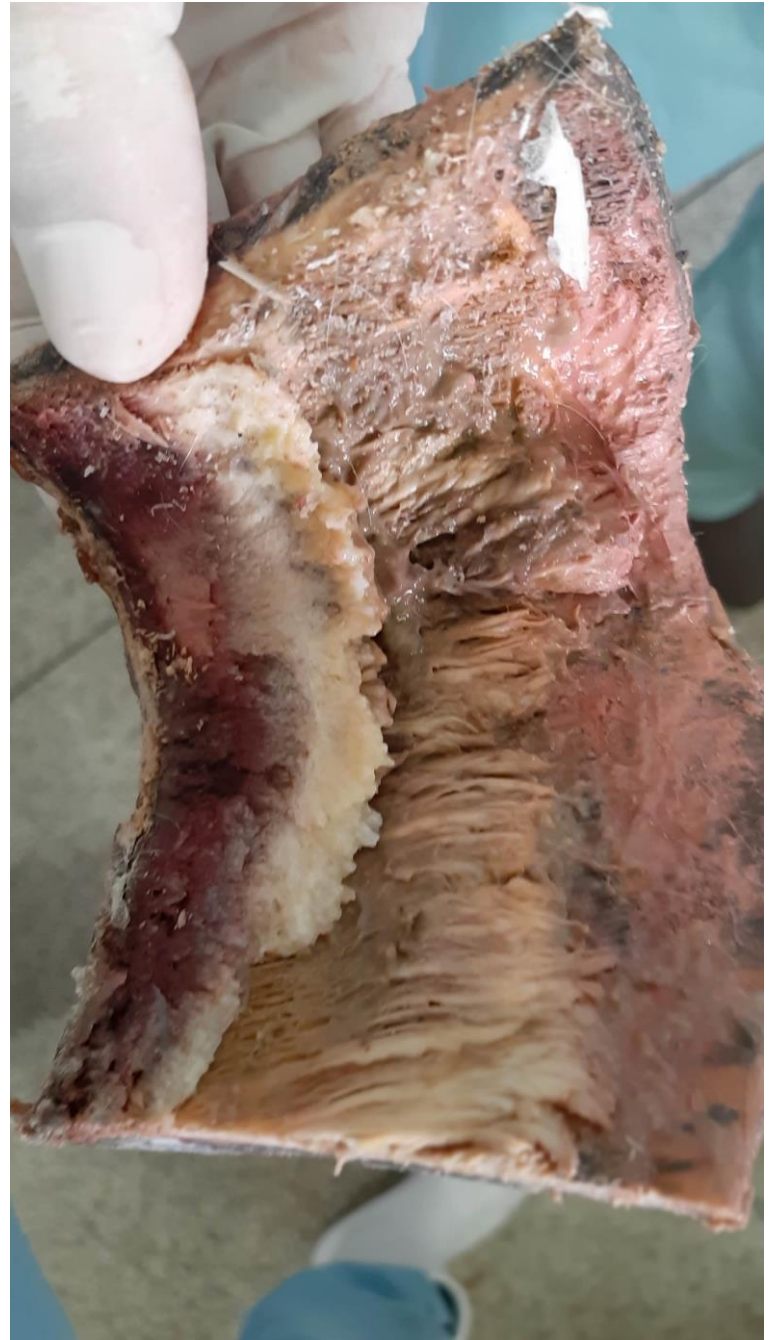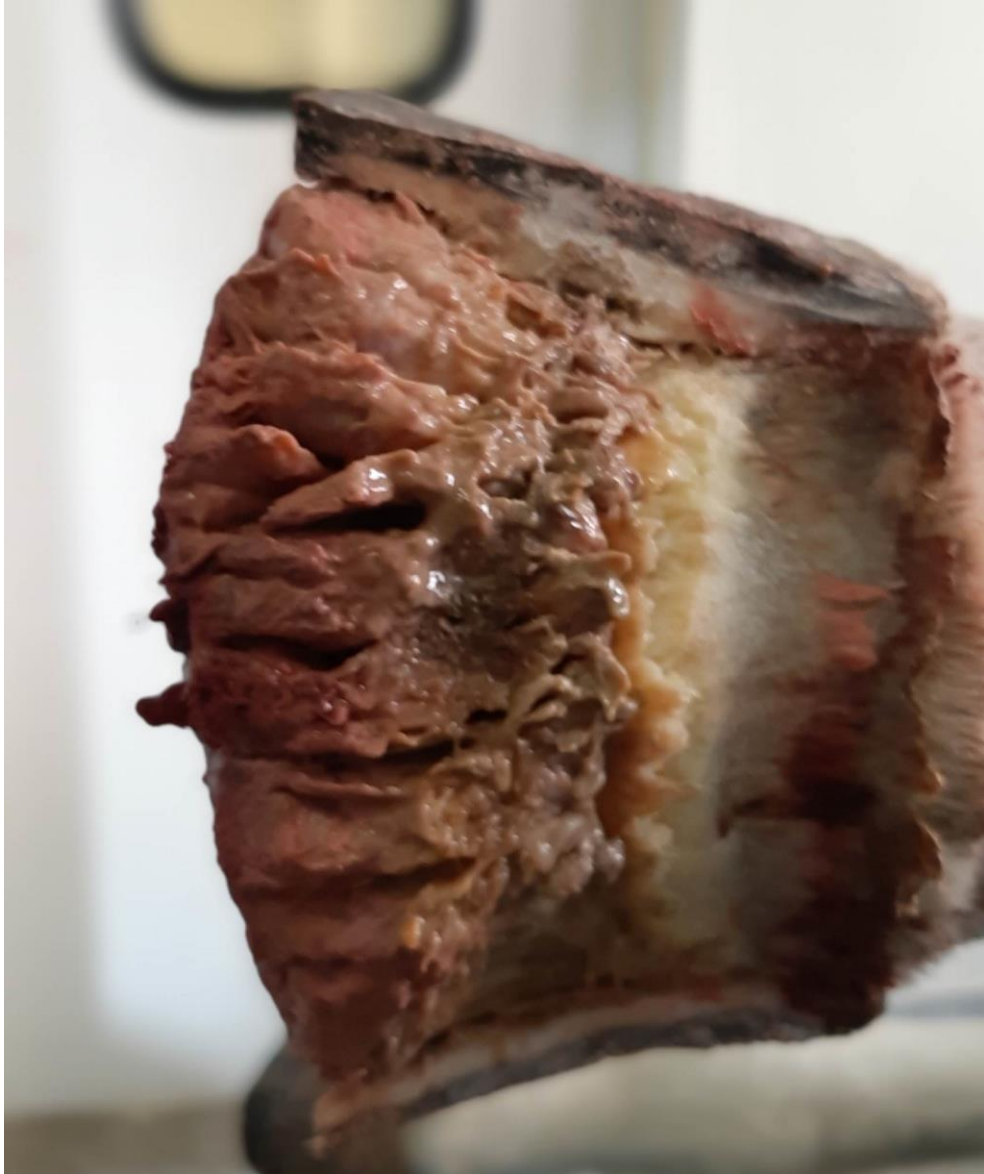Pododermatite vegetante

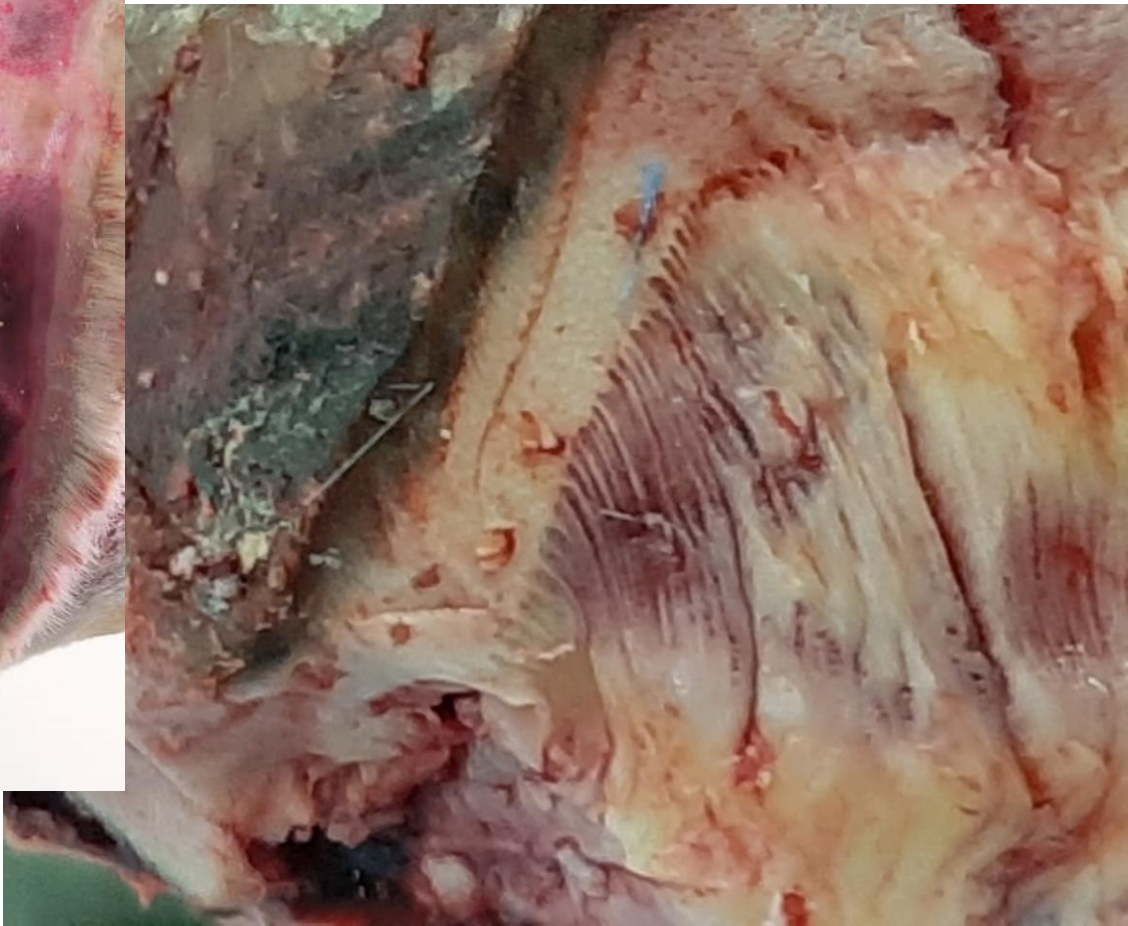
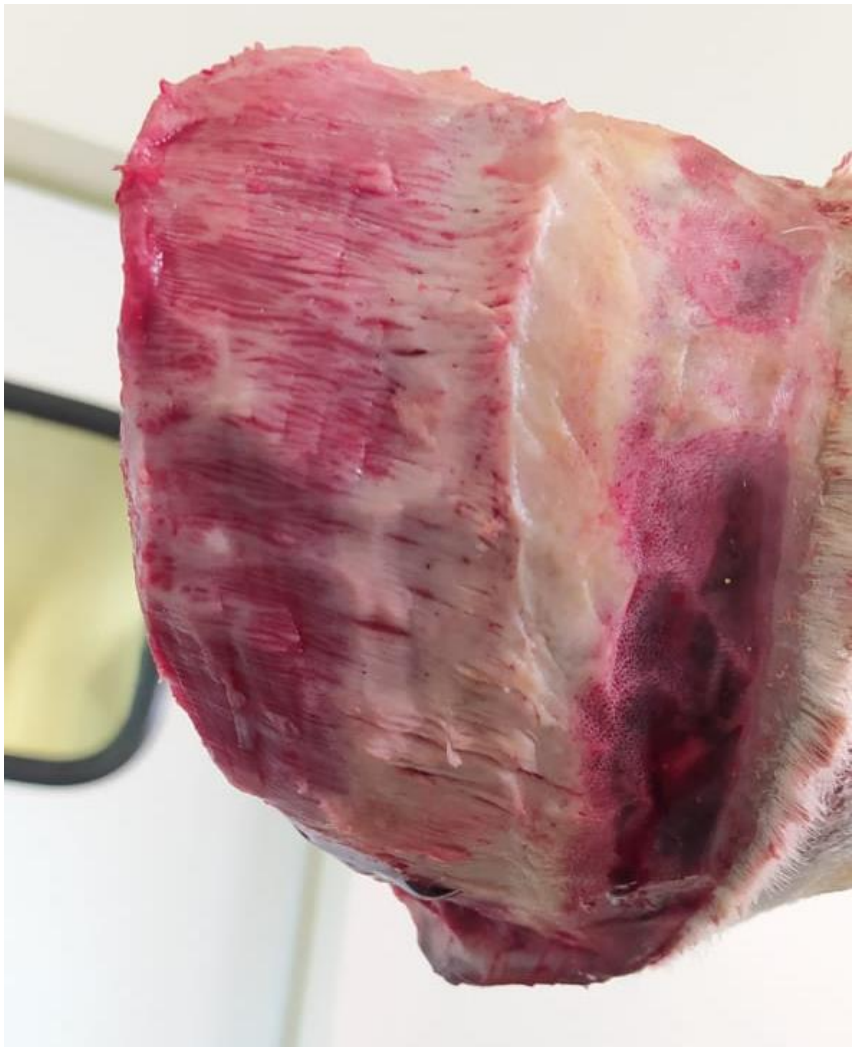

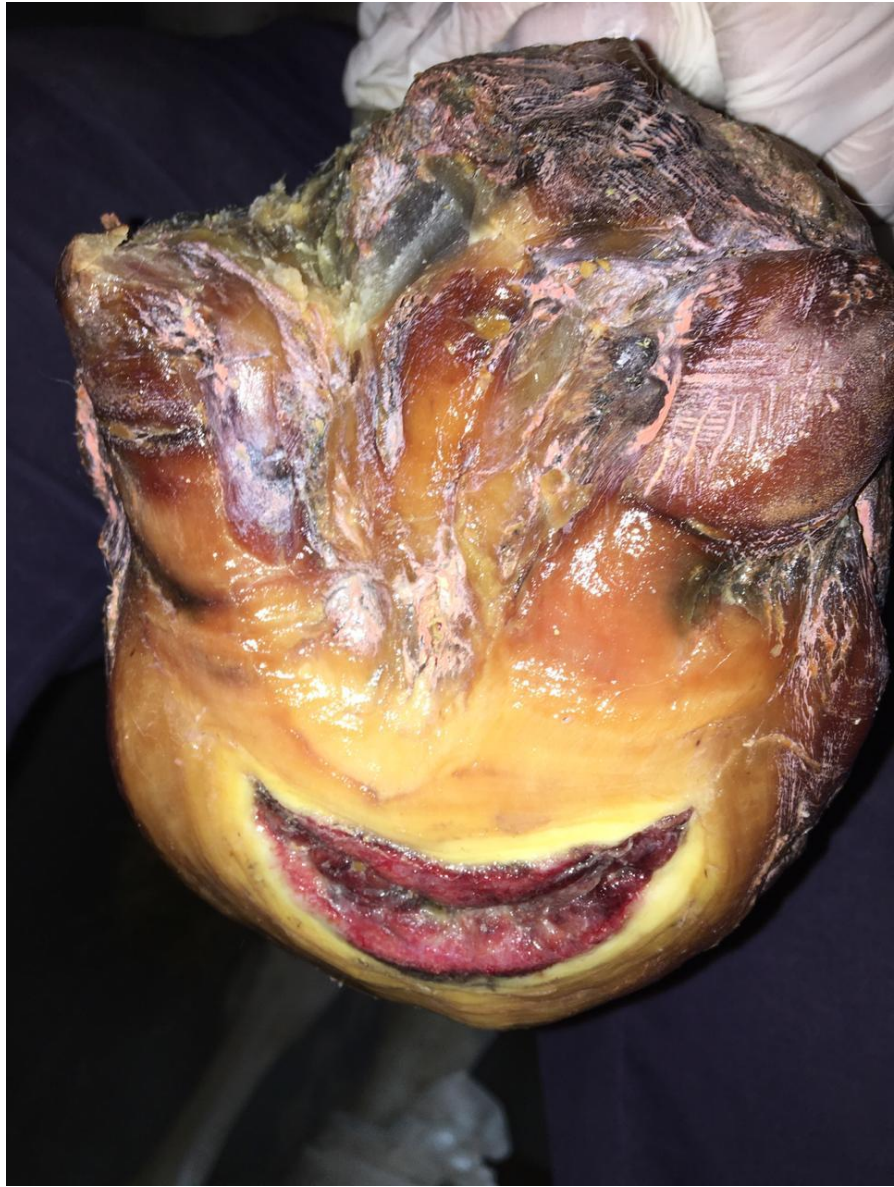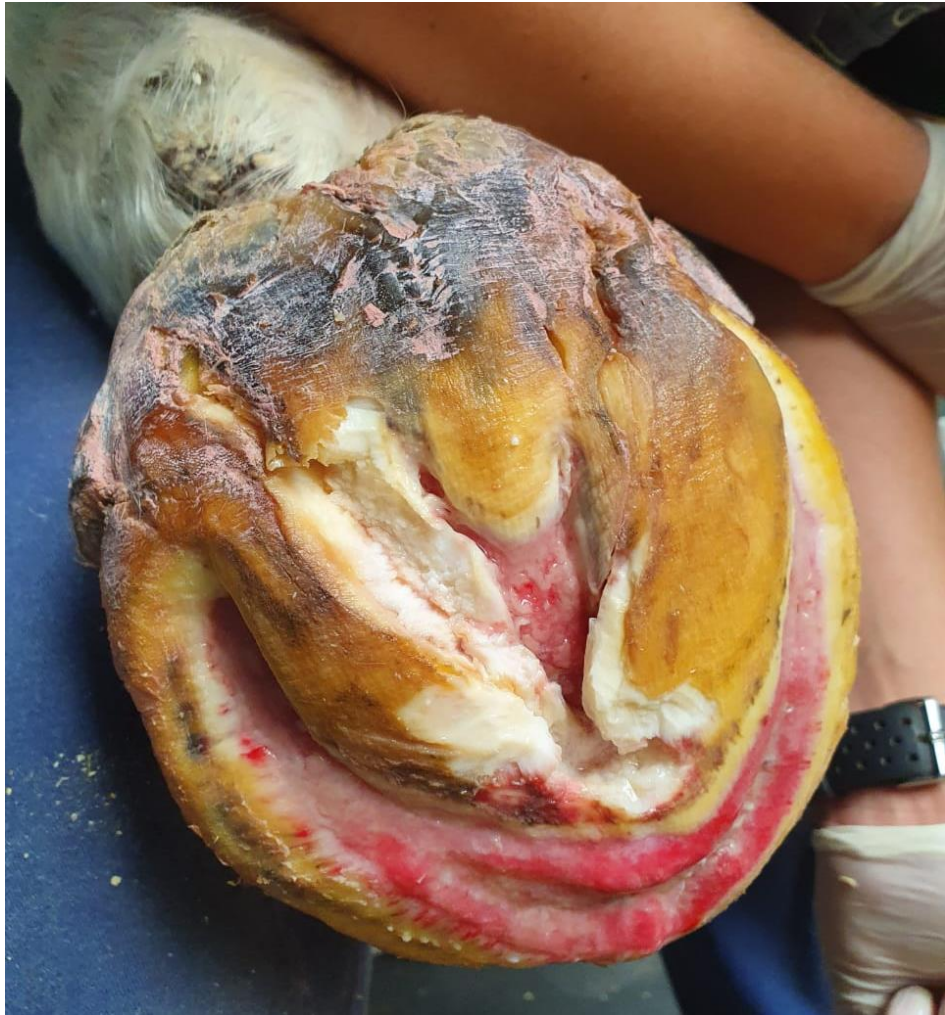Pododermatite vegetante



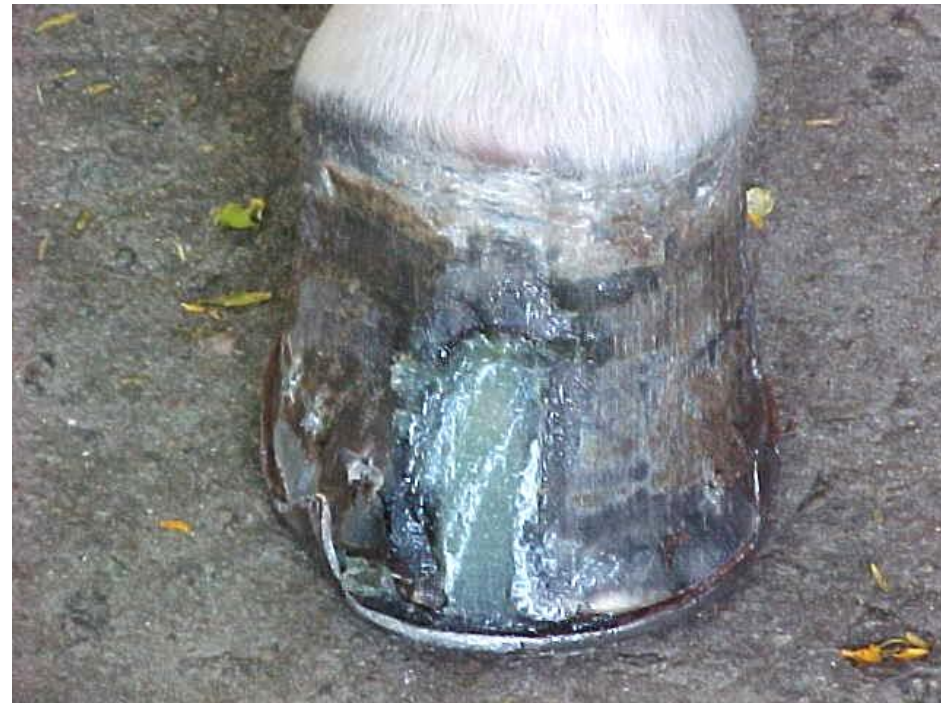
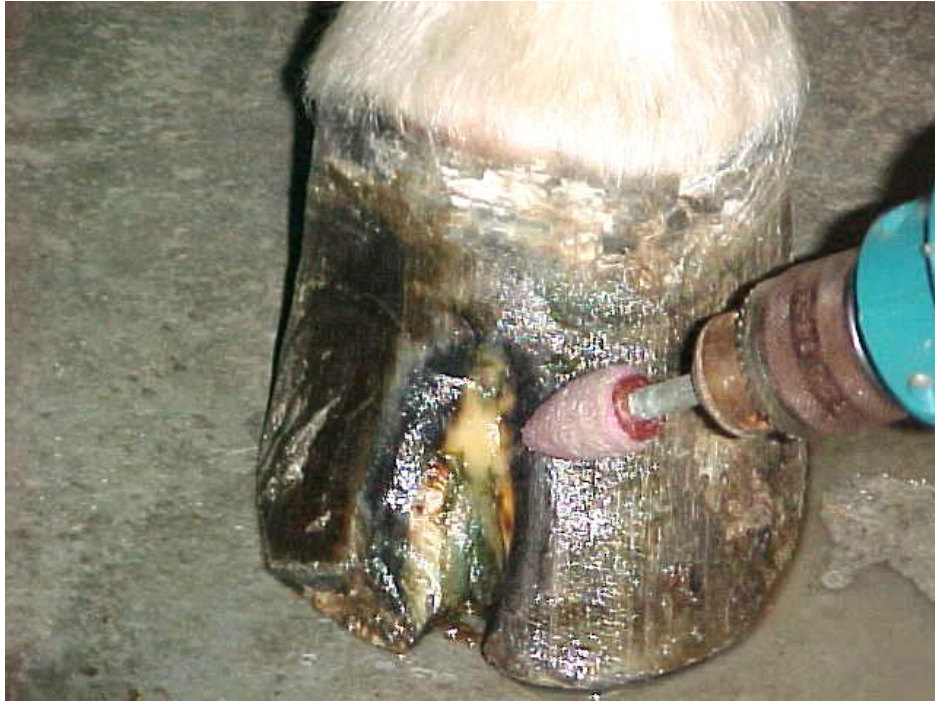


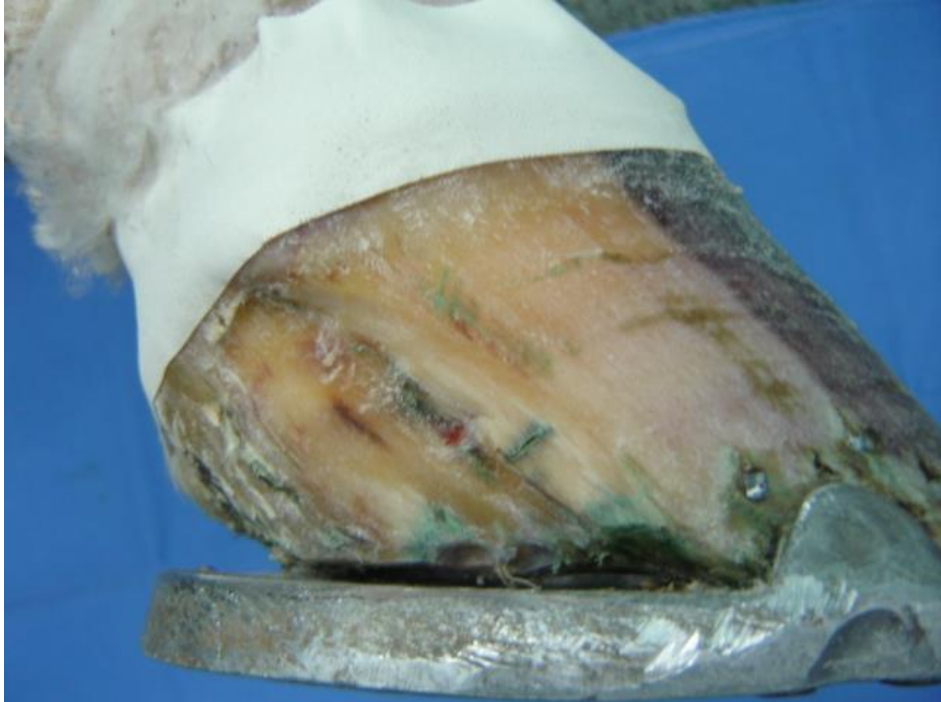
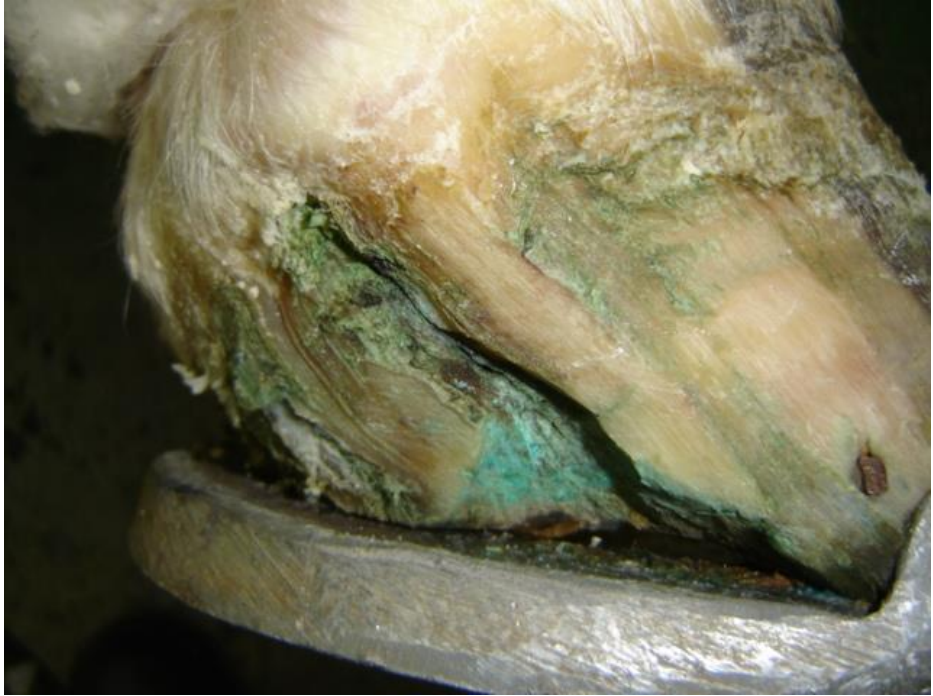


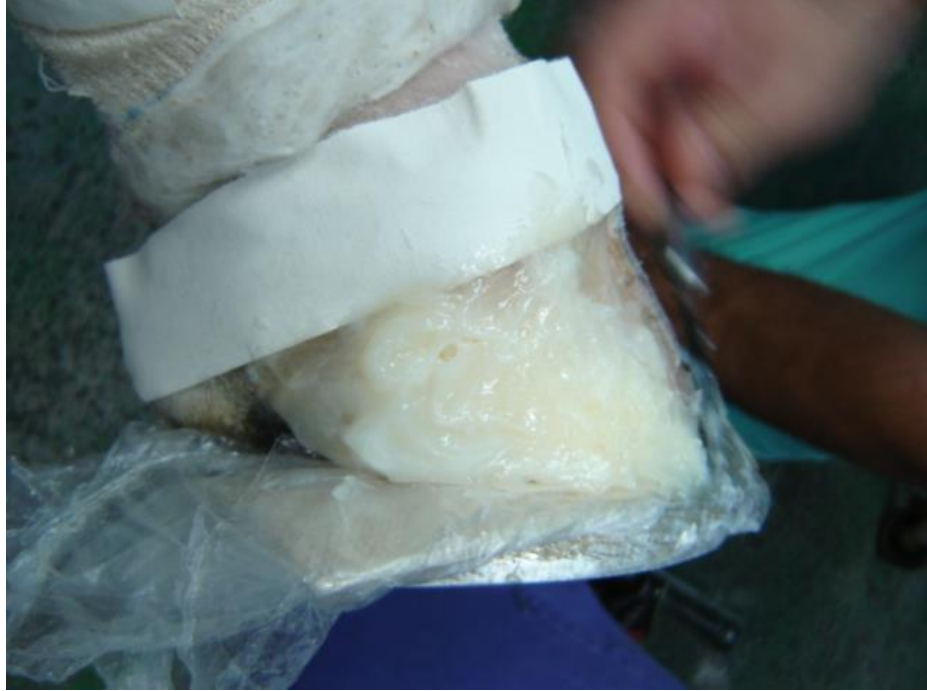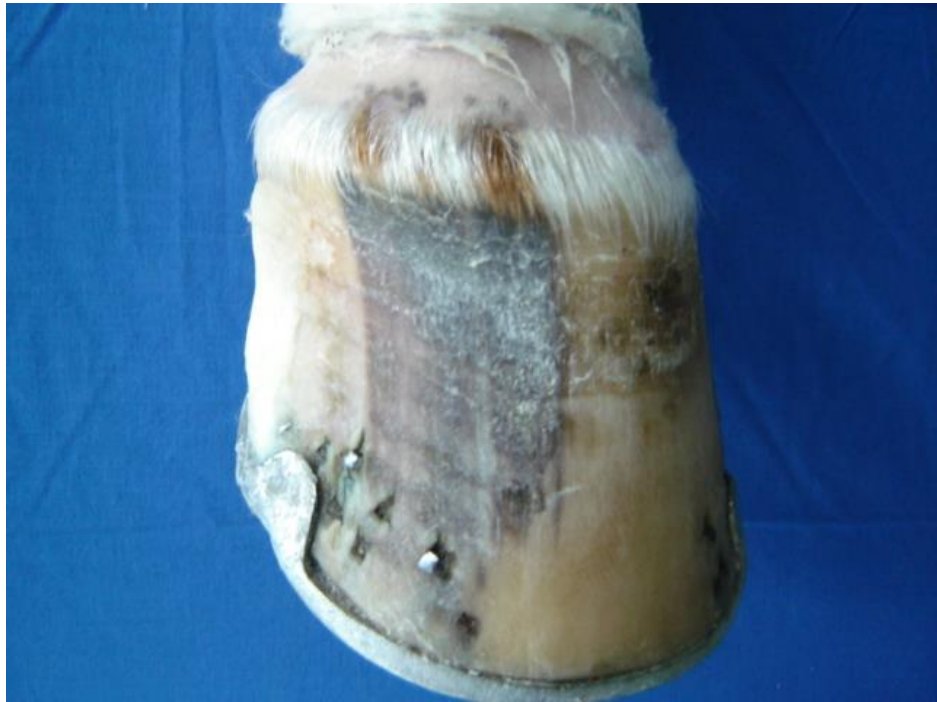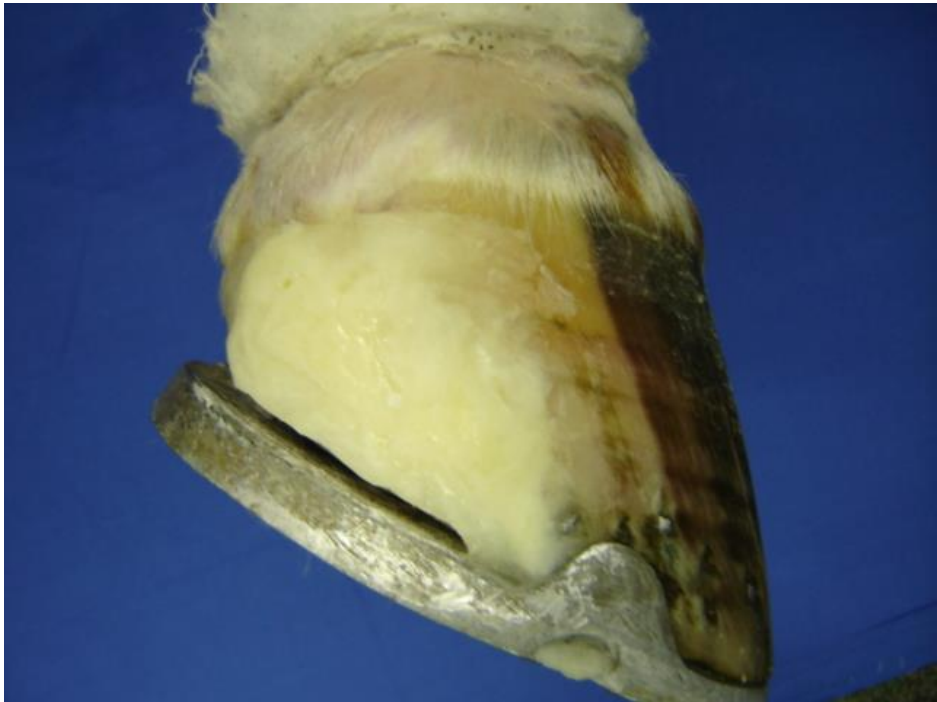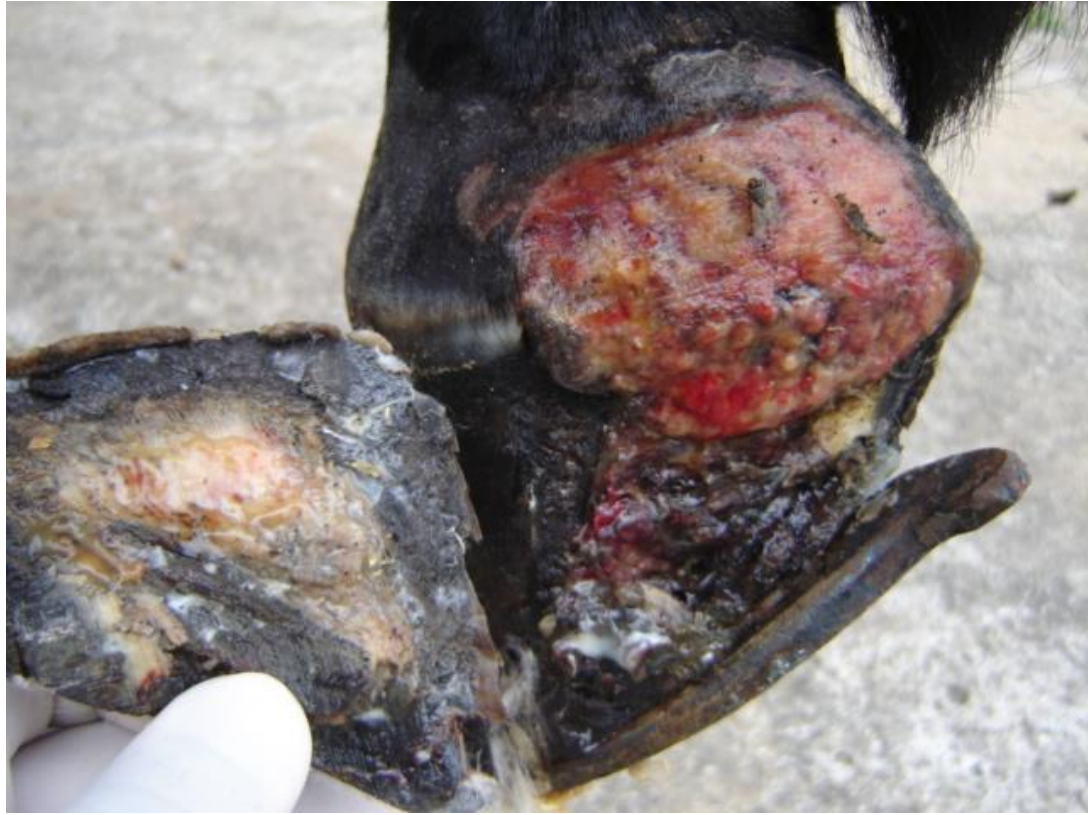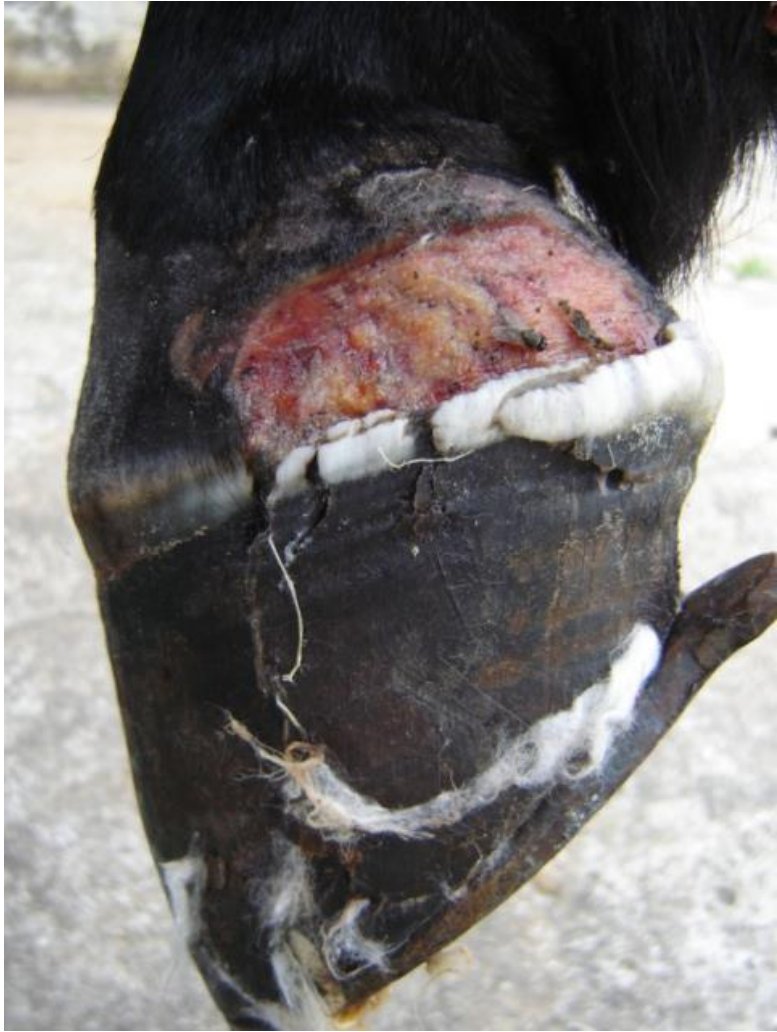Fratura de casco / resina



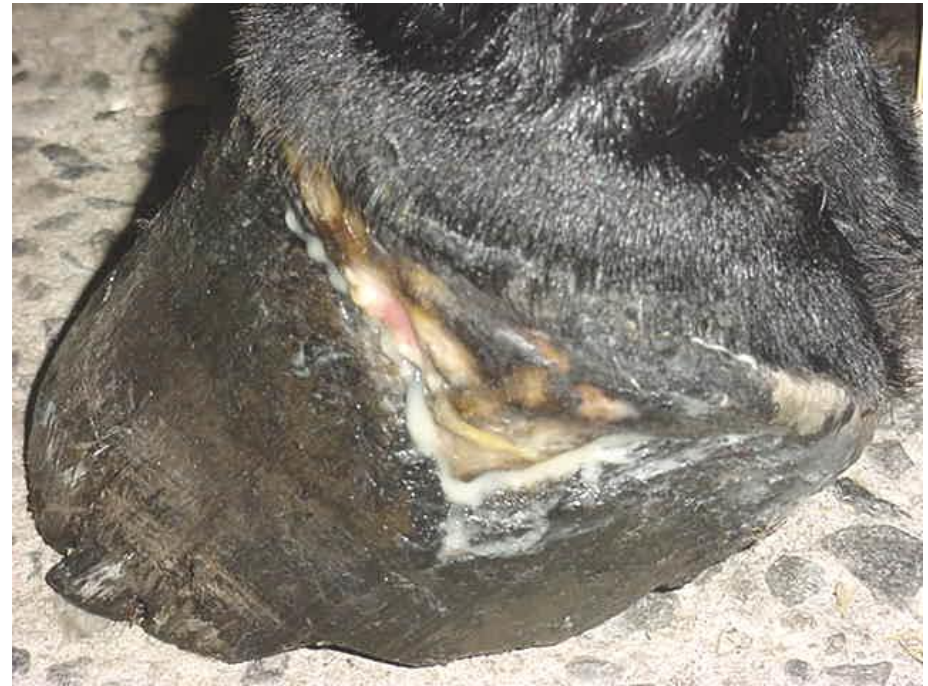
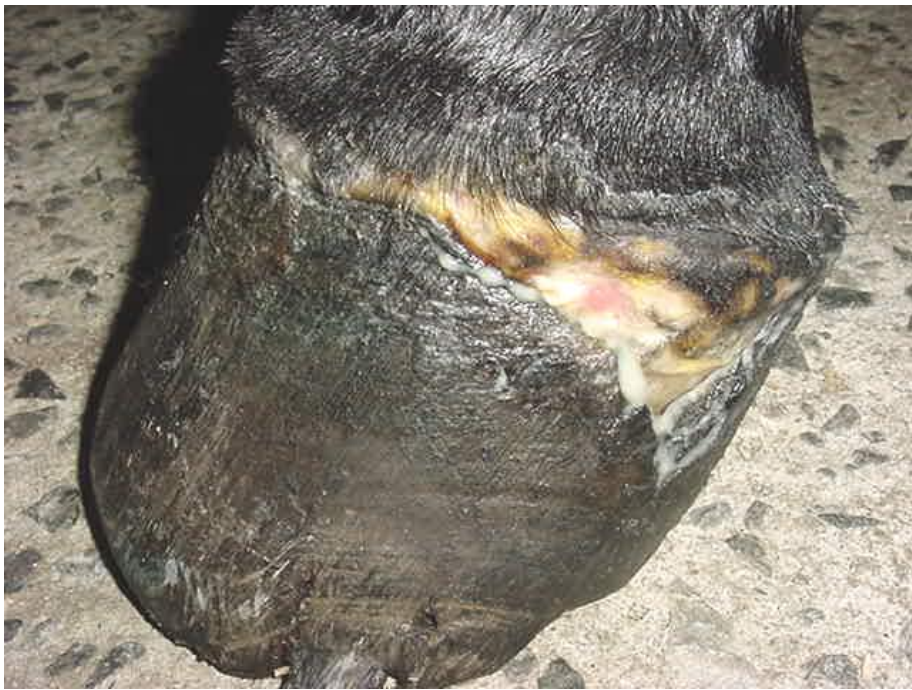




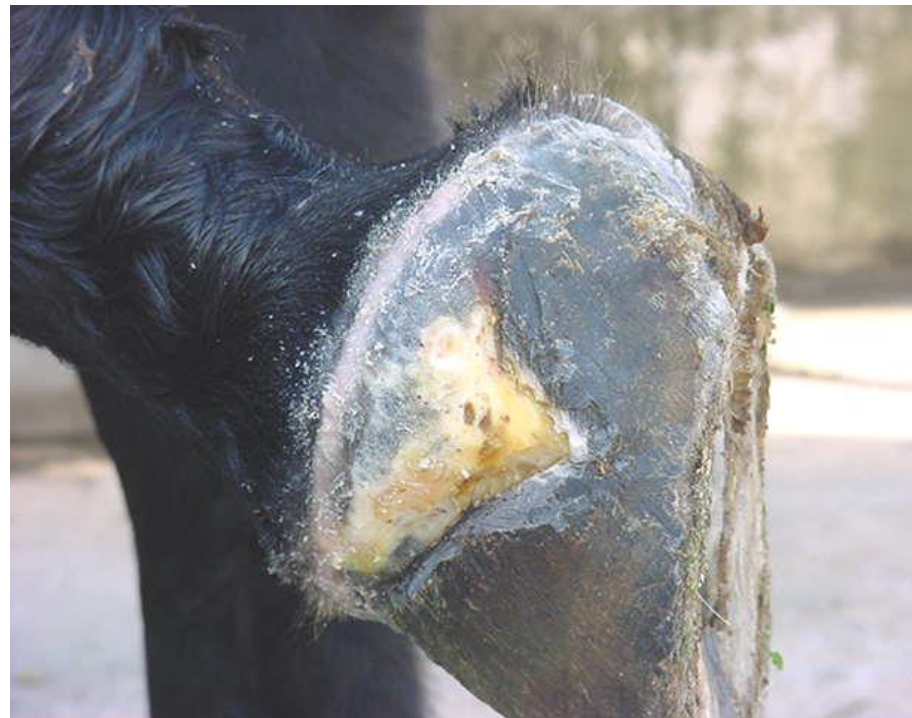
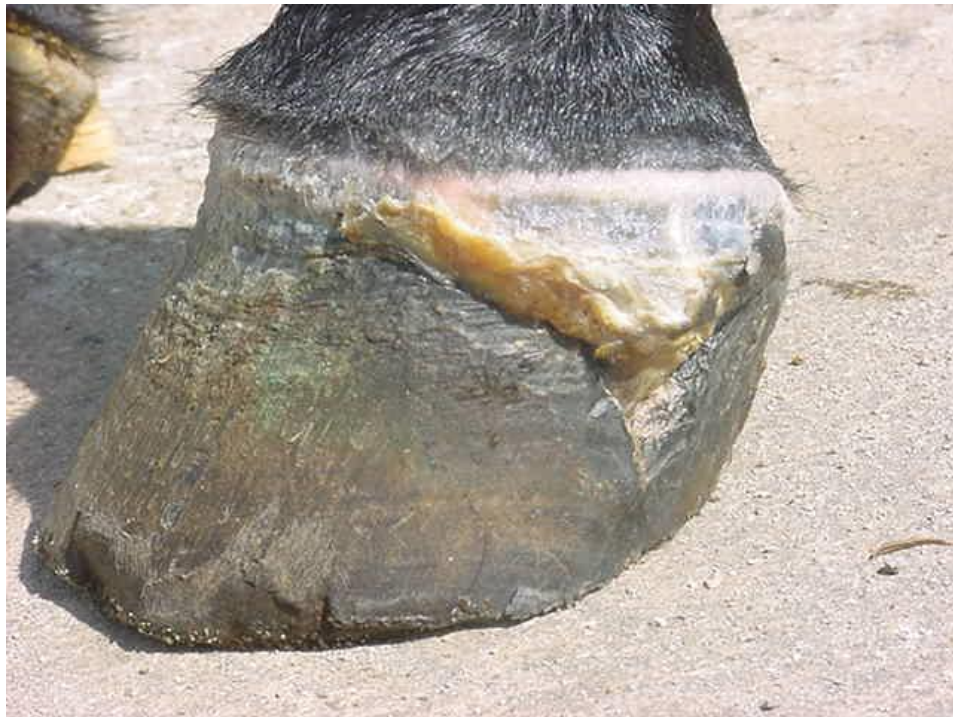
Avulsão de casco



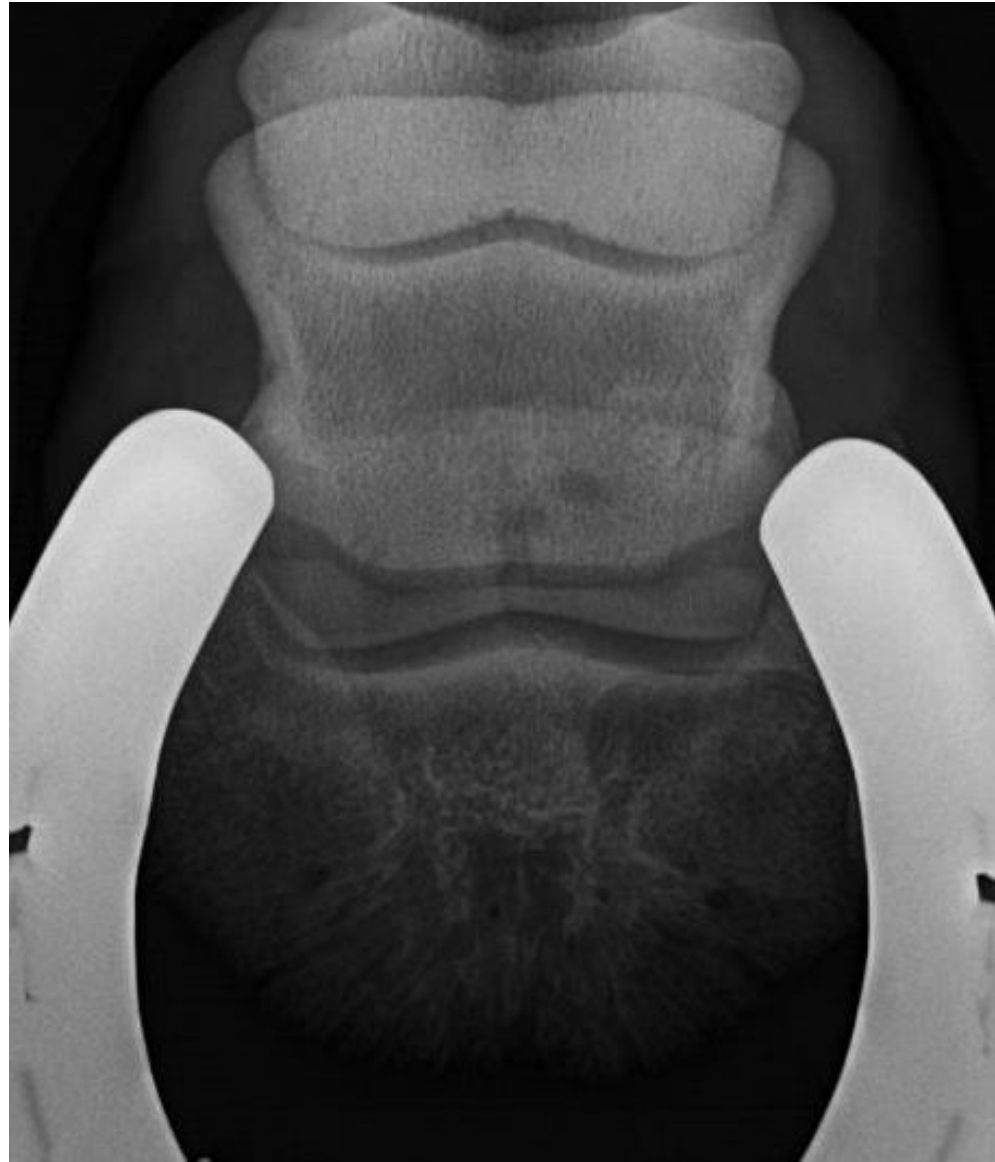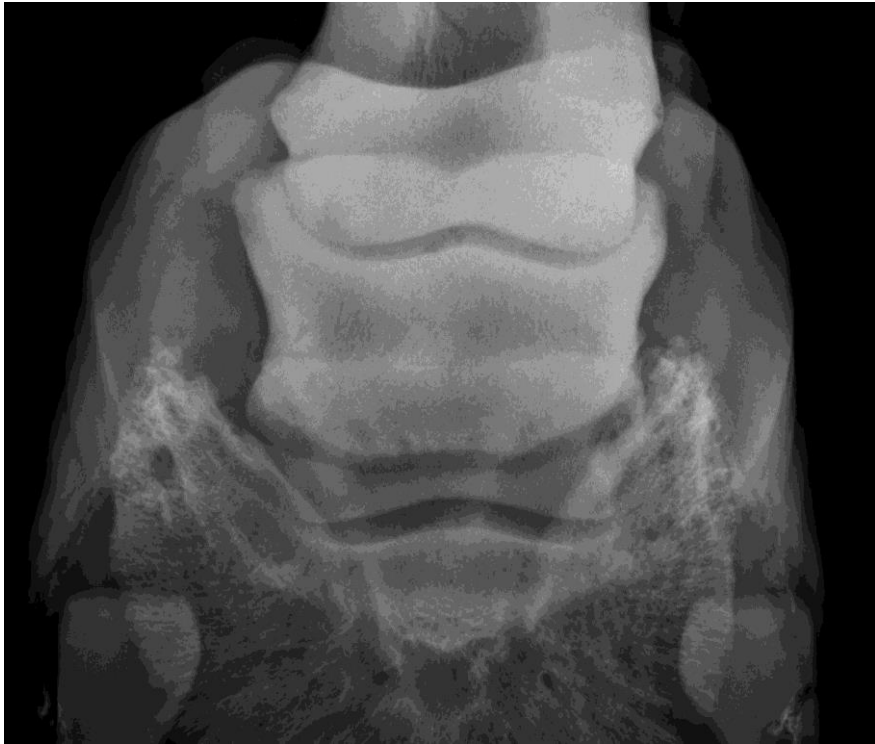Avulsão de casco

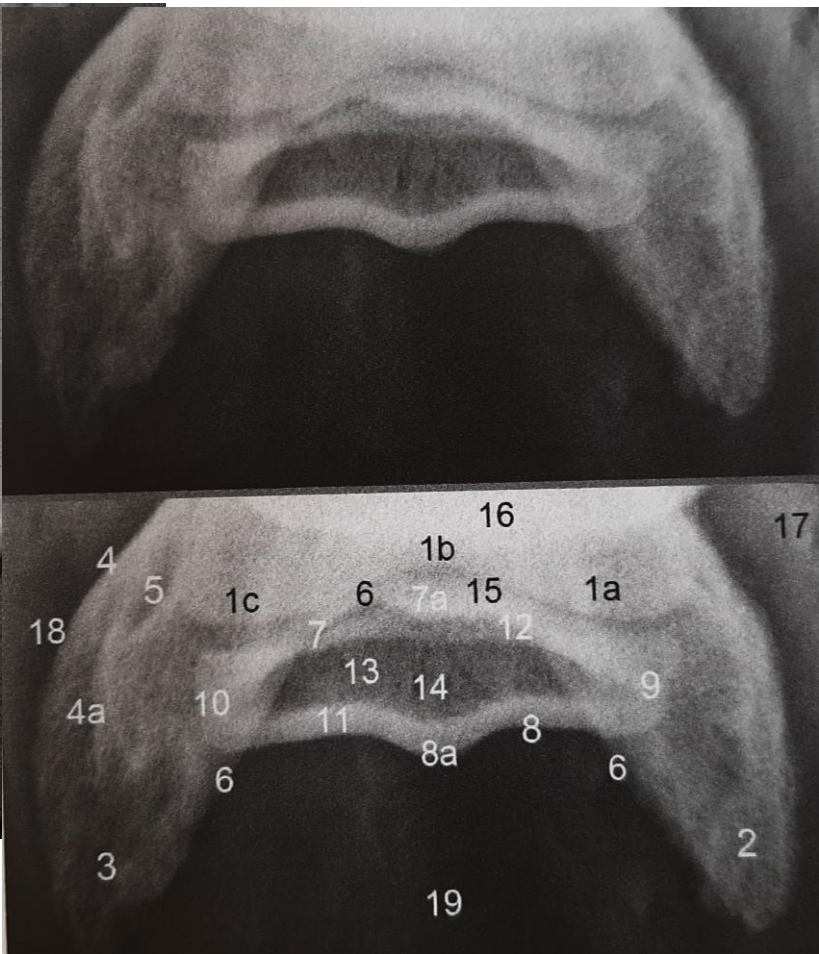
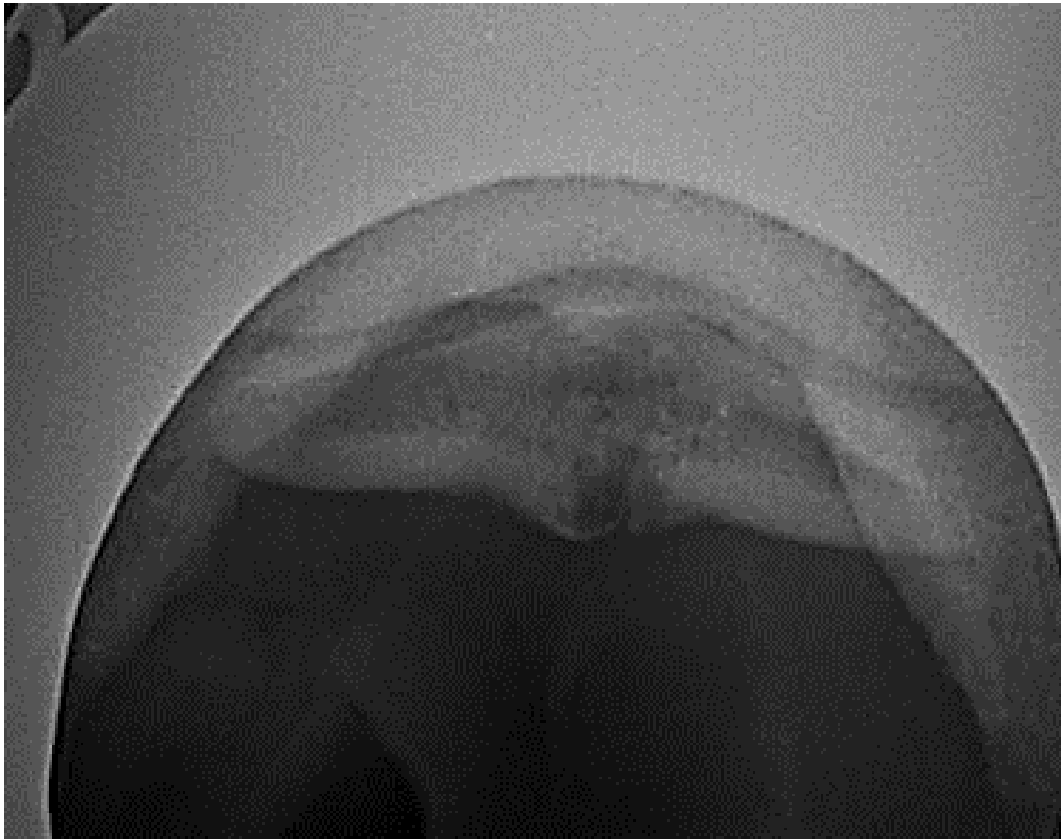


Avulsão de casco



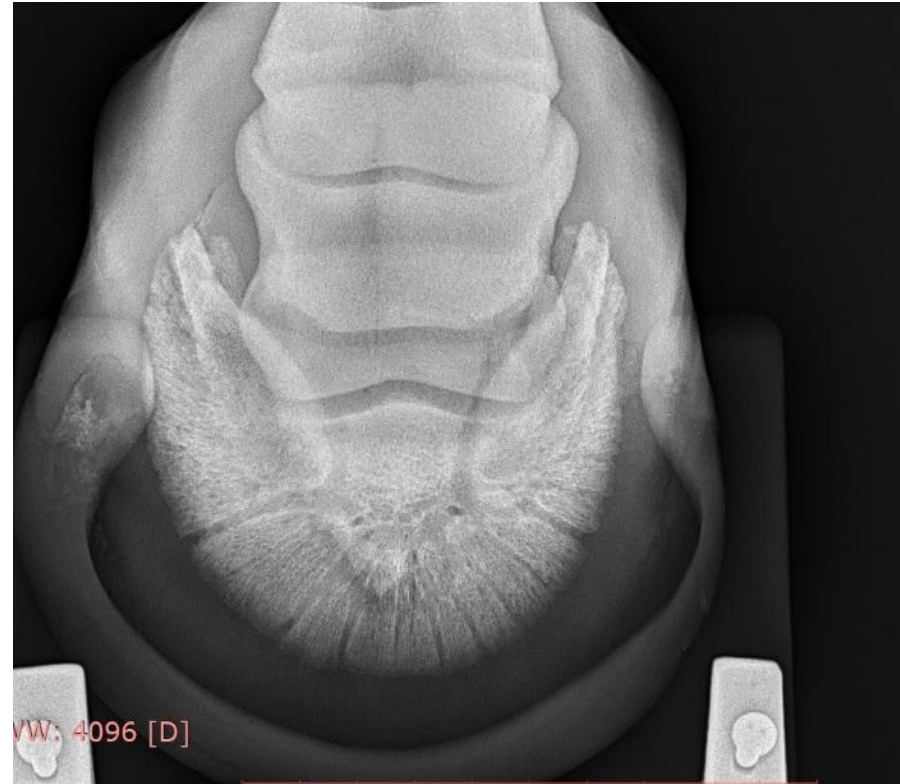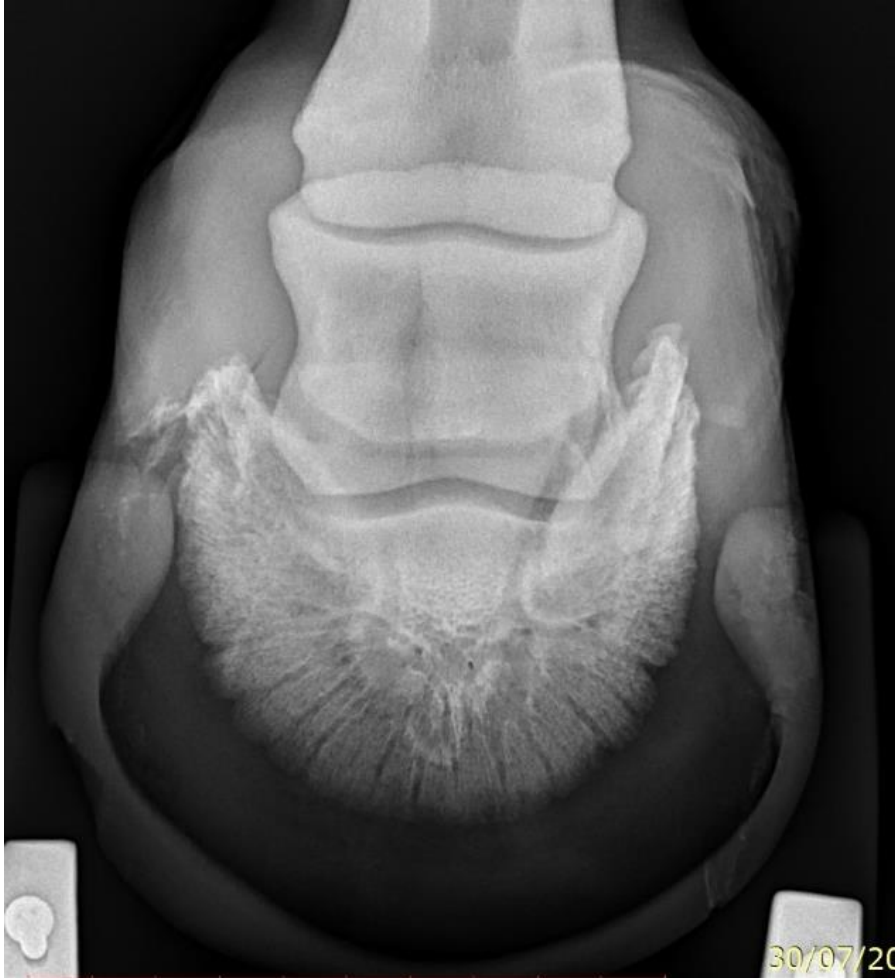Podotrocleose

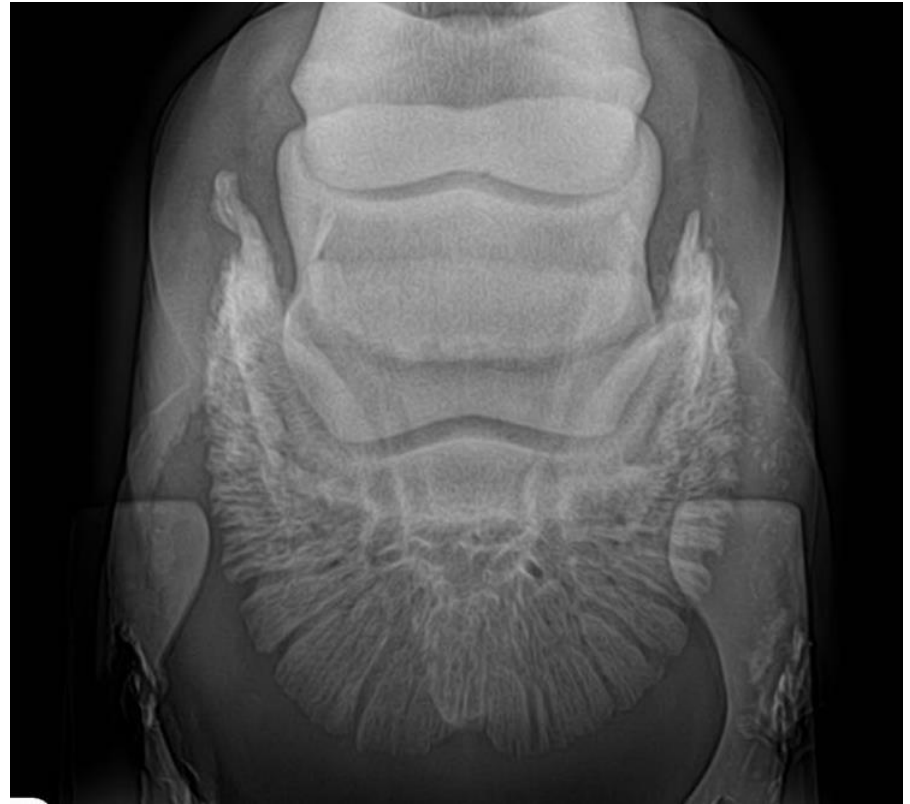
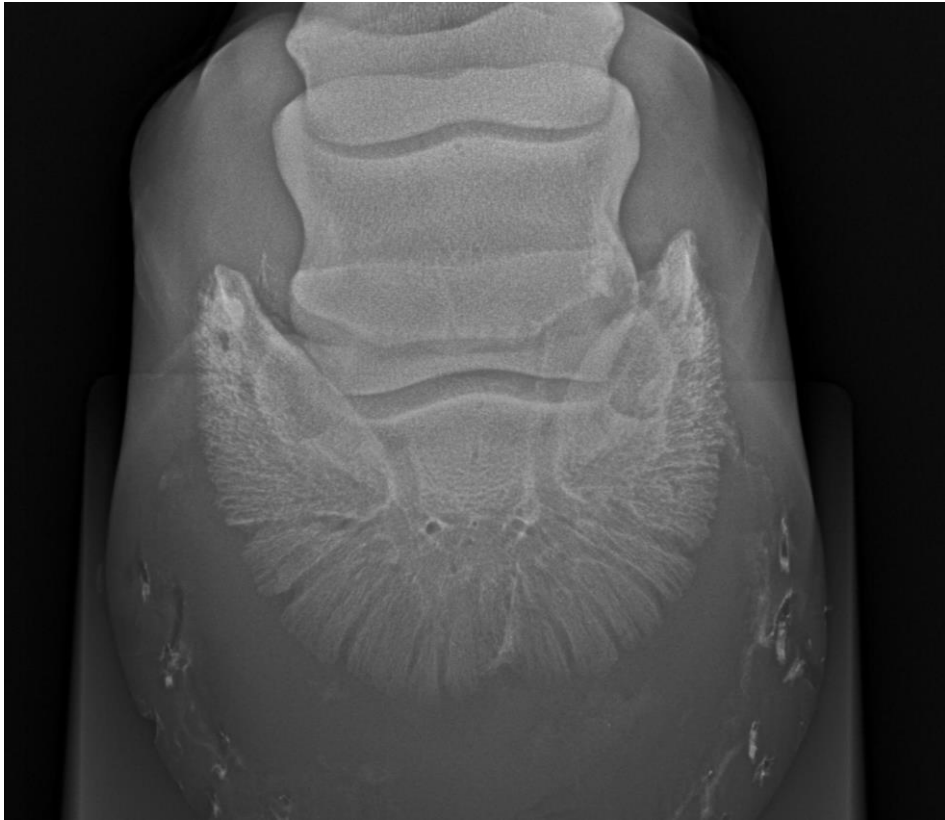


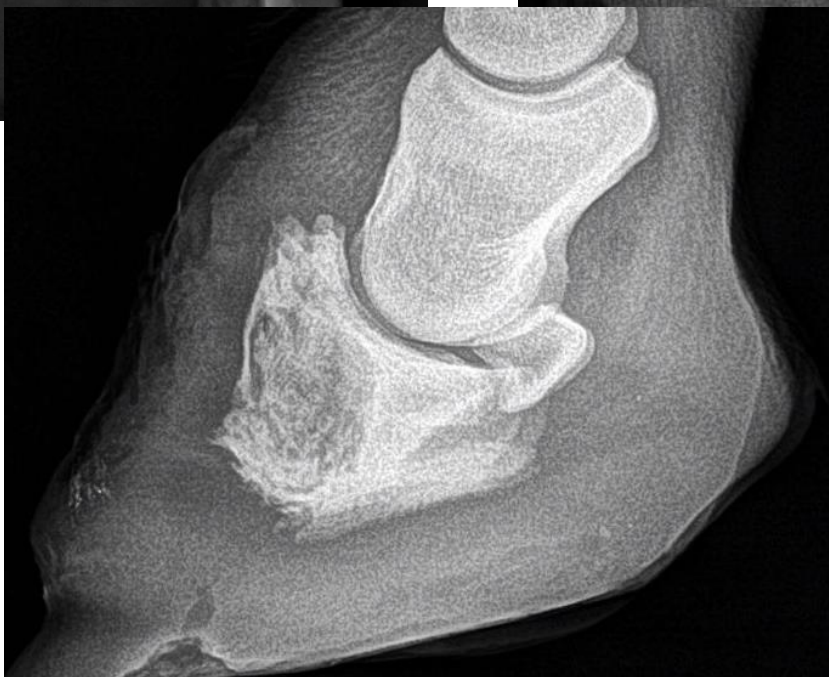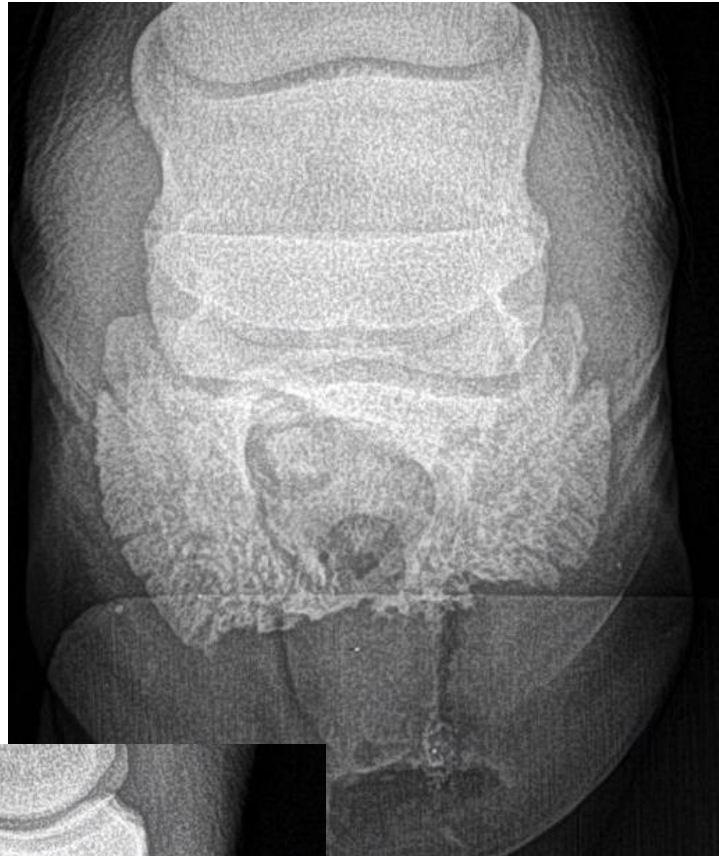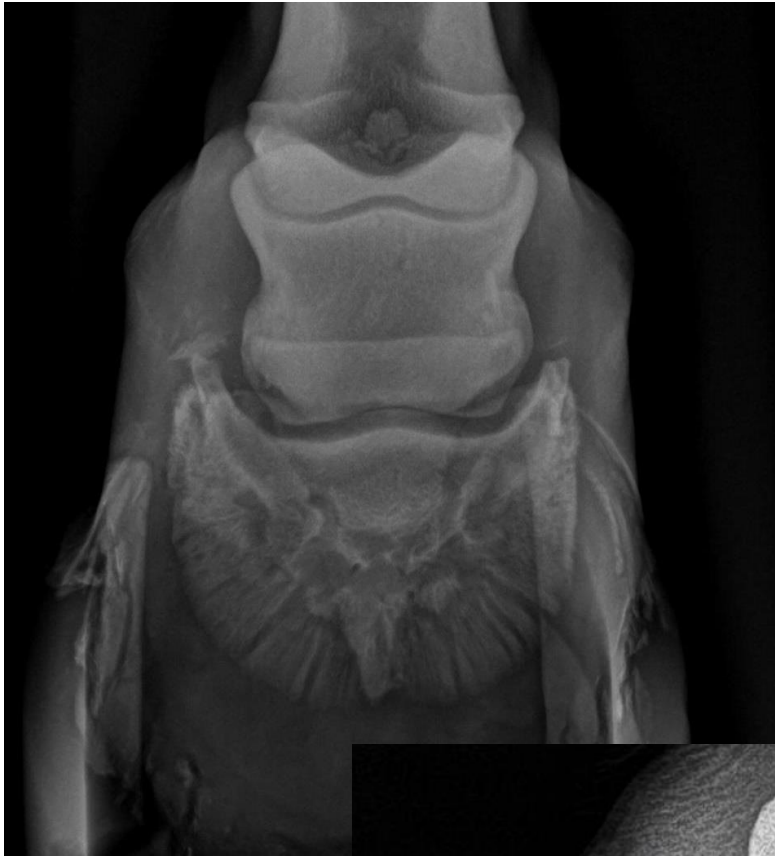Essentials of clinical anatomy of the equine locomotor system, DENOIX. 2019

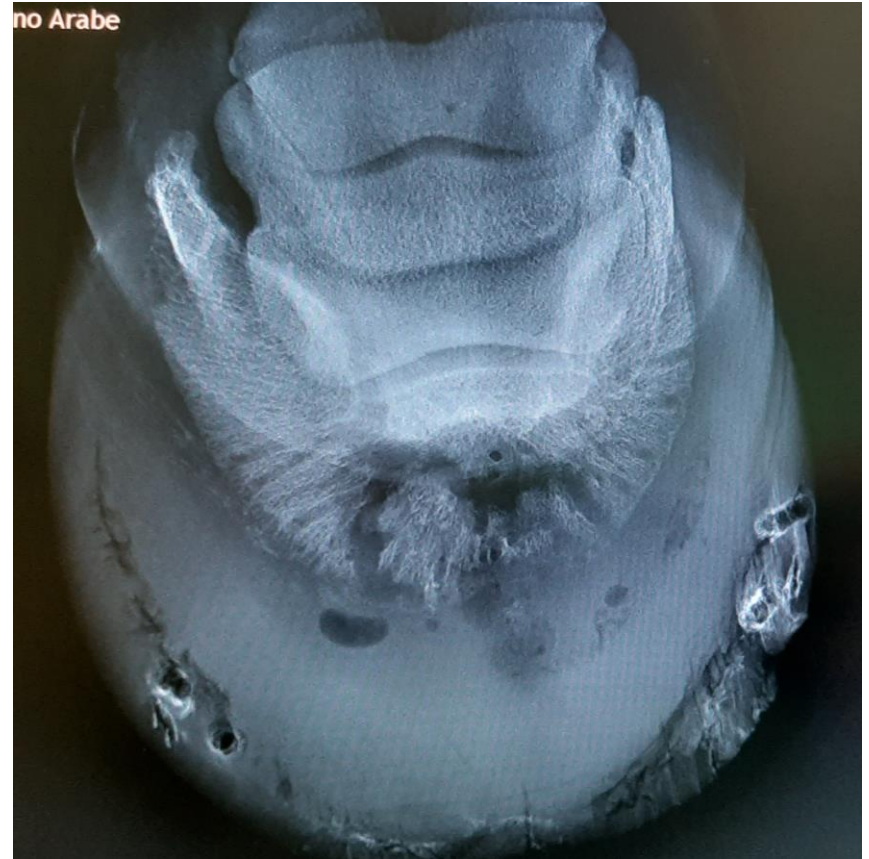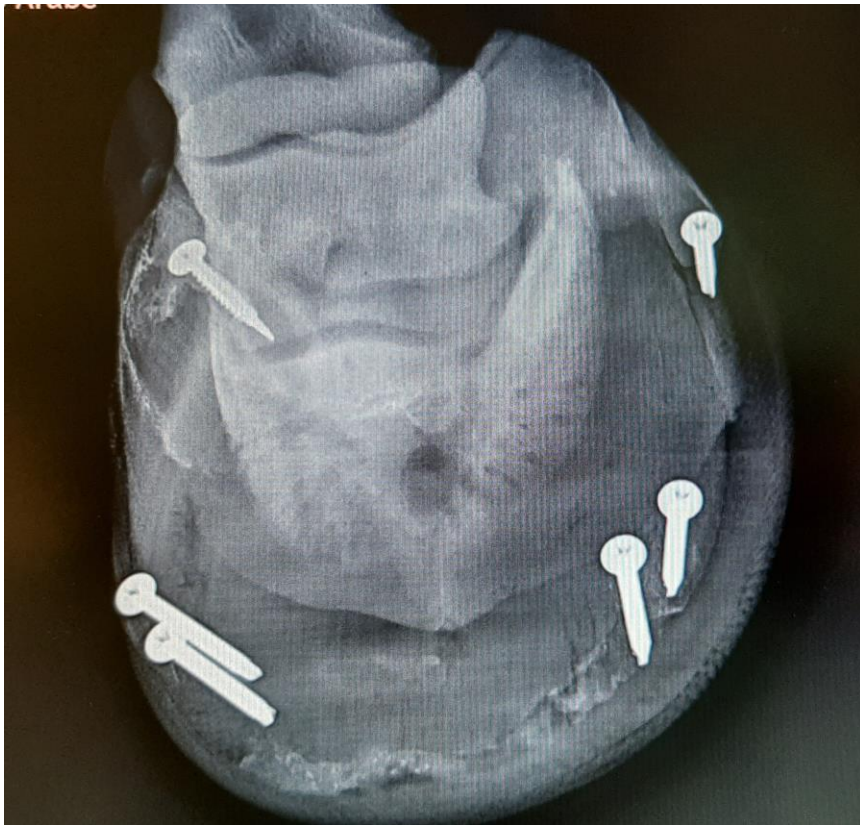OSTEÍTE PODAL

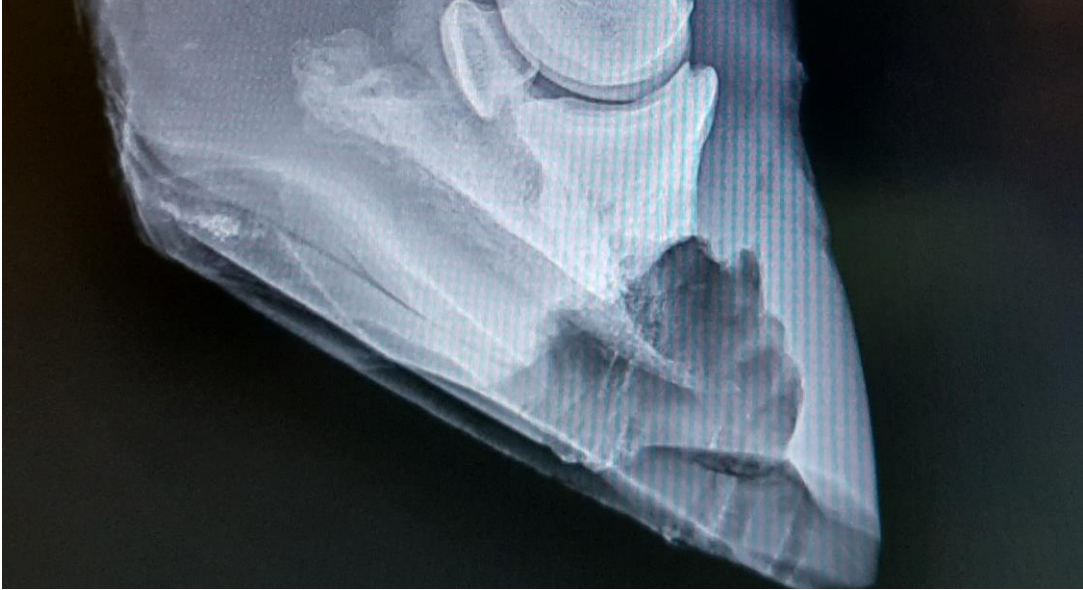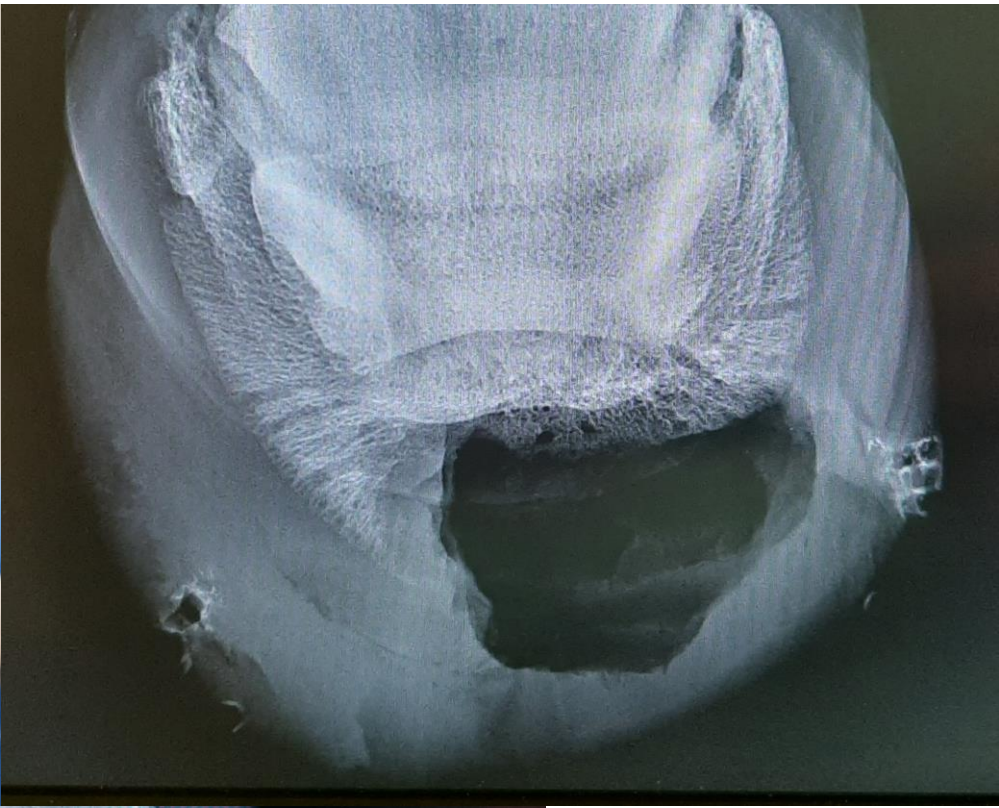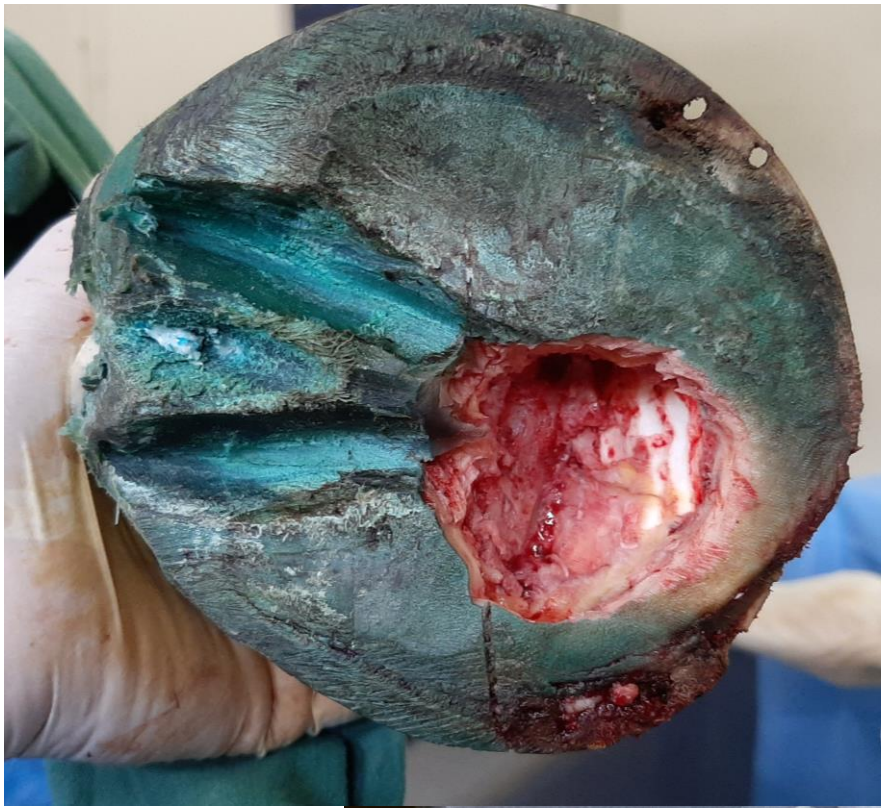




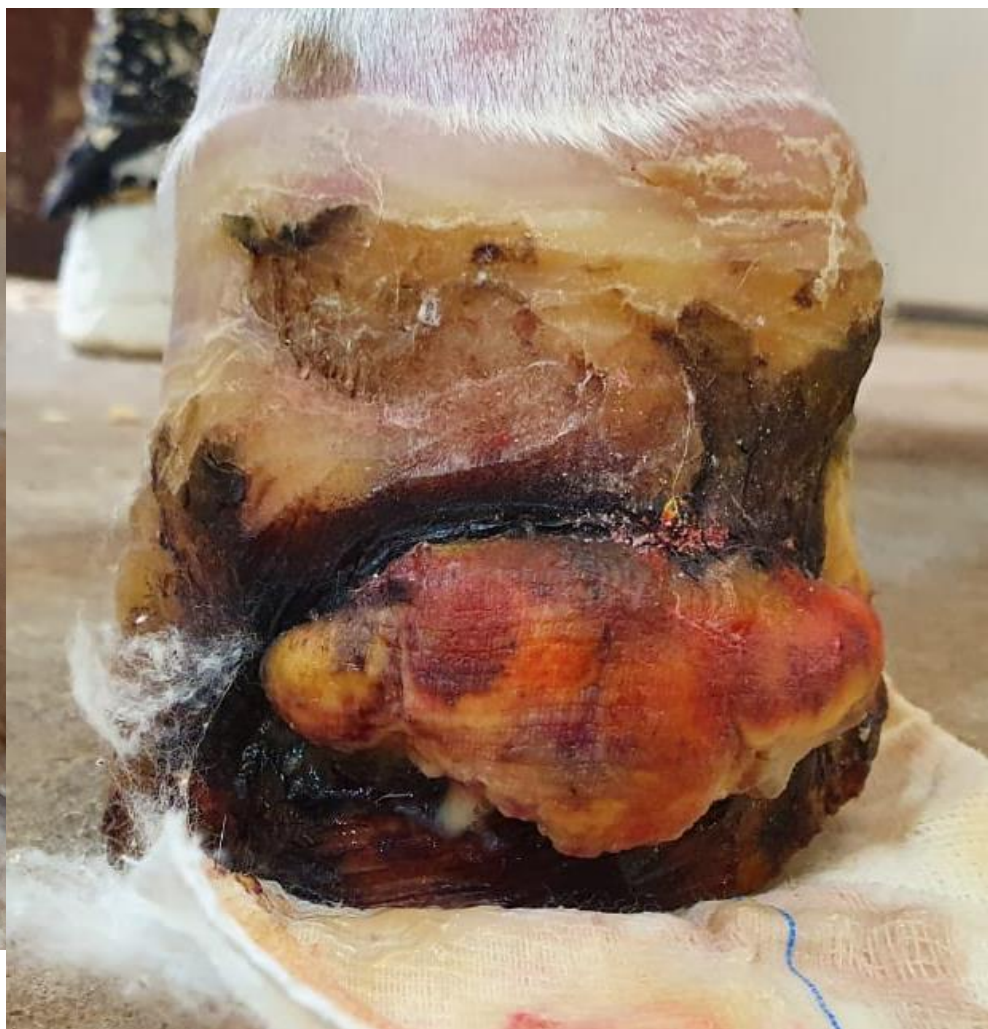
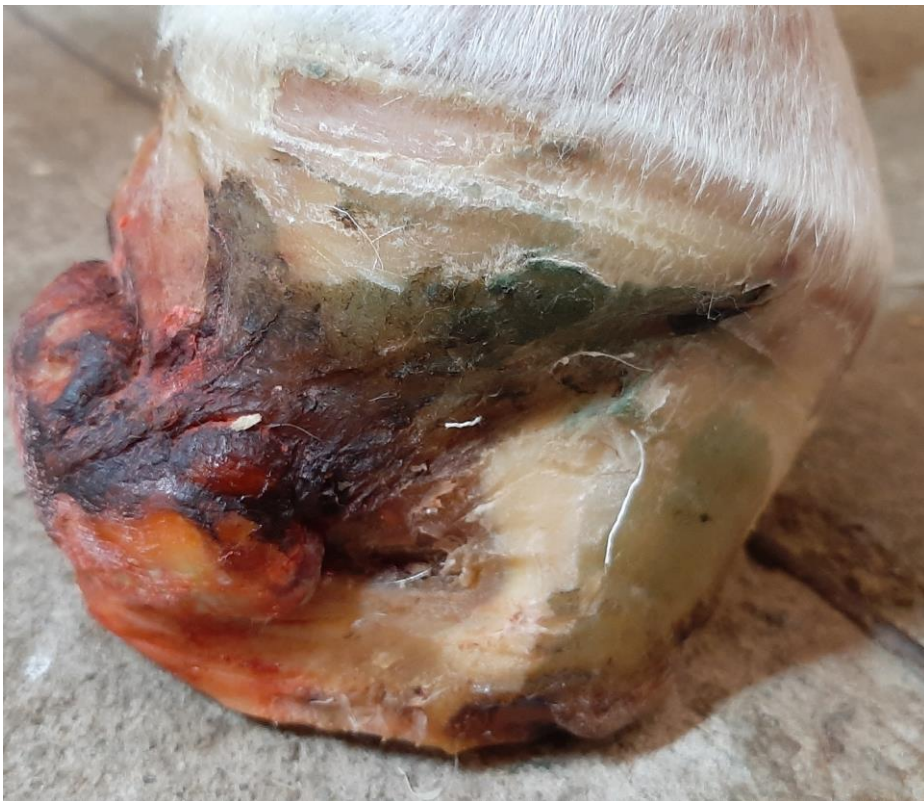
Sequestro ósseo

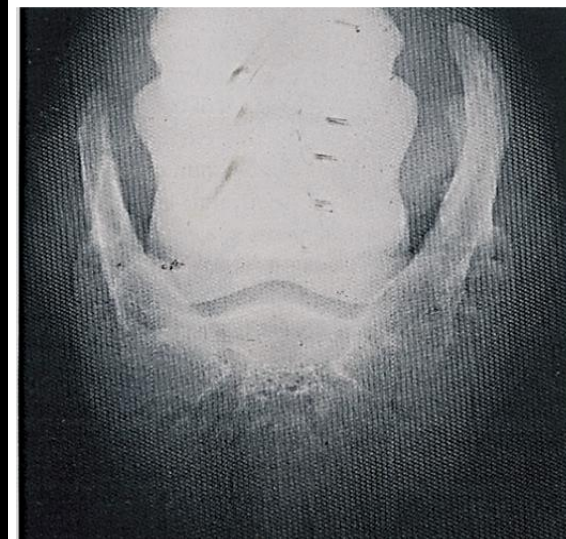
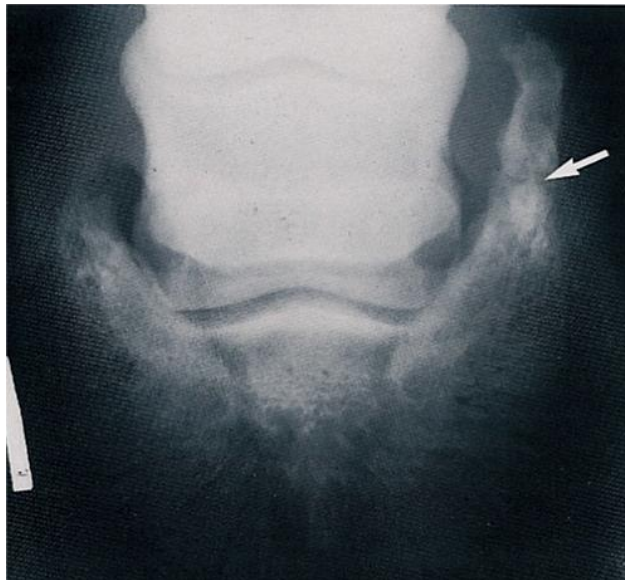
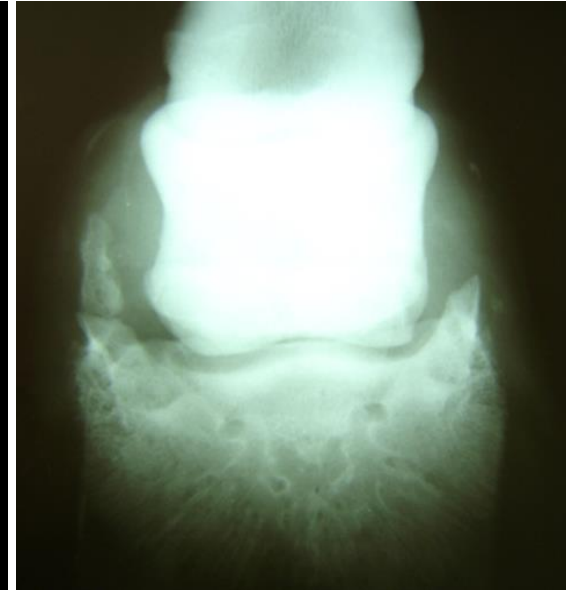
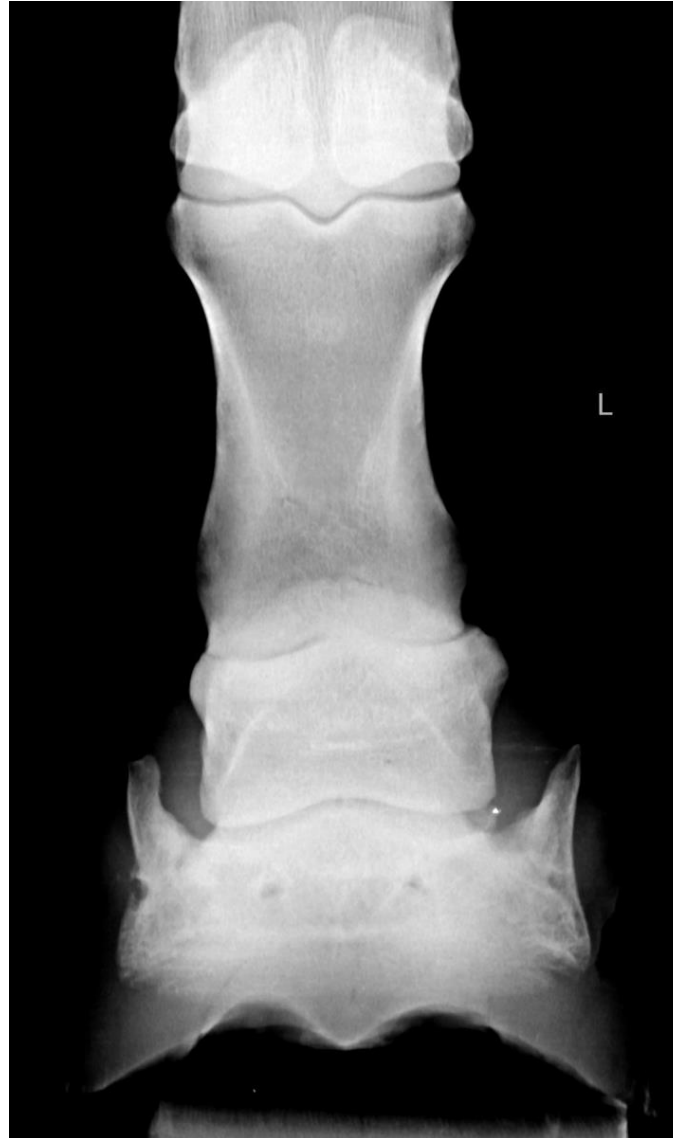
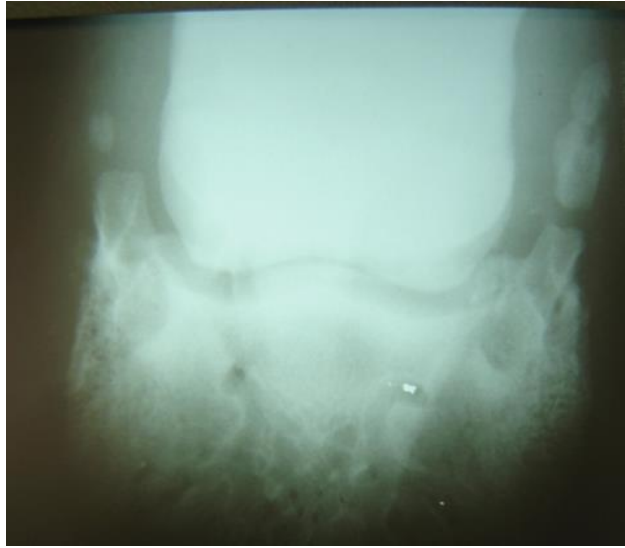




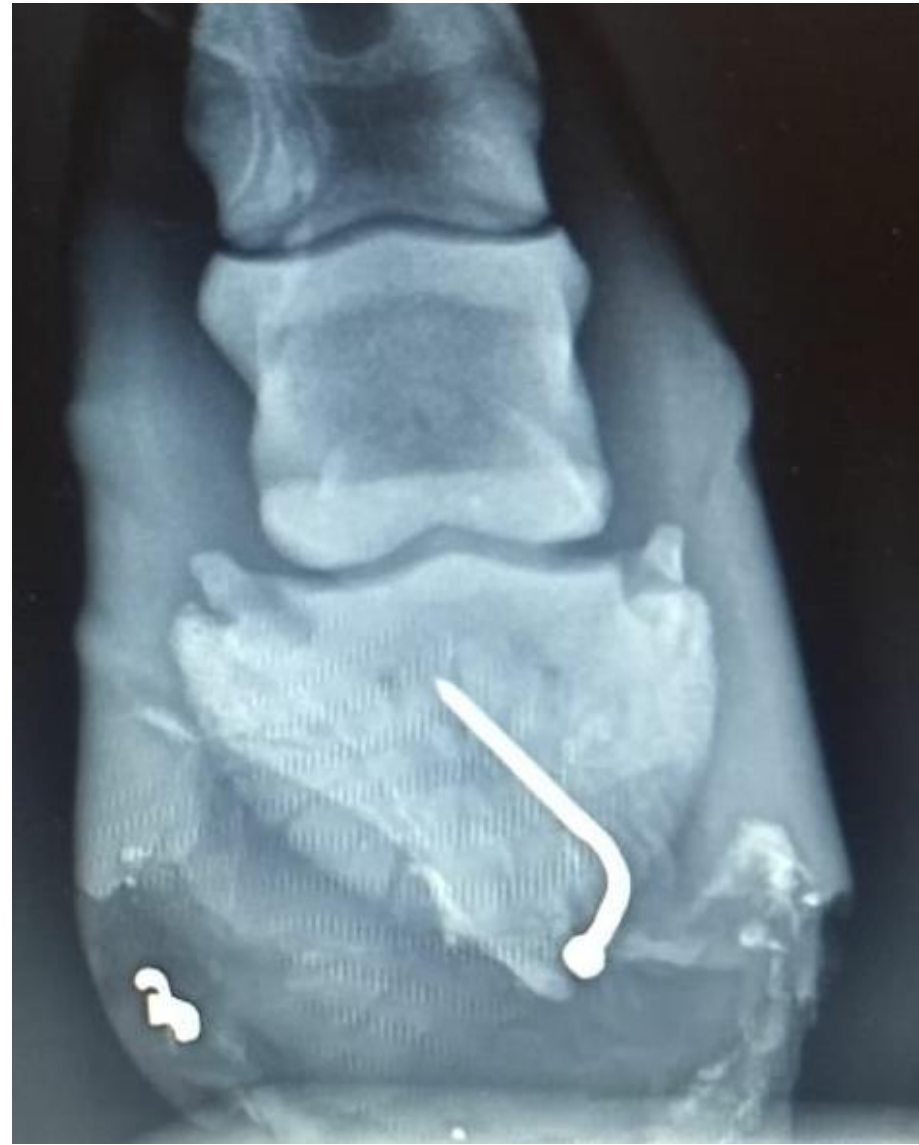
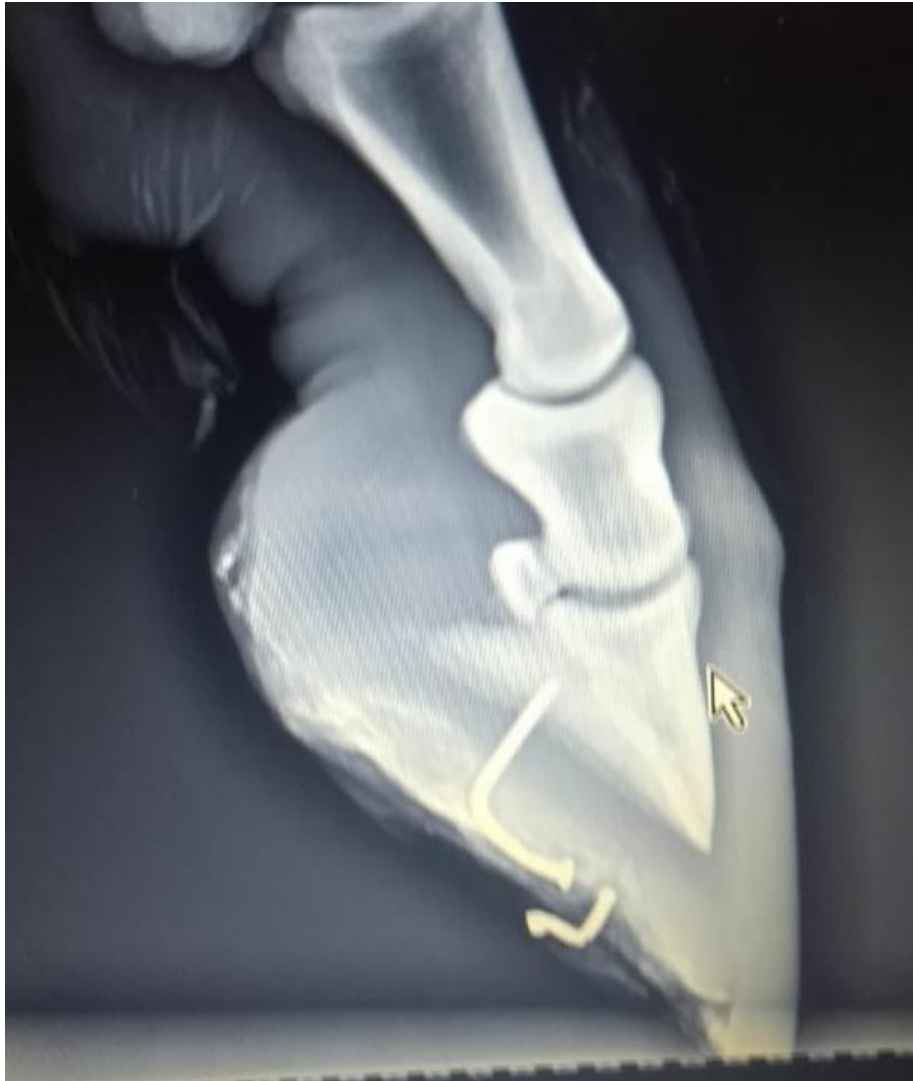
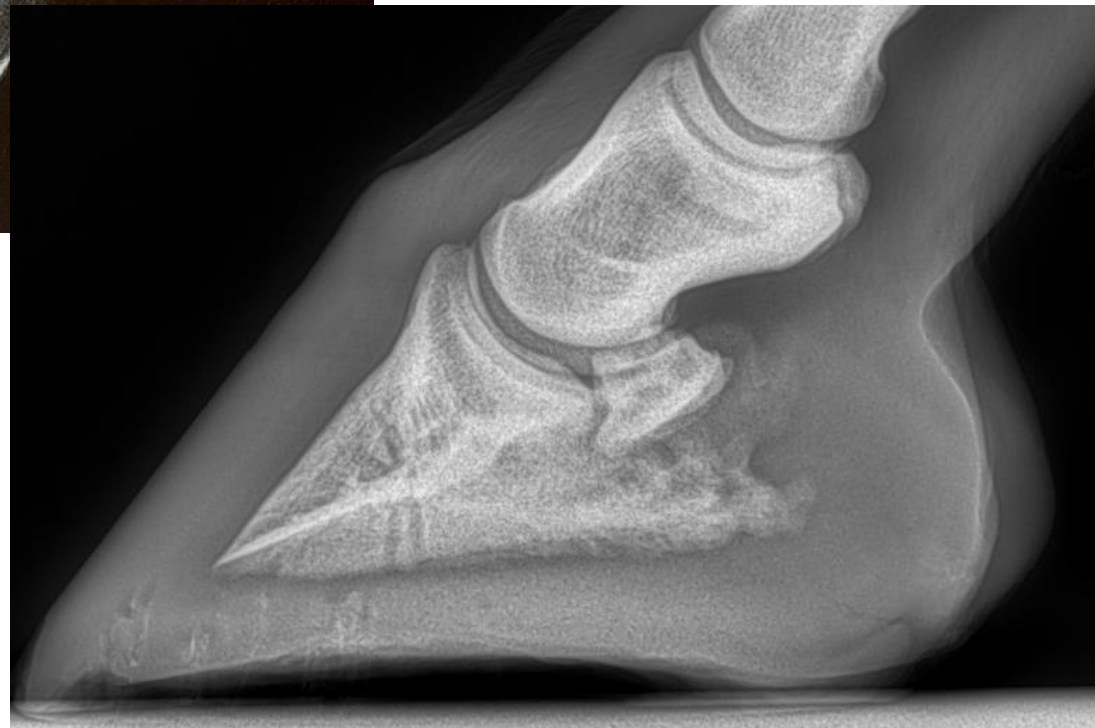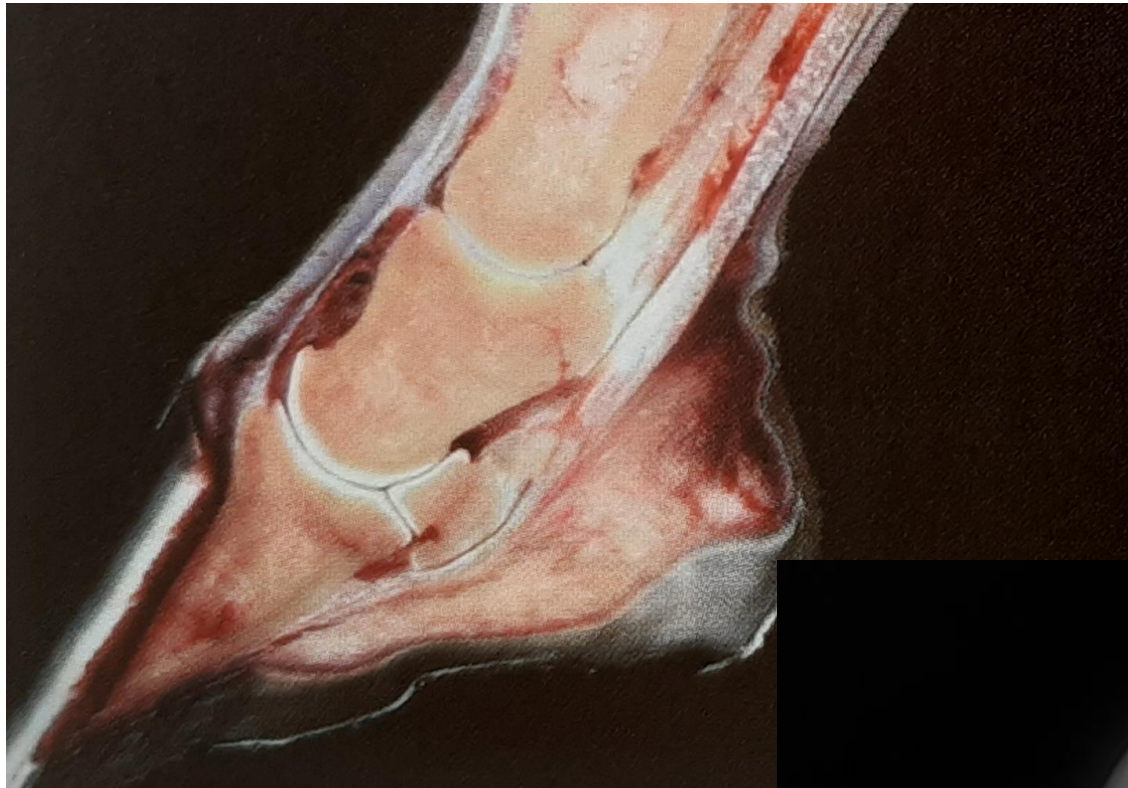CALCIFICAÇÃO DE CARTILAGEM ALAR

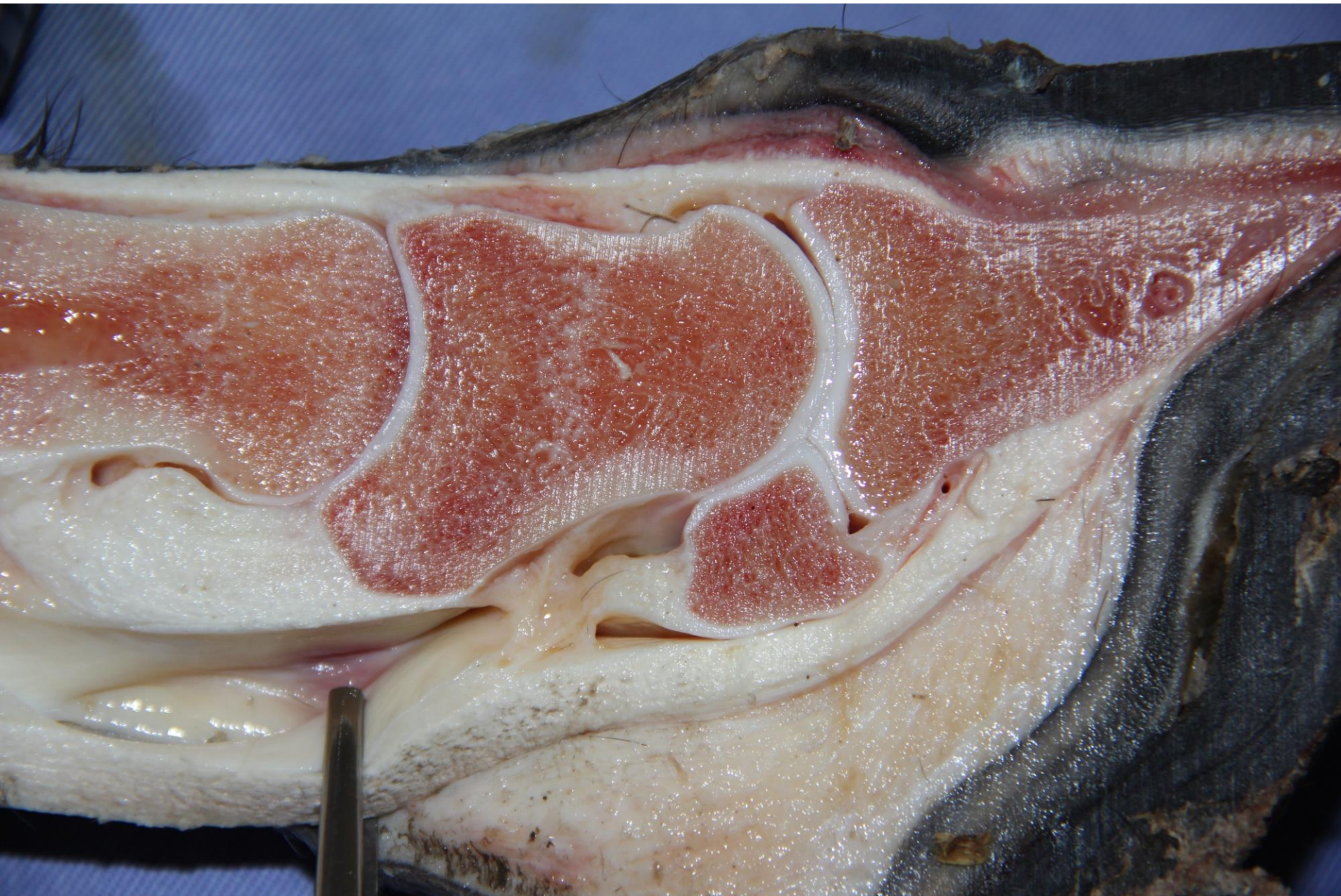

Perfurações

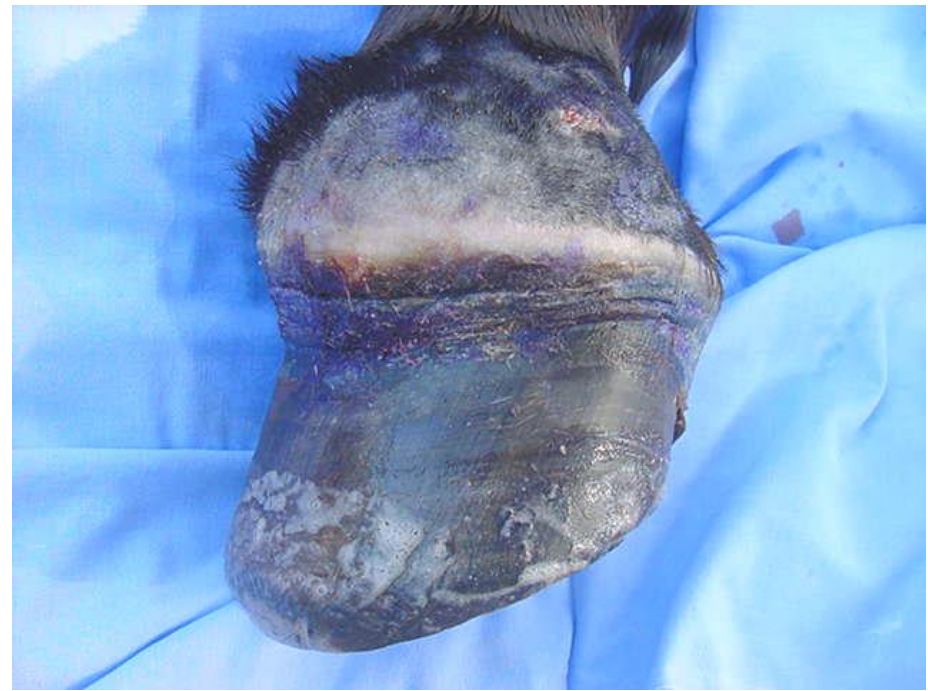
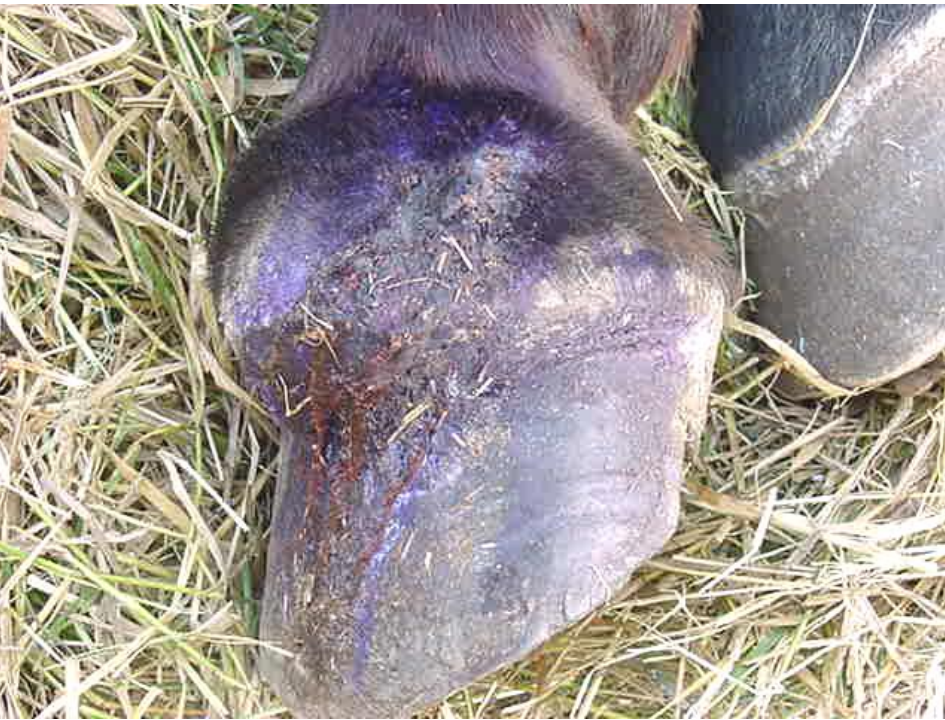
Essentials of clinical anatomy of the equine locomotor system, DENOIX. 2019

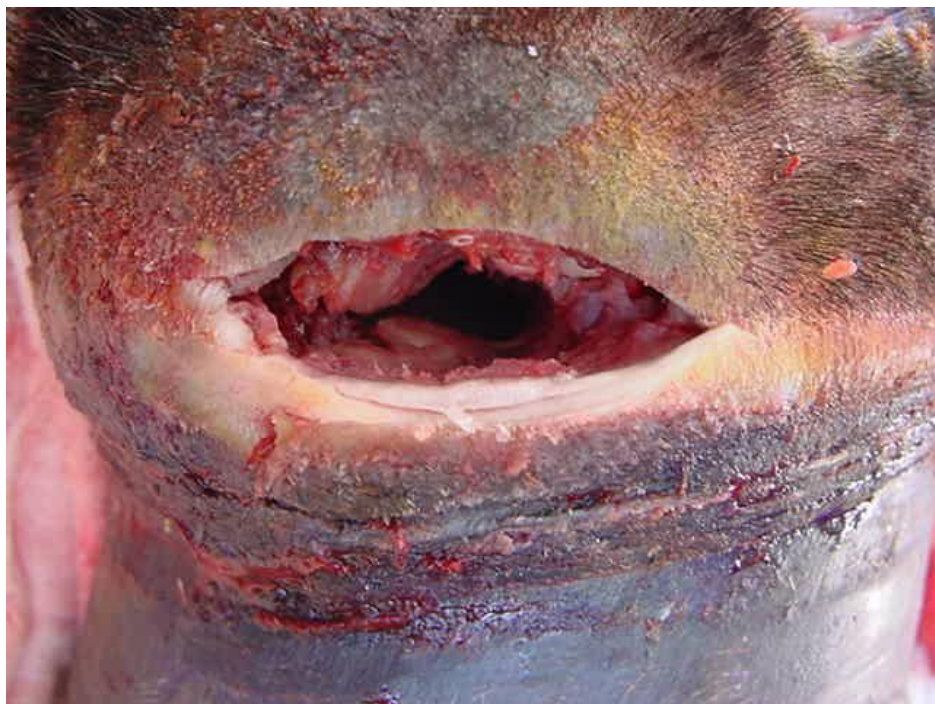


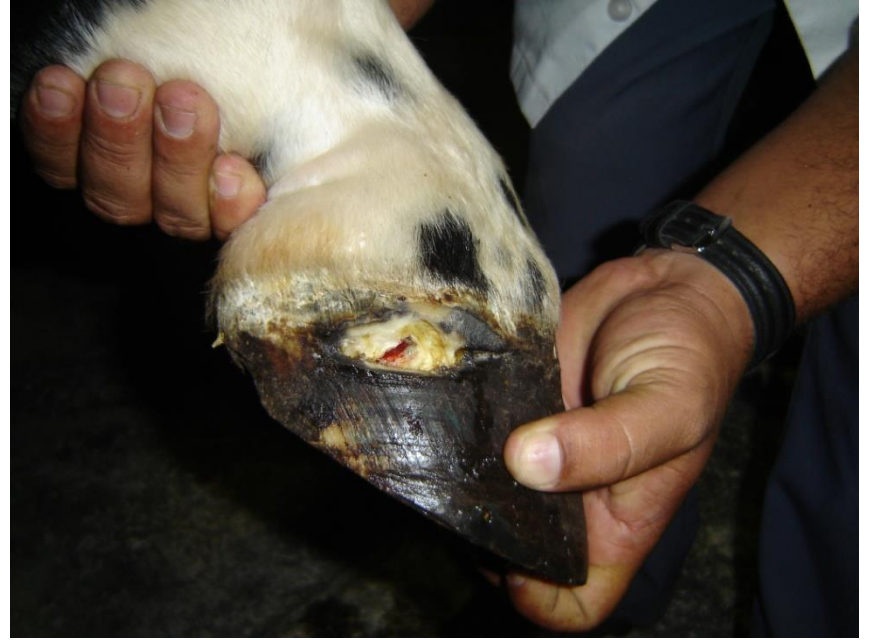
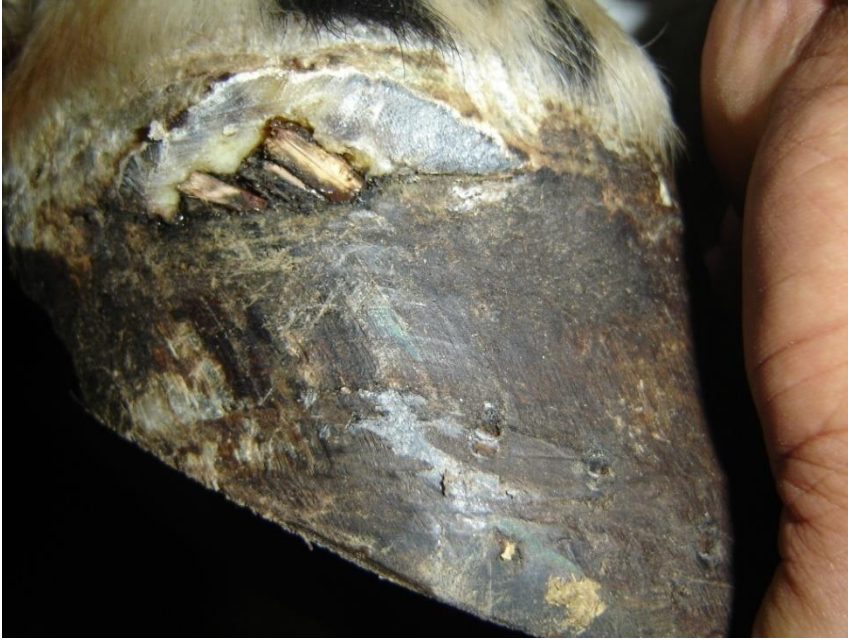Perfuração + fístula

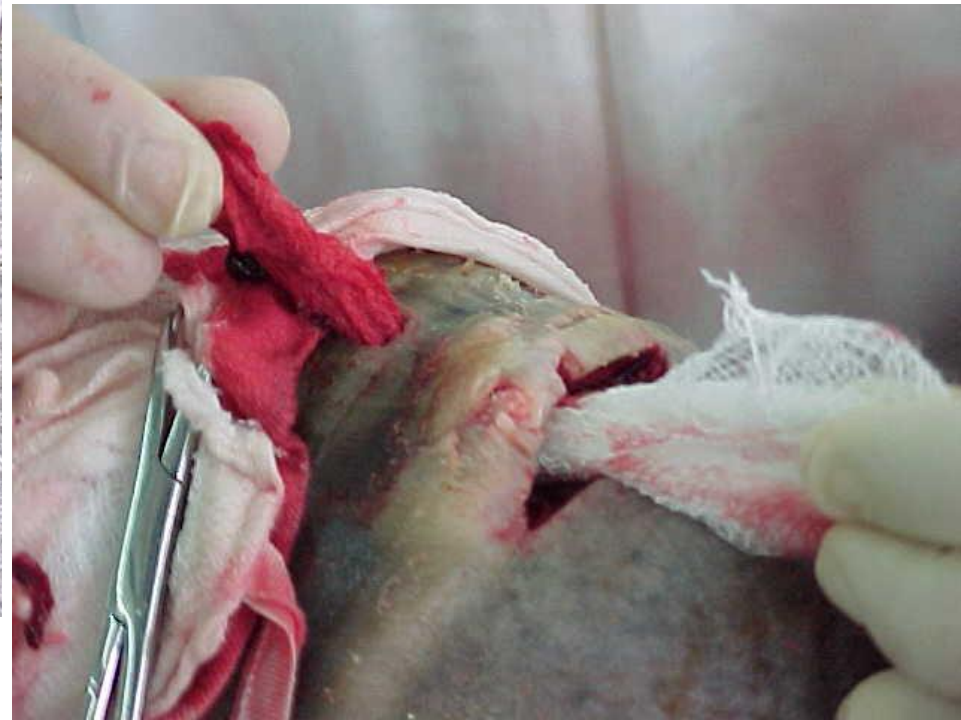
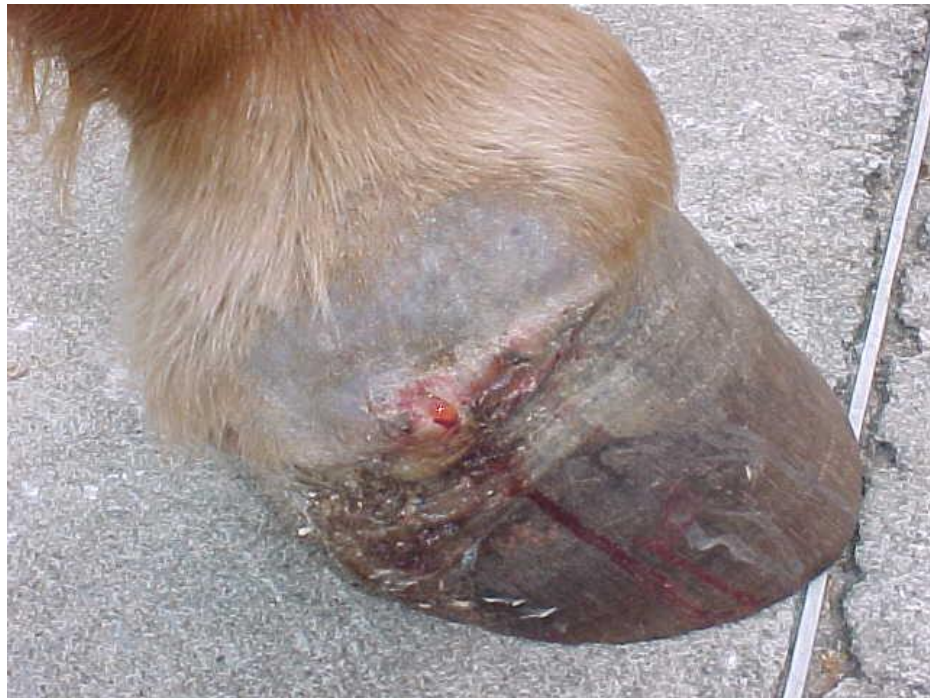
Perfuração + fístula

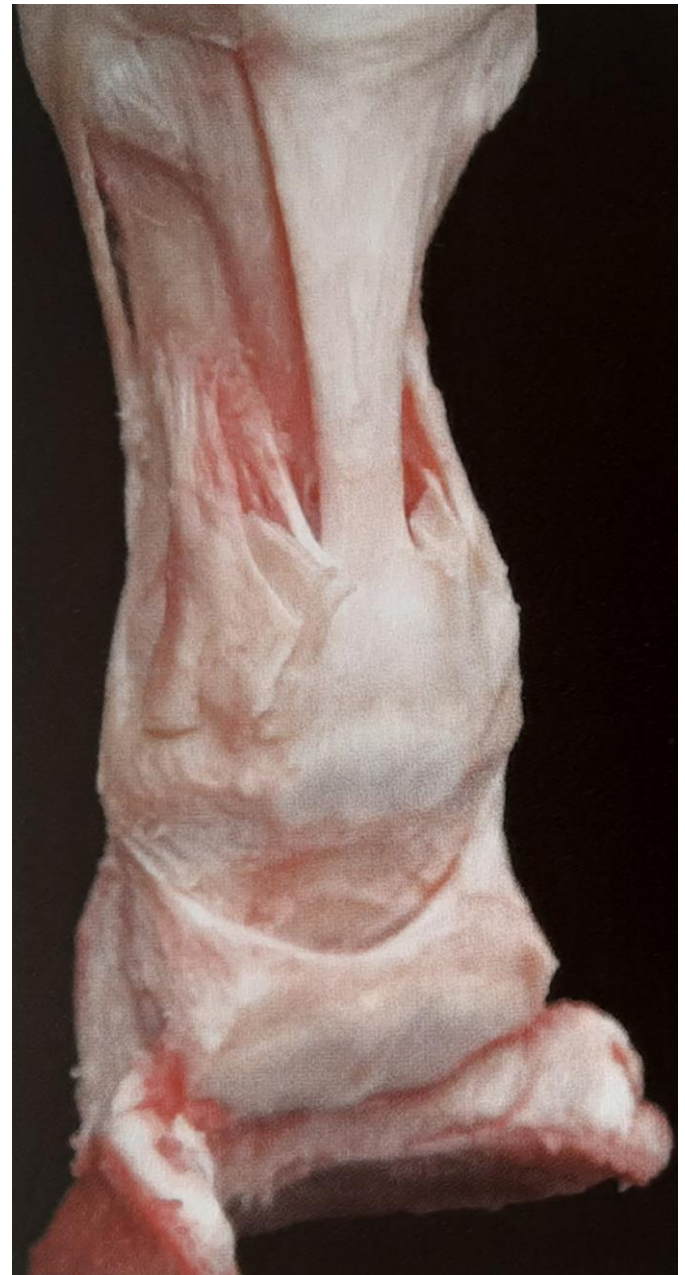
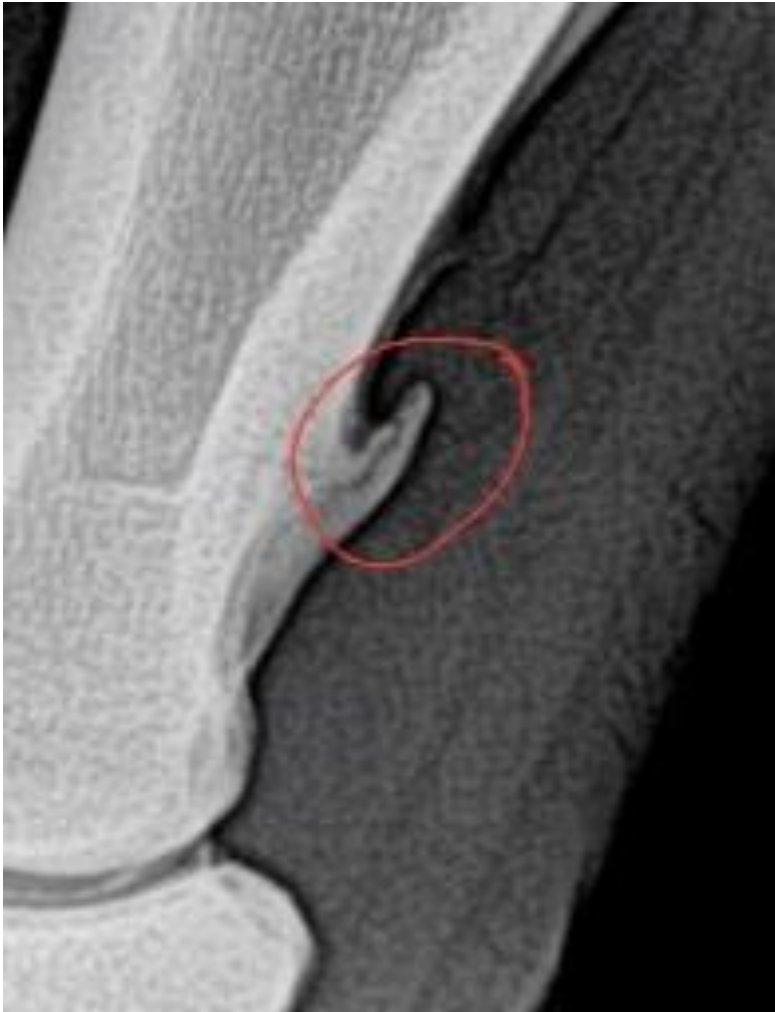


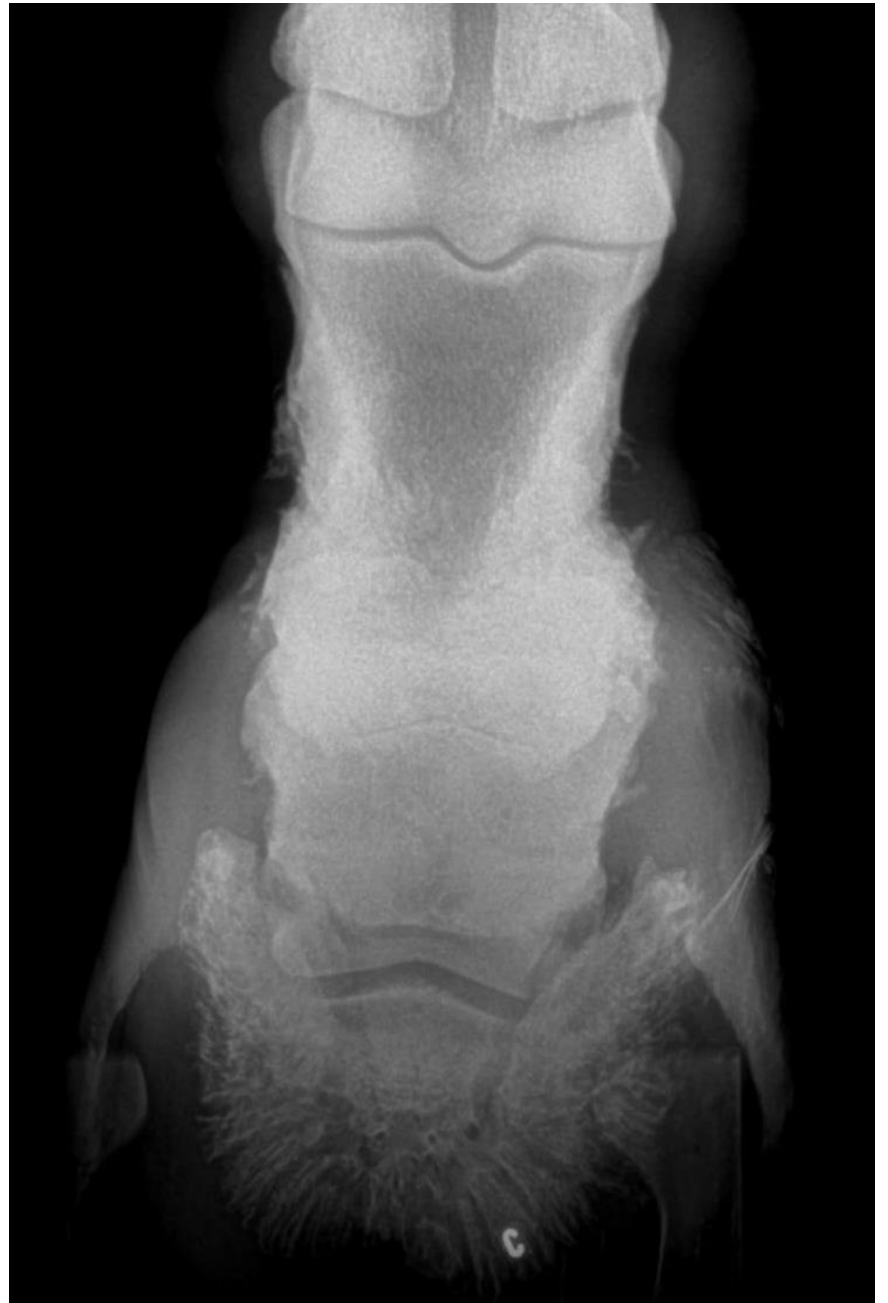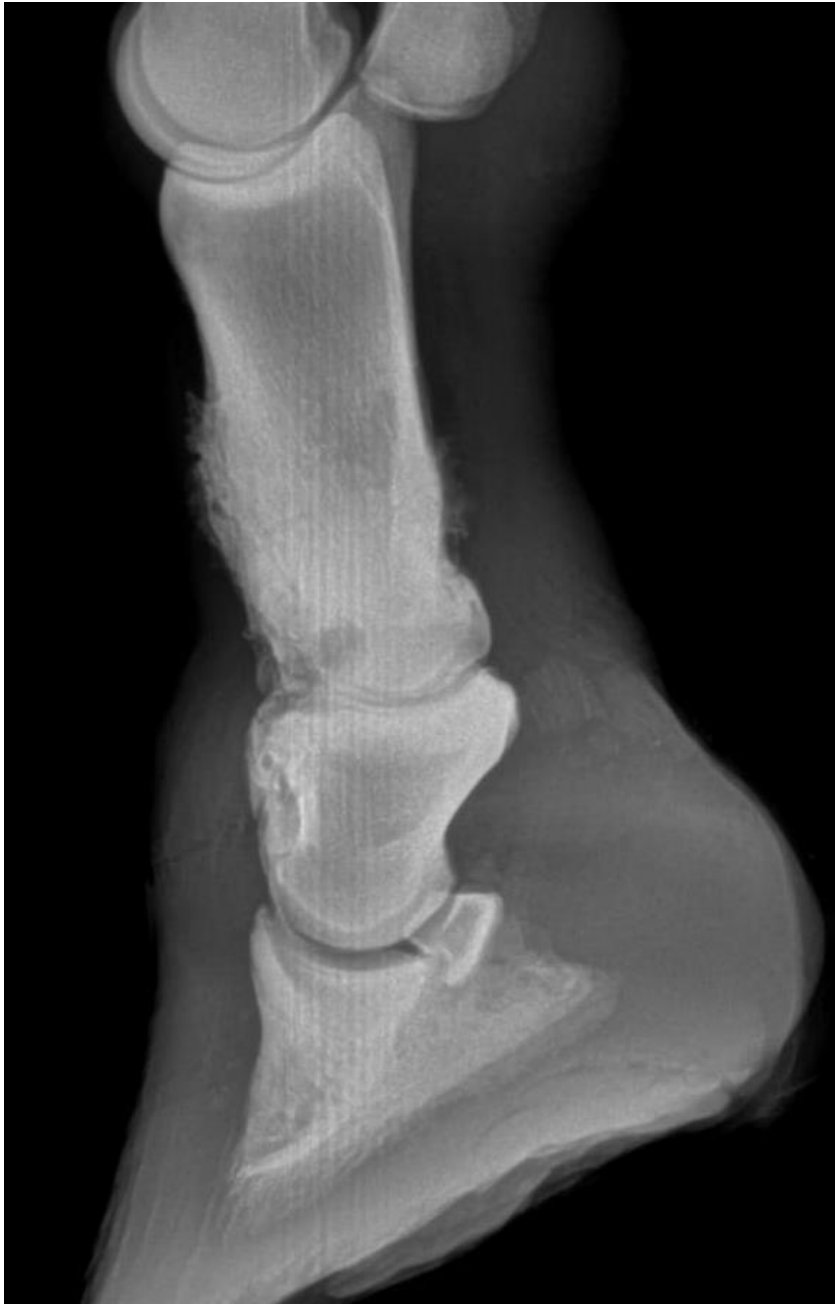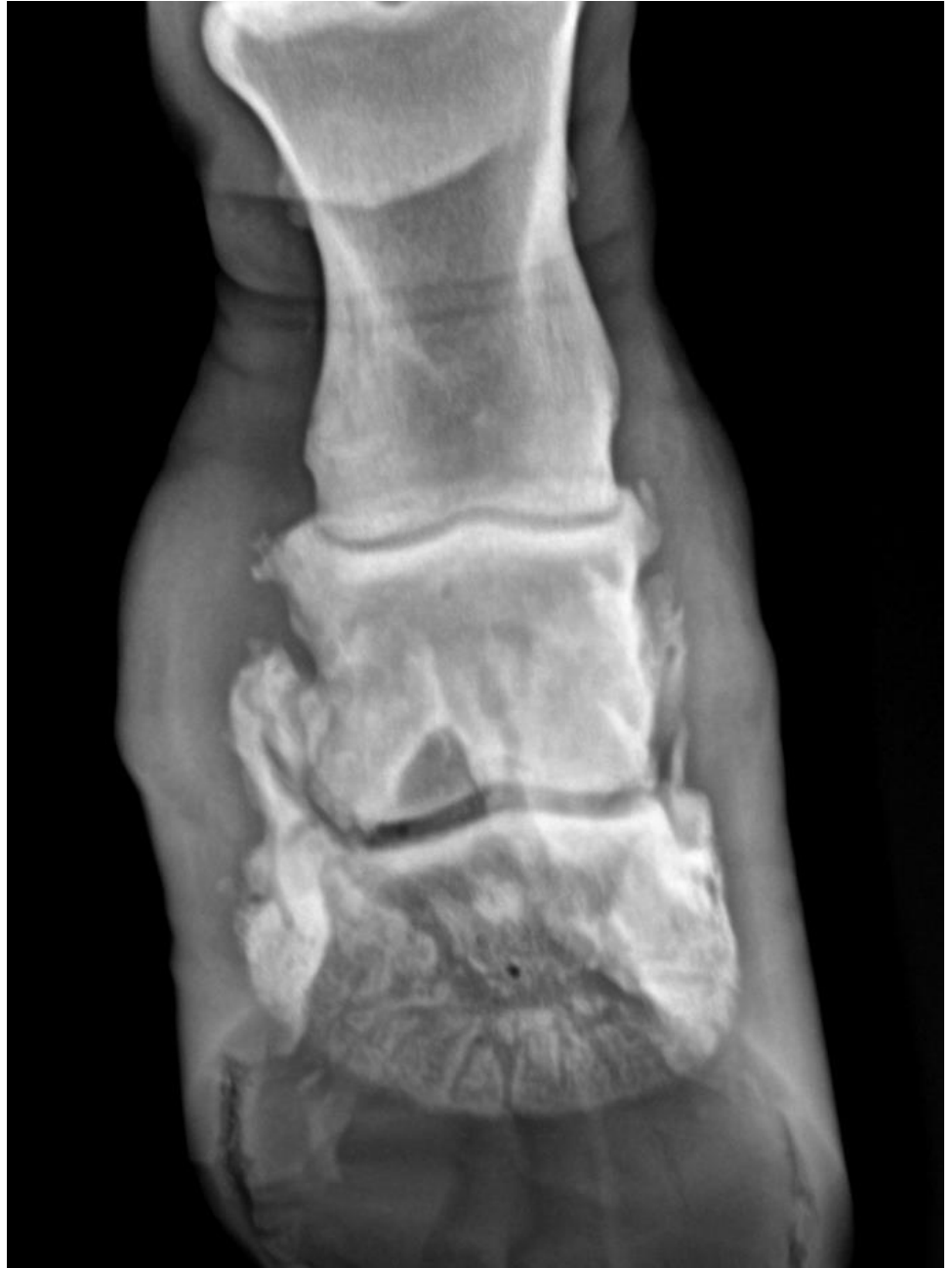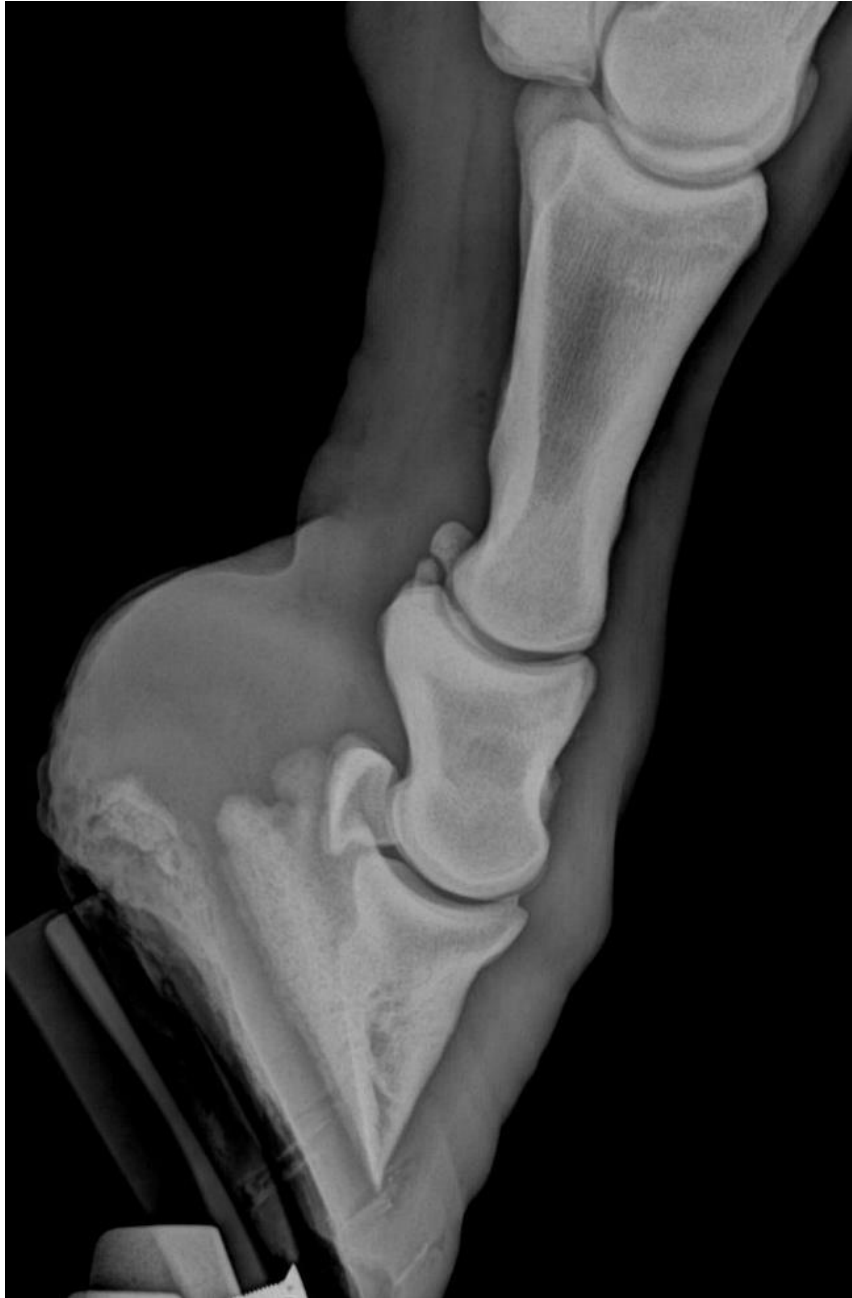Necrose de cartilagem - “quittor” -



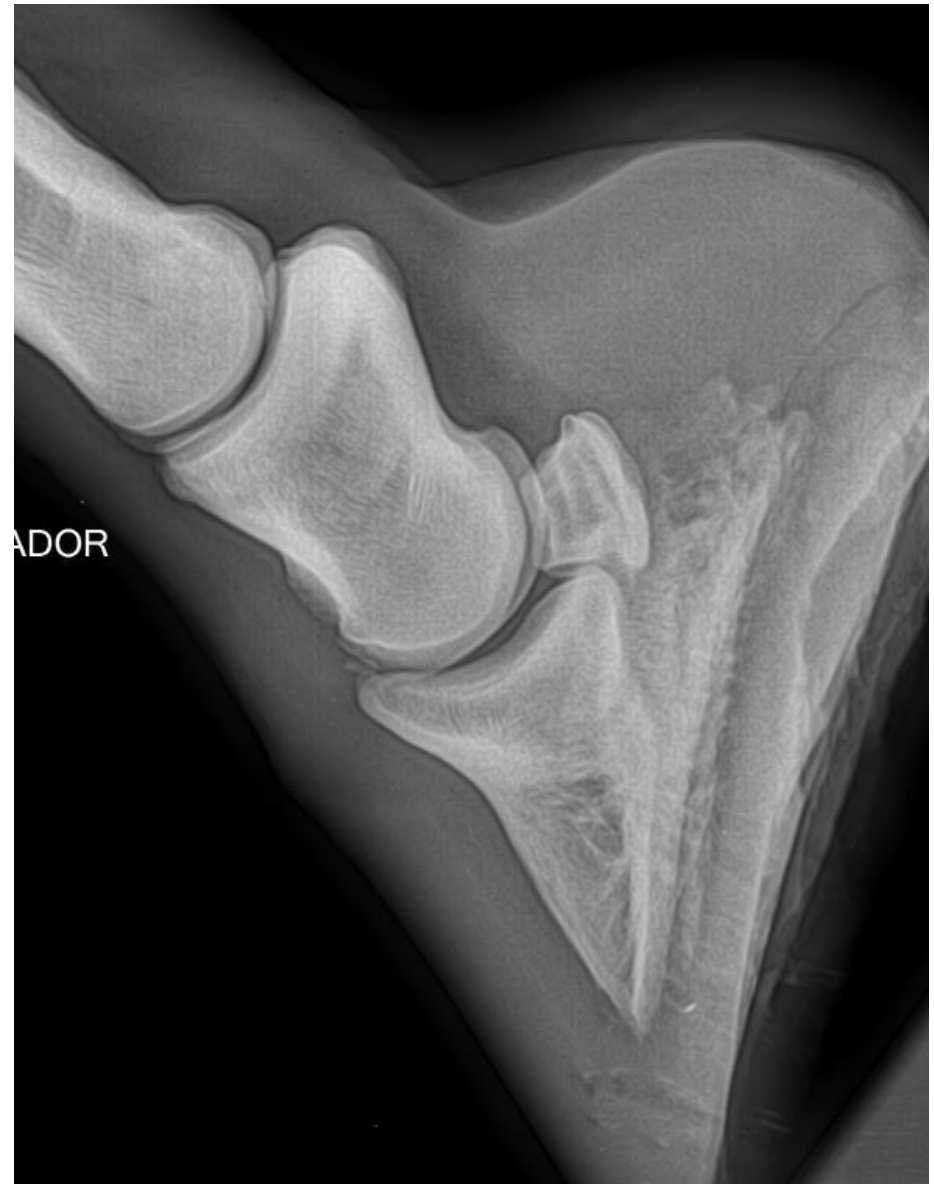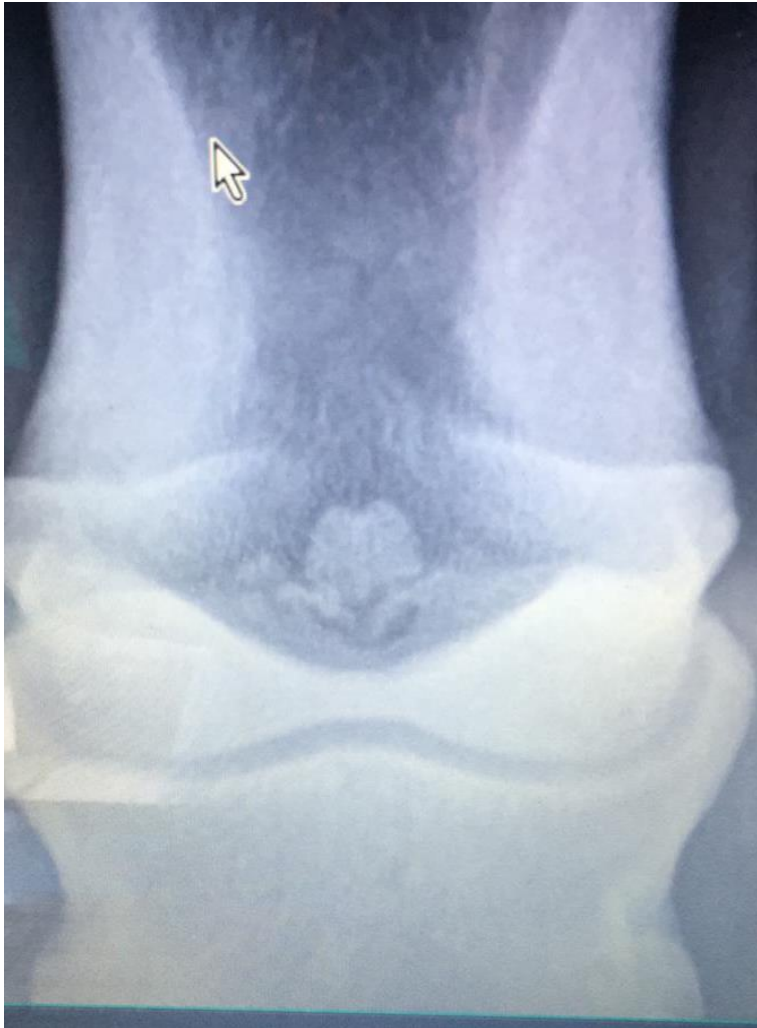Proliferações



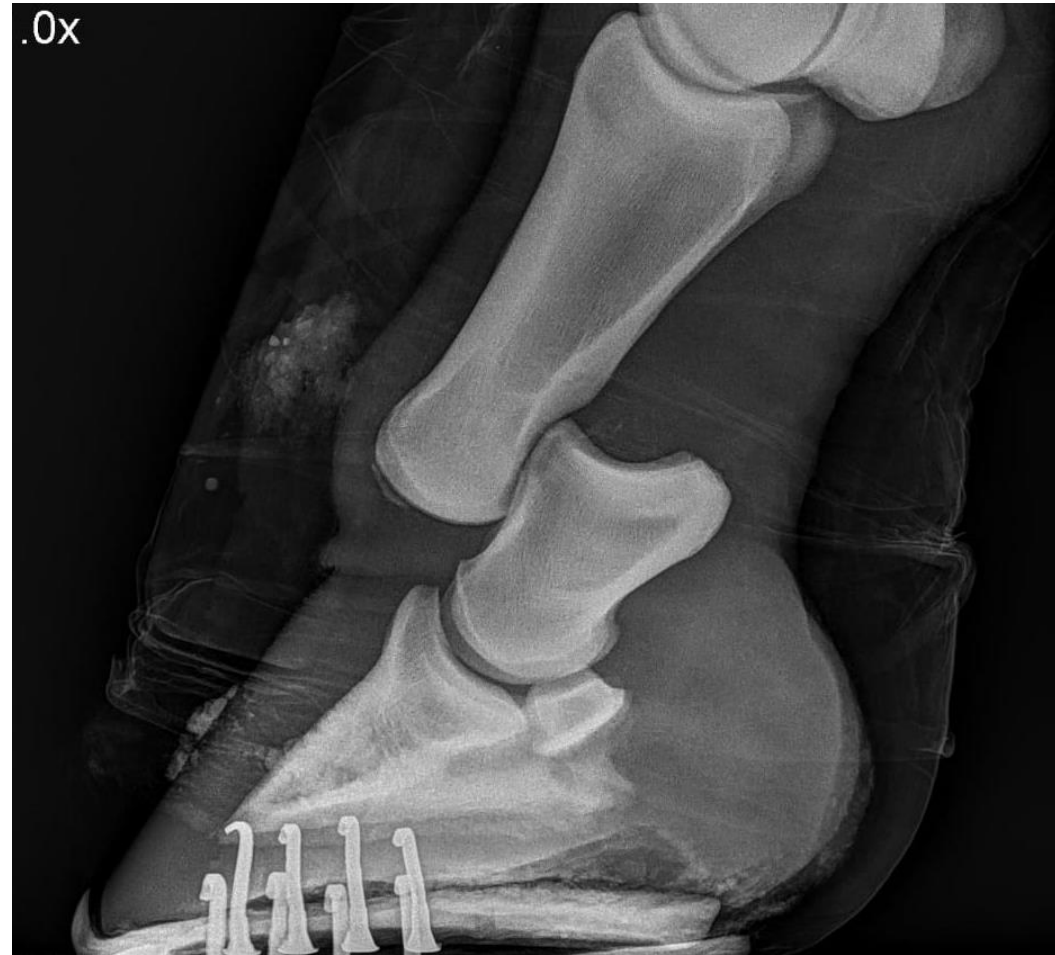
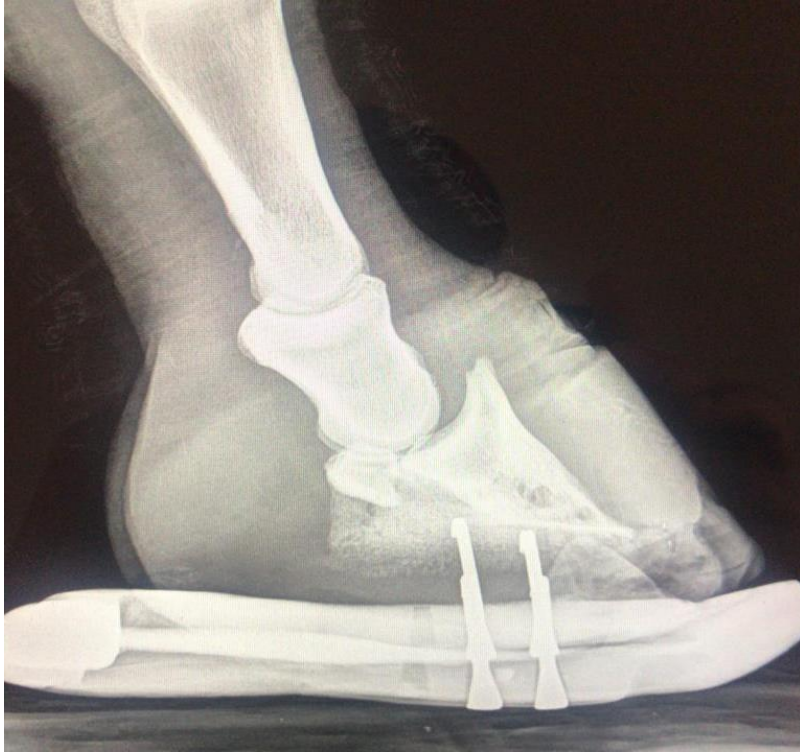


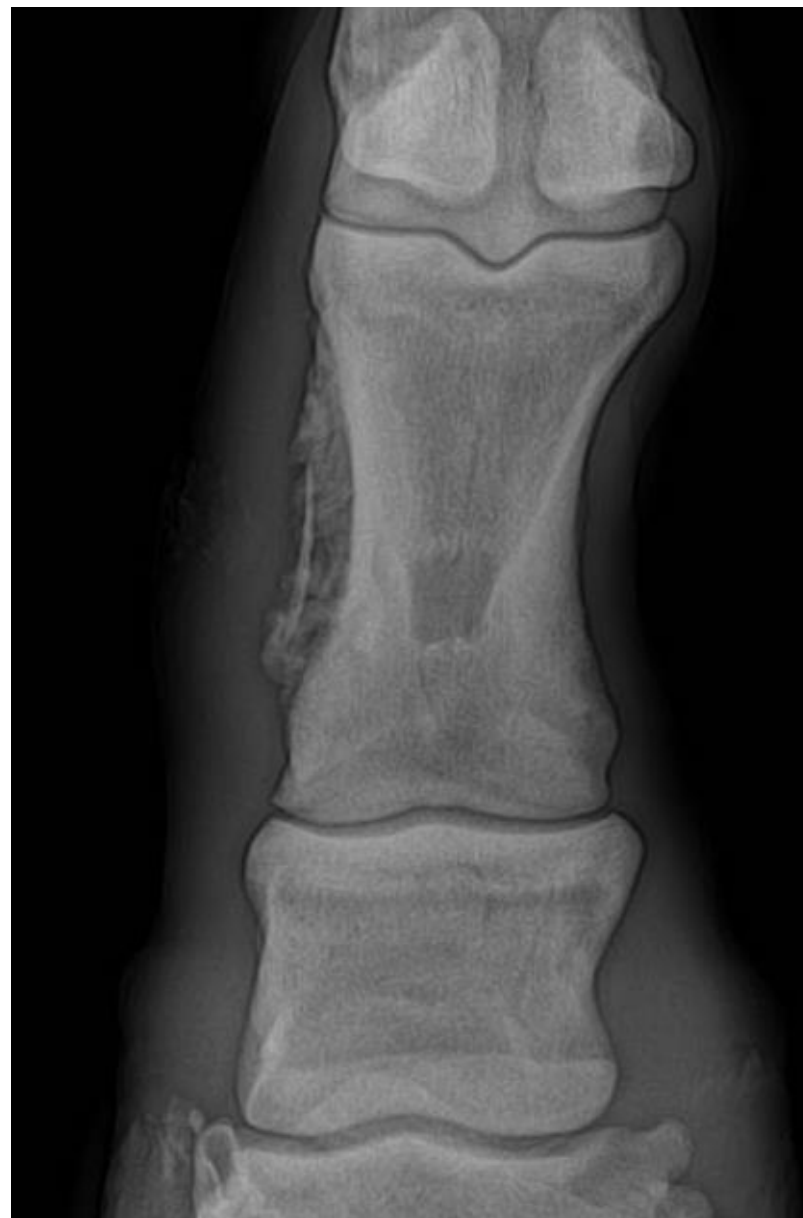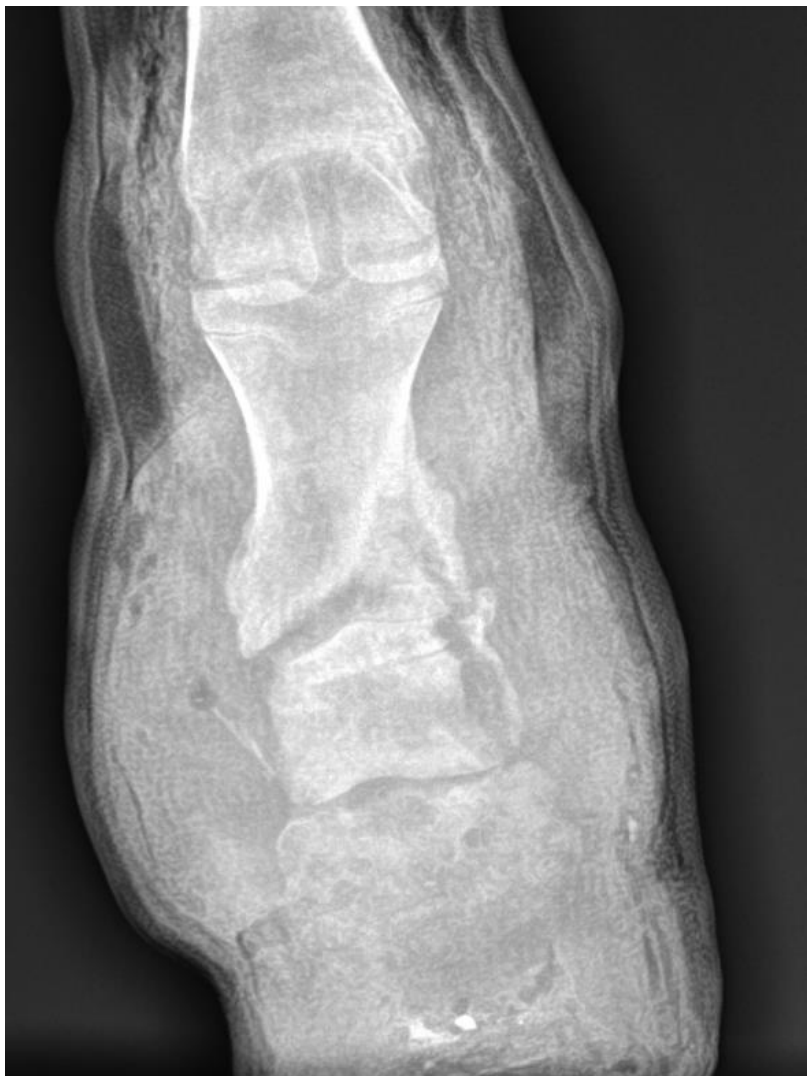Fragmentação



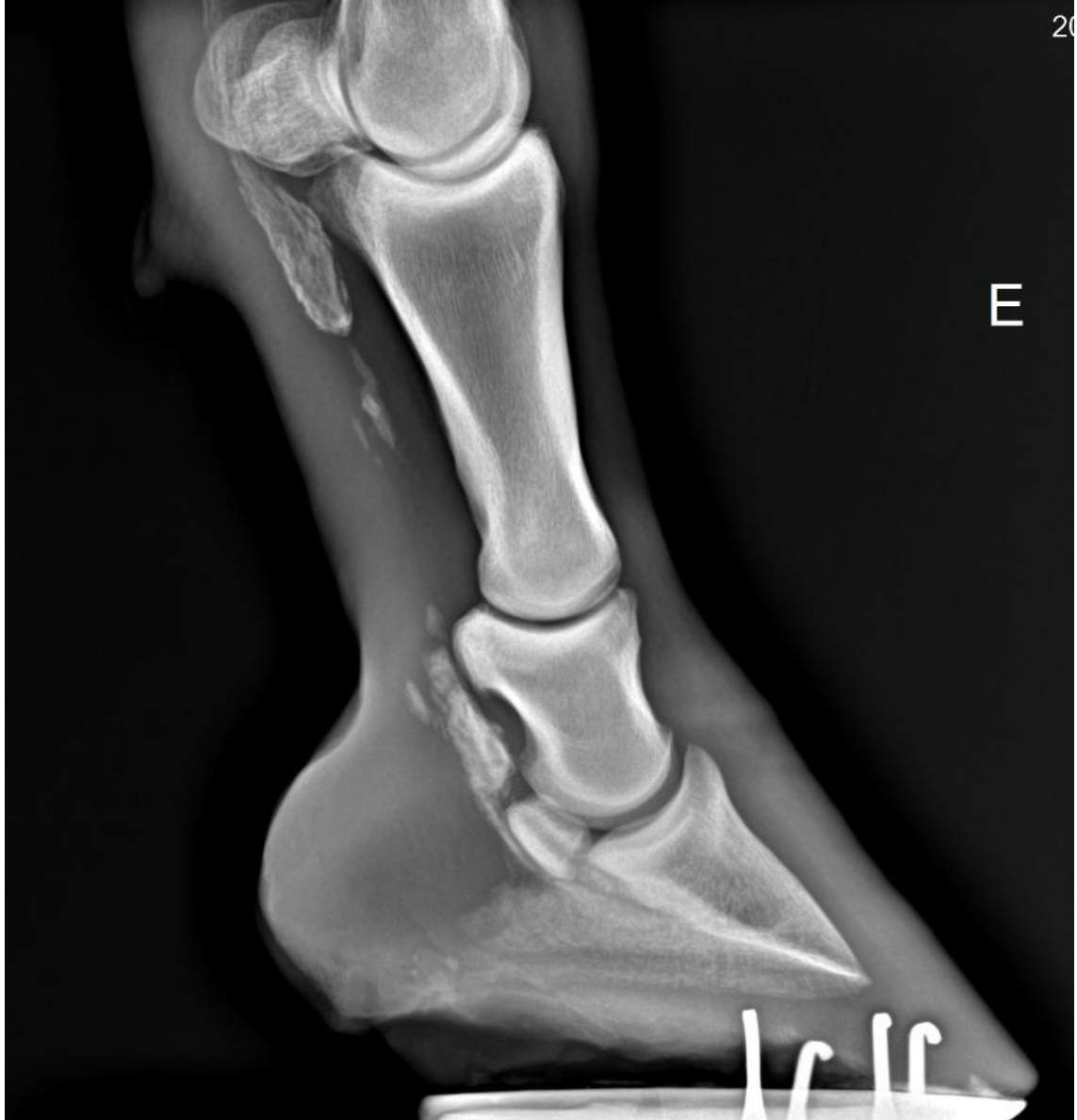Luxação



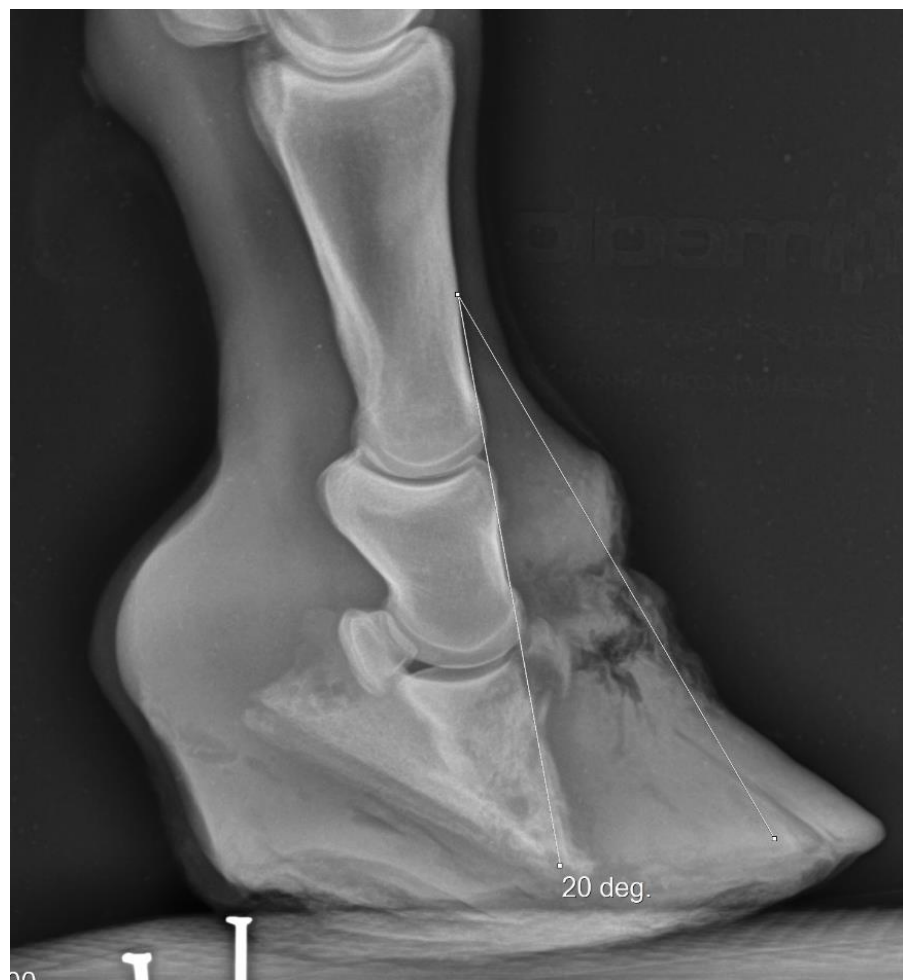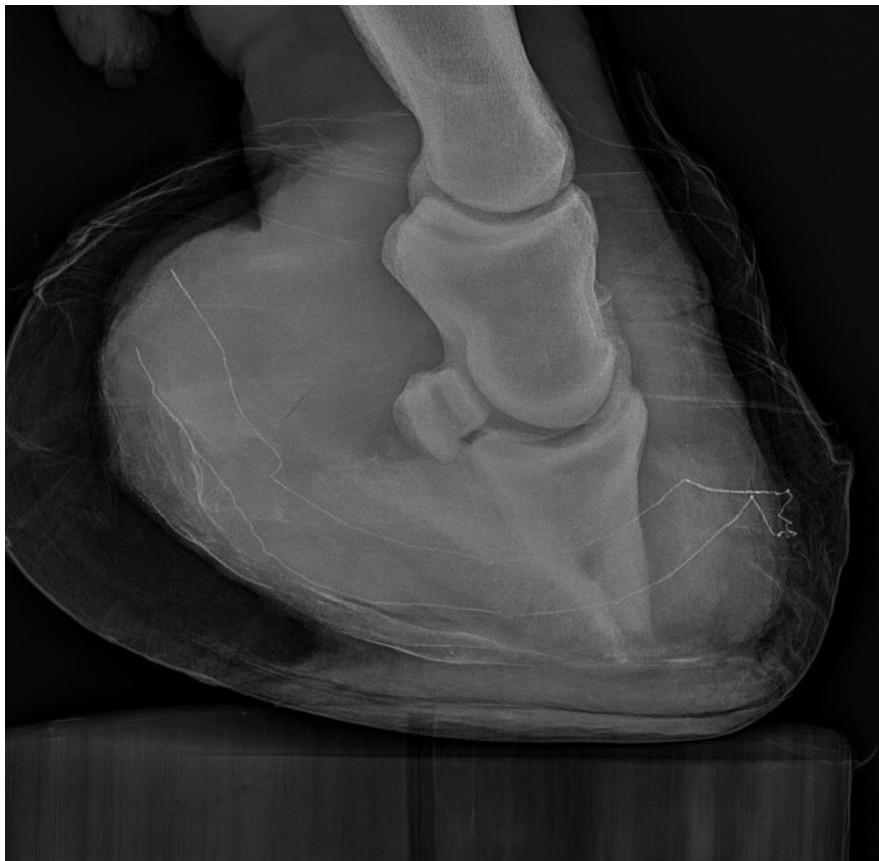Fratura



Calcificações



Rotação de 3ª falange



Cavaleiro do apocalipse, Honoré Fragonard
1766 a 1771

