Received: 18 August 2018 | Revised: 22 March 2019 | Accepted: 14 April 2019
DOI: 10.1111/vsu.13229

ORIGINAL ARTICLE – CLINICAL

WILEY

Long-term outcomes of 54 dogs with tracheal collapse treated with a continuous extraluminal tracheal prosthesis

Masahiro Suematsu DVM[1,4] | Hiroaki Suematsu DVM[1] | Tomomi Minamoto DVM, PhD[2] | Noboru Machida DVM, PhD[3] | Daiki Hirao DVM[1] | Makoto Fujiki DVM, PhD[4]

[1]AMC Suematsu Animal Hospital, Oita, Japan

[2]Evergreen Vet Research & Publication, Aichi, Japan

[3]Cooperative Department of Veterinary Medicine, Laboratory of Veterinary Clinical Oncology, Tokyo University of Agriculture and Technology, Tokyo, Japan

[4]Laboratory of Veterinary Surgery, Joint Faculty of Veterinary Medicine, Kagoshima University, Kagoshima, Japan

Correspondence
Masahiro Suematsu, AMC Suematsu Animal Hospital, 3-52 Nakajomachi, Hita, Oita Prefecture 877-0011, Japan.
Email: suematsu.hita@mac.com

Abstract

Objective: To describe the surgical placement of a continuous extraluminal tracheal prosthesis (CETP) and report the subsequent postoperative clinical outcomes in dogs with tracheal collapse.

Study design: Retrospective case series.

Animals: Fifty-four dogs.

Methods: Medical records of dogs in which cervical and/or thoracic inlet tracheal collapse was diagnosed and treated by placement of a CETP between 2010 and 2017 were reviewed to evaluate postoperative complications, changes in respiratory function, and survival. Histological examinations of tracheal tissues performed in 2 dogs at 51 and 57 months after surgery were also reviewed.

Results: Fifty-three (98%) dogs survived to discharge. Postoperative complications included laryngeal paralysis (1 dog), disseminated intravascular coagulation (1 dog), and recurrent tracheal collapse (2 dogs). None of the dogs exhibited clinical evidence of tracheal necrosis. Preoperative dry, harsh cough resolved in 87% of the dogs after surgery. Goose honking cough was resolved in 25 of 26 (96%) dogs. Median follow-up time was 30 months (range, 16 days to 76 months). The survival rate at 36 months was 86% (CI: 75%-96%). On histological examination in 2 dogs, the tracheal tissue surrounding the prosthesis was well preserved and without evidence of chronic inflammation.

Conclusion: Continuous extraluminal tracheal prosthesis placement in dogs with tracheal collapse resulted in low postoperative complication rates and good long-term outcomes.

Clinical significance: Continuous extraluminal tracheal prosthesis placement provides a viable alternative surgical option for managing dogs with tracheal collapse.

1 | INTRODUCTION

Tracheal collapse, a relatively common disease in dogs, results from dorsoventral flattening of the trachea due to widening of the trachealis muscle and weakening of the cartilaginous rings.[1,2] Clinical signs of tracheal collapse include respiratory signs, such as a dry, harsh cough and dyspnea,[2] which can lead to death

The content of this study was presented in part at the Japan Veterinary Small Animal Conference; October 14, 2012, October 13, 2013, October 4, 2014, and October 15, 2017; Kyusyu, Japan; conference of the Japanese Society of Veterinary Anesthesia and Surgery; December 9–10, 2017; Nagoya, Japan; and Conference of the Japanese Society of Veterinary Anesthesia and Surgery; June 15–17, 2018; Omiya, Japan.

from the resulting airway obstruction in severe, progressive cases. Medical management of respiratory signs includes administration of steroids and/or antibiotics, weight loss, and elimination of environmental triggers such as high temperature and irritating substances (eg, allergens or pollutants).[3]

Surgical intervention or stenting can be considered when severe clinical signs persist and dogs fail to respond to medical management. Several different procedures for the placement of an extraluminal prosthesis[4,5] or an intraluminal stent[6] have been reported. Recently, the placement of an intraluminal tracheal stent has been preferred because it is less invasive and the procedure time is shorter.[7] Postoperative complications associated with stent placement include intratracheal granuloma formation, stent fracture or migration, and inflammatory tracheitis.[8-10] Laryngeal paralysis is particularly problematic with extraluminal prosthesis and ring placement, occurring in 11%-21% of cases.[5,10-12] In addition, perioperative death has been reported in 4%-19% of cases after extraluminal ring and prosthesis placement. Consequently, an alternative procedure that provides better clinical outcomes and lower rates of postoperative complications is required. To address this, we previously developed the continuous extraluminal tracheal prosthesis (CETP), which is made of a commercially available polymer optical fiber (Figure 1). The inner layer of the fiber is polymethyl methacrylate, which has been used for medical devices such as microsensors as well as in drug delivery applications, bone cement, and denture base because of its biocompatibility, reliability, relative ease of manipulation, and low toxicity.[13,14] The outer fiber layer is fluorocarbon polymer, which has also used medically, including in artificial blood vessels and lungs.[15] The potential advantages of the CETP include ease of intraoperative adjustment, decreased chance for damage to the recurrent laryngeal nerve and segmental tracheal vessels, placement of the prosthesis to extend caudally as far as the second rib, and in situ flexibility of the prosthesis.

Between 2010 and 2017, CETP placement procedures were performed in 87 dogs that were deemed suitable candidates for the surgery. The objectives of the current study were to describe the surgical placement of the CETP and conduct a retrospective analysis of the prior surgical procedures to investigate the short- and long-term outcomes in dogs treated with a CETP. We hypothesized that the placement of a CETP would yield good clinical outcomes and be a suitable alternative procedure in dogs with tracheal collapse.

2 | MATERIALS AND METHODS

The medical records of all dogs diagnosed with tracheal collapse that underwent a CETP placement procedure between 2010 and 2017 were reviewed. Among the records reviewed, only dogs with radiographic evidence of a 100% reduction in the tracheal lumen at any point along the cervical trachea up to the thoracic inlet during both inspiratory and expiratory phases were included in this retrospective study.[16] Dogs were included only when their medical record included signalment, history, preoperative radiographic evaluation, and radiographic records from at least 1 week after surgery.

Demographic information including breed, age, body weight, and sex at the time of the surgery was obtained from the medical records. Data regarding perioperative and postoperative complications (eg, tracheal necrosis and laryngeal paralysis), progression or improvement of clinical signs associated with tracheal collapse after surgery (eg, dry, harsh cough and goose honking), medical management after surgery, and survival time after surgery were also collected.

2.1 | Diagnostic tests

Complete blood count, chemistry panel, and coagulation profile (ie, prothrombin time and activated partial thromboplastin time) were performed on all dogs as part of a routine presurgical screening procedure. In addition, cervical and thoracic radiographs during both inspiratory and expiratory phases and echocardiography were performed prior to surgery. The diameter of the cervical tracheal lumen during inhalation was compared to the diameter of the intrathoracic tracheal lumen during inhalation. The location of radiographic evidence of 100% collapse was categorized as cervical, thoracic inlet, or intrathoracic.

The dogs were considered candidates for the surgery because they had not responded to appropriate medical management (eg,

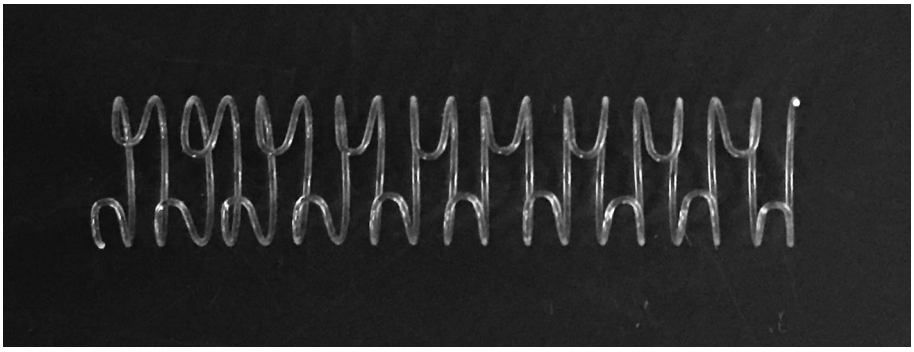

FIGURE 1 Continuous extraluminal tracheal prosthesis

antibiotics, steroids, antitussives, or bronchodilators) or their respiratory signs associated with tracheal collapse had worsened. Dogs with suspected/definitive laryngeal paralysis, chronic valvular heart disease stage C and D according to the American College of Veterinary Internal Medicine (ACVIM) consensus guideline,[17] and/or any condition that could confer a higher risk of perioperative complications associated with anesthesia and surgical intervention (eg, pulmonary disease, compromised liver or kidney function, or anemia) were considered unsuitable candidates for the surgery. Patients with concurrent malignant disease at the time of CETP placement were excluded from the retrospective study. During anesthesia induction, laryngeal function was evaluated by observing the movement of the arytenoid cartilage under spontaneous breathing before intubation. Only dogs with normal laryngeal function underwent the surgery.

2.2 | Informed client consent

As a routine precautionary practice, all owners of dogs that were deemed suitable candidates for a CETP placement were informed by their veterinarians of the risks associated with the surgical procedures, the materials used in the CETP, and any possible perioperative complications associated with the surgery. In addition, the veterinarians explained that the prosthesis was made by the first author (MS) at AMC Suematsu Animal Hospital and that the optical fiber used for the prosthesis was not specifically intended for medical implants. All owners provided consent to perform the procedure prior to surgery.

2.3 | Tracheal prosthesis

The CETP were prepared from a commercially available 0.75-mm-thick polymer optical fiber (Eska; Mitsubishi Chemical Holdings, Tokyo, Japan). After the cable had been softened by soaking in boiling water for a few seconds, the cable was placed on a spiral ring-shaped mold and maintained at −18°C for approximately 30 minutes. After the mold had been thawed at room temperature, the cable was removed from the mold and dried (Figure 1). Prostheses with 10-, 12-, and 15-mm diameters were prepared. The prostheses were sterilized in 10% ethylene oxide at 50°C for 24 hours.

2.4 | Preoperative care and anesthesia

Prednisolone (1 mg/kg subcutaneously) and piperacillin sodium (30 mg/kg IV) were administered 30 minutes before surgery. Midazolam (0.1 mg/kg IV) was used for preoperative sedation. Propofol (5 mg/kg IV) was infused to induce anesthesia to effect, and the dogs were intubated. Isoflurane inhalation was used to maintain a surgical plane of anesthesia. Fentanyl citrate (0.01 mg/kg IV continuous rate infusion [CRI]) was used as an analgesic during surgery. Lidocaine hydrochloride (0.5%, 2 mg/kg) was intraoperatively injected into the sternocephalic and sternohyoid muscles.

2.5 | Continuous extraluminal tracheal prosthesis placement surgery

All prior surgeries reviewed in this study were performed by the first author (MS). The cervical trachea was approached by a ventral midline incision from the larynx to the manubrium of the sternum. The connective tissues were circumferentially and continuously isolated from the trachea between the larynx and the second rib by using Potts-Smith forceps. Most of the segmental tracheal blood supply was preserved by isolating individual segmental vessels from the connective tissues of the trachea by blunt dissection with Potts-Smith forceps. The surgical technique used for blunt dissection was different from skeletonization, in which the segmental tracheal blood supply was completely dissected from the trachea.[7,18] Bipolar forceps were used to control bleeding, as required. The recurrent laryngeal nerves were visualized and isolated along with the surrounding tissue from the trachea between the larynx and the second rib. Gelpi retractors were used at the cranial and caudal ends of the surgical incision. The trachea was elevated using Satinsky forceps (Figure 2). Supporting Information Video Clips 1–3 provide an outline of the surgical procedure.

2.6 | Prosthesis sizing

Prior to surgery, the length of the prosthesis was estimated by measuring the distance from the larynx to the second rib on a radiograph. During intubation, the distal end of the endotracheal tube was inserted beyond the thoracic inlet and situated at the level of the intrathoracic area. The prosthesis was selected intraoperatively from 3 different diameters (10, 12, or 15 mm) on the basis of fit to the intubated trachea under spontaneous breathing or artificial respiration. The diameter was considered optimal when the prosthesis was slightly larger than the trachea. When a prosthesis was slightly loose, it was tightened with DeBakey forceps.

2.7 | Placement of the prosthesis

The CETP was composed of a single fiber and placed between the segmental vessels (Figure 3). Each loop of the prosthesis was placed around the ventral side of each tracheal ring (Figure 4). Polypropylene suture (5-0) was used to suture the prosthesis to the trachea. Partial-thickness sutures were used so that the tracheal lumen would not be penetrated. The loops of the prosthesis were first sutured on the ventral side of the trachea from the most cranial aspect to as far as the second rib (Figure 5, position 1 and 2). The prosthesis was then sutured with 1 knot on both sides of each tracheal ring between the

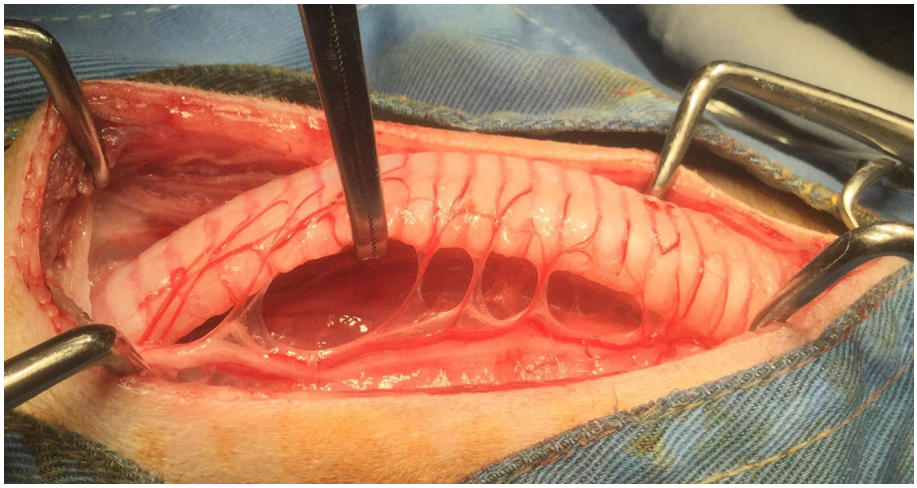

FIGURE 2 The trachea was elevated by using blood vessel clamp Satinsky forceps. The individual tracheal segmental vessels were isolated from the connective tissues between the larynx and the second rib by blunt dissection

tracheal cartilage and trachealis muscle (Figure 5, position 3 and 4). The tails of the sutures (Figure 5, position 3 and 4) were kept long and used as stay sutures. Finally, the trachea was rotated by lifting the stay sutures, and the prosthesis was sutured to the dorsal wall by placing 3 knots at equal intervals (Figure 5, position 5, 6, and 7). The prosthesis was placed below the thyroid cartilage to the thoracic inlet, extending as far as the second rib. The diameter and length of the prosthesis was easily adjusted during surgery; a slightly loose prosthesis was tightened with DeBakey forceps, and any excess length was removed with operating scissors. The trachea was tested for leaks after placement of the prosthesis. The cuff was deflated, and the trachea was submerged and observed for air bubbles during several breath cycles. At the end of surgery, tracheobronchoscopy, fluoroscopy, or radiography was performed to confirm that the tracheal collapse was entirely corrected. After surgery, the dog was extubated, and arytenoid movement was observed under spontaneous breathing prior to recovering the dog.

2.8 | Postoperative care

Fentanyl citrate (0.003 mg/kg CRI) was administered for 2 days after surgery. Prednisolone (0.5 mg/kg subcutaneously once daily) and piperacillin sodium (30 mg/kg IV twice daily) were administered for 5 days after surgery. Regardless of respiratory condition after surgery, the dogs were hospitalized in an oxygen chamber with 0.4 FiO_2. If no respiratory signs were observed, FiO_2 was gradually reduced to 0.35 after 2 days, and 0.3 after 3 days. The duration of hospitalization ranged from 5 to 7 days. After discharge, prednisolone (0.3 mg/kg orally once daily) was prescribed for 7 days.

2.9 | Postoperative and short-term (<4 weeks) follow-up

Dogs were observed daily during the hospital stay for labored inspiratory breathing and voice changes to monitor for the development of laryngeal paralysis and were observed daily for frequent cough and cervical subcutaneous emphysema to monitor for the development of tracheal necrosis. Cervicothoracic radiography was performed in all dogs 1 week after surgery. Follow-up examinations at 2 and 4 weeks after surgery were recommended. During the follow-up appointments, physical examination, history, and indirect evaluation of laryngeal function were conducted. Laryngeal function was assessed by evaluating the presence or absence of labored inspiratory breathing and changes in voice. In addition, potential tracheal necrosis was evaluated by the presence or absence of frequent cough and cervical subcutaneous emphysema. Cervicothoracic radiography was performed when possible.

2.10 | Long-term follow-up

The dogs were brought to AMC Suematsu Animal Hospital between November 2017 and December 2017 to conduct long-term assessment. For dogs that were not brought to the clinic for their follow-up appointment, either the referring veterinarian or the owner was contacted by phone, e-mail, or letter. The long-term assessment consisted of the same evaluations as the short-term follow-up examinations. Owners and referring veterinarians were asked to provide information regarding (1) the presence of postoperative complications (eg, laryngeal paralysis and tracheal necrosis), (2) clinical signs associated with tracheal collapse, (3) history of medical management after surgery, (4) survival time, and (5) cause of death if the dog had died.

2.11 | Histological examination

We performed necropsies on 2 dogs that had undergone a CETP placement and died of disease unrelated to tracheal collapse (ie, abdominal tumor and congestive heart failure) after 51 and 57 months. Neither dog had developed postoperative complications related to the CETP placement. The tracheas of the 2 dogs were harvested and fixed with



FIGURE 3 Image illustrates the continuous extraluminal tracheal prosthesis placed around the collapsed trachea. The segmental vessels are indicated in red. The recurrent laryngeal nerves are indicated in yellow

FIGURE 4 Positioning of the continuous extraluminal tracheal prosthesis around the trachea. The image illustrates the ventral side of the trachea, around which each loop was placed

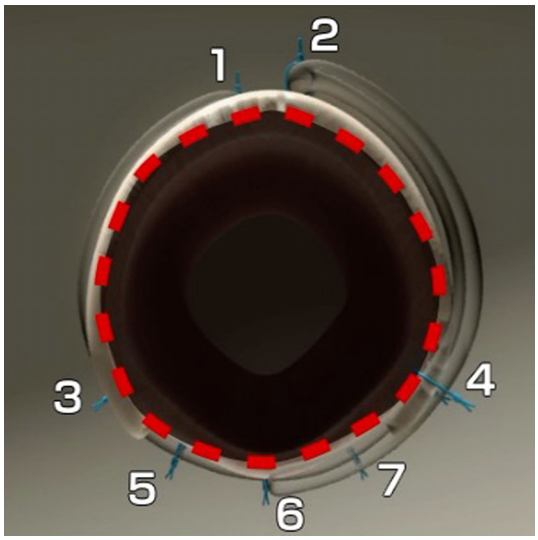

FIGURE 5 Suturing order (position 1–7) for placing the continuous extraluminal tracheal prosthesis around the trachea

formalin for histological examination. After fixation, the prostheses were removed from the trachea, and the tissue was sliced into five or six 3-mm sections. The slices were mounted onto slides, stained with hematoxylin and eosin and elastica-van Gieson stain, and examined by a pathologist.

2.12 | Statistical analysis

Statistical analyses were performed to investigate differences in the diameter of the prosthesis based on the dogs' weights and thoracic inlet diameters, as measured by radiography. Normality in the distribution of the data was assessed by visual inspection and a Shapiro–Wilk test. Nonparametric Wilcoxon signed-rank test and Dunn's multiple-comparison test (post hoc test) were performed when appropriate. Significance was set at $P < .05$. Kaplan–Meier estimate analysis was used to generate a survival curve and to calculate survival rates at 12, 24, and 36 months.

3 | RESULTS

3.1 | Signalment

The initial records review resulted in the identification of 63 dogs that had undergone a CETP placement between 2010-2017. Nine dogs were excluded from the study because of concurrent neoplastic diseases (n = 4), or incomplete medical history (n = 5). The remaining 54 dogs were included in the study. Breeds included Yorkshire terrier (n = 14), Chihuahua (n = 8), toy poodle (n = 9), Pomeranian (n = 9), shiba inu (n = 6), mix breed (n = 3), Maltese (n = 2),

miniature schnauzer (n = 2), and papillon (n = 1). Average age (±SD) at the time of surgery was 7 years (±3), and average body weight (±SD) was 4.4 kg (± 2.0). Sexes included intact male (n = 23), neutered male (n = 9), intact female (n = 12), and spayed female (n = 10). All 54 dogs exhibited clinical signs attributable to the presence of tracheal collapse. Clinical signs before surgery included dry, harsh cough (45 dogs, 83%), labored breathing (22 dogs, 41%), goose honking (26 dogs, 48%), and respiratory arrest (1 dog, 2%). Dogs with cough were treated with a combination of antibiotics, steroids, antitussives, or bronchodilator. However, the cough persisted or worsened in these dogs prior to surgery. Radiographic evaluation revealed that 26 (48%) dogs had 100% collapse in both the cervical and thoracic inlet areas. Among the 26 dogs, 1 also had 100% intrathoracic collapse. Eighteen (33%) dogs had 100% cervical collapse alone, and 10 (20%) dogs had 100% thoracic inlet tracheal collapse alone.

3.2 | Continuous extraluminal tracheal prosthesis

We placed prostheses of 10 mm in 14 dogs, 12 mm in 28 dogs, and 15 mm in 12 dogs. The dogs that received 15-mm prostheses weighed more (median [minimum-maximum (min-max)] 7.2 [5.1-13] kg) than the dogs that received 10-mm (3.3 [2-6] kg; $P < .001$) or 12-mm (3.7 [2.6-5.1] kg; $P < .001$) prostheses. No difference in the weight of dogs that received a 10-mm or 12-mm prostheses was detected ($P = .07$). The thoracic inlet diameters in dogs that received 15-mm prostheses (median [min-max] 48.3 [37.8-56.4] mm) were larger than in the dogs that received 10-mm (31.3 [26.2-40] mm; $P < .001$) or 12-mm prostheses (31.2 [25.3-45.3] mm; $P < .001$). No difference was detected between the thoracic inlet diameters in dogs that received 10-mm and 12-mm prostheses ($P = .57$).

3.3 | Postoperative complications

No dogs died during surgery. The duration of the surgeries ranged from 120-150 minutes. Examination of the preoperative radiographs revealed 100% tracheal collapse anywhere between the cervical region and the thoracic inlet. Conversely, examination of the radiographs acquired 1 week after surgery revealed that the trachea was expanded between the larynx and the second rib in all dogs (Figure 6).

The median follow-up time was 30 months (range, 16 days to 76 months). Because less than 50% of the dogs had died by the end of the follow-up period, we report survival rates instead of median survival time. The survival rates at 12, 24, and 36 months were 96% (CI: 91%-100%), 86% (CI: 75%-96%), and 86% (CI: 75%-96%), respectively (Figure 7).

Fifty-three (98%) dogs were discharged after 5–7 days of hospitalization. After 16 days, 1 dog died of disseminated intravascular coagulation (DIC) in the hospital after the development of acute pancreatitis and acute kidney failure. Postoperative tracheobronchoscopy of this dog revealed that the tracheal lumen was expanded between the cranial cervical area and the thoracic inlet. Postoperative respiratory conditions were recorded as stable in all dogs (eg, absence of inspiratory labored breathing). One of the 54 (2%) dogs developed severe respiratory stridor 12 days after surgery. The dog underwent a laryngeal examination under propofol, which revealed laryngeal paralysis. Consequently, a left-sided unilateral arytenoid lateralization was performed 15 days after surgery. The dog was still alive after 72 months, at the time of data collection.

Goose honking cough was resolved in 25 of 26 (96%) dogs. Presence of a dry, harsh cough was not completely resolved in 6 of 45 (13%) dogs after surgery. Medical management was required at some point for all 6 of the dogs with a persistent dry, harsh cough, and 2 of the 6 dogs experienced recurrent tracheal collapse. One dog developed recurrence of coughing 2 months after surgery. A subsequent radiographic

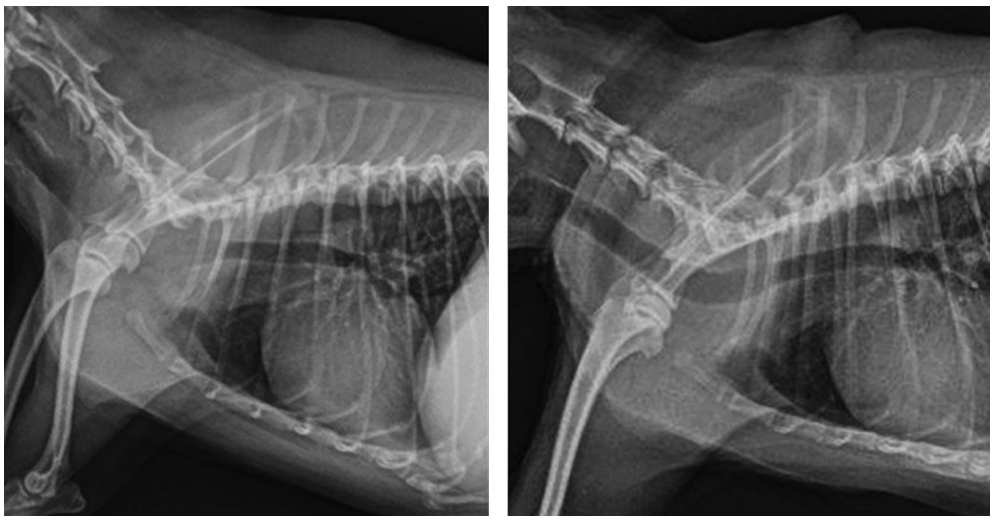

FIGURE 6 Preoperative (image at left) and 1-week postoperative (image at right) cervicothoracic radiographs in a dog with tracheal collapse treated with continuous extraluminal tracheal prosthesis. The 100% tracheal collapse between the cervical region and the thoracic inlet was apparent on the preoperative radiograph (left), whereas the expanded trachea between the larynx and the second rib was apparent on the postoperative radiograph (right)

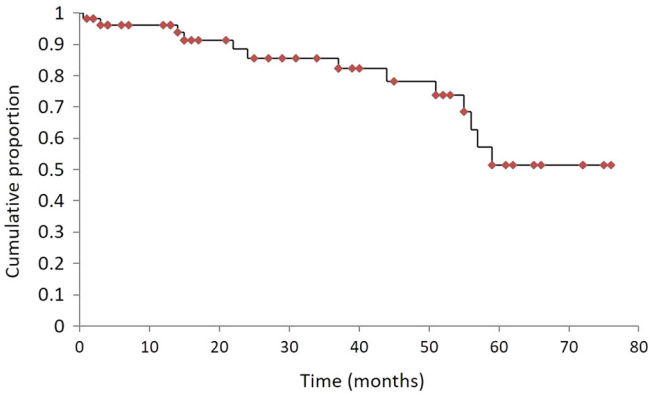

FIGURE 7 Kaplan–Meier survival curve for 54 dogs. The solid line represents survival for dogs treated with continuous extraluminal tracheal prosthesis. Red dots indicate censored values, which were dogs either still alive (n = 40) or lost to follow-up (n = 1)

examination revealed that recurrent cervical tracheal collapse had occurred. The recurrent coughing was well controlled with occasional administration of oral steroids and antitussives, so an additional surgical intervention was not performed. Another dog developed respiratory stridor after 5 days of postoperative hospitalization. A radiographic examination indicated that recurrent tracheal collapse had occurred around the second rib. However, preoperative clinical signs (eg, dry, harsh cough, labored breathing, and goose honking) did not recur for 3 months after surgery. After 5 months, the dog developed goose honking cough, and recurrent tracheal collapse at the thoracic inlet was confirmed by tracheobronchoscopy, but no granuloma formation was observed. Orbifloxacin (3 mg/kg orally once daily) and prednisolone (0.7 mg/kg orally once daily) were administered for 6 days. Butorphanol (0.3 mg/kg orally once or twice daily) was administered when the cough persisted. Nebulization infused with saline was then used twice daily for the next 5 months. The dog remained clinically stable, and clinical signs of goose honking cough occurred only when the dog was excited. Progressive tracheal collapse was observed in 1 dog 7 months after surgery, and intrathoracic tracheal and bronchial collapse were detected by radiographic examination. Prednisolone (0.5 mg/kg orally once daily) was initiated for use when the cough persisted. Among the remaining 3 dogs whose dry, harsh cough was not resolved, 2 had mitral valve regurgitation ACVIM stage B2 prior to surgery, and 1 had suspected chronic bronchitis after surgery. In total, postoperative complications were observed in 4 (7%; Table 1) dogs. Medical management was not required in 48 (89%) dogs after surgery.

During retrospective data collection, we determined that 13 dogs had died between 16 days and 59 months after surgery (Table 2). The cause of death was unknown in 3 dogs, but the remaining 10 dogs had died from conditions unrelated to tracheal collapse or CETP placement. None of the dogs had required additional surgical procedures for tracheal collapse, such as intraluminal stent placement, by the time of data collection.

3.4 | Histological examination

At macroscopic examination, the prosthesis was uniformly covered with a fibrous connective tissue layer in both dogs that died and were necropsied. Mature fibrous tissue formed a strong scaffold, which stabilized the prosthesis to the surface of the trachea. The prostheses that were removed from the tracheas retained their original shape and were not fractured. In addition, at histological examination, no abnormalities were found in the mucosal epithelium, submucosal tissue, or cartilaginous tissue at the site of the tracheal collapse (Figure 8). The fibrous tissues on the surface of the trachea consisted primarily of collagen fiber bundles, and almost no fibroblasts or fibrocytes were observed, suggesting complete collagen fiber organization. No chronic inflammation was associated with the placement of the CETP, and the histological structure of the trachea was not disrupted.

4 | DISCUSSION

Retrospective analysis of CETP placement revealed favorable short- and long-term outcomes in dogs with tracheal collapse.

TABLE 1 Summary of postoperative complications in 4 dogs

Breed	Sex	Age, y	Complication	Onset of complication	Treatment	Outcome
Pomeranian	IM	10	Pancreatitis, acute kidney failure	4 d after surgery	Antibiotics, heparin, and intravenous fluid	Died 16 d after surgery
Yorkshire terrier	MN	8	Recurrent tracheal collapse	5 d after surgery	Nebulizer, steroids, antibiotics, and antitussives	Still alive after 15 mo
Chihuahua	IM	4	Recurrent tracheal collapse	2 mo after surgery	Steroids and antitussives	Still alive after 51 mo
Maltese mix	MN	4	Laryngeal paralysis	12 d after surgery	Unilateral arytenoid lateralization	Still alive after 72 mo

Abbreviations: IM, intact male; MN, male neutered.

TABLE 2 Summary of cause of death after long-term follow-up in 13 dogs

Breed	Sex	Age, y	Weight, kg	Cause of death	Survival time, mo
Pomeranian	IM	10	4	Pancreatitis, acute kidney failure	0.5[a]
Yorkshire terrier	MN	6	3.5	Unknown	14
Maltese	FS	13	3	Heart failure	15
Chihuahua	IF	10	3.6	Heart failure	16
Yorkshire terrier	IM	8	4	Unknown	22
Yorkshire terrier	MN	12	3.8	Endotracheal abscess	24
Papillon	IM	5	4	Pancreatitis	37
Toy poodle	IM	1	3	Unknown	44
Chihuahua	IM	13	3.7	Intraperitoneal tumor	51
Shiba inu	IF	2	8.6	Suspected gastrointestinal lymphoma	55
Maltese	FS	8	4.7	Chronic kidney failure	56
Mix	IF	12	2	Heart failure	57
Yorkshire terrier	MN	6	2	Status epilepticus	59

Abbreviations: FS, female spayed; IF, intact female; IM, intact male; MN, male neutered.
[a]16 days.

FIGURE 8 Tracheal tissue in dogs treated with continuous extraluminal tracheal prosthesis (CETP). After fixation, the CETP was removed from the trachea. Arrow indicates the prosthesis tract. At histological examination, no abnormalities were found in the mucosal epithelium, submucosal tissue, or cartilage tissues at the site of tracheal collapse, suggesting that no chronic inflammation associated with the placement of the CETP occurred. Hematoxylin eosin stain

Recent studies have reported that 92%-95% of dogs survived to discharge after the placement of C-shaped tracheal rings.[5,10] We reported that 98% of the dogs survived to discharge except for 1 death due to DIC 16 days after surgery. In addition, follow-up surgical procedures are sometimes required after extraluminal ring placement.[5,10] However, none of the dogs in our study required an additional surgical procedure for continued or recurrent tracheal collapse. Migration of extraluminal tracheal ring prostheses has also been previously reported, but no prosthesis migration was observed in our study.[19] Various mortality rates related to respiratory compromise after tracheal ring placement ranging from 9%–26% have been reported.[5,10] In our study, 13 of the 54 (24%) dogs had died by the time of data collection (median follow-up time, 30 months). The cause of death was unknown in 3 dogs. One (2%) dog died of respiratory compromise secondary to endotracheal abscess. The remaining 9 dogs died of conditions unrelated to respiratory compromise. All but 1 dog lived between 14 and 59 months after surgery. The survival rate at 36 months was 86% (CI: 75%-96%). Tinga et al[10] showed that the presence of main-stem bronchial collapse decreased survival time in dogs with tracheal collapse that underwent surgical intervention, so the short- and long-term outcomes of the current study may have been influenced by a lower incidence of main-stem bronchial collapse compared to the prior study.

One prior article reported that the severity of clinical signs improved in all dogs that underwent extraluminal tracheal ring placement and that 65% of the dogs did not require medication postoperatively.[5] In another study in which 26% of the dogs exhibited main-stem bronchial collapse, persistent coughing was observed in 33% of the dogs after extraluminal ring placement.[10] Prior to the development of the CETP placement procedure, we hypothesized that a goose honk cough was caused by the trachealis muscle falling inward at the thoracic inlet during inhalation and exhalation. Thus, placement of the prosthesis was extended caudally to the thoracic inlet and as far as the second rib. As a result, goose honking cough was resolved in 25 of 26 (95%) dogs. Dry, harsh cough was also resolved in 87%

of dogs, and 89% of dogs did not require medical management after surgery.

In our study, only 1 (2%) dog developed laryngeal paralysis 12 days after surgery. Careful visualization of the recurrent laryngeal nerves and isolation of the nerves from the trachea at the beginning of surgery may have contributed to the lower rate of postoperative laryngeal paralysis compared with other recent reports.[5,10] Controlling hemostasis ensured better visualization for the surgeon and reduced the risk of iatrogenic injury to the nerves, especially the nerves in the area of the thoracic inlet. In addition, all soft tissues were handled with forceps rather than by digital manipulation, which minimized the damage to the trachea and surrounding tissues. It is important to note, however, that we did not evaluate laryngeal nerve function under anesthesia in all dogs, so the incidence of laryngeal paralysis may have been underestimated.

Skeletonization of the segmental blood vessels entails complete dissection of the trachea from the segmental tracheal blood supply. A prior study provided evidence that interruption of the segmental blood supply to the trachea by dissection of the lateral pedicles (ie, skeletonization) may cause necrosis,[20] leading some experts to recommend that only unilateral pedicles, including the segmental blood supply, should be dissected from the trachea.[7,18] Alternative extraluminal tracheal ring placement procedures have involved the dissection of localized tunnels at the point at which the ring was passed around the trachea.[7] This technique requires the surgeon to take extreme caution to preserve the recurrent laryngeal nerves, however, because they remain intimately associated with the trachea.[7] Unlike in other surgical techniques, because a CETP is constructed of one continuous piece, the recurrent laryngeal nerves and the segmental tracheal vessels must be isolated by blunt dissection and preserved for the length of the trachea as a CETP spans from the larynx to the second rib. Recent articles have reported that preserving the segmental blood supply to the trachea can minimize the incidence of tracheal necrosis and ischemic damage.[5,10] We also report no incidence of tracheal necrosis as evidenced by the absence of frequent cough, subcutaneous emphysema, and procedure-related mortality after the CETP placement.

We constructed the CETP using a commercially available optical fiber that was not specifically intended for medical implants. However, all materials in the fiber are approved for medical applications. At necropsy, we confirmed that the prosthesis retained its original shape, suggesting that the prosthesis did not fracture, even after an extended period. However, because the tracheal prosthesis may have been at risk of fracture from external pressure, we instructed the owners to refrain from neck collar use after surgery. At histological examination, no chronic inflammatory response associated with the placement of the CETP was observed after an extended period, suggesting that the prosthesis materials were tissue compatible with the surrounding tissues. Nonetheless, because histological examination was performed in only 2 cases, a larger sample size is required to confirm this finding as a part of comprehensive biocompatibility testing. In addition, in vitro biocompatibility tests, such as cytotoxicity, must be performed. The results of the current study also provide evidence that the selection of a prosthesis diameter between 10 and 12 mm might not be critical. However, if a dog weighs more than 7.2 kg or its thoracic inlet diameter exceeds 48.3 mm, a 15-mm diameter prosthesis might be more suitable.

There are several potential advantages of using a CETP. Because the prosthesis is composed of thin gauge material (ie, 0.75 mm), it is less likely to inadvertently damage the surrounding tissue and compress the segmental tracheal blood supply compared with thicker, opaque extraluminal rings.[5] Unlike opaque extraluminal rings, the translucent continuous prosthesis allows the surgeon to visualize the surrounding tissues and vessels through the prosthesis itself, which aids in preventing iatrogenic injury to the nerves and blood vessels. The tightness of the ligatures around the prosthesis can also be adjusted to protect blood vessels that pass between the prosthesis and the trachea.

The CETP is radiolucent and, thus, not directly visible on radiographs. However, postoperative radiographs revealed that the tracheal lumen was expanded along the entire length of the trachea, suggesting that the prosthesis extended to the first or second rib. Previously described rings have been placed only to the thoracic inlet or first rib.[5,7] The CETP was intentionally extended caudally from the larynx to the first or second rib to avoid partial tracheal collapse and prosthesis migration.

The tracheal cartilage provides both rigidity and flexibility to the trachea to allow the trachea to move and flex while breathing and to prevent tracheal collapse, which is why extraluminal tracheal prostheses must correspond to the dynamic movement of the trachea. The CETP is flexible enough to accommodate the spontaneous movement of the trachea. In addition, because the CETP is continuous and sutured evenly throughout the trachea, it can support both cartilaginous rings and the trachealis muscle.

The limitations of the current study include the retrospective and long-term nature of the study design. Consequently, not all of the dogs completed the follow-up examinations. Hence, a prospective study that includes a control cohort or a randomized controlled trial is required to evaluate the effectiveness of the placement of the CETP. To evaluate the severity of tracheal collapse, we performed radiography rather than tracheobronchoscopy, with the goal of minimizing the risk associated with anesthesia in dogs with severe tracheal collapse (eg, dyspnea and respiratory arrest). However, prior reports

have indicated that the frequency and degree of tracheal collapse were underestimated with radiography[16,21] and that the grading system previously described is accurate only when tracheobronchoscopy is performed.[22] Additional fluoroscopic and/or tracheobronchoscopic examination is thus required to evaluate accurately the severity of tracheal and bronchial collapse and to compare our findings to previous reports.[23]

The results of our retrospective study provide evidence that dogs undergoing a CETP placement experience low postoperative complication rates and high survival rates compared with the outcomes of previously reported extraluminal ring/prosthesis placement surgeries. Clinical signs, such as goose honking cough and dry, harsh cough, were resolved in most dogs. Hence, the placement of a CETP could be a viable alternative procedure for dogs with tracheal collapse.

ACKNOWLEDGMENT

We thank Noboru Ogi DVM (Ogi Small Animal Clinic) for assistance with the development of the surgical methodology and his encouragement throughout the process.

CONFLICT OF INTEREST

The authors declare no potential conflicts of interest with respect to the research, authorship, or publication of this report.

REFERENCES

1. Deweese MD, Tobias KM. Tracheal collapse in dogs. *Clin Br.* May 2014:83-87. https://www.cliniciansbrief.com/article/tracheal-collapse-dogs Accecced April 28, 2019.
2. Tappin SW. Canine tracheal collapse. *J Small Anim Pract.* 2016; 57(1):9-17.
3. White RAS, Williams JM. Tracheal collapse in the dog—is there really a role for surgery? A survey of 100 cases. *J Small Anim Pract.* 1994;35(4):191-196.
4. Fingland RB, DeHoff WD, Birchard SJ. Surgical management of cervical and thoracic tracheal collapse in dogs using extraluminal spiral prostheses. *J Am Anim Hosp Assoc.* 1987;23:163-172.
5. Chisnell HK, Pardo AD. Long-term outcome, complications and disease progression in 23 dogs after placement of tracheal ring prostheses for treatment of extrathoracic tracheal collapse. *Vet Surg.* 2015;44(1):103-113.
6. Rosenheck S, Davis G, Sammarco CD, Bastian R. Effect of variations in stent placement on outcome of endoluminal stenting for canine tracheal collapse. *J Am Anim Hosp Assoc.* 2017;53(3):150-158.
7. Haynes AM, Seibert R, Sura PA. Trachea and bronchi. In: Johnston SA, Tobian KM, eds. *Veterinary Surgery: Small Animal*. 2nd ed. St Louis, MO: Elsevier; 2017:137740-139501.
8. Durant AM, Sura P, Rohrbach B, Bohling MW. Use of nitinol stents for end-stage tracheal collapse in dogs. *Vet Surg.* 2012;41(7): 807-817.
9. Sura PA, Krahwinkel DJ. Self-expanding nitinol stents for the treatment of tracheal collapse in dogs: 12 cases (2001–2004). *J Am Vet Med Assoc.* 2008;232(2):228-236.
10. Tinga S, Thieman Mankin KM, Peycke LE, Cohen ND. Comparison of outcome after use of extra-luminal rings and intra-luminal stents for treatment of tracheal collapse in dogs. *Vet Surg.* 2015;44(7):858-865.
11. Buback JL, Boothe HW, Hobson HP. Surgical treatment of tracheal collapse in dogs: 90 cases (1983–1993). *J Am Vet Med Assoc.* 1996;208(3):380-384.
12. Becker WM, Beal M, Stanley BJ, Hauptman JG. Survival after surgery for tracheal collapse and the effect of intrathoracic collapse on survival. *Vet Surg.* 2012;41(4):501-506.
13. Kim SJ, Choi B, Kim KS, et al. The potential role of polymethyl methacrylate as a new packaging material for the implantable medical device in the bladder. *Biomed Res Int.* 2015;2015:852456.
14. Frazer RQ, Byron RT, Osborne PB, West KP. PMMA: an essential material in medicine and dentistry. *J Long Term Eff Med Implants.* 2005;15(6):629-639.
15. Tanzawa H. 繊維のメディカル分野への展開. 血液適合性材料とその医療用途.繊維工学. *J Text Mach Soc.* 1978;31(7):287-292.
16. Macready DM, Johnson LR, Pollard RE. Fluoroscopic and radiographic evaluation of tracheal collapse in dogs: 62 cases (2001–2006). *J Am Vet Med Assoc.* 2007;230(12):1870-1876.
17. Atkins C, Bonagura J, Ettinger S, et al. Guidelines for the diagnosis and treatment of canine chronic valvular heart disease. *J Vet Intern Med.* 2009;23(6):1142-1150.
18. Coyne BE, Fingland RB, Kennedy GA, Debowes RM. Clinical and pathologic effects of a modified technique for application of spiral prostheses to the cervical trachea of dogs. *Vet Surg.* 1993;22(4): 269-275.
19. Moser JE, Geels JJ. Migration of extraluminal tracheal ring prostheses after tracheoplasty for treatment of tracheal collapse in a dog. *J Am Vet Med Assoc.* 2013;243(1):102-104.
20. Kirby BM, Bjorling DE, Rankin JH, Phernetton TM. The effects of surgical isolation and application of polypropylene spiral prostheses on tracheal blood flow. *Vet Surg.* 1991;20(1):49-54.
21. Johnson LR, Singh MK, Pollard RE. Agreement among radiographs, fluoroscopy and bronchoscopy in documentation of airway collapse in dogs. *J Vet Intern Med.* 2015;29(6):1619-1626.
22. Tangner CH, Hobson HP. A retrospective study of 20 surgically managed cases of collapsed trachea. *Vet Surg.* 1982;11(4):146-149.
23. Tracheal collapse. American College of Veterinary Surgeons. https://www.acvs.org/small-animal/tracheal-collapse. Accessed April 28, 2019.

SUPPORTING INFORMATION

Additional supporting information may be found online in the Supporting Information section at the end of this article.

How to cite this article: Suematsu M, Suematsu H, Minamoto T, Machida N, Hirao D, Fujiki M. Long-term outcomes of 54 dogs with tracheal collapse treated with a continuous extraluminal tracheal prosthesis. *Veterinary Surgery*. 2019;48:825–834. https://doi.org/10.1111/vsu.13229