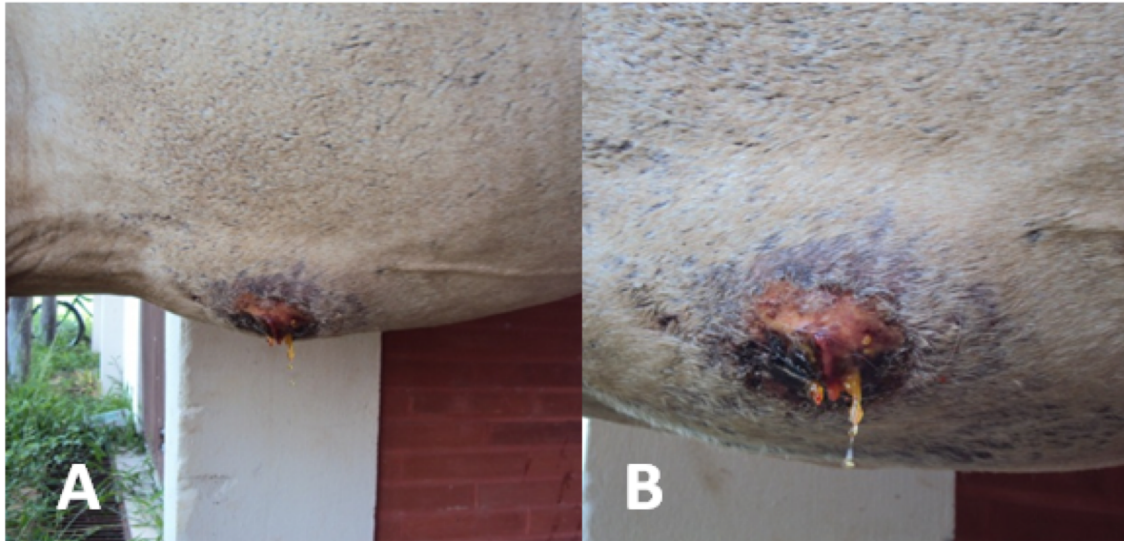
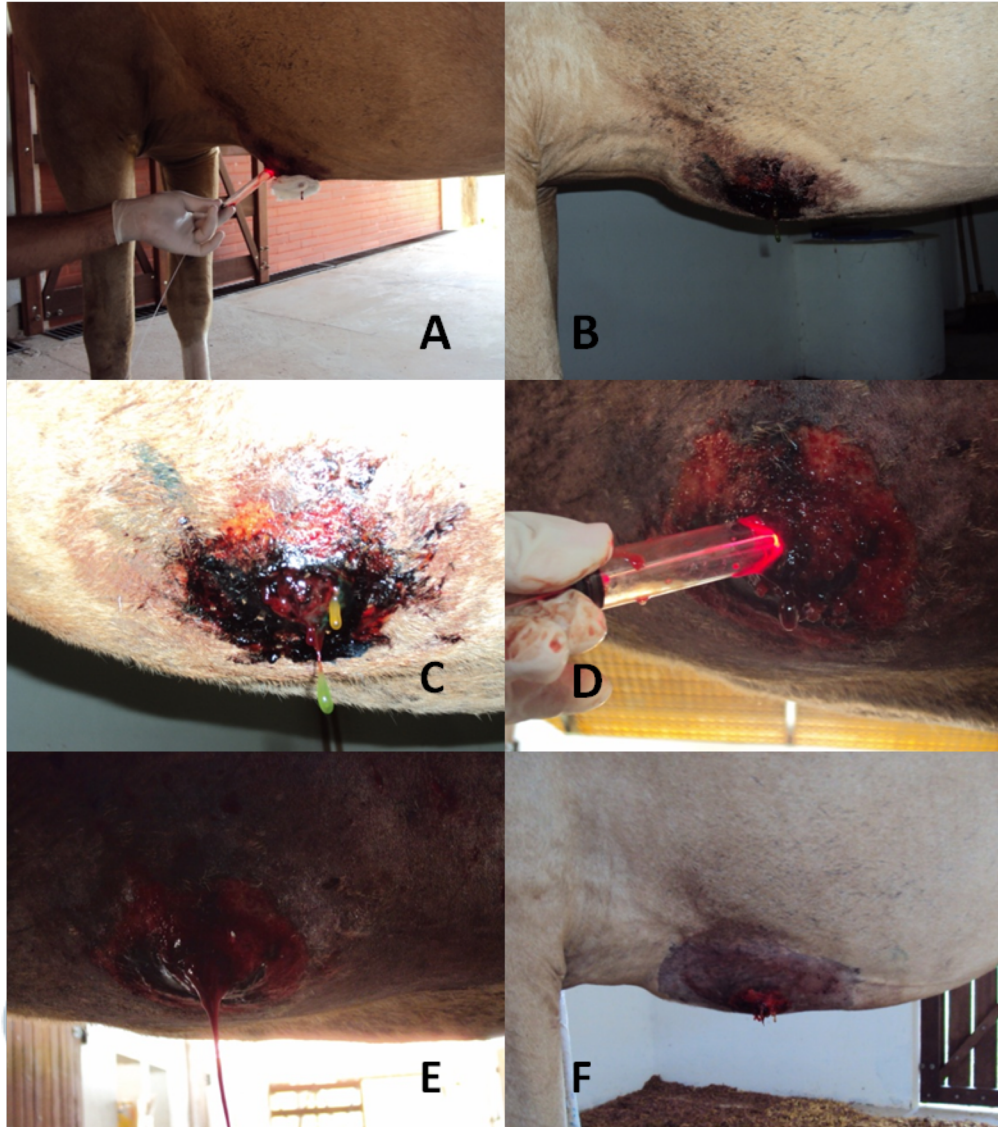


## Case 2

Pregnant horse from Castanhal-PA, with ulceration and infiltrative lesion at the belly region and of fast growing rate.



## Case 2



-Intralesional injection –  
Photodithazine (5mg/mL);

- Intralesional irradiation with 20  
mm cylindrical fiber;

- Local infection was controlled and  
the delivery occurred 4 weeks after  
PDT.



# Instrumentação

