

---

# TÉCNICA CIRÚRGICA DO APARELHO DIGESTÓRIO DE GRANDES ANIMAIS

Prof. Dr. André Luis do Valle De Zoppa

Departamento de Cirurgia

FMVZ - USP

---

# Técnica cirúrgica do aparelho digestório de eqüinos

- Laparotomia
- Enterotomia
- Enterectomia



---

# DEFINIÇÕES

- **LAPAROTOMIA: abertura dos flancos;**
  - **CELIOTOMIA: abertura do abdômen;**
  
  - **LAPAROTOMIA: devido às primeiras técnicas cirúrgicas abdominais, o termo médico foi consagrado para qualquer abertura abdominal.**
-

---

# LAPAROTOMIA

- Indicações:
  - Posicionamento do animal:
    - em posição quadrupedal (estação)
    - em decúbito
-

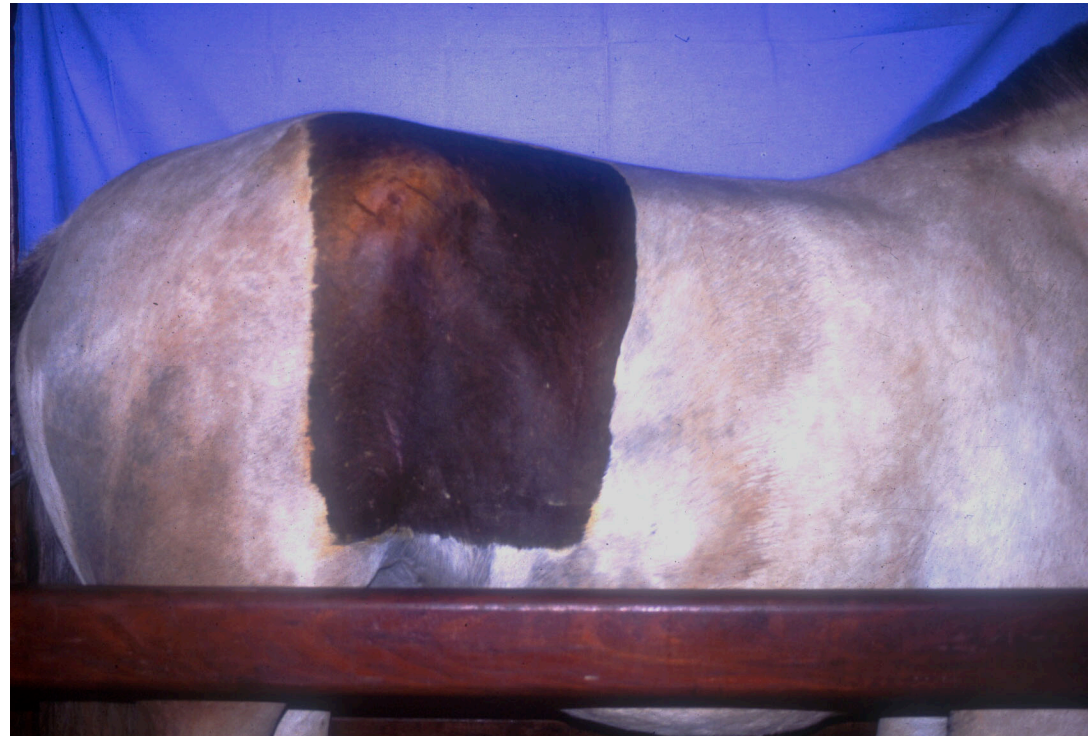---

# ACESSOS CIRÚRGICOS

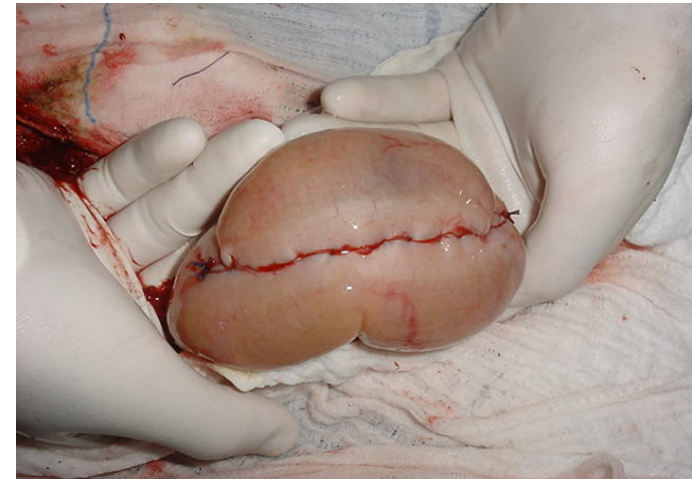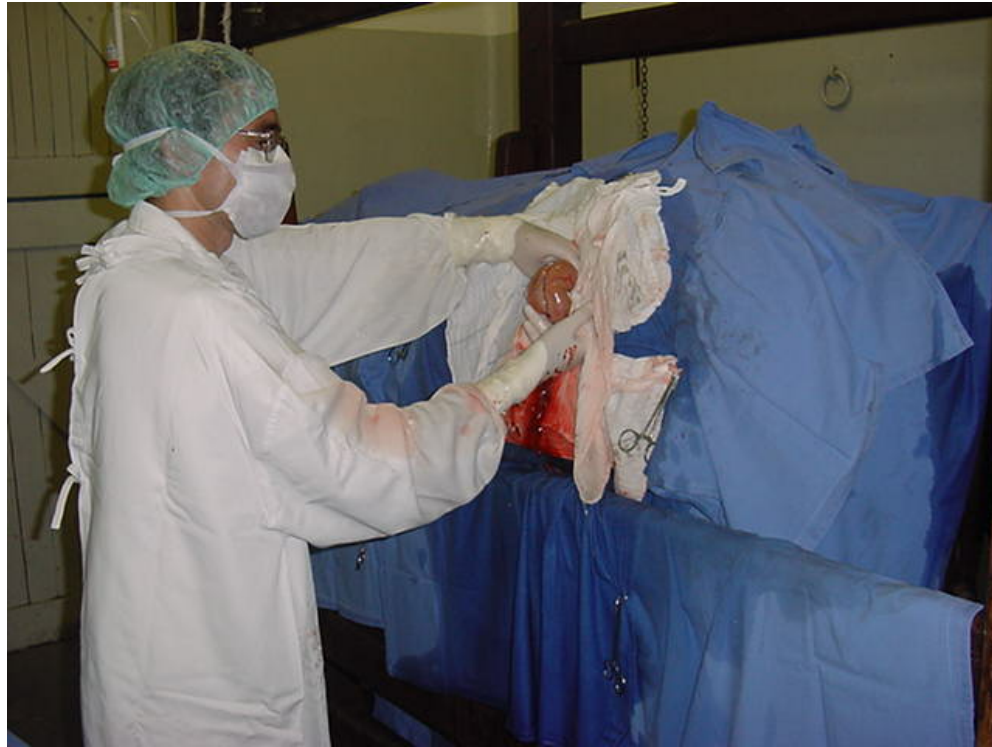- Linha média ventral: animal em decúbito dorsal;
  - Paramediano: animal em decúbito dorsal;
  - Inguinal: animal em decúbito dorsal ou lateral;
  - Flanco: Animal em posição quadrupedal.
-

# Laparotomia pelo flanco

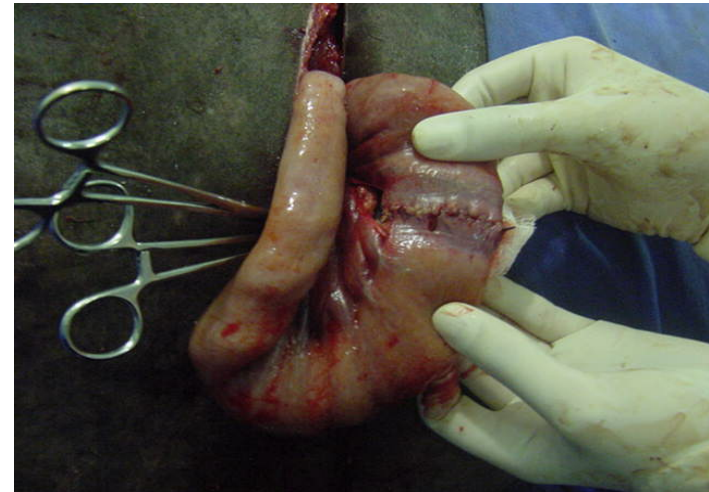
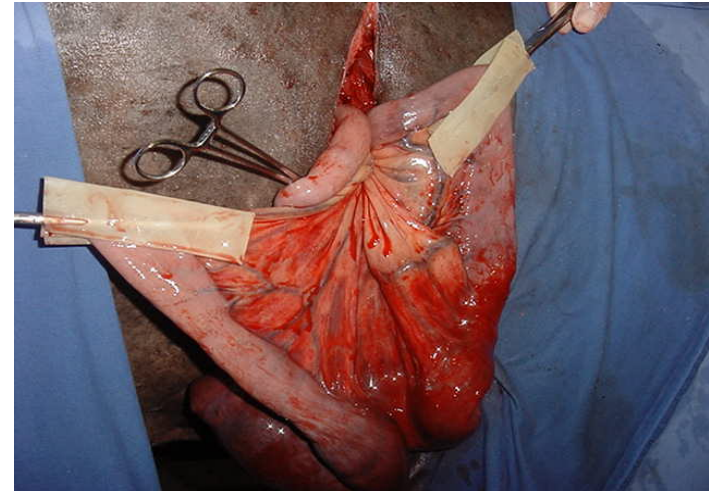
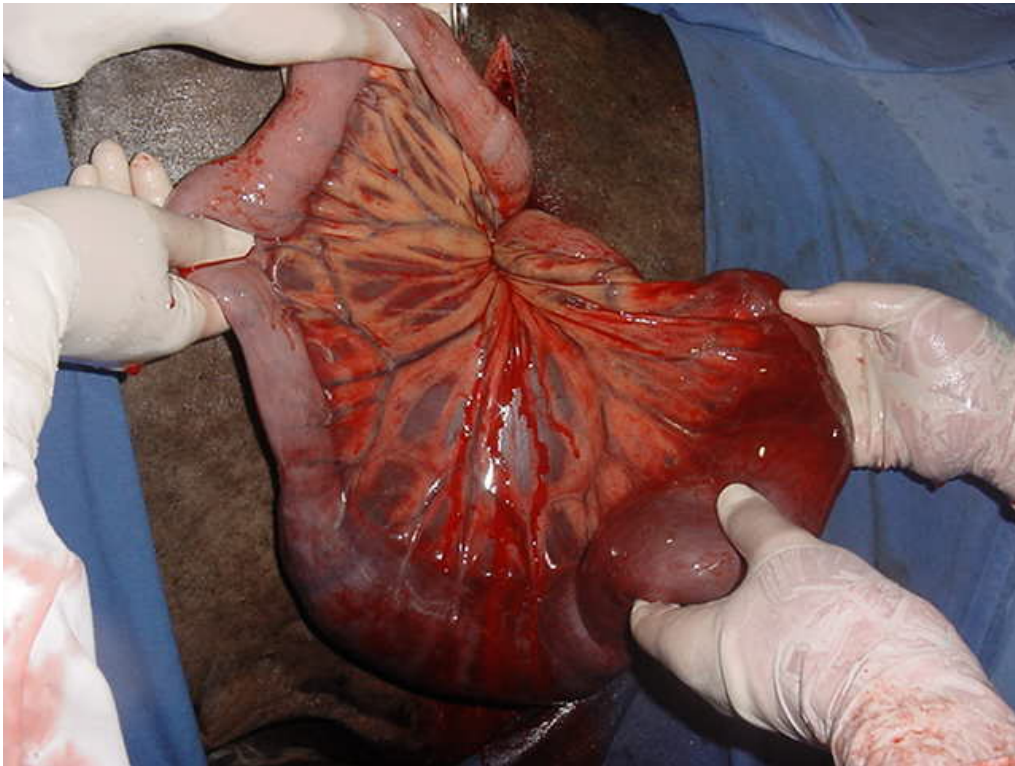
- Indicações:



# Indicações



# Indicações





---

# LAPAROTOMIA PELO FLANCO

Vantagens:

- Menor custo do procedimento;
  - Menor risco anestésico;
  - Ausência da recuperação da anestesia geral;
  - Menor influência dos fármacos anestésicos sobre a motilidade intestinal.
-

---

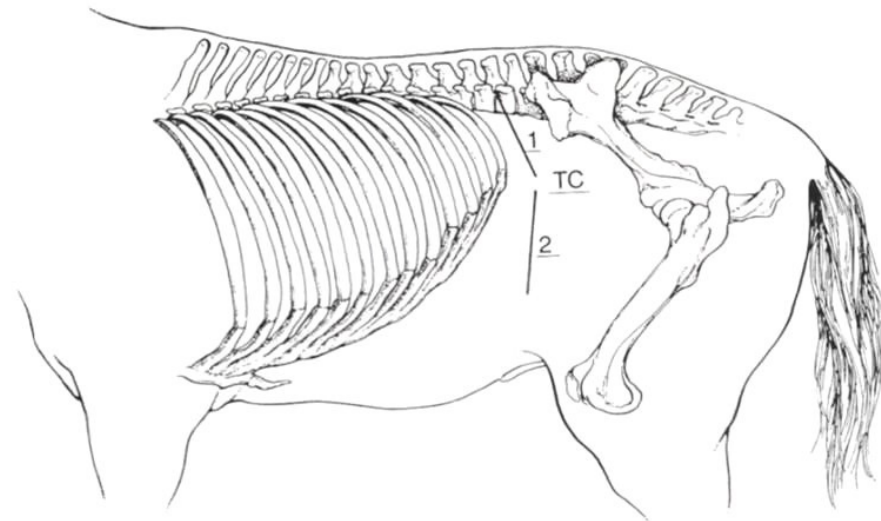
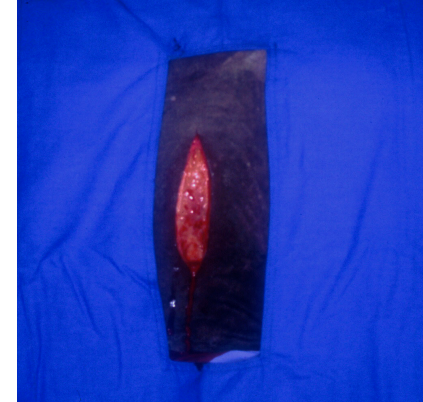
# LAPAROTOMIA PELO FLANCO

Riscos:

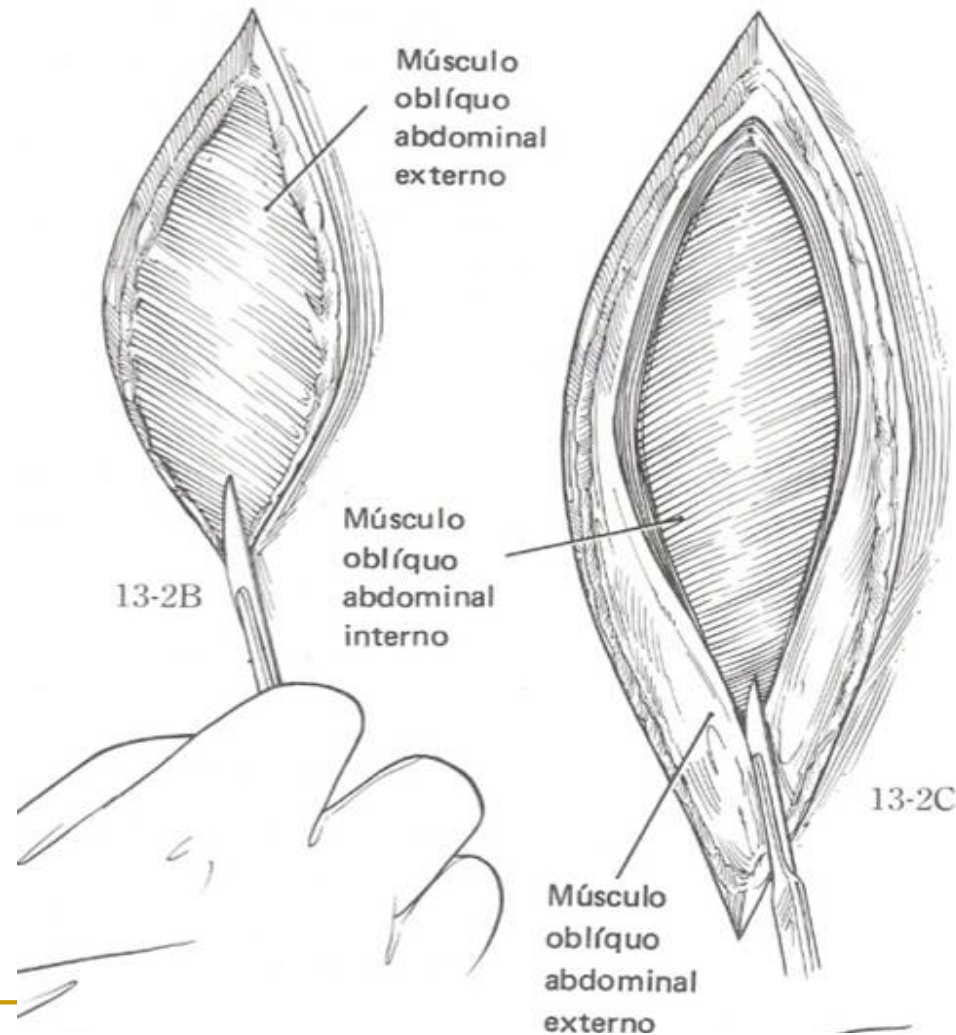
- Queda durante o procedimento;
  - Acidentes no tronco de contenção;
  - Necessidade de nova laparotomia (mediana ventral).
-

# Laparotomia pelo flanco

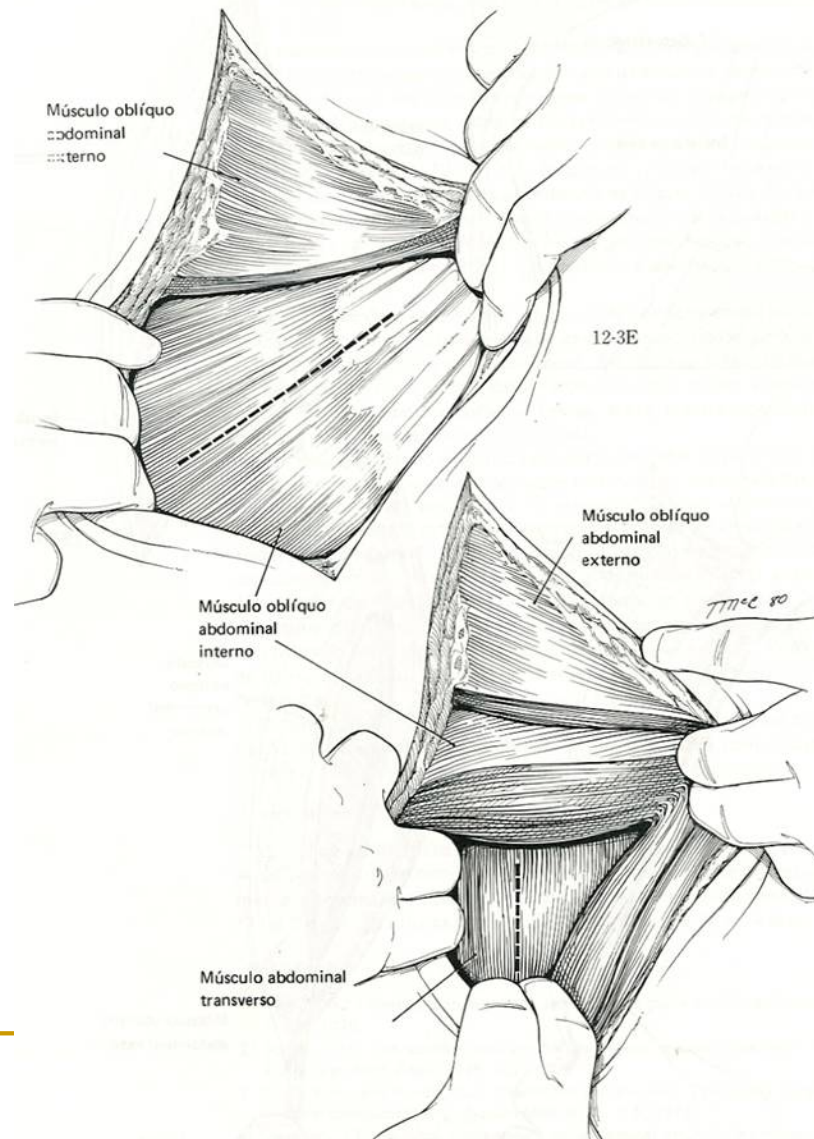
- Técnica cirúrgica:
  - incisão de pele (20 cm)



# LAPAROTOMIA PELO FLANCO

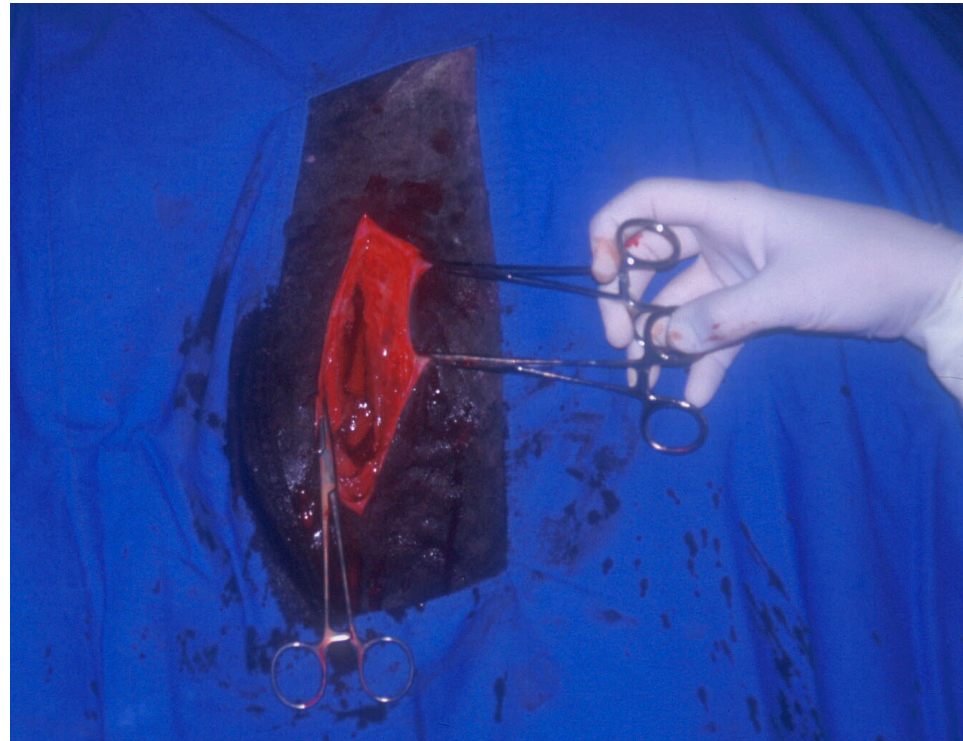


# LAPAROTOMIA PELO FLANCO



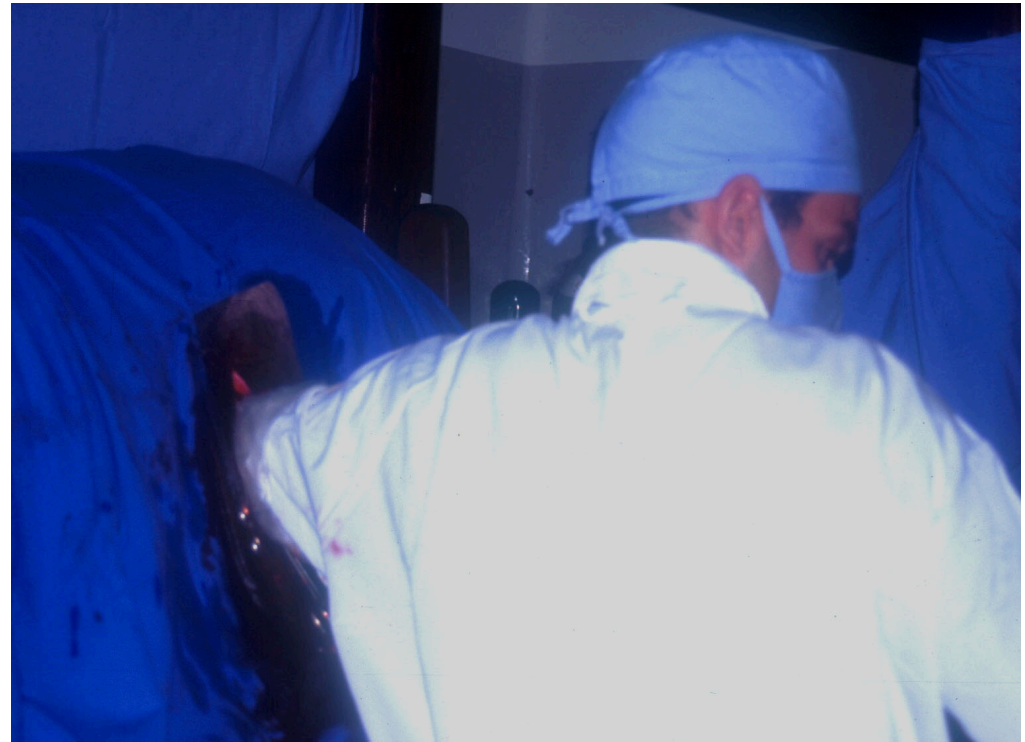# Laparotomia pelo flanco

- Técnica cirúrgica:
  - abordagem dos planos musculares:
    - músc. oblíq. abdom. externo
    - músc. oblíq. abdom interno
    - músc. transverso do abdom.
  - peritônio



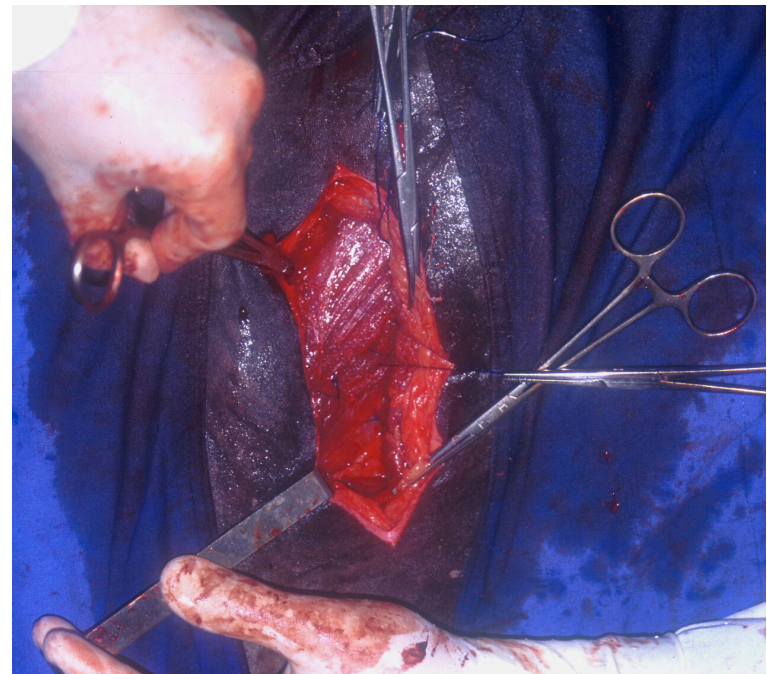
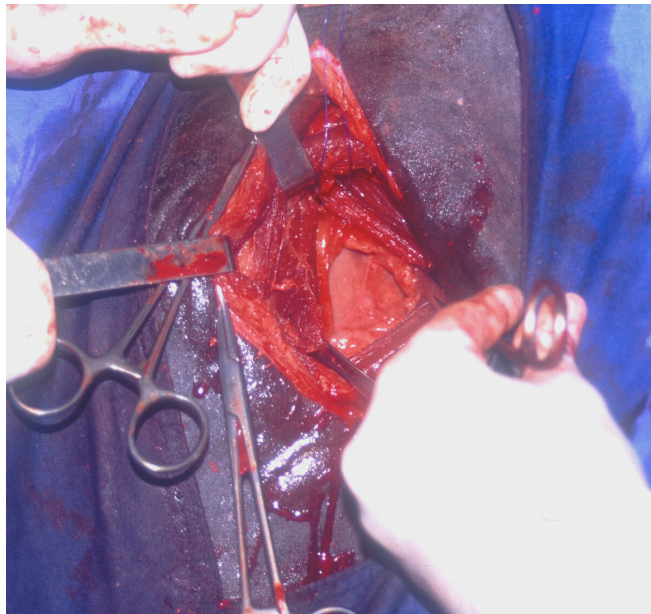
# Laparotomia pelo flanco

- Estruturas palpáveis:
  - flanco direito
  - flanco esquerdo
- Exteriorização:
  - intestino delgado
  - cólon menor
  - cólon maior /  
flexura pélvica
  - ceco



# Laparotomia pelo flanco

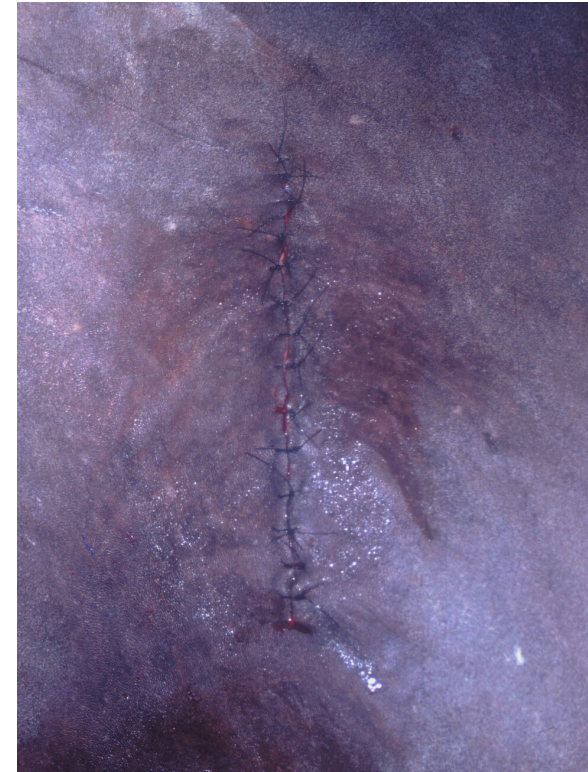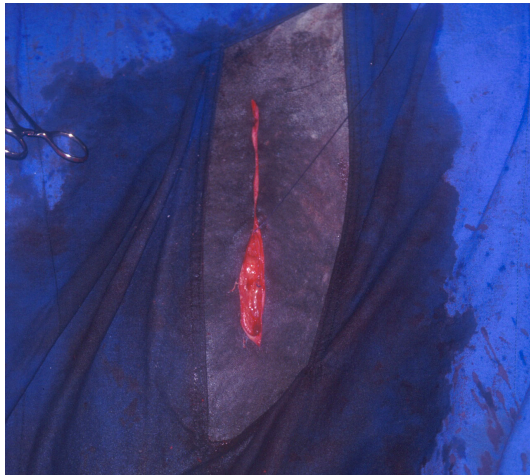- Sutura dos planos operatórios:
  - musculatura





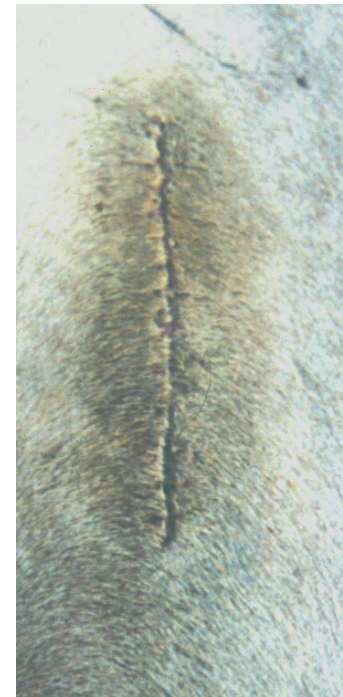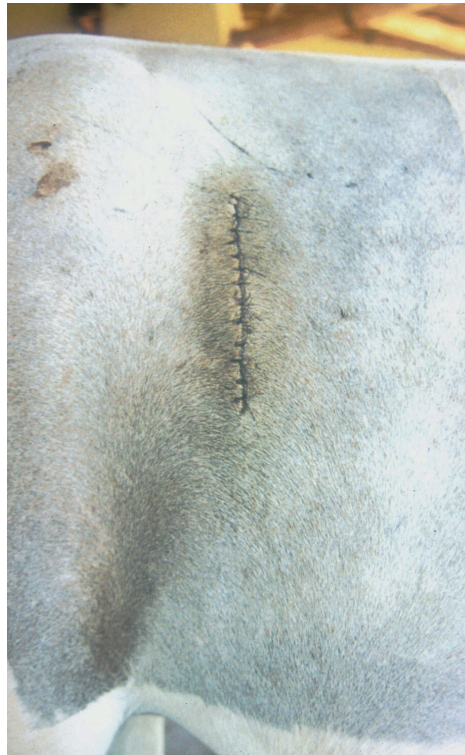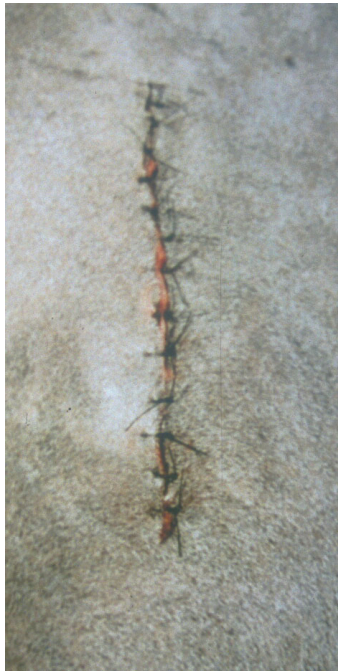# Laparotomia pelo flanco

- Sutura dos planos operatórios:
  - tecido subcutâneo
  - pele



# Laparotomia pelo flanco

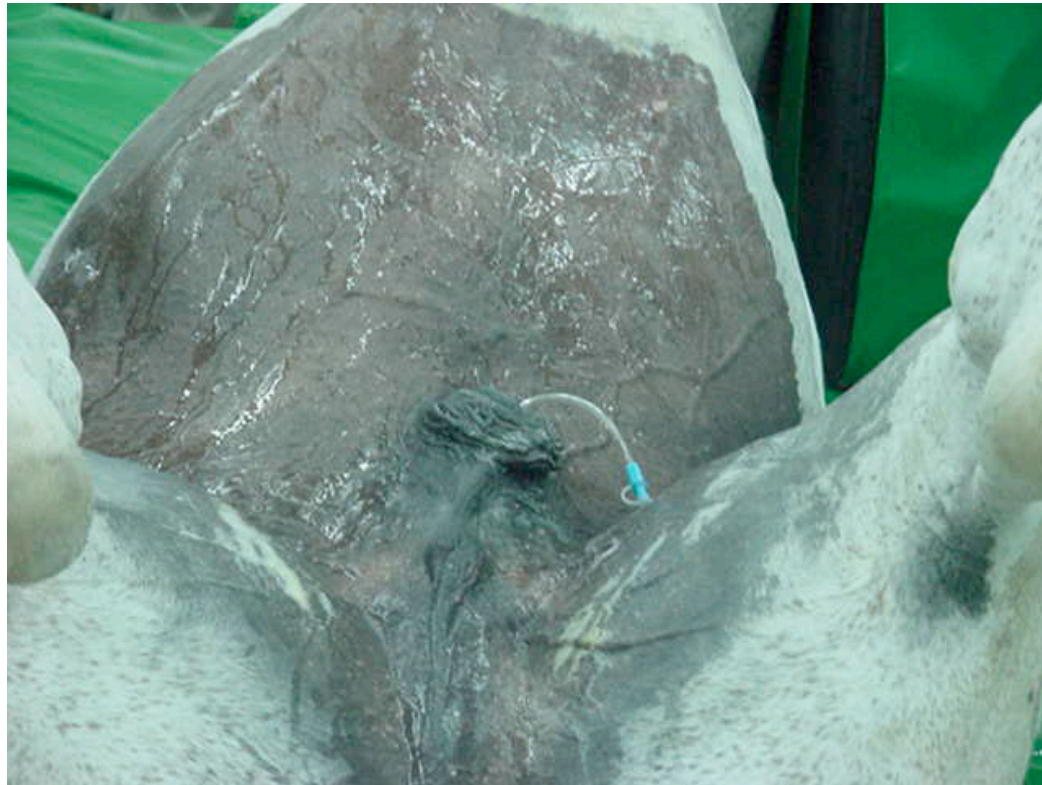- Pós-operatório:



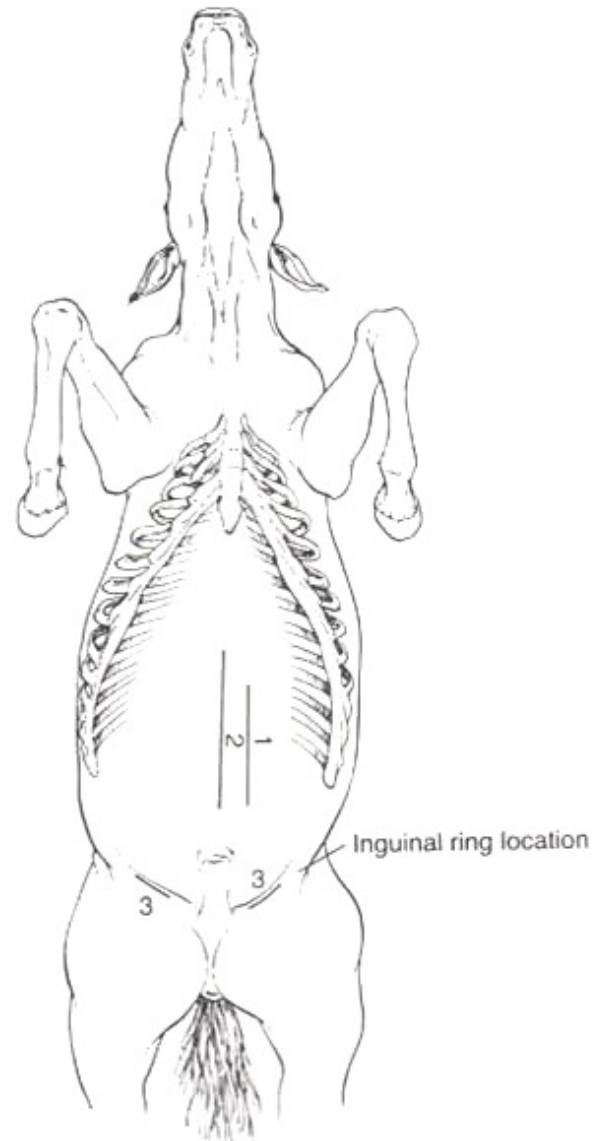
# LAPAROTOMIA

## decúbito dorsal

- Técnica:

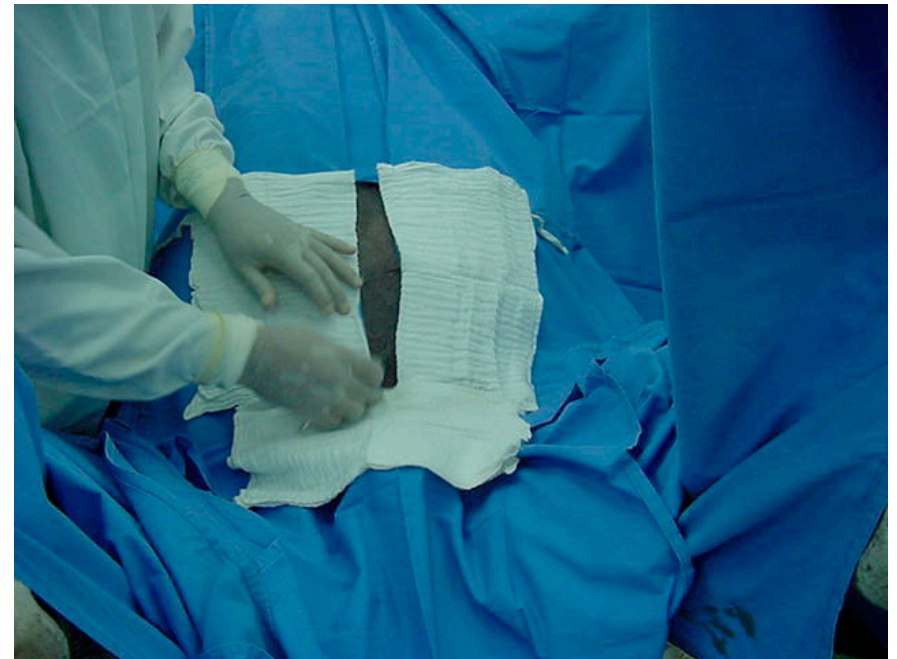
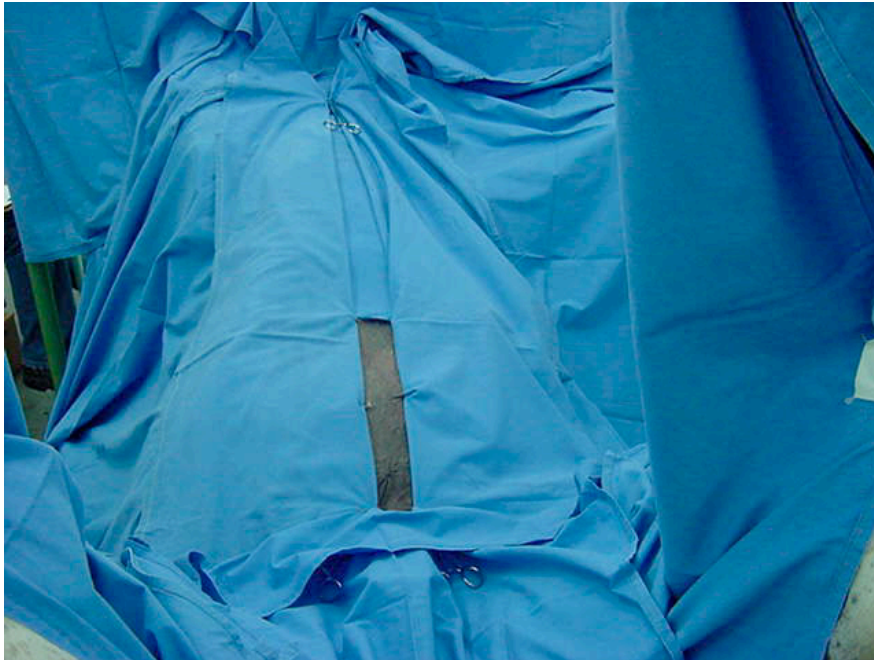


# ACESSOS VENTRAIS



---

- Pano de campo:

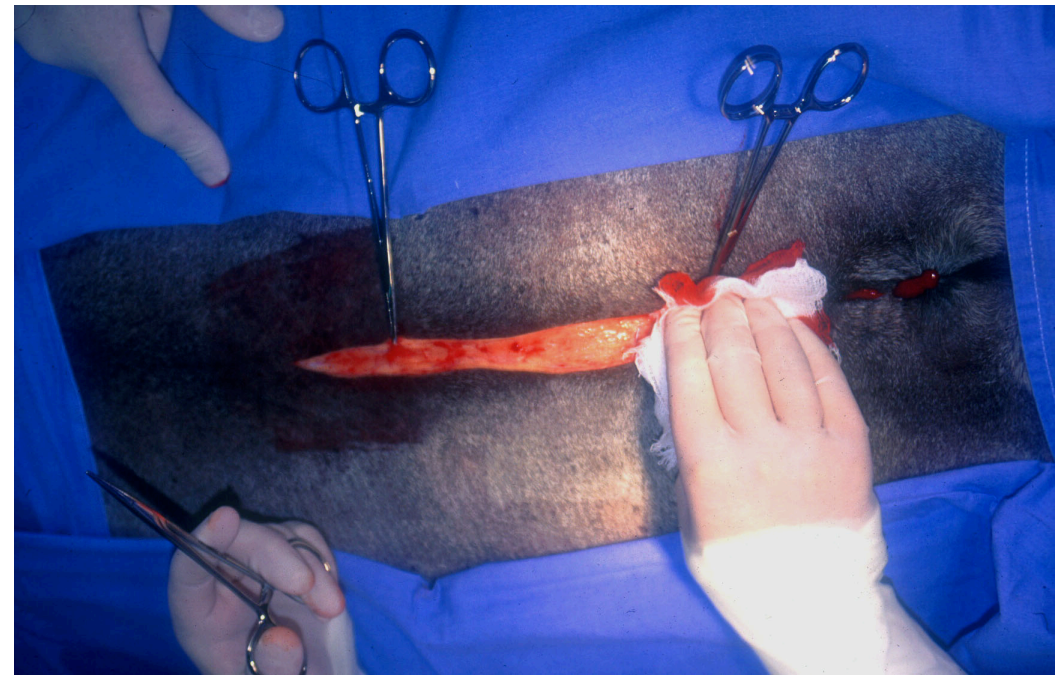
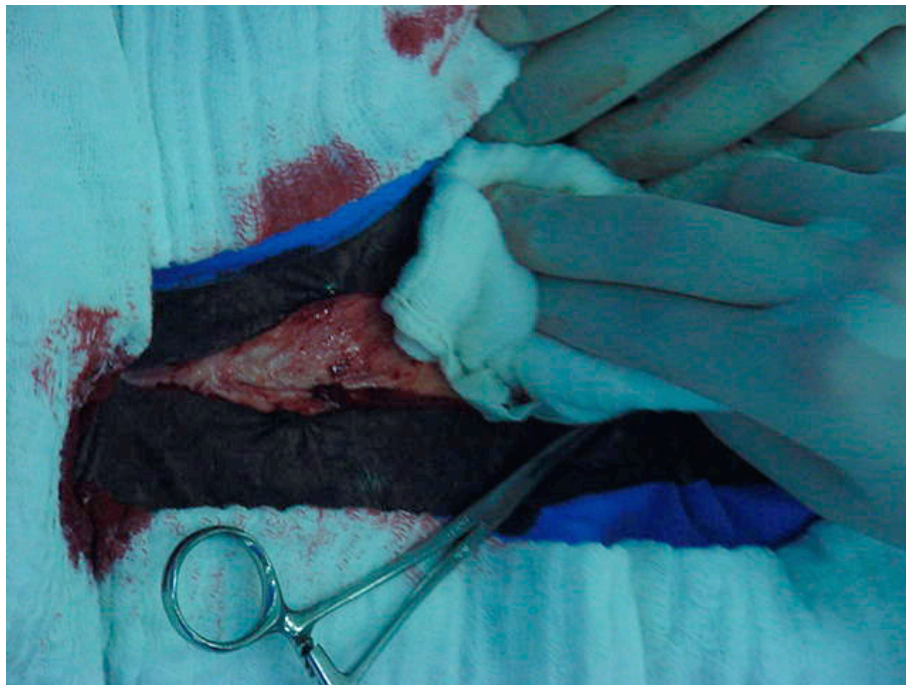



---

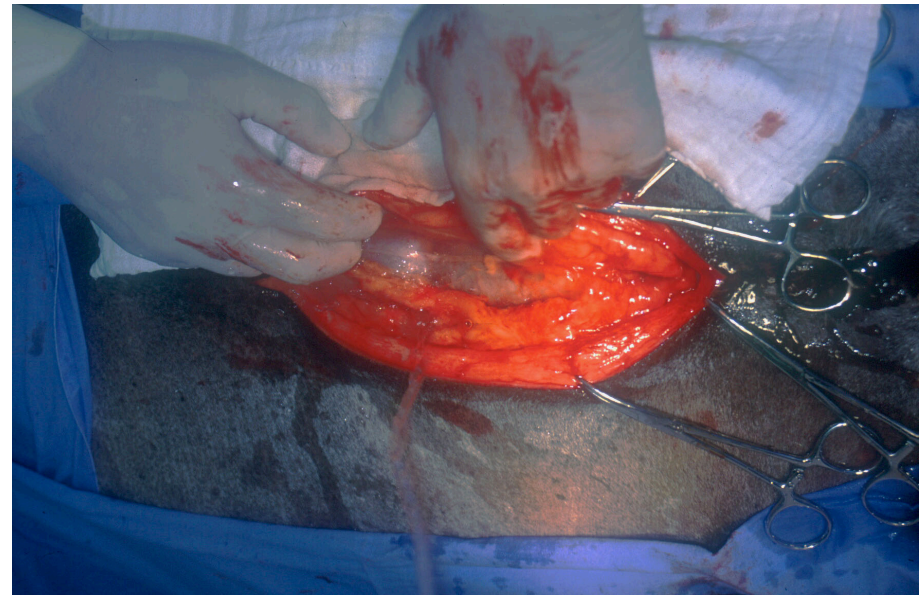
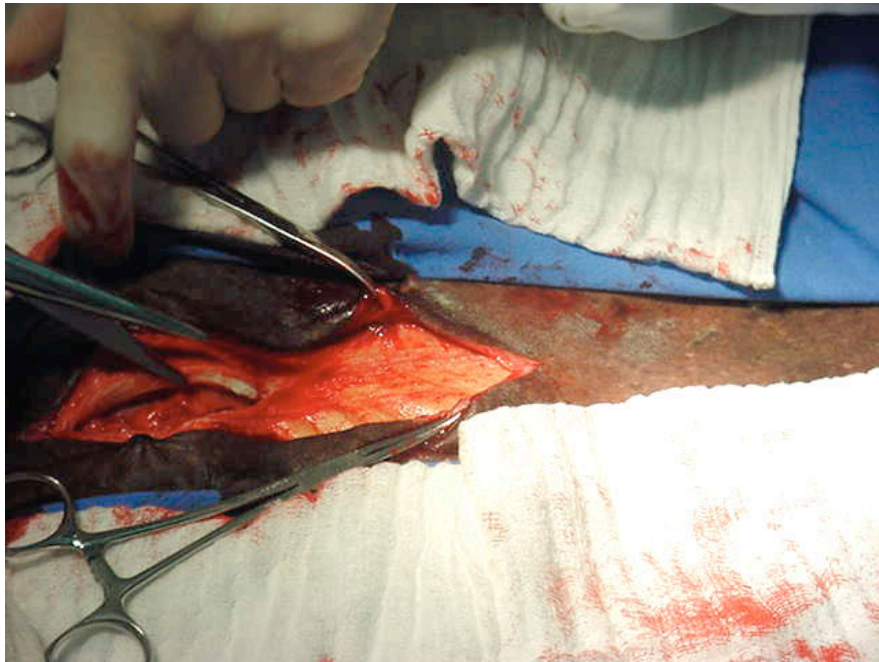
- Técnica cirúrgica:

- incisão de pele (linha Alba -30cm);



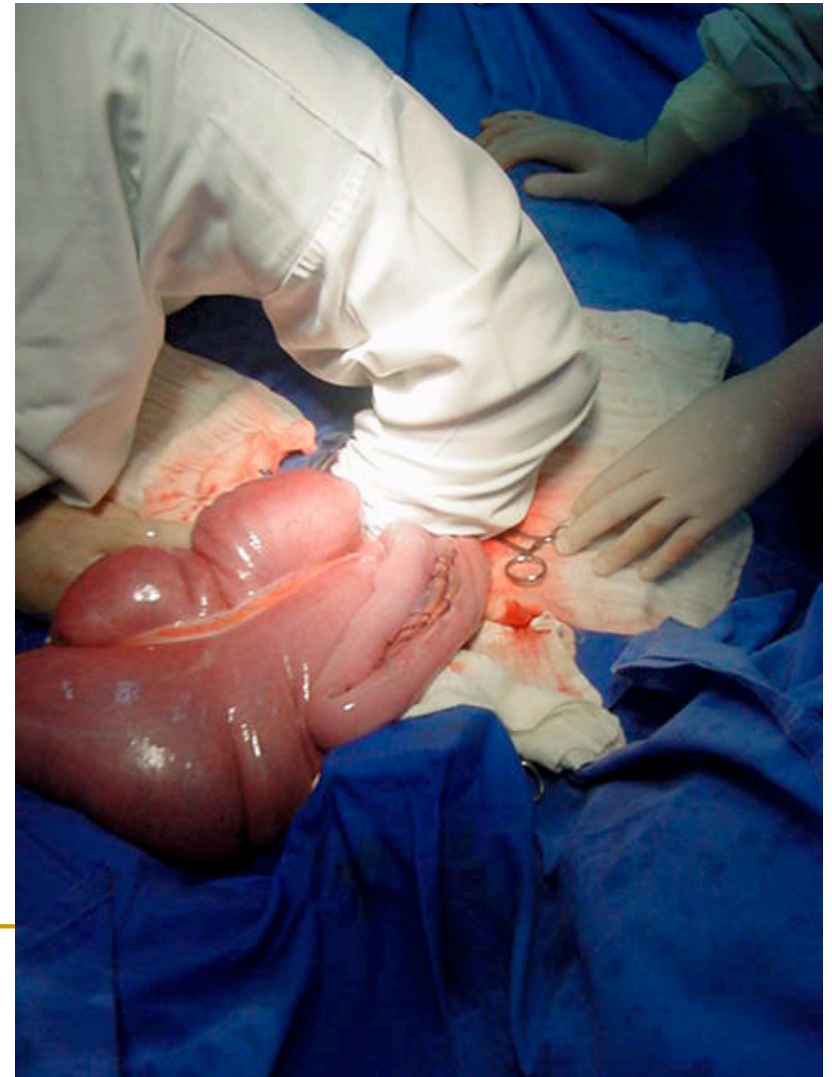- Técnica cirúrgica:

- incisão da musculatura / linha Alba;
- abertura do peritônio;

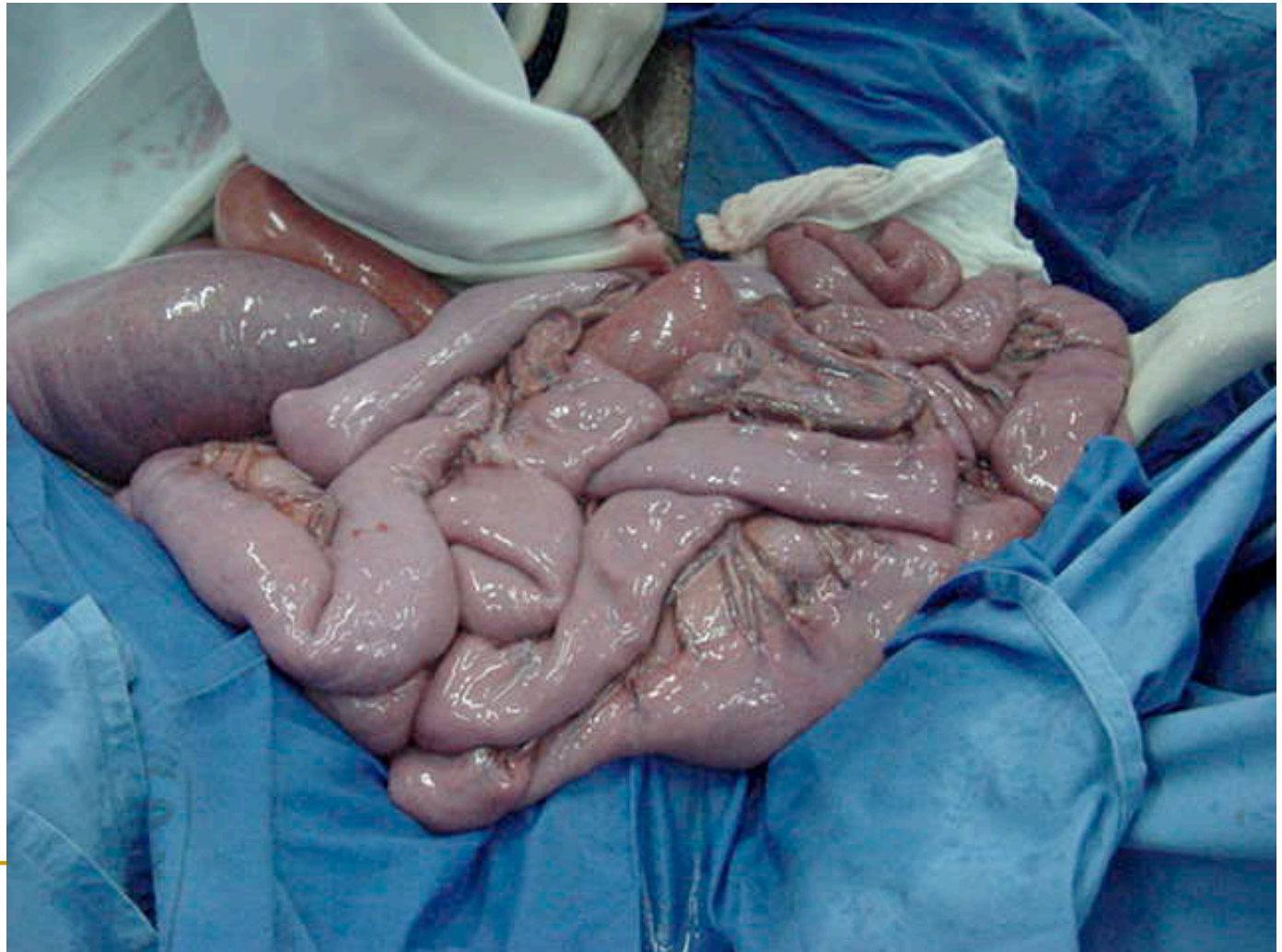



- Técnica cirúrgica:
  - inspeção da cavidade por palpação;
  - reavaliar o tamanho da incisão.



- Exteriorização:
  - intestino delgado;



ceco

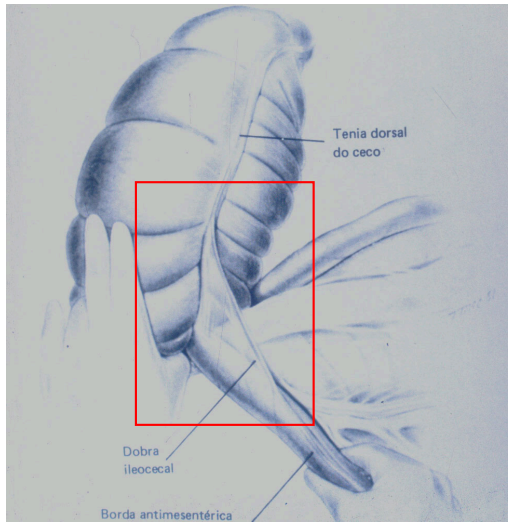
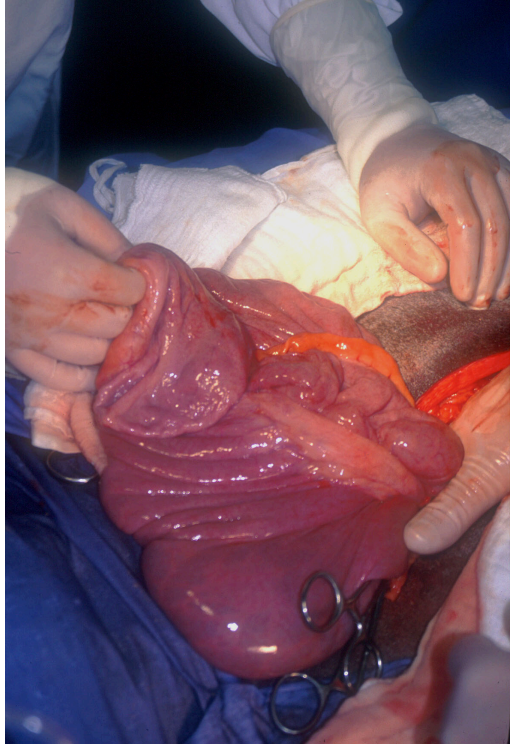
prega íleocecal

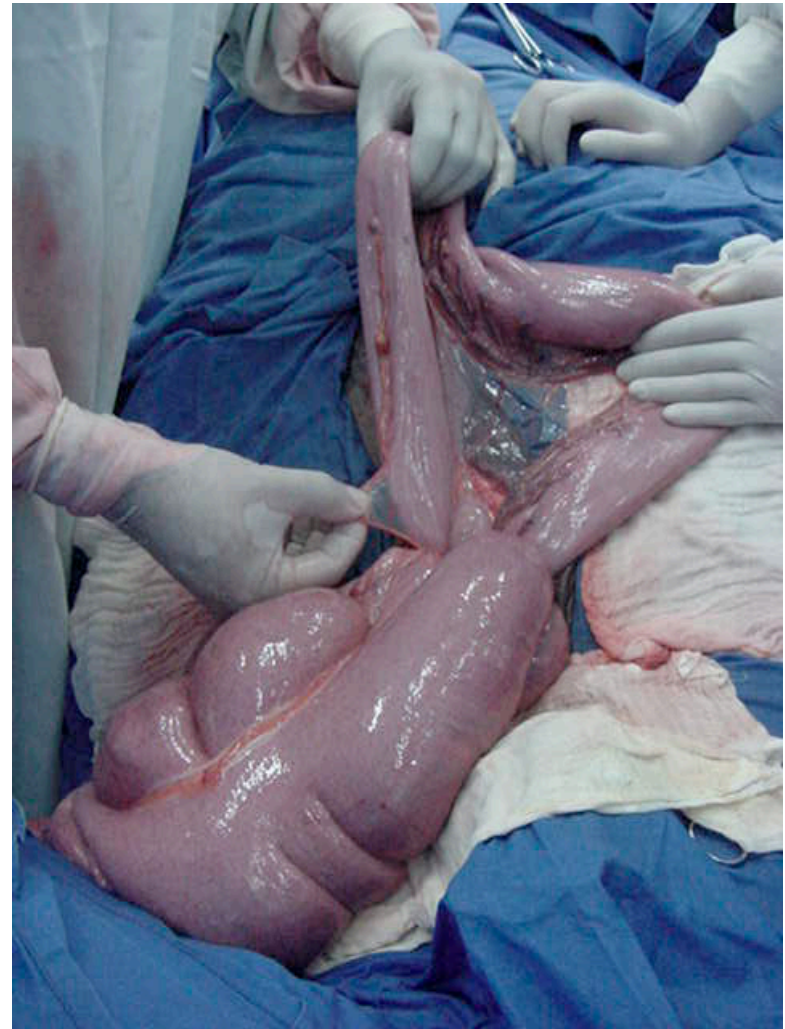
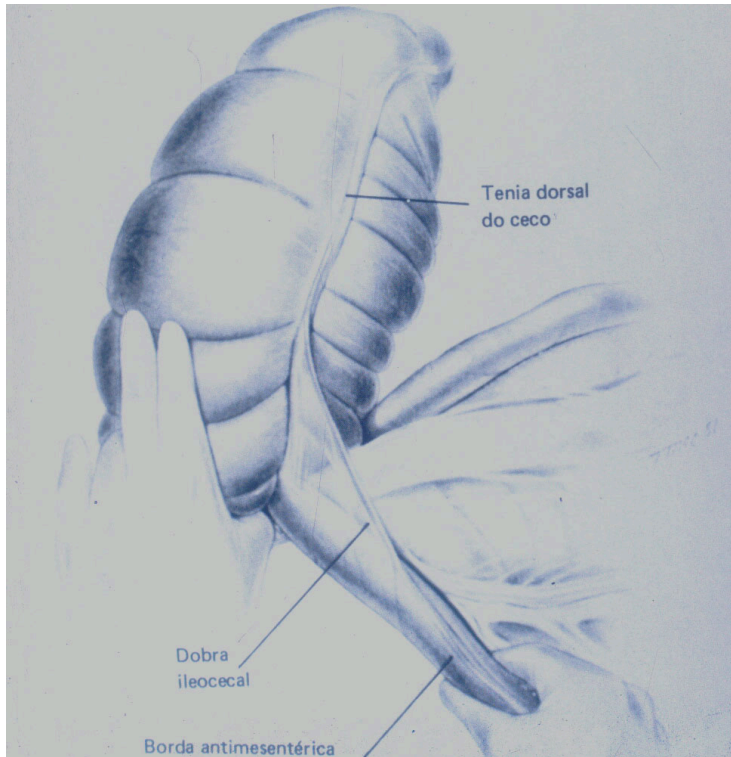
íleo

jejuno

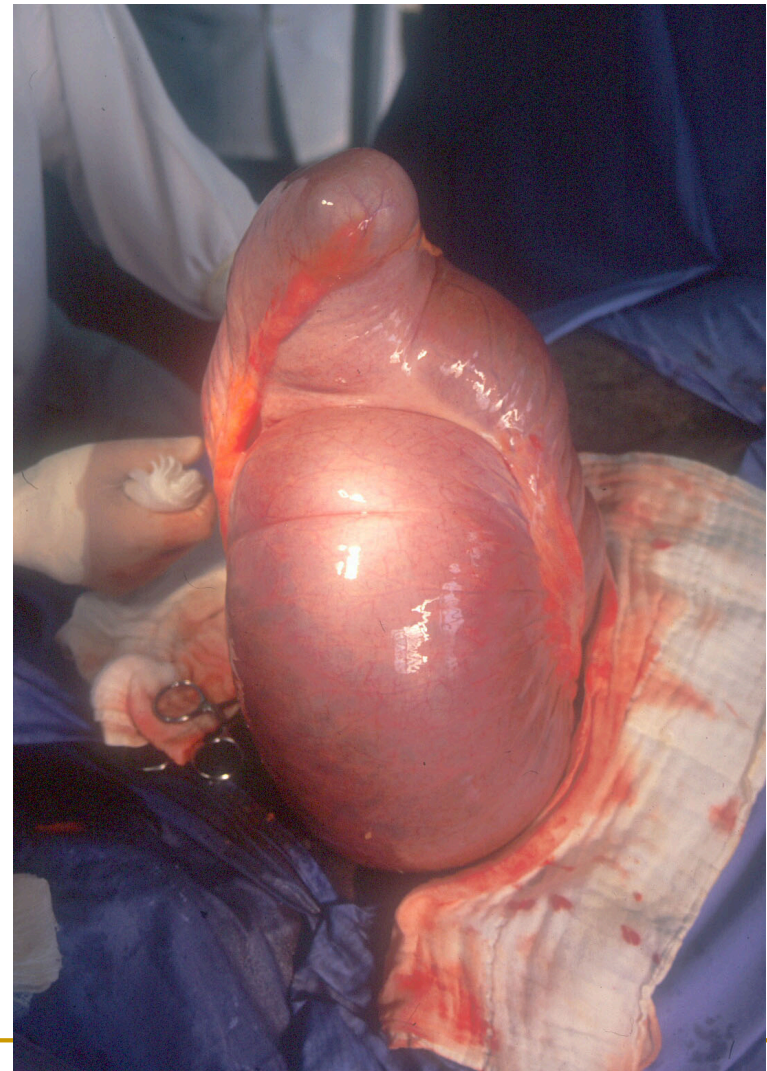
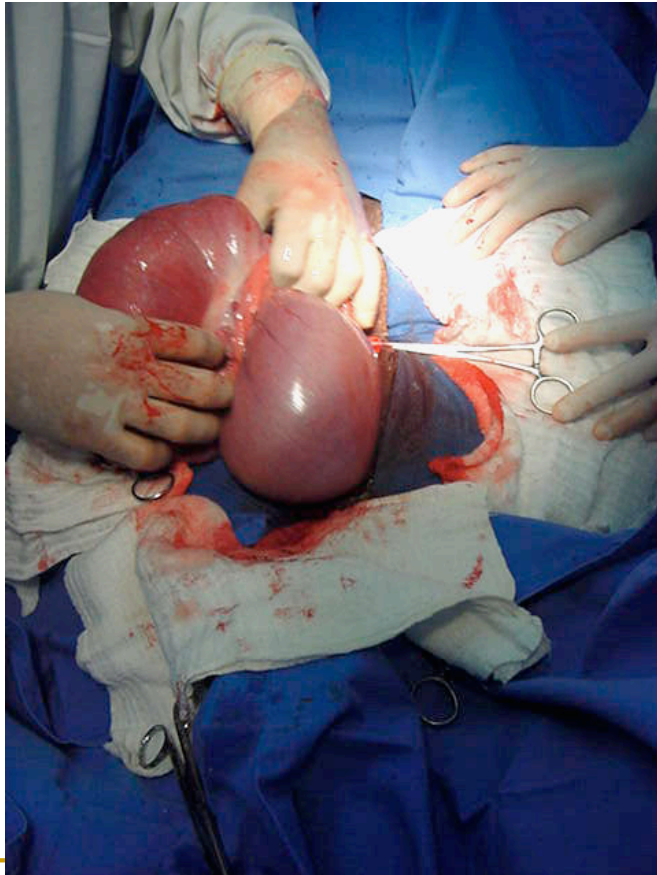
duodeno

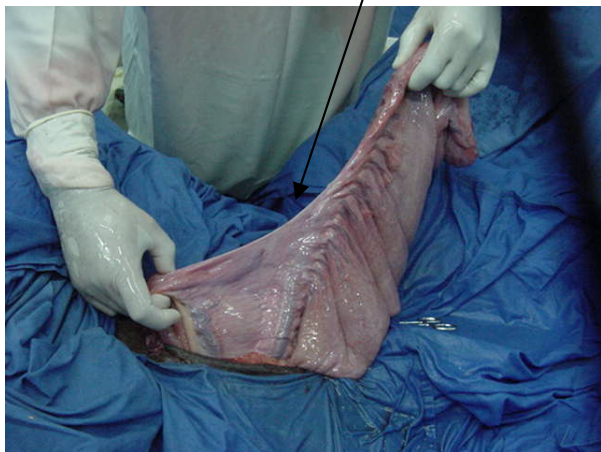estômago





- Exteriorização:
  - ceco (ápice e corpo);





prega  
cecocólica

ceco

Cólon ventral  
direito

Cólon ventral  
esquerdo

Cólon dorsal  
esquerdo

Cólon dorsal  
direito

Cólon  
transverso

Cólon menor

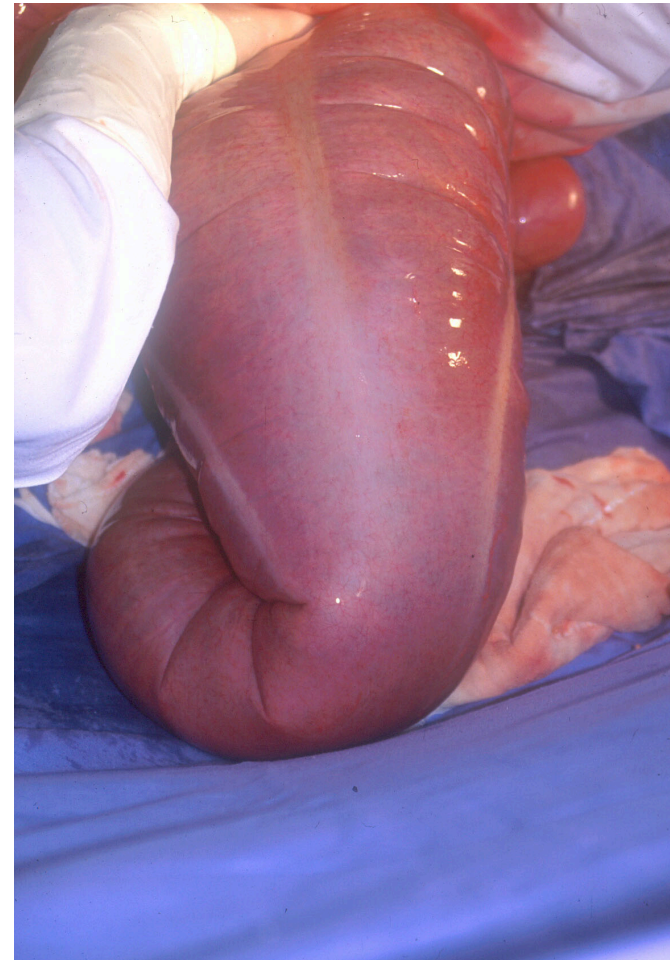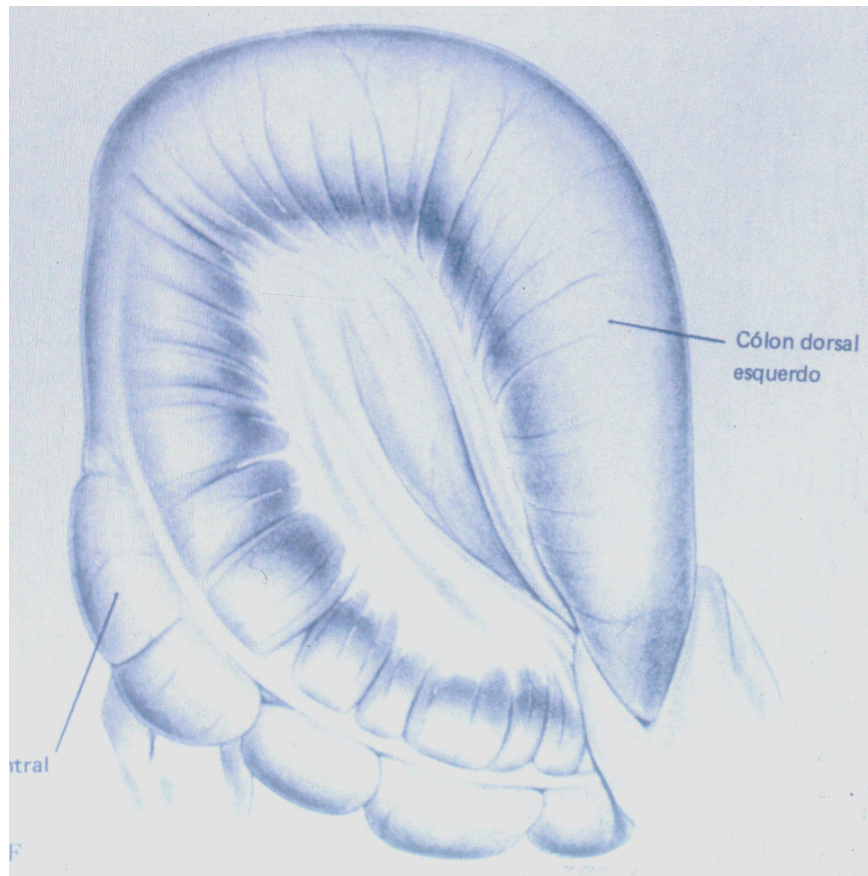
reto

flexura  
esternal

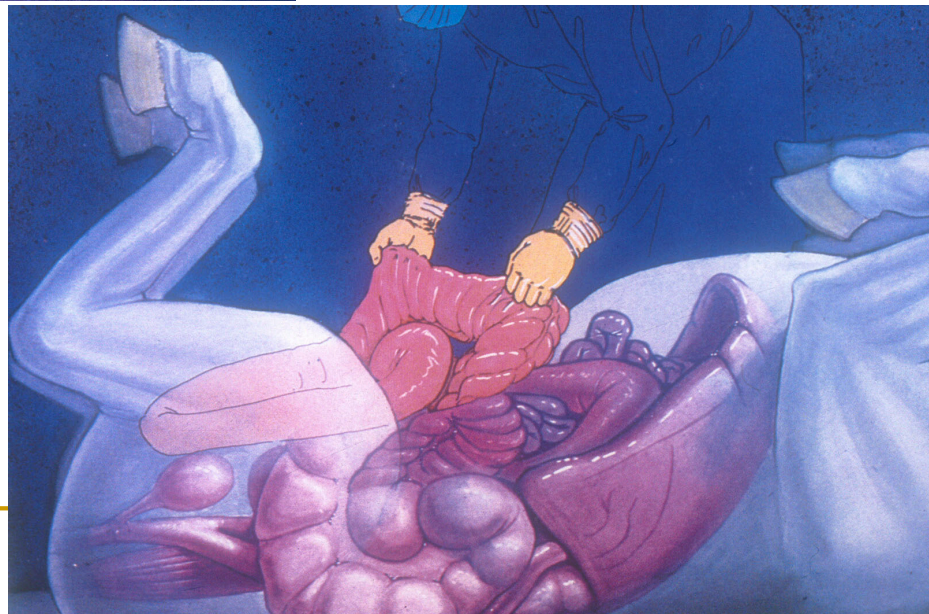
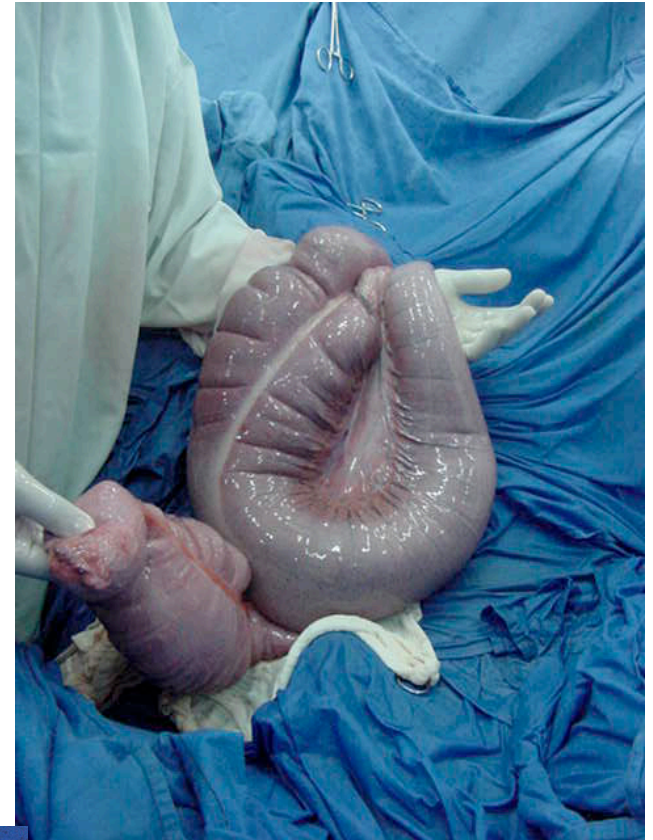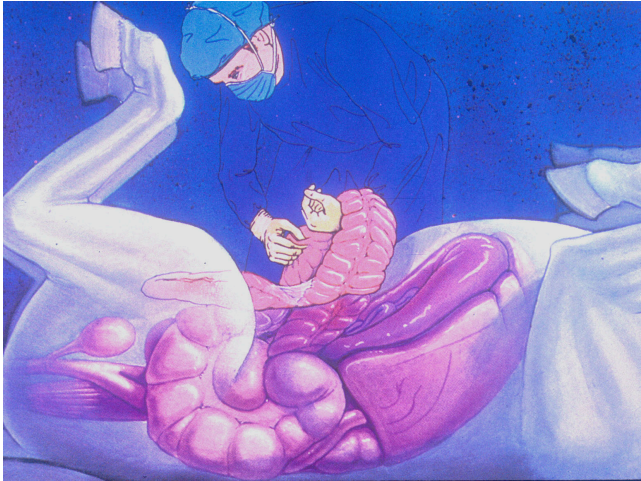flexura  
pélvica

flexura  
diafragmática

- Exteriorização:
  - cólon maior / flexura pélvica


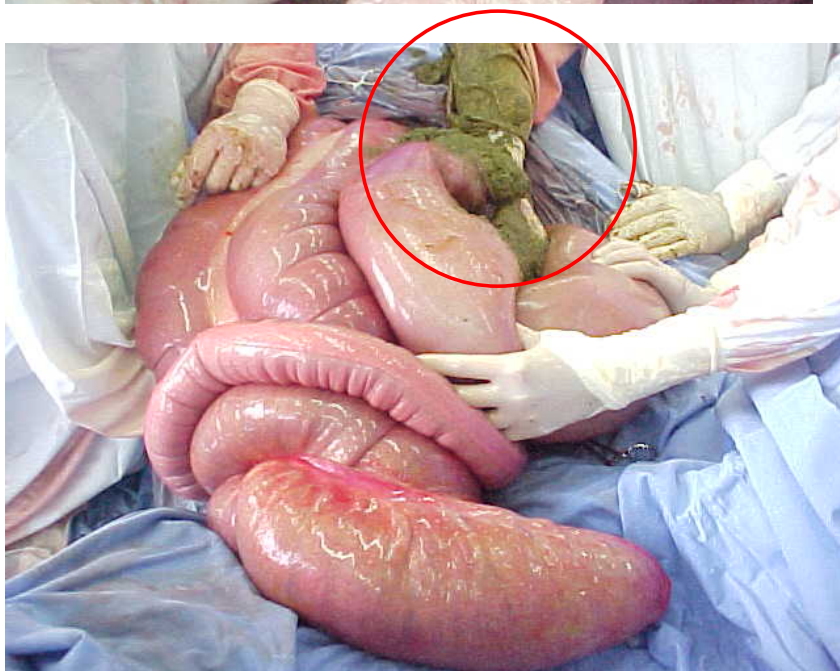
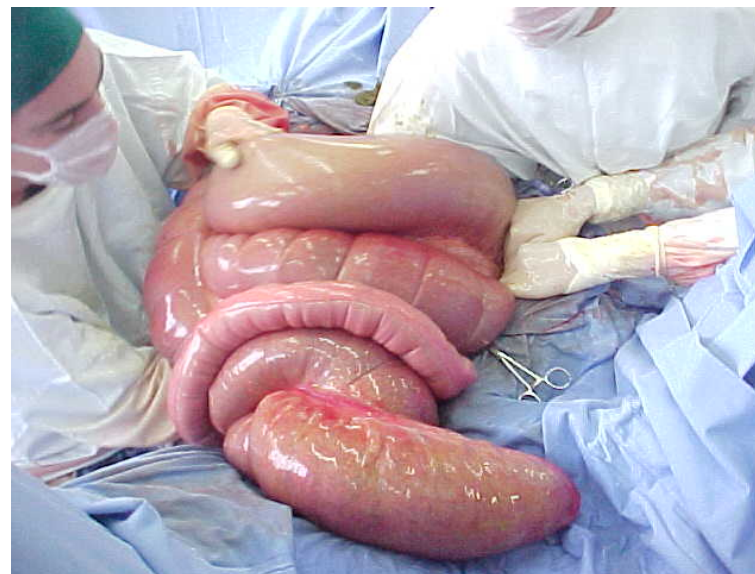

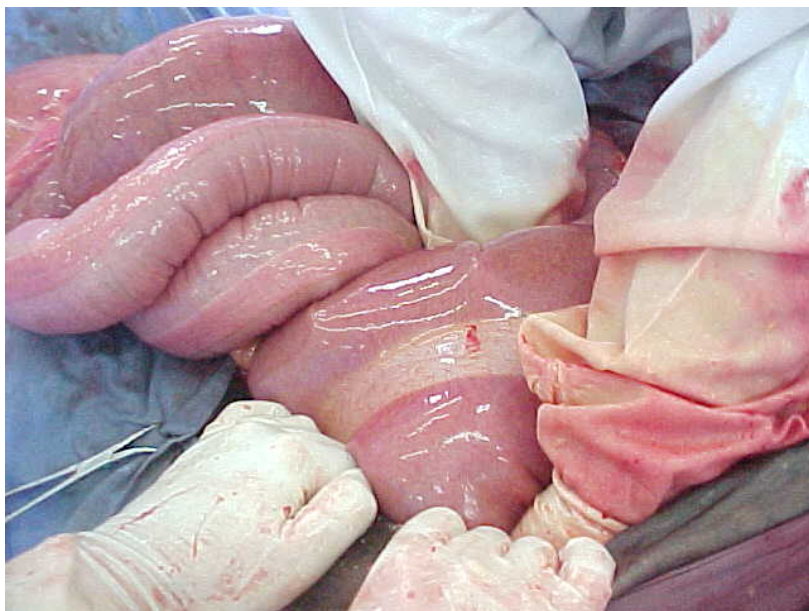


- Manipulação das alças:
  - tracionamento



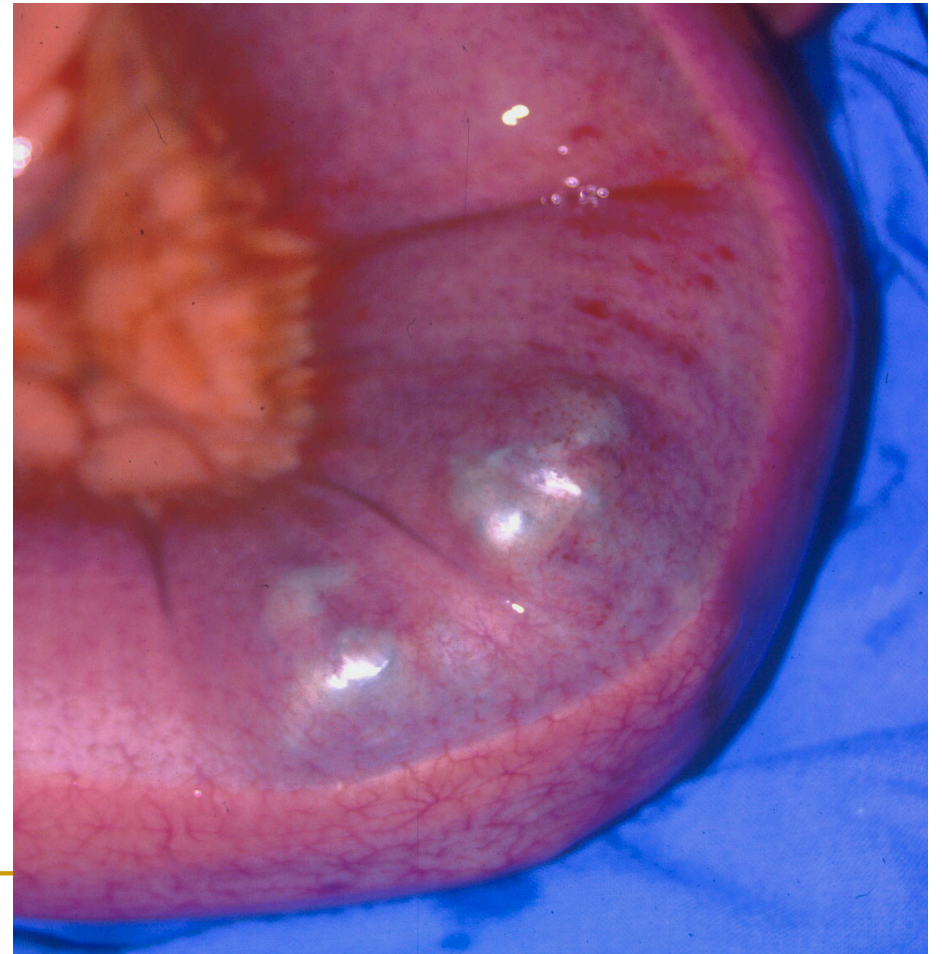
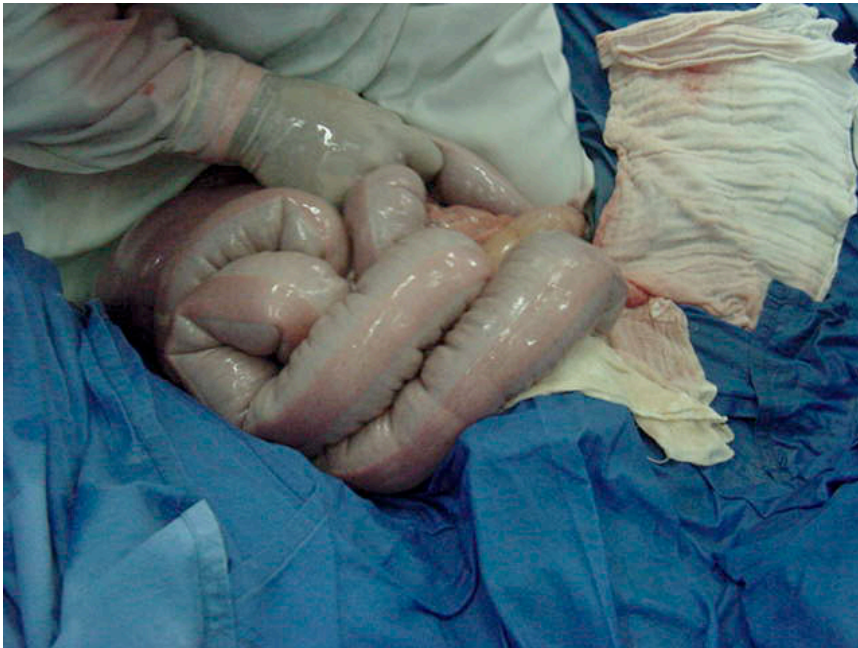
# Exposição do cólon

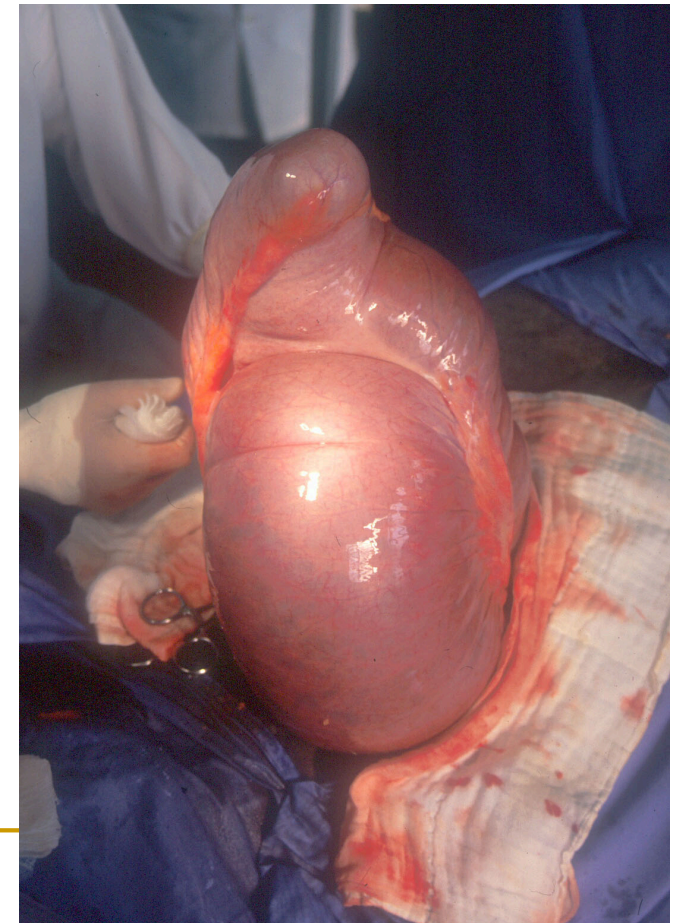

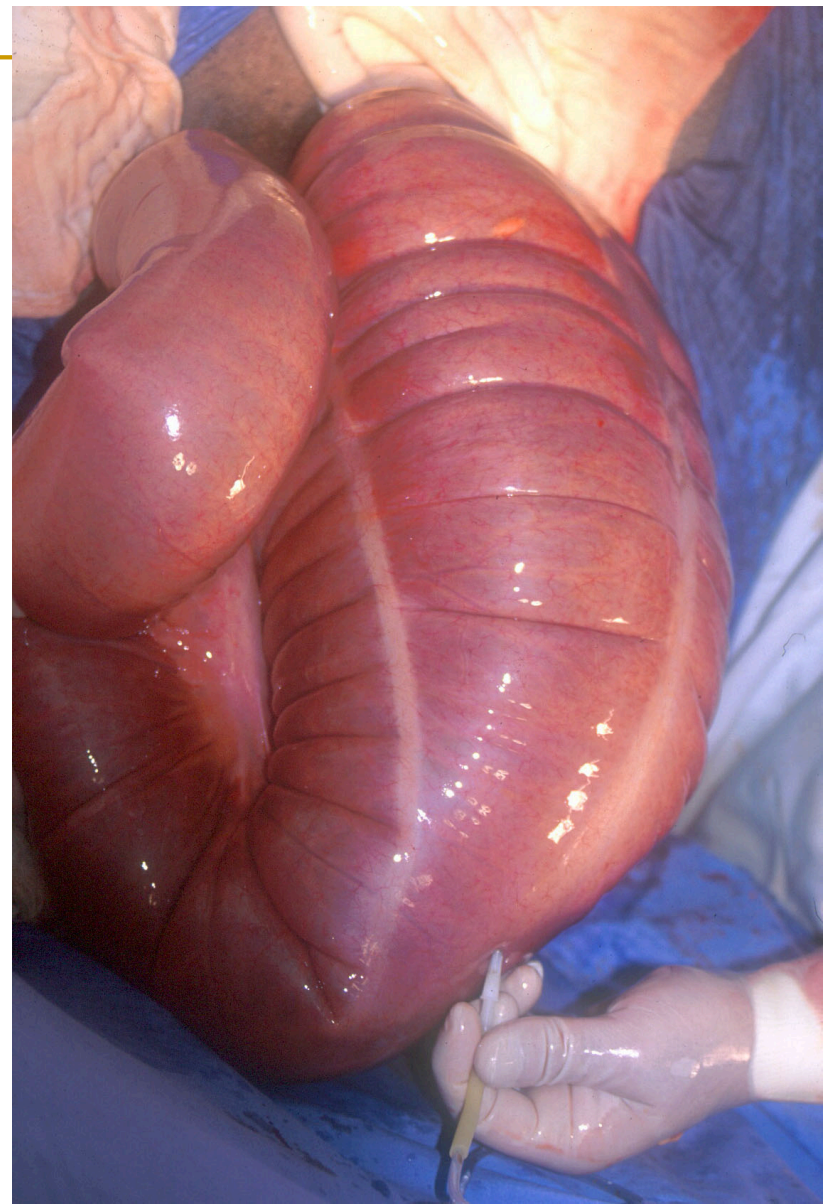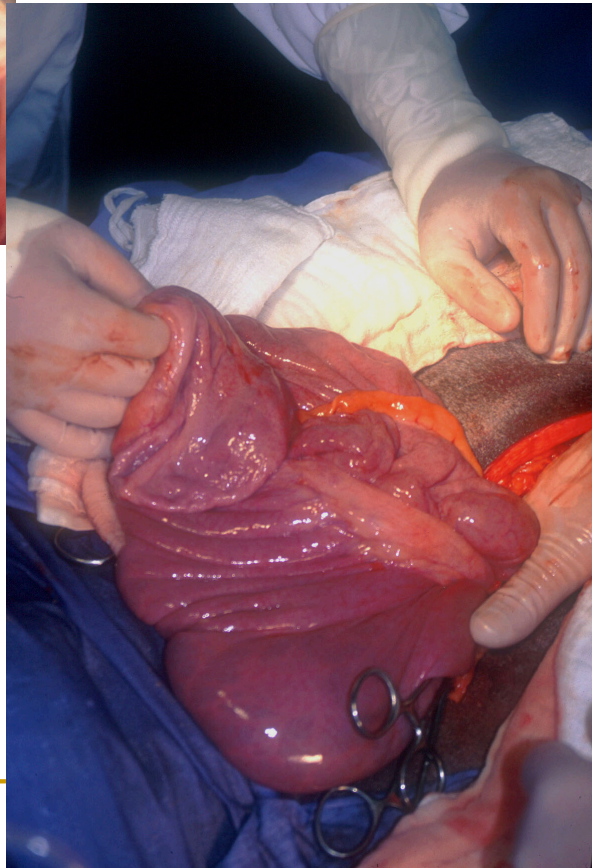
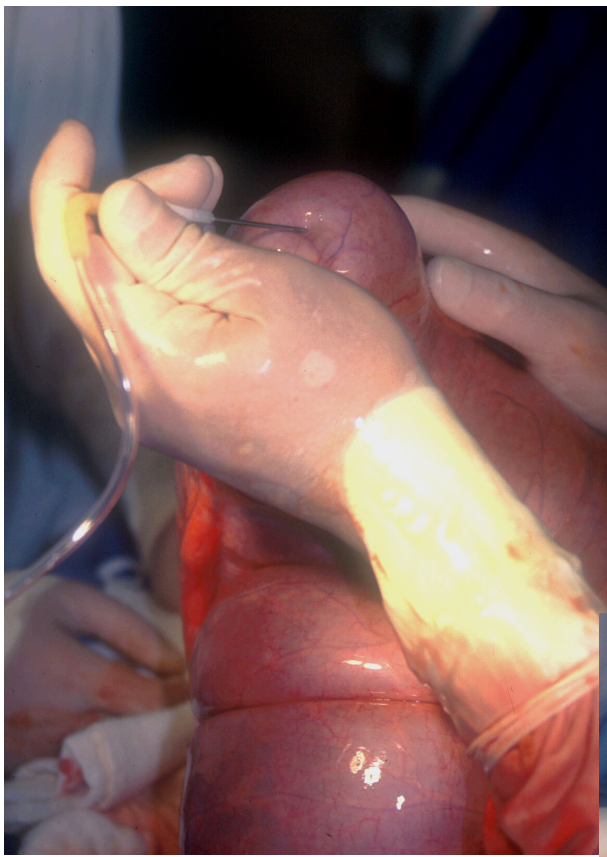
**CUIDADO !!!**

- Exteriorização:
  - cólon menor.



- Drenagem de ceco/  
cólon maior:
  - agulha 40x16 e equipo
  - ápice
  - não é necessário suturar





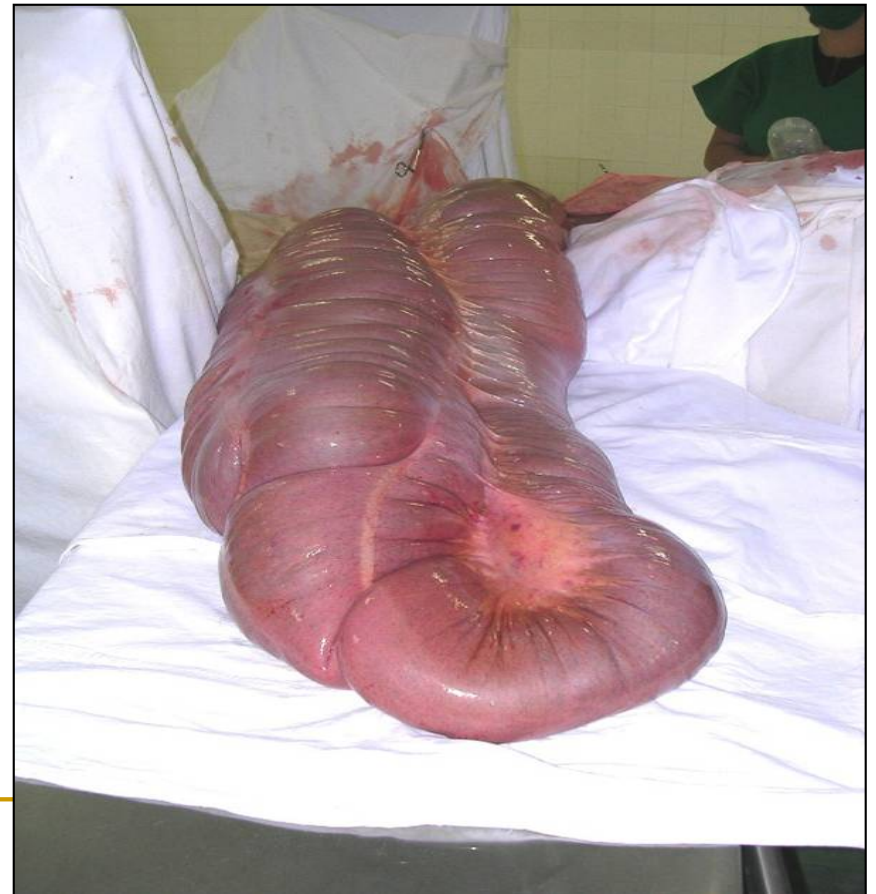- Enterotomia:

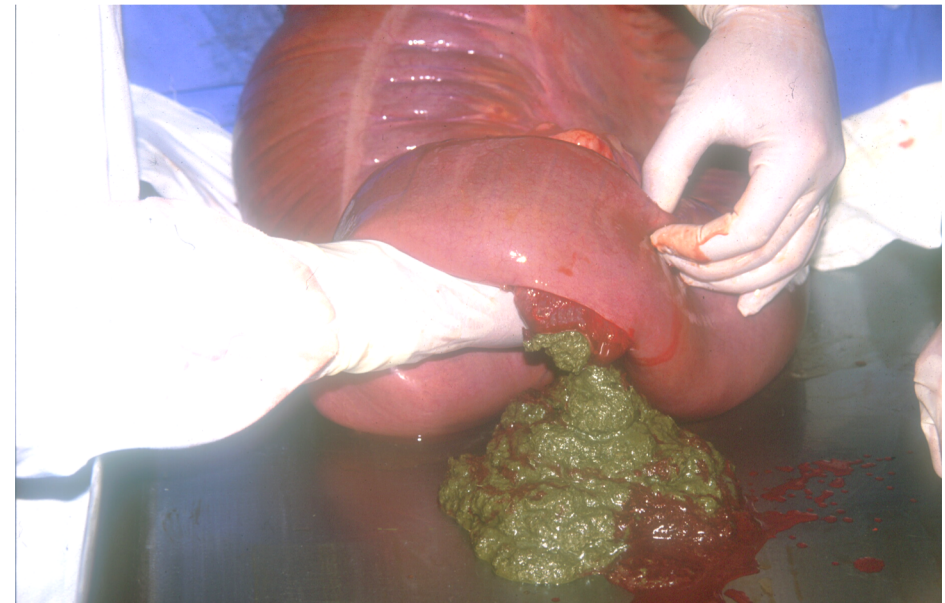
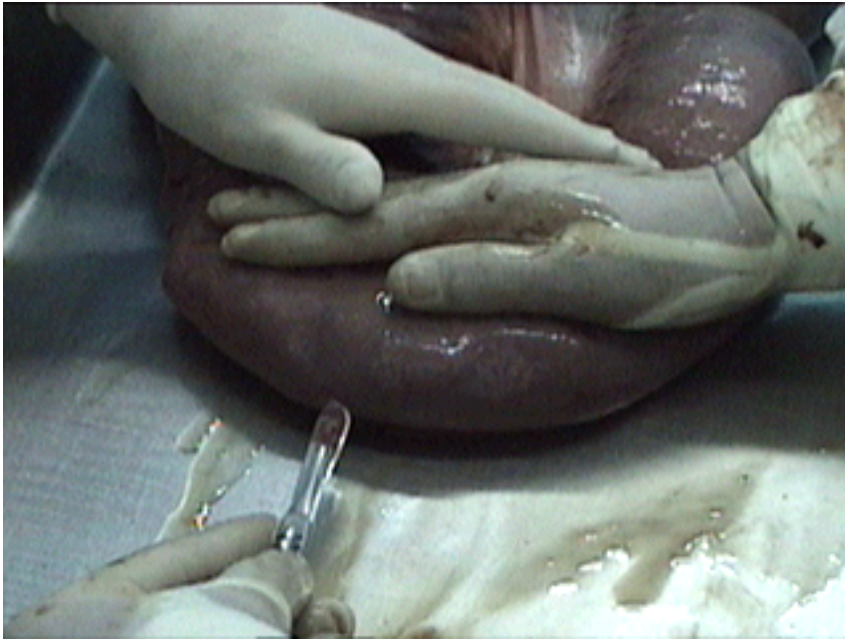
- flexura pélvica: retirada de enterólitos, lavagem do cólon



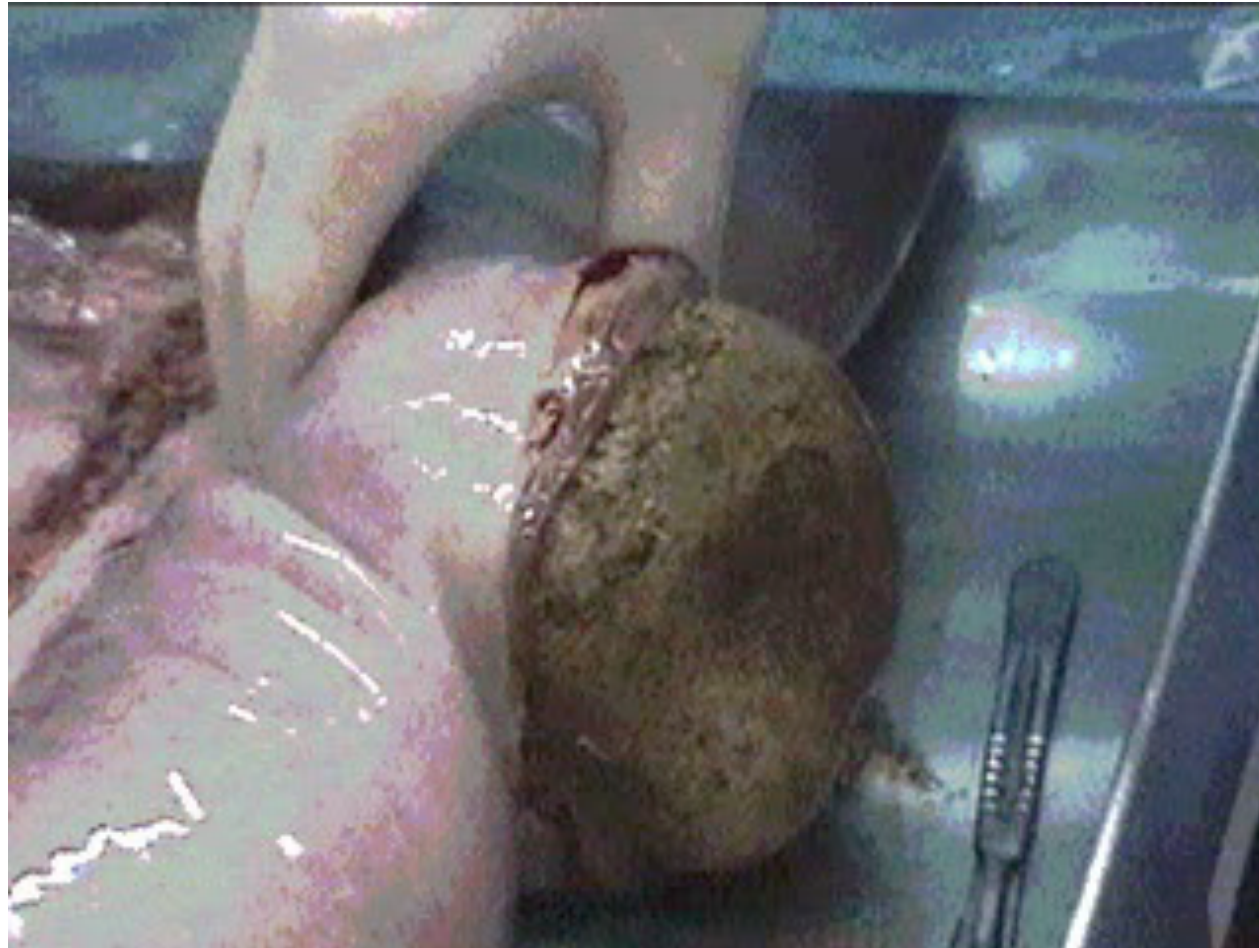
# LAPAROTOMIA MEDIANA VENTRAL

- Exteriorização do cólon maior



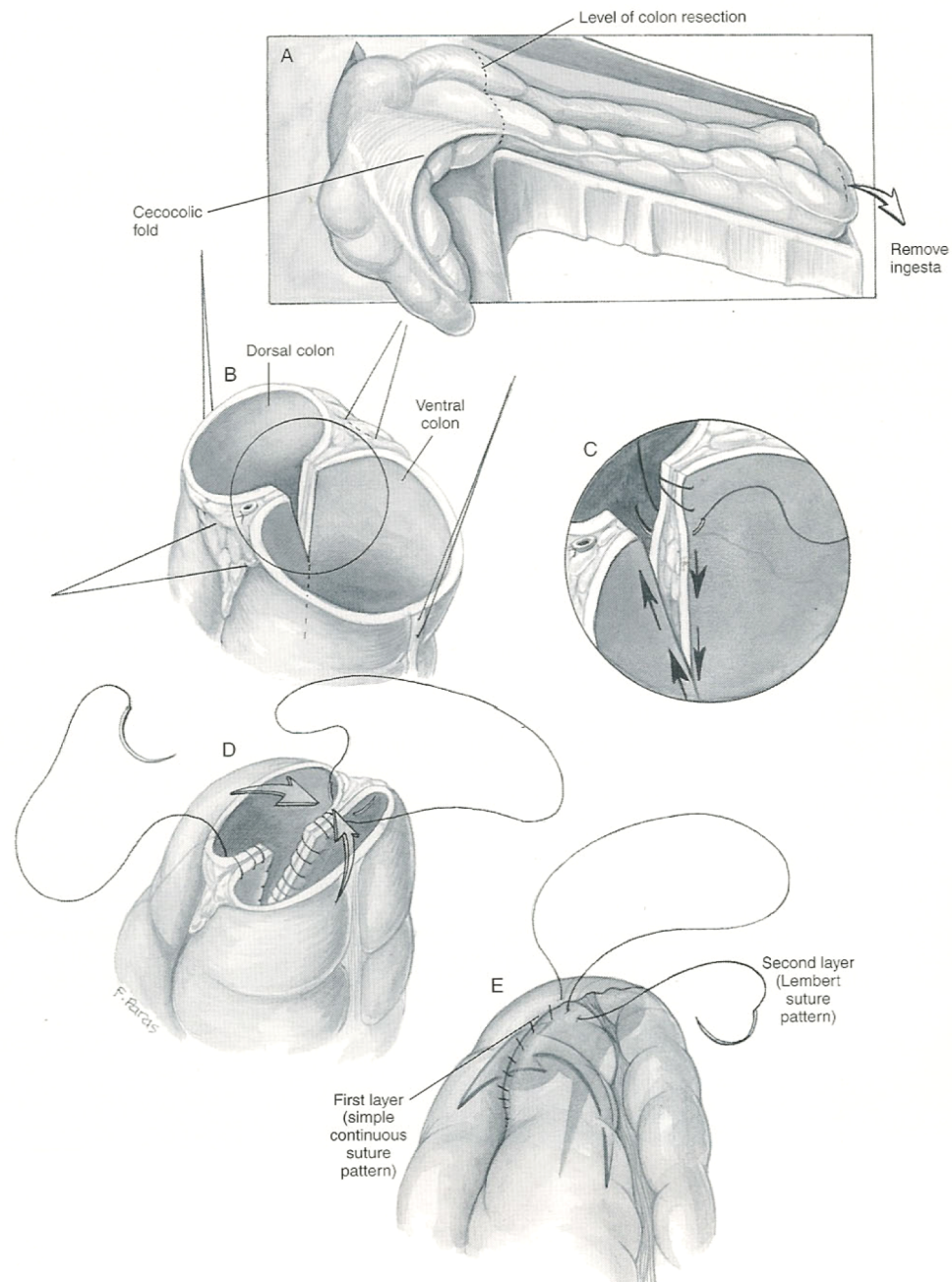
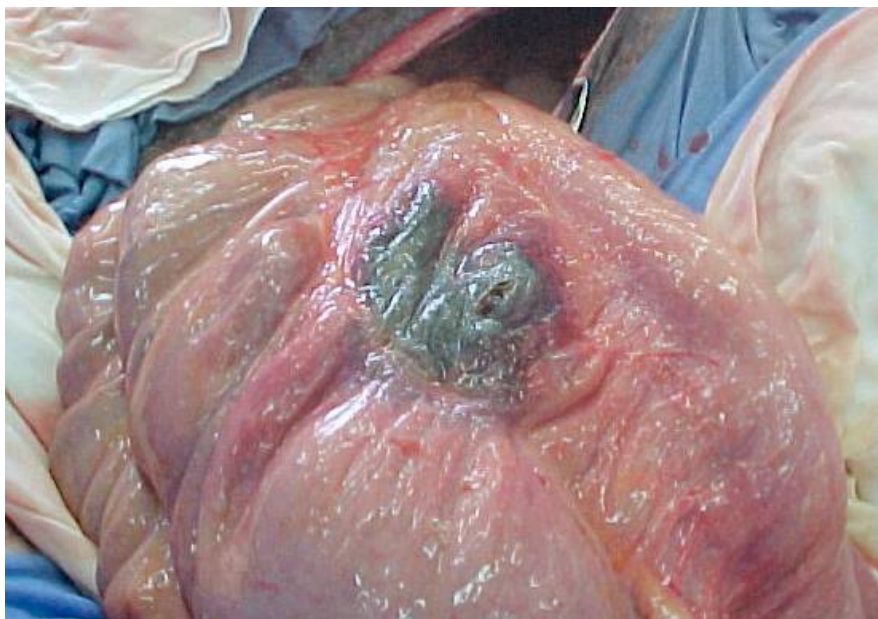

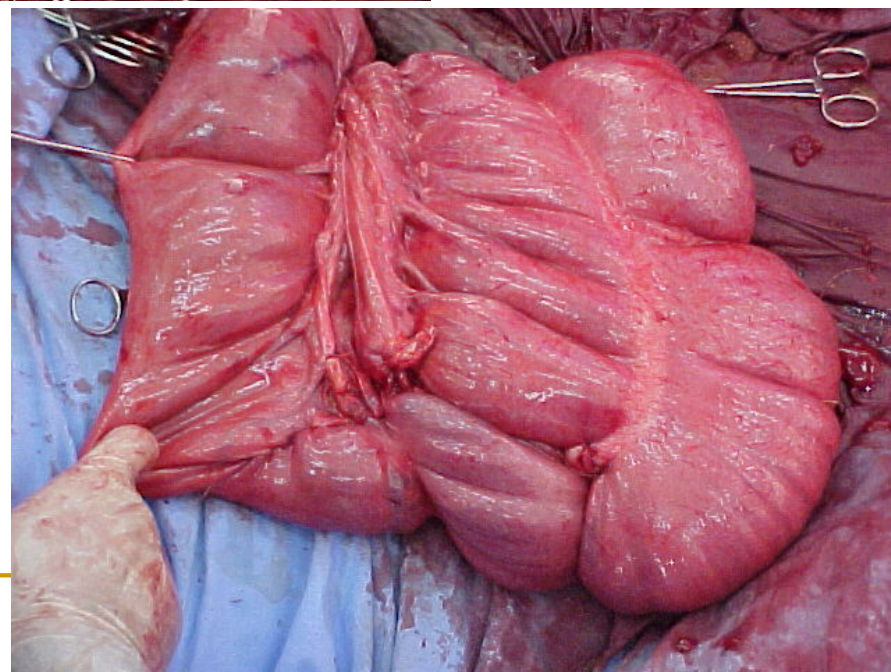
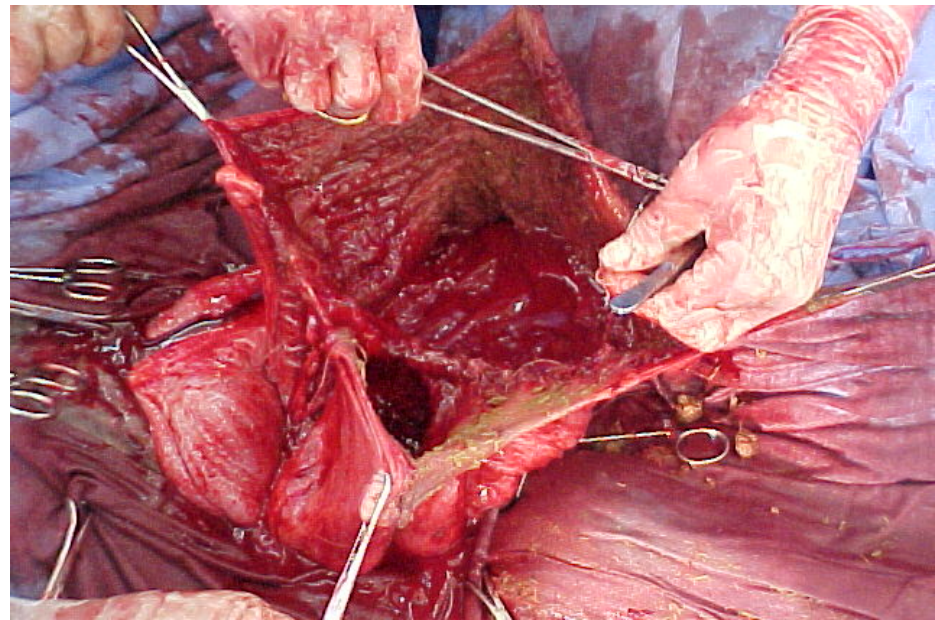
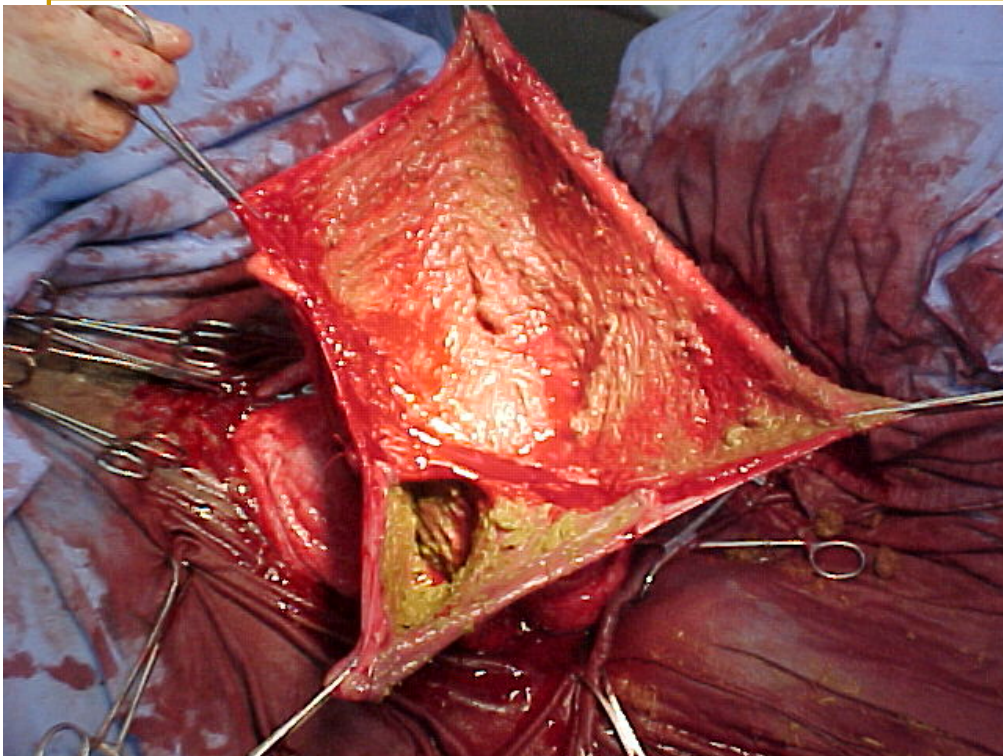
- Enterotomia:
  - sutura em dois planos
  - limpeza



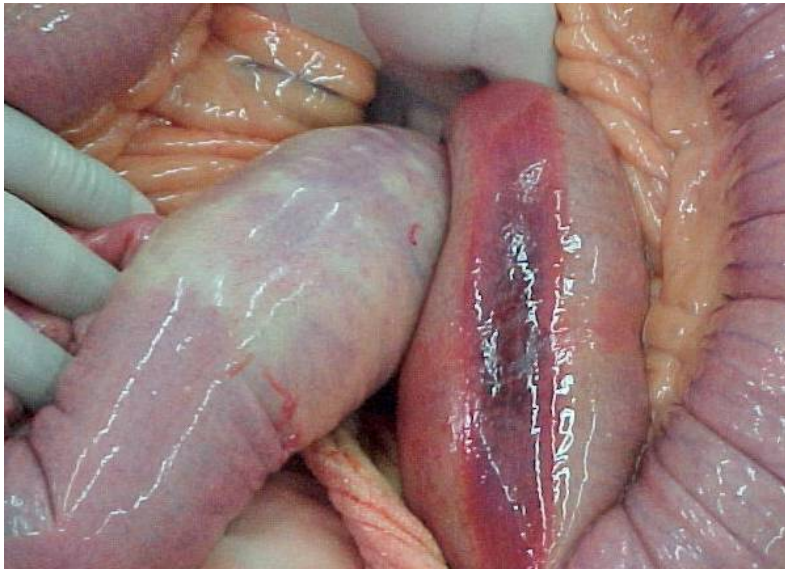


# *Ressecção de cólon maior*



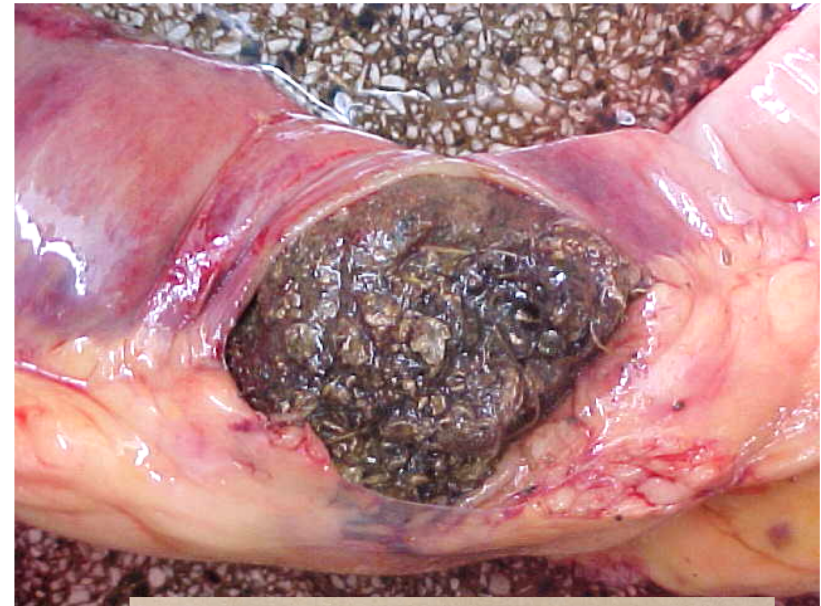

## *Enterotomia de cólon menor*

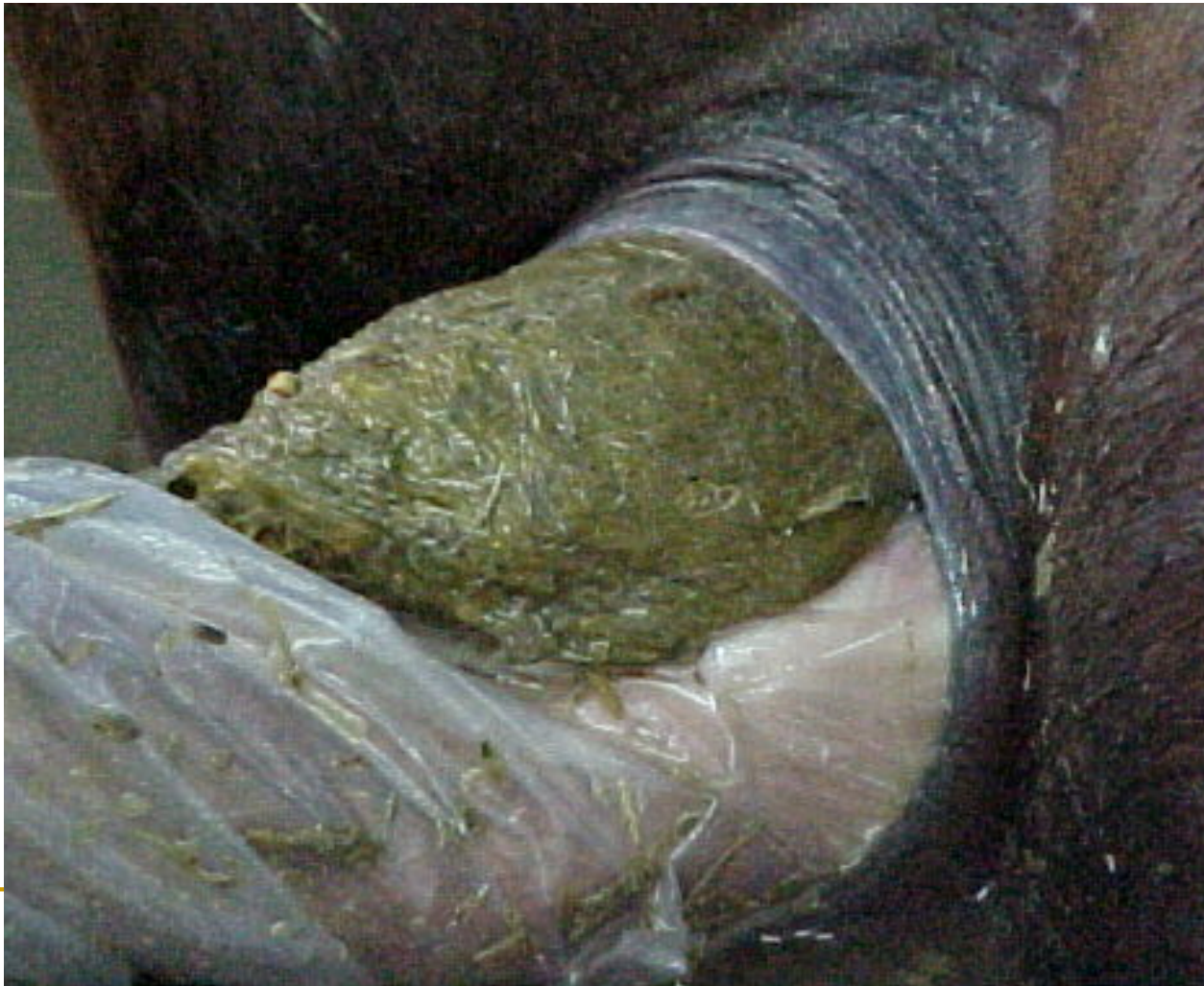

**Compactações**

## *Ruptura de cólon menor*

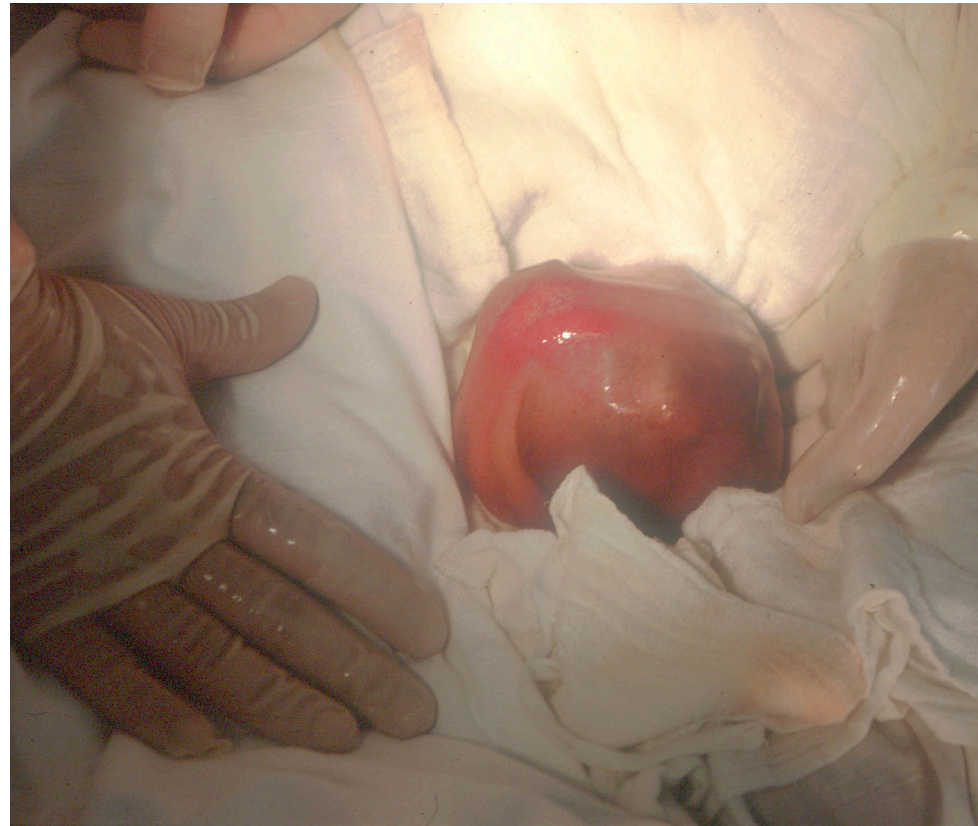

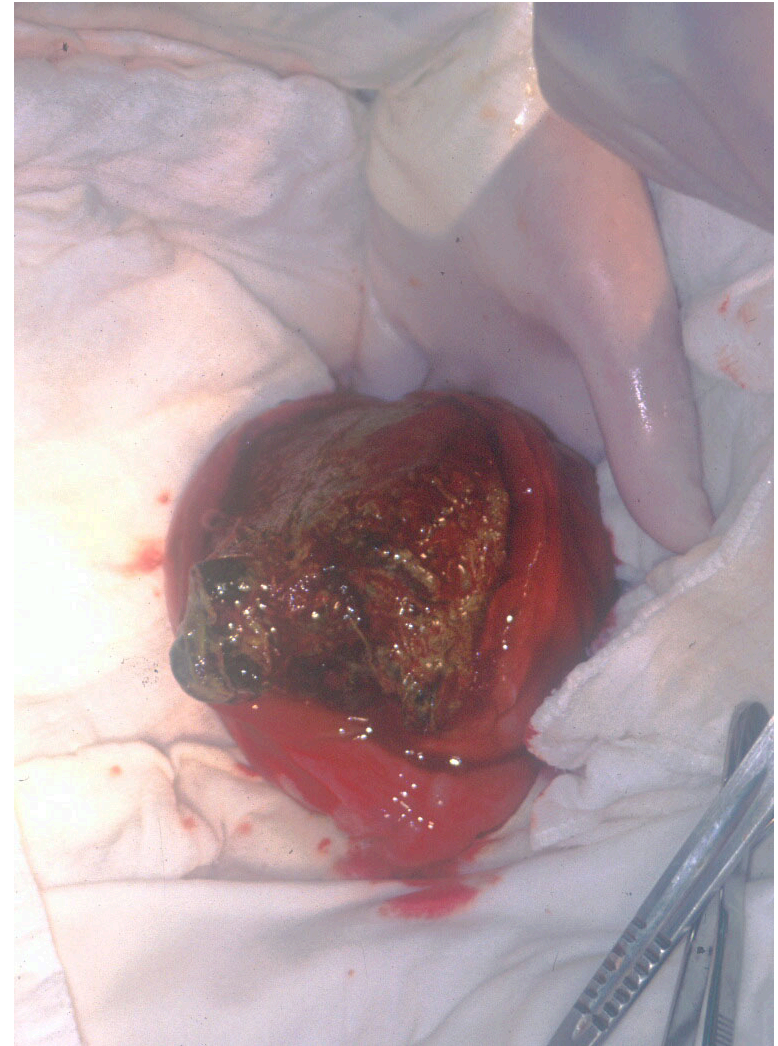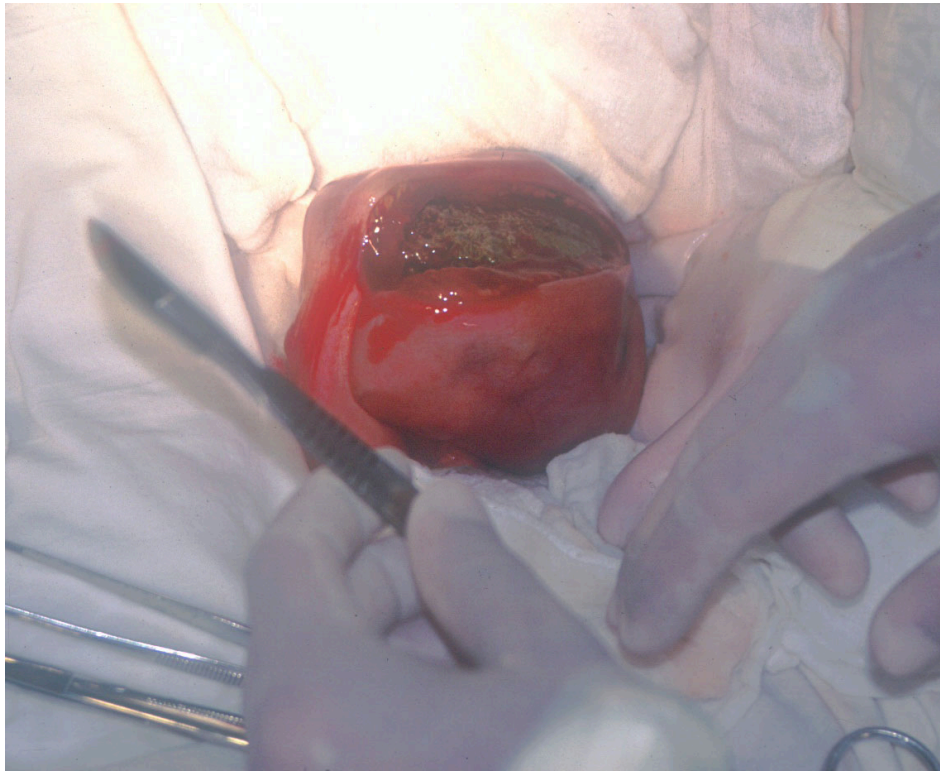# ***Enema e massagem de cólon menor***

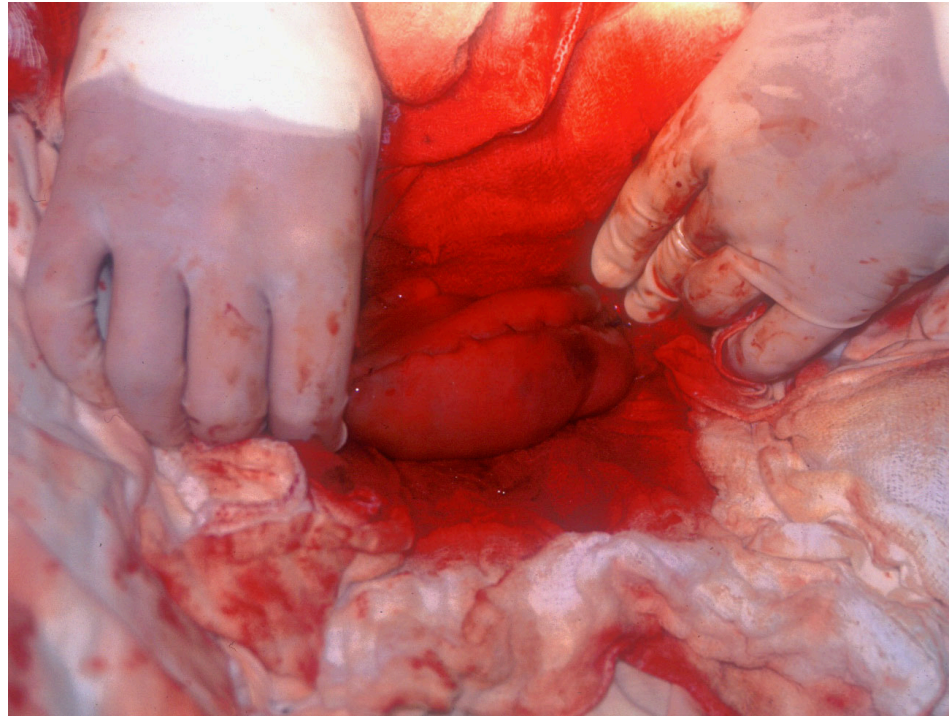
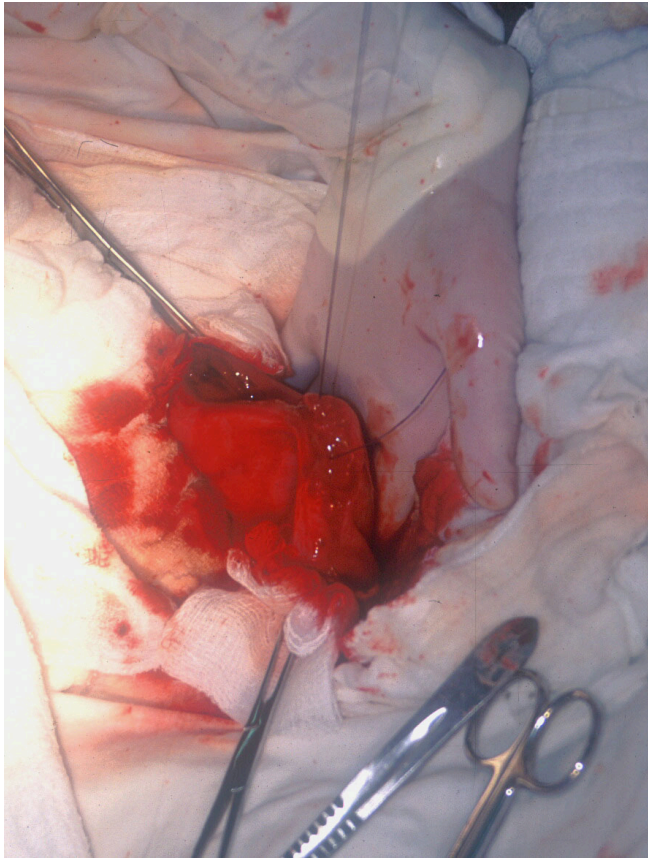


# Laparotomía: técnica

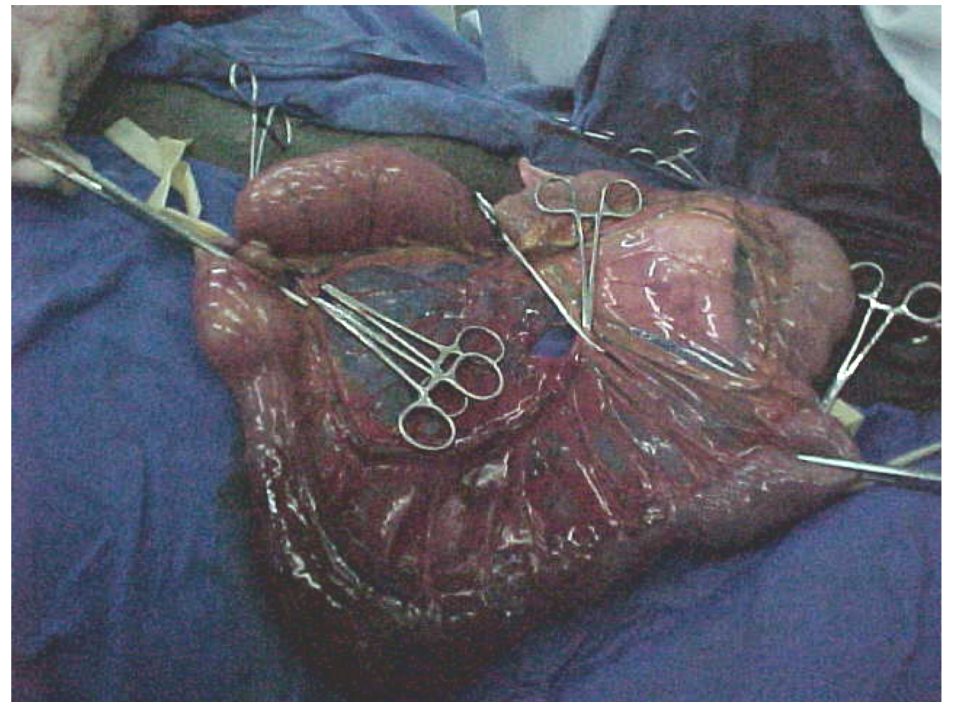
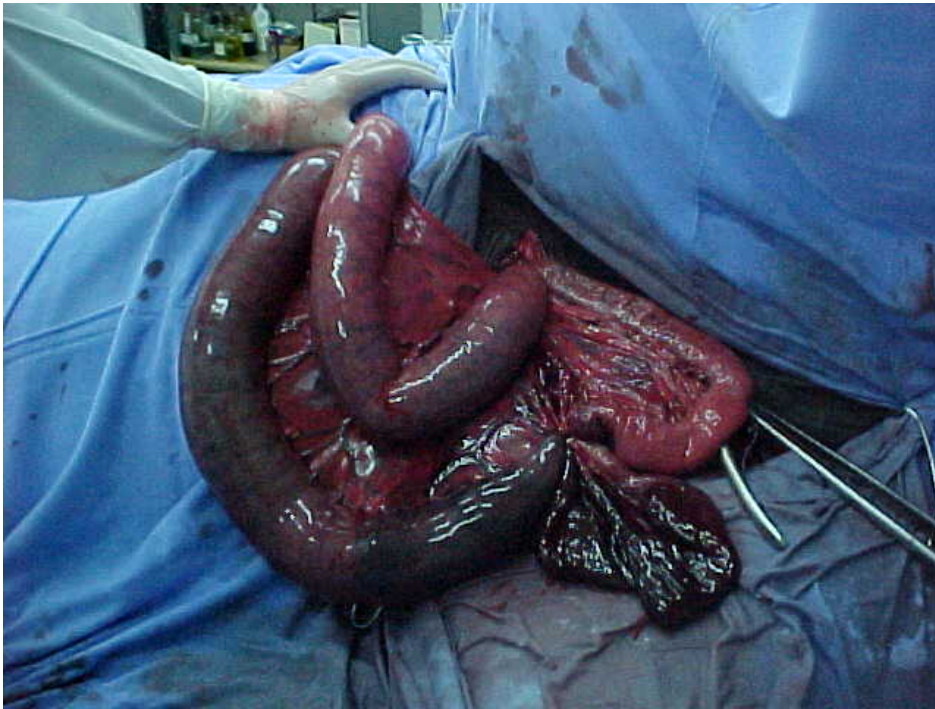
- Enterotomía:
  - cólon menor







- Enterectomia:
  - alças inviáveis;



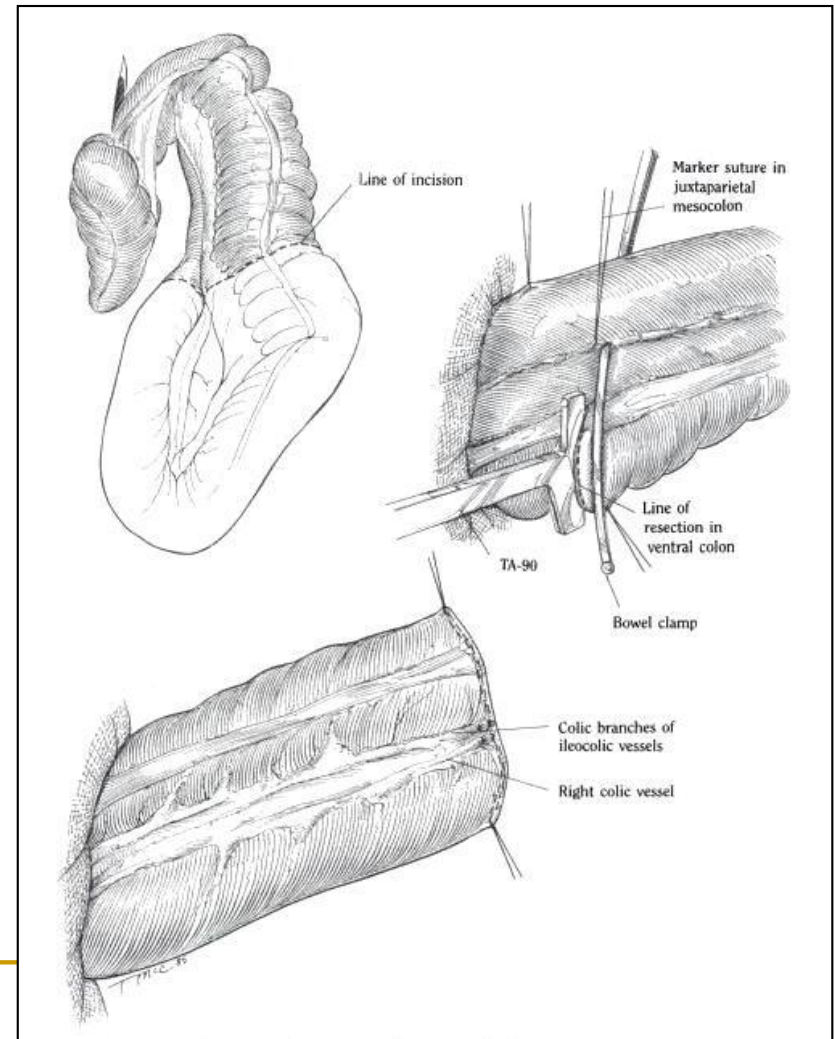
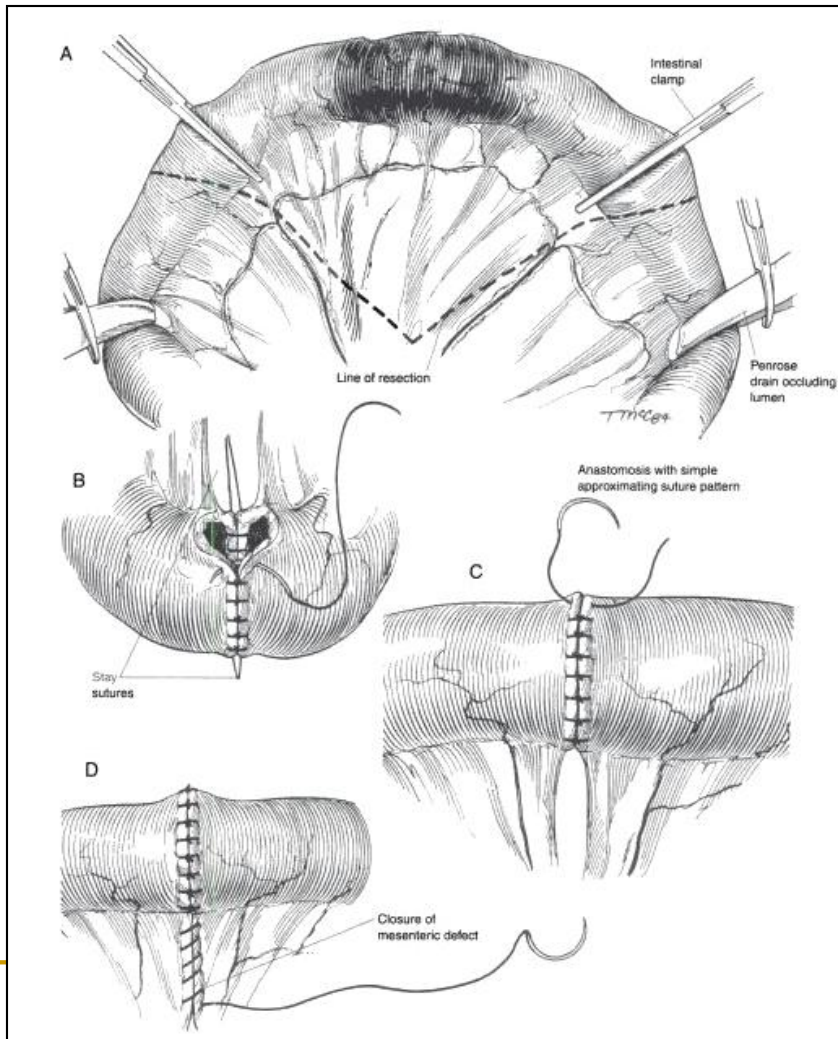


---

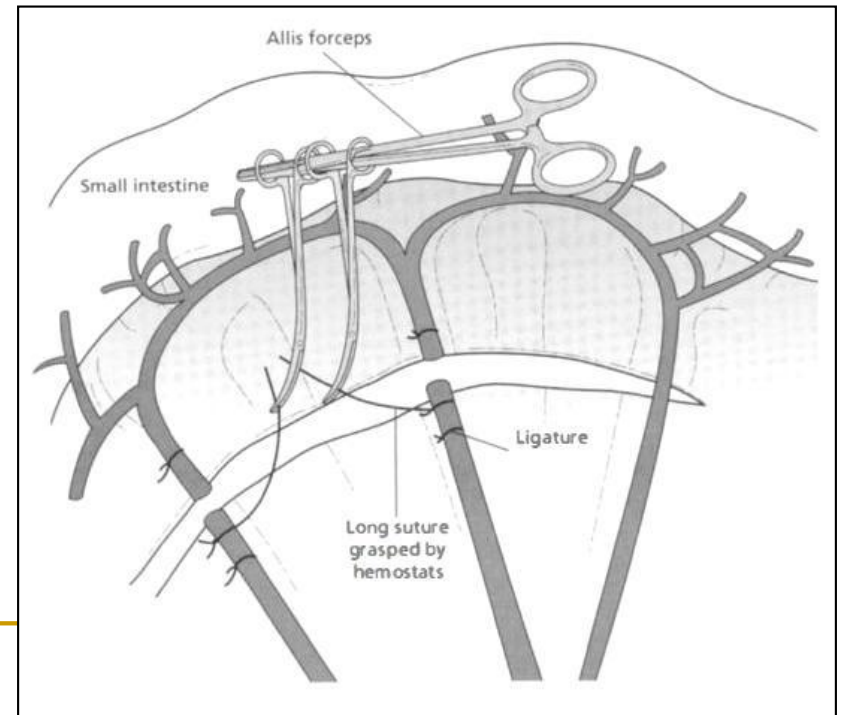
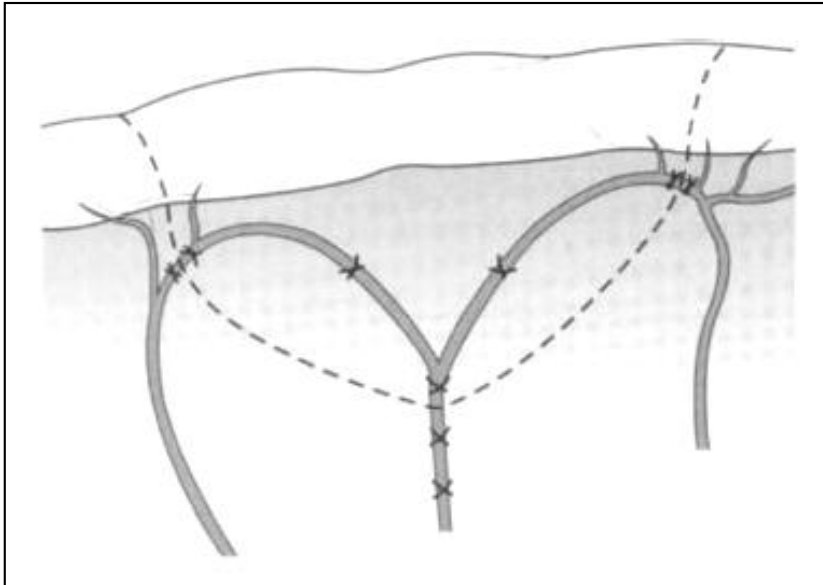
# Laparotomia: técnica

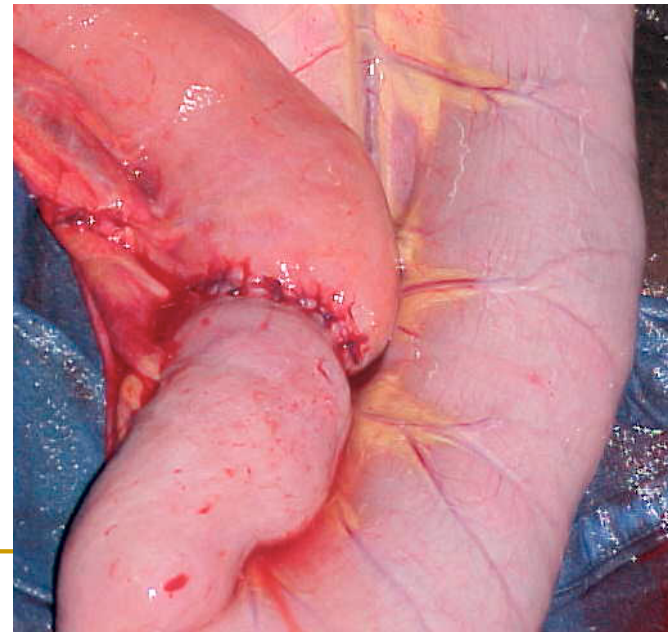
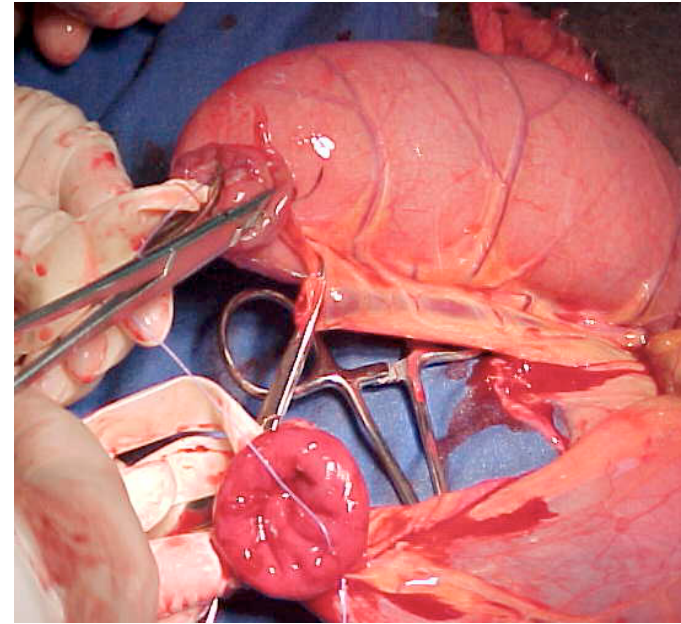
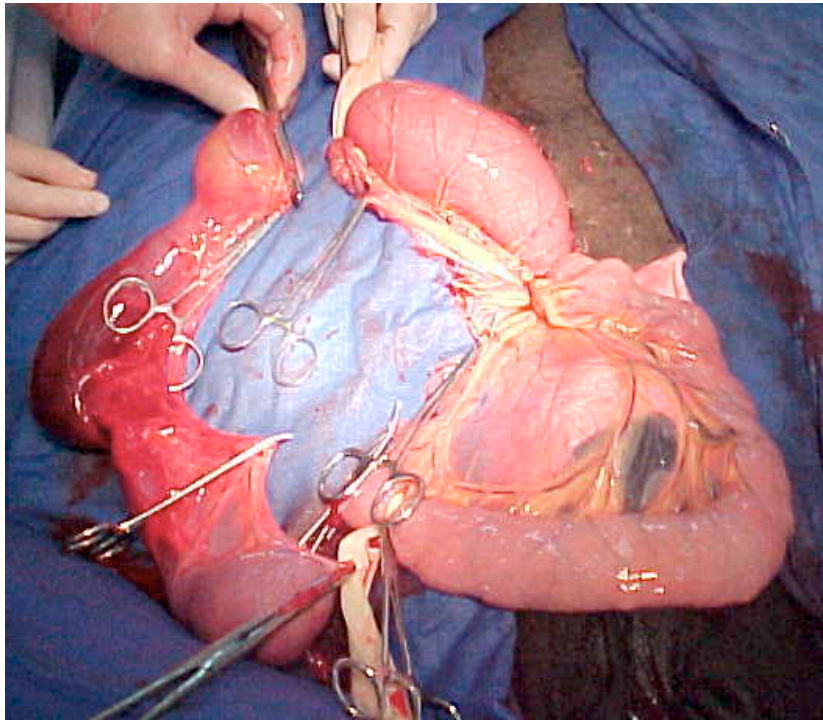
- Enterectomia:
    - enteroanastomose término-terminal
    - sutura em dois planos:
      - mucosa e submucosa
      - seromuscular
      - limpeza com sol. de P.V.P.
-

# ENTERECTOMIA / ENTEROANASTOMOSE



# ENTERECTOMIA

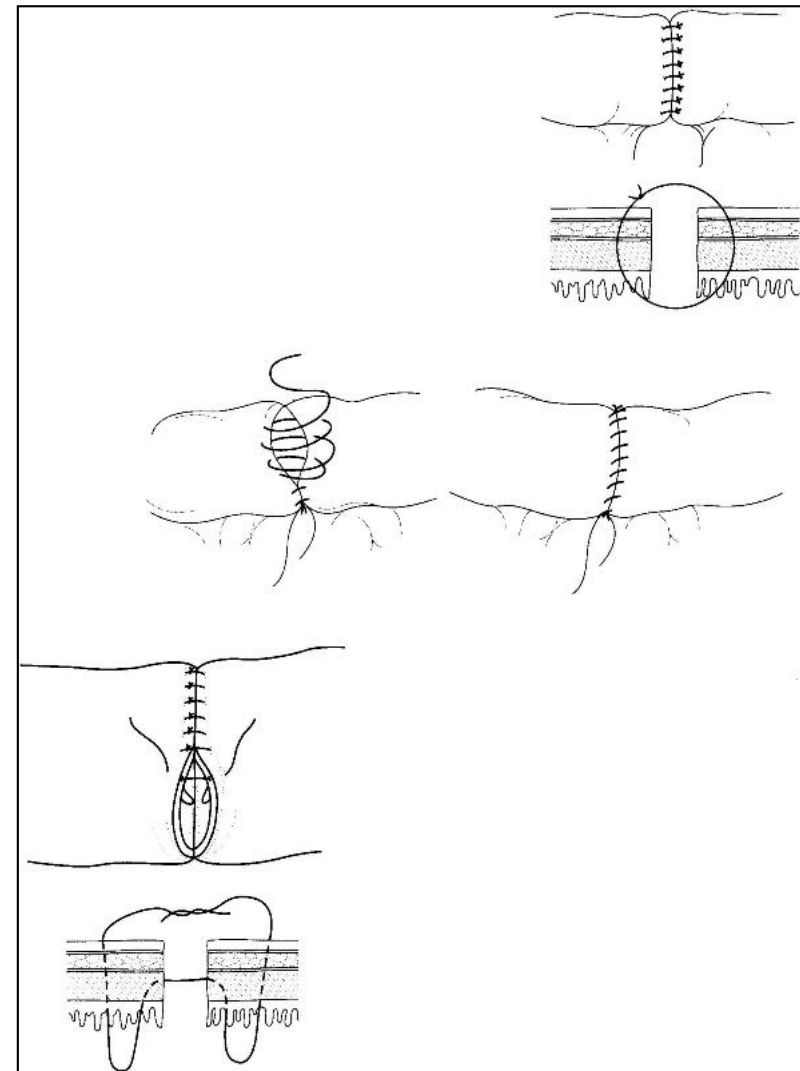
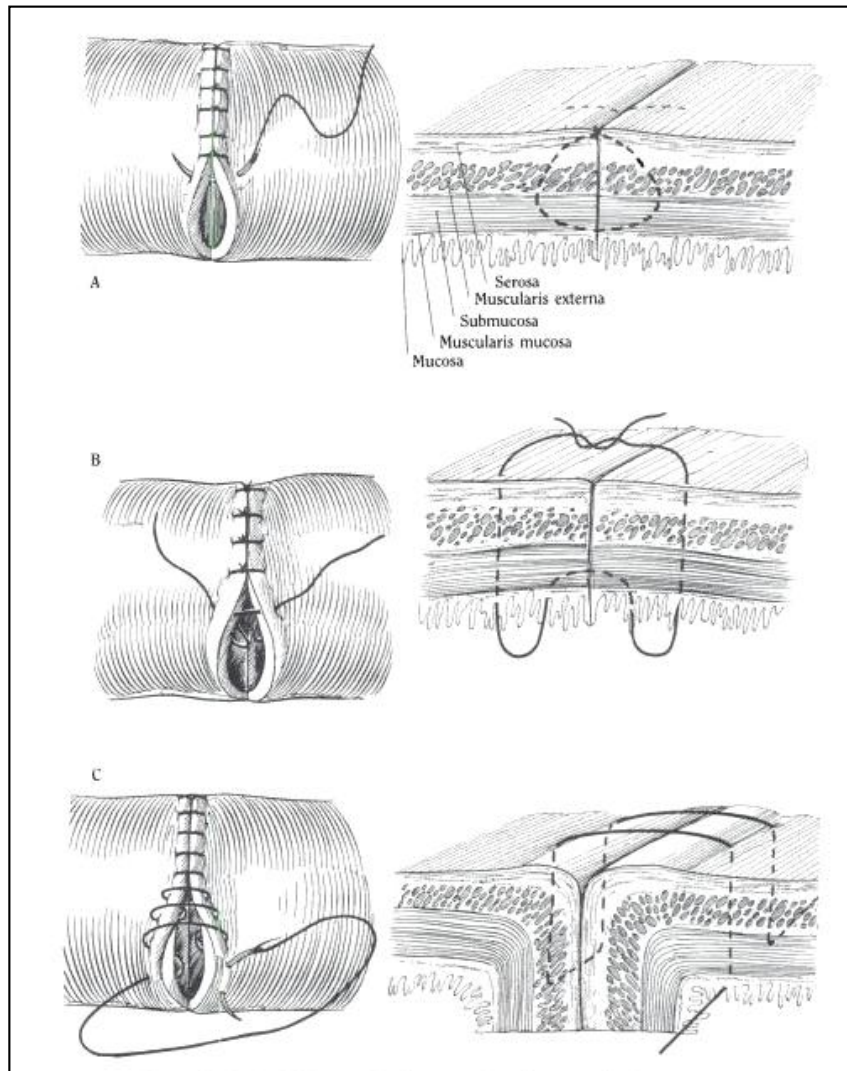




# ENTEROANASTOMOSE

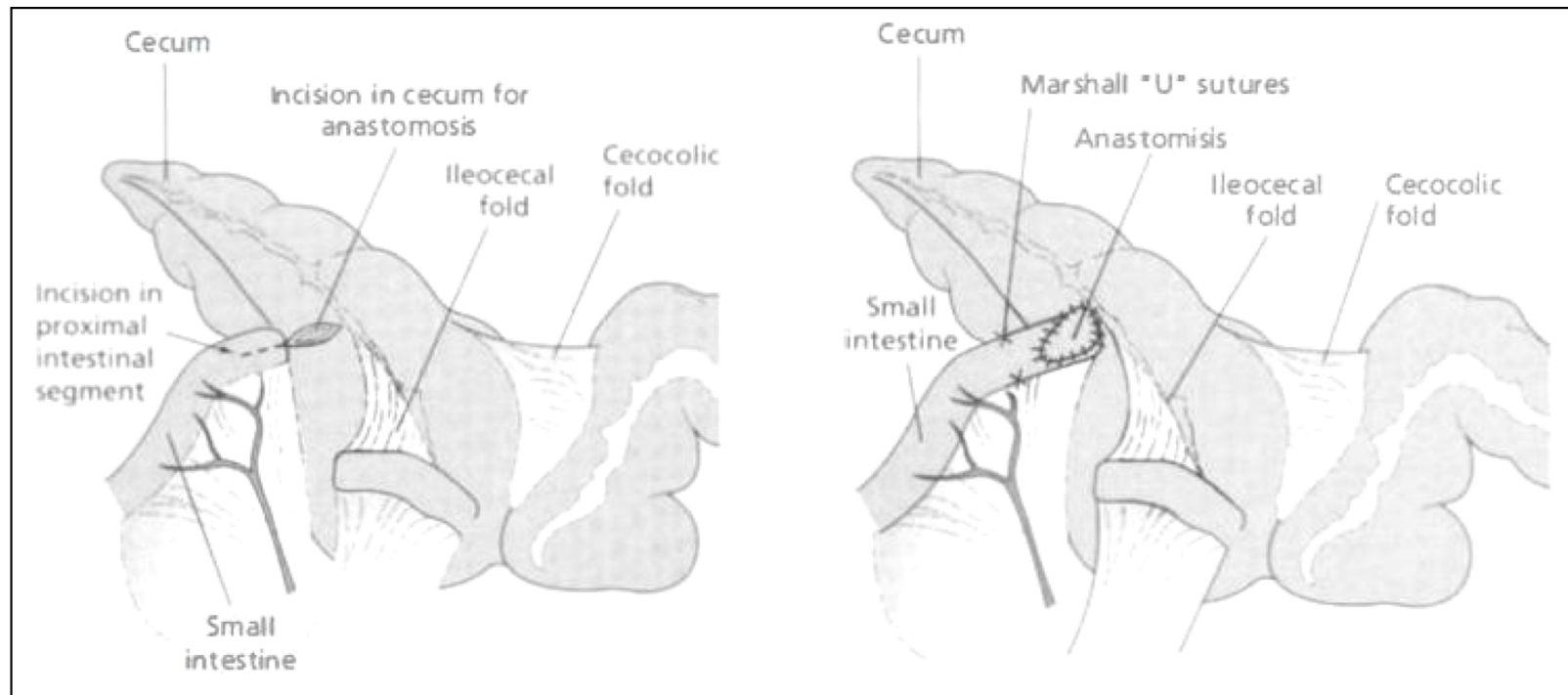
- Fio absorvível sintético
- Sutura de mucosa;
- Sutura dupla invaginante seromuscular contínua;
  - Perfurante parcial
- Sutura aposicionante + sutura invaginante seromuscular contínua;
  - Perfurante parcial;
- Sutura aposicionante ou invaginante interrompida;
  - Perfurante total.

# ENTEROANASTOMOSE



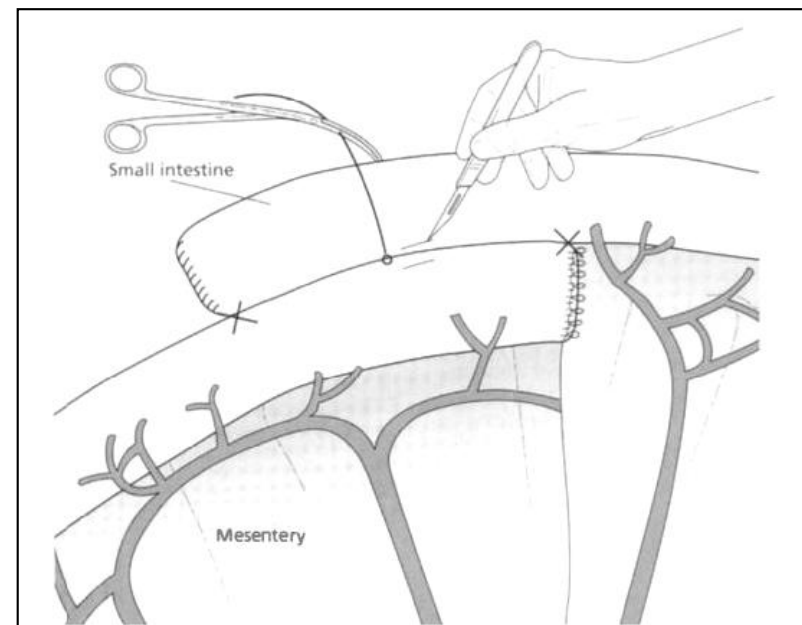
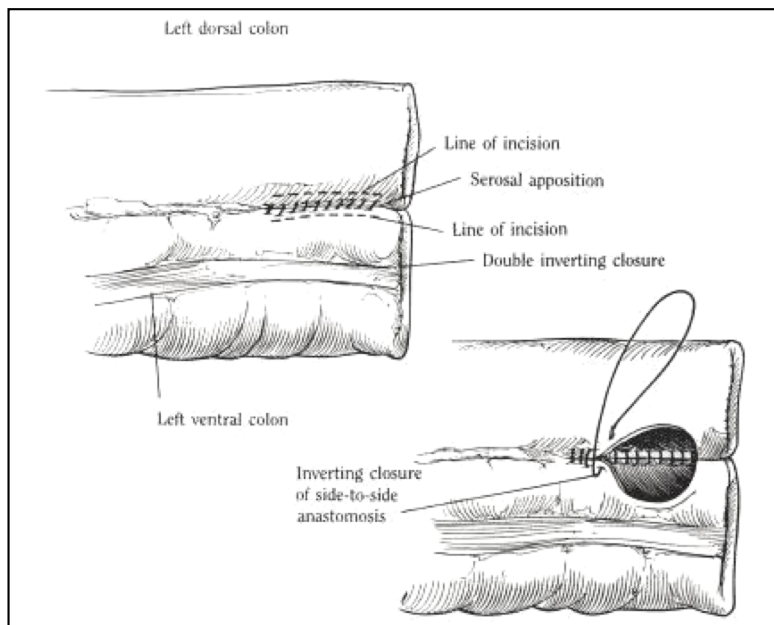
# ENTEROANASTOMOSE

- Término-lateral



# ENTEROANASTOMOSE

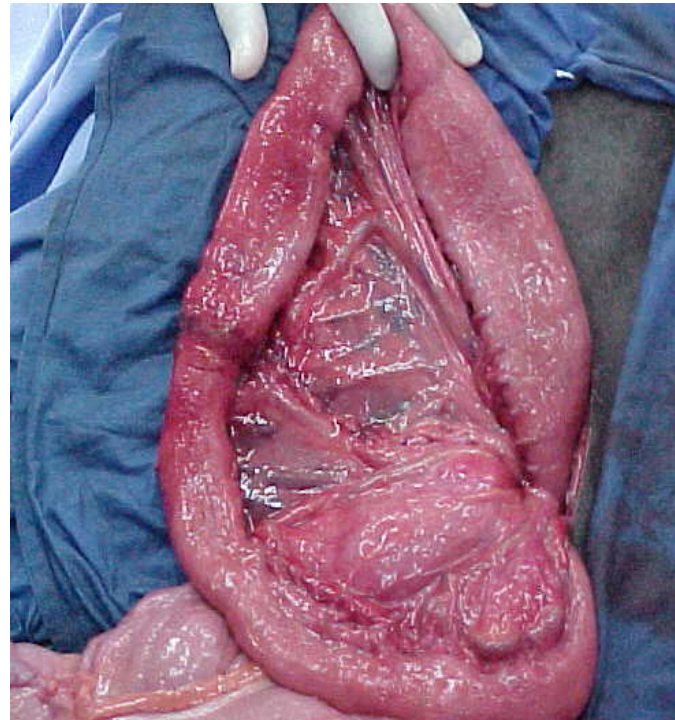
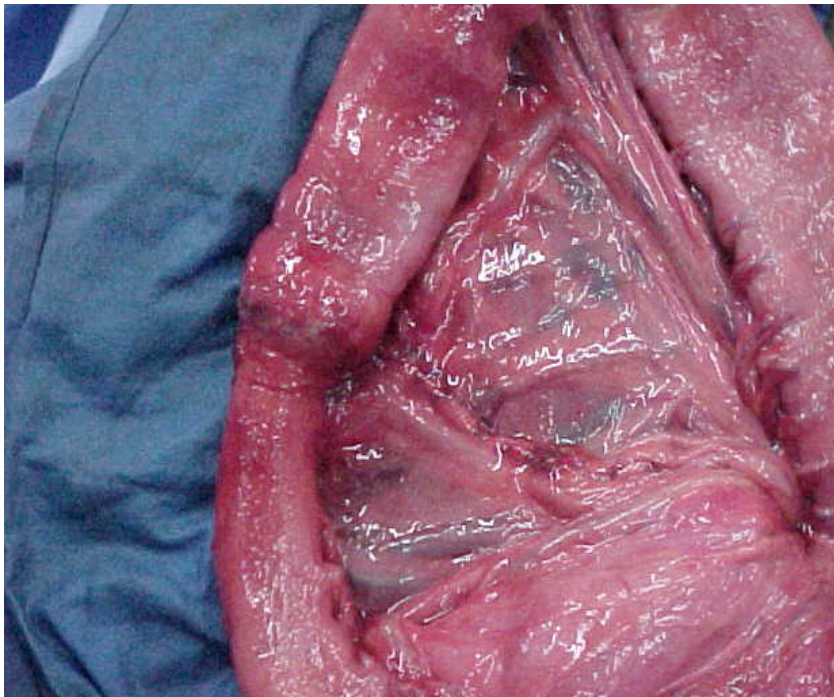
- Látero-lateral

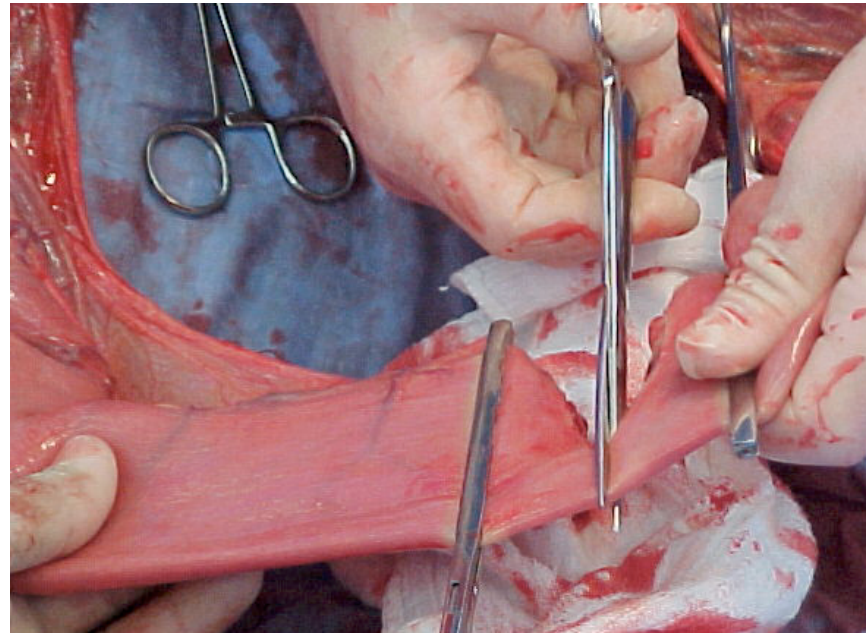
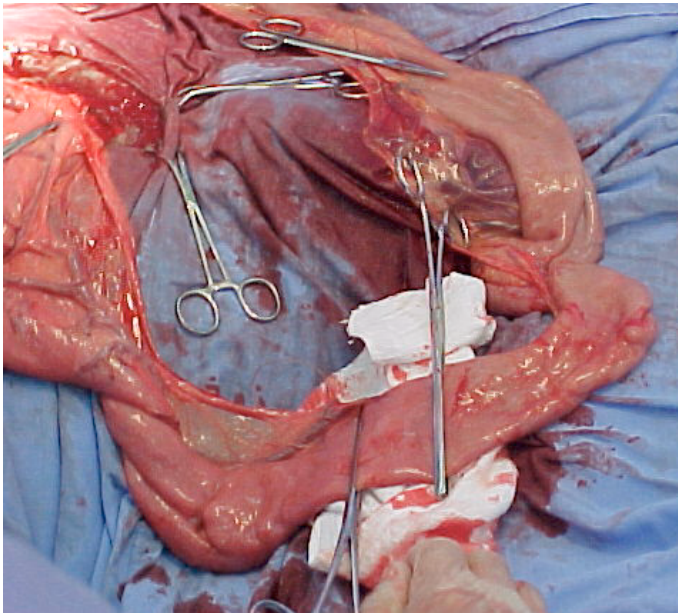


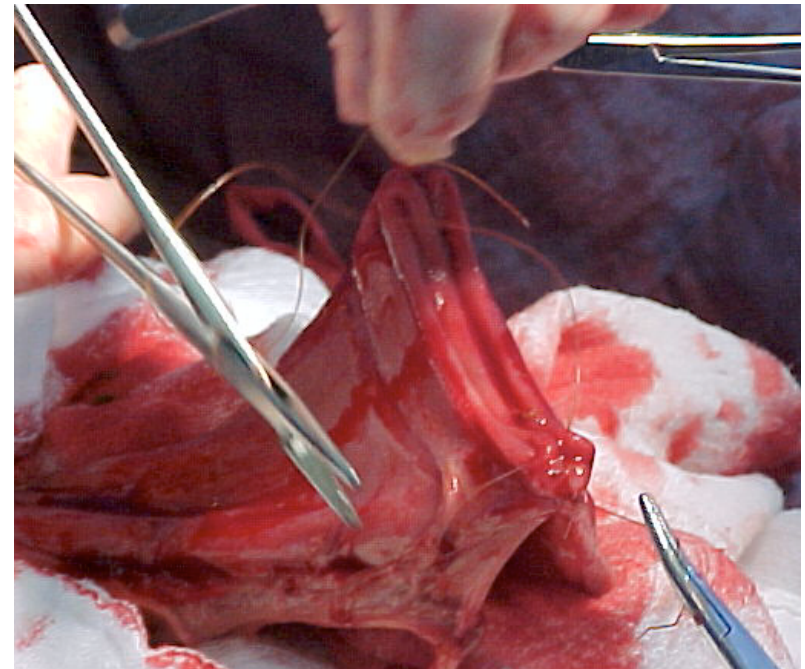
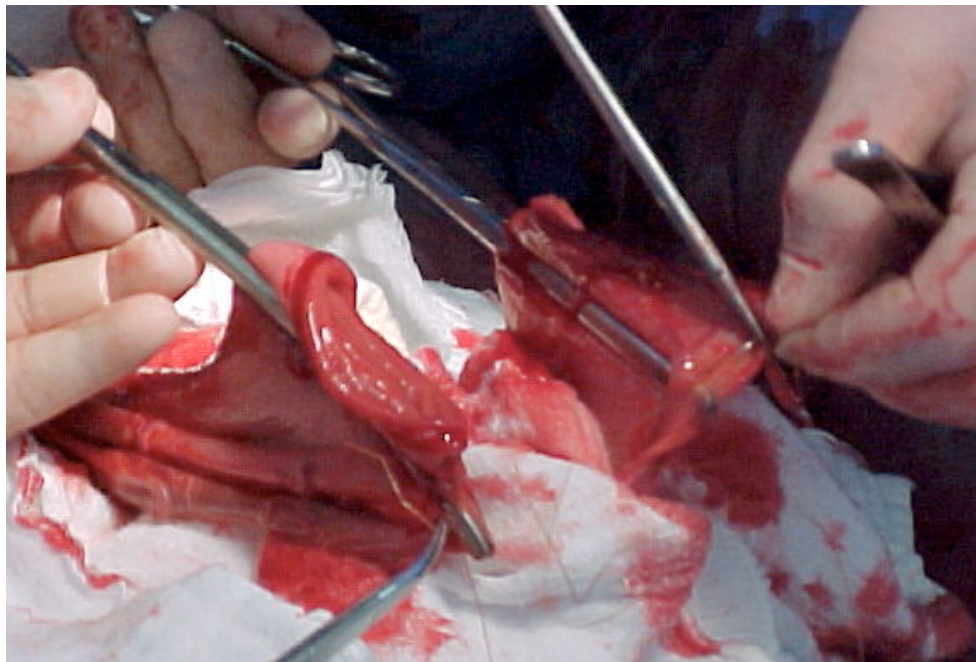

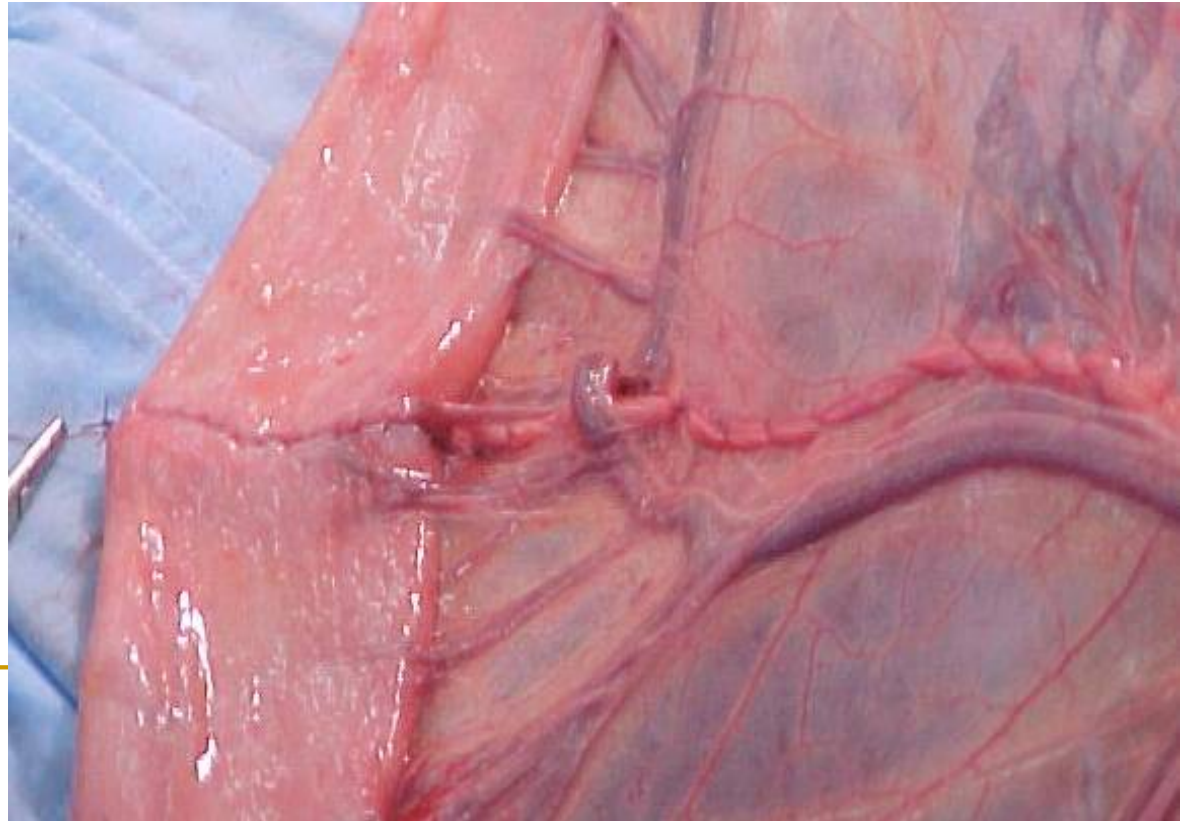
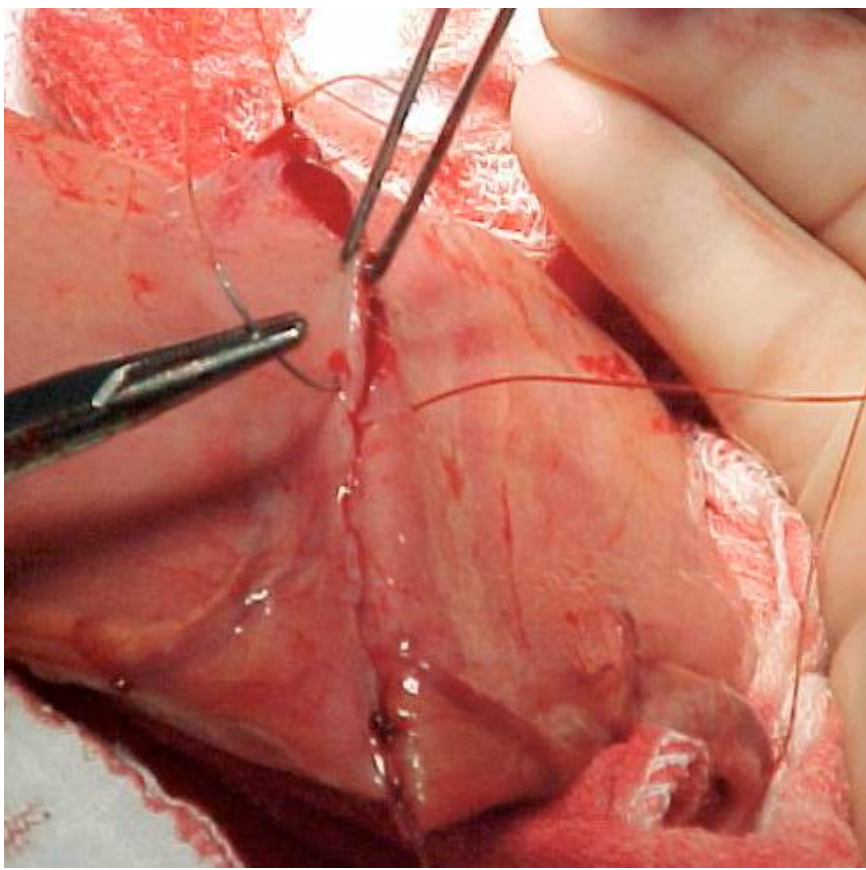
# Enteroanastomose término-terminal:

8 dias de pós-operatório

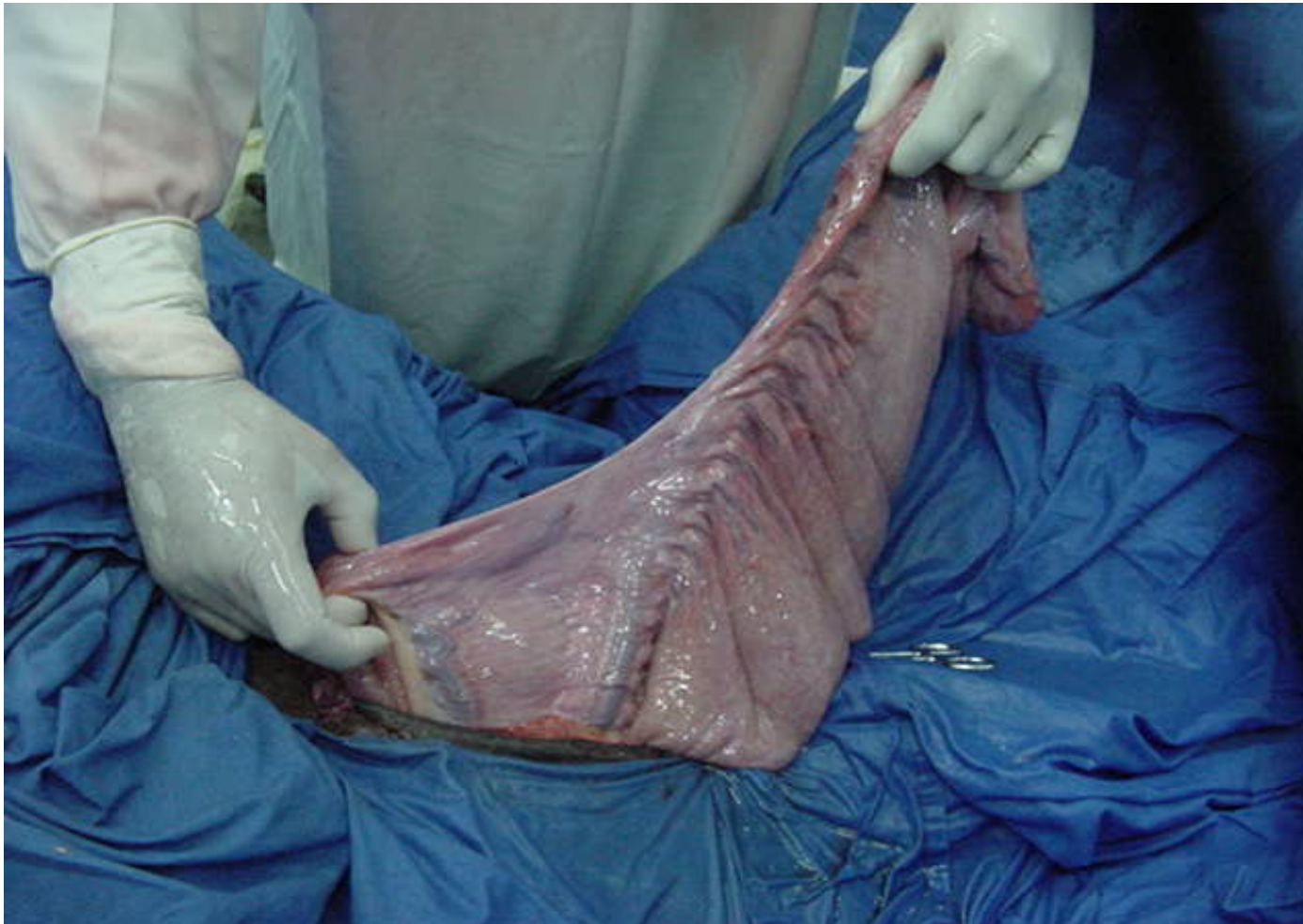



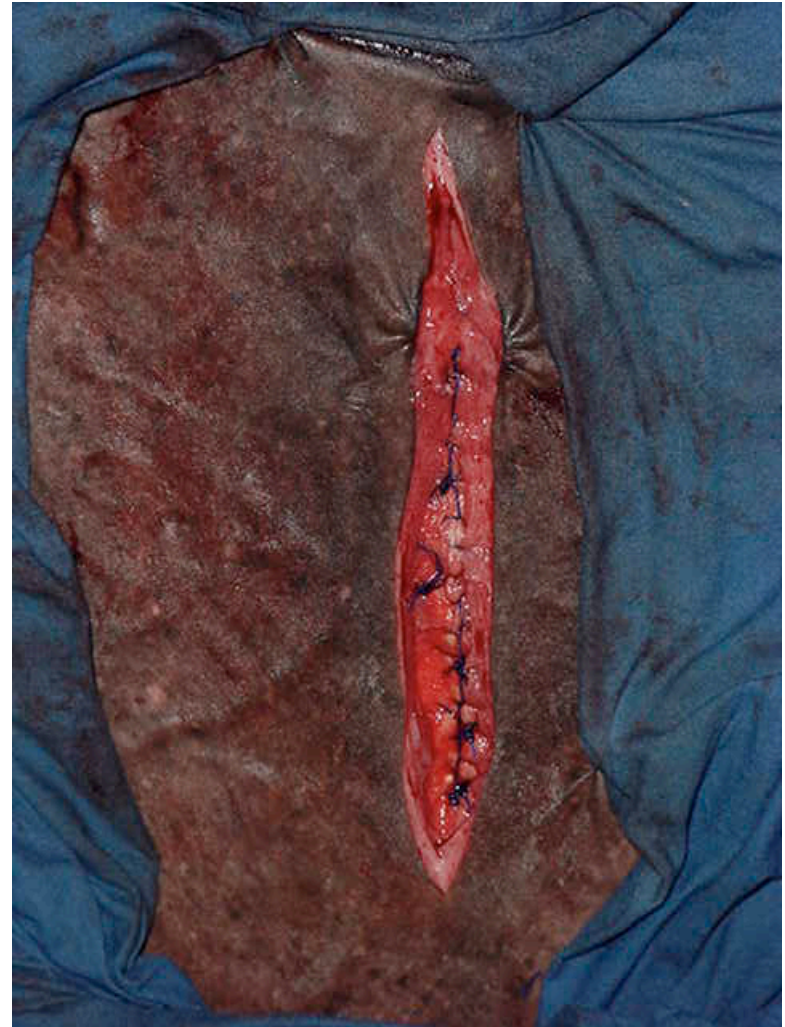
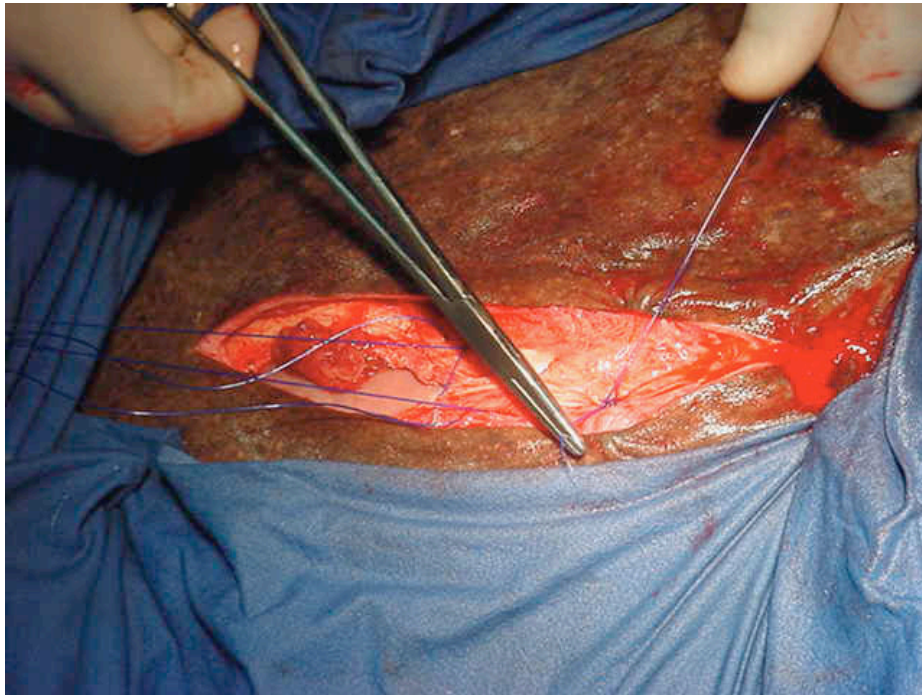




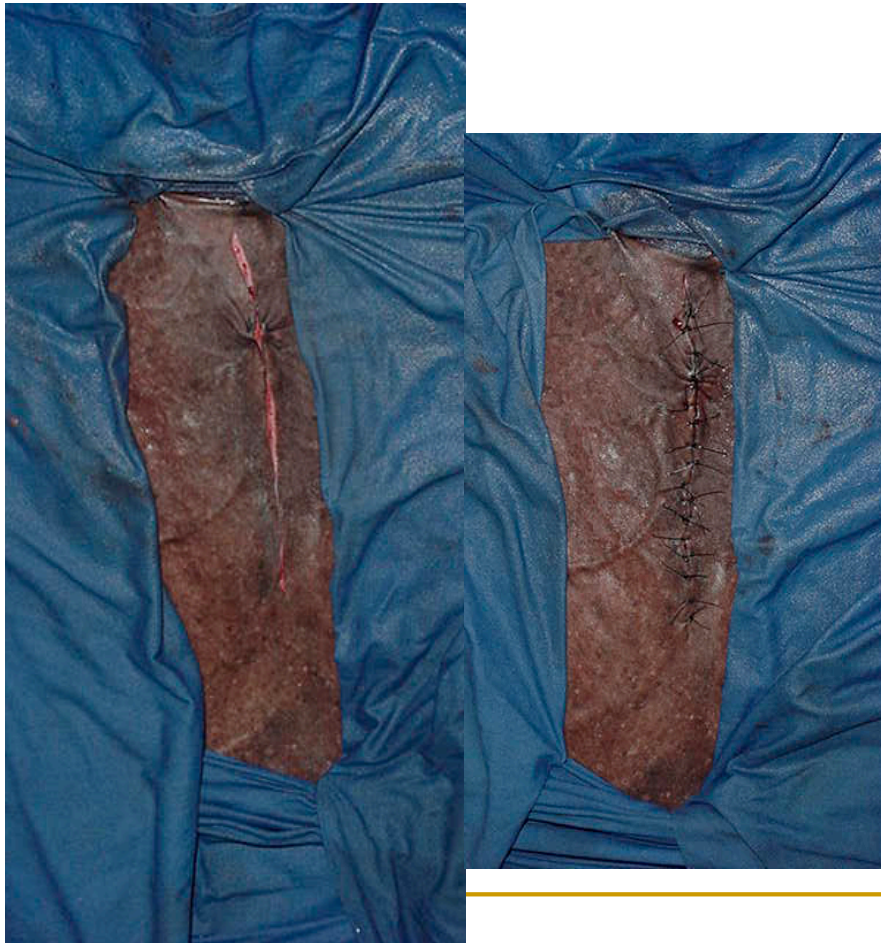- Reposição das alças intestinais na cavidade



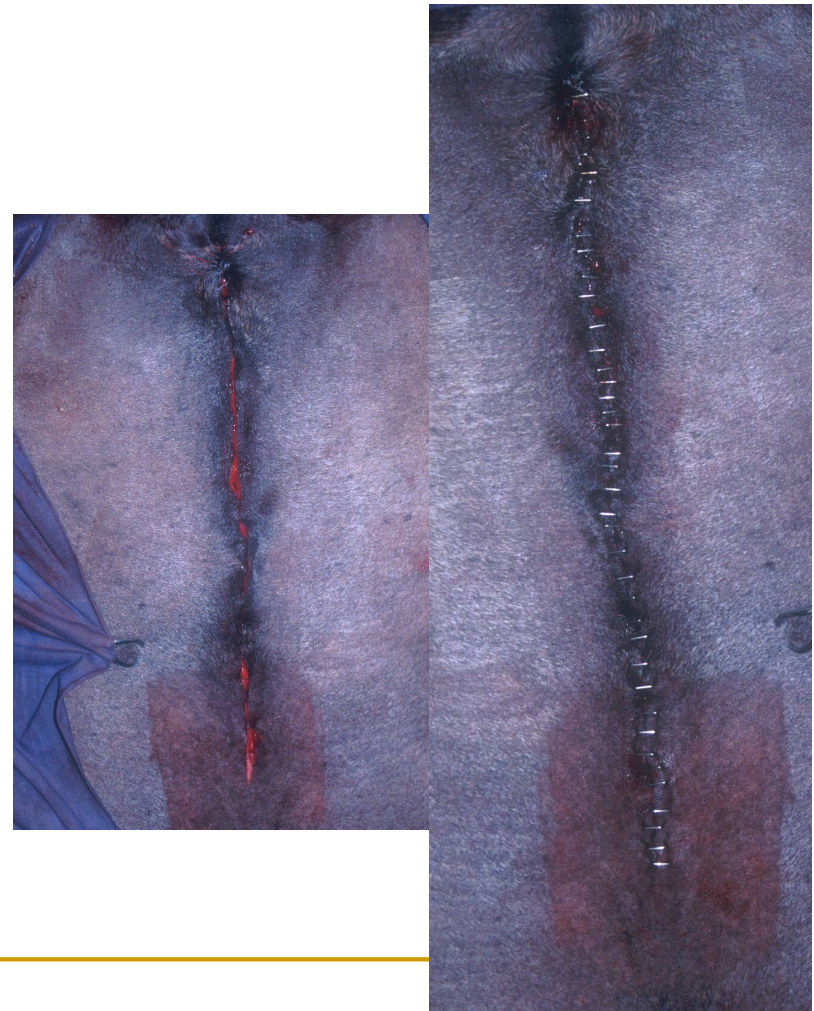
## Sutura dos planos da parede abdominal



- Sutura dos planos operatórios:
  - tecido subcutâneo



- Sutura dos planos operatórios:
  - pele



- Curativo no pós-operatório imediato





---

# LAPAROTOMIA

## ■ CUIDADOS IMPORTANTES

- ❑ Manter as alças intestinais sempre úmidas
  - ❑ Ter duas equipes cirúrgicas - enterotomia
  - ❑ Limpeza das alças antes de colocá-las na cavidade
  - ❑ Posicionamento correto das alças na cavidade
-

