VCI – 516: CLÍNICA CIRÚRGICA DE GRANDES ANIMAIS

AFECÇÕES CIRÚRGICAS DOS DÍGITOS DOS RUMINANTES

PROF. DR. RODRIGO ROMERO CORRÊA

AFECÇÕES DOS DÍGITOS DOS RUMINANTES

- População acometida
- Importância
- Economia
- Identificação

ETIOLOGIA / INDUÇÃO DAS LESÕES

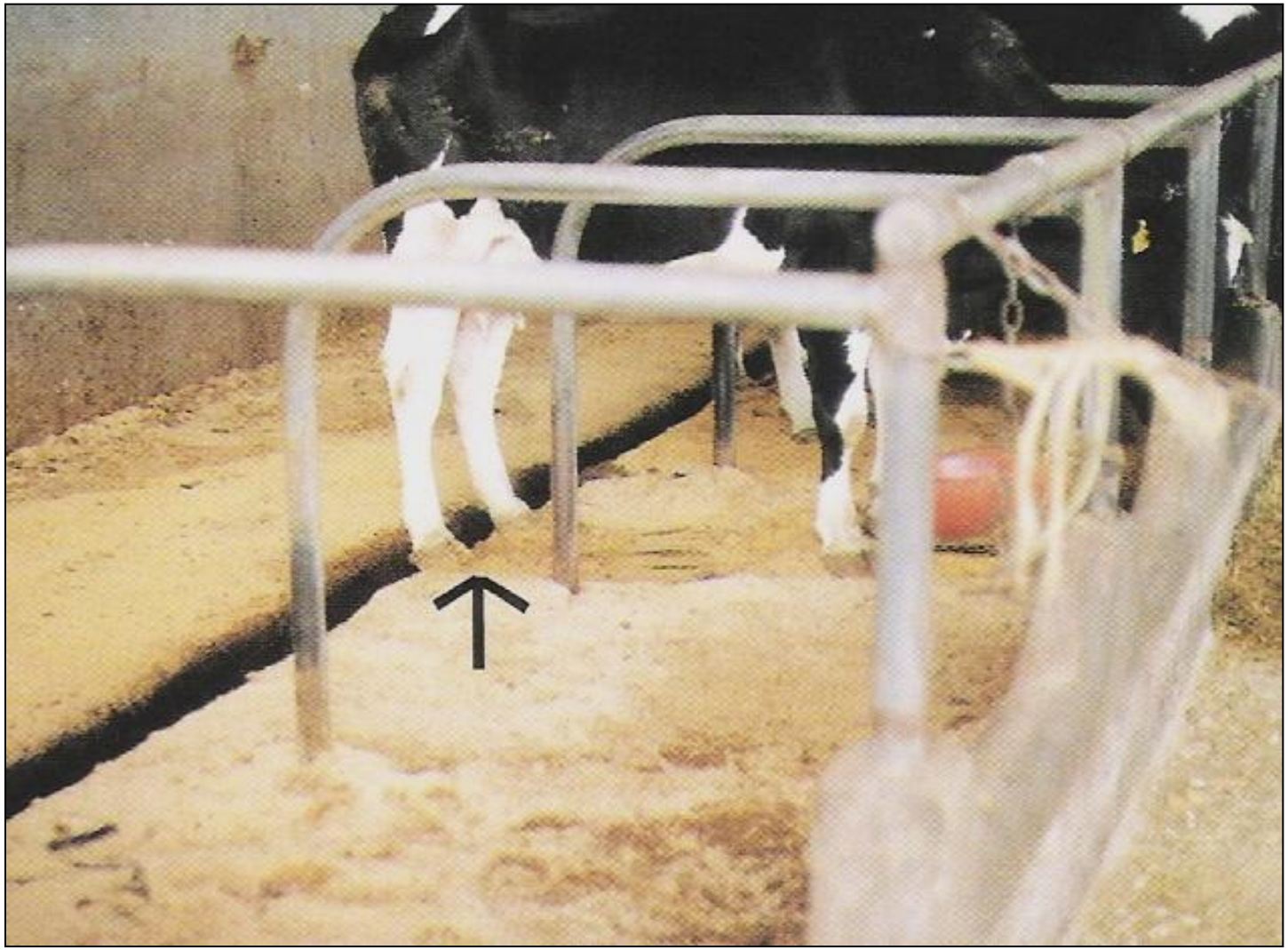

REGIÃO ACOMETIDA / ANATOMIA

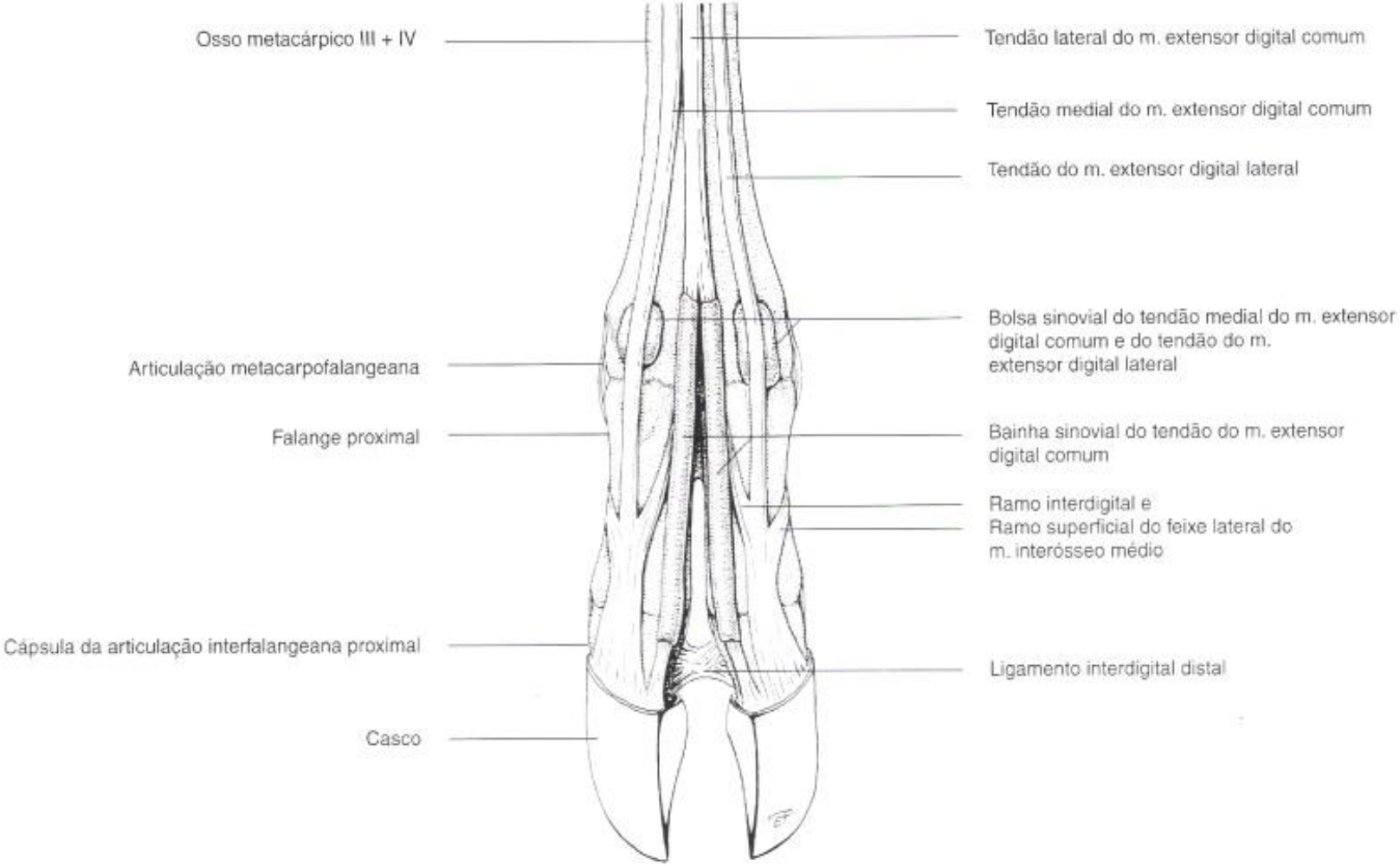

REGIÃO ACOMETIDA / ANATOMIA

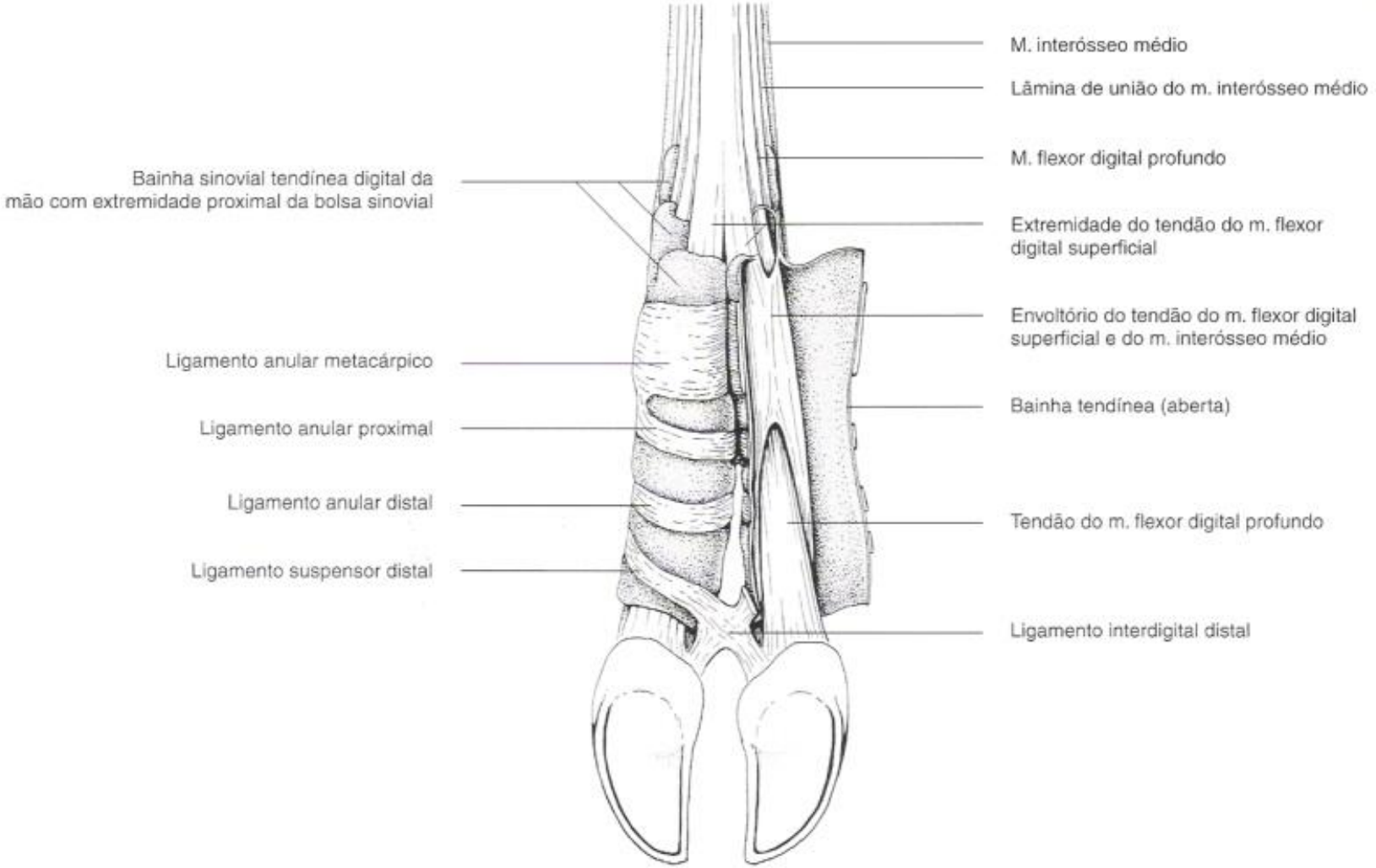

REGIÃO ACOMETIDA / ANATOMIA

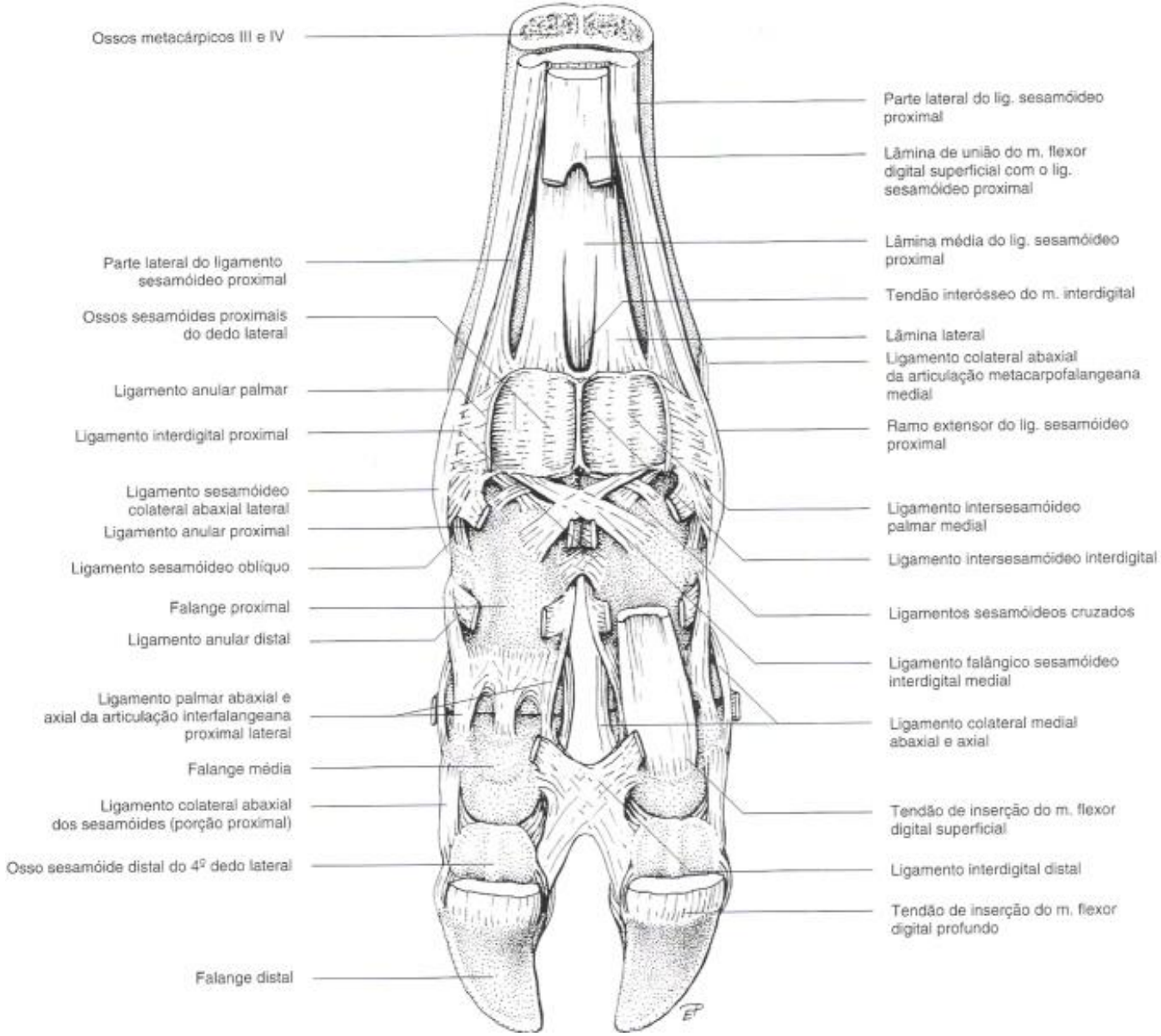

REGIÃO ACOMETIDA / ANATOMIA

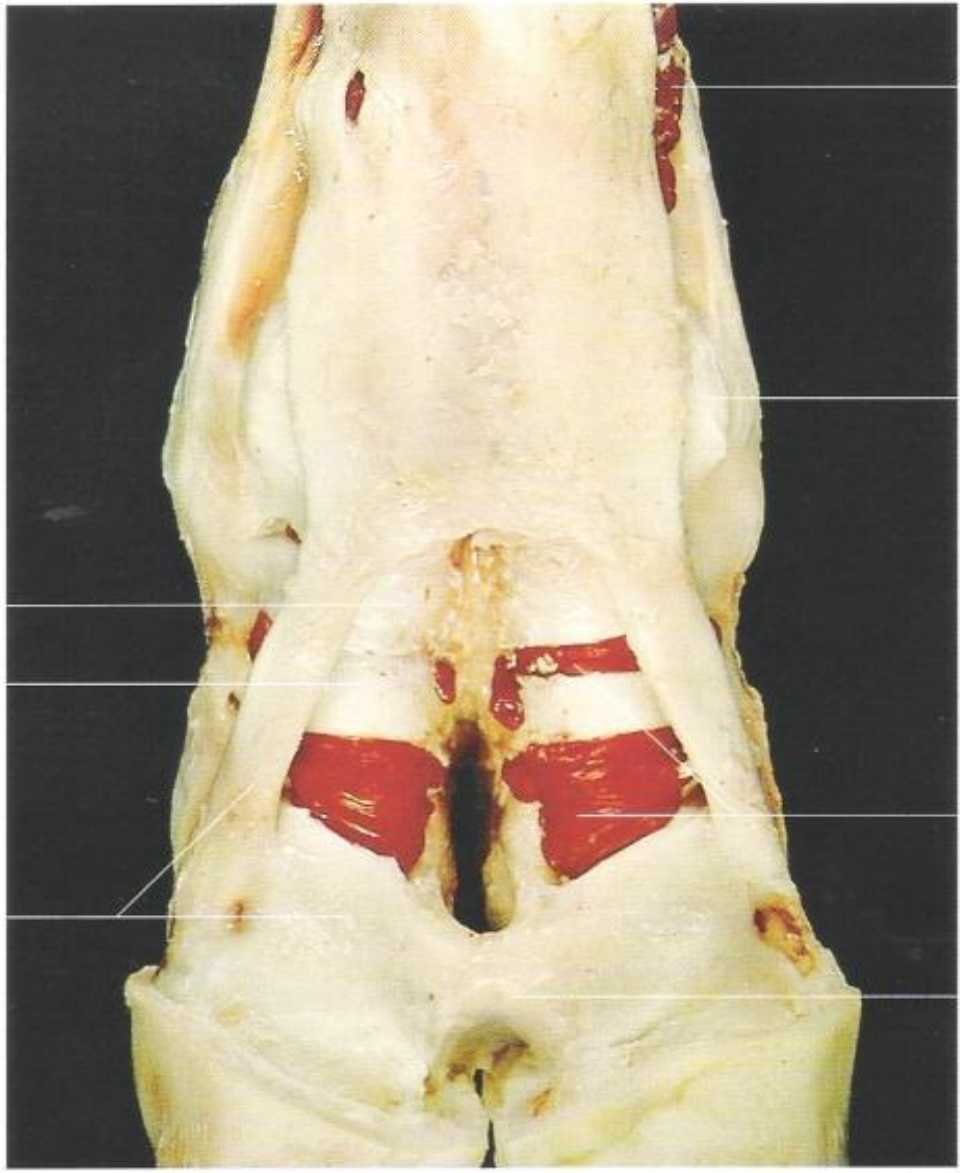

REGIÃO ACOMETIDA / ANATOMIA

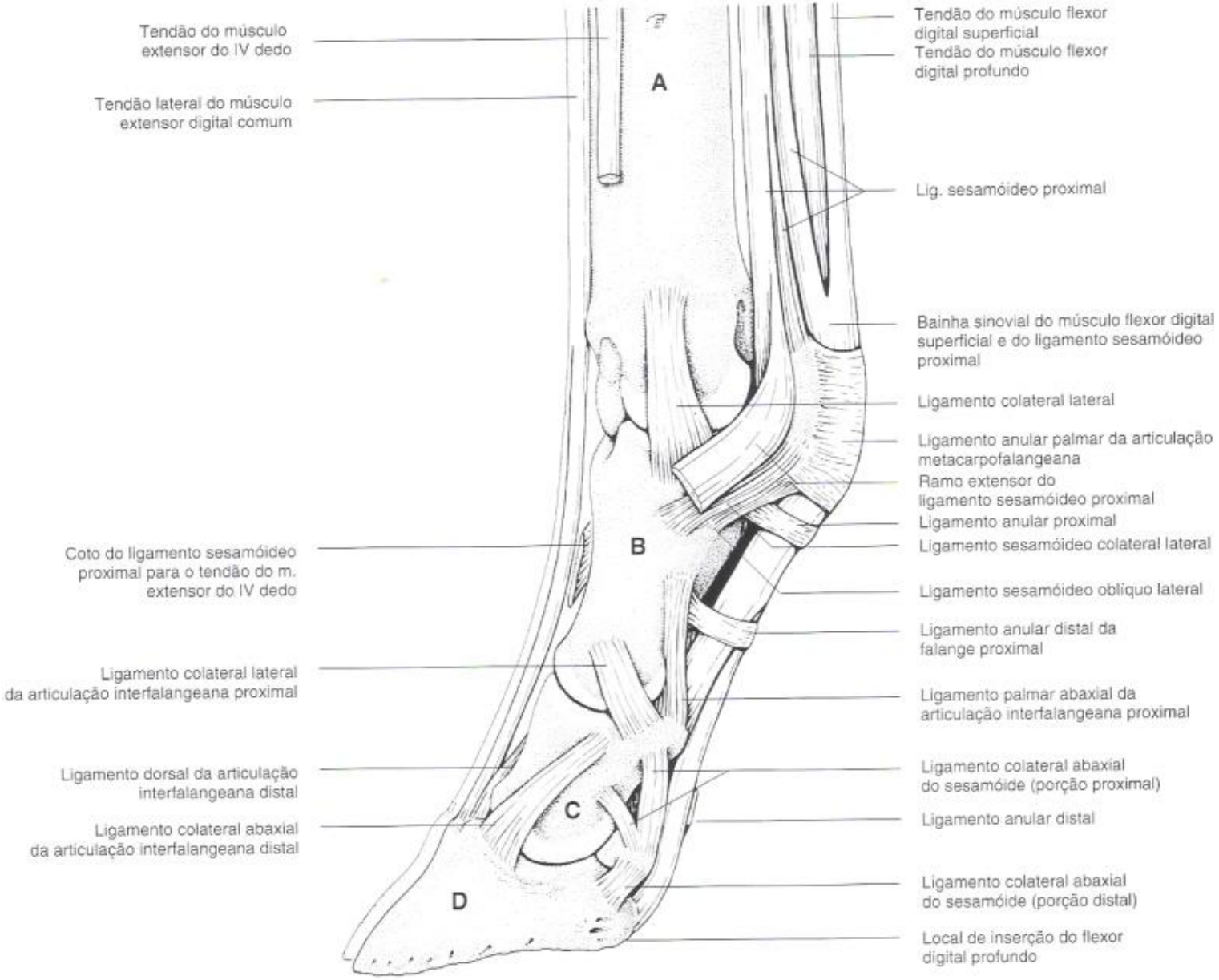

REGIÃO ACOMETIDA / ANATOMIA

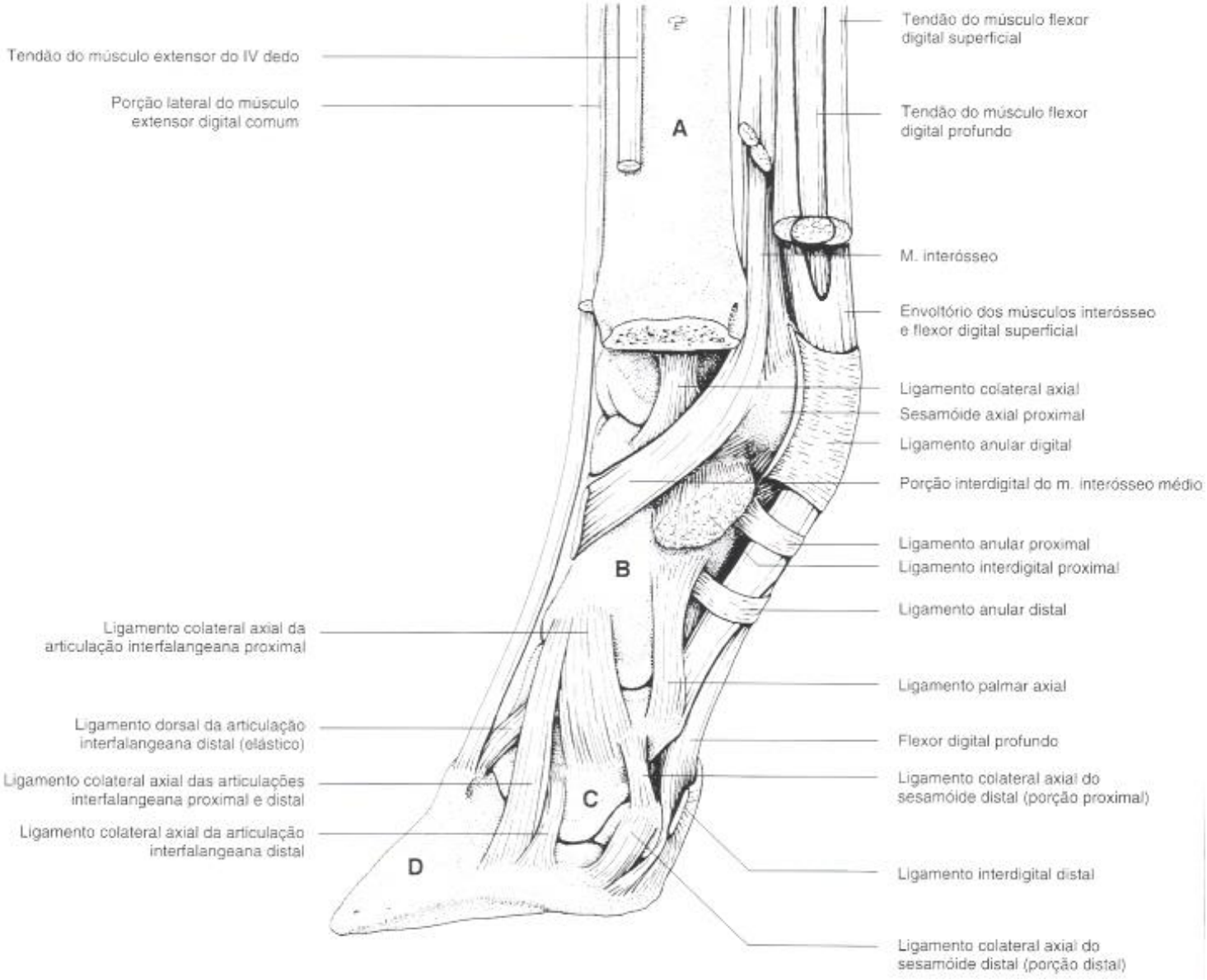

ANATOMIA RADIOLÓGICA

EXAME FÍSICO

Tronco fixo modelo Romancini

EXAME FÍSICO

Tronco fixo modelo Romancini



EXAME FÍSICO

Tronco fixo modelo Fregonezzi

Bug-busting the easy way

HIPERPLASIA INTERDIGITAL - TILOMA INTERDIGITAL -

- Comissura interdigital
- Higiene precária
- Processo crônico – dermatite interdigital
- Gram - : *Bacteroides nodosus*

  outras: *Fusobacterium necrophorum*

  Spirochaetas

HIPERPLASIA INTERDIGITAL
- TILOMA INTERDIGITAL -

- Outras: conformação anormal; acúmulo gordura interdigital
- Ausência de sinais em casos com pequenas formações ou sem dermatite associada
- Tratamento cirúrgico:

  - sinais

  - estético

HIPERPLASIA DA PELE INTERDIGITAL
FIBROMA INTERDIGITAL
TILOMA

HIPERPLASIA DA PELE INTERDIGITAL

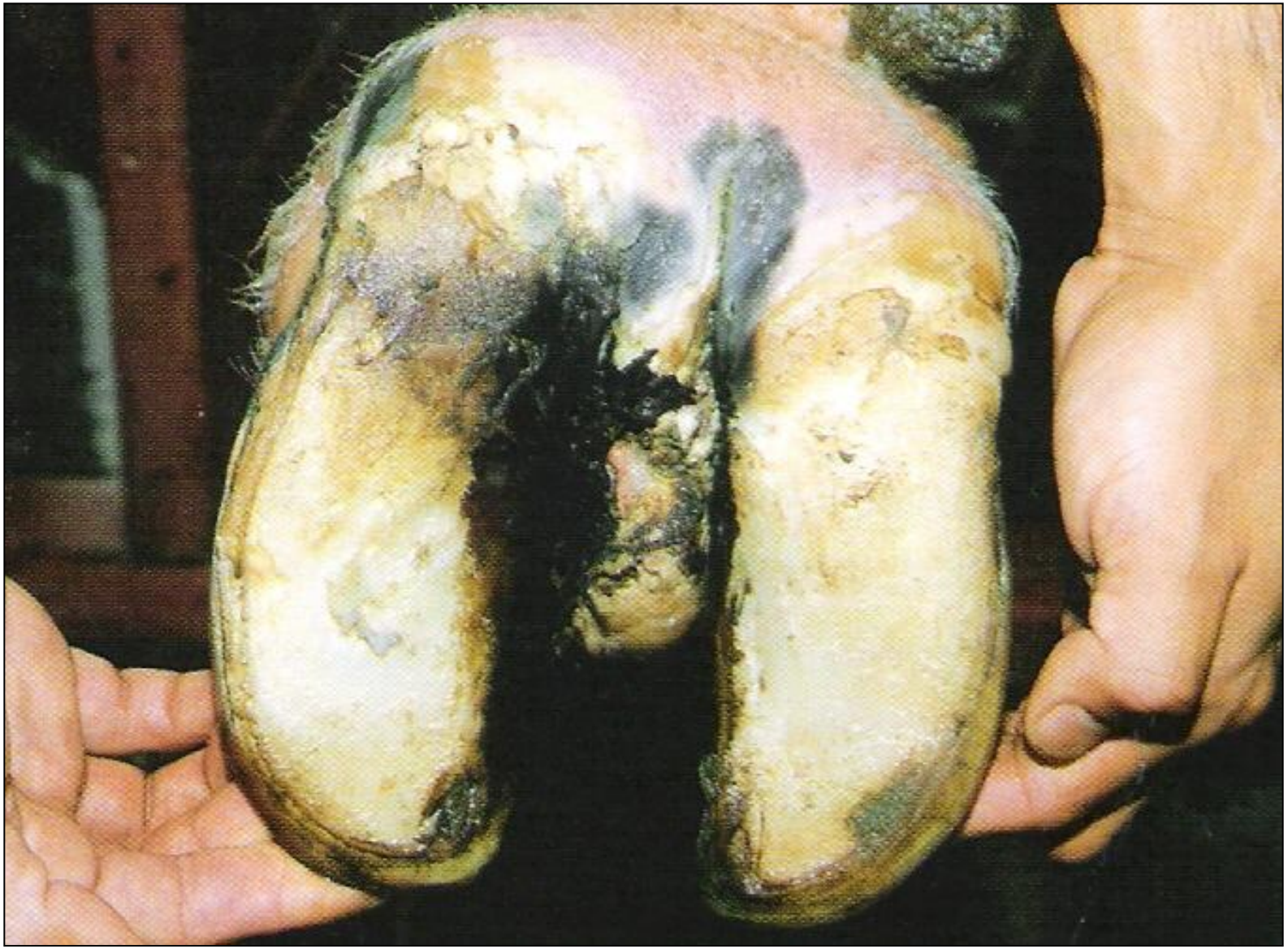

HIPERPLASIA DA PELE INTERDIGITAL

HIPERPLASIA DA PELE INTERDIGITAL

HIPERPLASIA DA PELE INTERDIGITAL

HIPERPLASIA DA PELE INTERDIGITAL

DERMATITE DIGITAL PAPILOMATOSA

- Bulbo e região coronária
- Mais posteriores
- Aspecto papilomatoso
- Higiene precária
- Origem bacteriana (?) gram -

DERMATITE DIGITAL PAPILOMATOSA

- Diagnóstico

- individual

- rebanho (surto)

- Tratamento:

- conservativo

- cirúrgico (crônica proliferativa)

DERMATITE DIGITAL PAPILOMATOSA

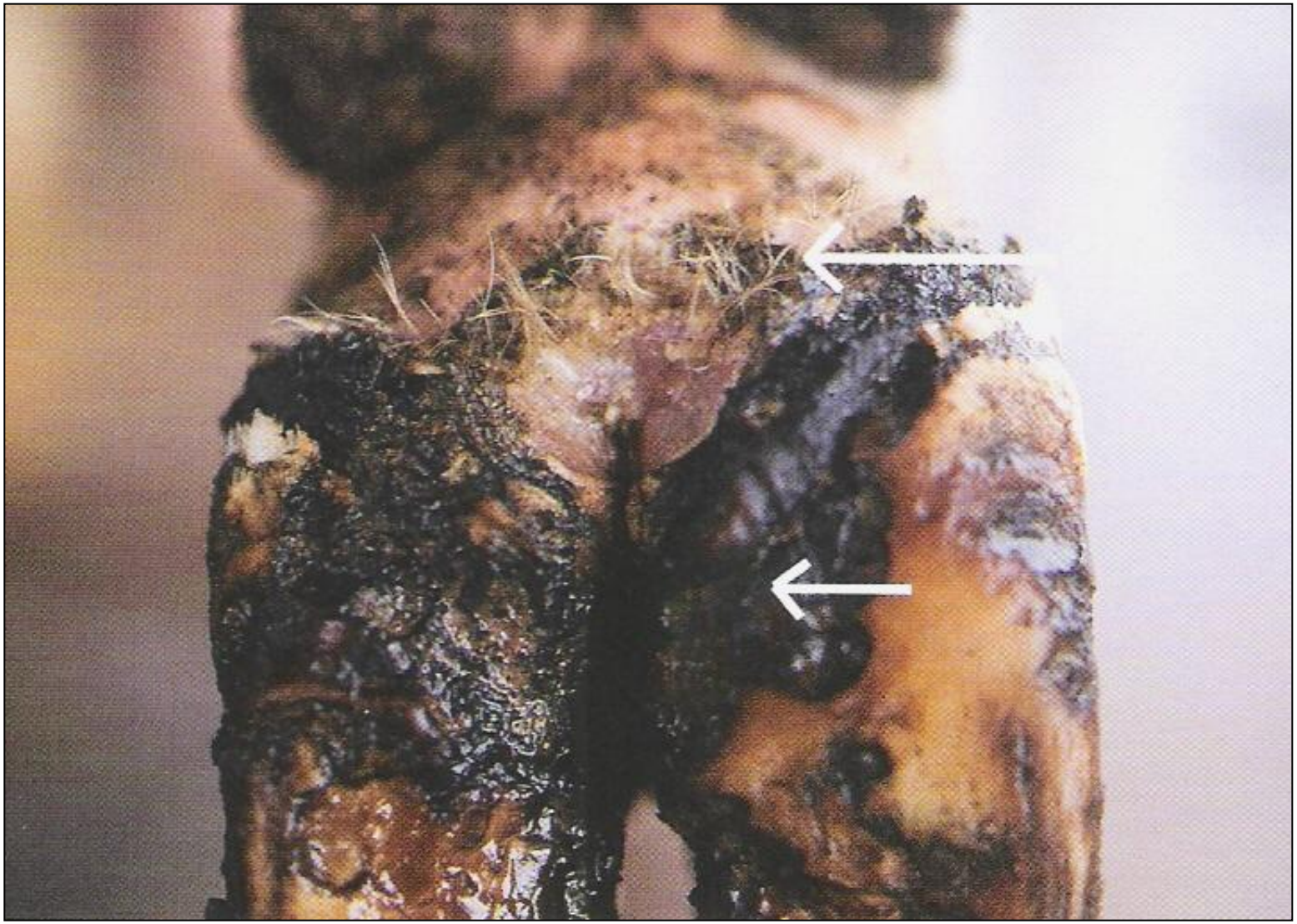

DERMATITE DIGITAL PAPILOMATOSA

DERMATITE DIGITAL PAPILOMATOSA

DERMATITE DIGITAL PAPILOMATOSA

DERMATITE DIGITAL PAPILOMATOSA

ABSCESSO E FLEGMÃO INTERDIGITAL

- Abscesso mais localizado / sem envolvimento das estrut. internas do estojo córneo
- Secundário a dermatite, traumas, miíase
- Bactérias gram – / outras
- Sinais de inflamação intensa e difusa

ABSCESSO E FLEGMÃO INTERDIGITAL

- Pode levar à artrite séptica e osteomielite
- Tratamento

  - drenagem;

  - curetagem

  - pedilúvio;

  - bandagem

  - Antibiótico sistêmico e regional

  - fresamento / amputação (complicações)

EROSÃO / ABSCESSO DE TALÃO

EROSÃO / ABSCESSO DE TALÃO

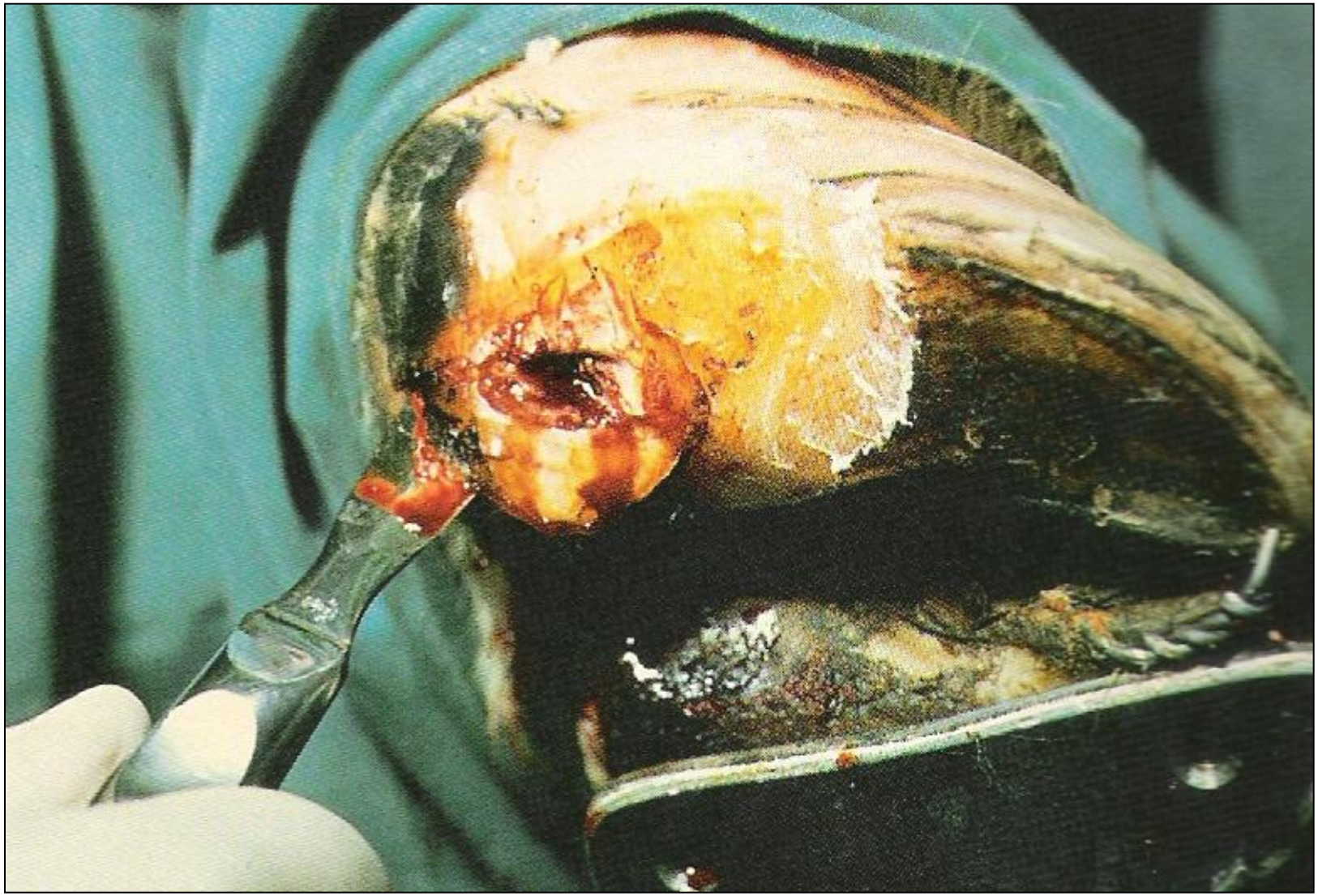

EROSÃO / ABSCESSO DE TALÃO

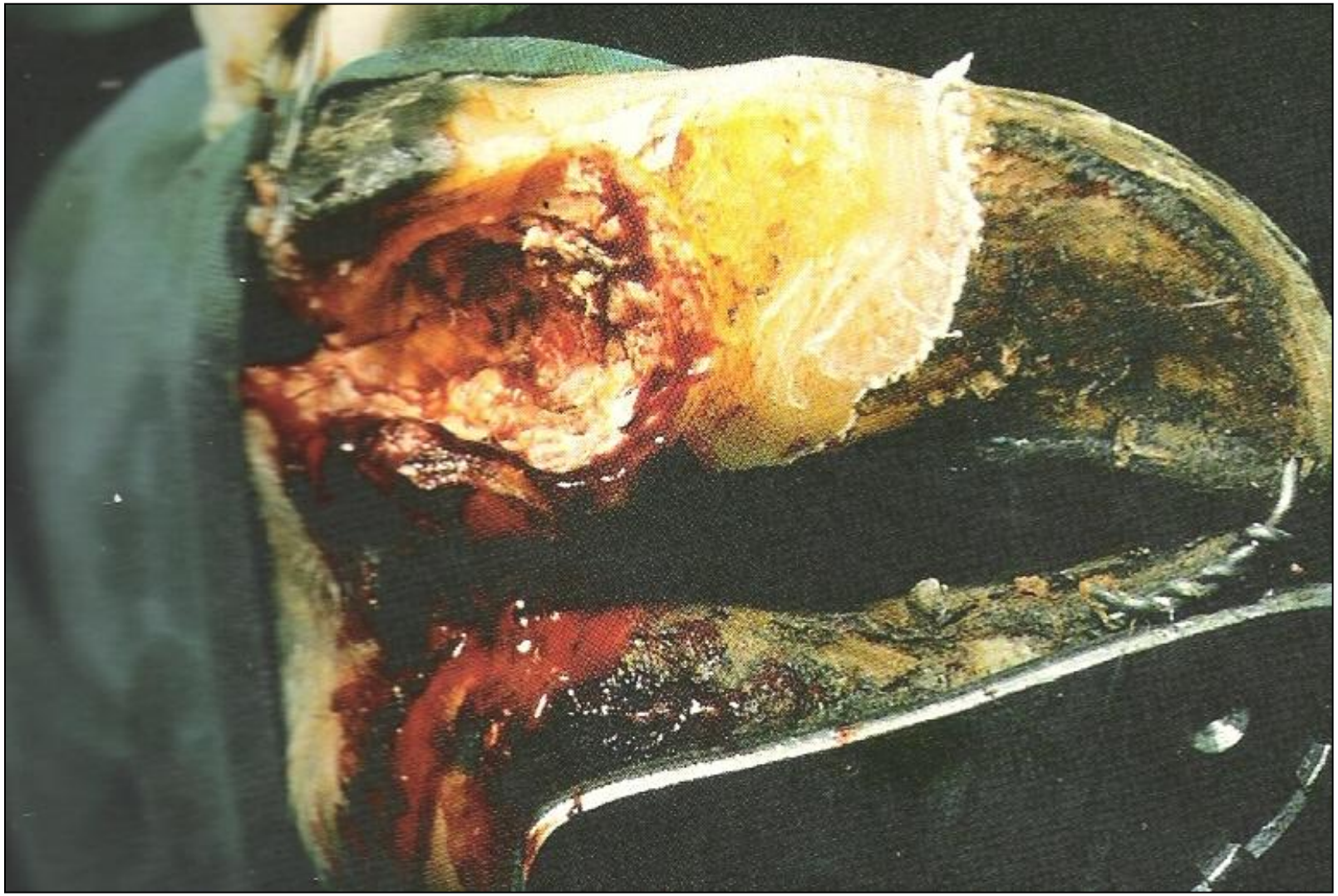

EROSÃO / ABSCESSO DE TALÃO

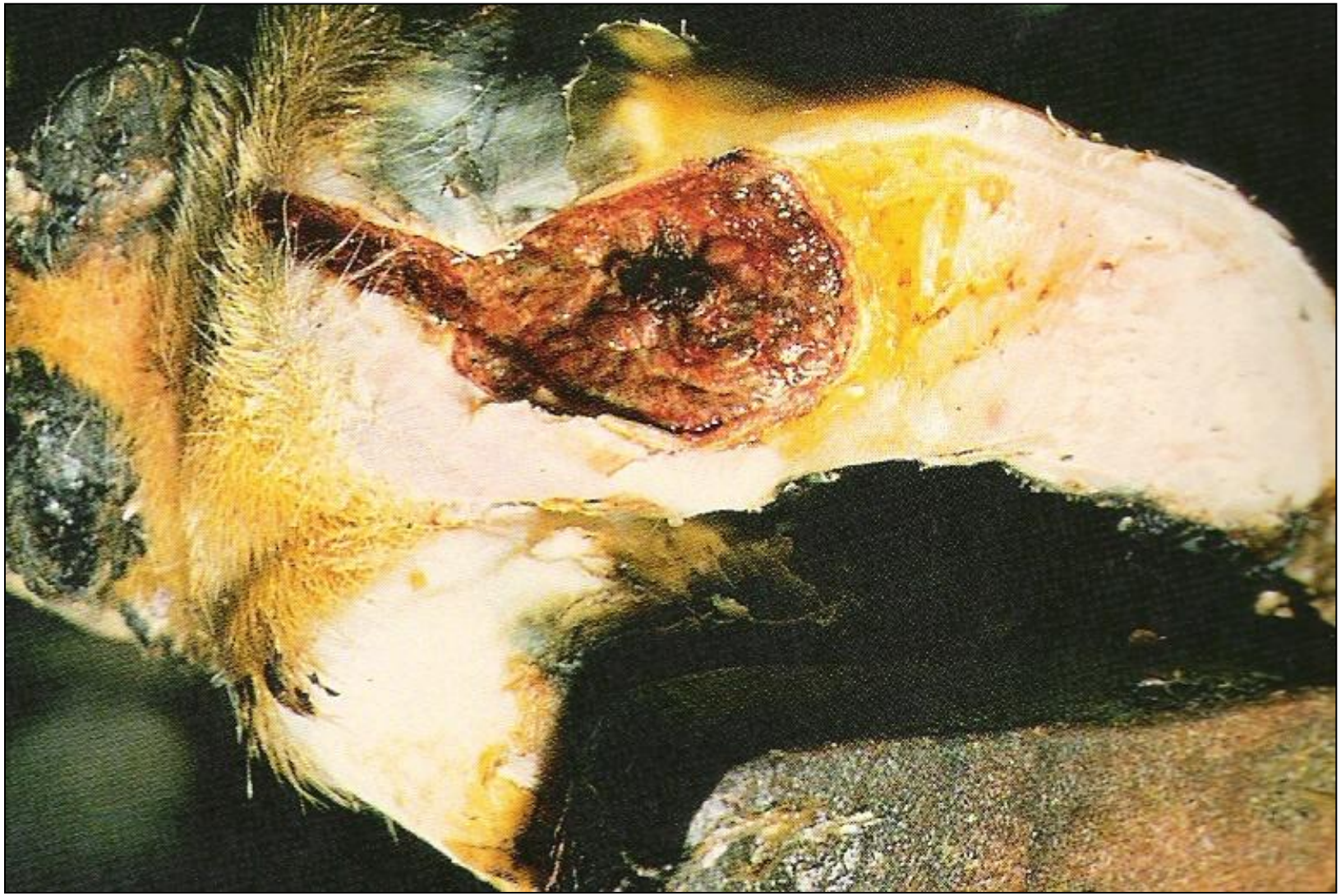

ARTRITE SÉPTICA INTERFALANGEANA DISTAL

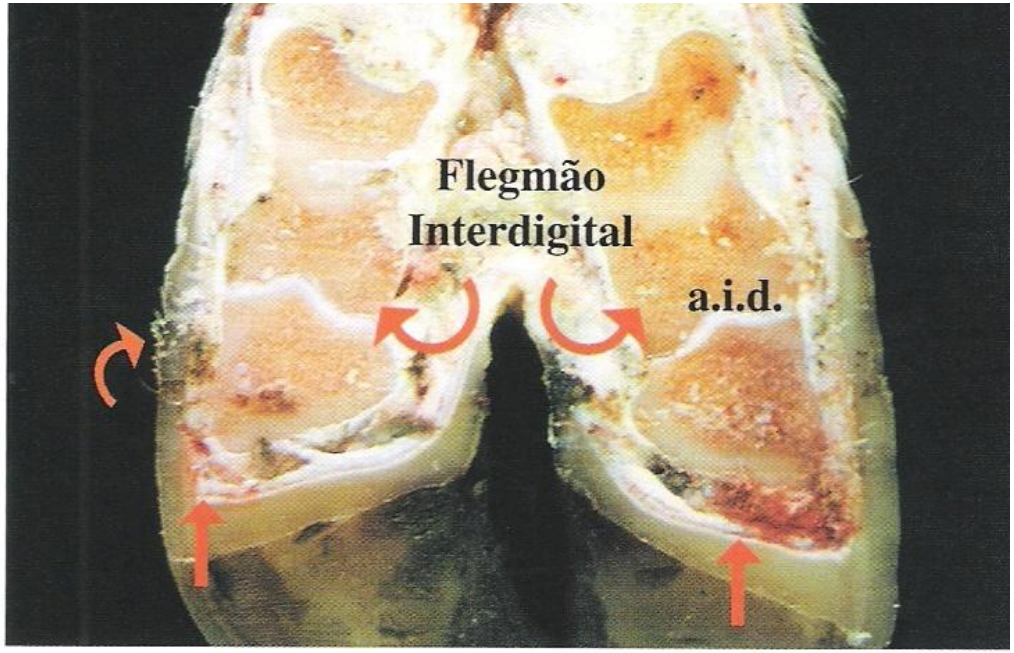

Rachadura no estrato córneo

Doença da Linha Branca

Perfuração da sola

ARTRITE SÉPTICA INTERFALANGEANA DISTAL

ARTRITE SÉPTICA INTERFALANGEANA DISTAL

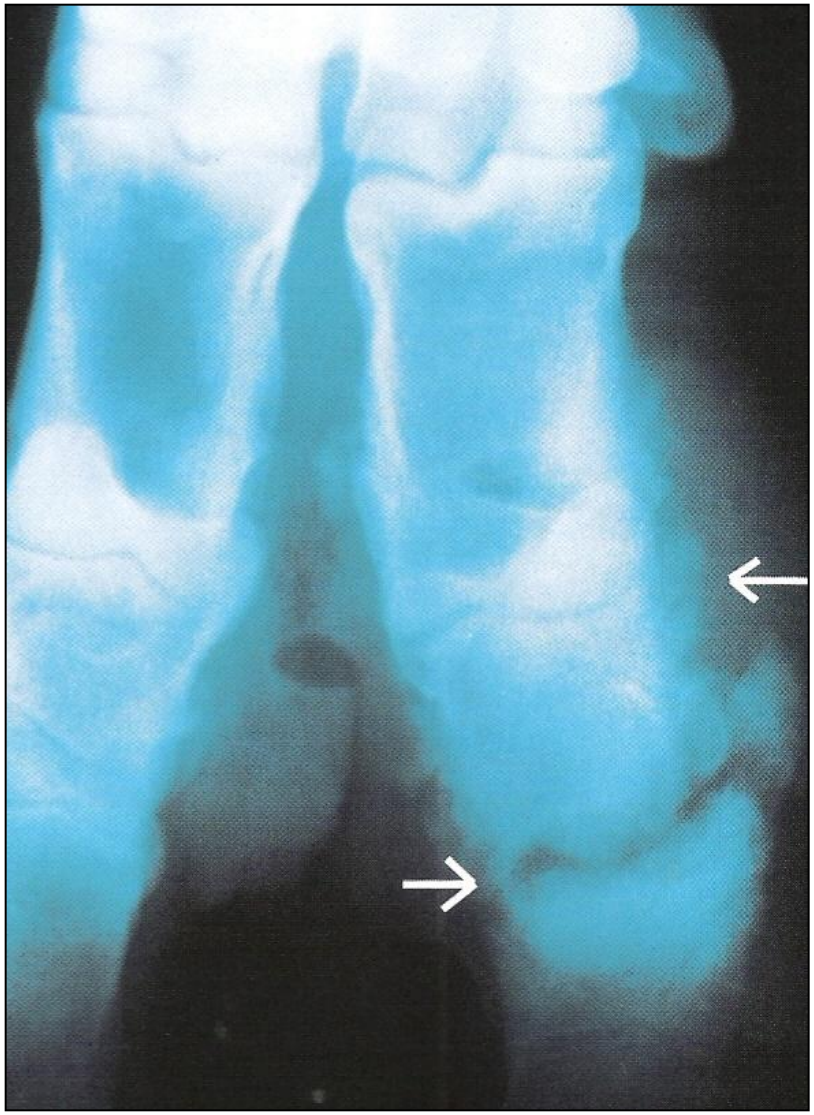

ARTRITE SÉPTICA INTERFALANGEANA DISTAL

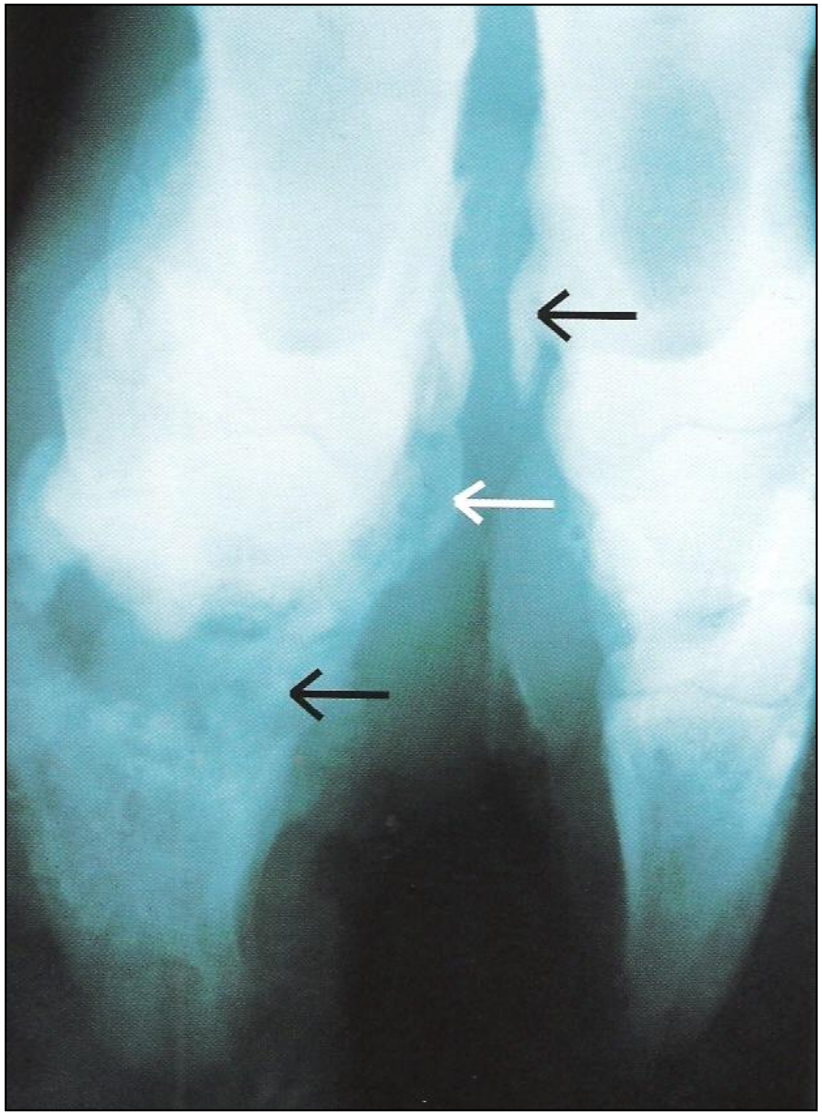

ARTRITE SÉPTICA INTERFALANGEANA DISTAL

ARTRITE SÉPTICA INTERFALANGEANA DISTAL

ARTRITE SÉPTICA INTERFALANGEANA DISTAL

ARTRITE SÉPTICA INTERFALANGEANA DISTAL

ARTRITE SÉPTICA INTERFALANGEANA DISTAL

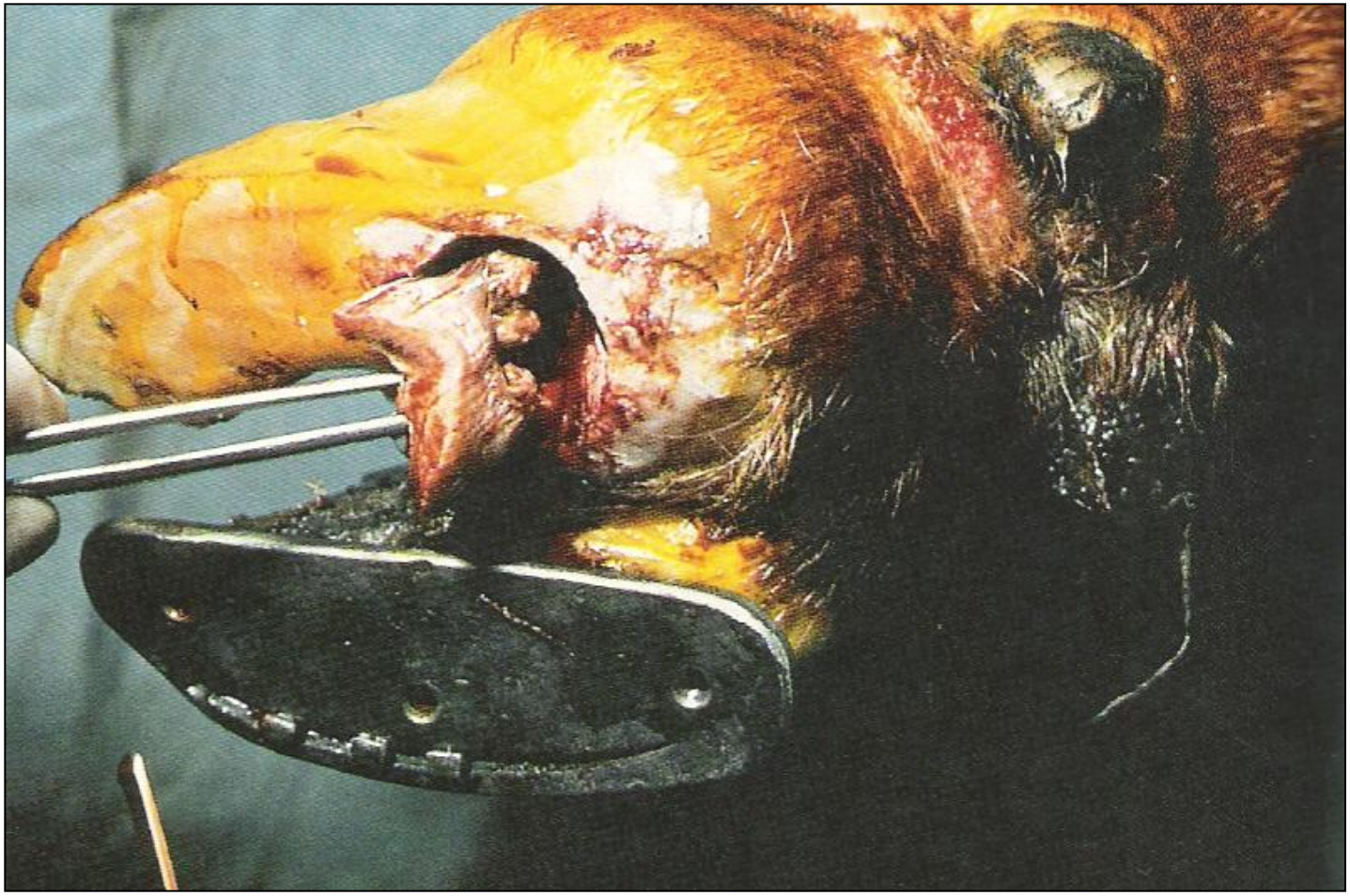

ARTRITE SÉPTICA INTERFALANGEANA DISTAL

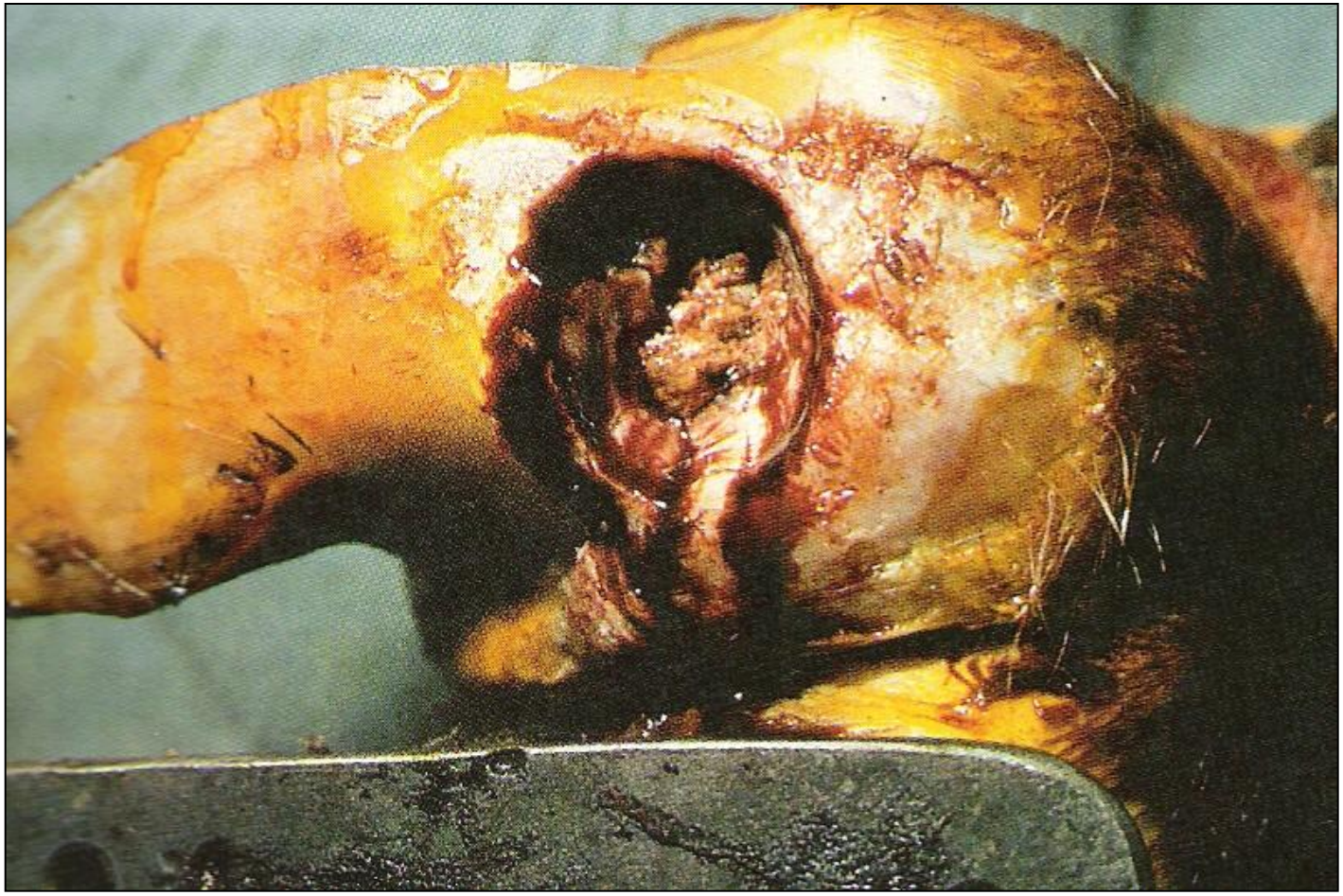

ARTRITE SÉPTICA INTERFALANGEANA DISTAL

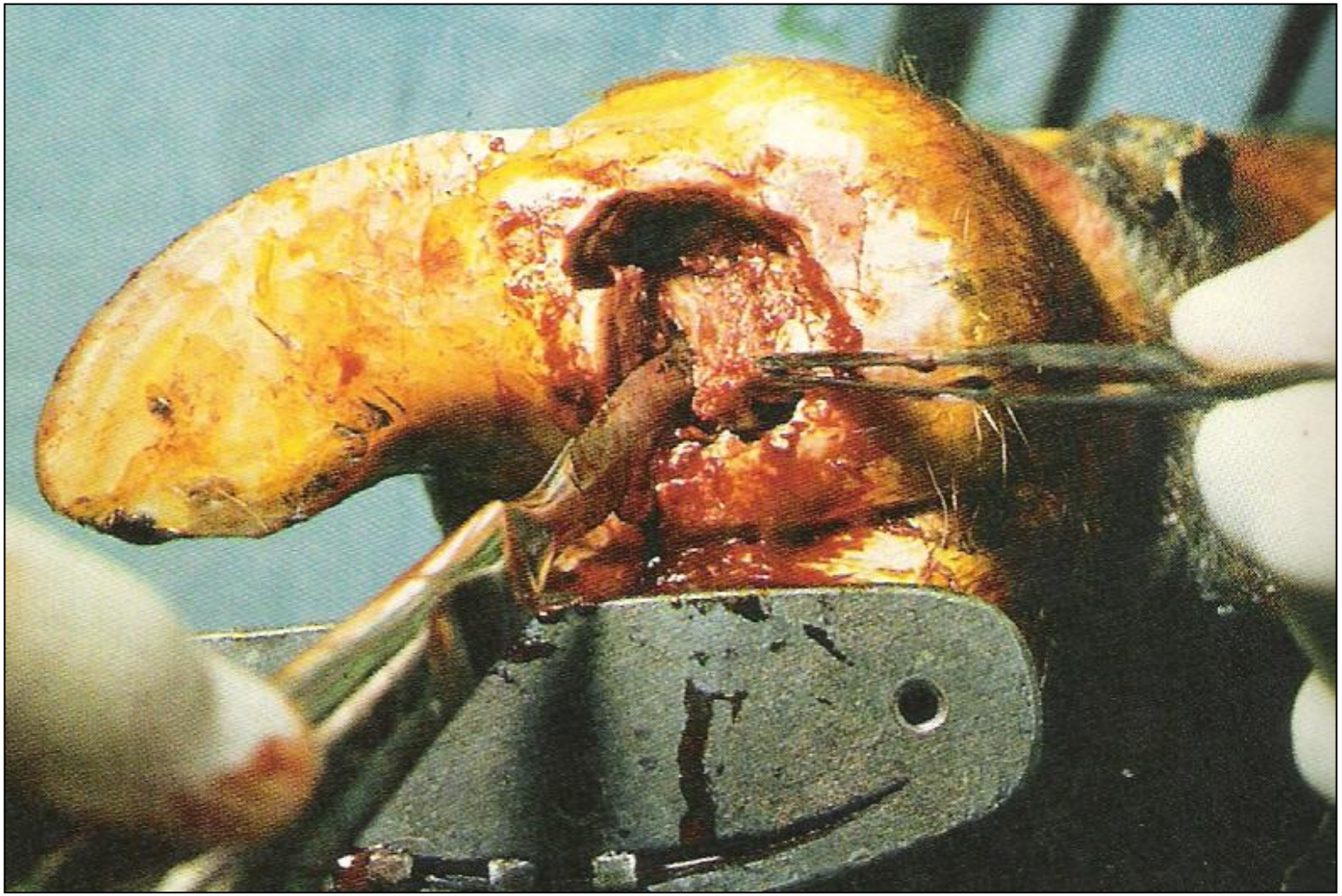

ARTRITE SÉPTICA INTERFALANGEANA DISTAL

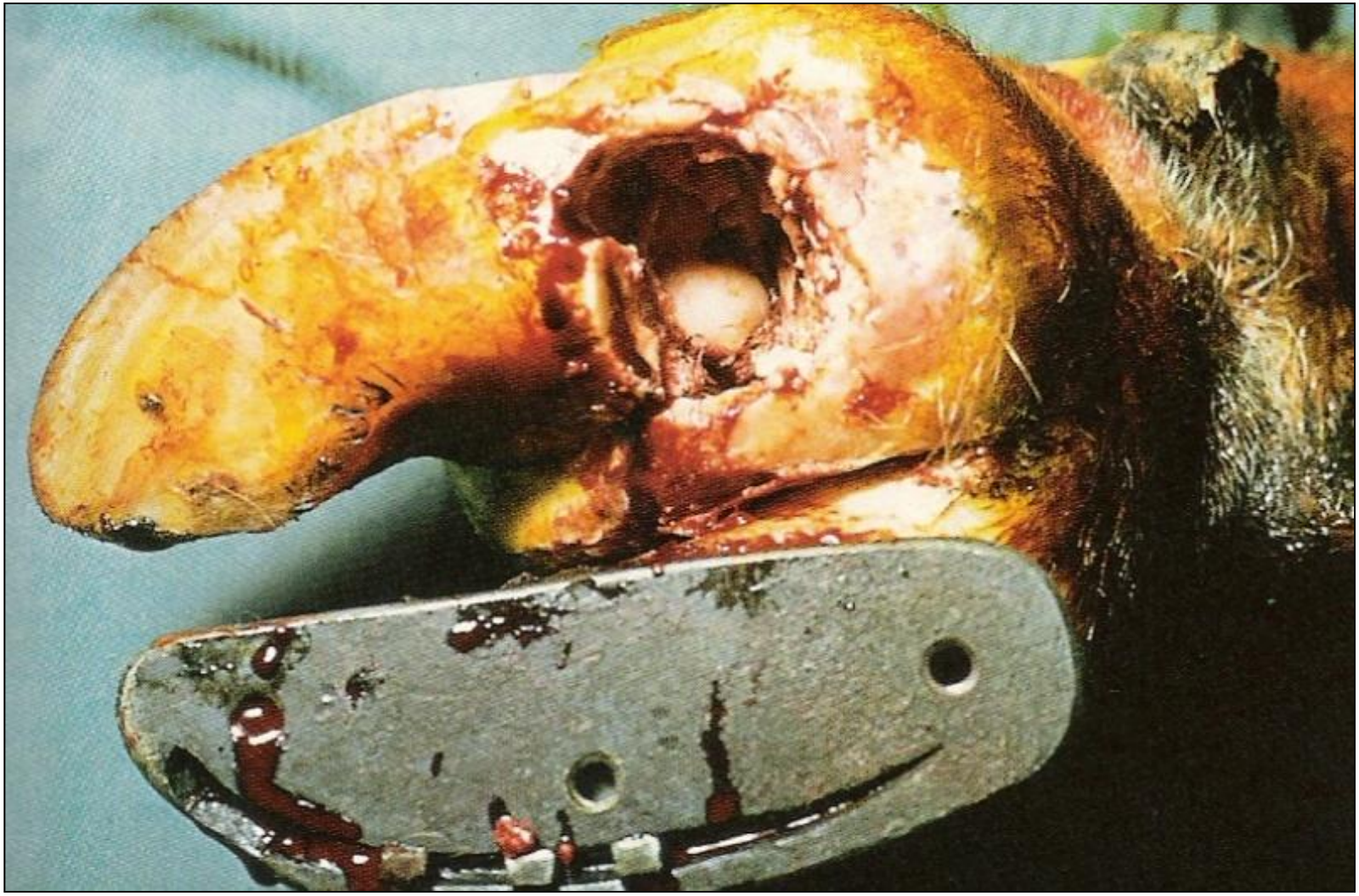

ARTRITE SÉPTICA INTERFALANGEANA DISTAL

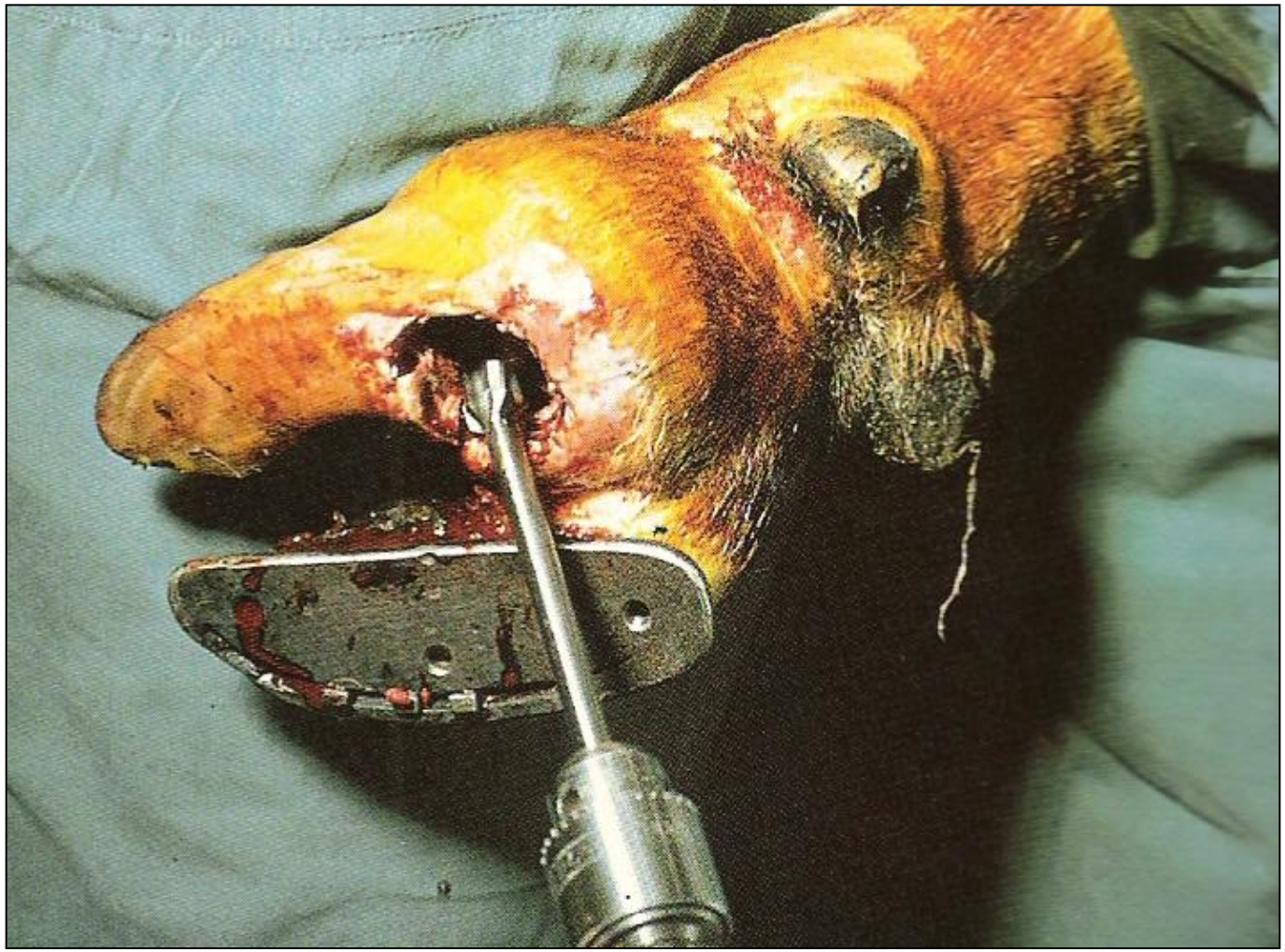

ARTRITE SÉPTICA INTERFALANGEANA DISTAL

ARTRITE SÉPTICA INTERFALANGEANA DISTAL

NEOPLASIAS

Fibropapiloma

AMPUTAÇÃO DIGITAL

AMPUTAÇÃO DIGITAL

AMPUTAÇÃO DIGITAL

AMPUTAÇÃO DIGITAL

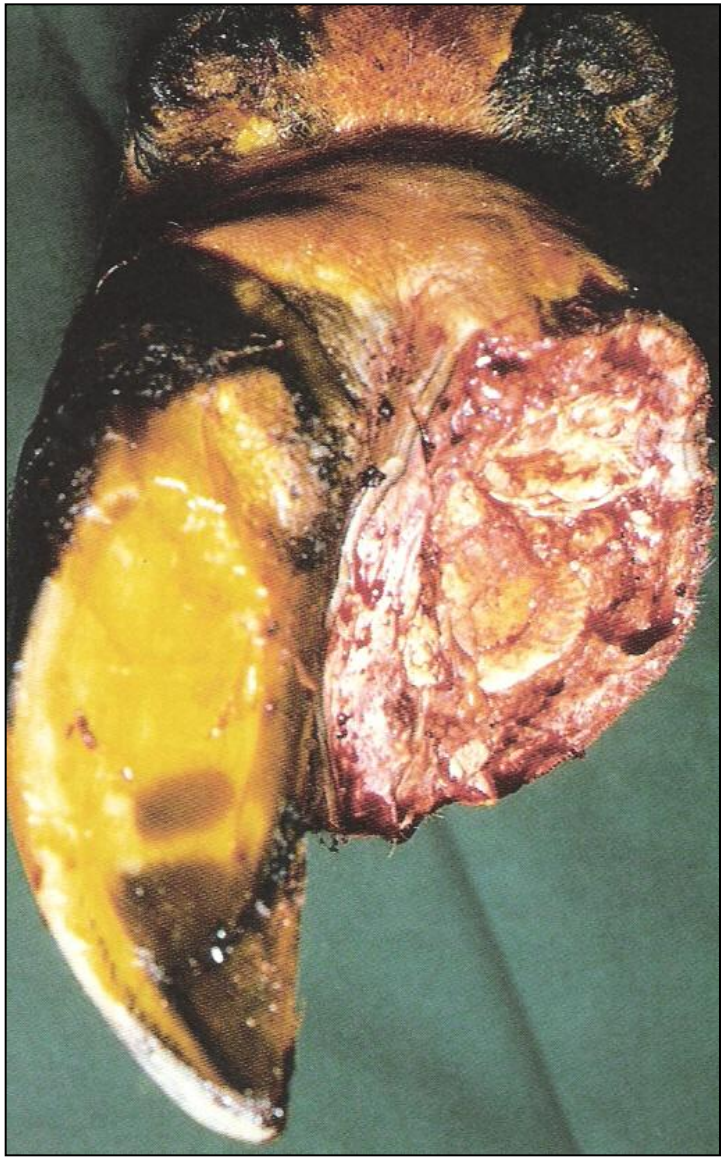

AMPUTAÇÃO DIGITAL

CASOS CLÍNICOS

- Revisão
- Aplicação dos conceitos
- Treinamento
- Casos de rotina de campo

- DISCUSSÃO!!

DERMATITE INTERDIGITAL + FLEGMÃO

DERMATITE INTERDIGITAL HIPERPLÁSICA + FLEGMÃO

DERMATITE INTERDIGITAL + ABSCESSO

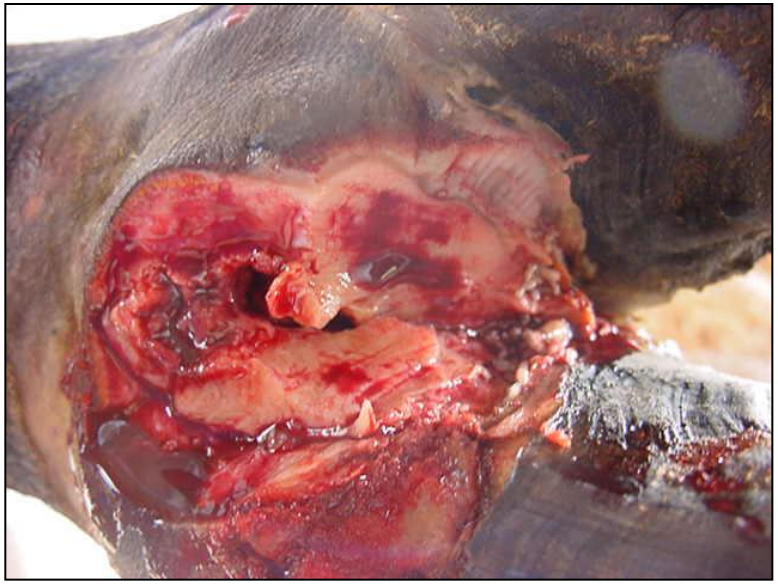

AVULSÃO

AVULSÃO

AVULSÃO

AVULSÃO

AVULSÃO

AVULSÃO / FERIDA

AVULSÃO / FERIDA

AVULSÃO / FERIDA

AVULSÃO / FERIDA

AVULSÃO / FERIDA

AVULSÃO / FERIDA

AVULSÃO / FERIDA



AVULSÃO / FERIDA

AMPUTAÇÃO DIGITAL

AMPUTAÇÃO DIGITAL

AMPUTAÇÃO DIGITAL

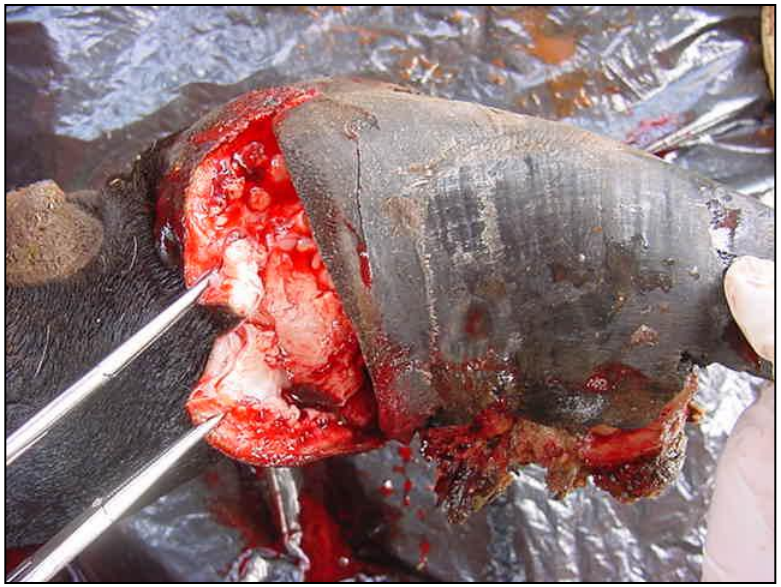

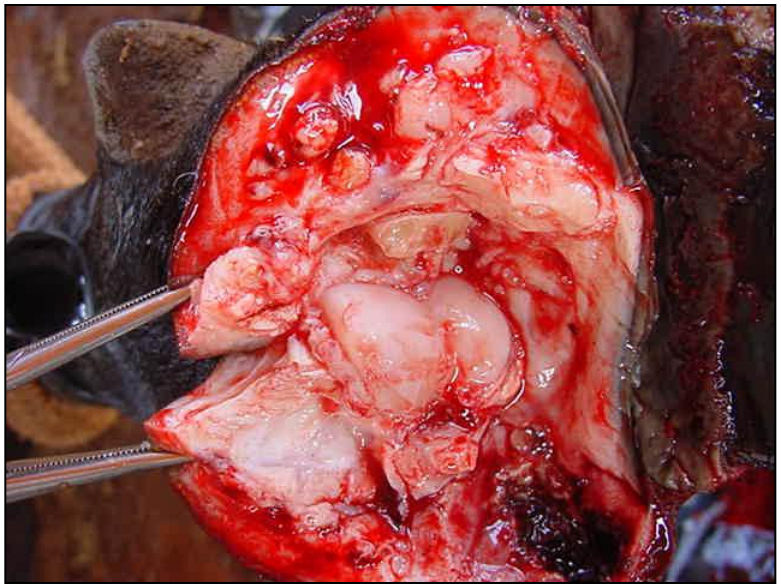

AMPUTAÇÃO DIGITAL

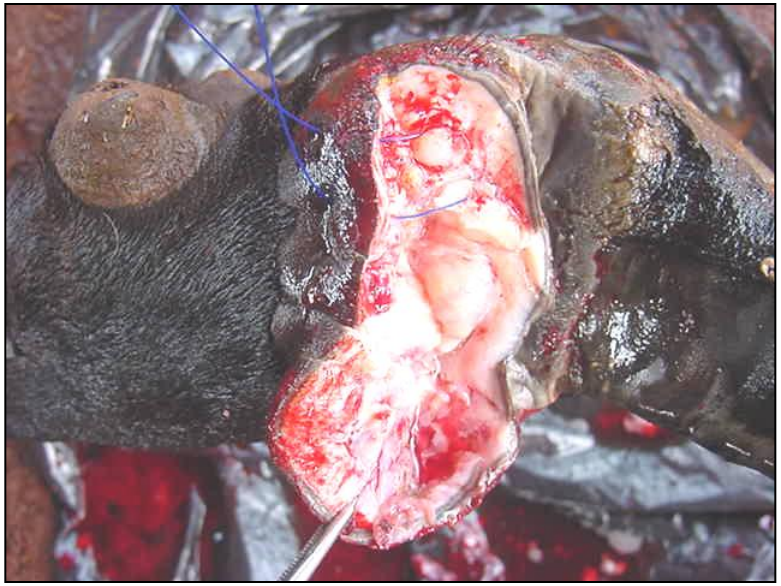

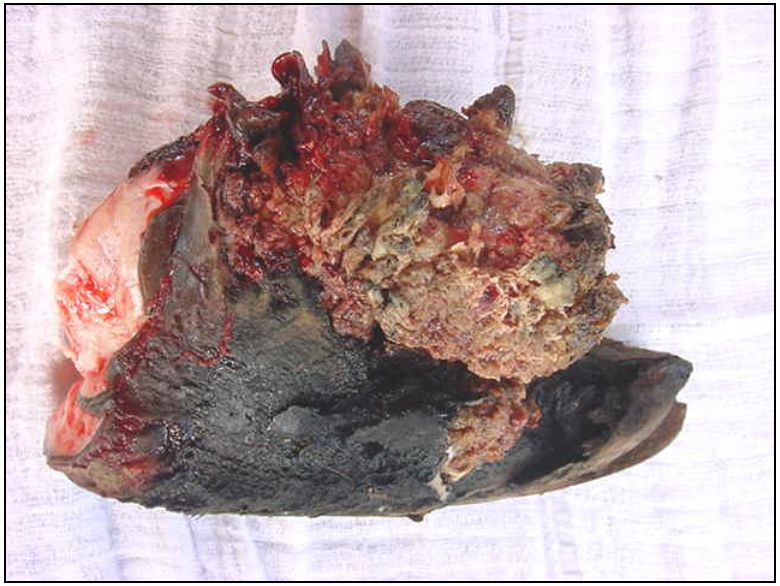
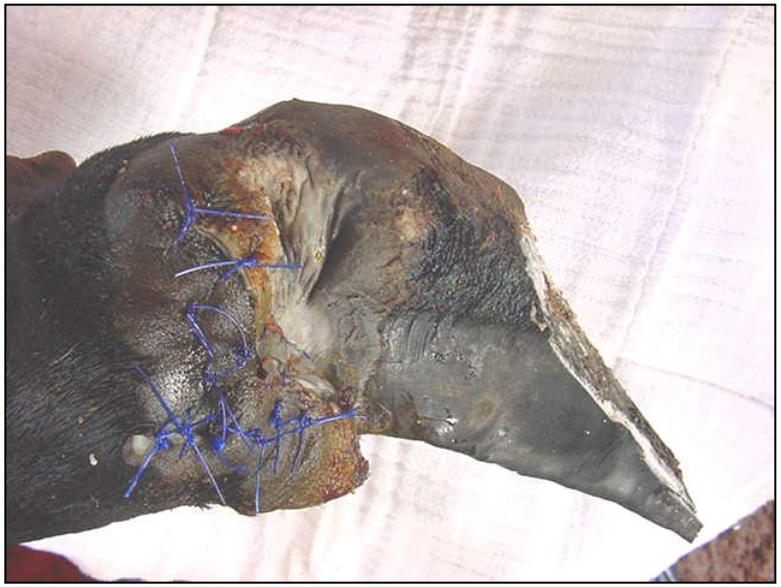
AMPUTAÇÃO DIGITAL