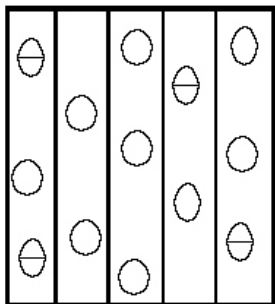
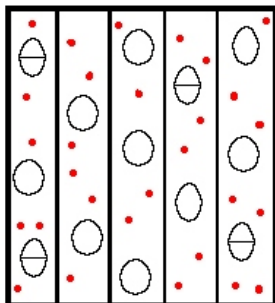


TIPOS DE PARÊNQUIMA AXIAL

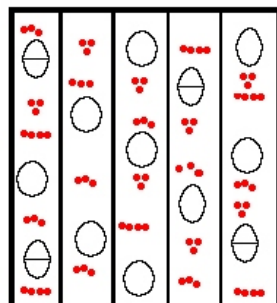


INDISTINTO

APOTRAQUEAL

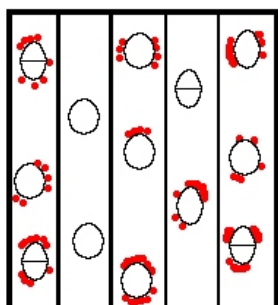


DIFUSO

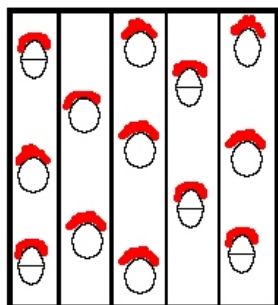


DIFUSO EM AGREGADOS

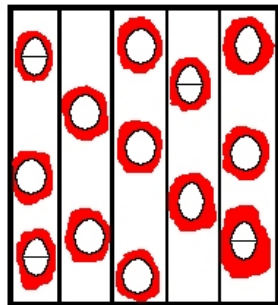
PARATRAQUEAL




PARETRAQUEAL ESCASSO



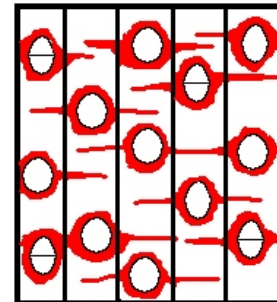
PARATRAQUEAL UNILATERAL



VASICÊNTRICO

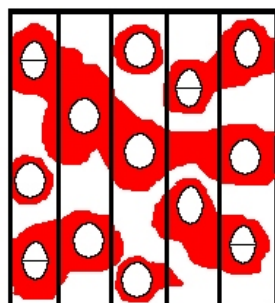


ALIFORME LOSANGULAR

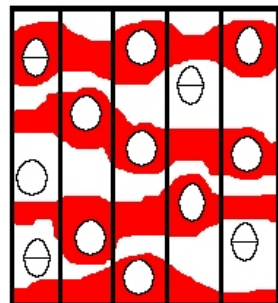


ALIFORME LINEAR

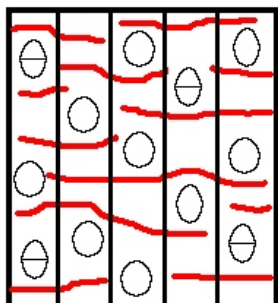
LINHAS/FAIXAS



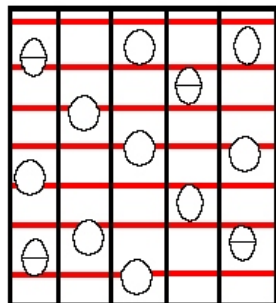
CONFLUENTE



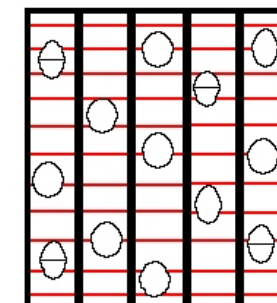
FAIXAS



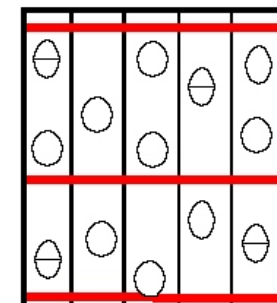
LINHAS



RETICULADO



ESCALARIFORME



MARGINAL