

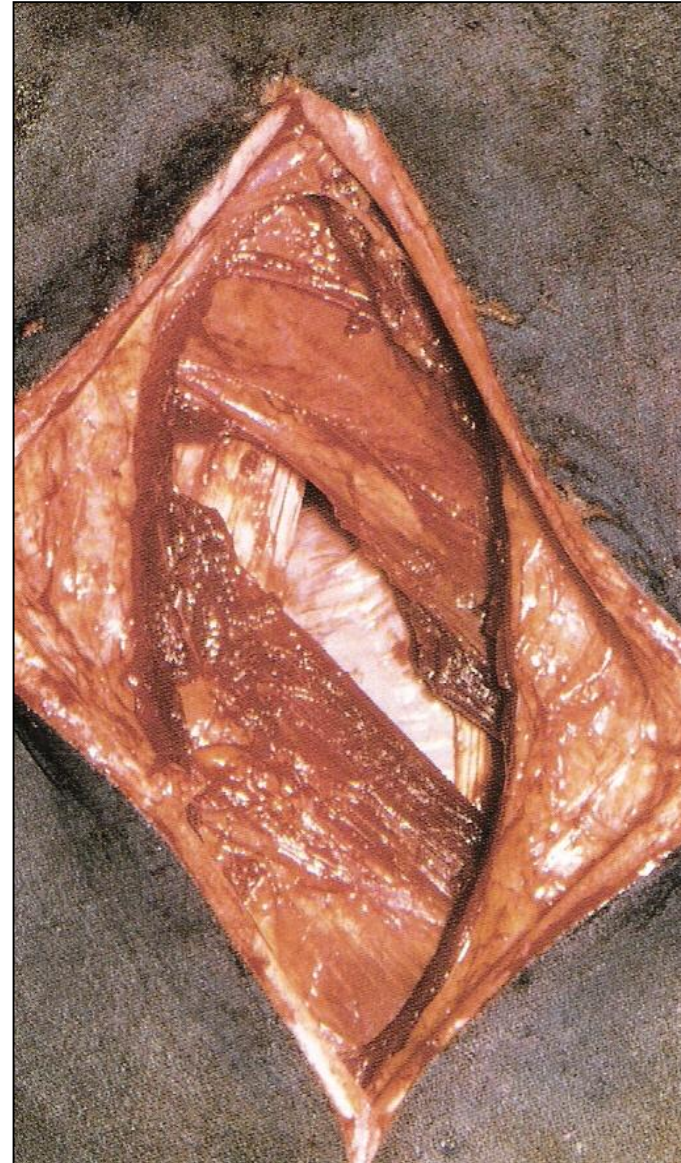
VCI 516 – Cirurgia de Grandes Animais

AFECÇÕES CIRÚRGICAS DO SISTEMA DIGESTÓRIO DOS RUMINANTES

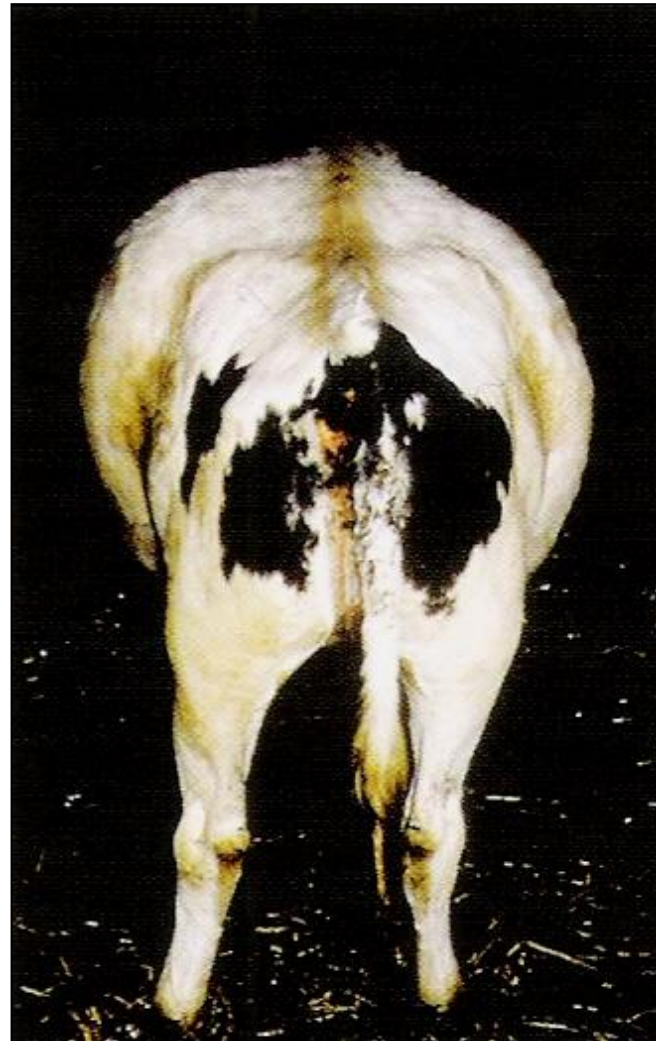Prof. Dr. Rodrigo Romero Corrêa
romero@usp.br

LAPAROTOMIA EXPLORATÓRIA

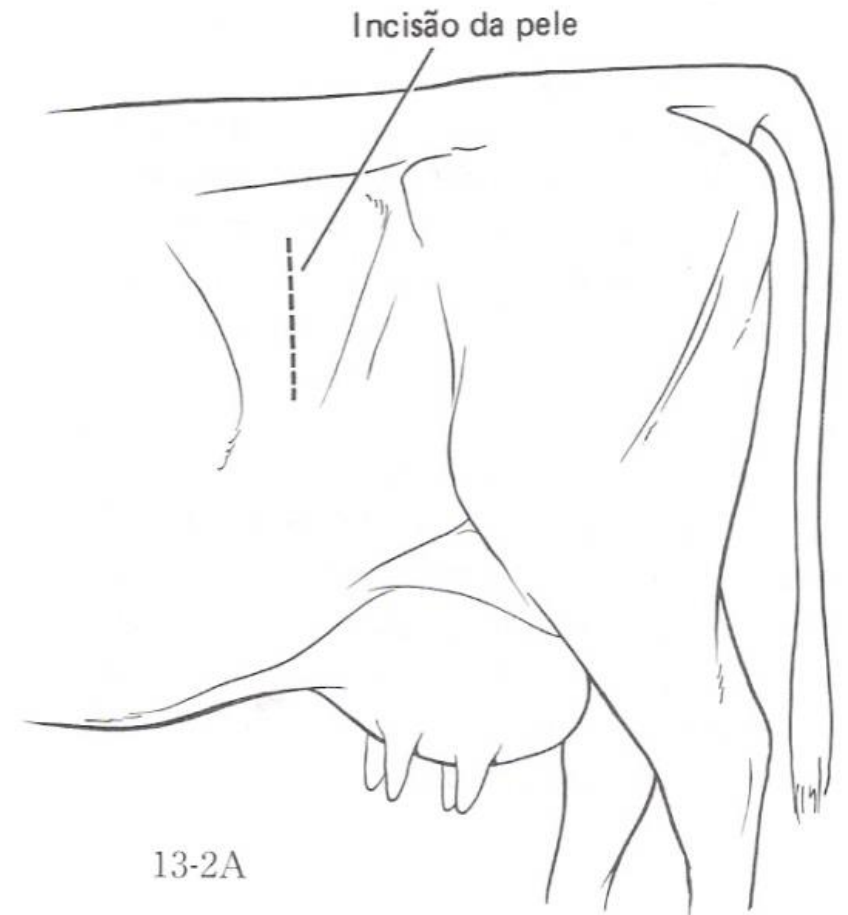
- Indicações
- Acessos cirúrgicos
- Pré-operatório
- Técnicas cirúrgicas
- Pós-operatório



LAPAROTOMIA PELO FLANCO ESQUERDO RUMENOTOMIA

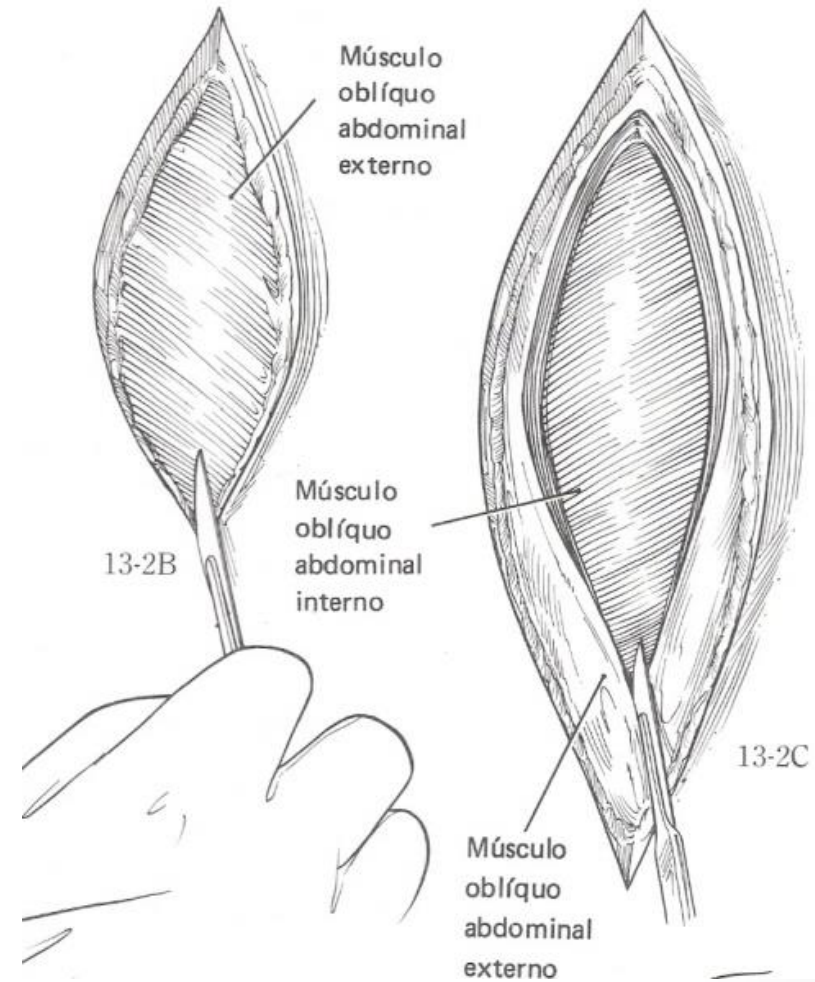


LAPAROTOMIA PELO FLANCO ESQUERDO RUMENOTOMIA

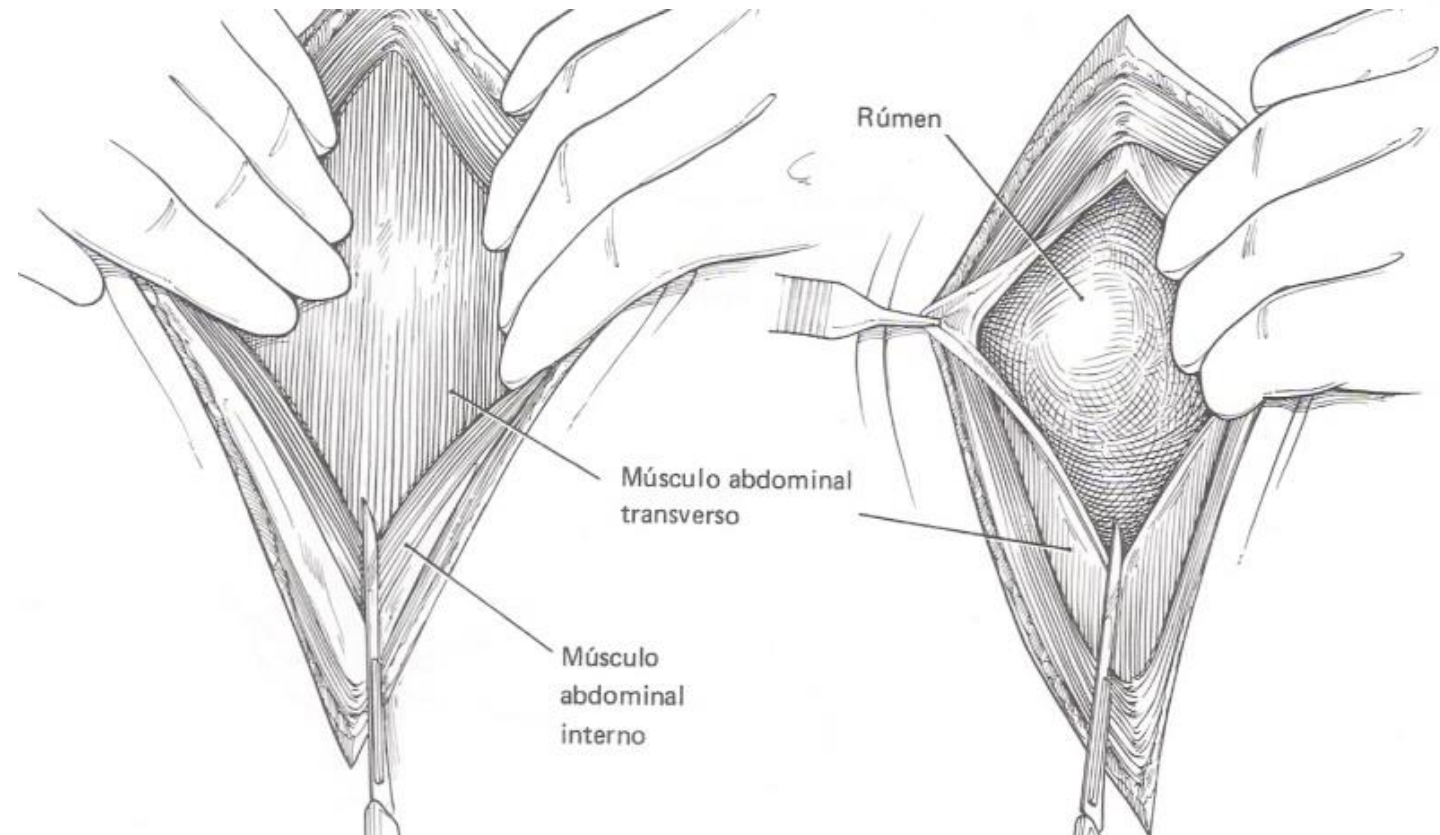


LAPAROTOMIA PELO FLANCO ESQUERDO

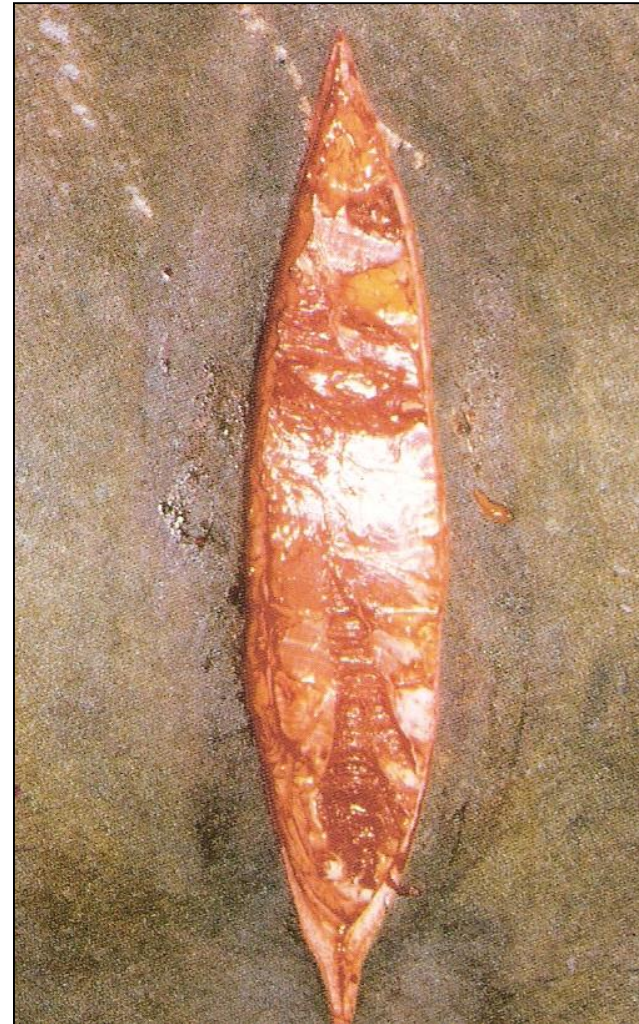RUMENOTOMIA



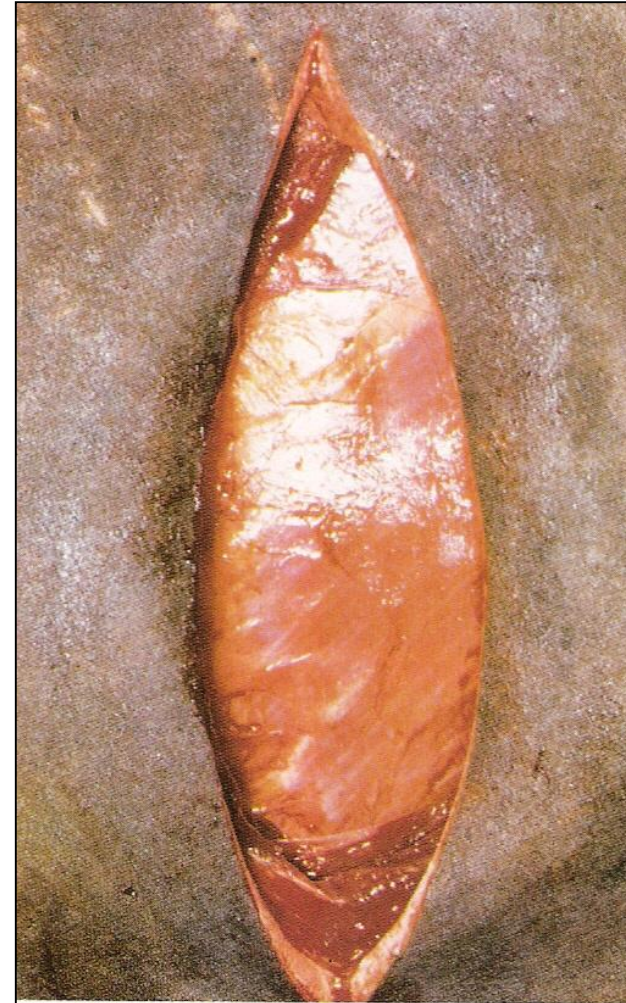LAPAROTOMIA PELO FLANCO ESQUERDO RUMENOTOMIA



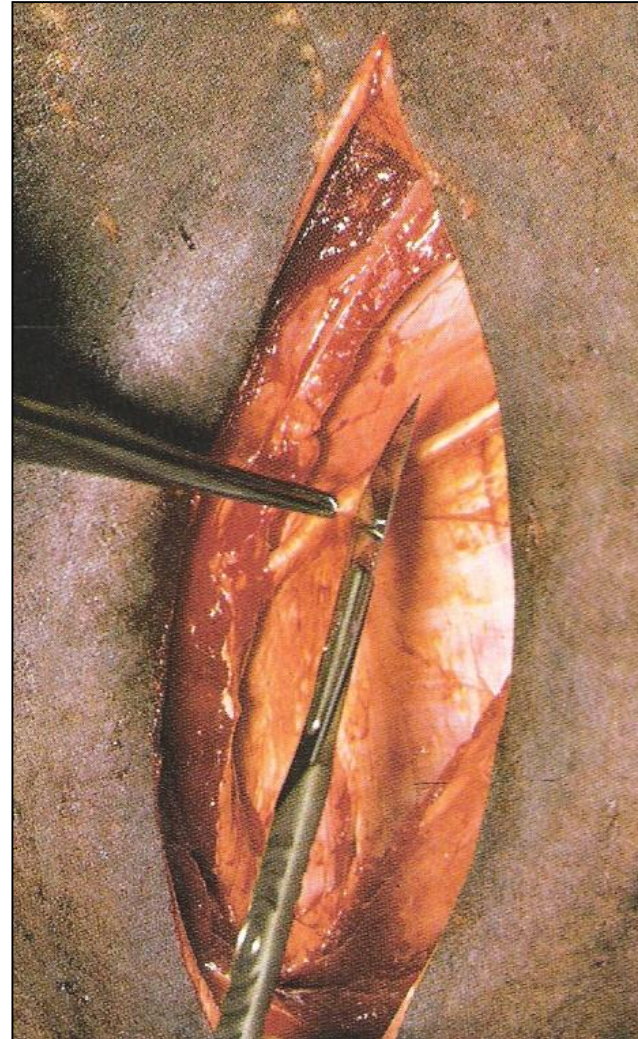
LAPAROTOMIA PELO FLANCO ESQUERDO RUMENOTOMIA



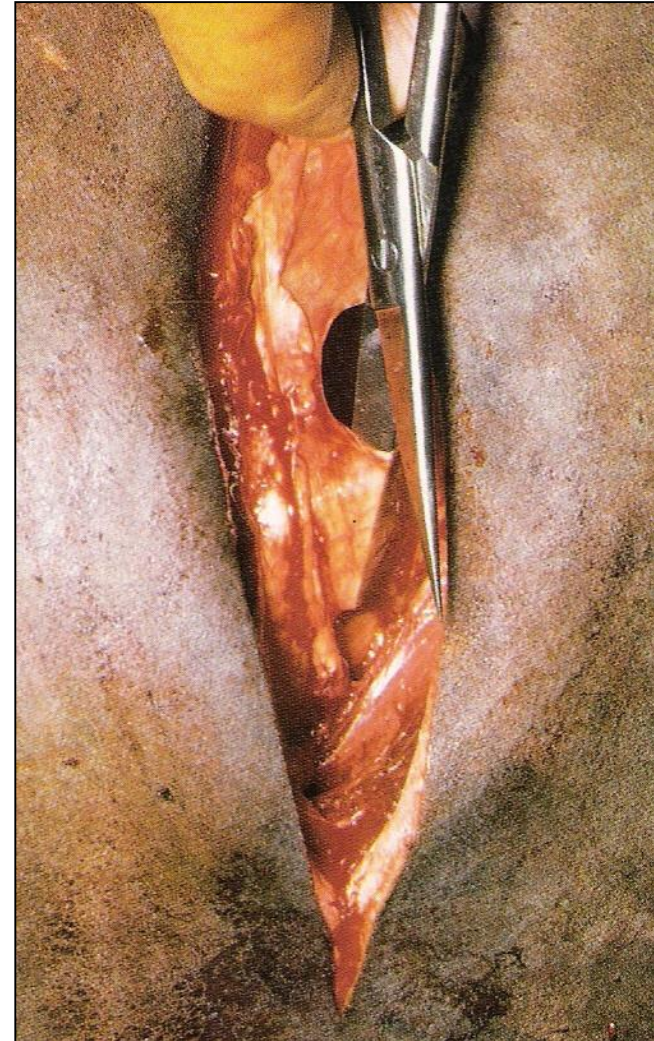
LAPAROTOMIA PELO FLANCO ESQUERDO RUMENOTOMIA



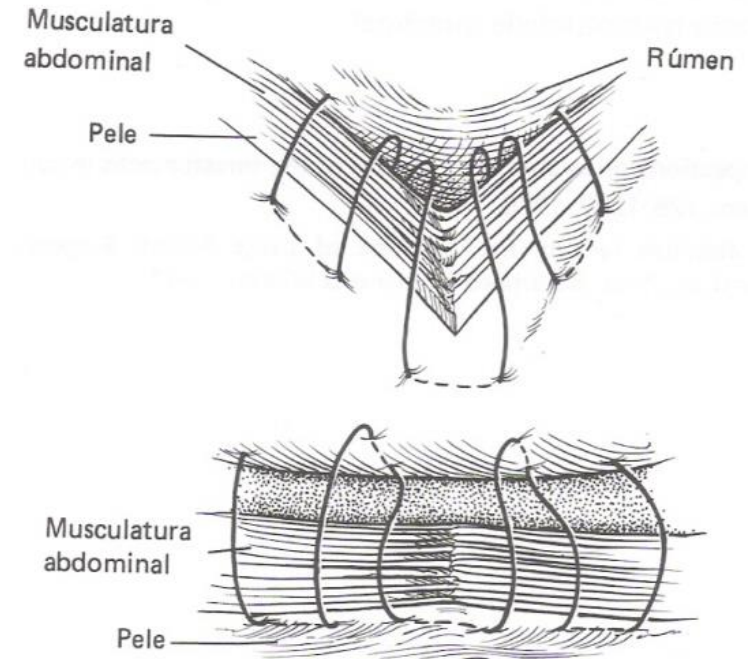
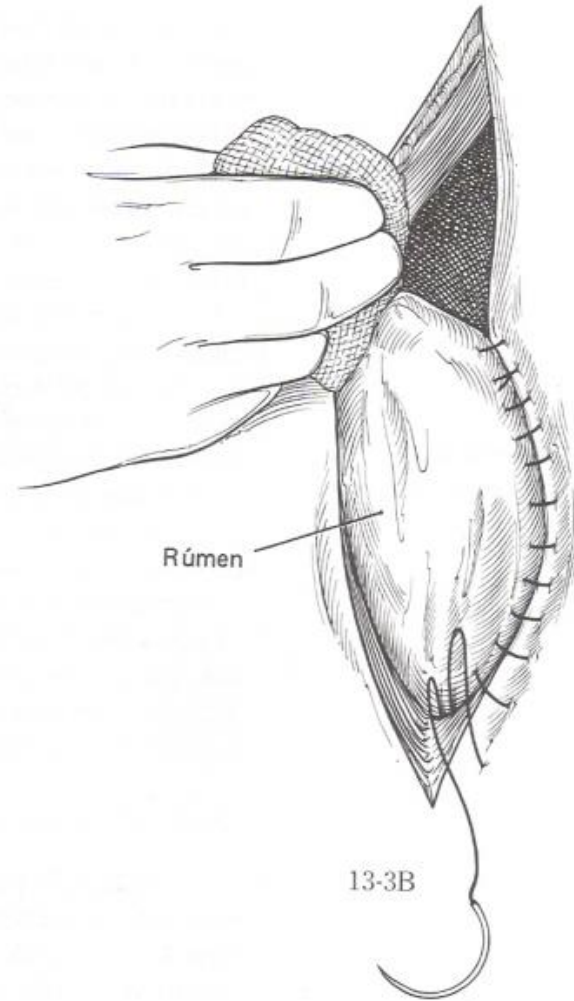
LAPAROTOMIA PELO FLANCO ESQUERDO RUMENOTOMIA



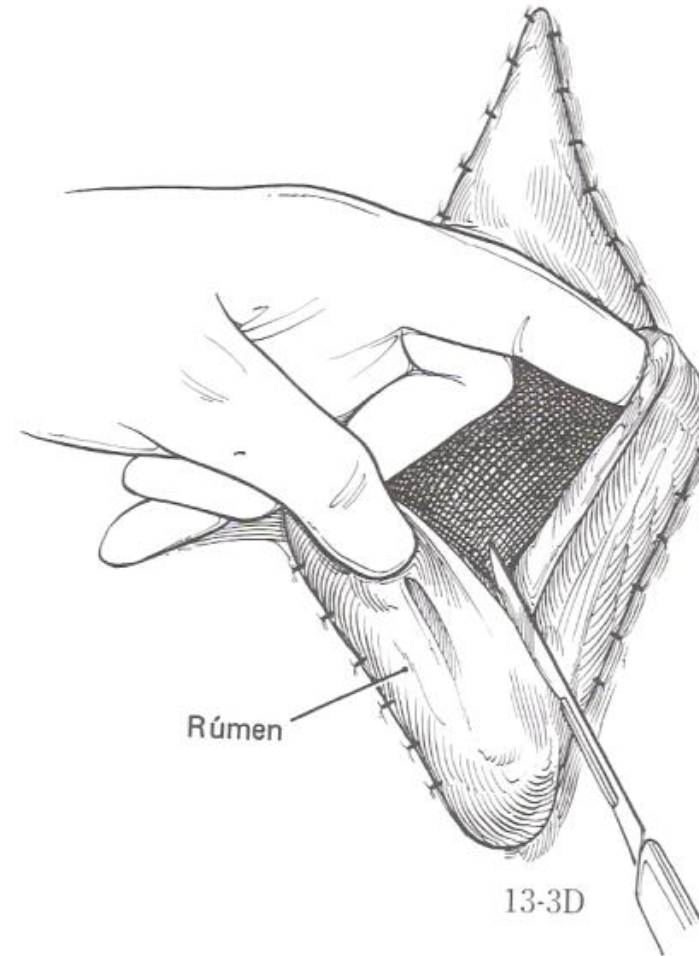
LAPAROTOMIA PELO FLANCO ESQUERDO RUMENOTOMIA



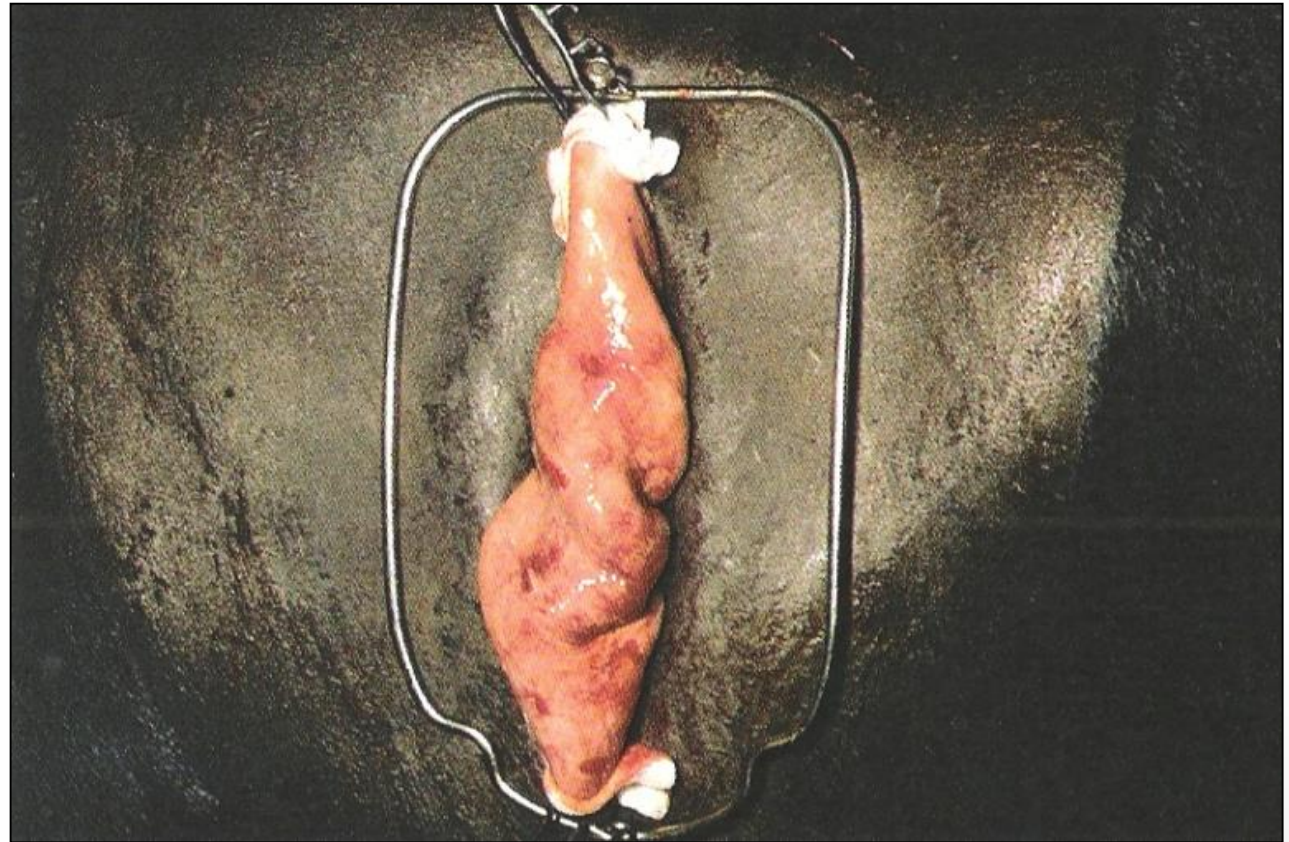
LAPAROTOMIA PELO FLANCO ESQUERDO RUMENOTOMIA



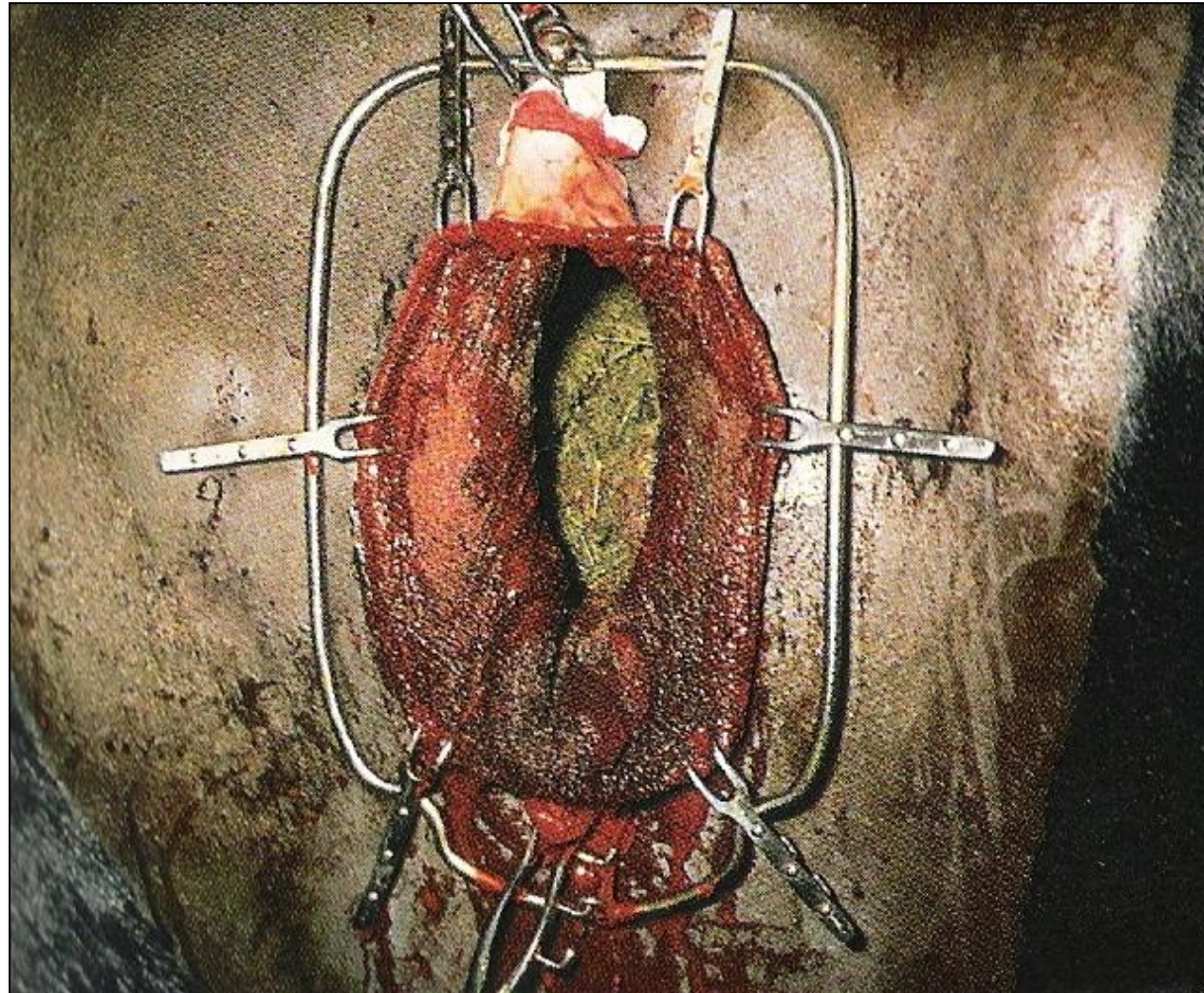
LAPAROTOMIA PELO FLANCO ESQUERDO RUMENOTOMIA



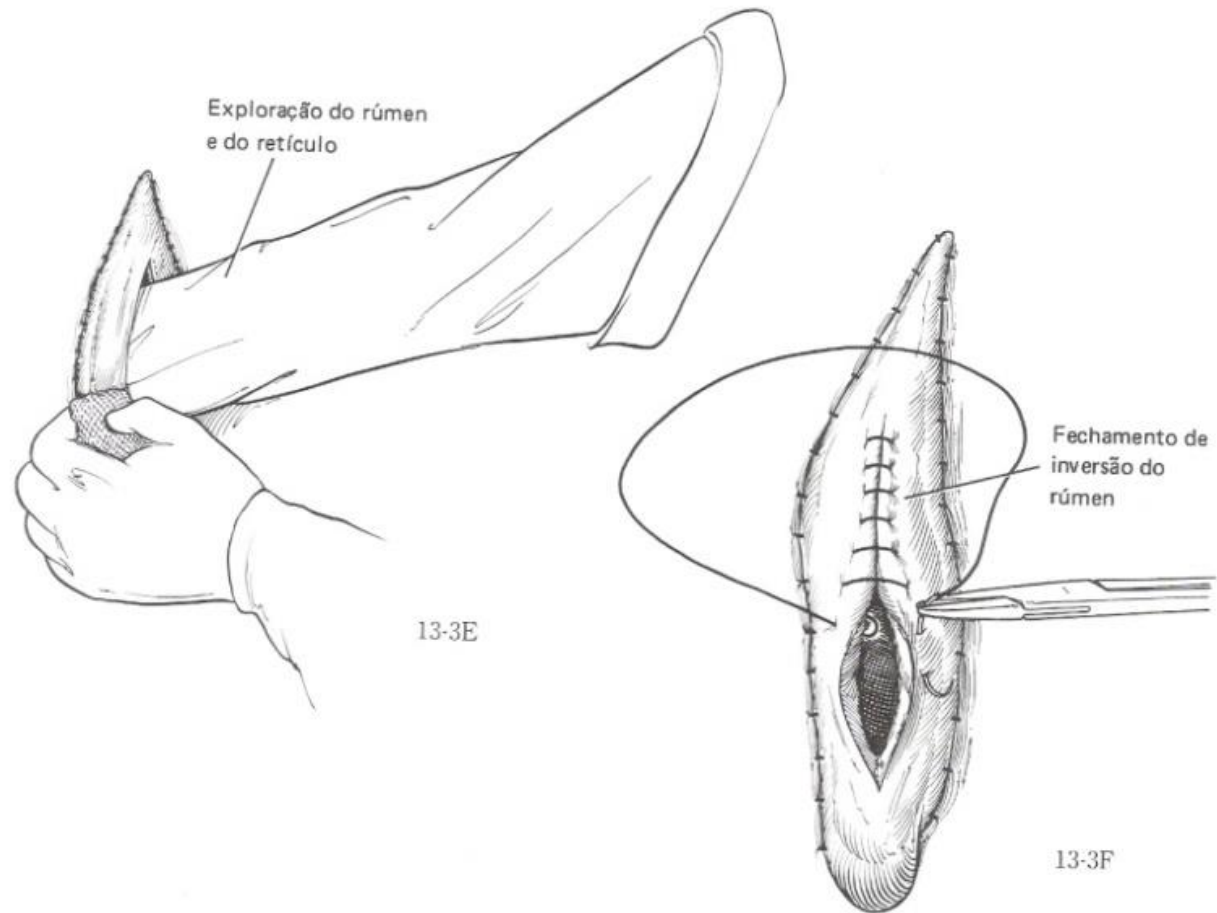
LAPAROTOMIA PELO FLANCO ESQUERDO RUMENOTOMIA



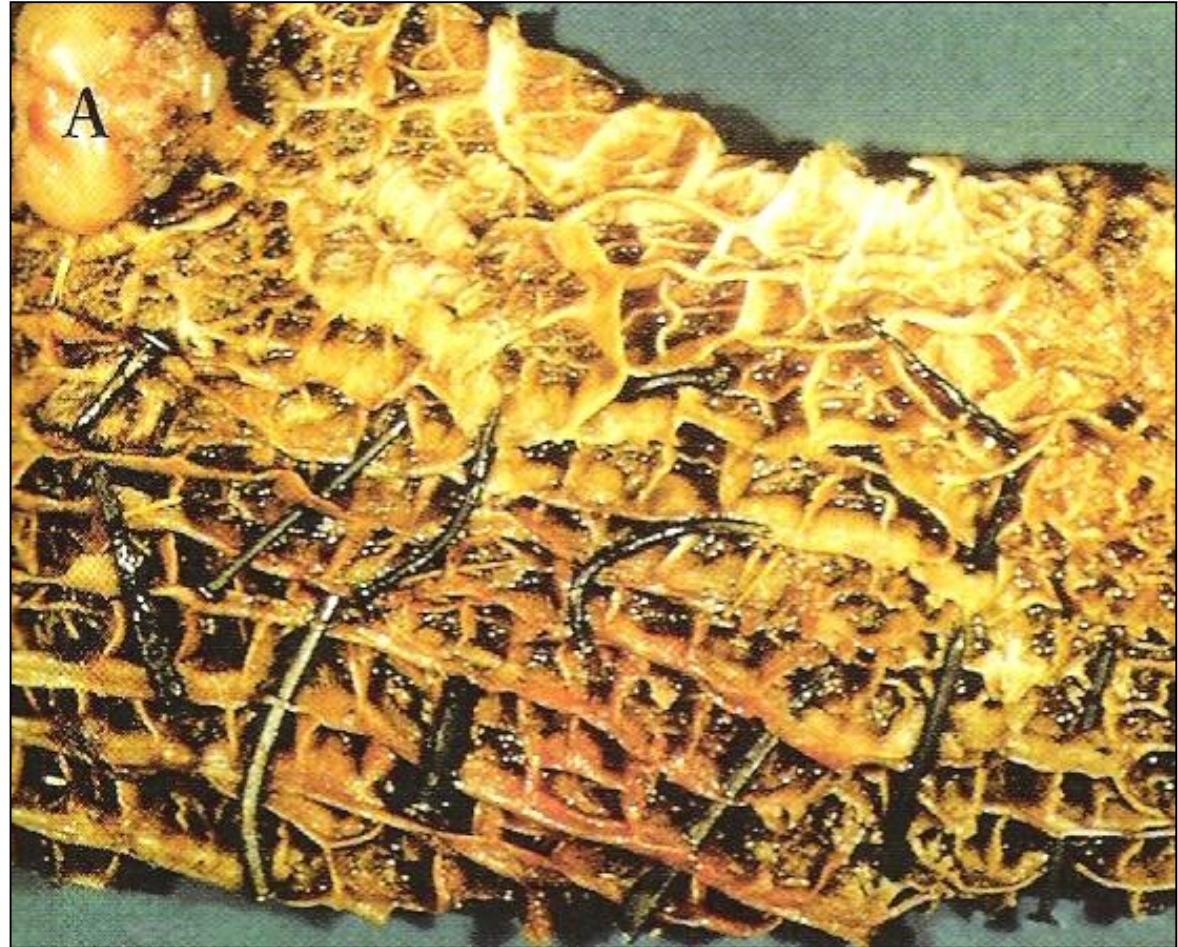LAPAROTOMIA PELO FLANCO ESQUERDO RUMENOTOMIA



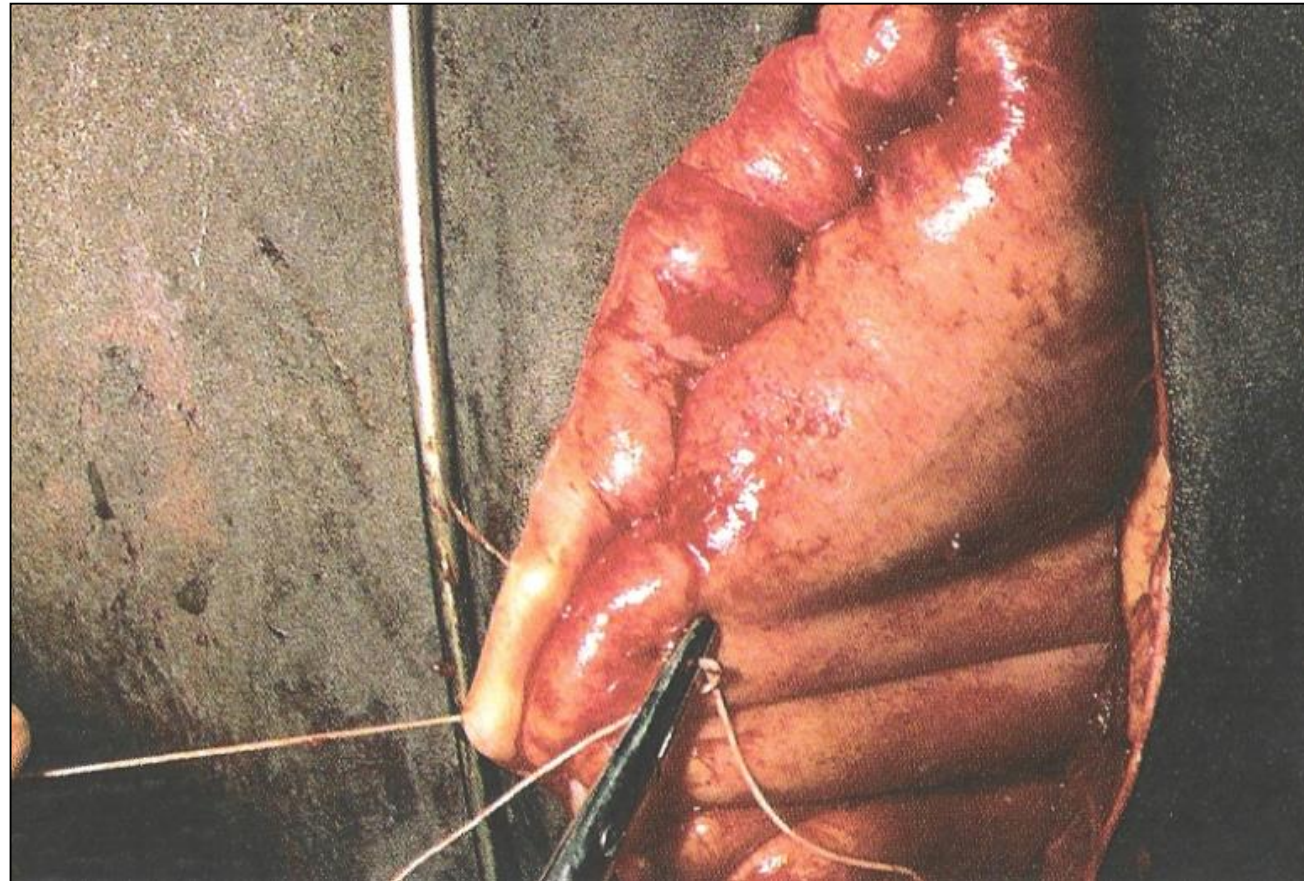LAPAROTOMIA PELO FLANCO ESQUERDO RUMENOTOMIA



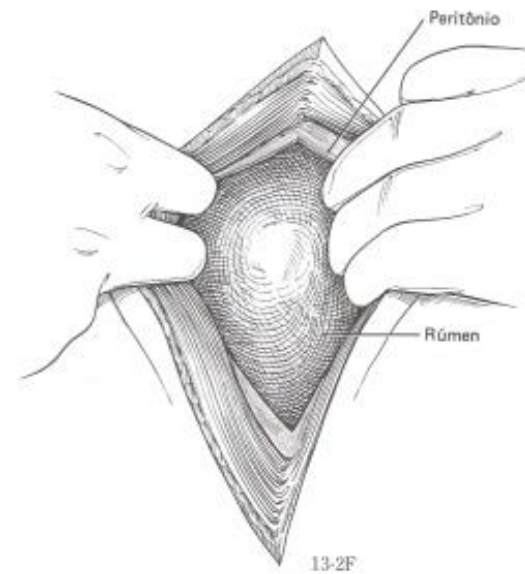
LAPAROTOMIA PELO FLANCO ESQUERDO RUMENOTOMIA



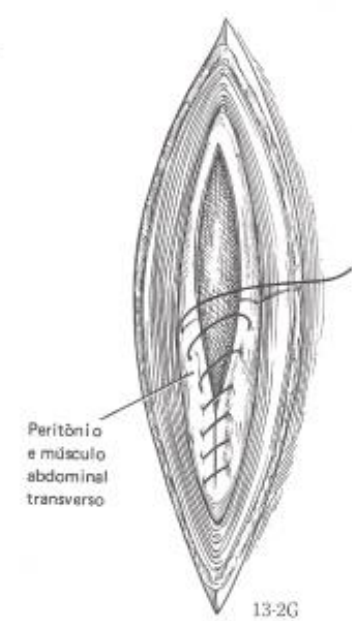
LAPAROTOMIA PELO FLANCO ESQUERDO RUMENOTOMIA



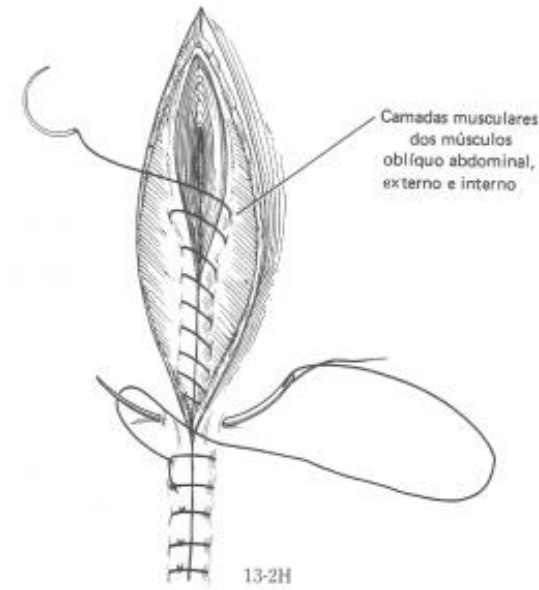
LAPAROTOMIA PELO FLANCO ESQUERDO RUMENOTOMIA



13-2F

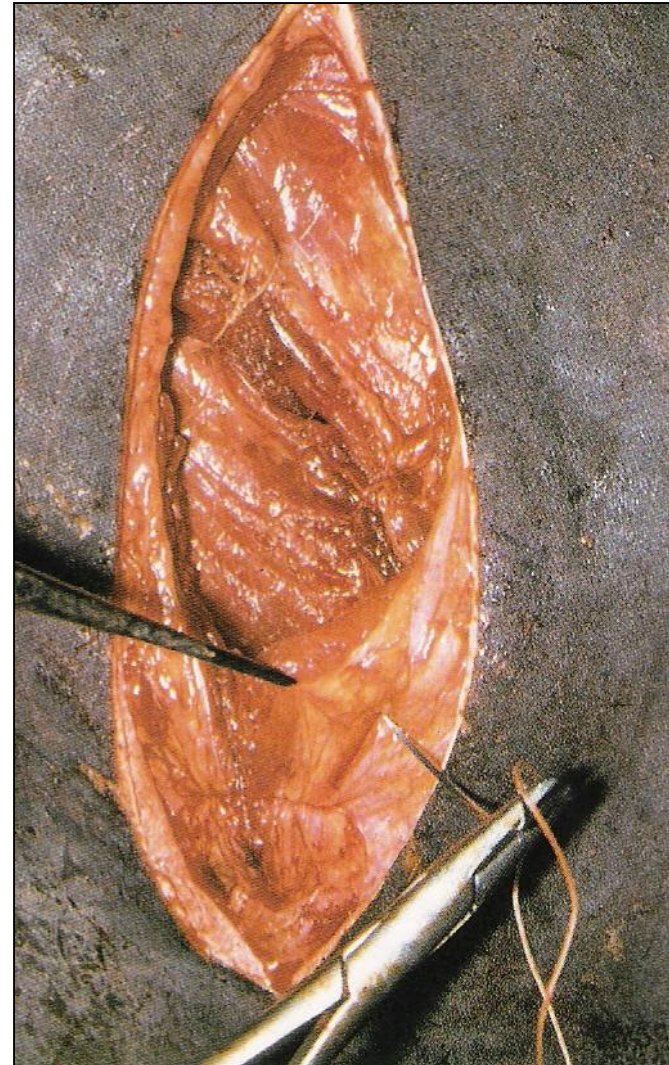


13-2G

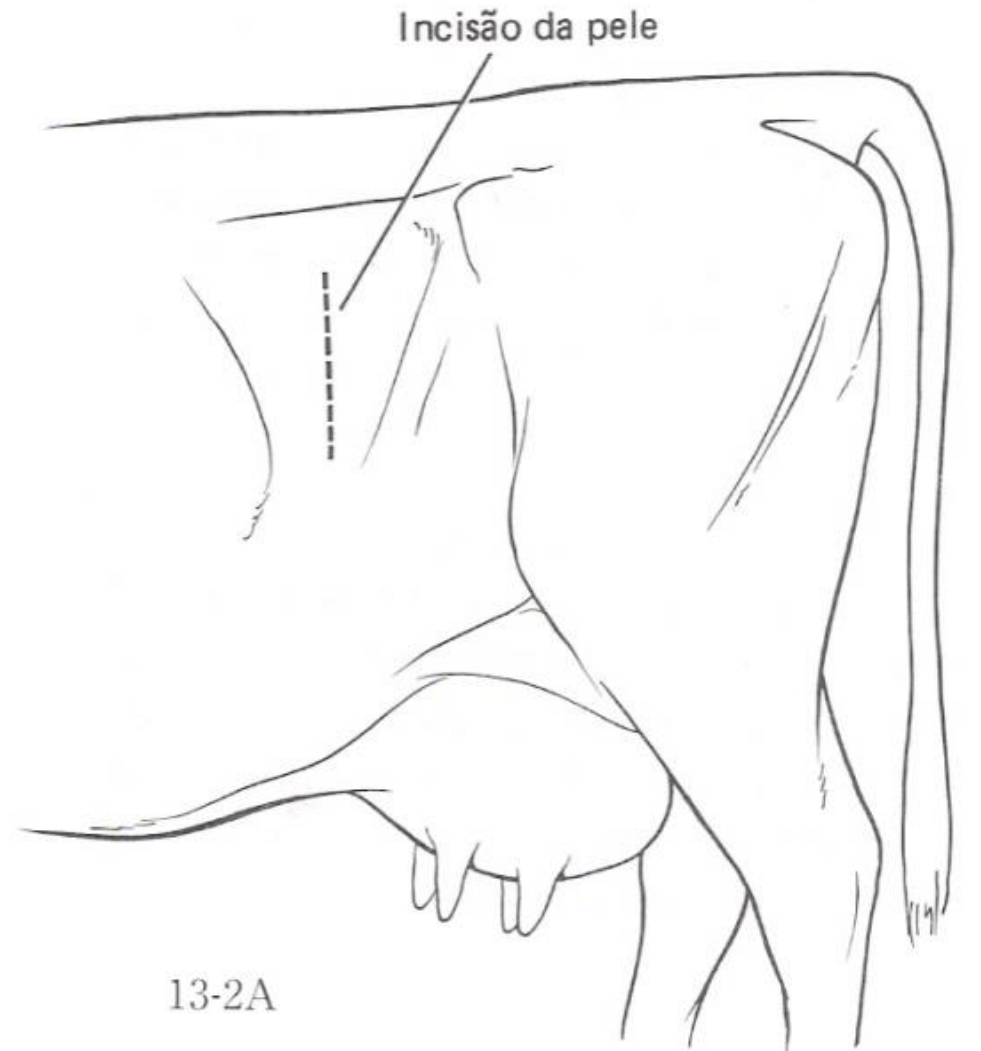


13-2H

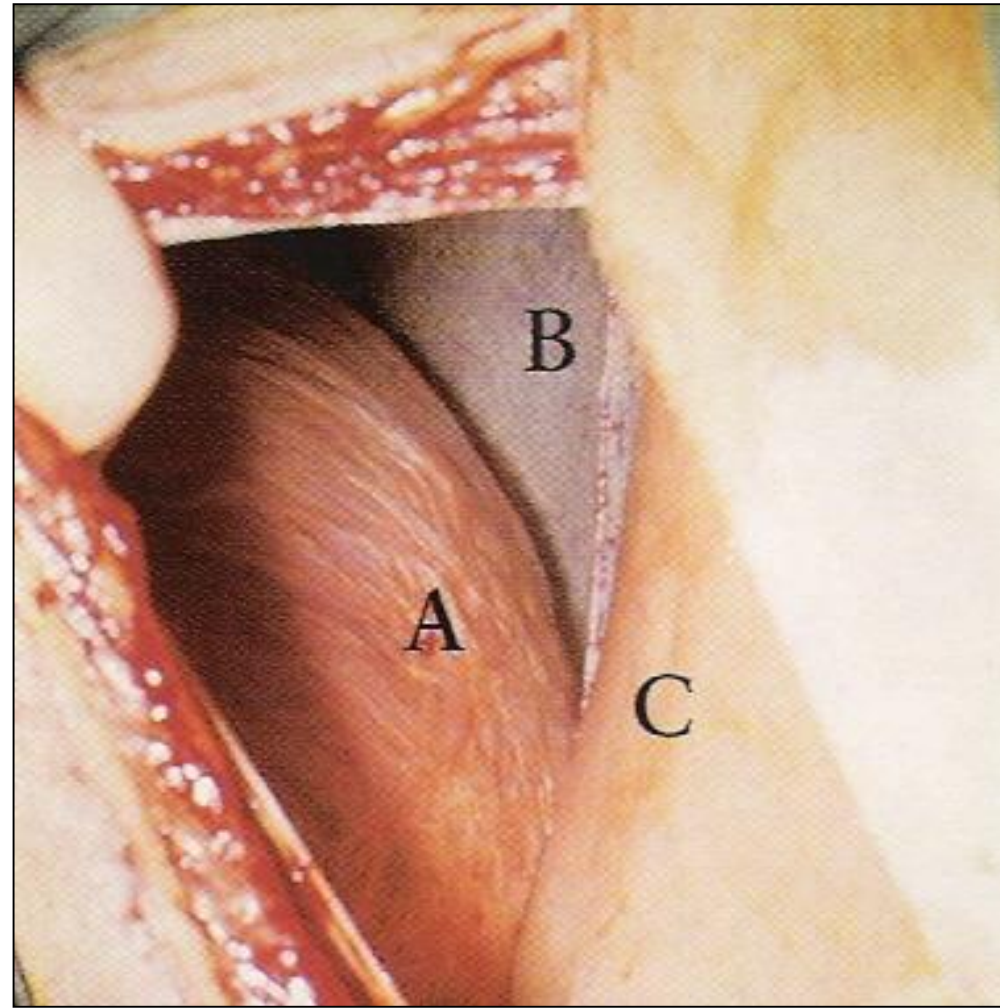
LAPAROTOMIA PELO FLANCO ESQUERDO RUMENOTOMIA



ABOMASOPEXIA PELO FLANCO ESQUERDO



ABOMASOPEXIA PELO FLANCO ESQUERDO



ABOMASOPEXIA PELO FLANCO ESQUERDO

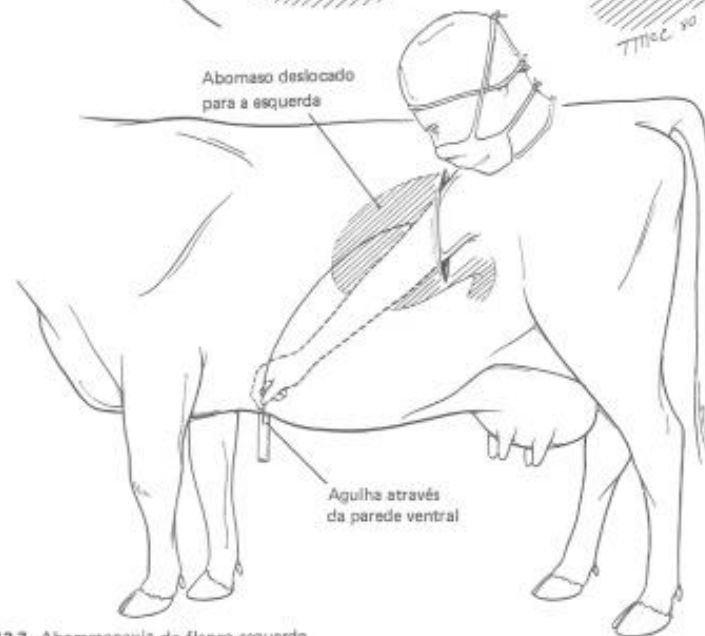
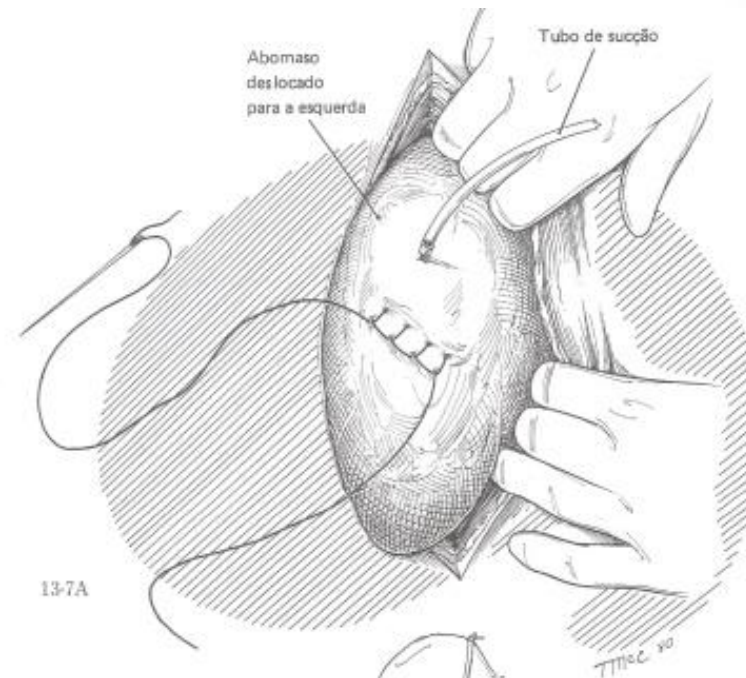
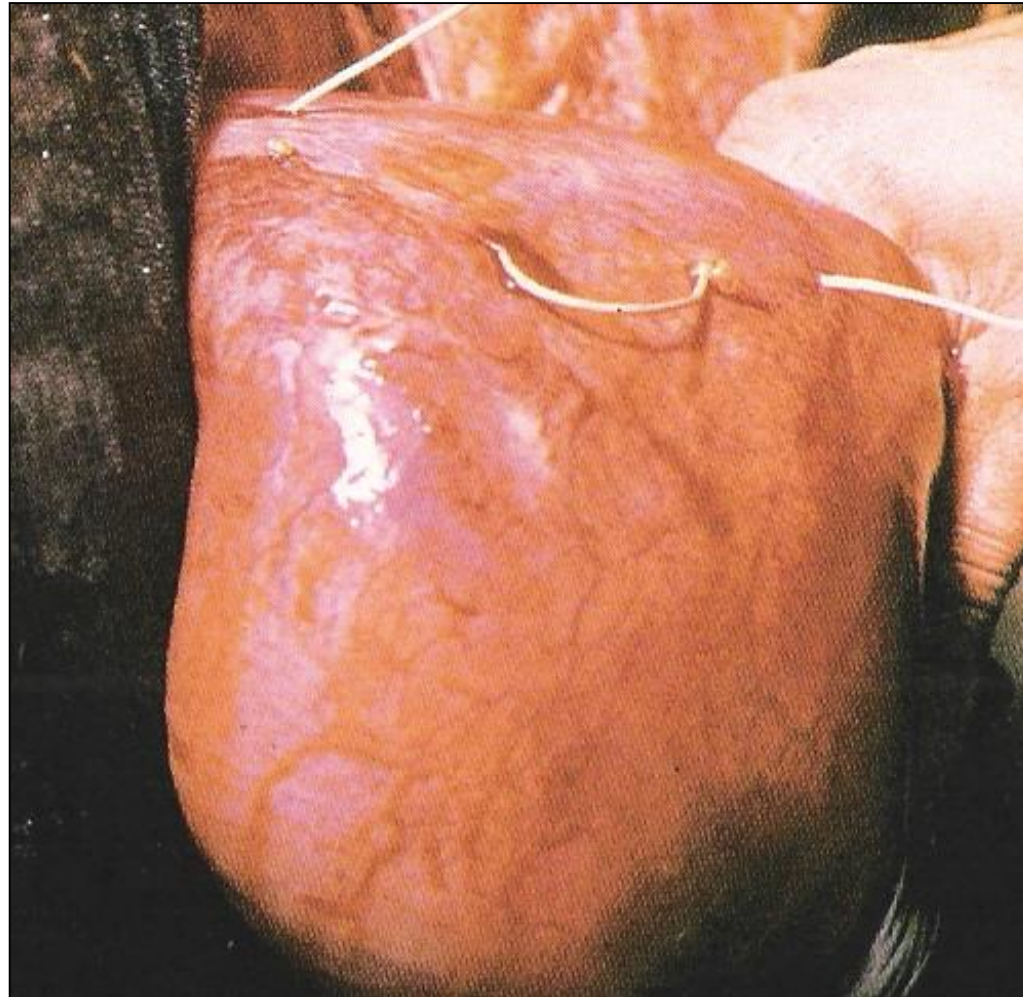


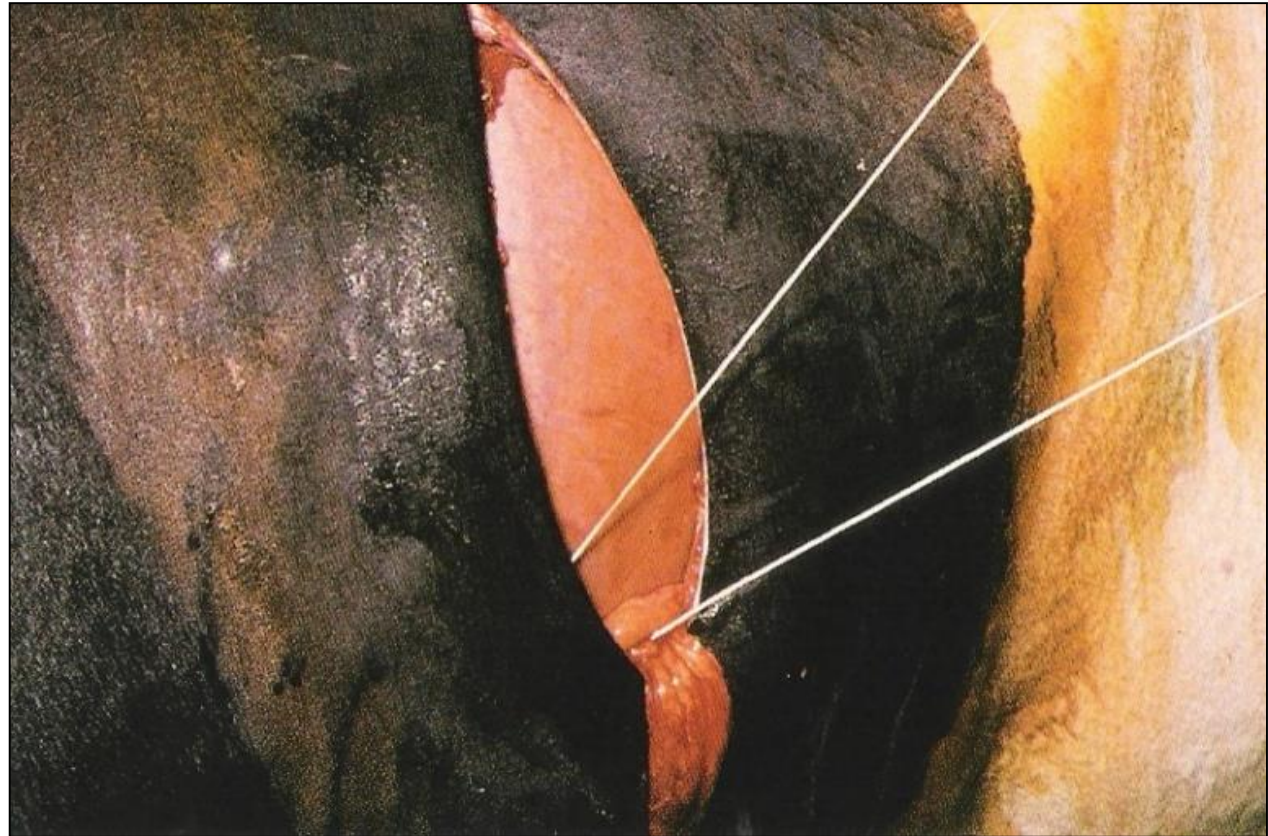
Fig. 13-7. Abomasopexia do flanco esquerdo.

13-7B

ABOMASOPEXIA PELO FLANCO ESQUERDO



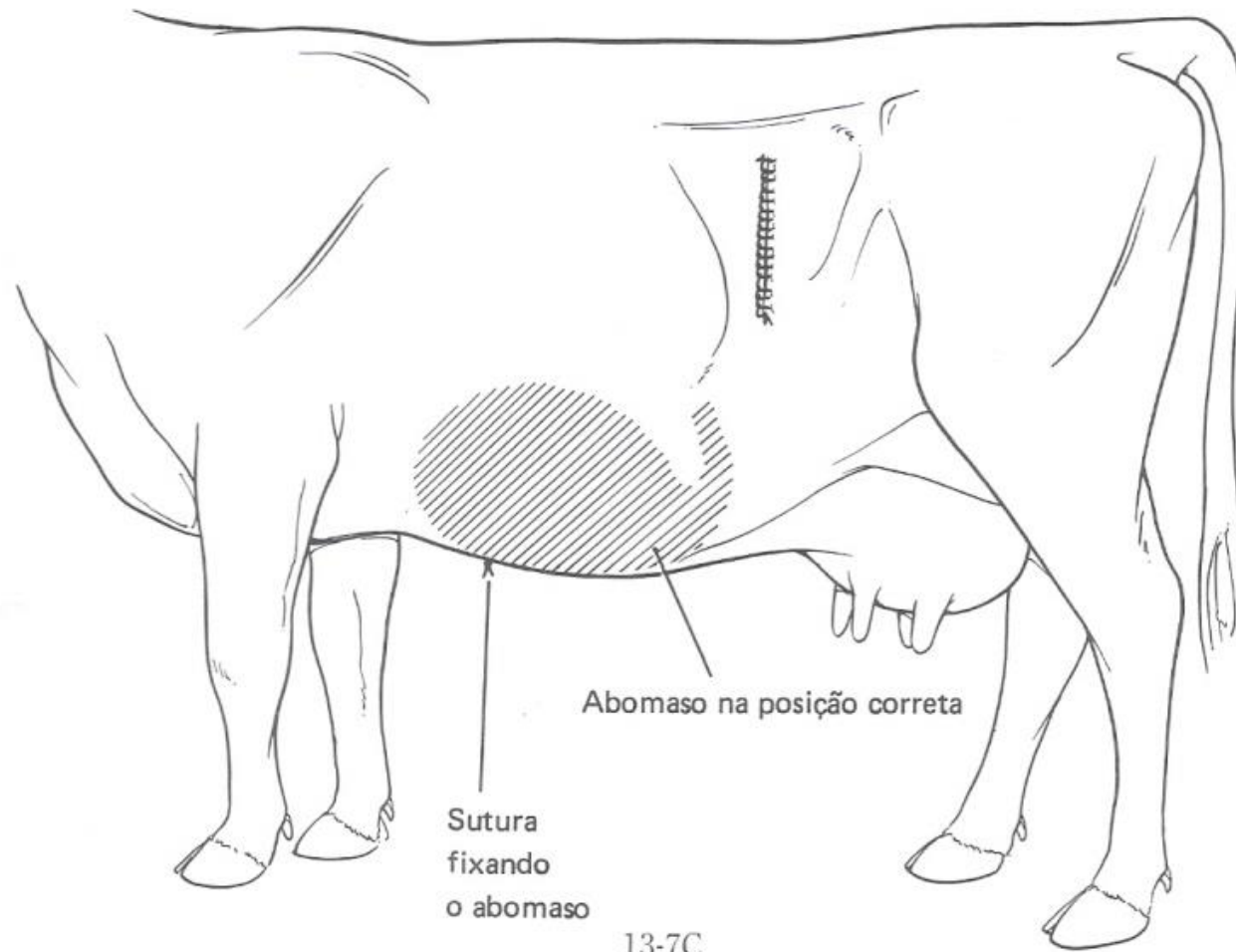
ABOMASOPEXIA PELO FLANCO ESQUERDO



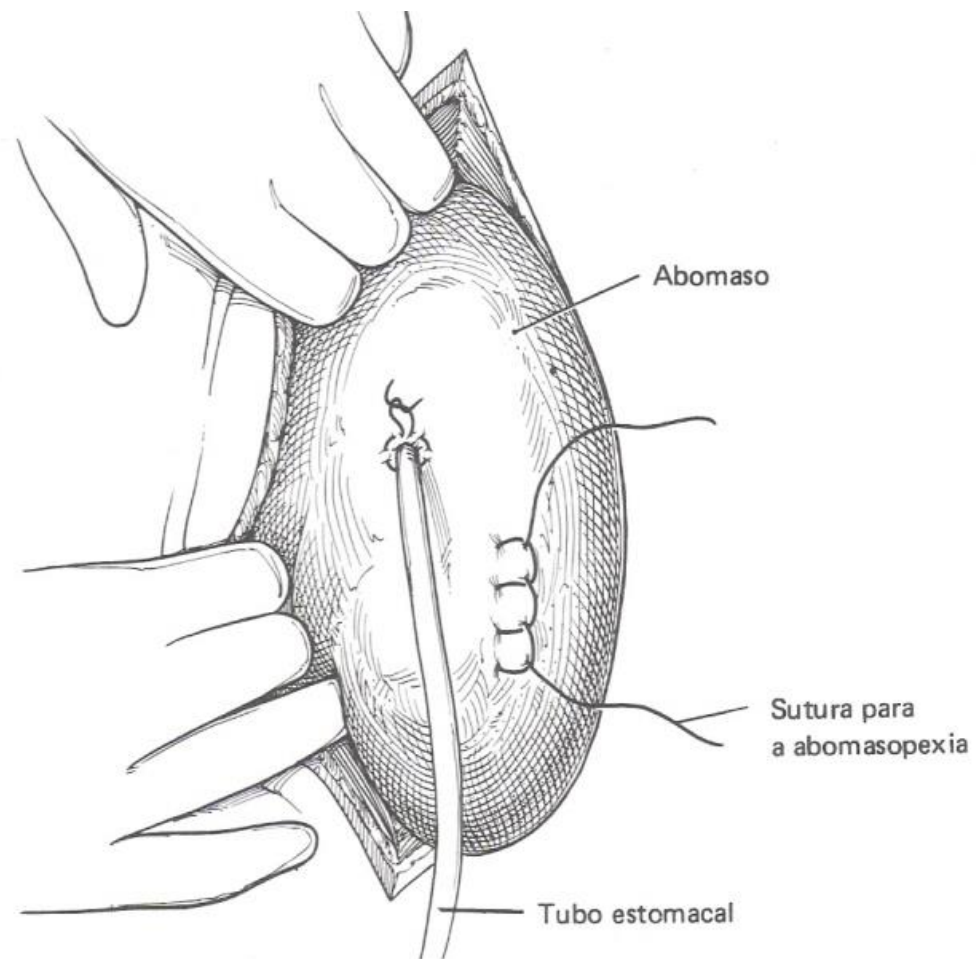
ABOMASOPEXIA PELO FLANCO ESQUERDO



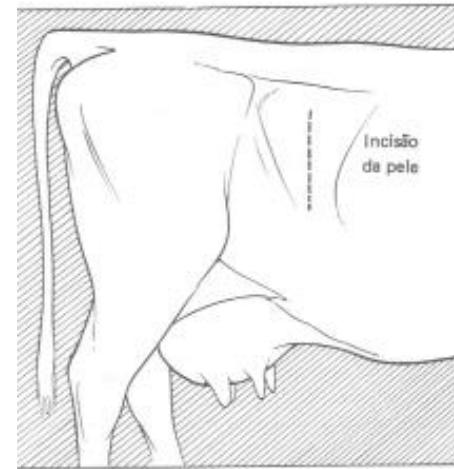ABOMASOPEXIA PELO FLANCO ESQUERDO



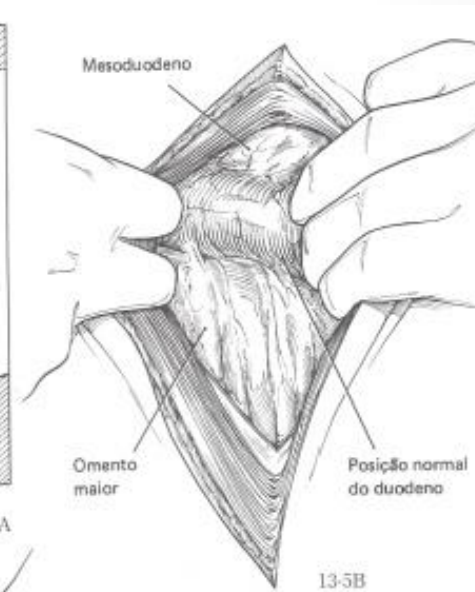
ABOMASOPEXIA / OMENTOPEXIA PELO FLANCO DIREITO



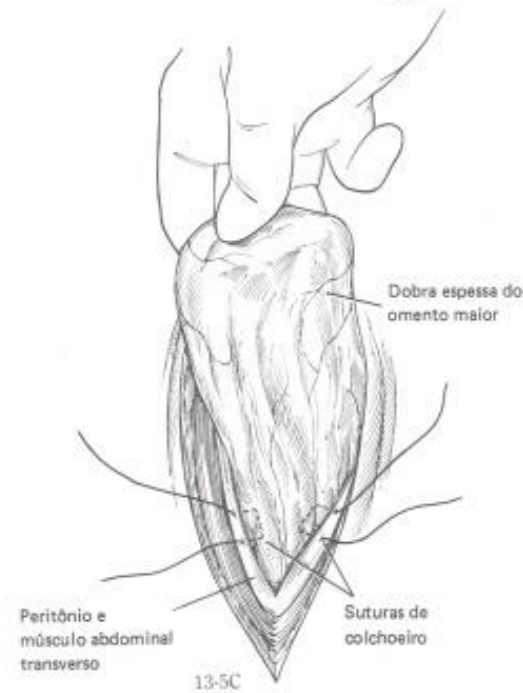ABOMASOPEXIA / OMENTOPEXIA PELO FLANCO DIREITO



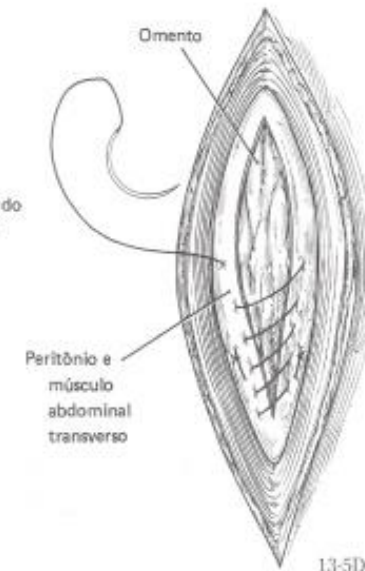
13-5A



13-5B



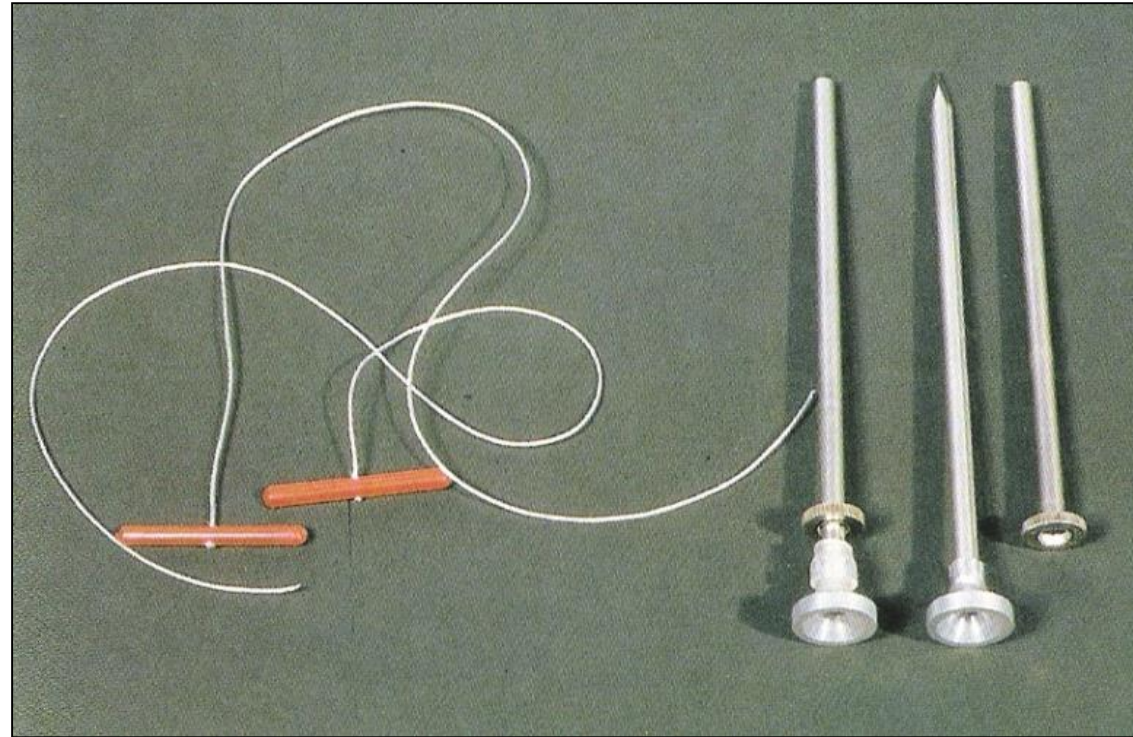
13-5C



13-5D

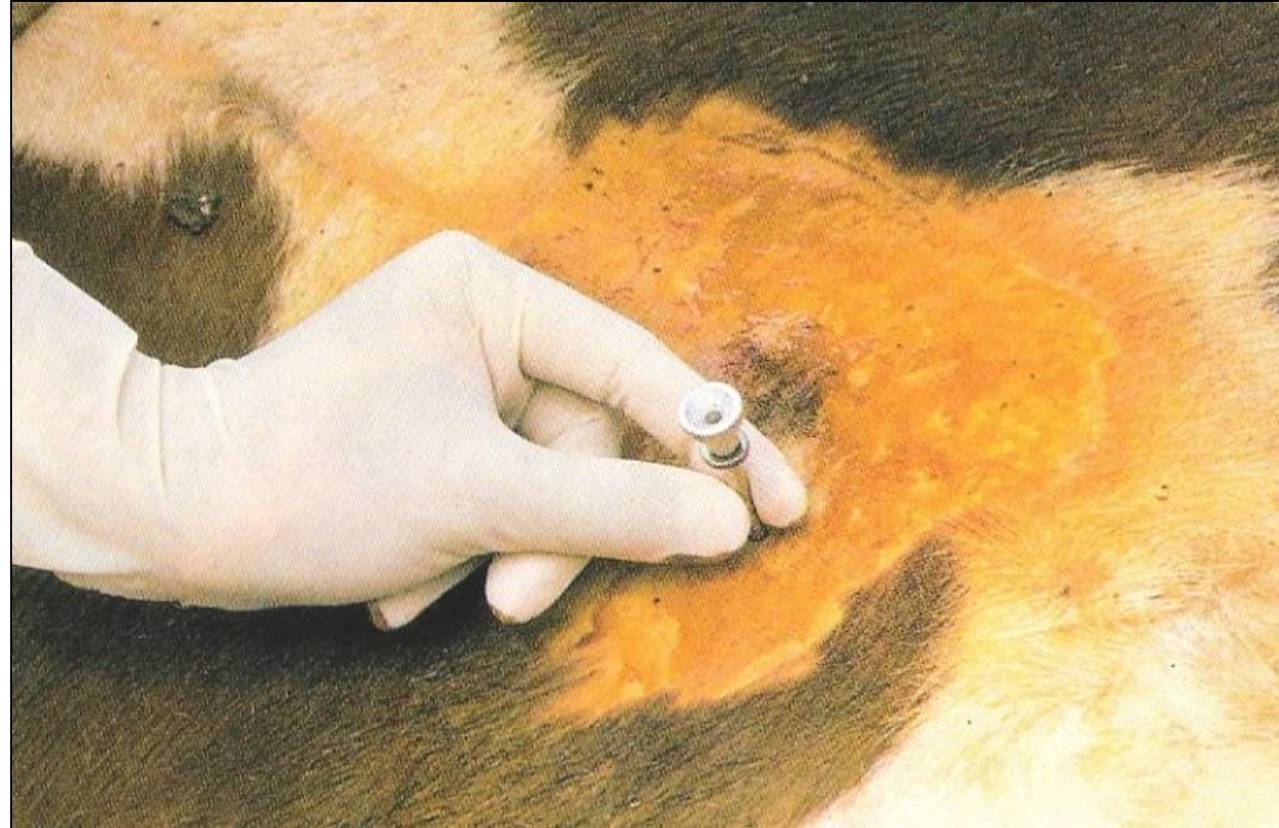ABOMASOPEXIA

Técnica fechada



ABOMASOPEXIA

Técnica fechada



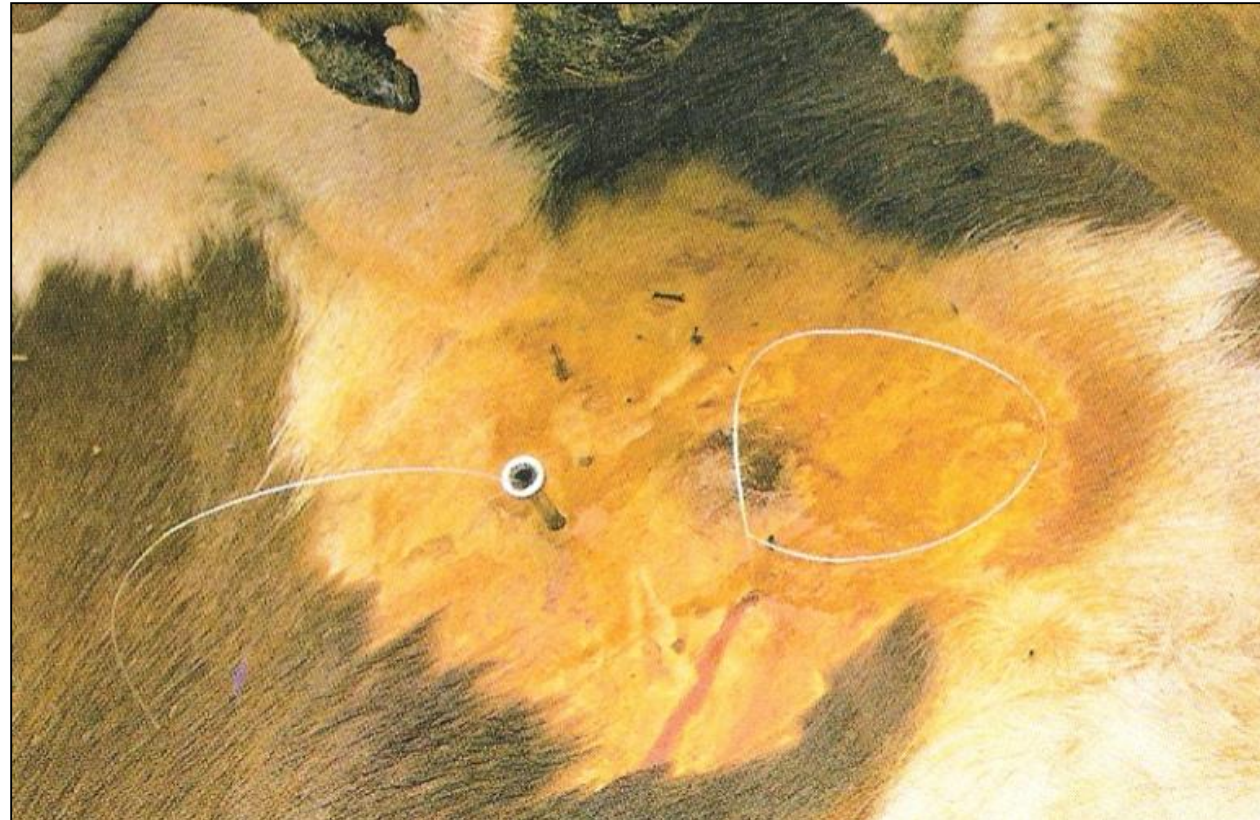
ABOMASOPEXIA

Técnica fechada



ABOMASOPEXIA

Técnica fechada



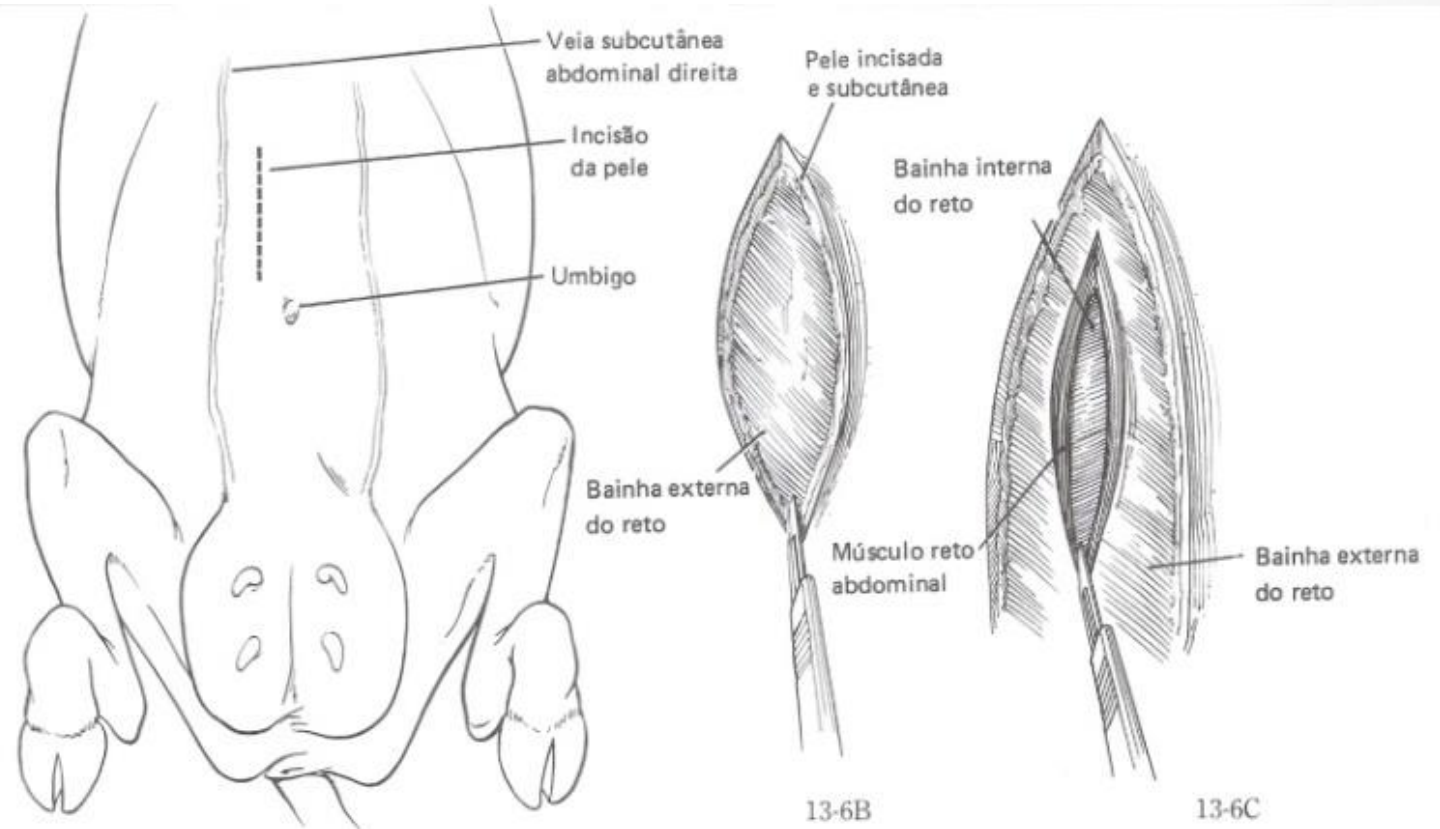
ABOMASOPEXIA

Técnica fechada



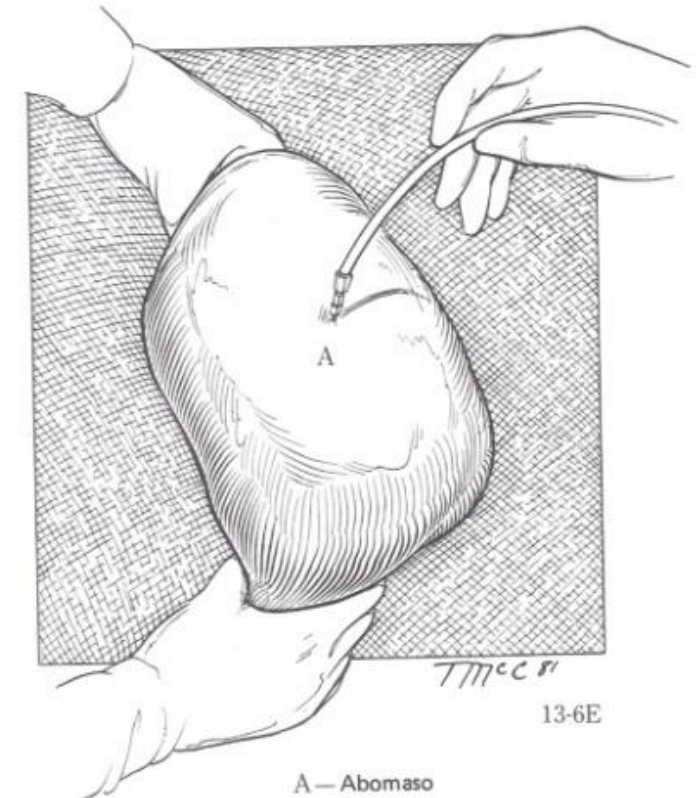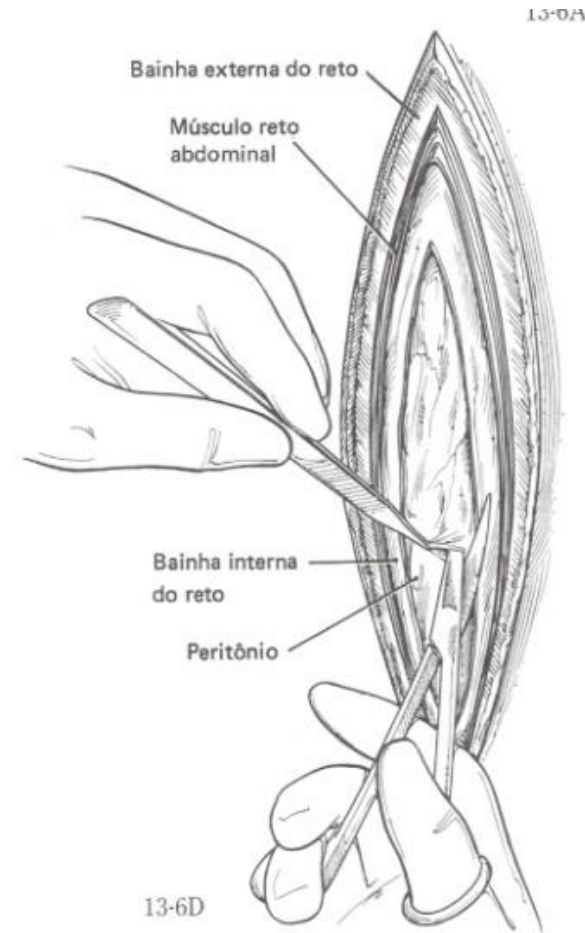
ABOMASOPEXIA

Laparotomia paramediana



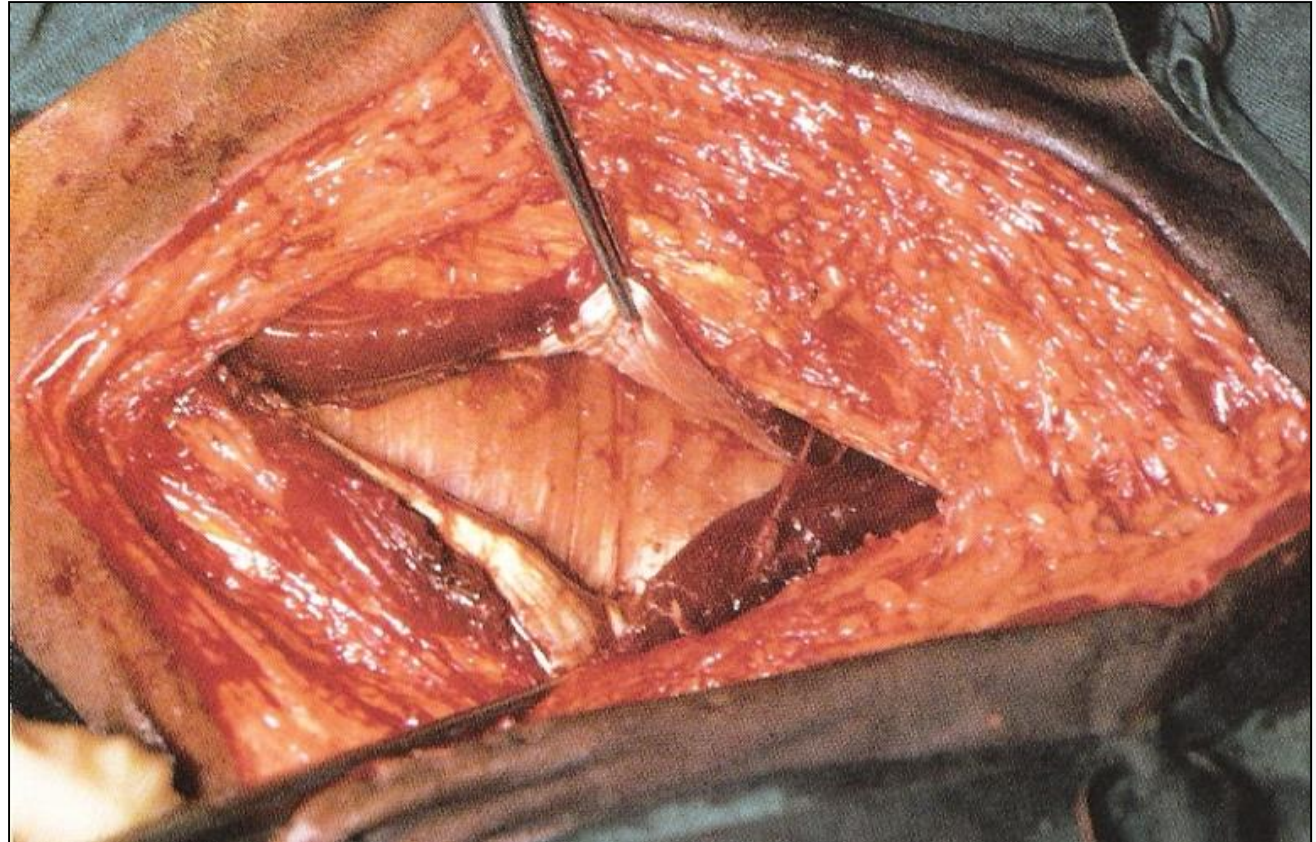
ABOMASOPEXIA

Laparotomia paramediana



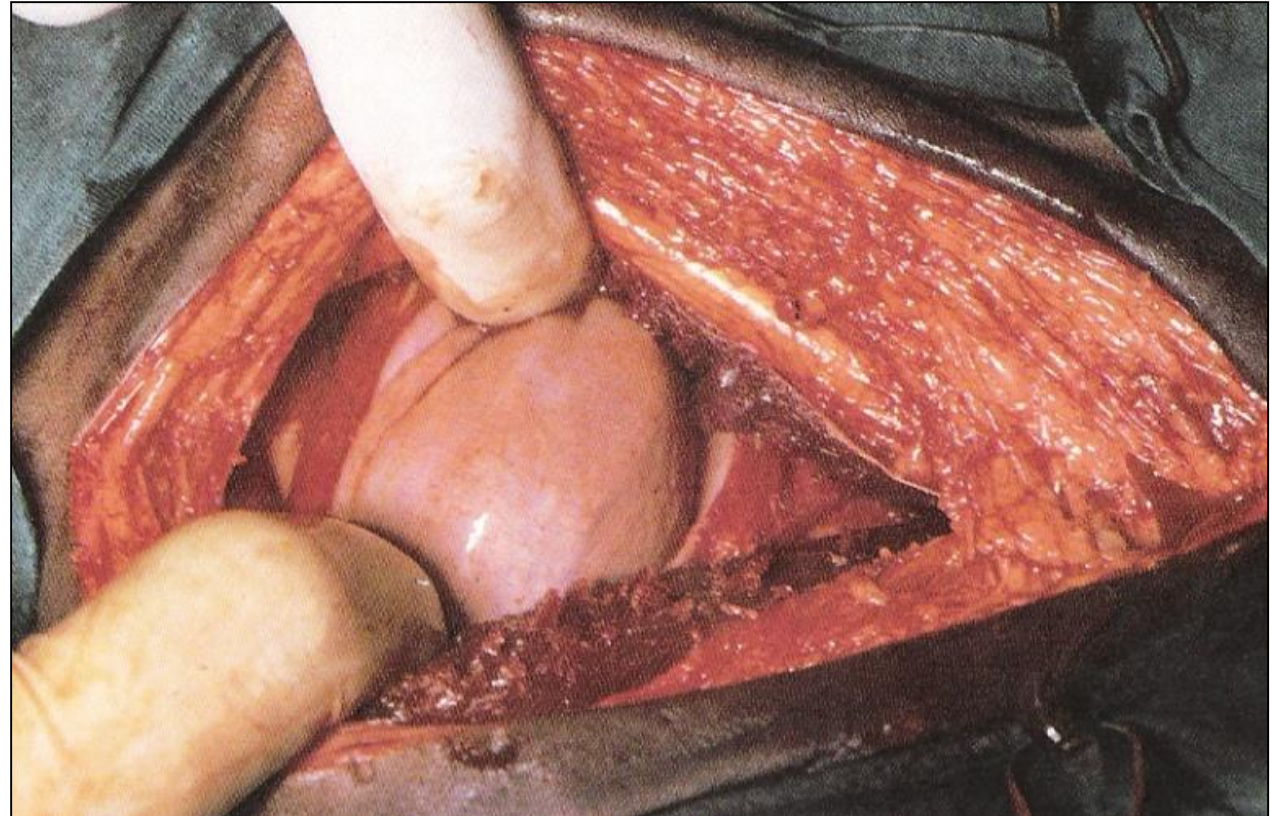
ABOMASOPEXIA

Laparotomia paramediana



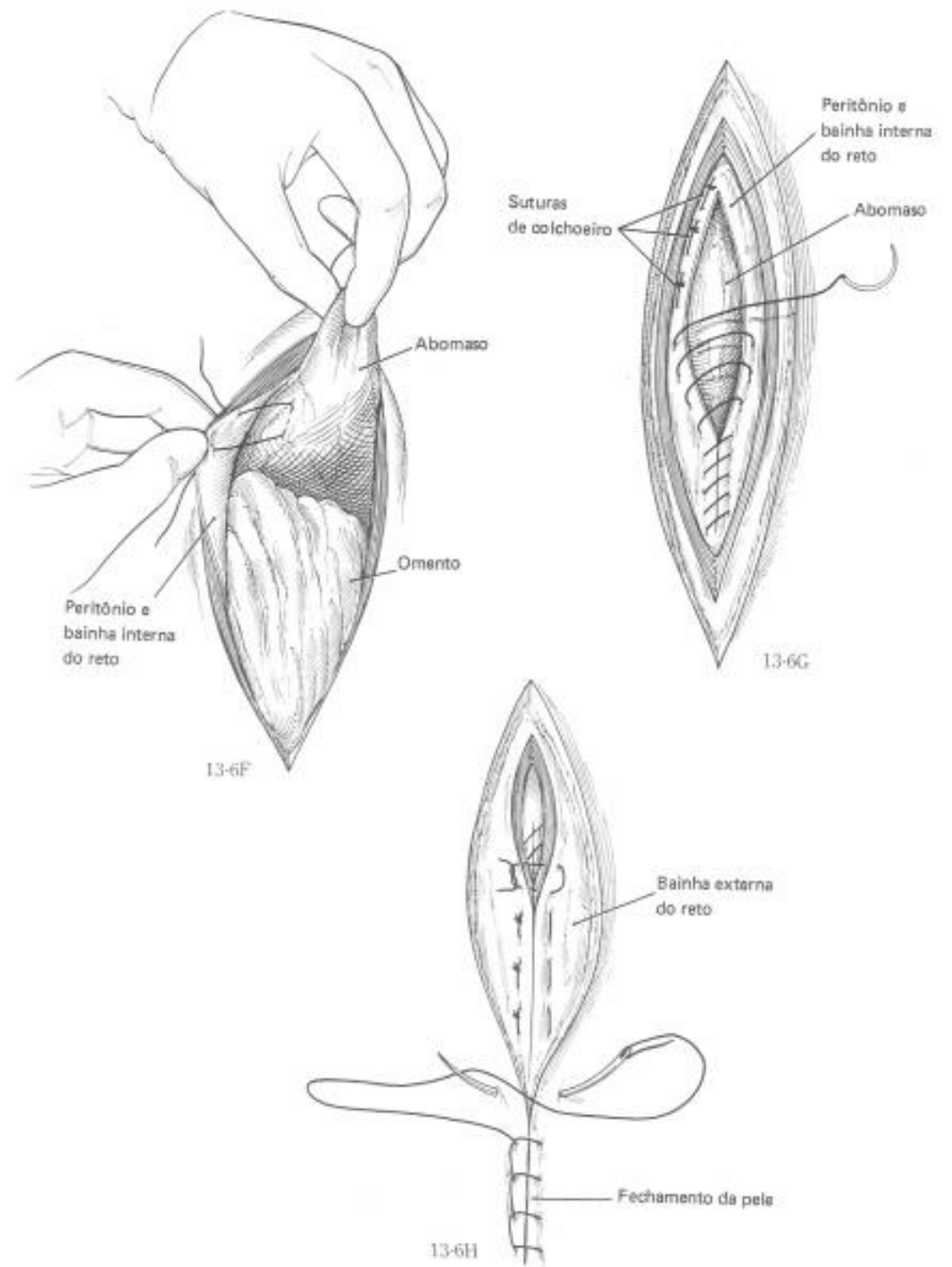
ABOMASOPEXIA

Laparotomia paramediana



ABOMASOPEXIA

Laparotomia paramediana



ABOMASOPEXIA

Laparotomia paramediana

