



# Angiografía Diagnóstica

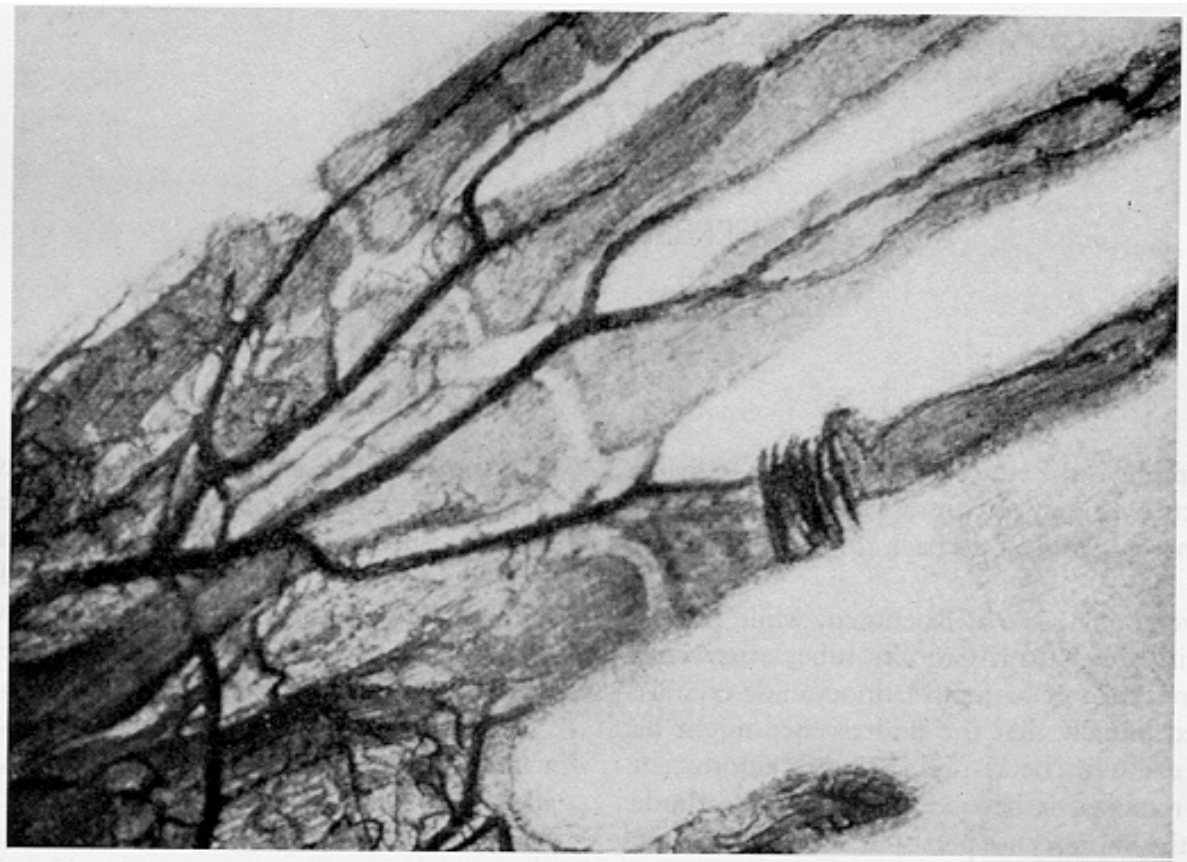
Daniel Giansante Abud

## Exame Radiológico Vascular

- Angiografia Convencional com Subtração Digital
- Angiografia por Tomografia Computadorizada
- Angiografia por Ressonância Magnética
- US com Doppler

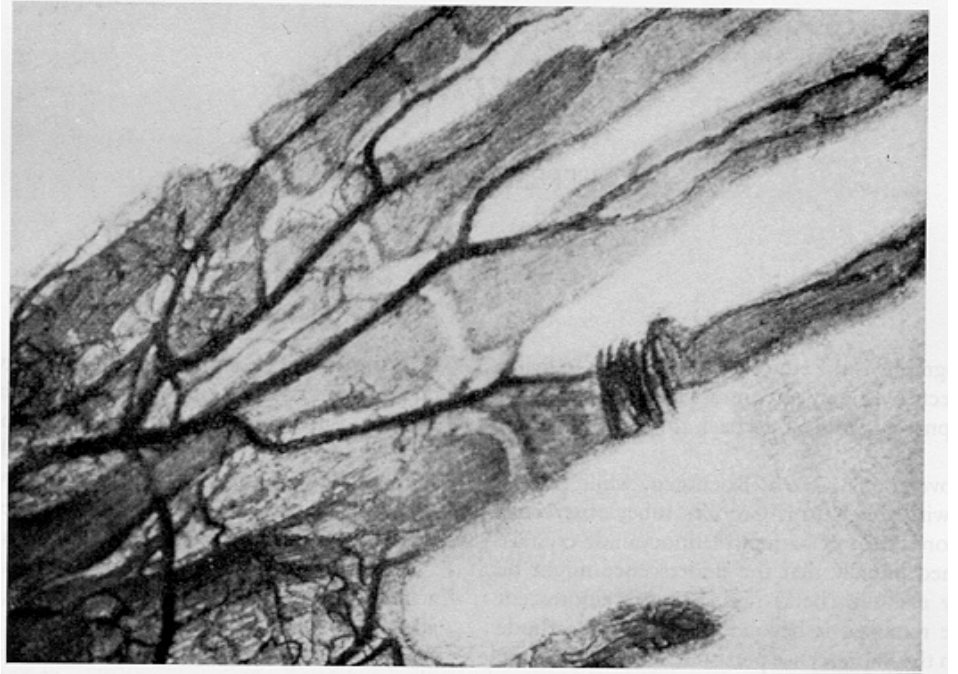
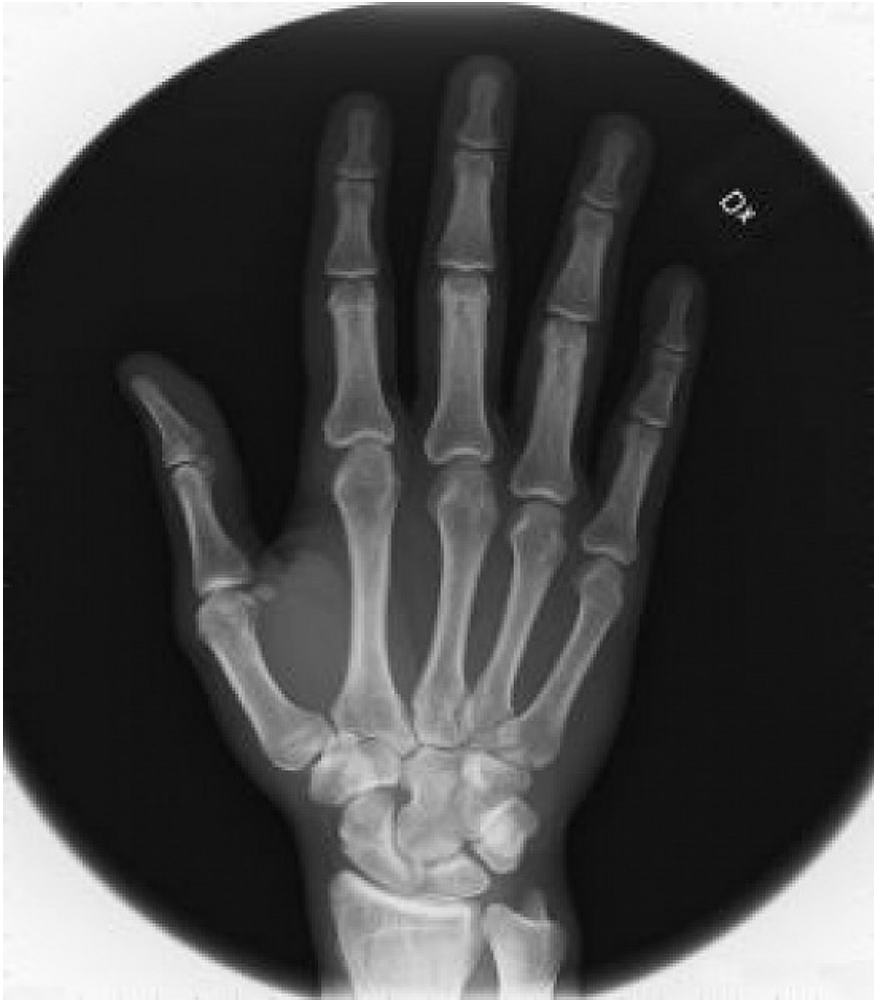# Histórico

- 1895 – Descoberta dos Raios X por Roentgen
- 1896 – primeira angiografia, em uma mão amputada
- 1923 – Venografia com lipiodol
- 1924 – Arteriografia de MI com iodeto de sódio
- 1928 – Angiografia cerebral (Egas Moniz)
- 1953 – Técnica de Seldinger
- 1964 – primeira angioplastia (nascimento da Radiologia Intervencionista)
- 1980 – Angiografia Digital



**Injeção de bismuto, prata e bário em uma mão amputada.  
Primeira radiografia de vasos.  
Haschek E. e Lidenthal O.T. - 1896**

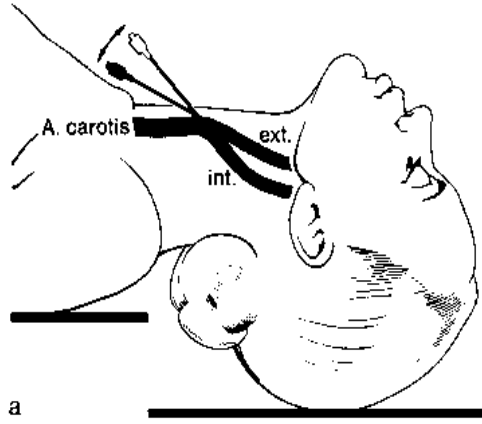




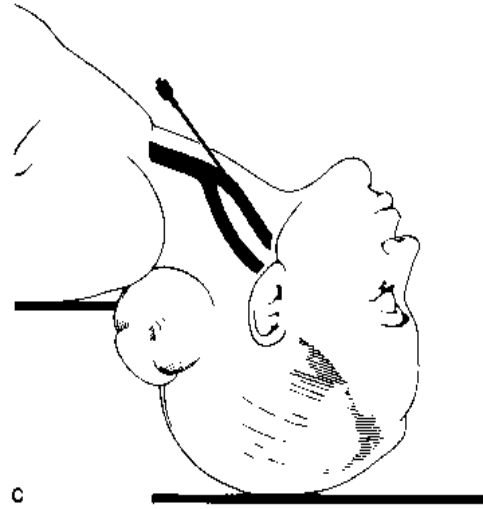
# Antônio Egas Muniz

**1927: Angiografia cerebral**

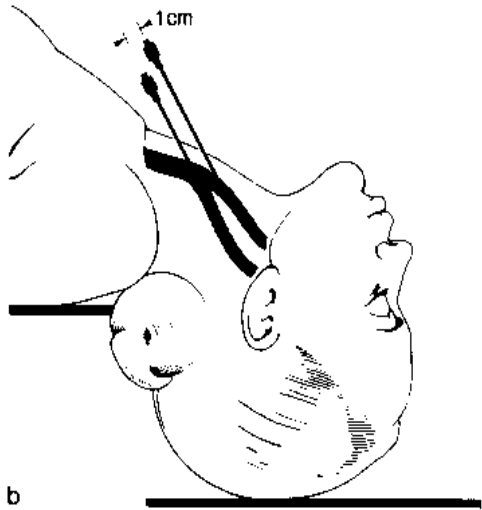




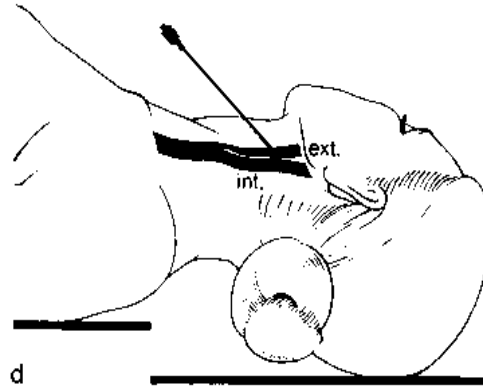
a



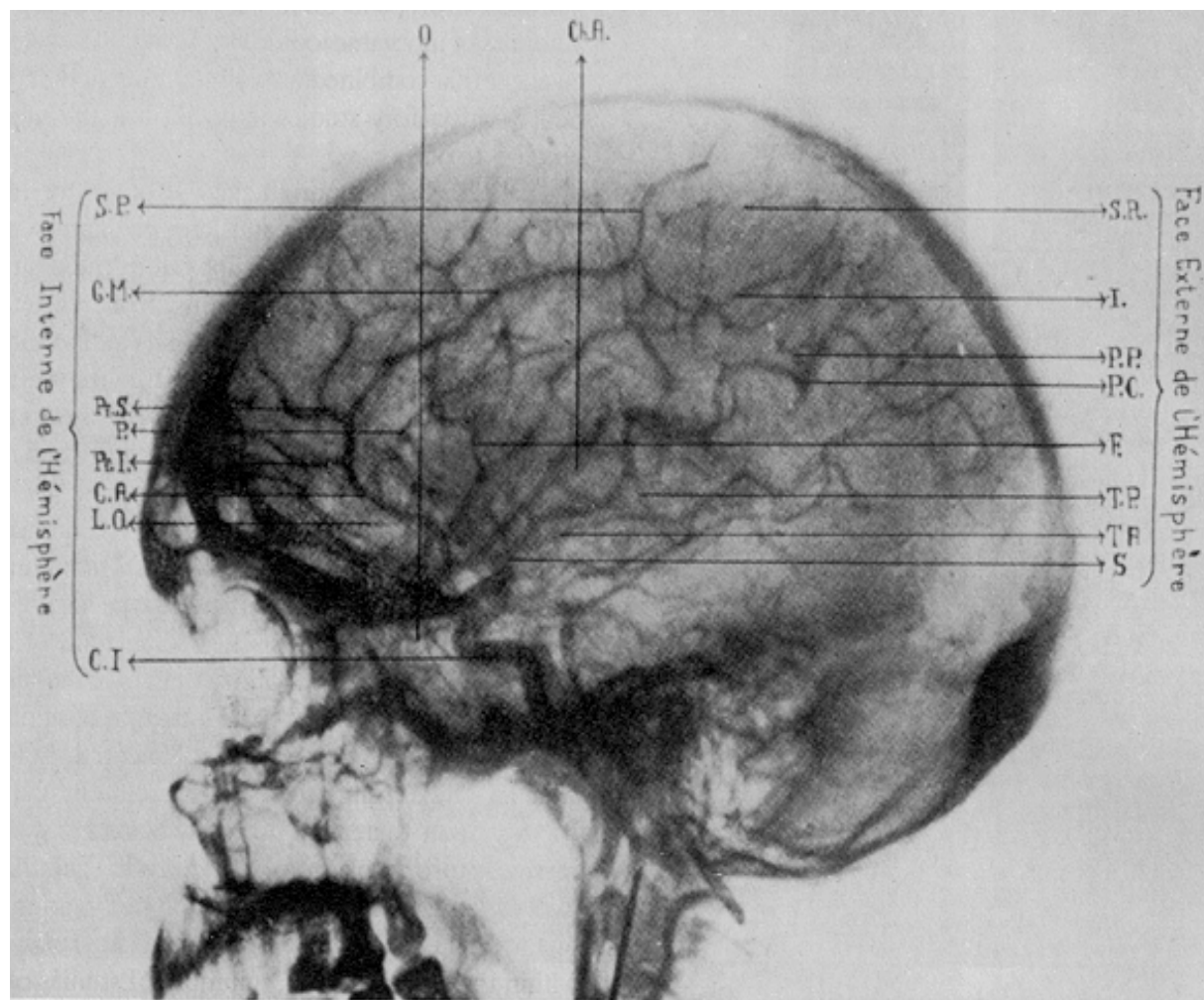
c



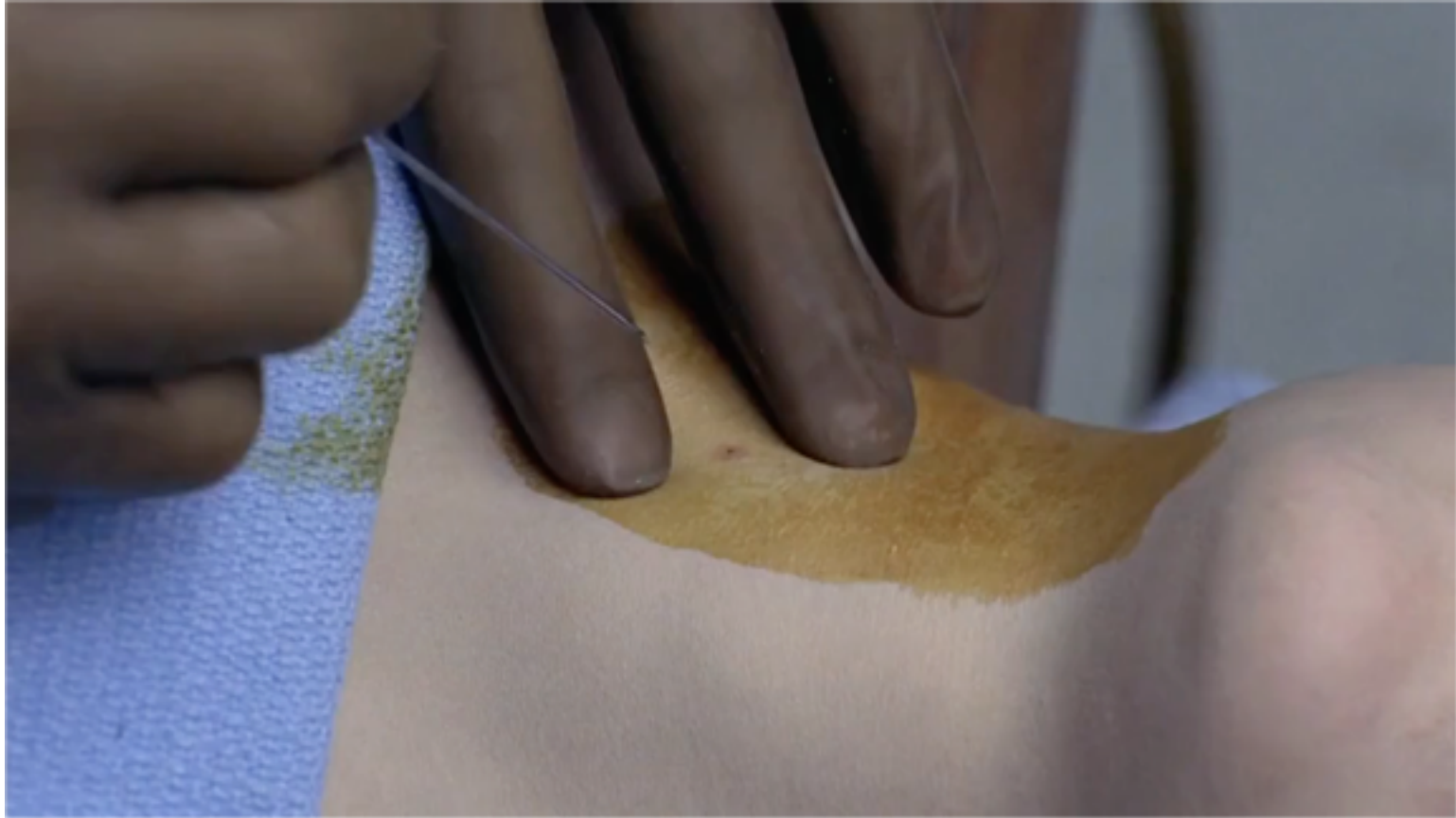b



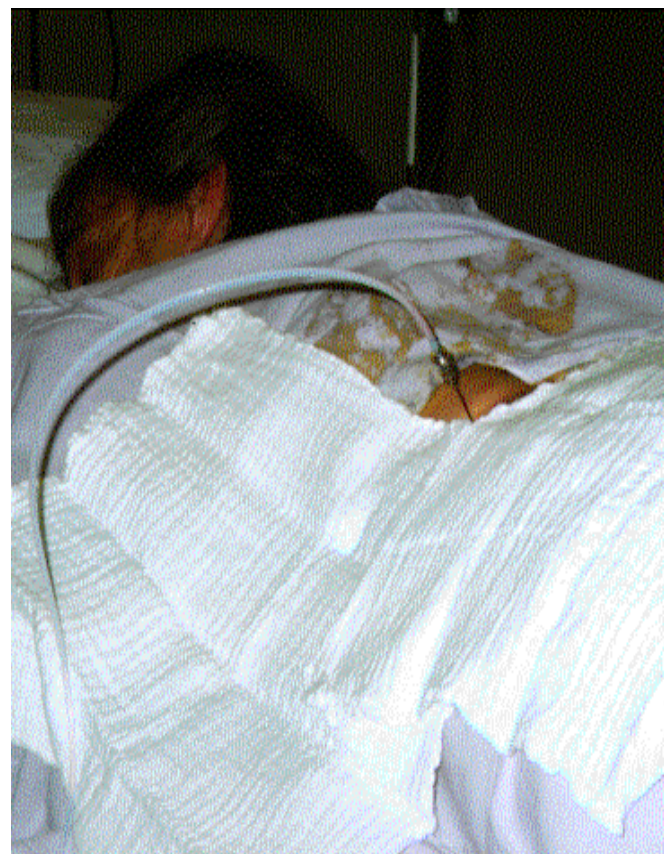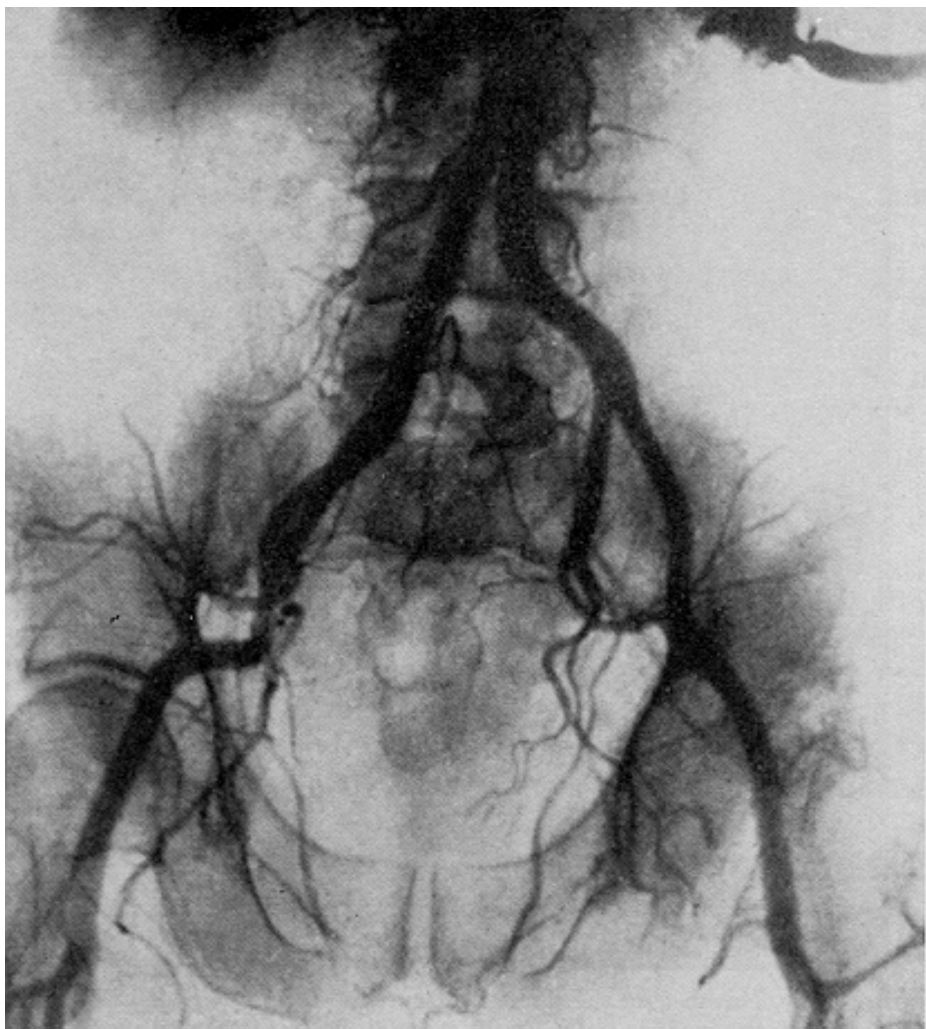
d



**Primeira arteriografia cerebral**  
**Egas Moniz, 1927**







**Primeira aortografia translombar**  
**Dos Santos, Lamas e Pereira-Caldas - 1929**

# Sven-Ivar Seldinger

1953

Radiologista

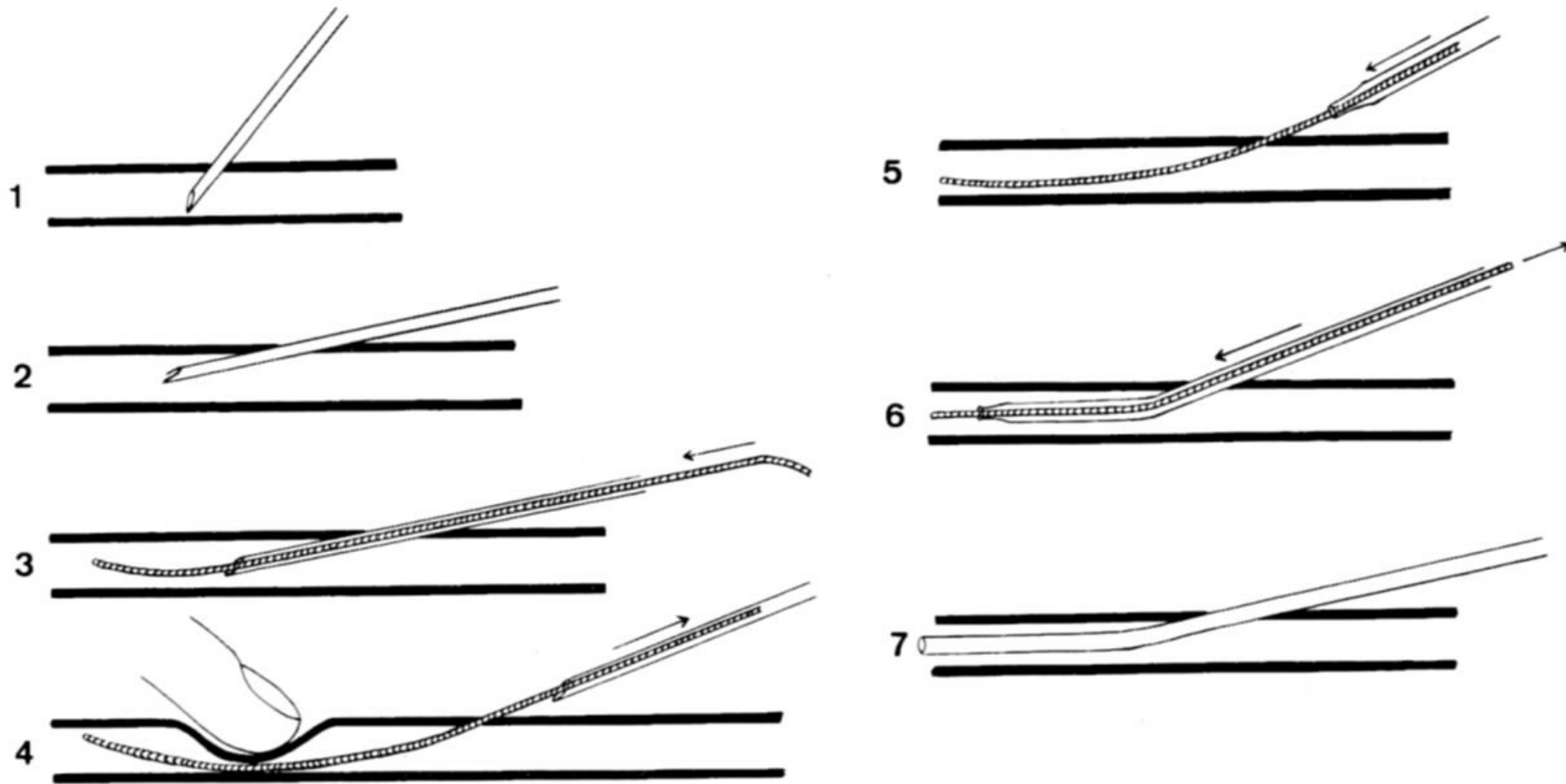
\* 1921

† 1998

Via percutânea  
Cateterismo



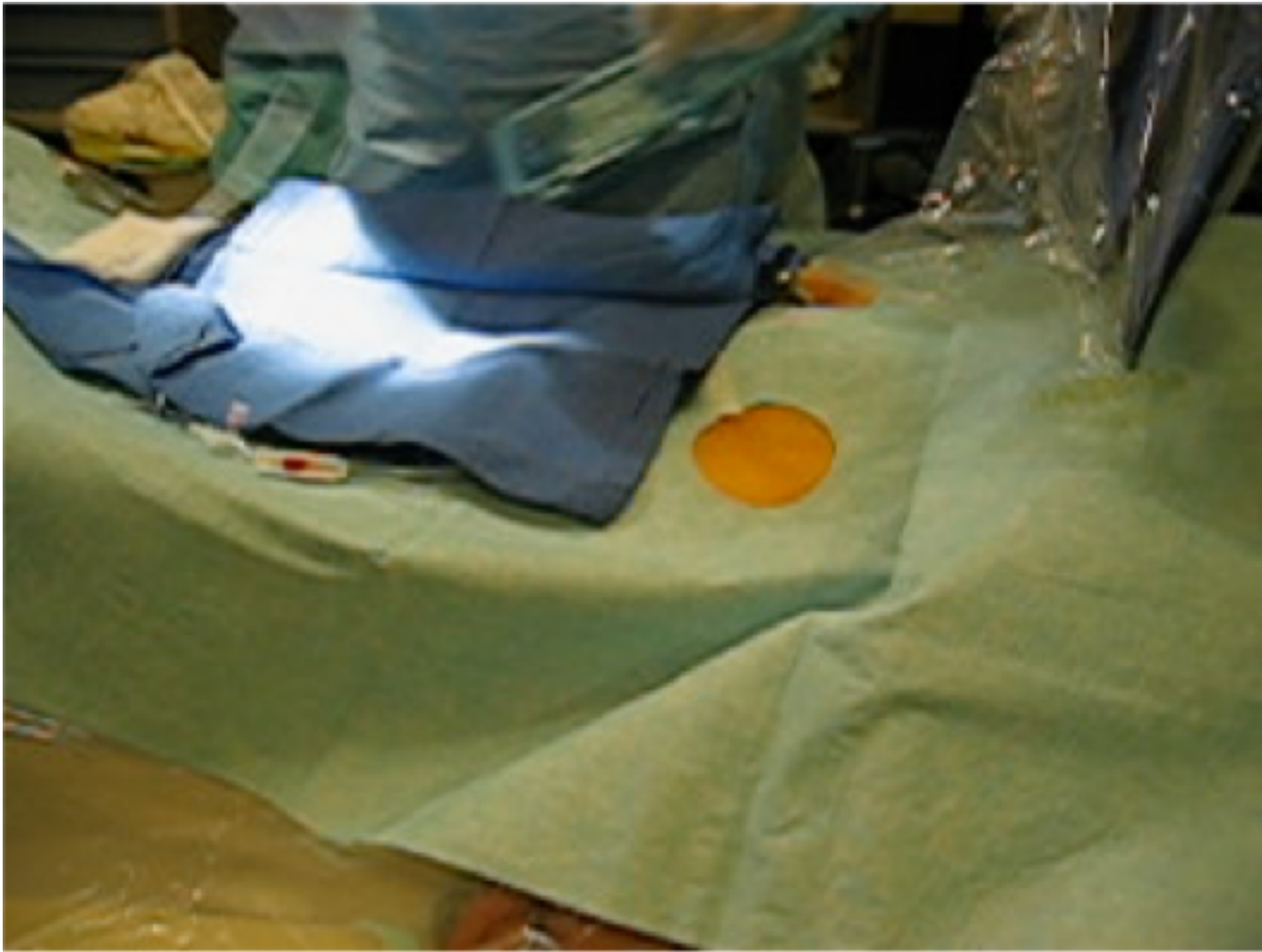
# Técnica de Seldinger



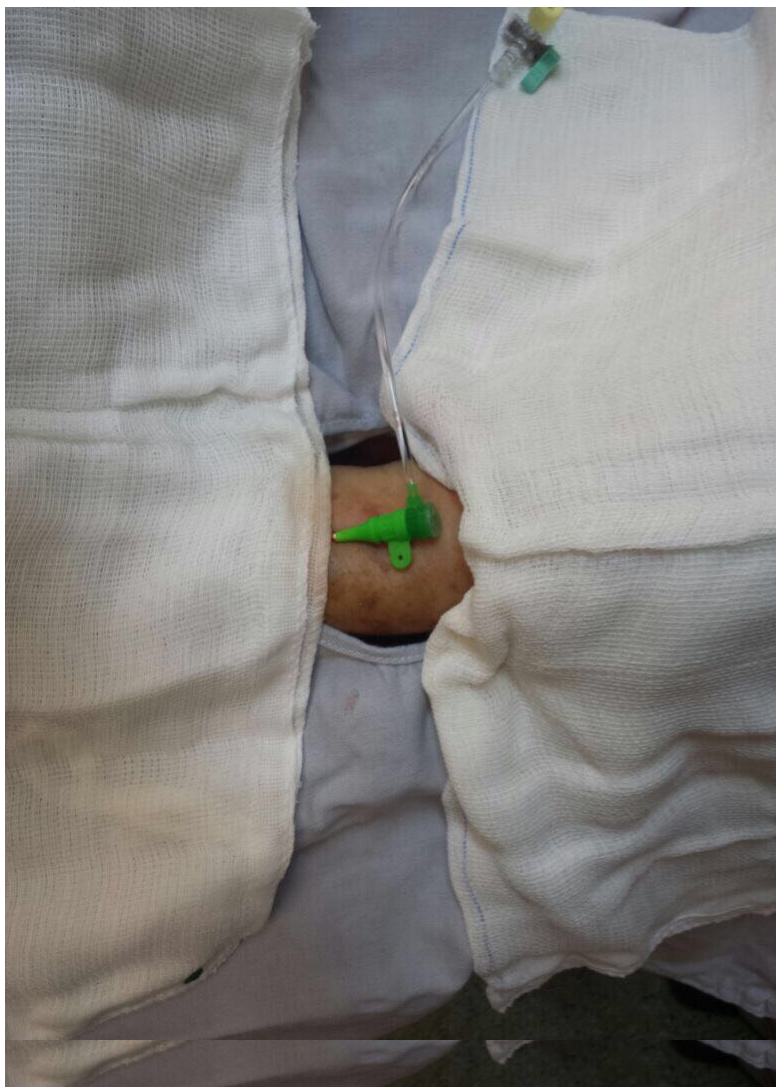

# Acessos Arteriais

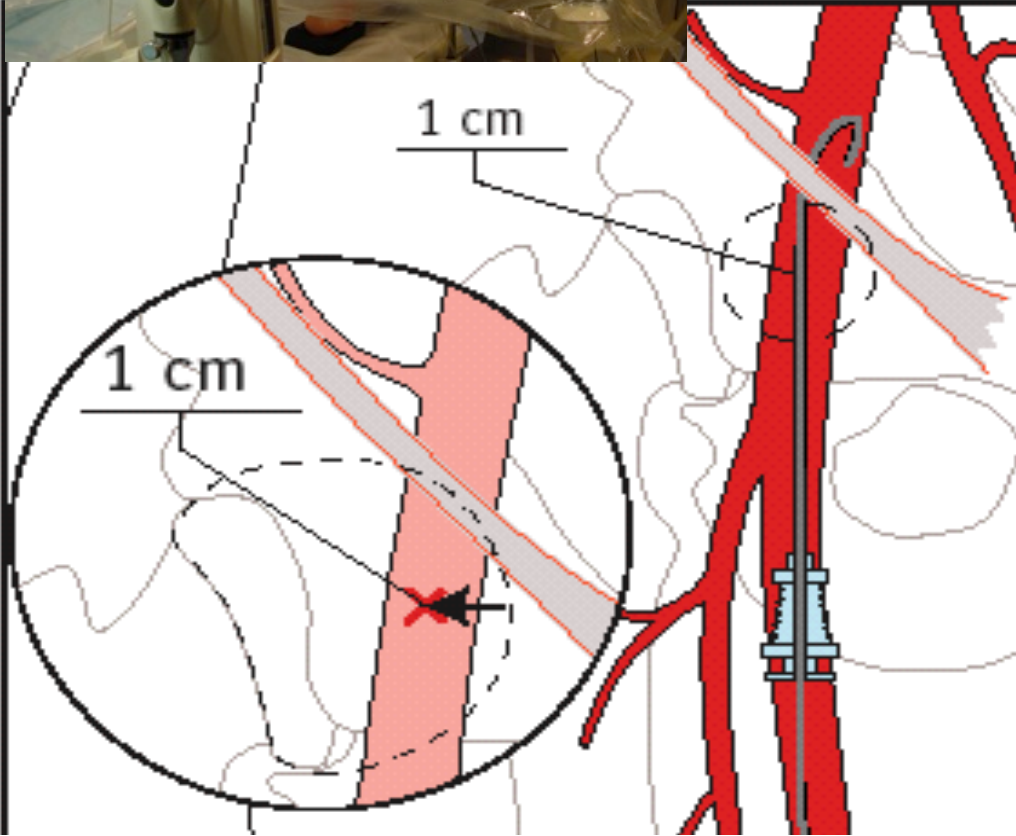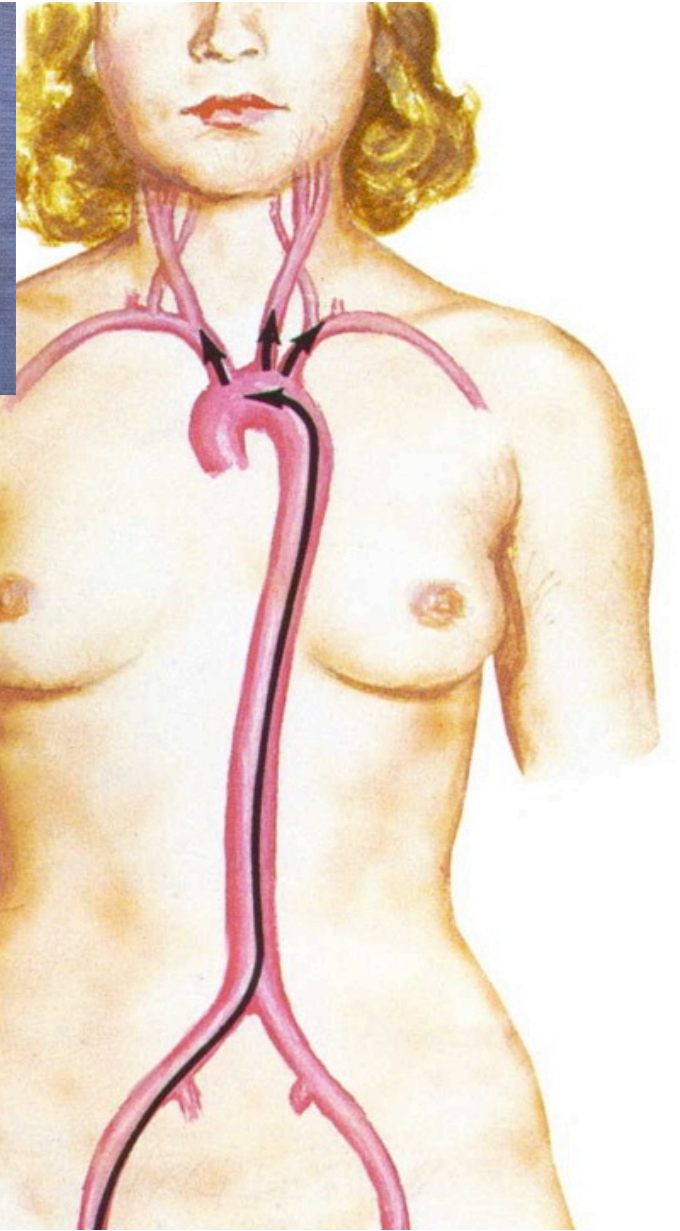
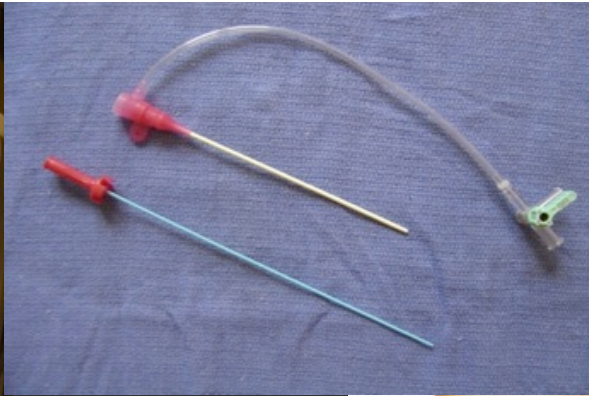
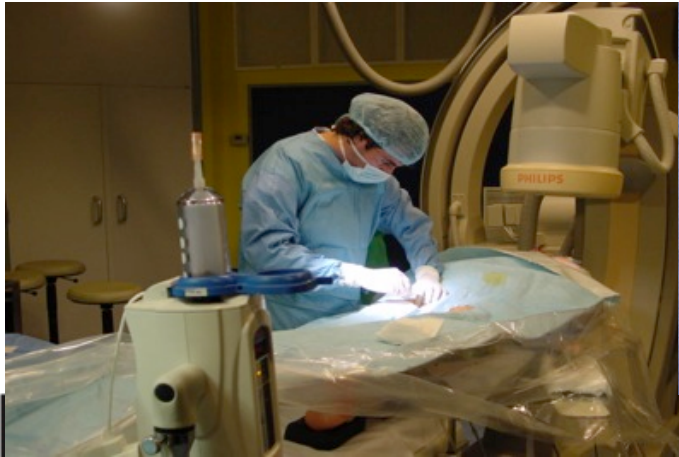- Artéria Femoral Comum
- Artéria Braquial
- Artéria Radial
- Artéria Axilar
- Aorta – Punção translombar

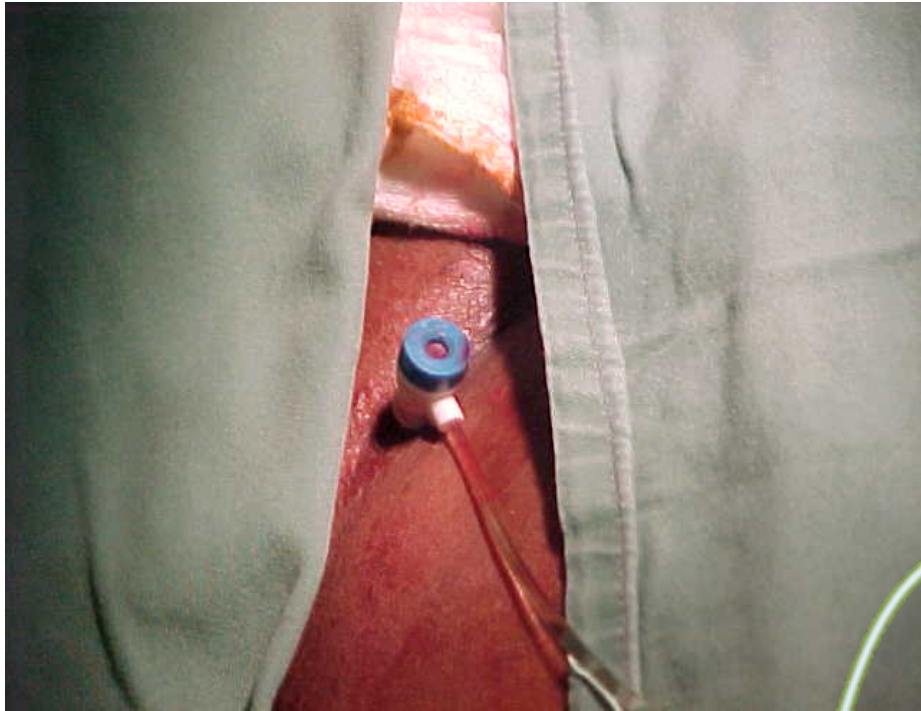


# Acesso Radial






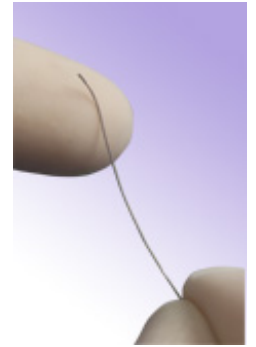




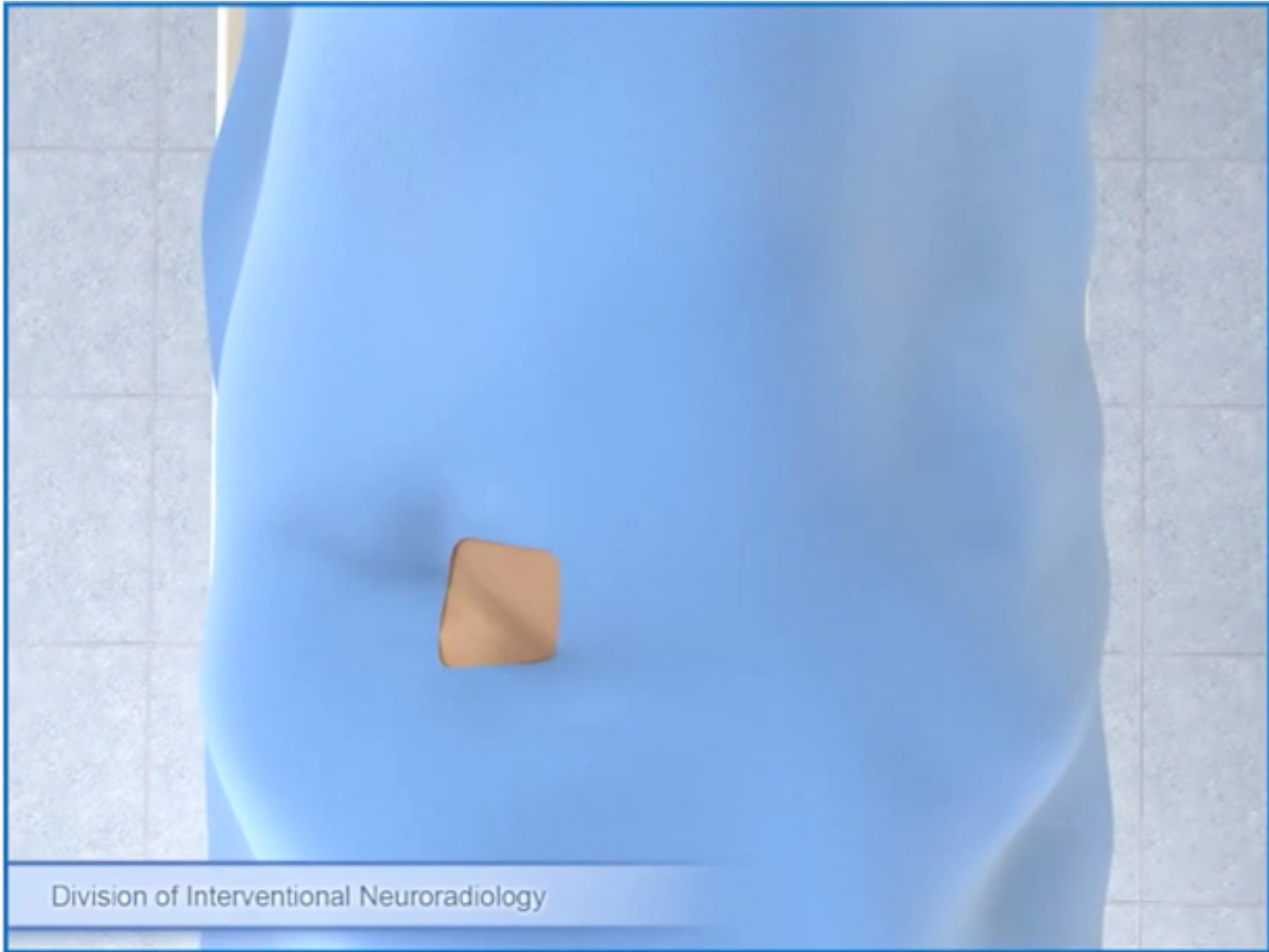
**1 mm = 3 Frechs**



# Técnica Angiográfica



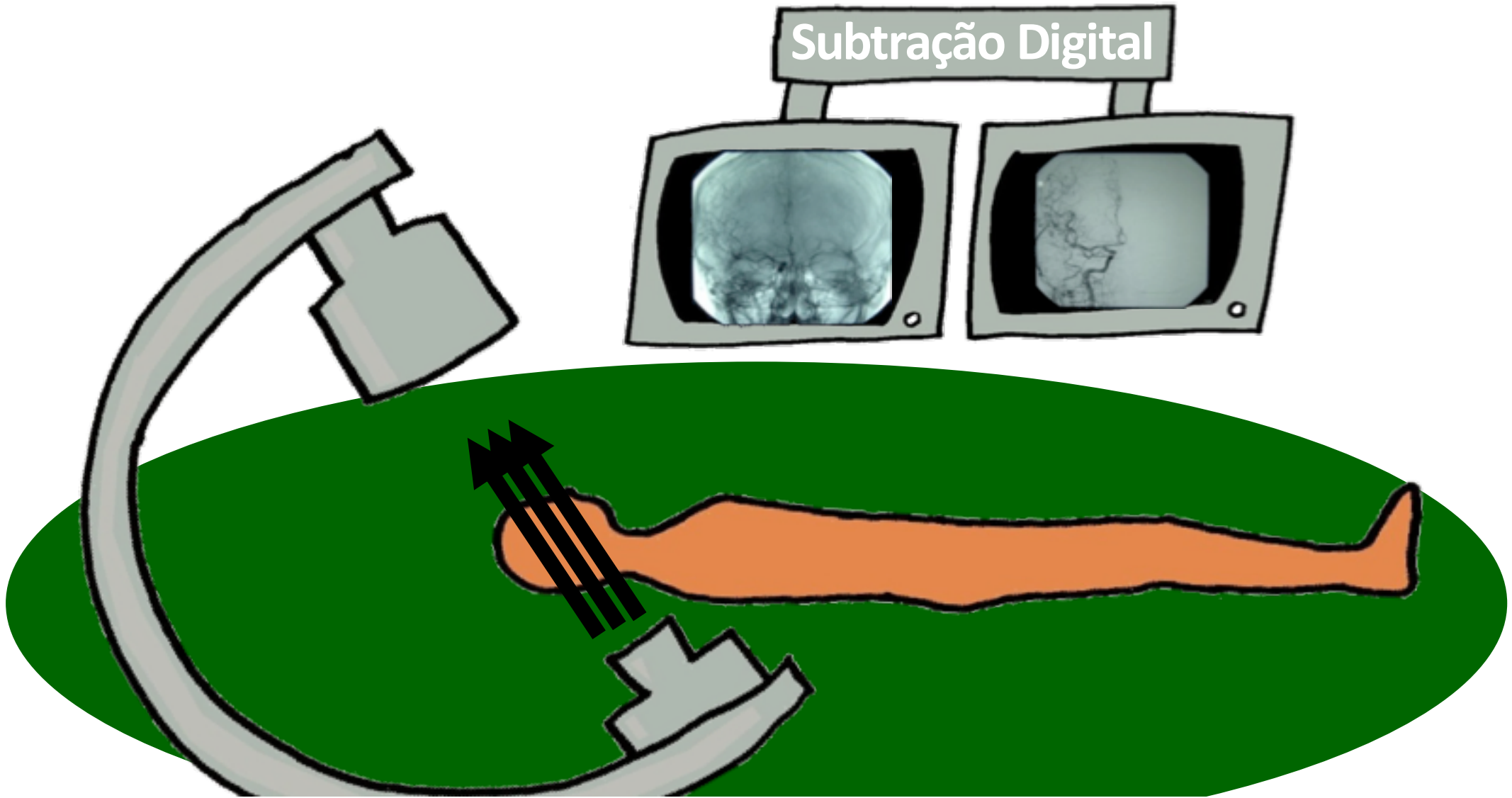
- Angiografia panorâmica, angiografia seletiva e angiografia super-seletiva
- Uso de fármacos antiespasmódicos em angiografias abdominais
- Drogas vasodilatadoras para documentar leito distal
- Contrastes não-iodados em pacientes alérgicos ( Gadolínio e CO<sub>2</sub> )



Division of Interventional Neuroradiology

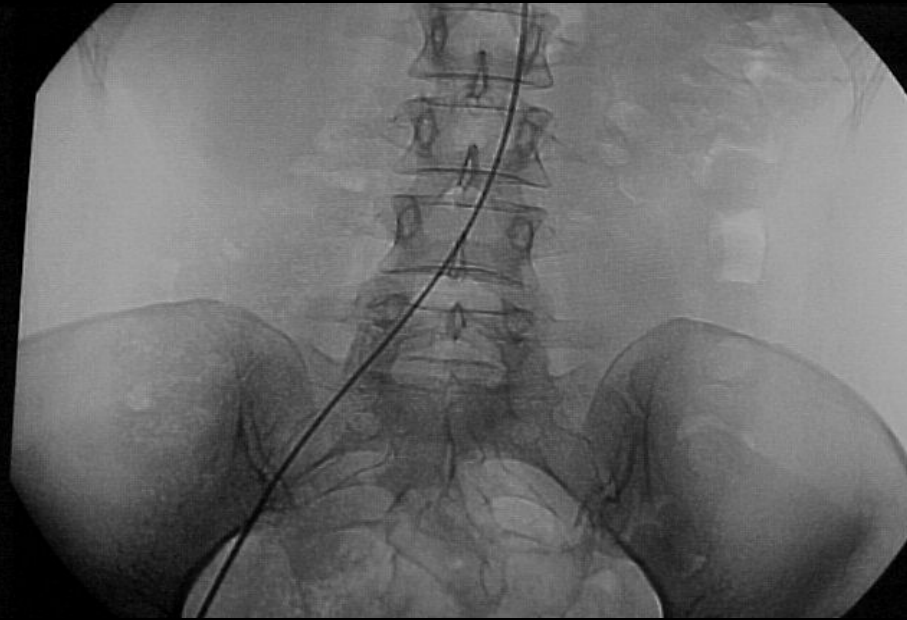


# Subtração Digital






SEM SUBTRAÇÃO



Os




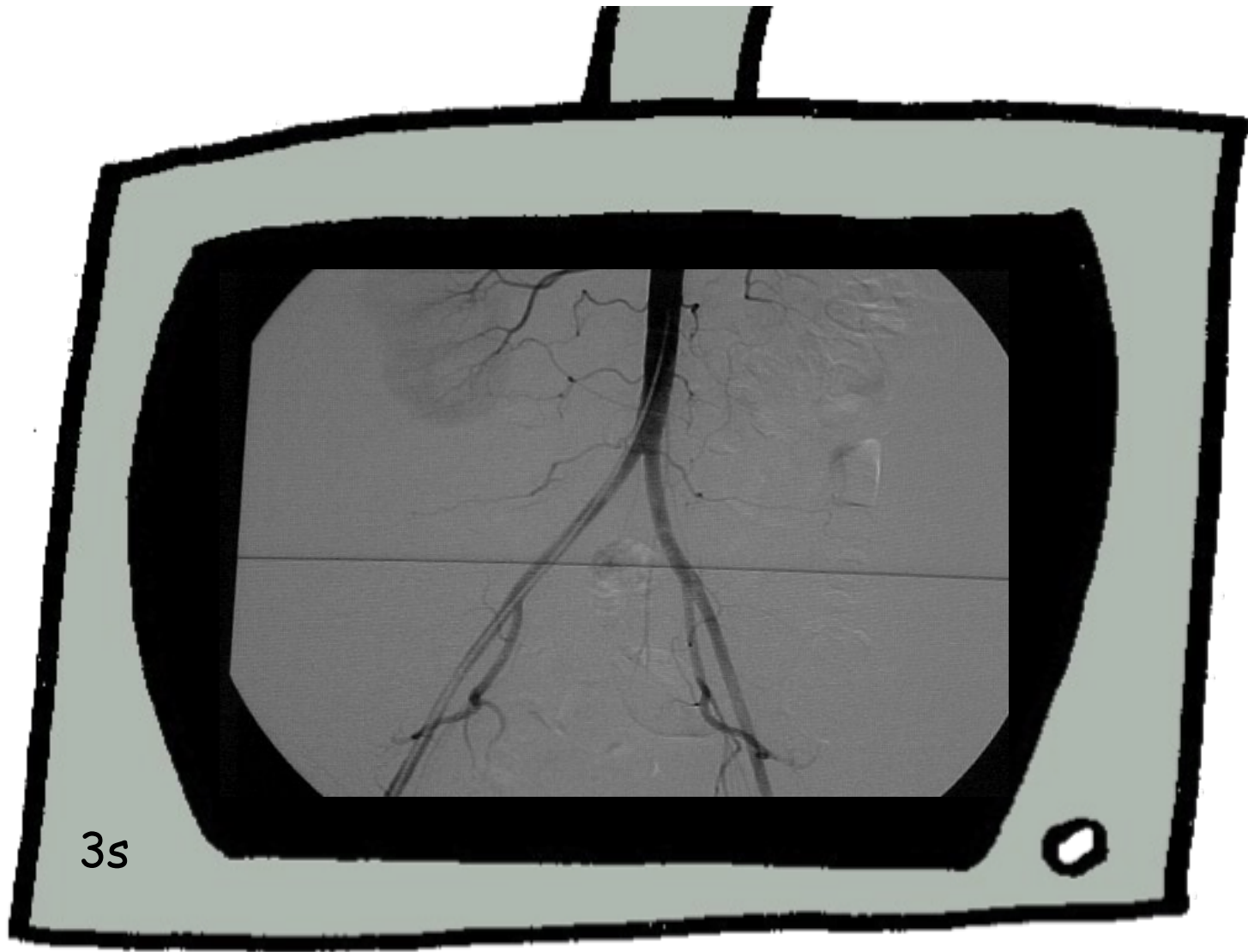
MÁSCARA

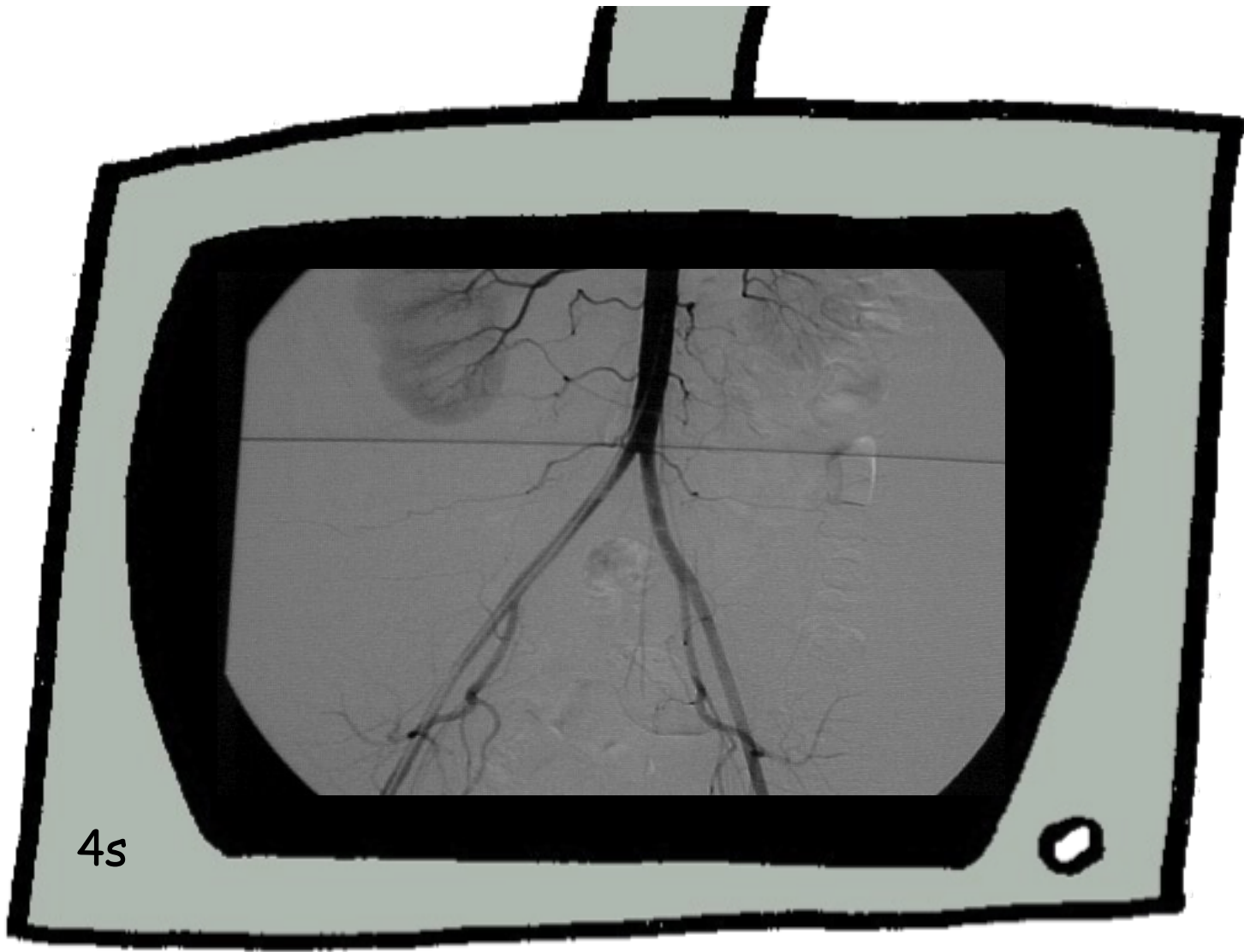
1s

COM SUBTRAÇÃO

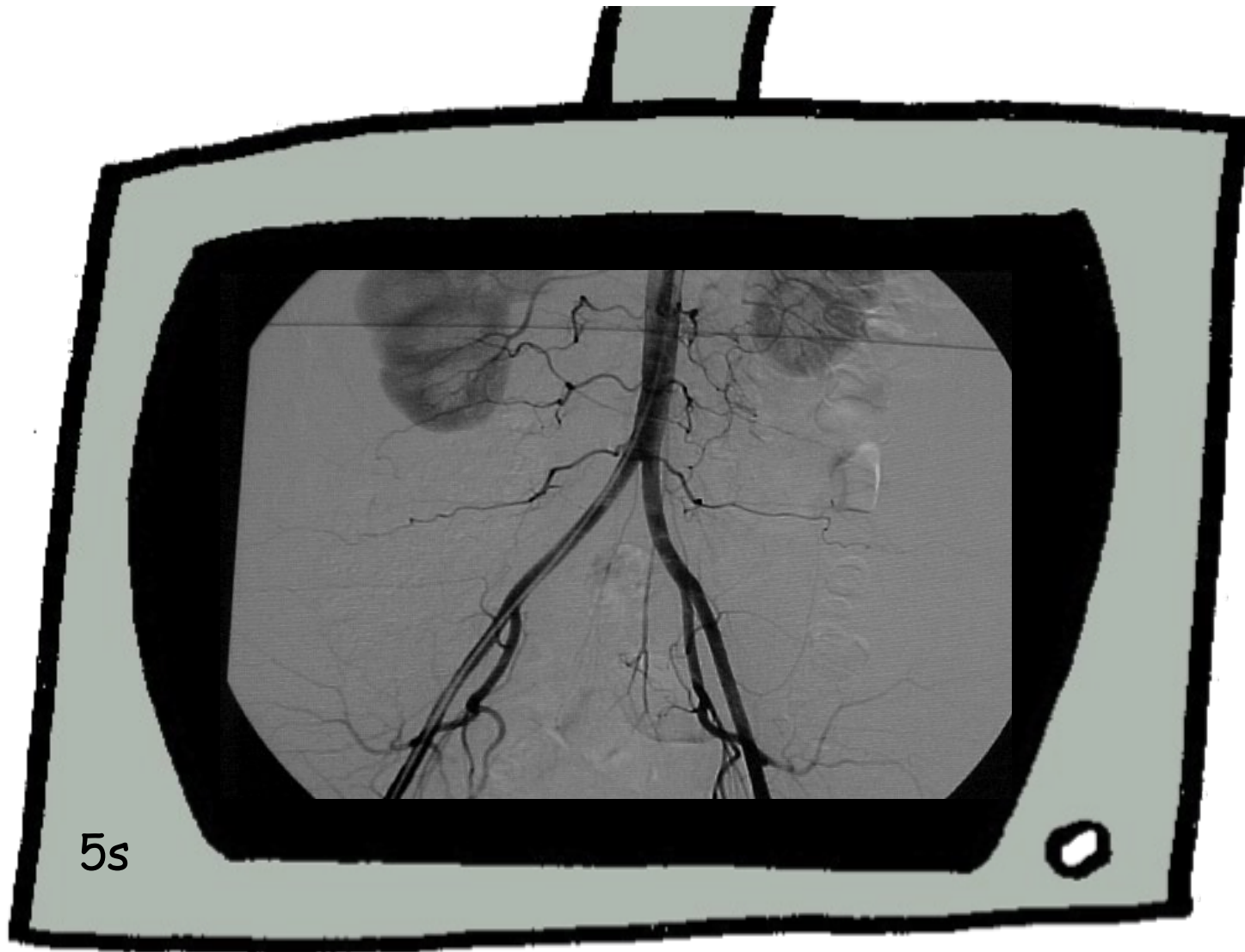
2s

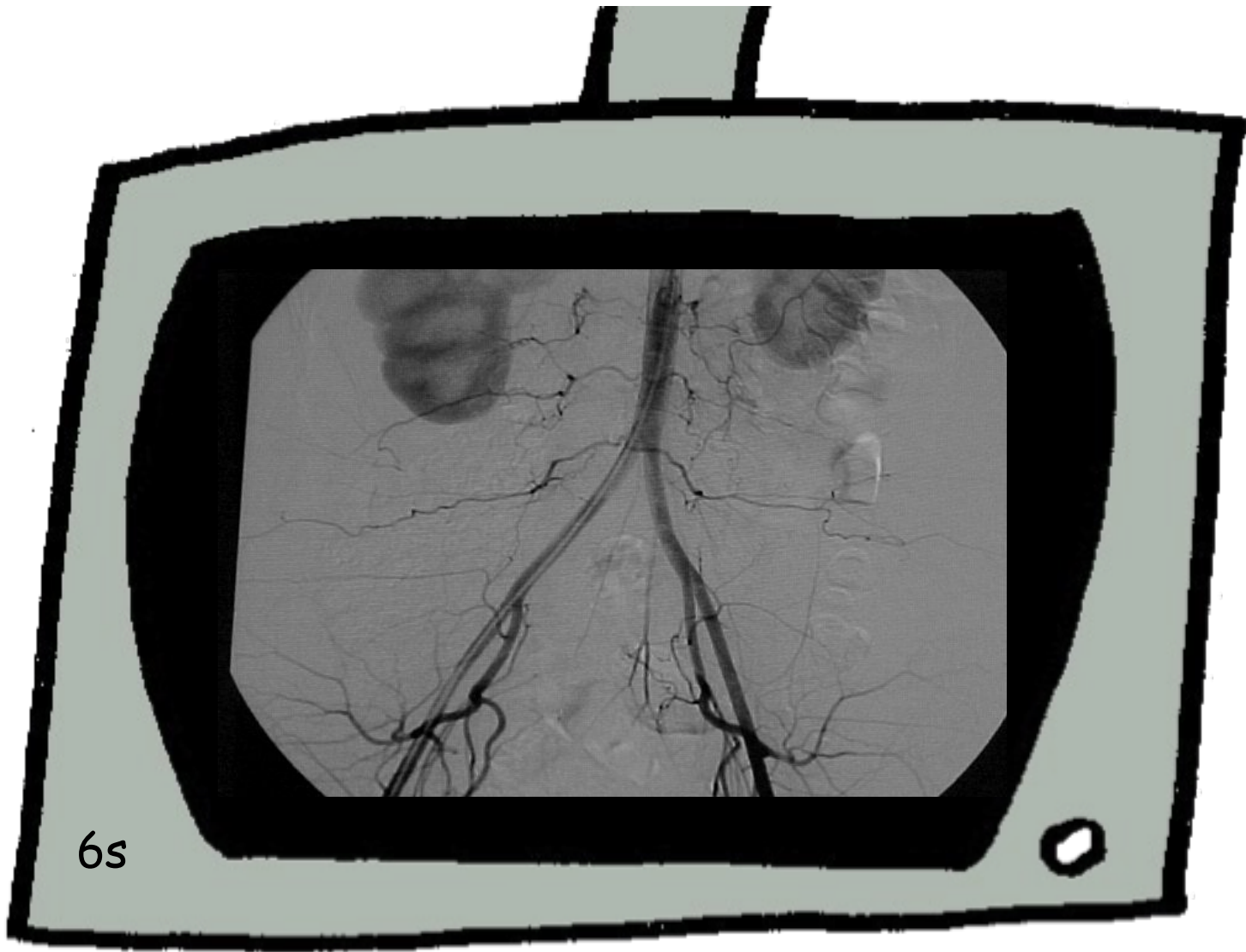




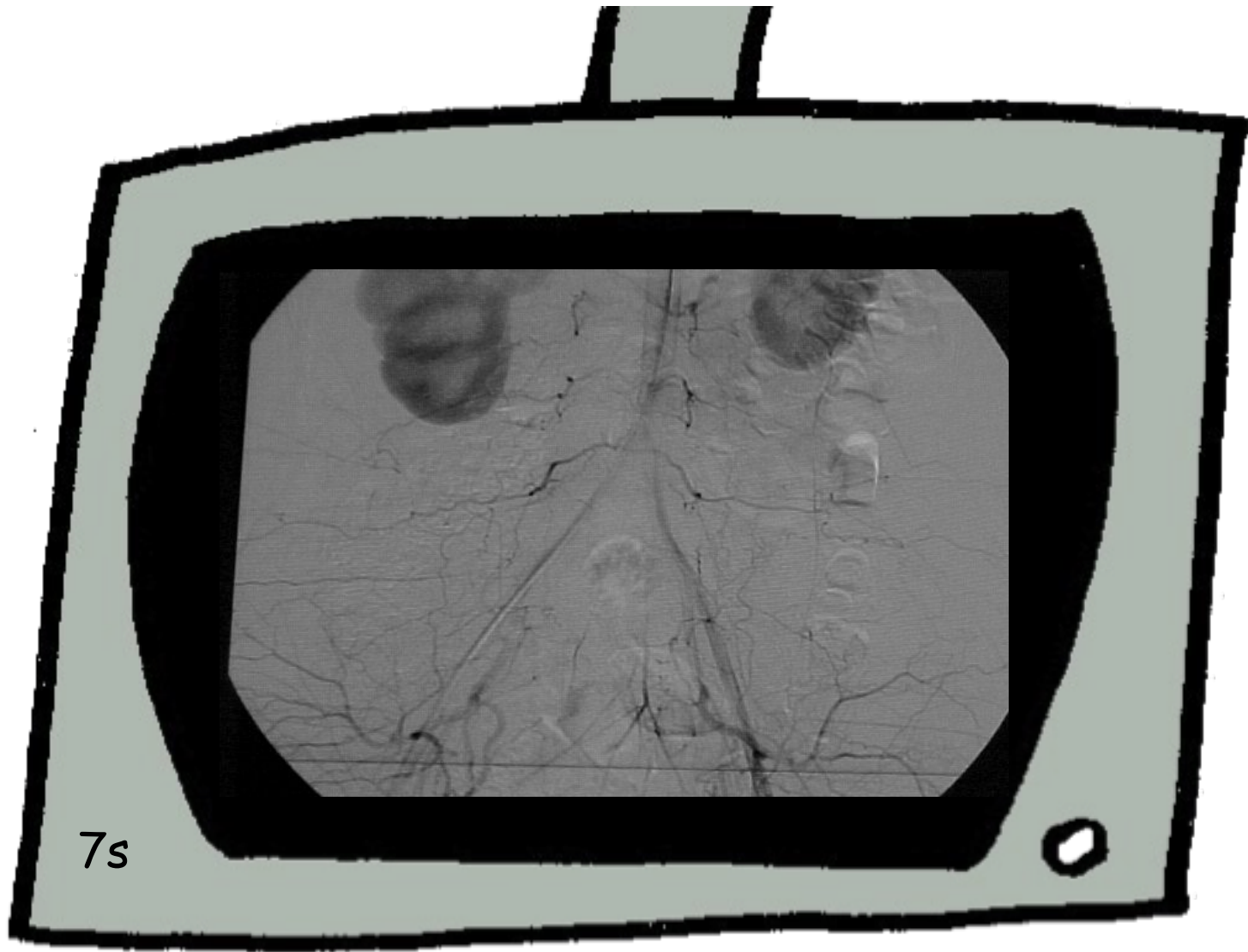


4s



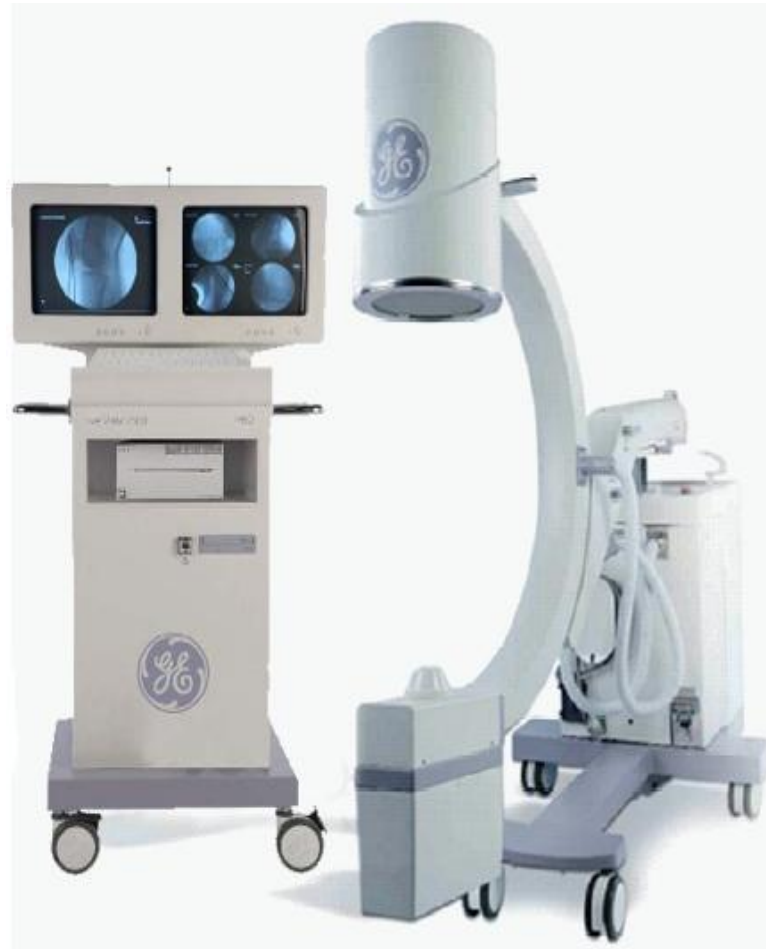



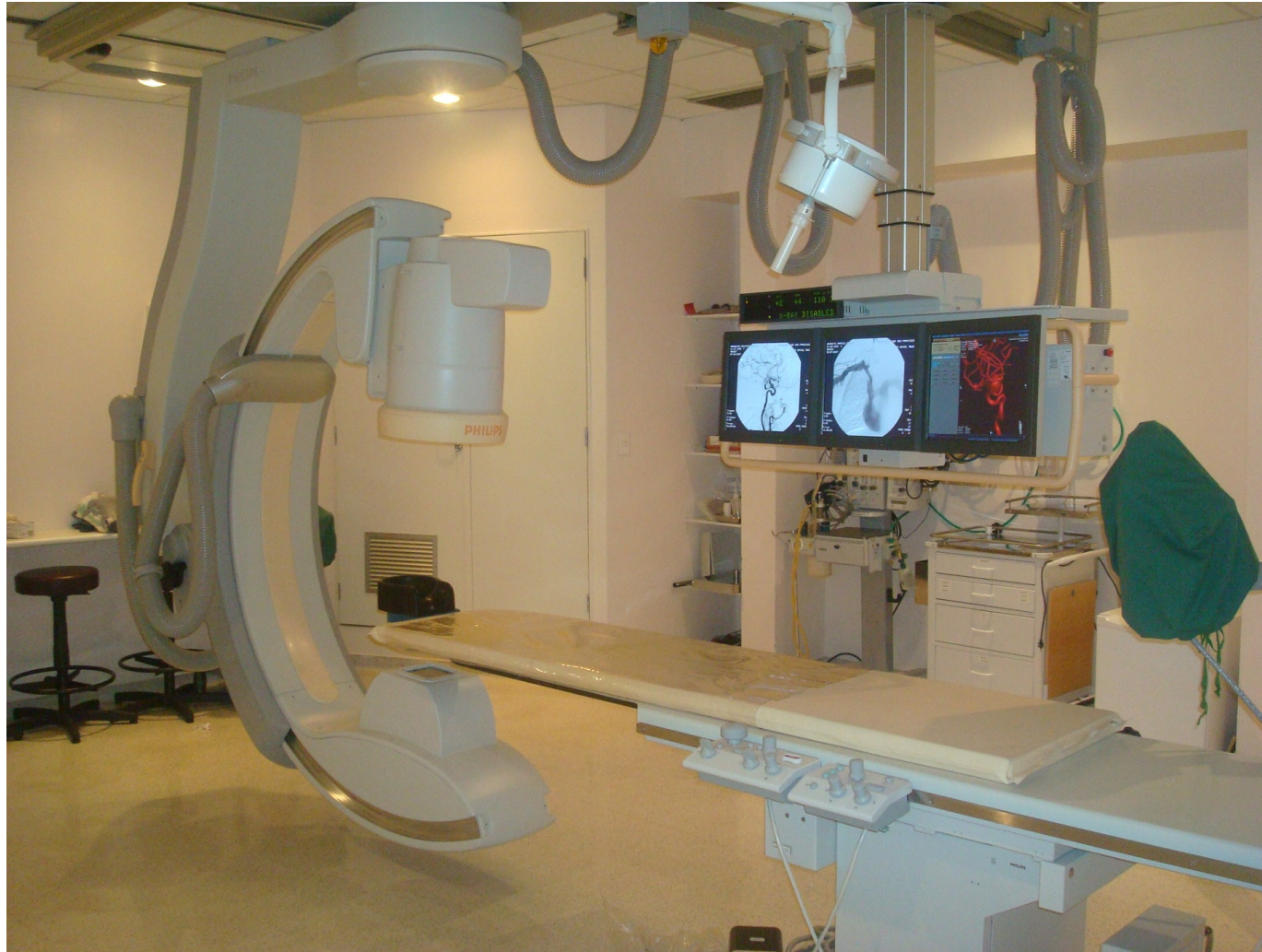



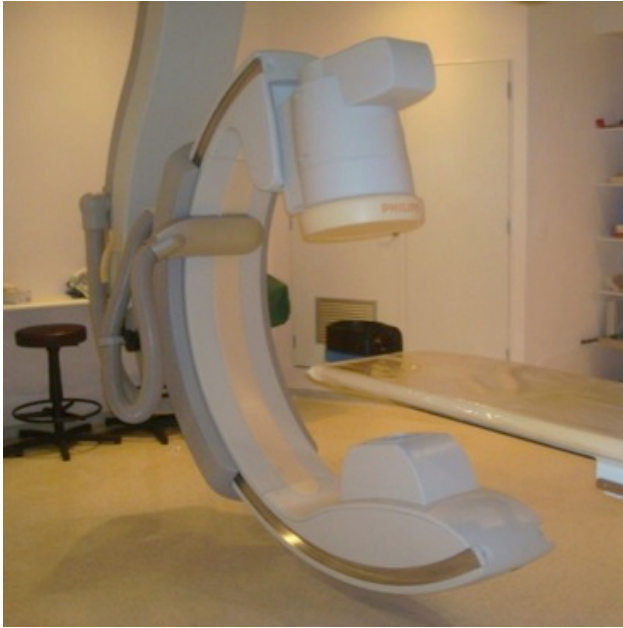
# Arco cirúrgico



# Sala de angiografía - analógico

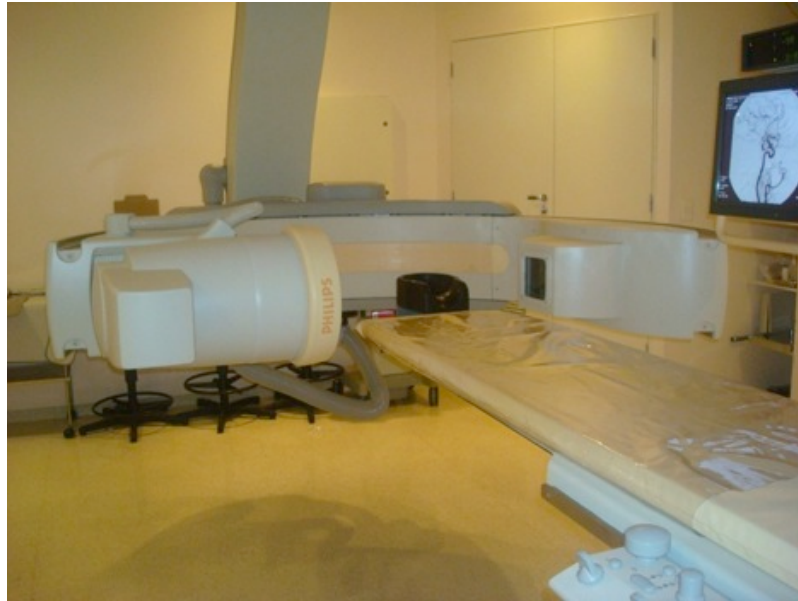



AP



OBLÍQUA

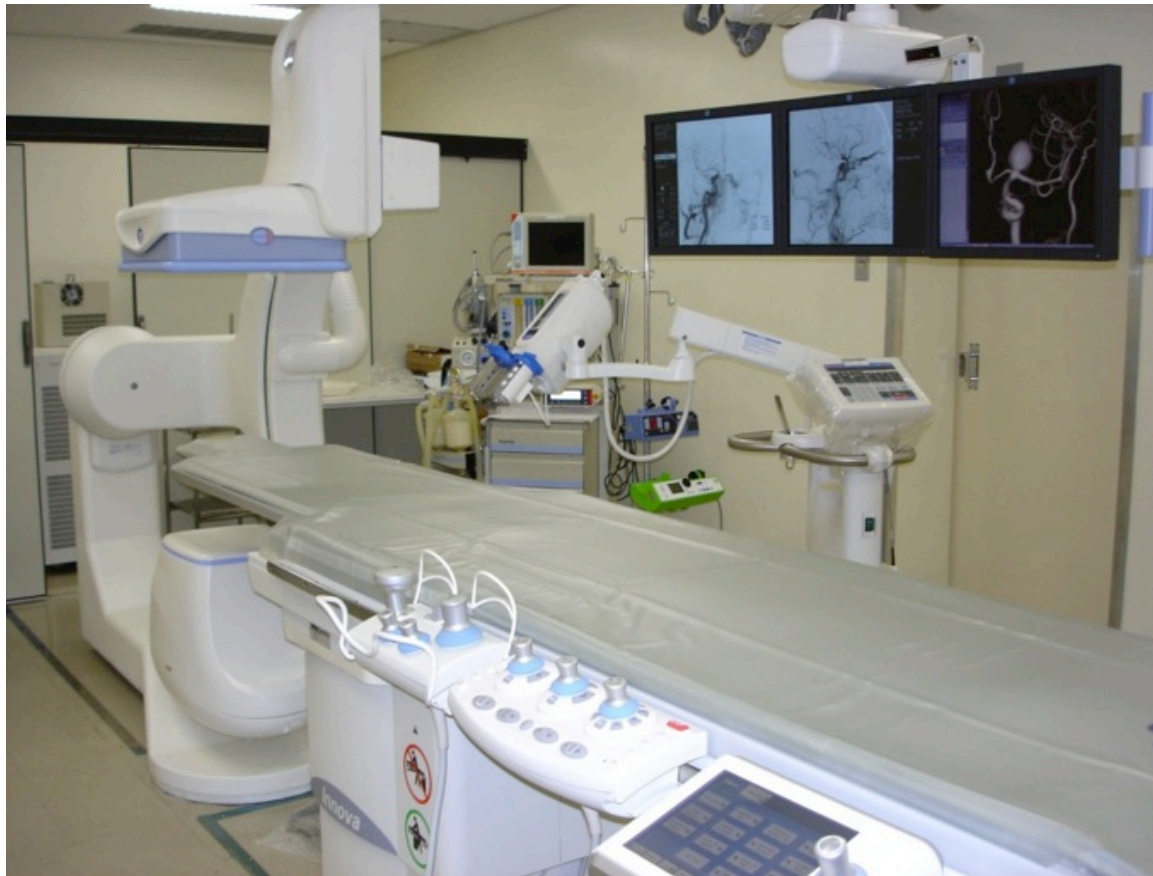

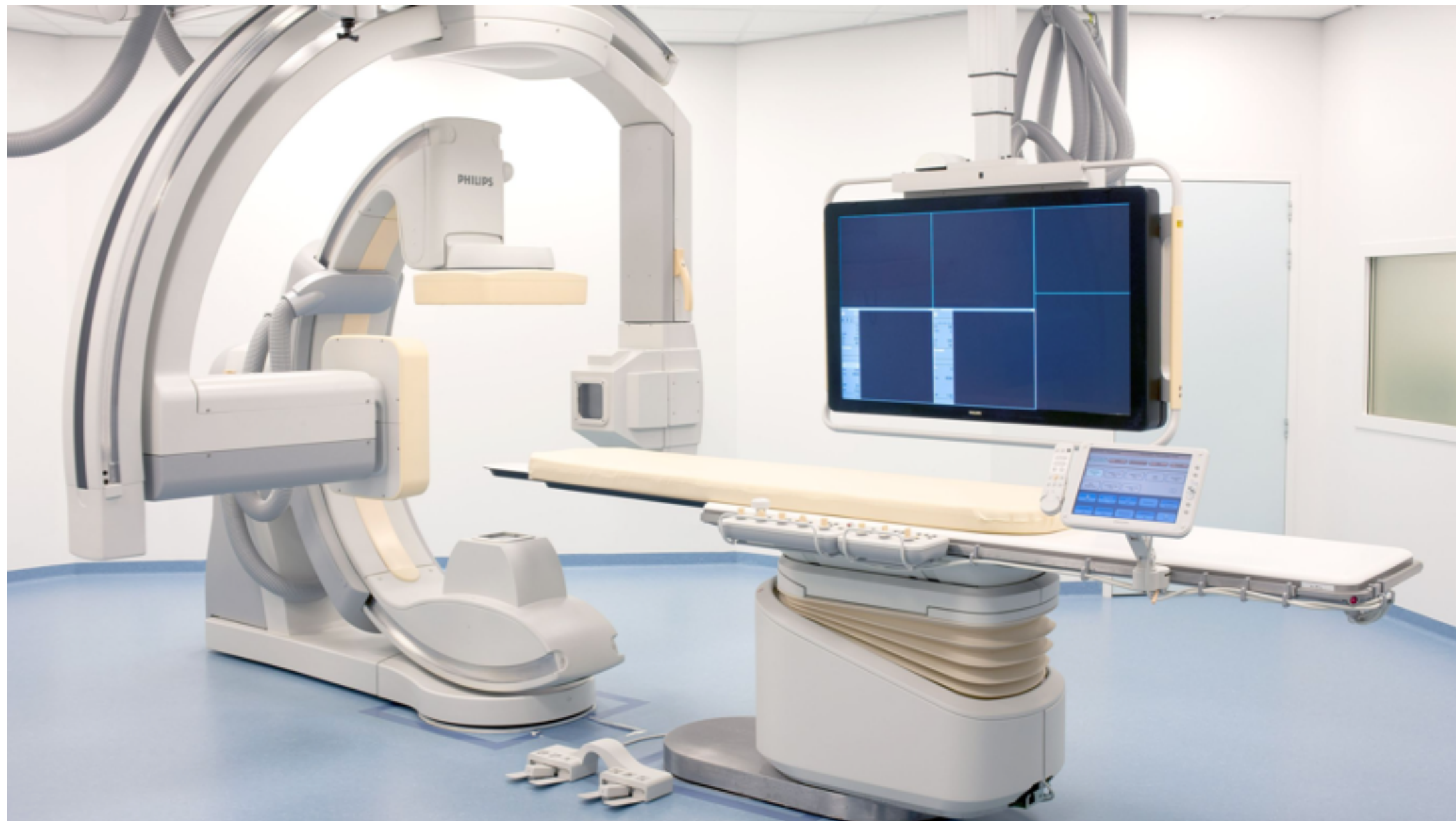PERFIL




HC-FMRP-USP Unidade Campus

Sala de angiografia  
Flat Detector



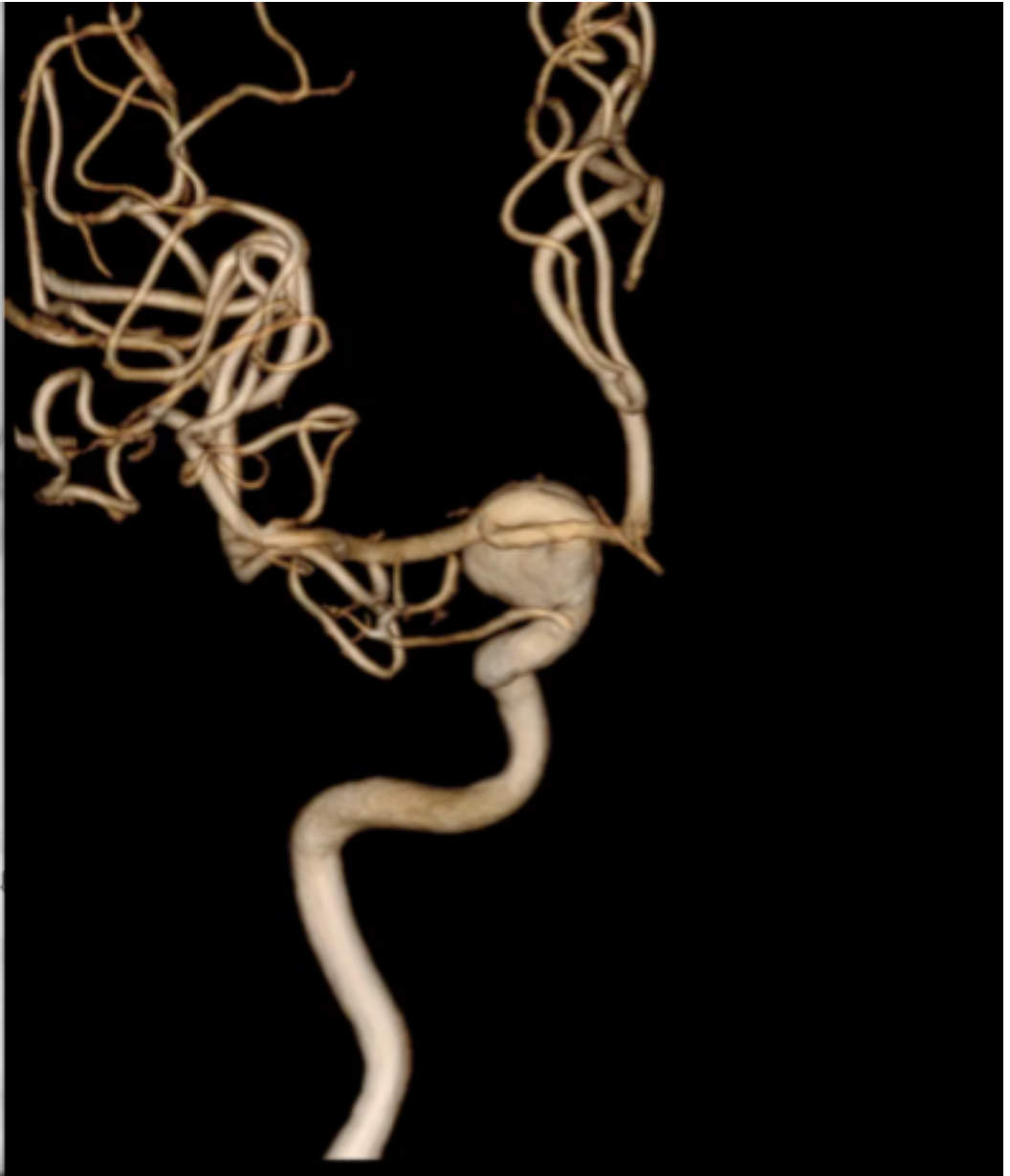
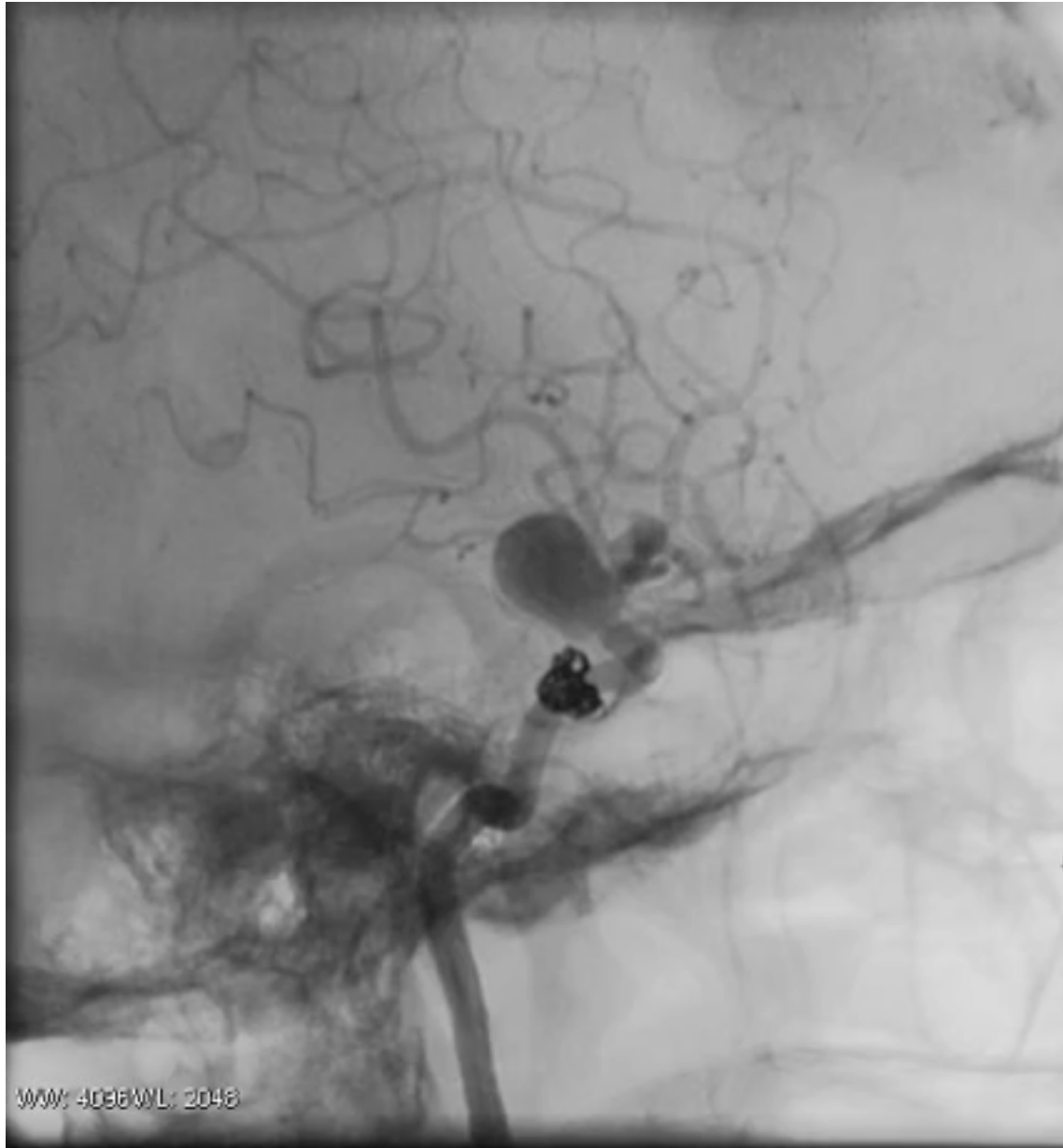
# Detector convencional x eletrônico digital



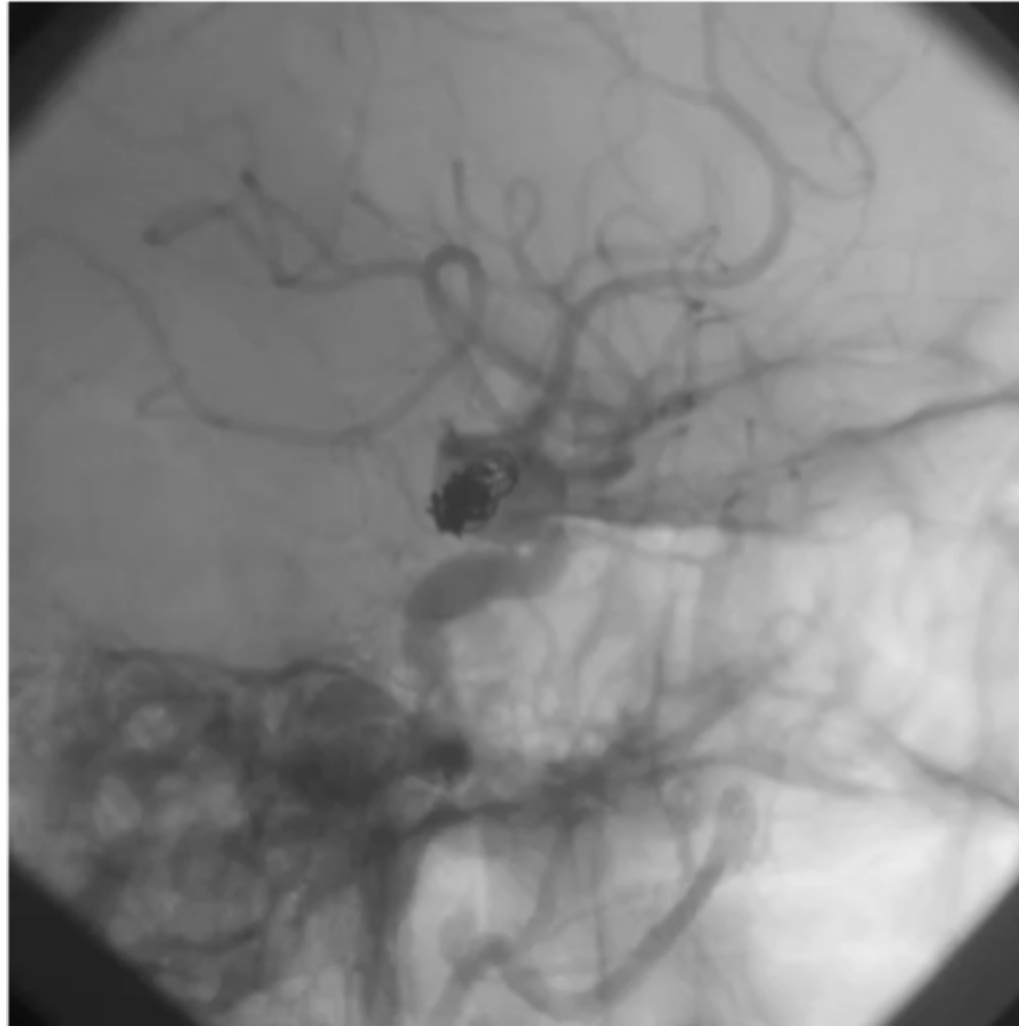
## Angiografia rotacional com reconstrução 3D

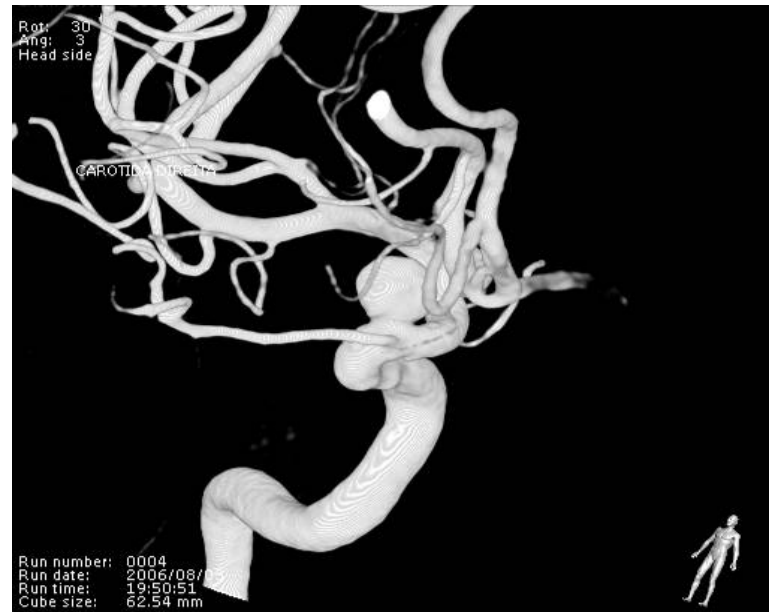
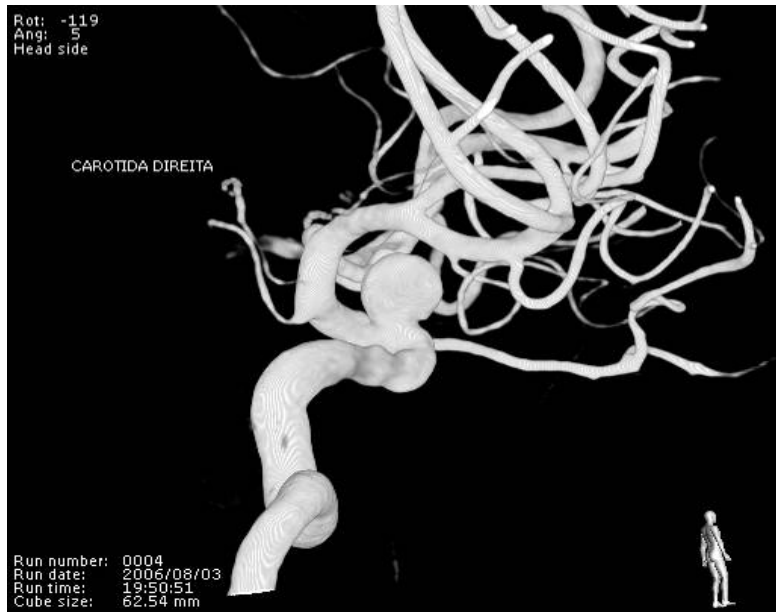
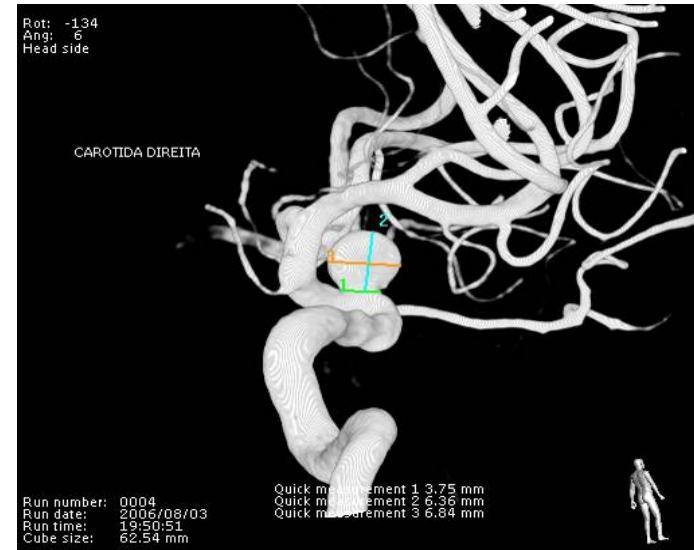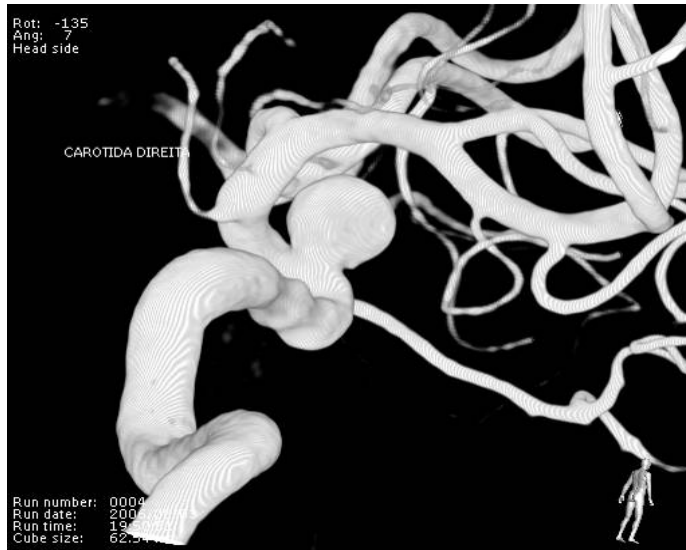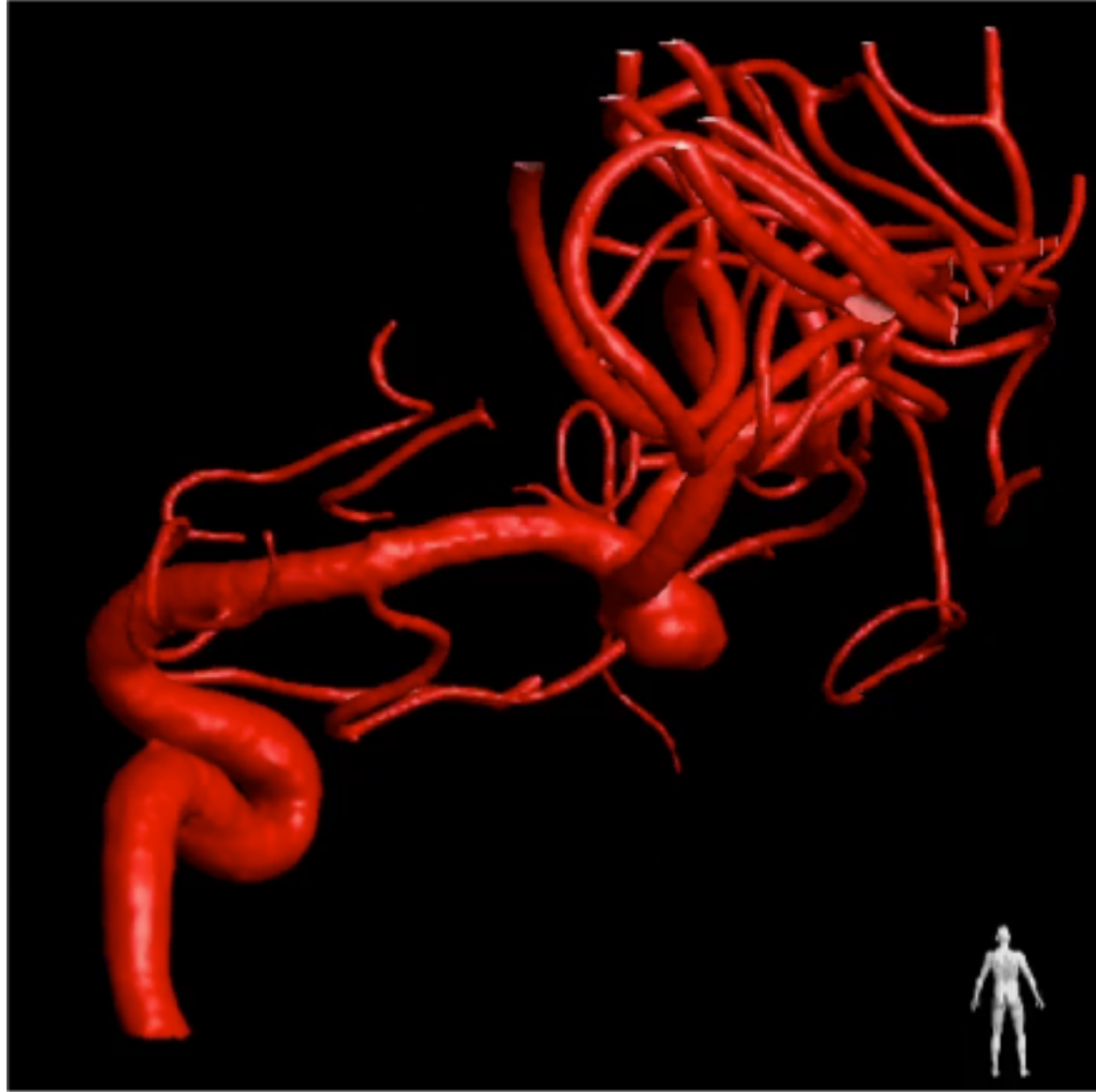


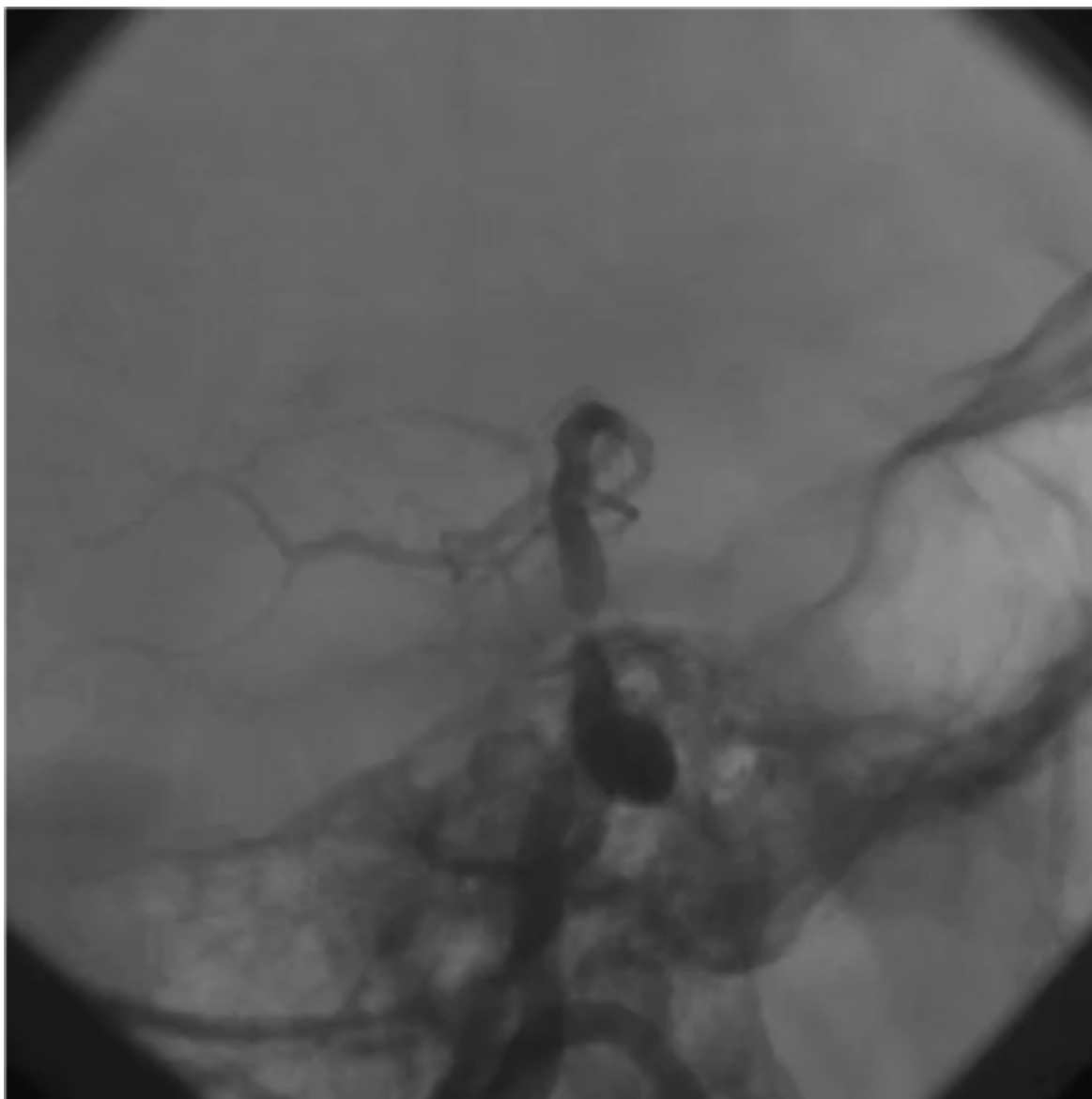


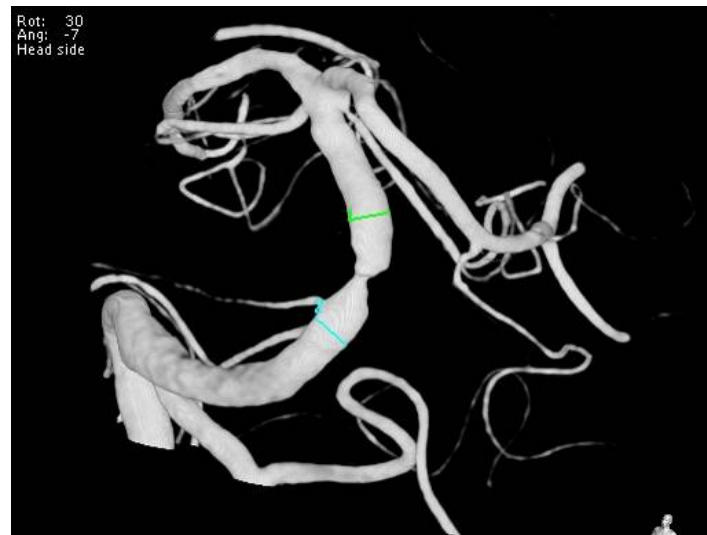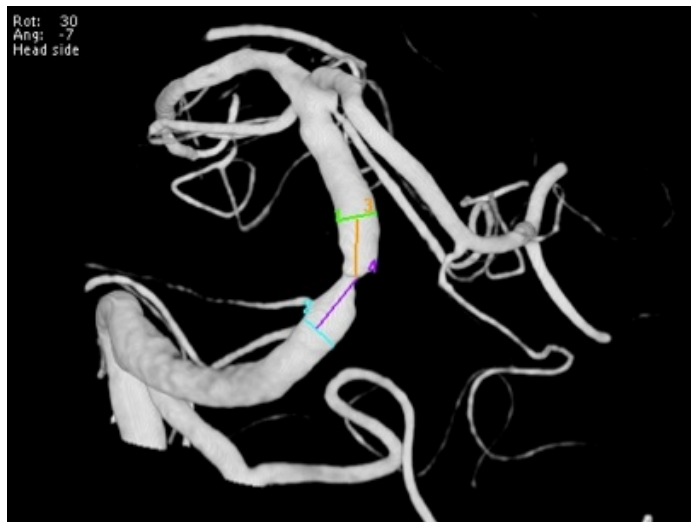
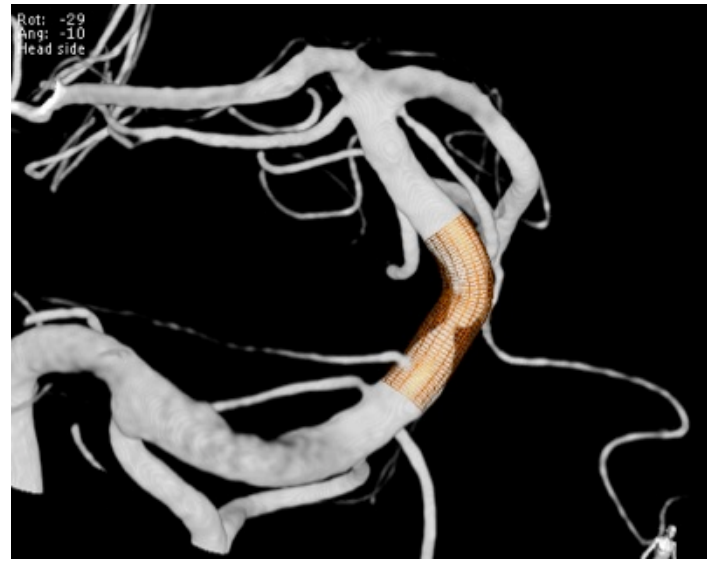
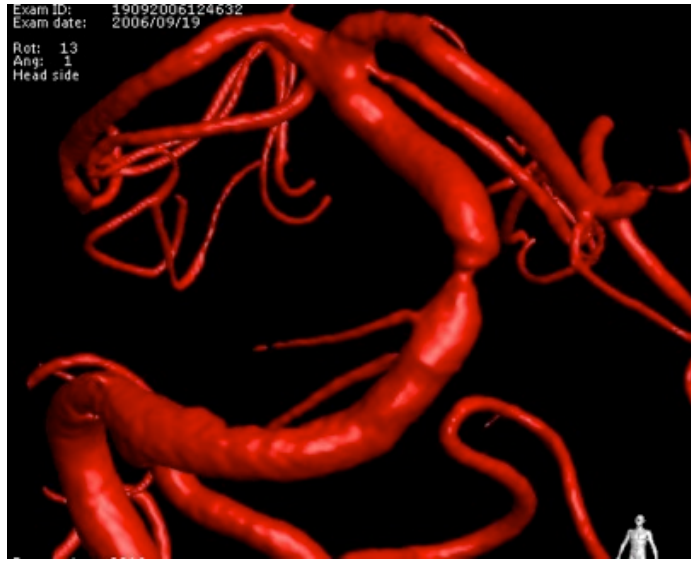
## Angiografia rotacional com reconstrução 3D

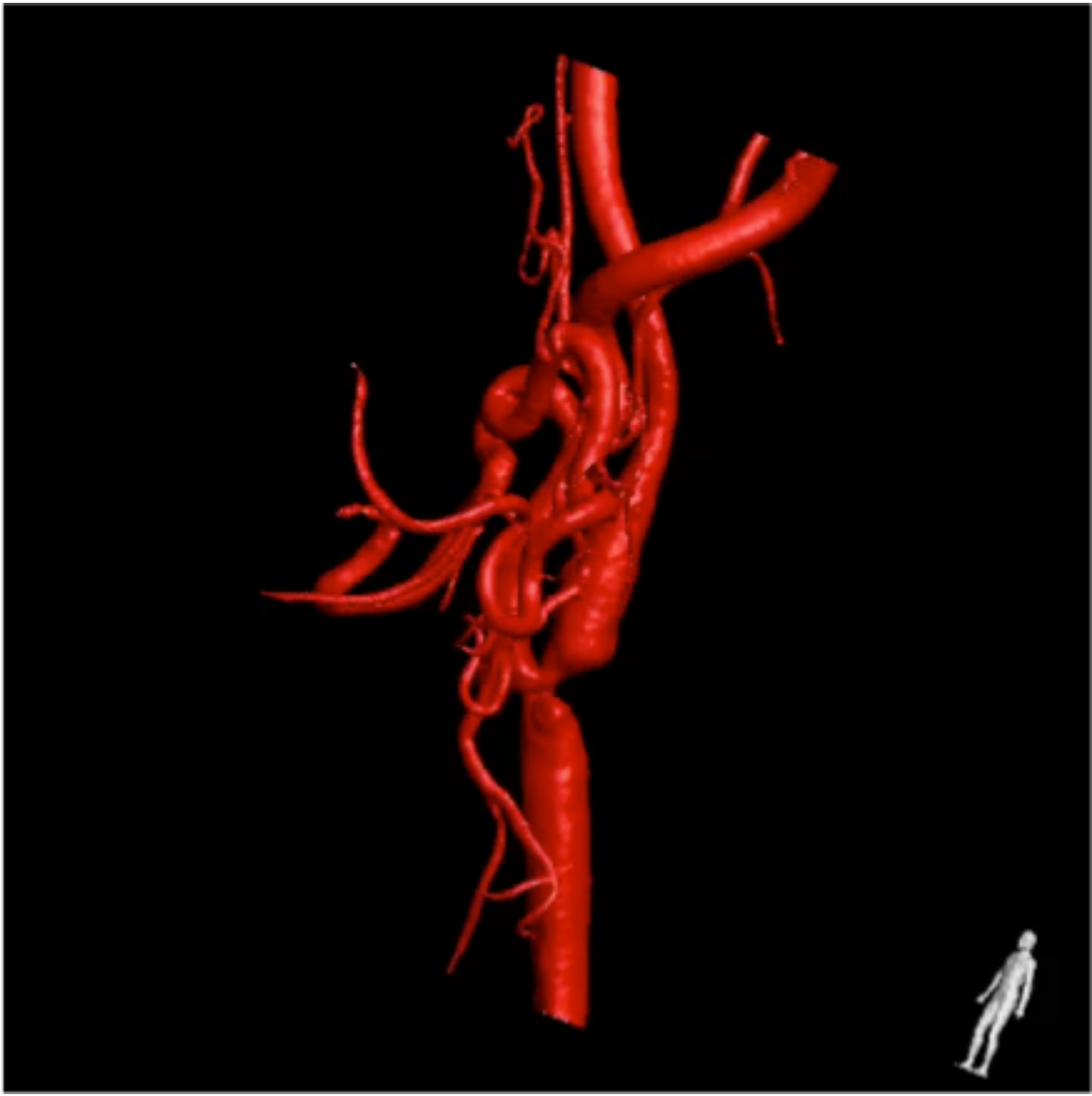





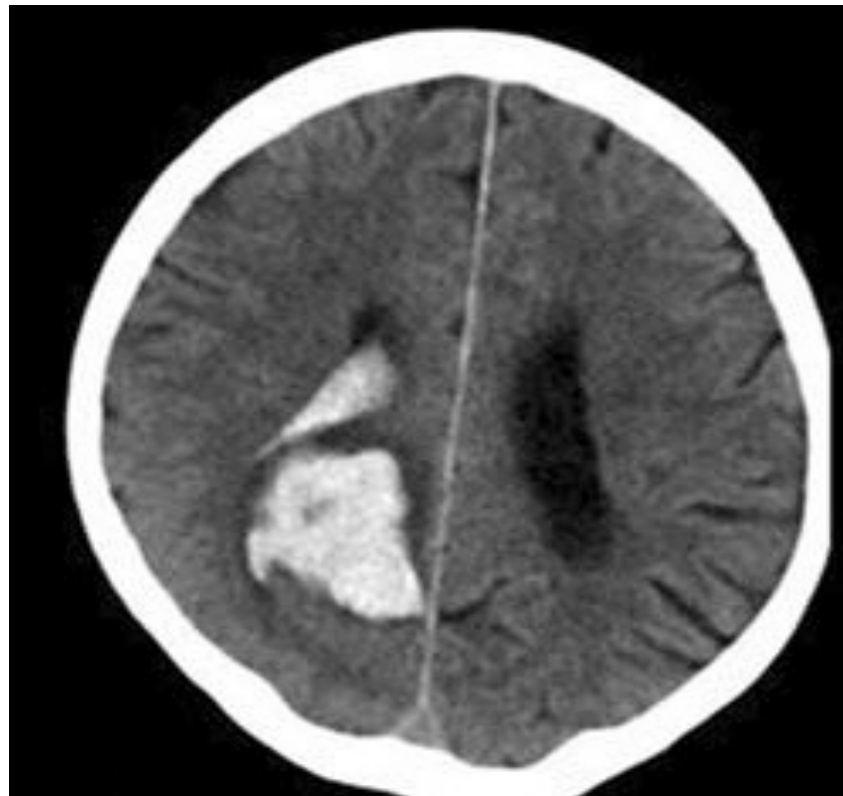
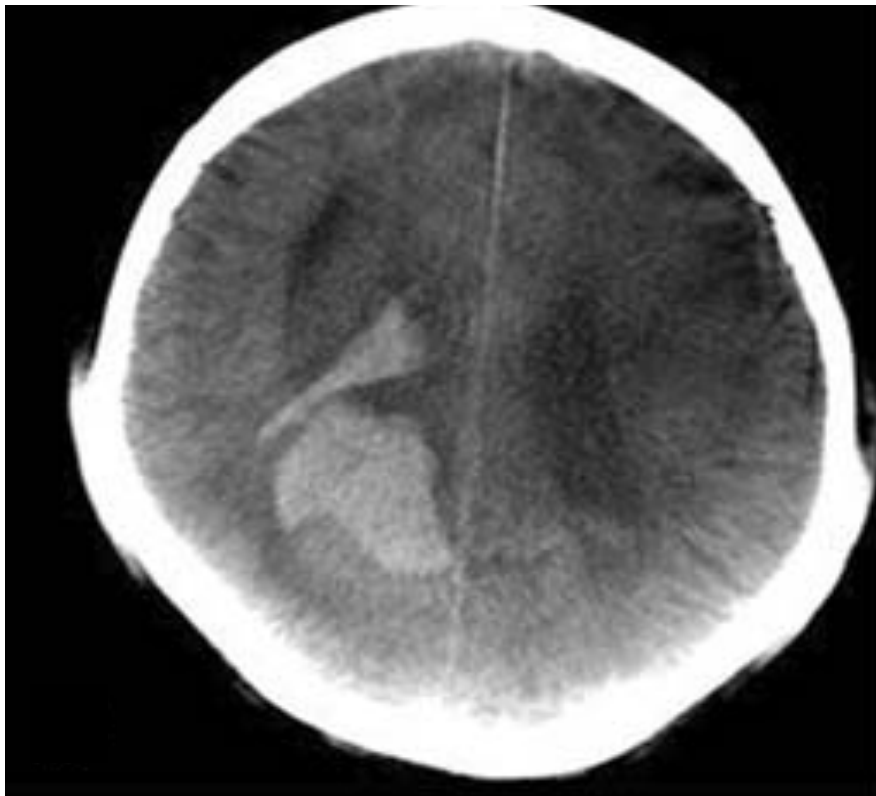






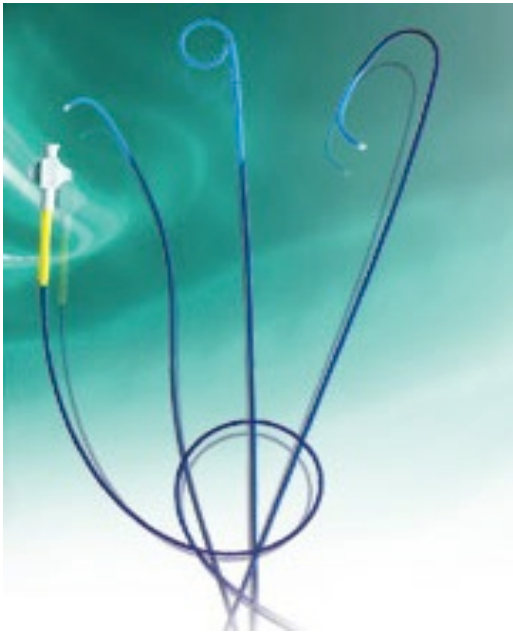


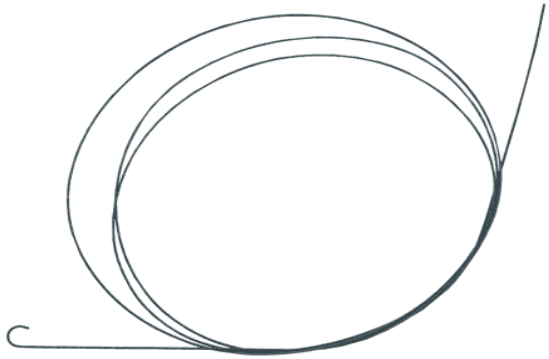


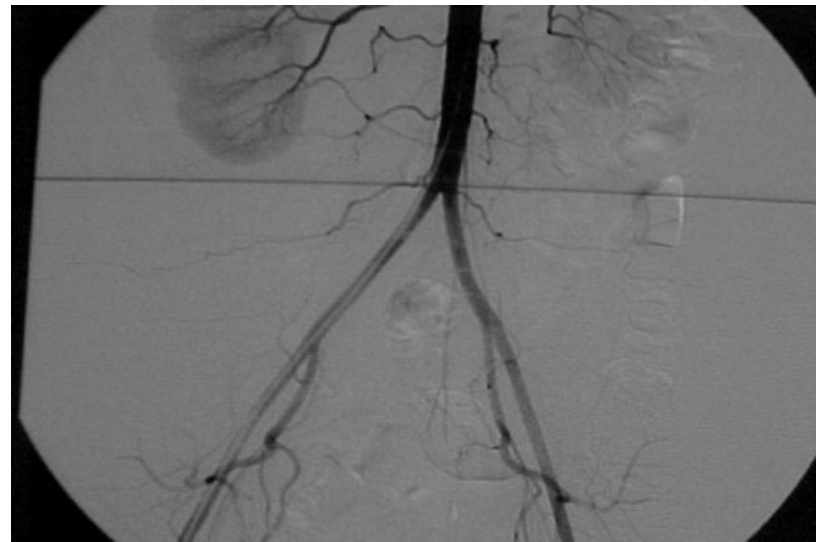

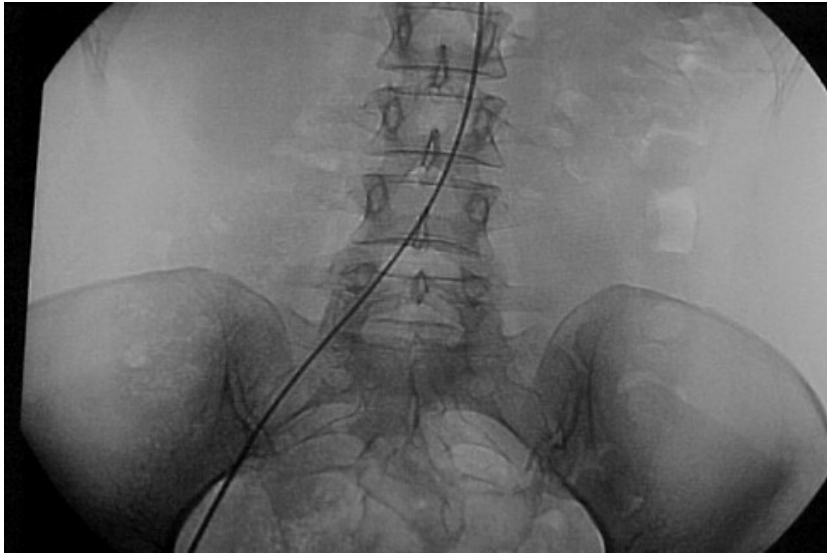


# CT Like

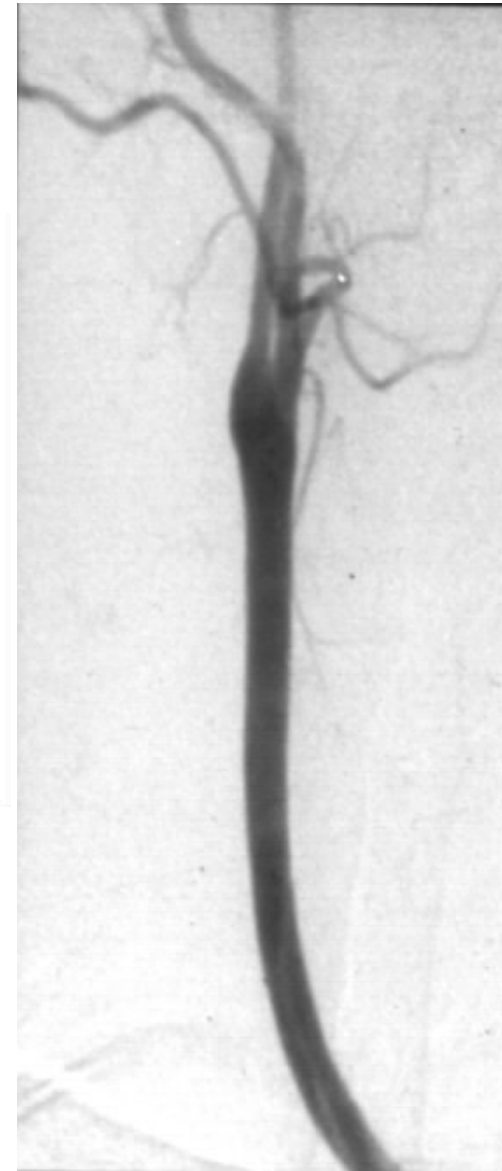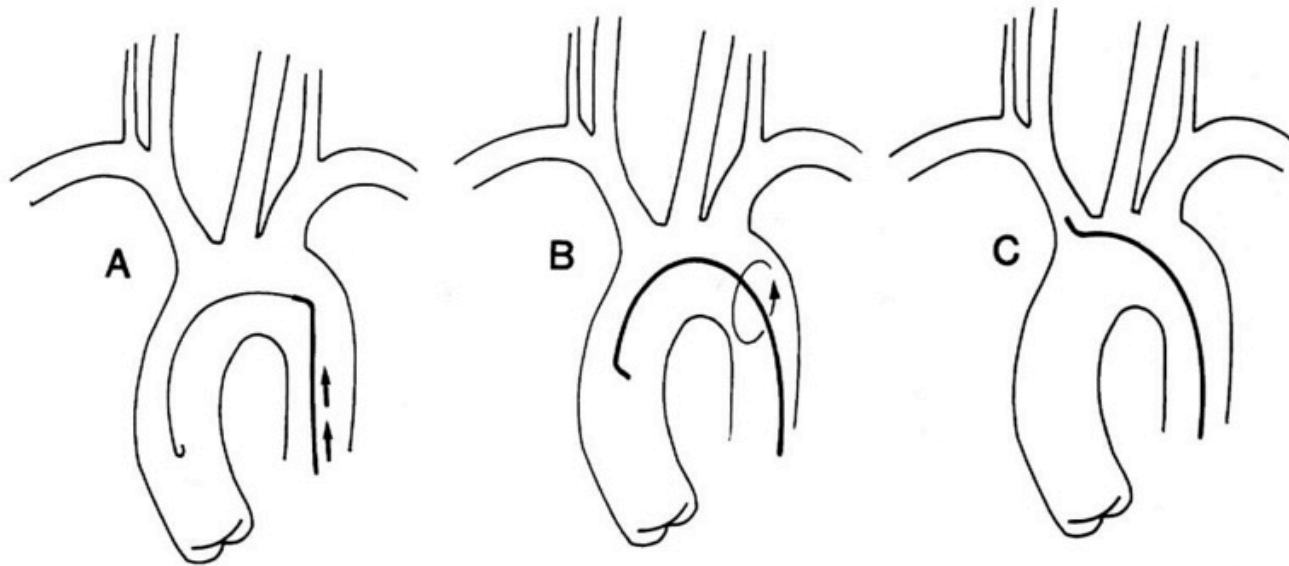


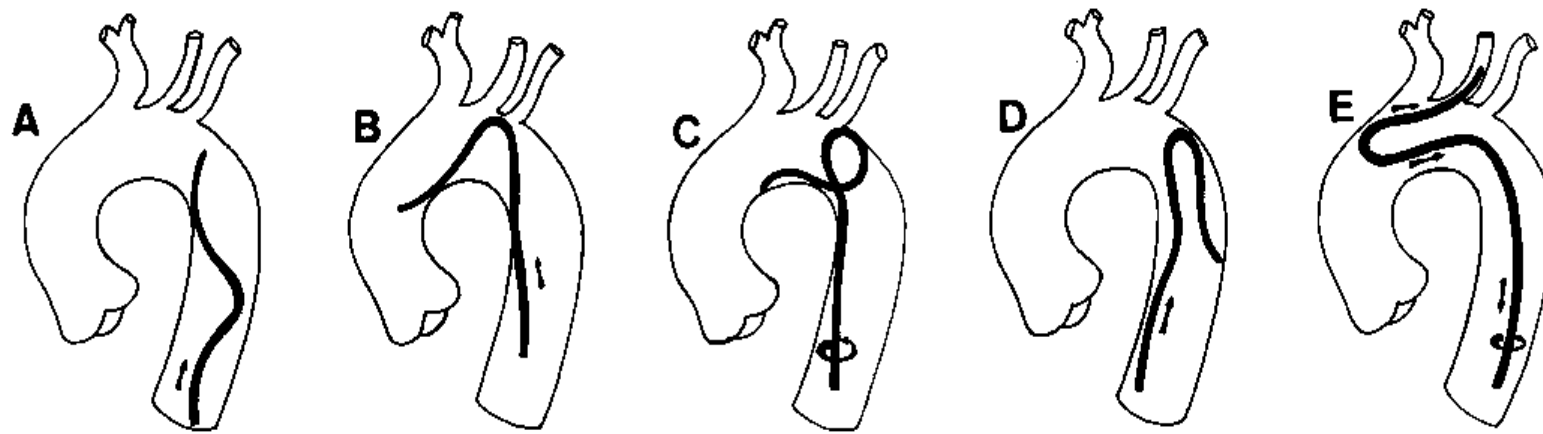






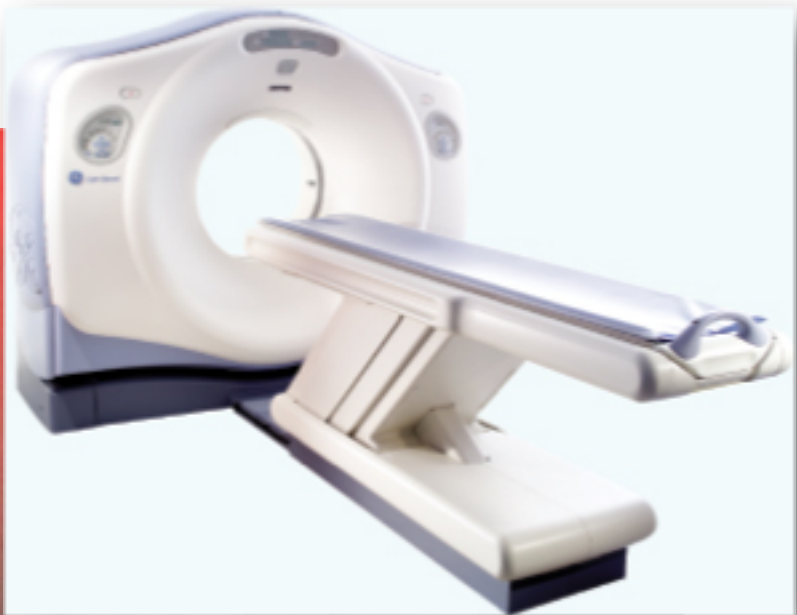
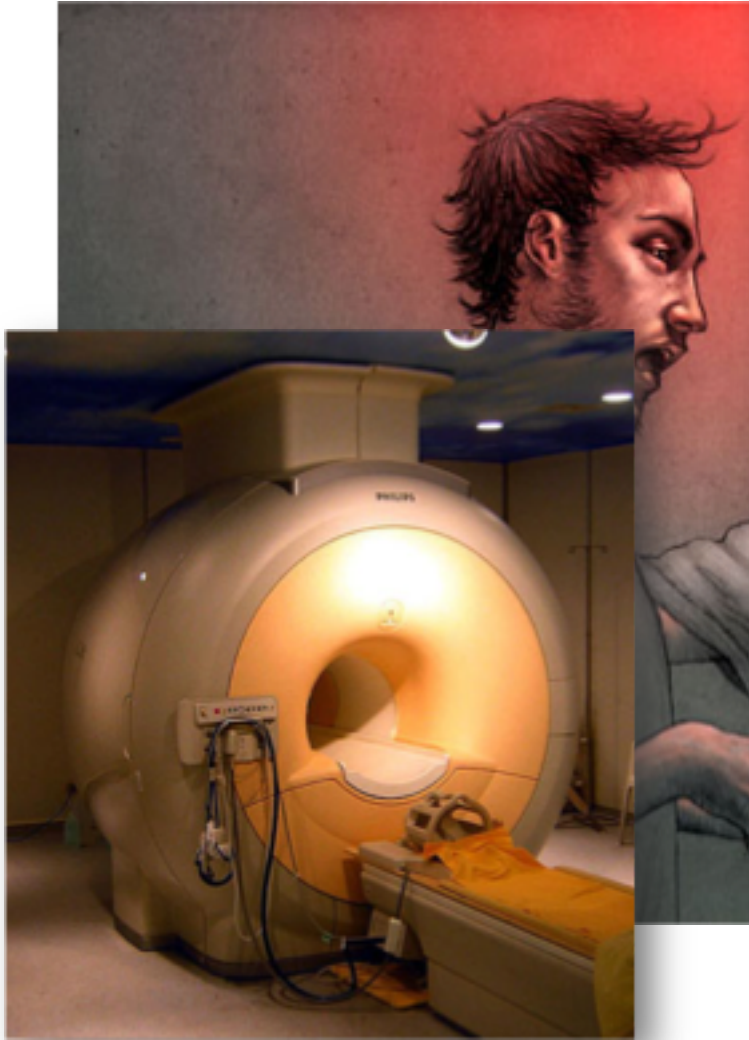# Cateterização direta

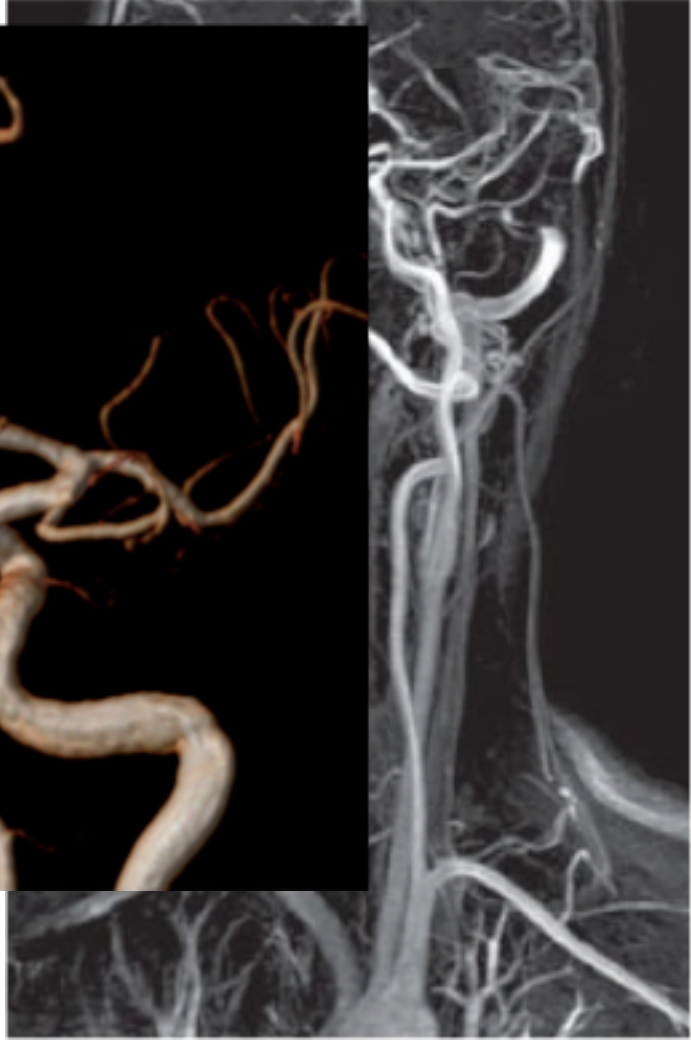
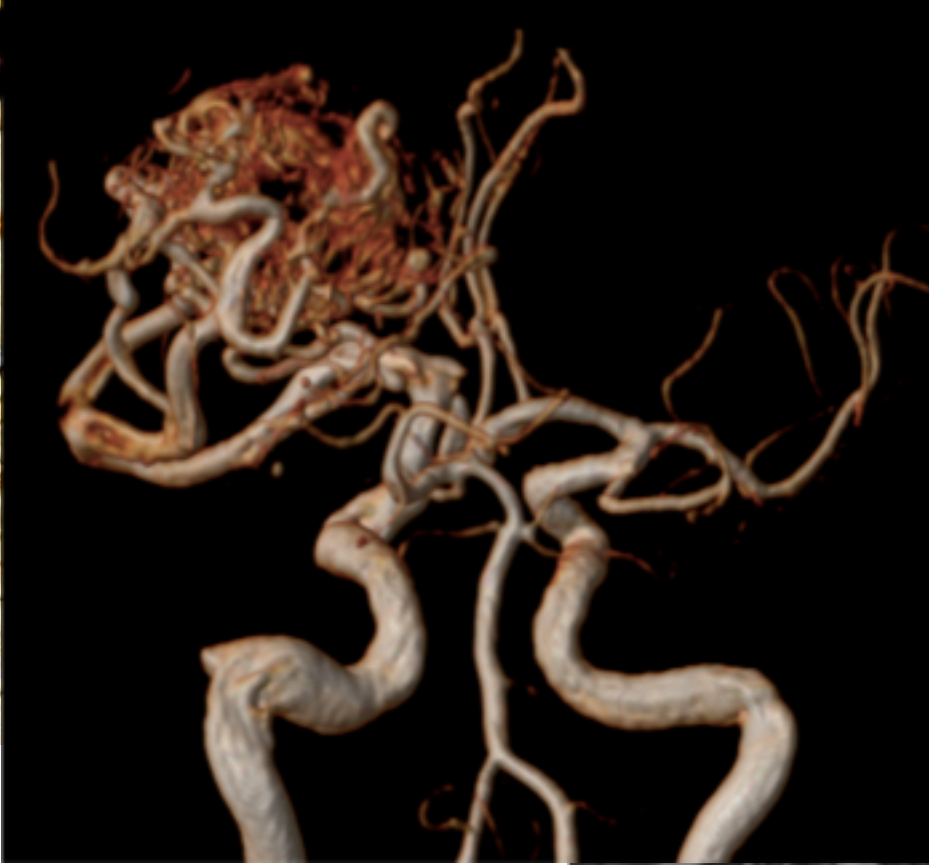
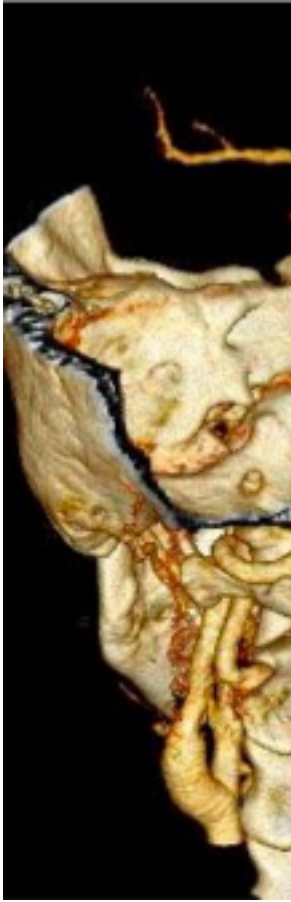



**Cateterização indireta: Simmons**





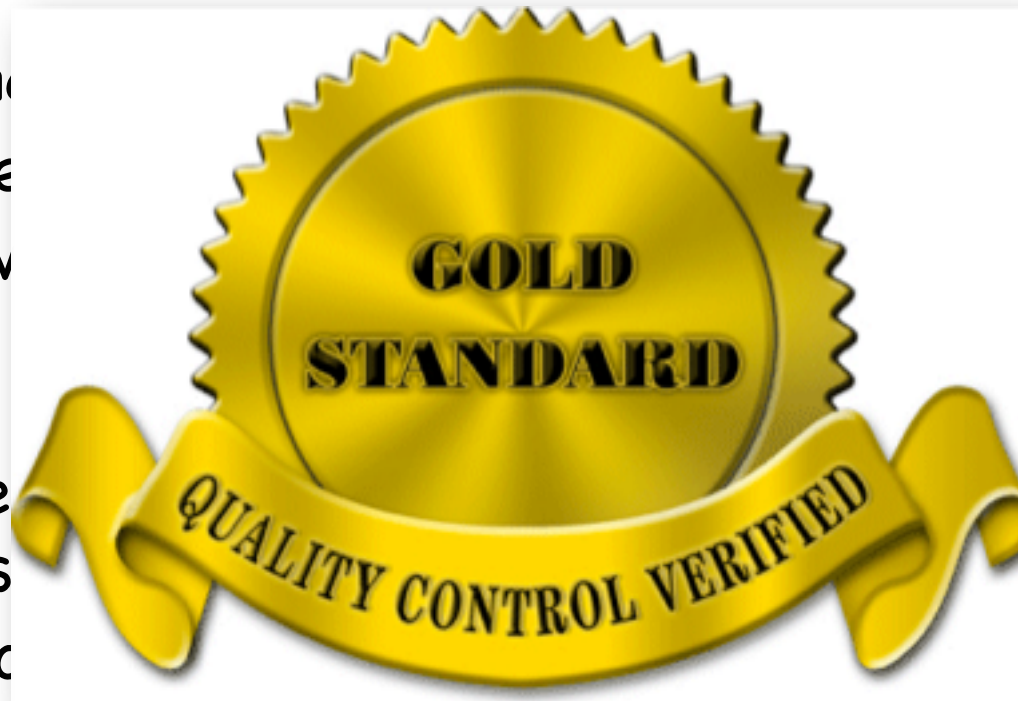

# Angiografia Digital

- O mais invasivo e arriscado exame vascular
- Necessita cateterismo arterial\*
- Curva de aprendizado
- Usa contraste iodado e radiação (RX)
- Não vê partes moles, apenas estruturas ósseas
- Altíssima resolução espacial
- Aplicações terapêuticas em evolução crescente

# Angiografia Digital

- O m
- Necess
- Curv
- Usa
- Não  
ósse
- Altís
- Aplic  
crescente



ular

# Angiografia Digital

- Técnica de Seldinger
- Cateteres de baixo perfil
- Contrastes não-iônicos
- Angiografia com subtração digital
- Equipe com treinamento específico (Radiologista Intervencionista, Anestesista, enfermagem e técnico de radiologia)
- Angiografia Biplanar e tridimensional



# Indicações

- Arteriopatia obstrutiva
- Aneurismas e pseudoaneurismas
- Trauma vascular
- Mal-formações vasculares
- Estudo da vascularização tumoral
- Mapeamento da anatomia arterial, pré-operatório
- Procedimentos terapêuticos endovasculares

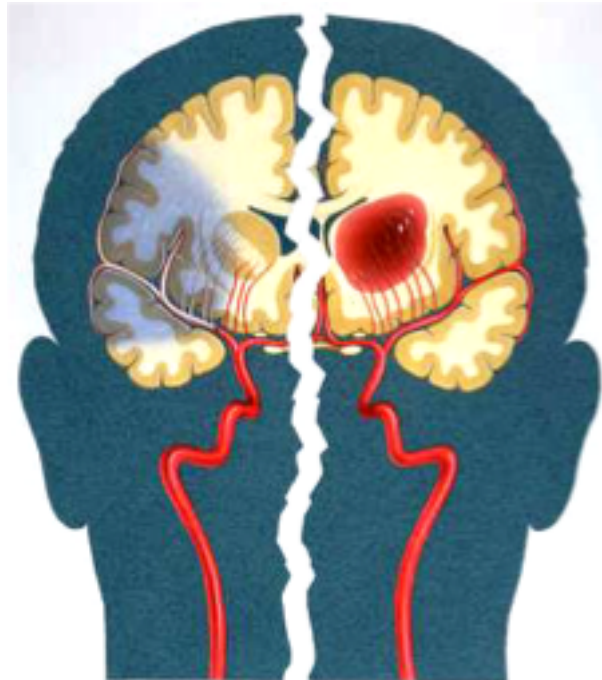
# Contra-Indicações

- Ausência de acesso
- Alergia ao contraste
- Insuficiência Renal
- Insuficiência Cardíaca

# Angiografia Digital

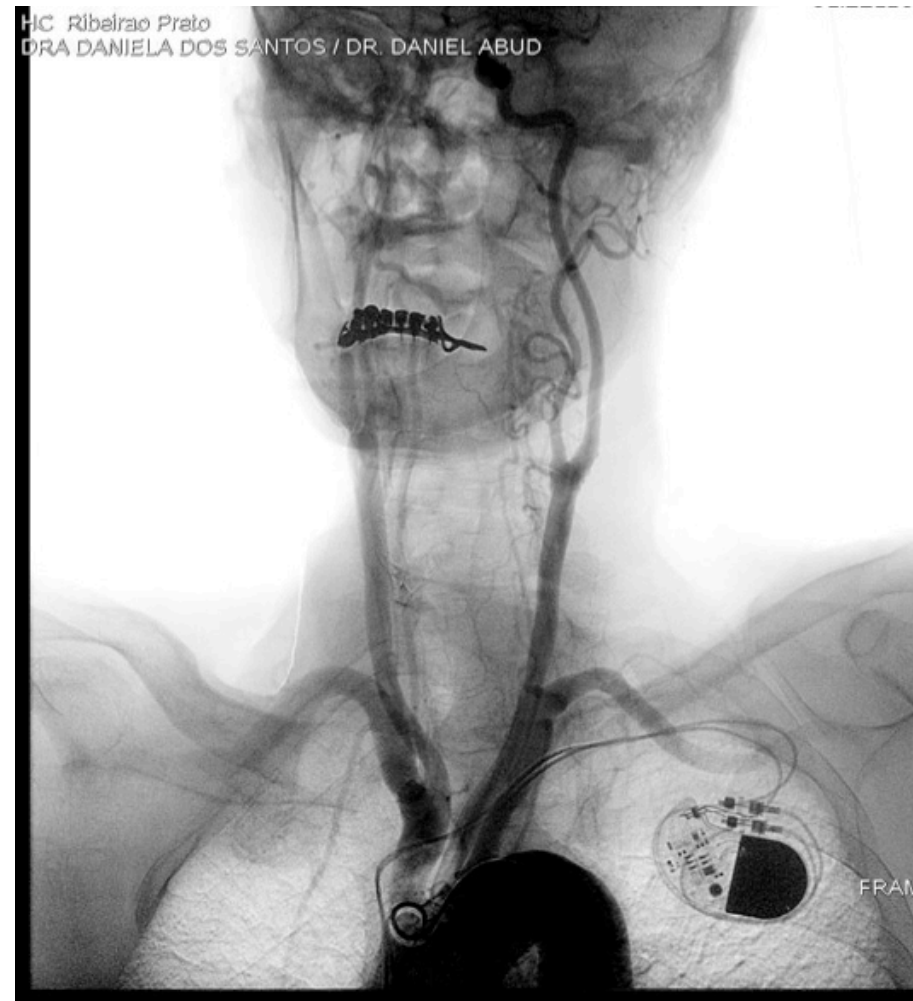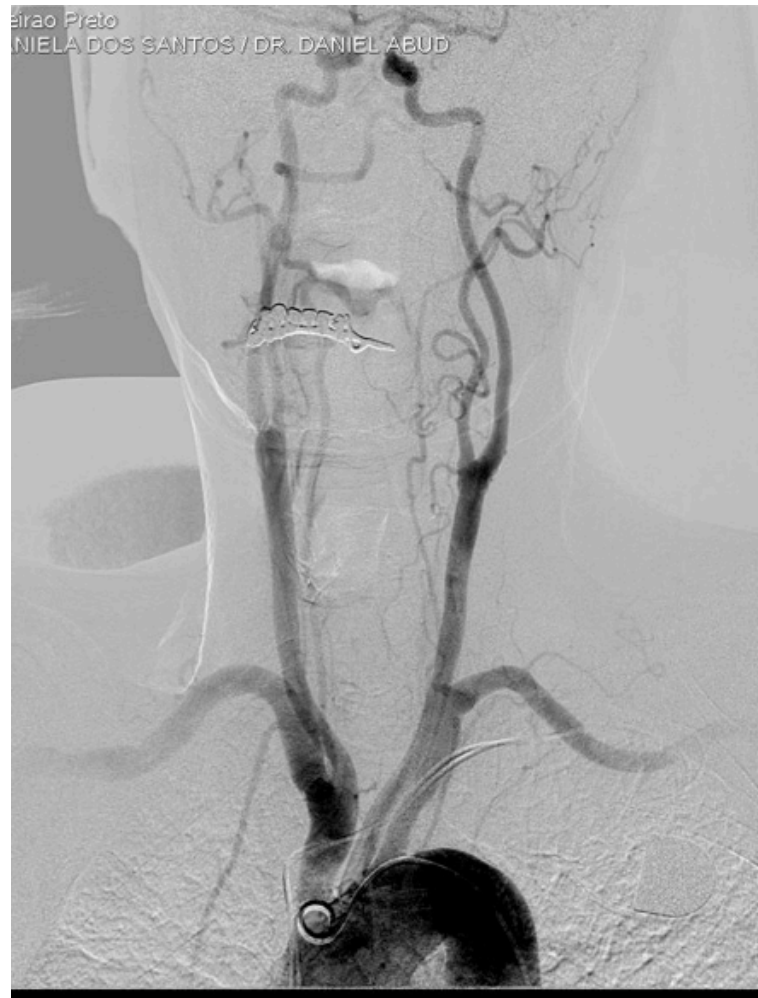## Aplicações atuais no AVC

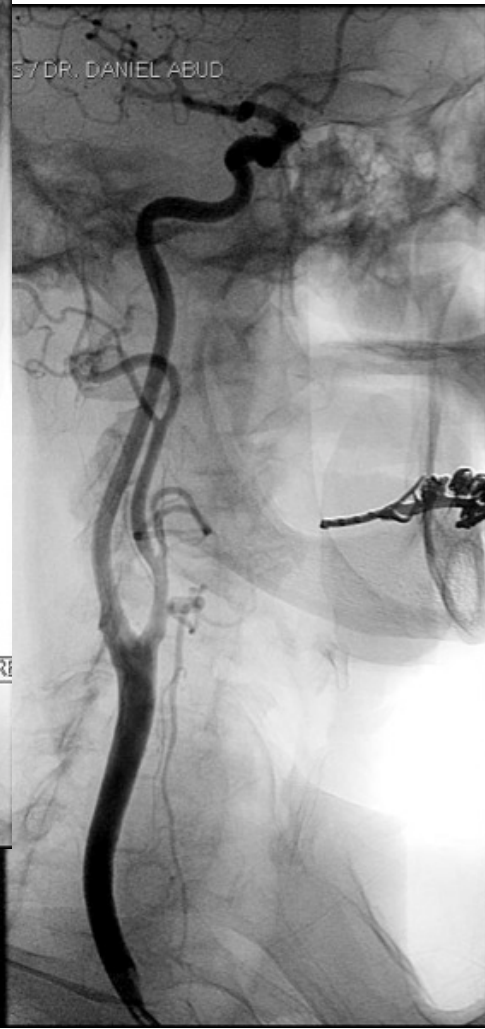
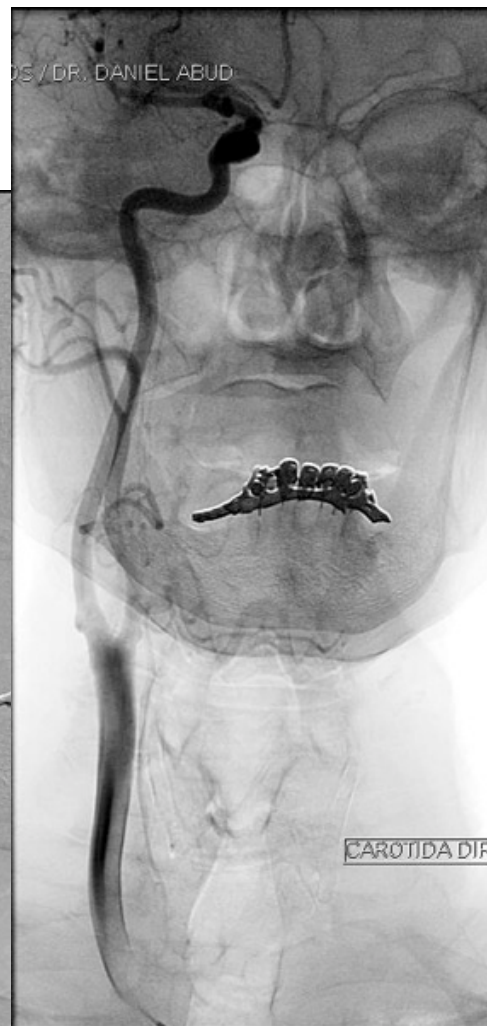
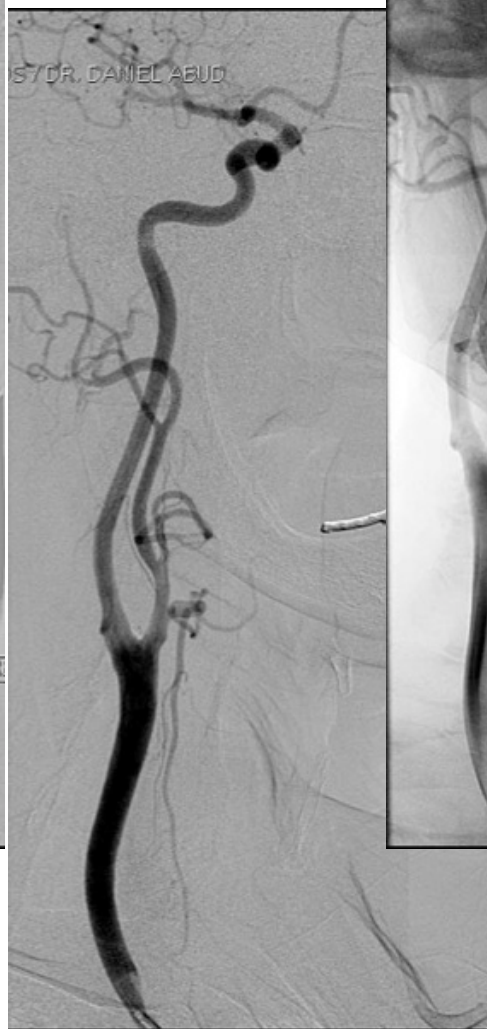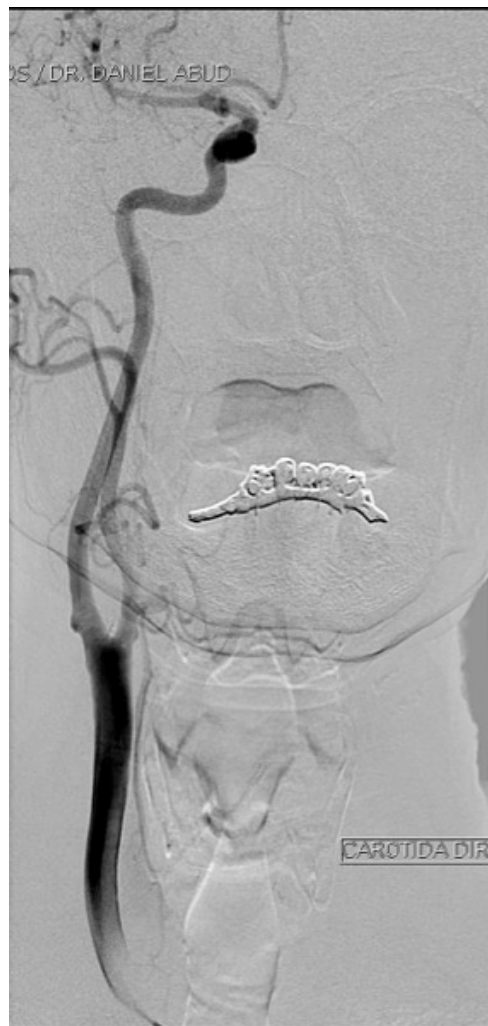Isquêmico  
80% dos casos



Hemorrágico  
20% dos casos

# Aterosclerose: obstrução arterial crônica

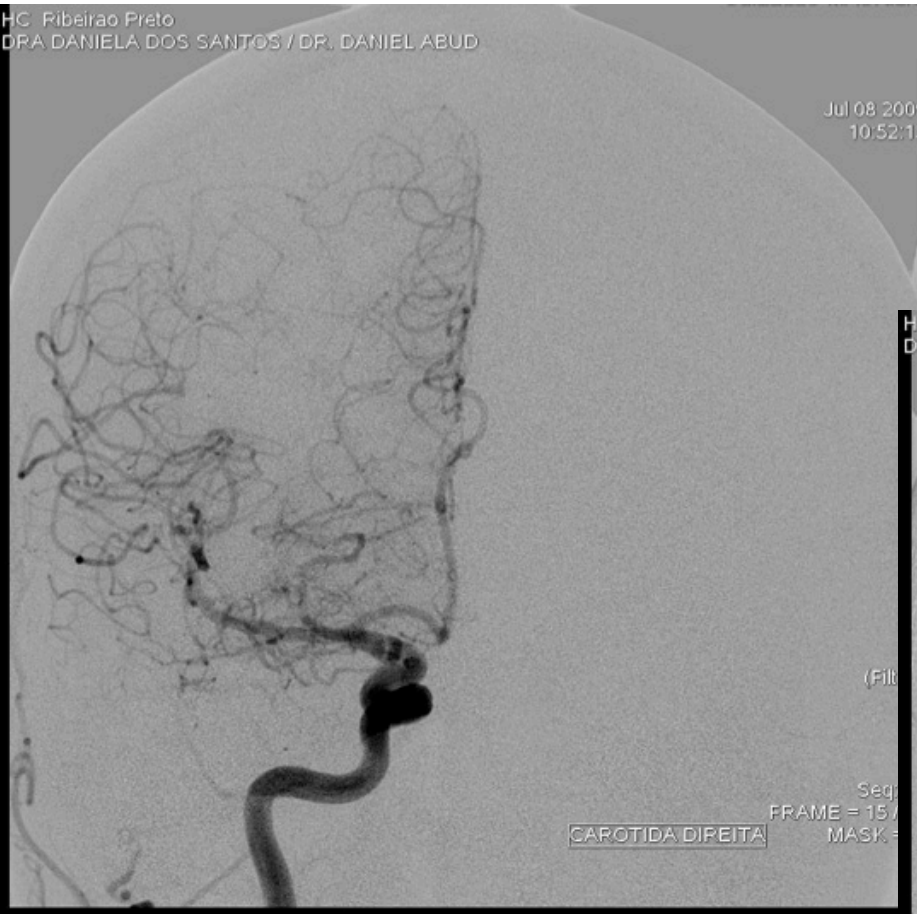





HC - Ribeirao Preto  
DRA DANIELA DOS SANTOS / DR. DANIEL ABUD

Jul 08 2009  
10:52:15



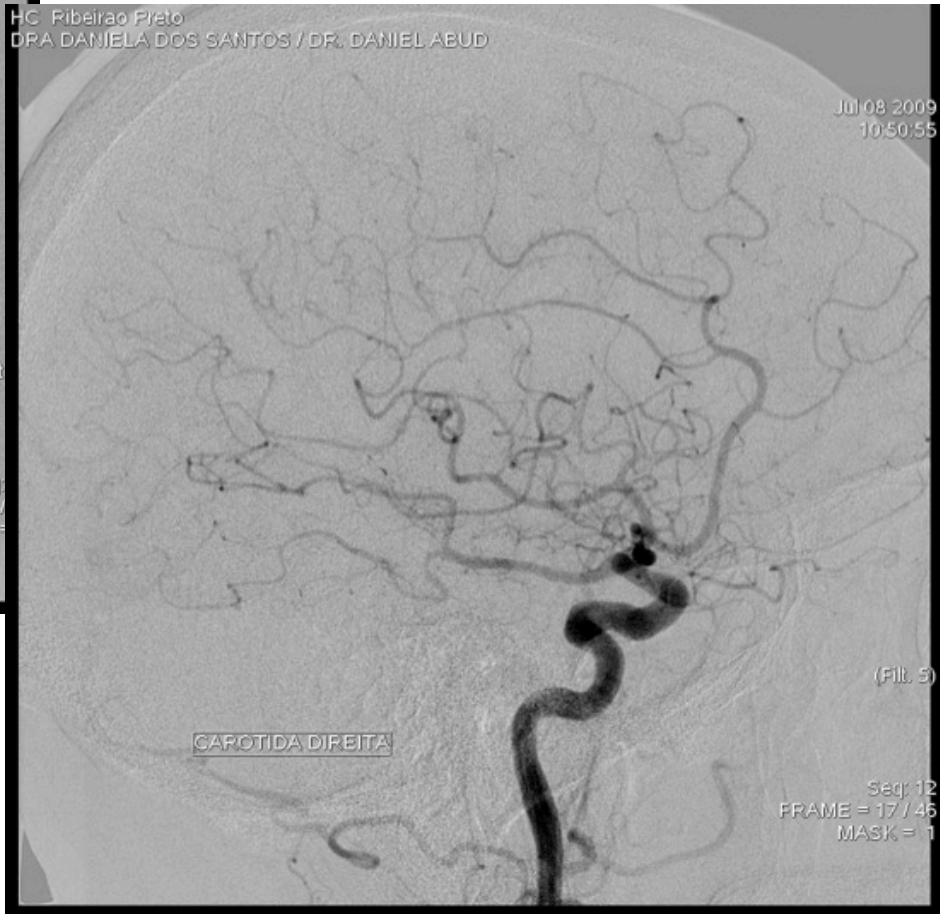
(Fil

CAROTIDA DIREITA

Seq:  
FRAME = 15 /  
MASK =

HC - Ribeirao Preto  
DRA DANIELA DOS SANTOS / DR. DANIEL ABUD

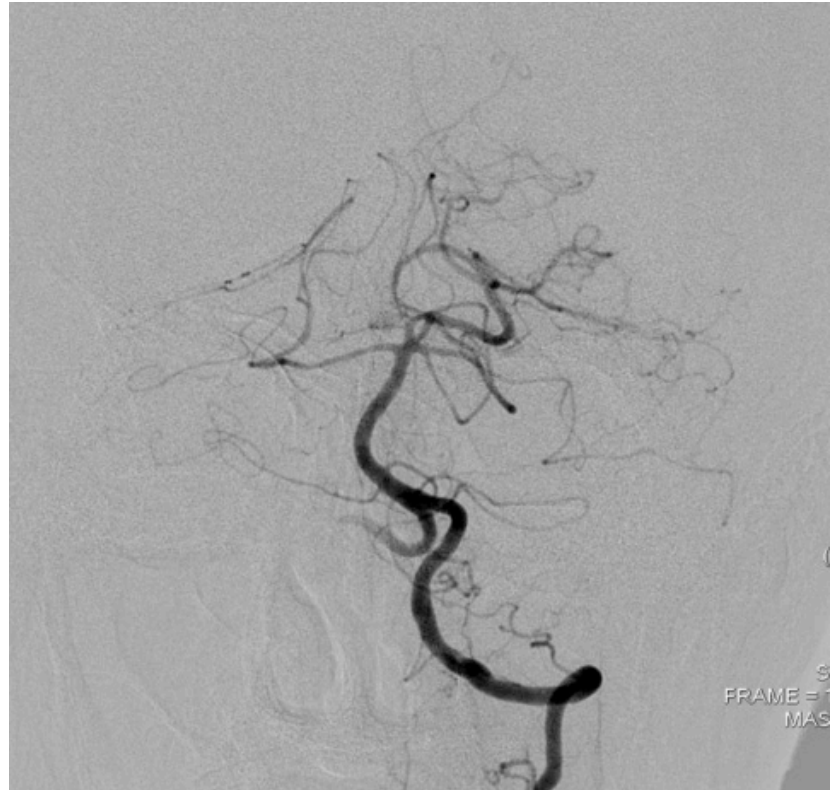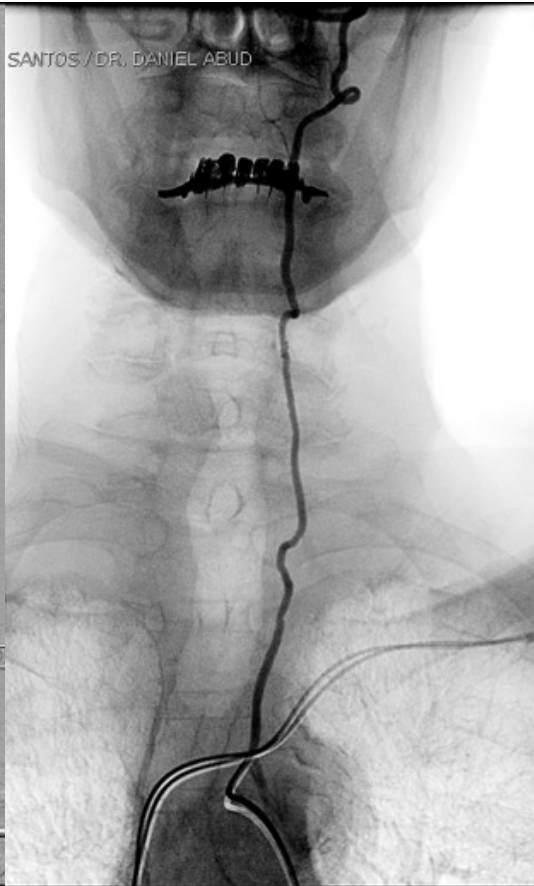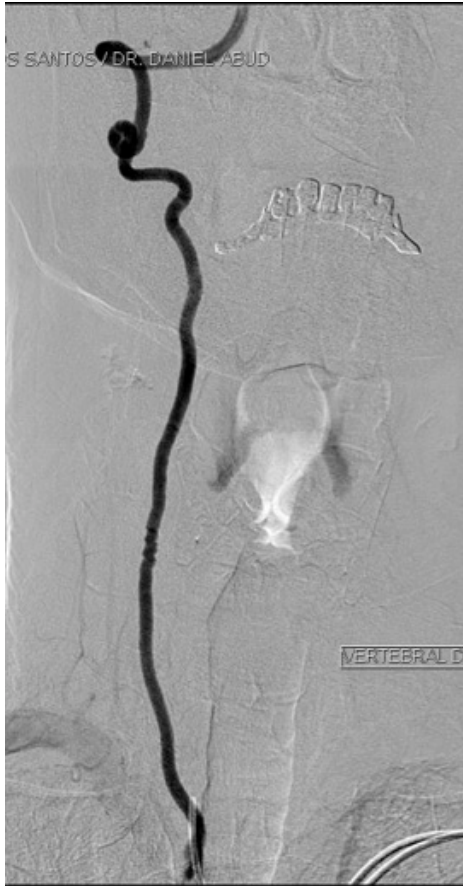Jul 08 2009  
10:50:55



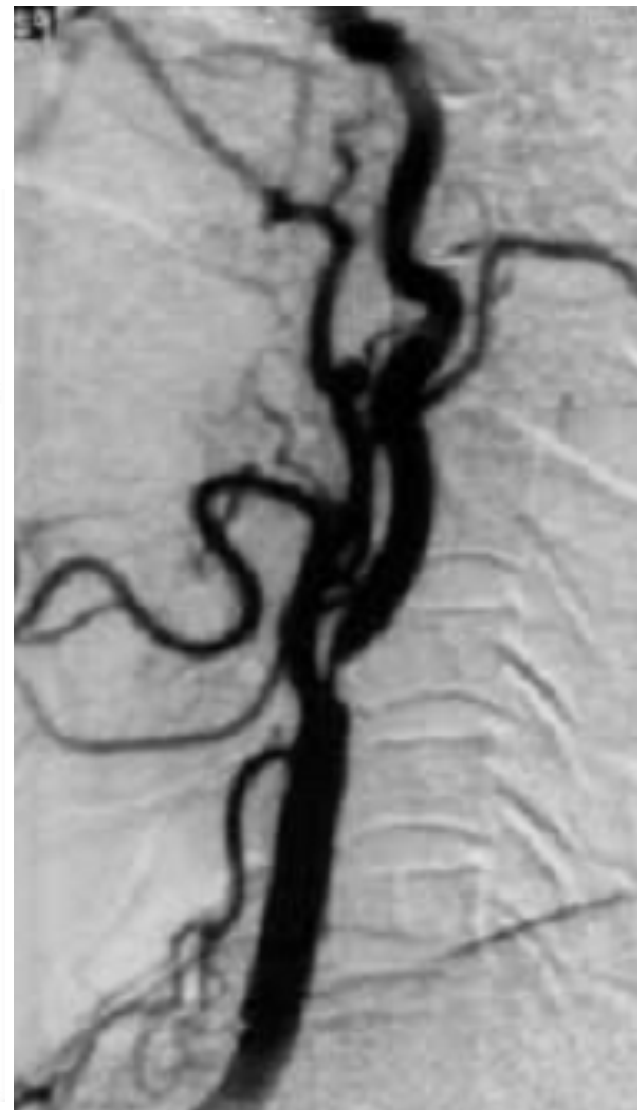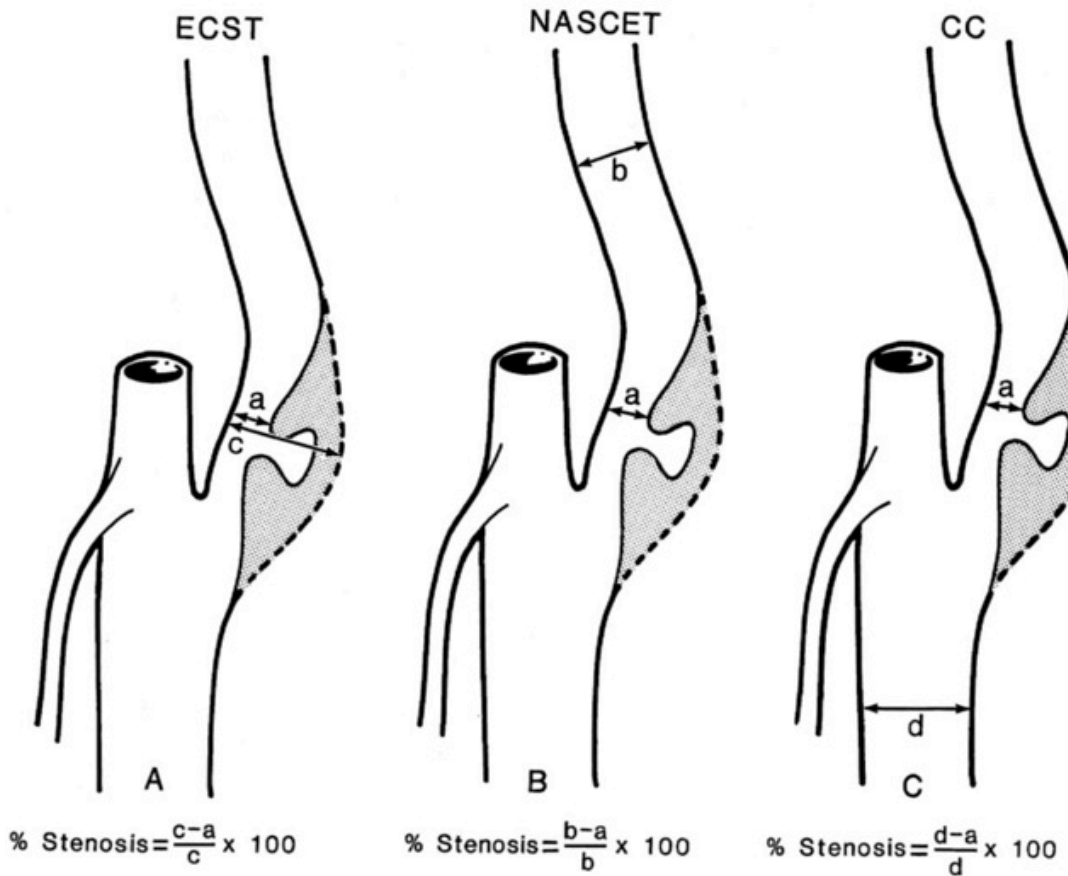
(Fil: 9)

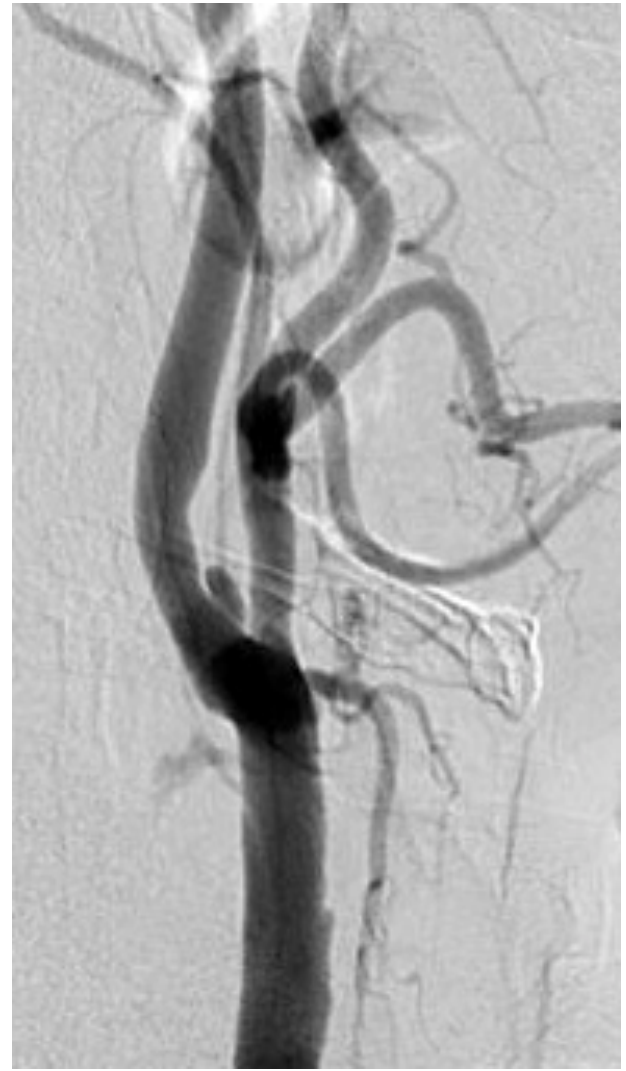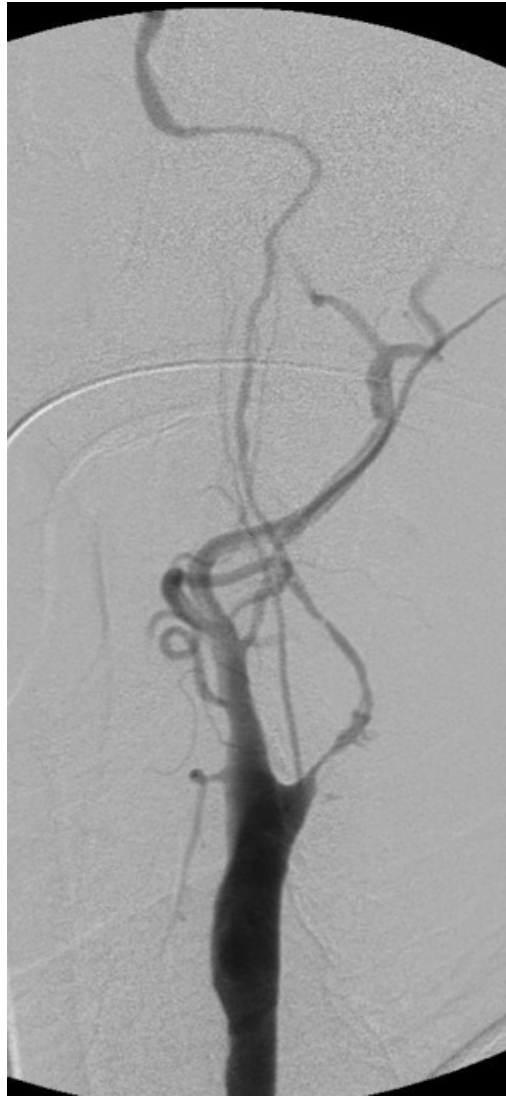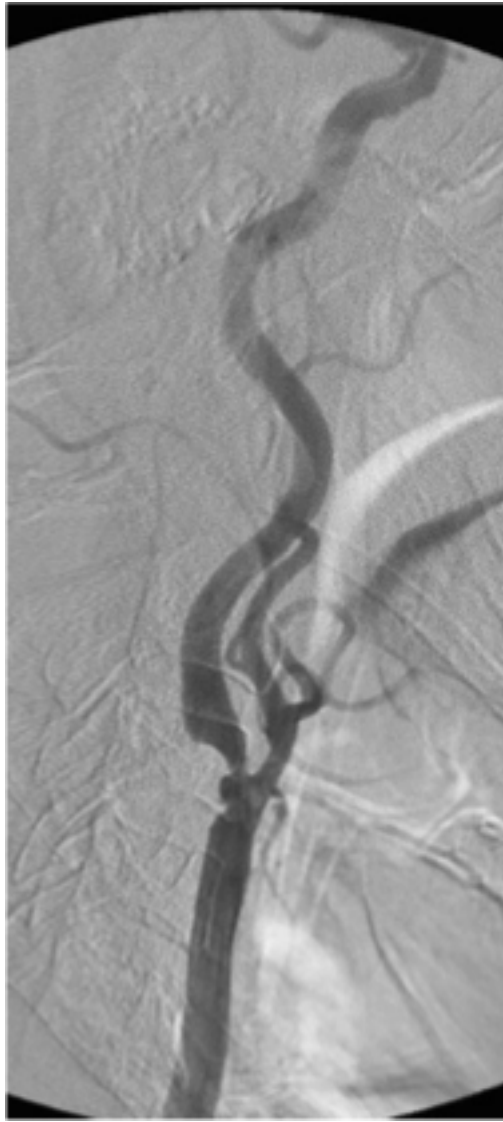
CAROTIDA DIREITA

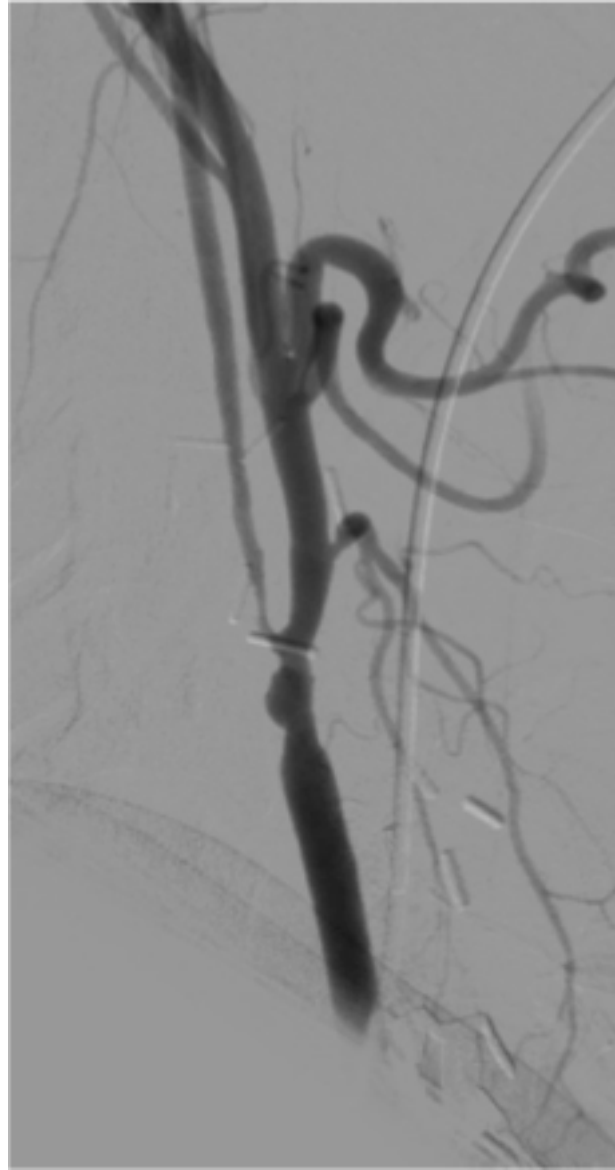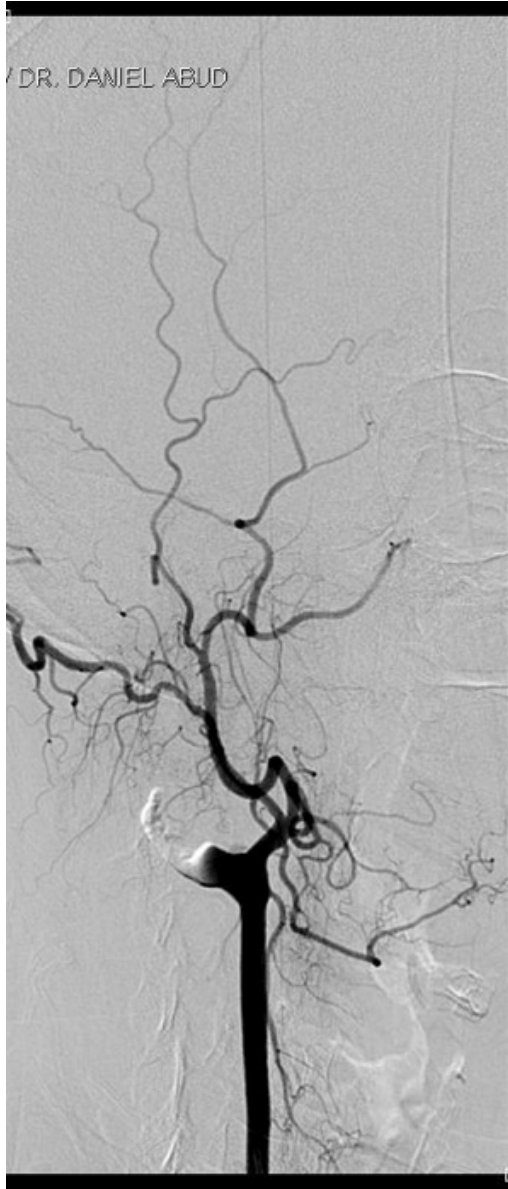
Seq: 12  
FRAME = 17 / 45  
MASK = 1



# Quantificação de estenose

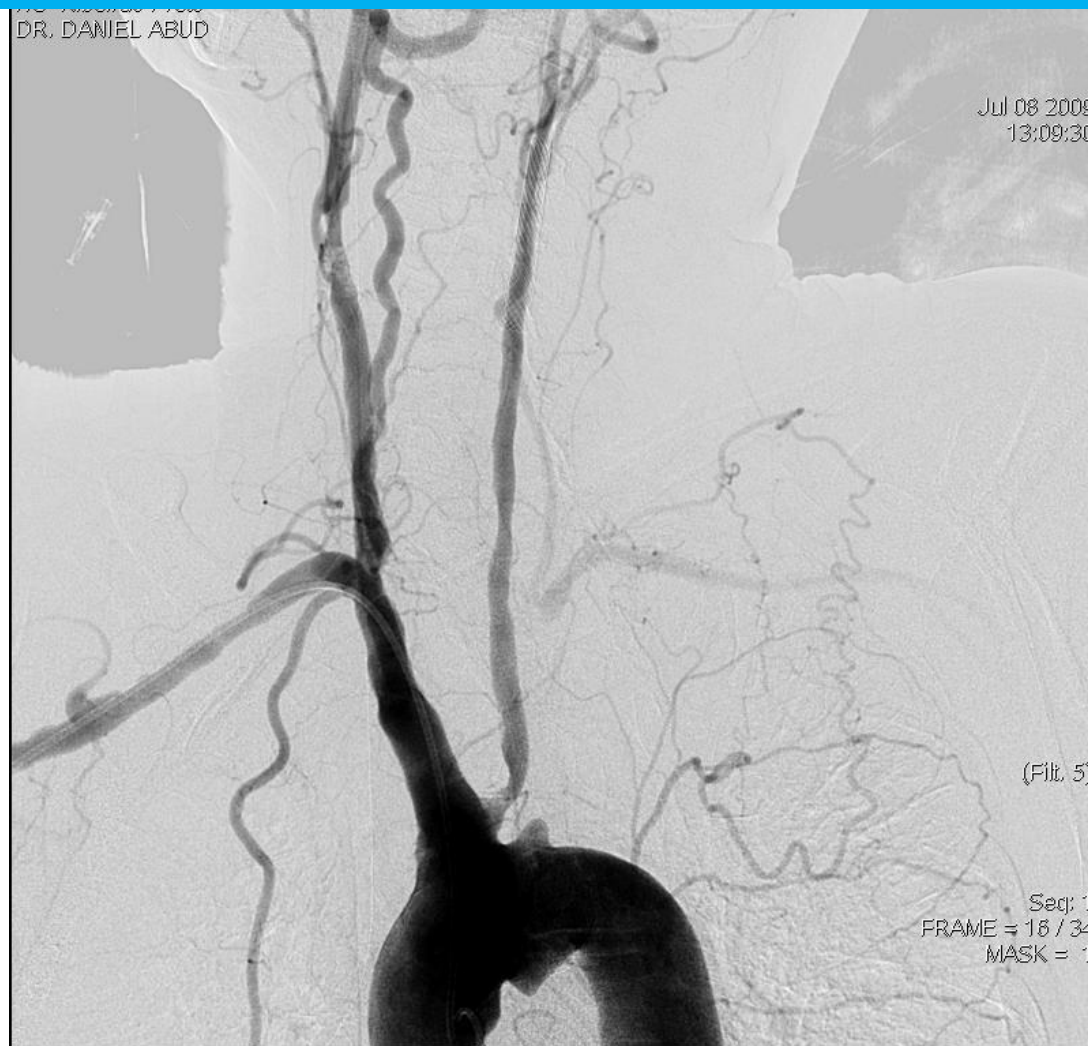






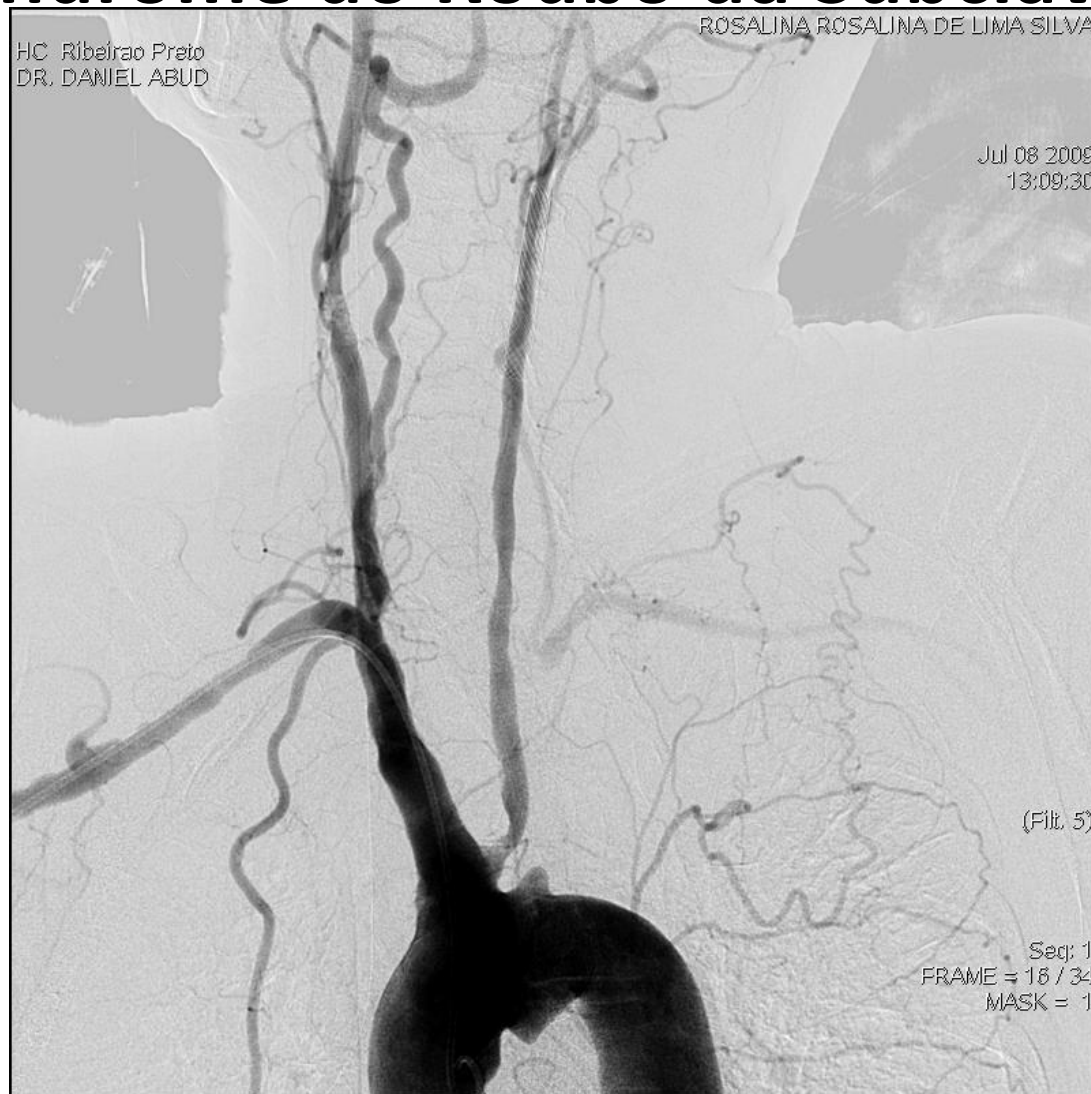


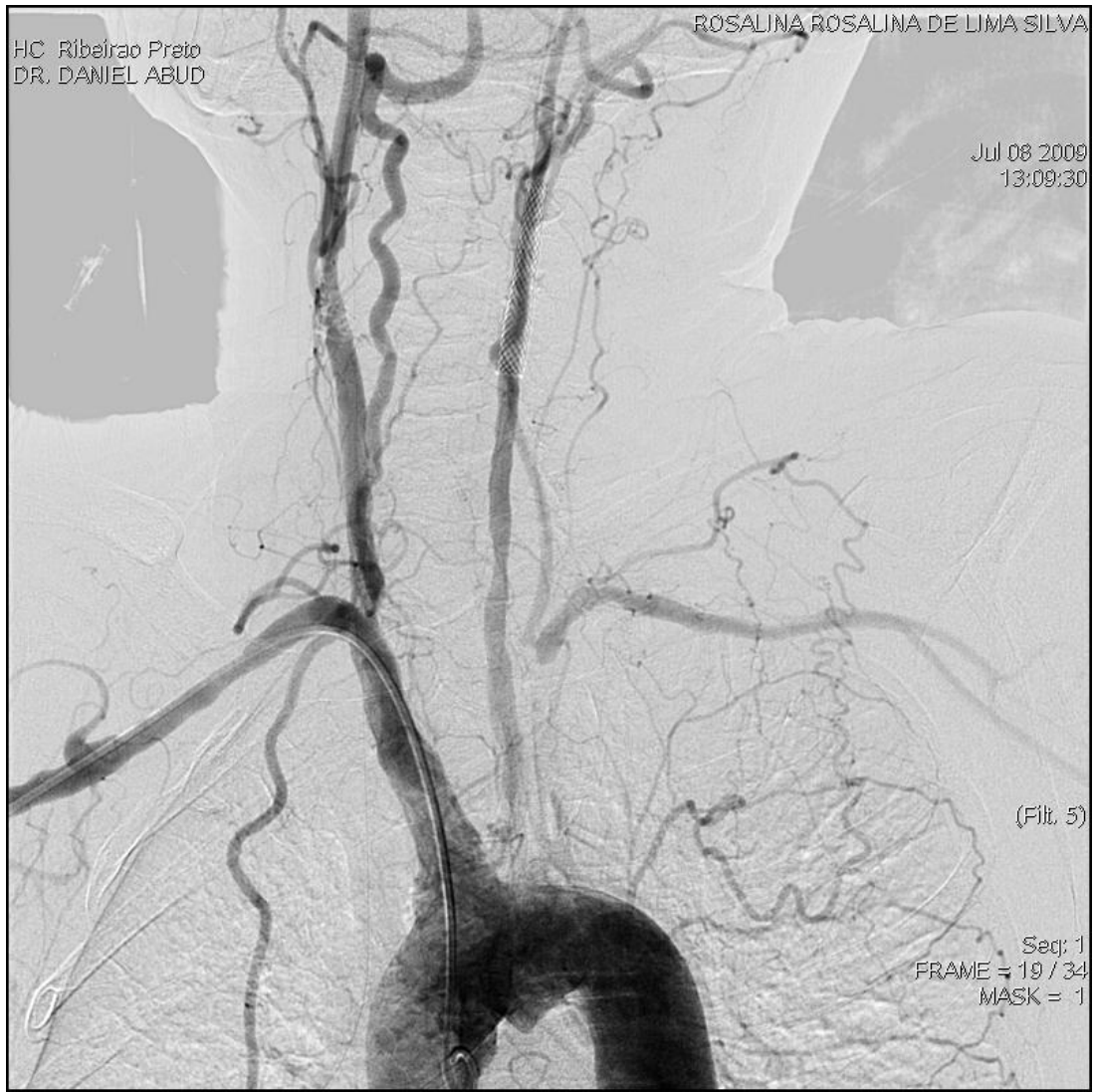
# Exame dinâmico com radiografias seriadas





# Síndrome do Roubo da Subclávia





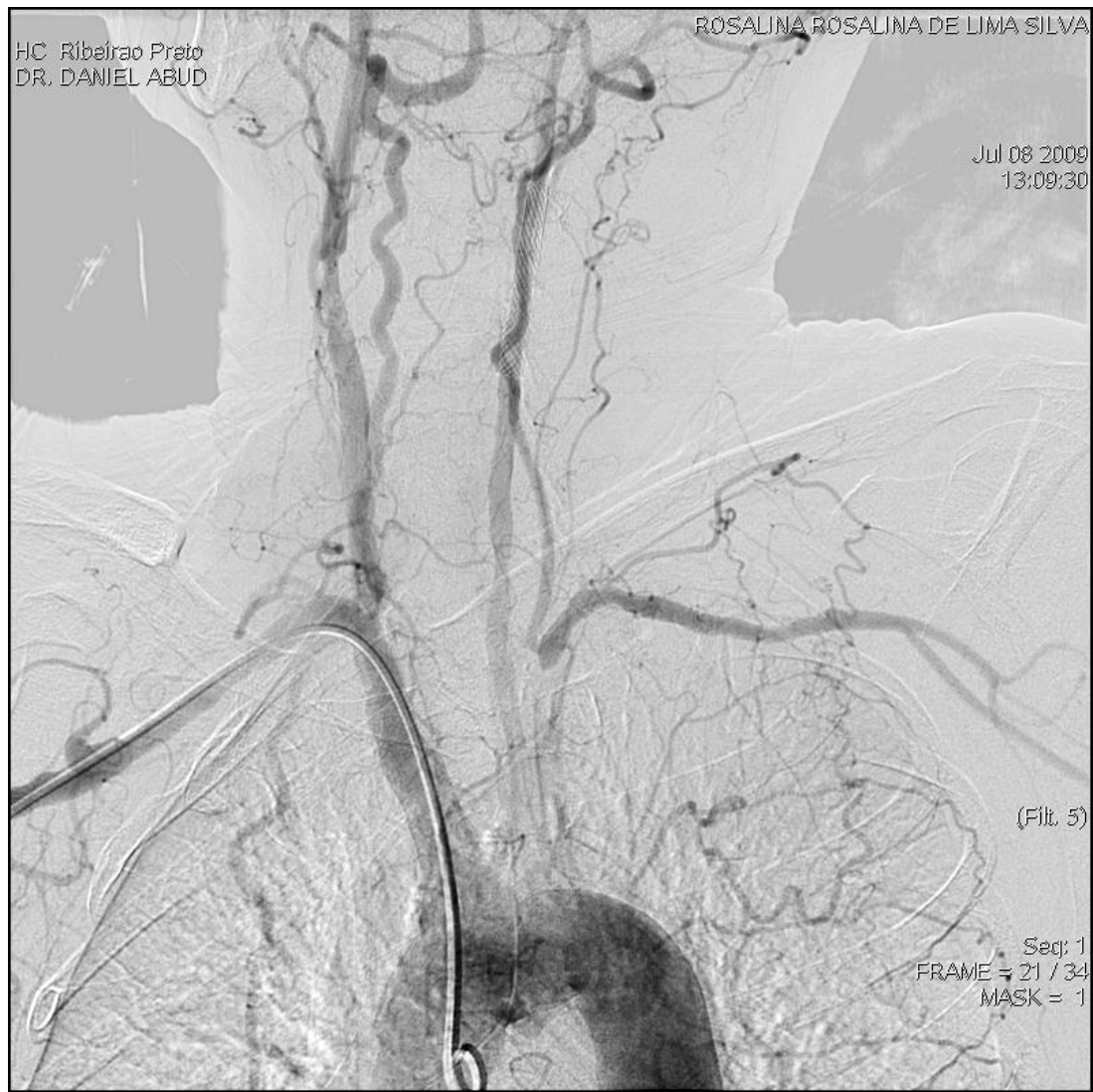HC Ribeirão Preto  
DR. DANIEL ABUD

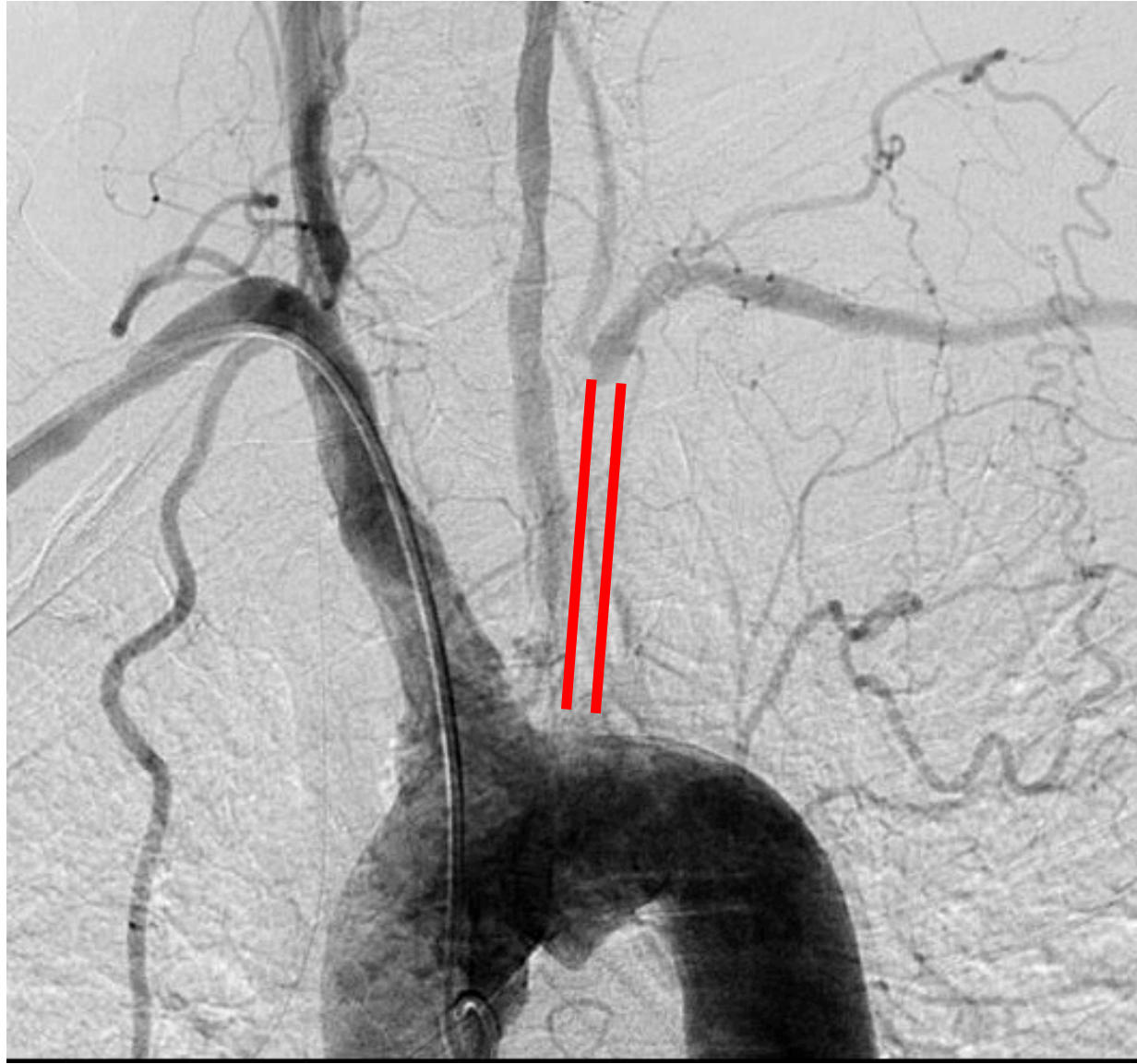ROSALINA ROSALINA DE LIMA SILVA

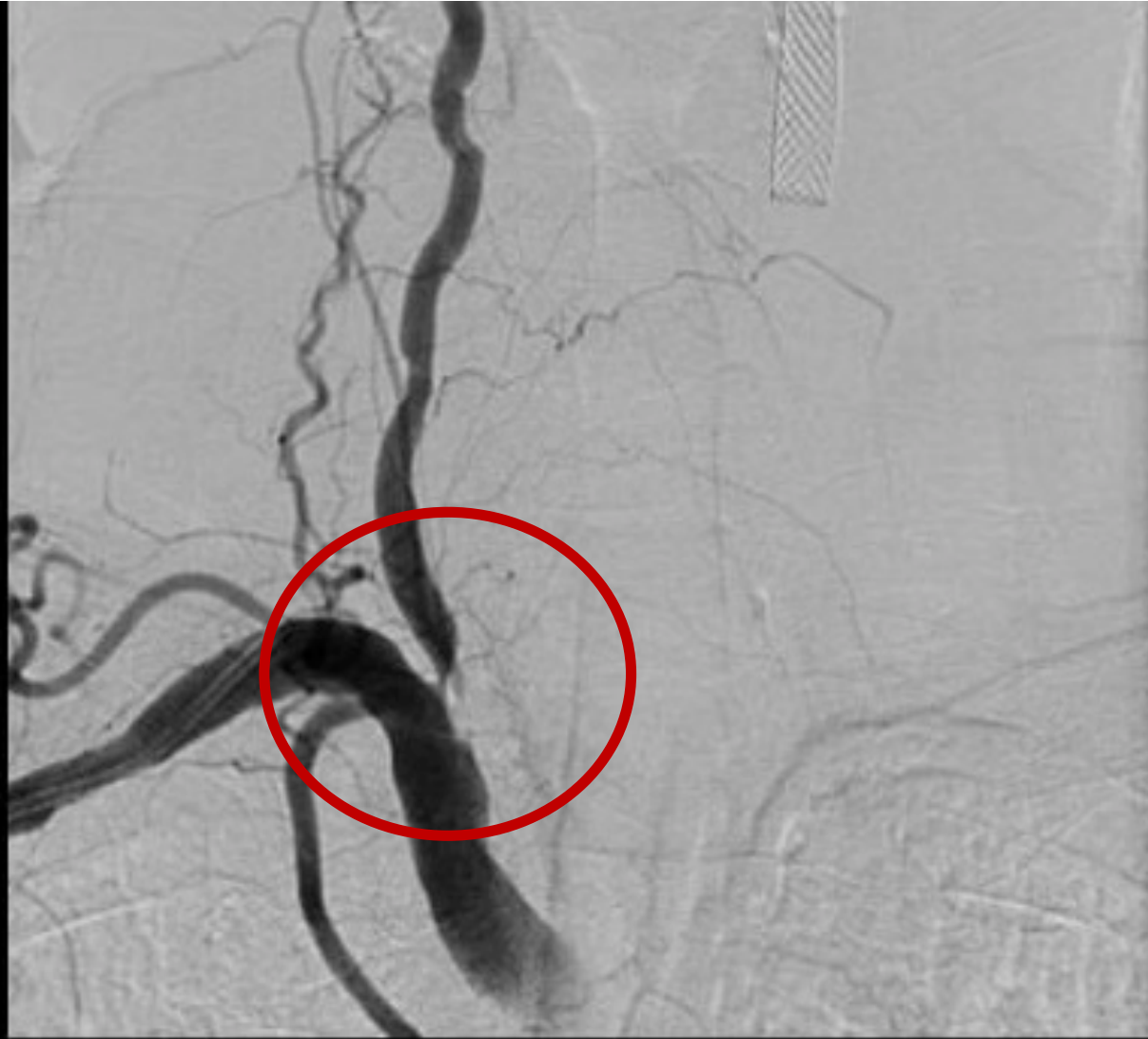JUL 08 2009  
13:09:30

(Filt. 5)

Seq: 1  
FRAME = 19 / 34  
MASK = 1







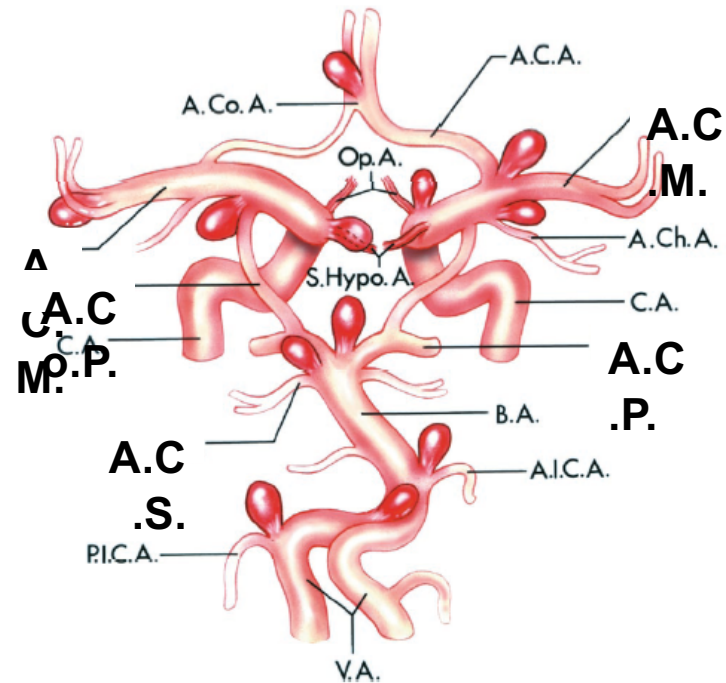
# Hemorragias

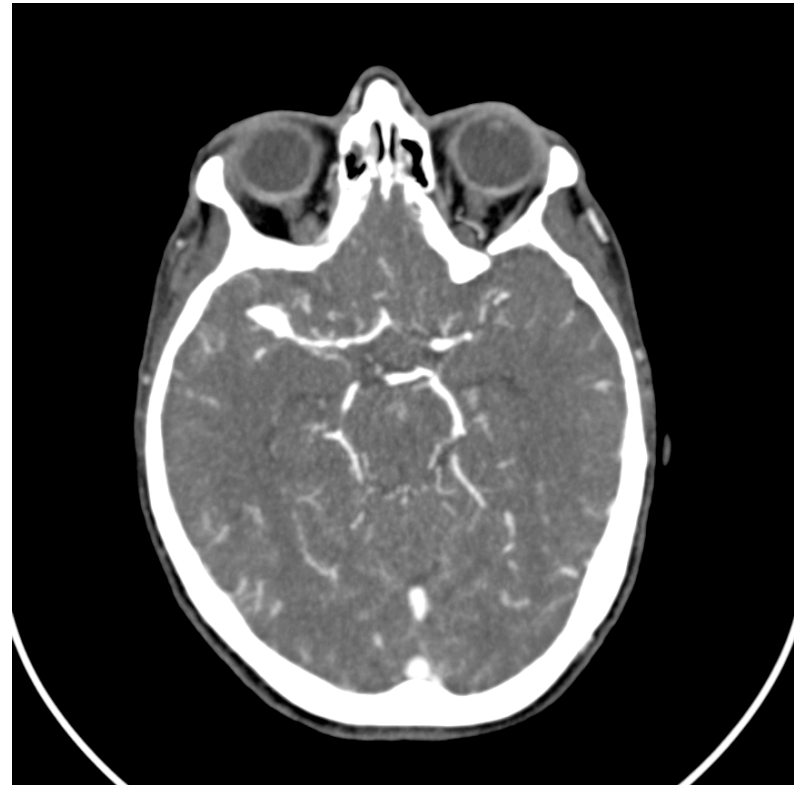
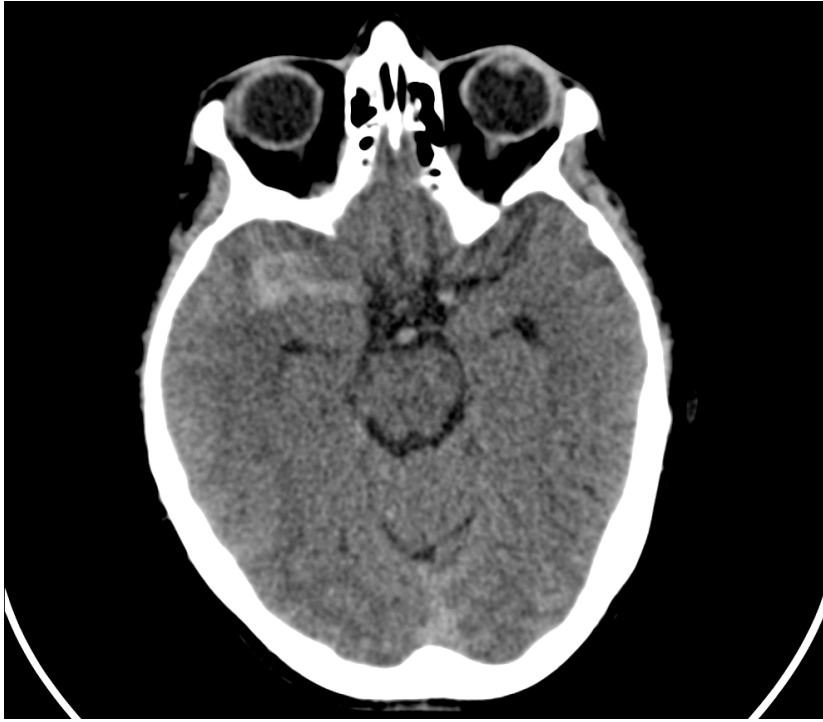- Aneurismas
- MAVs
- Fístulas Durais

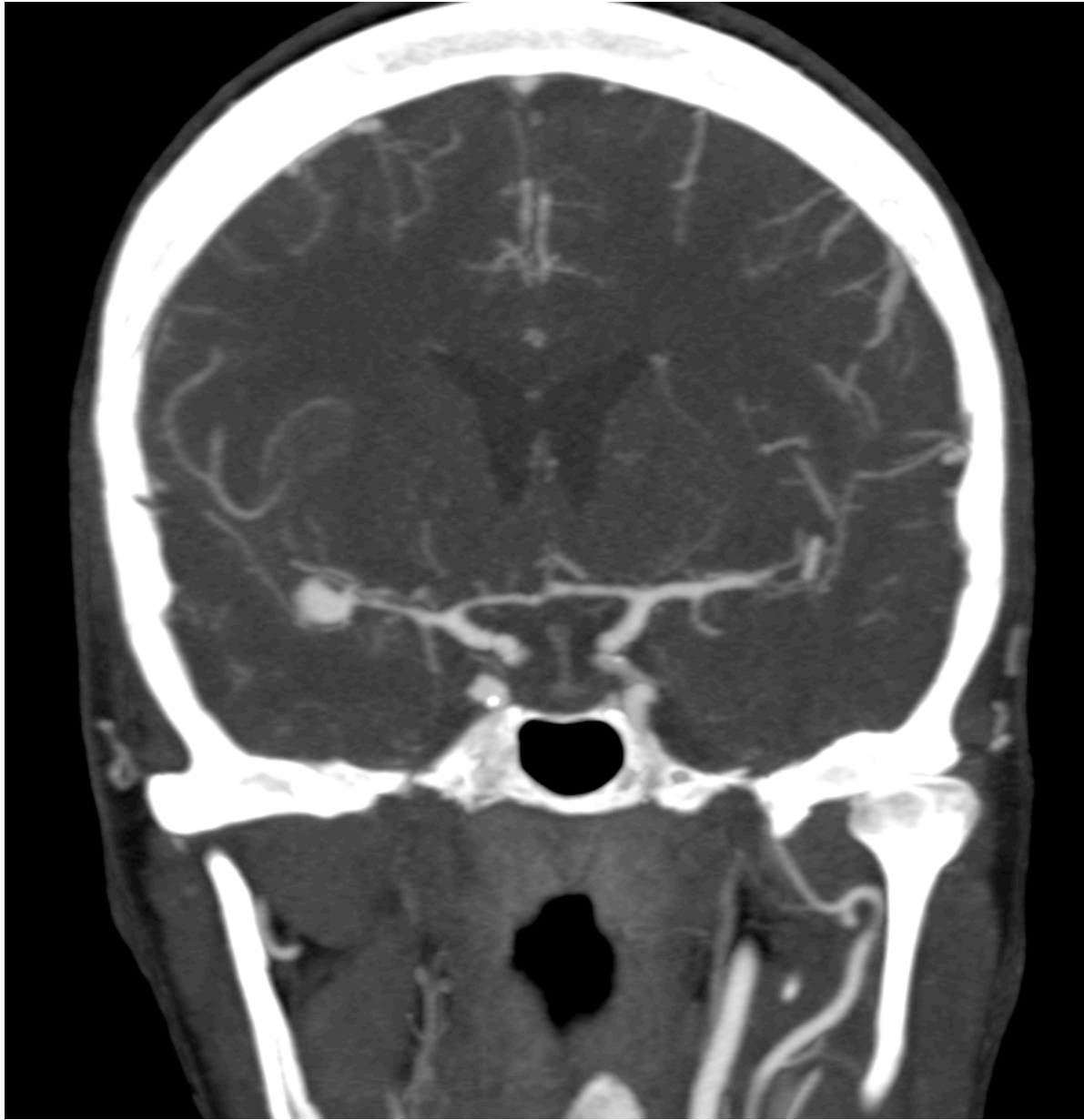


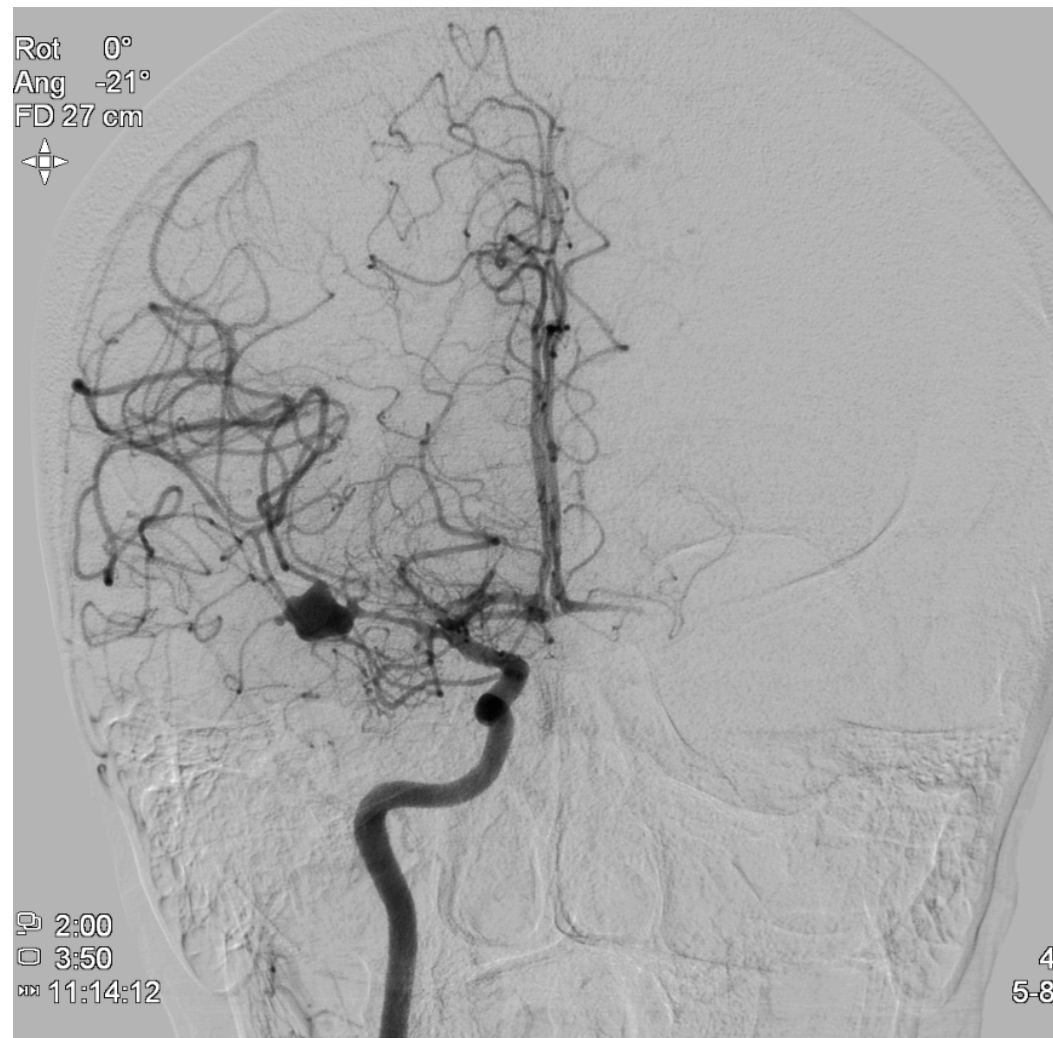
# Aneurismas

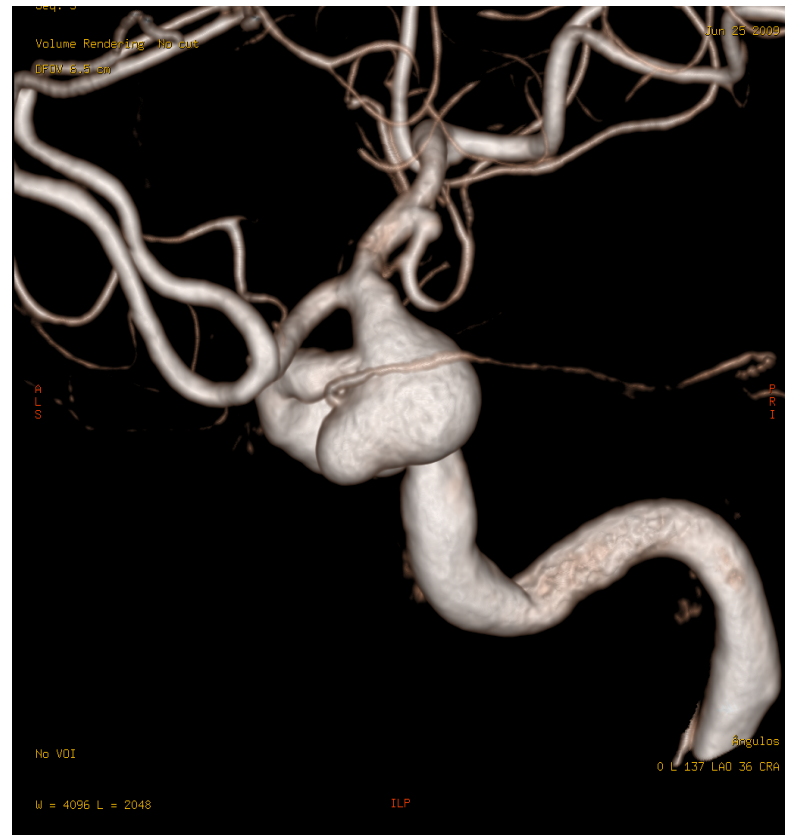
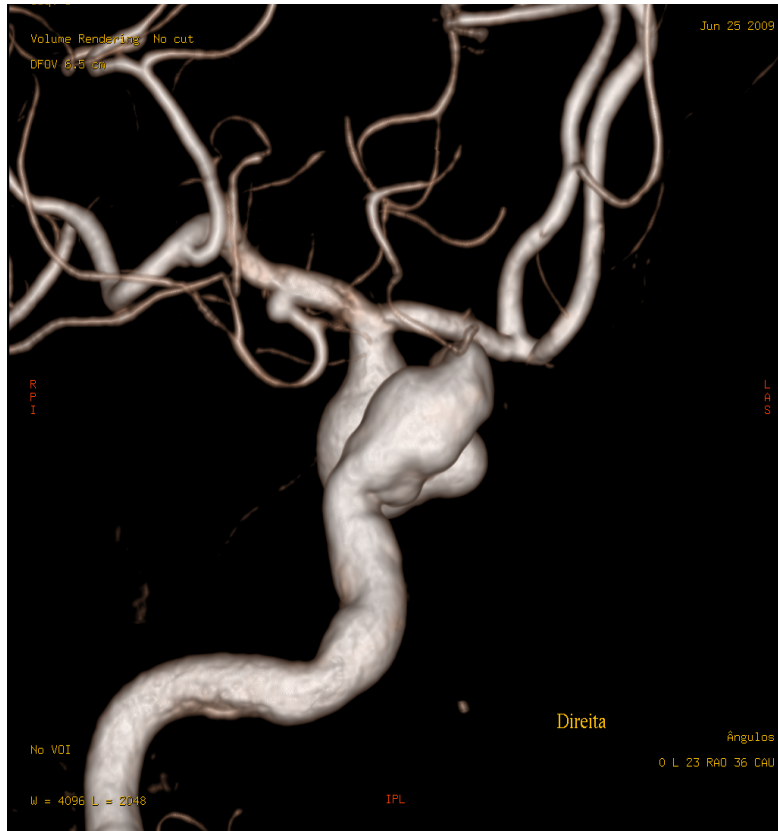
- Dilatação da luz arterial
  - Sacular (95%) ou fusiforme
- Localização e relação com os vasos
- Avaliar dimensão, colo e direcionamento
- Vasoespasmó associado

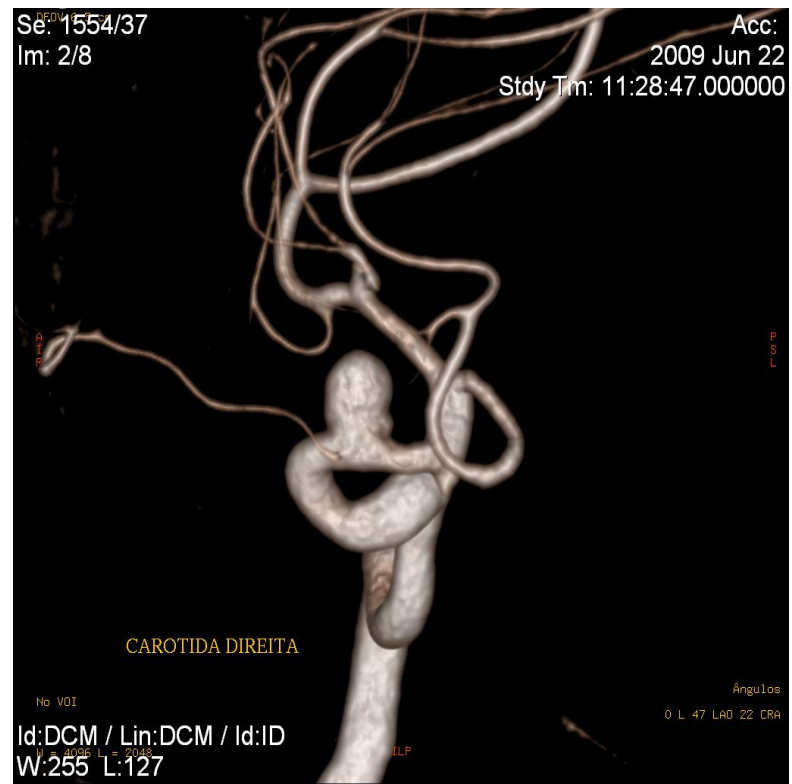
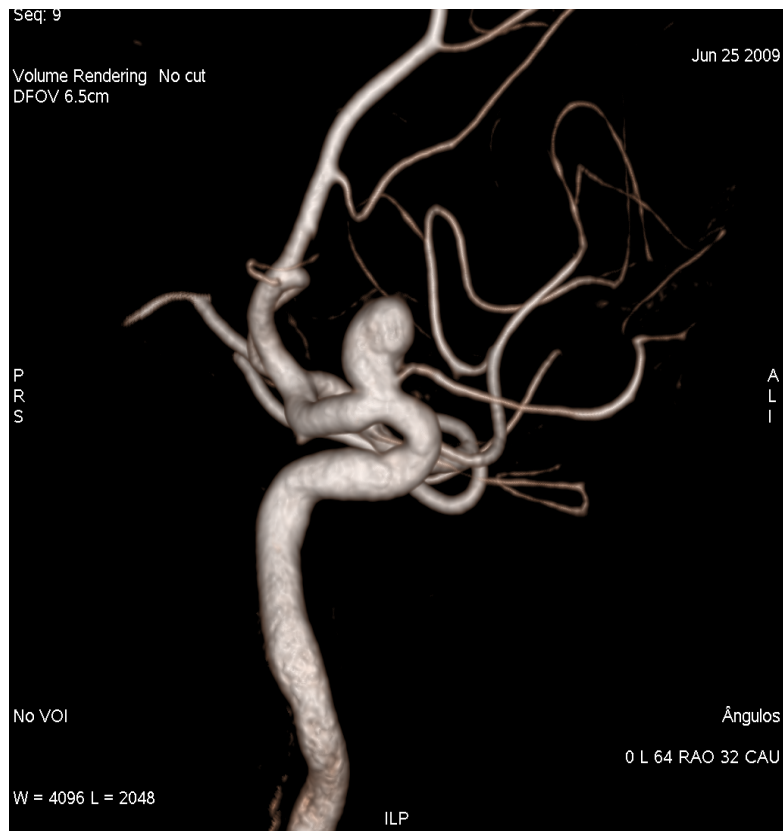



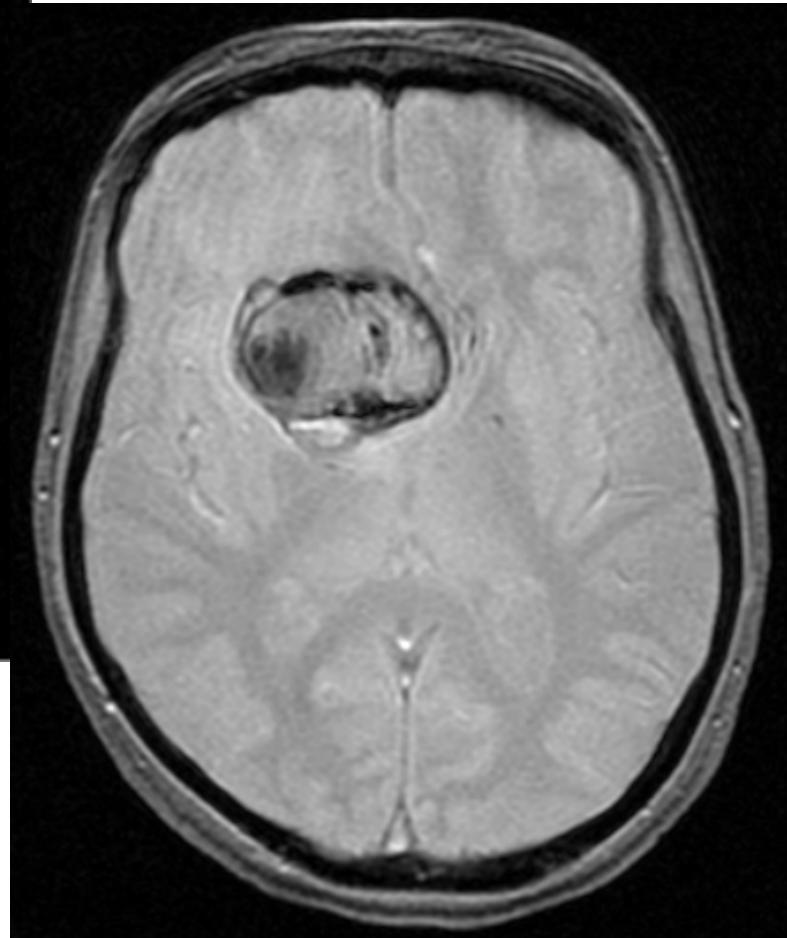
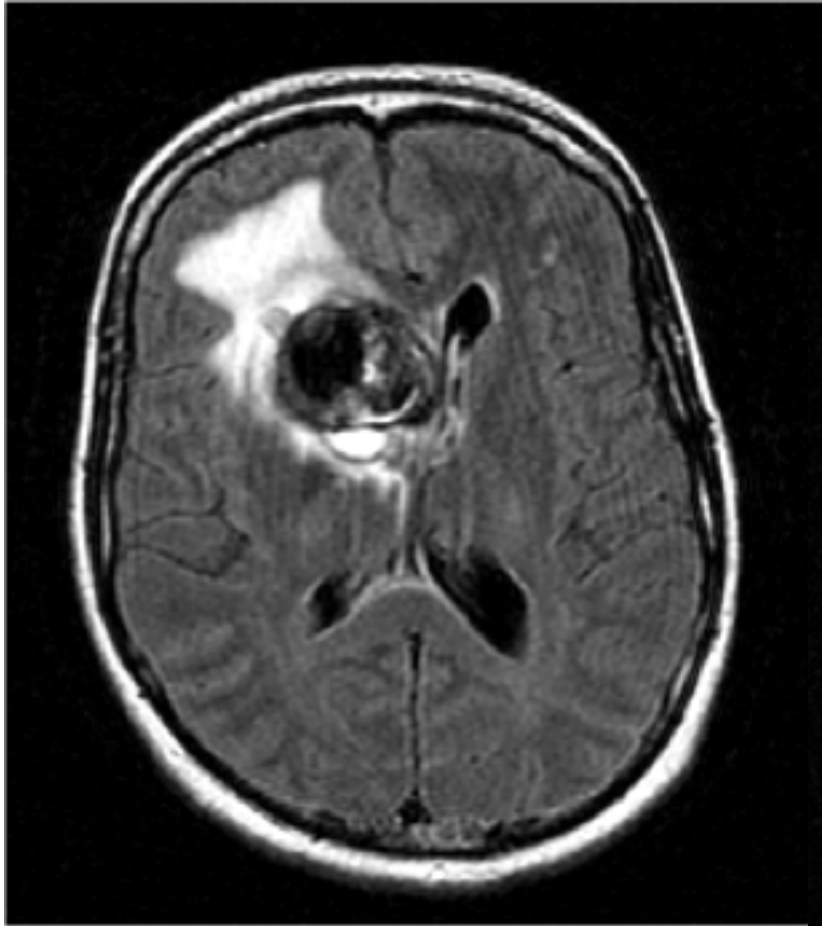




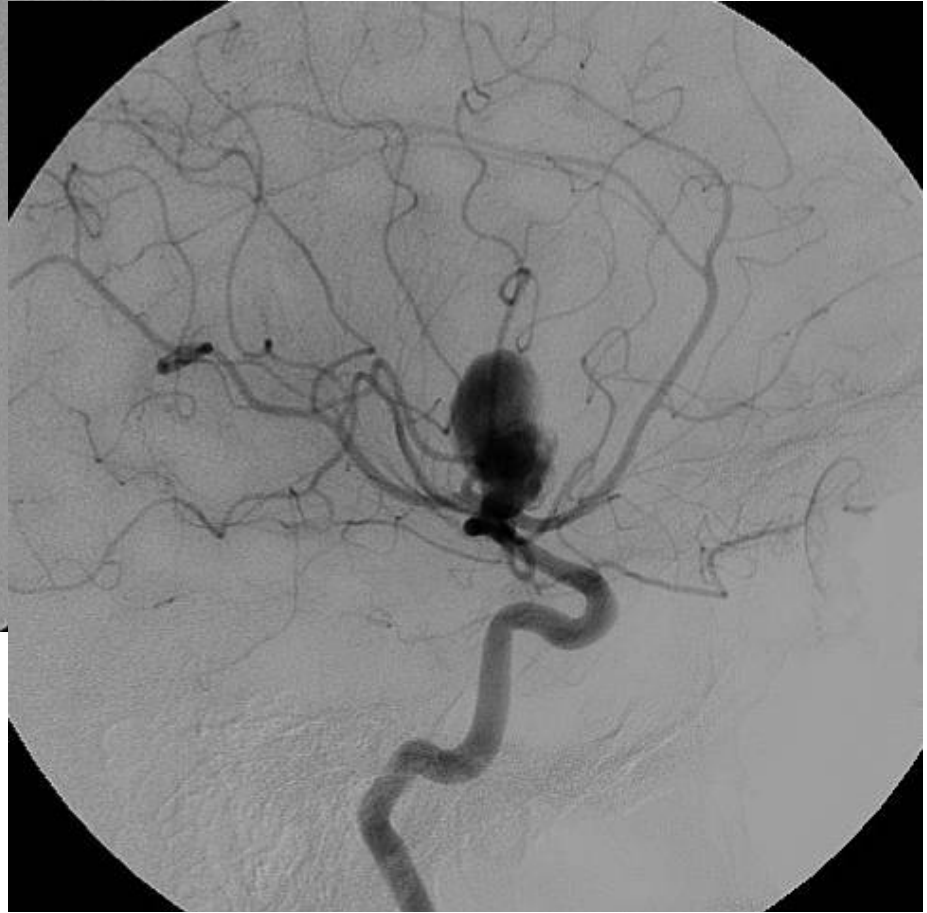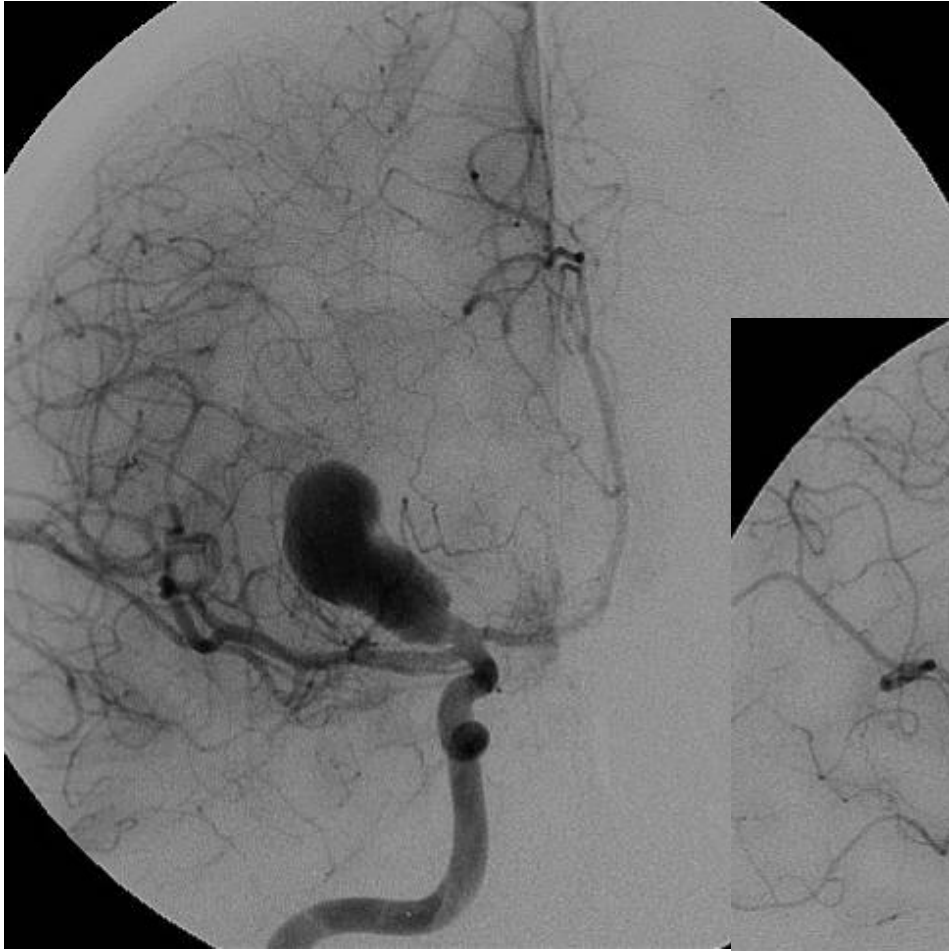


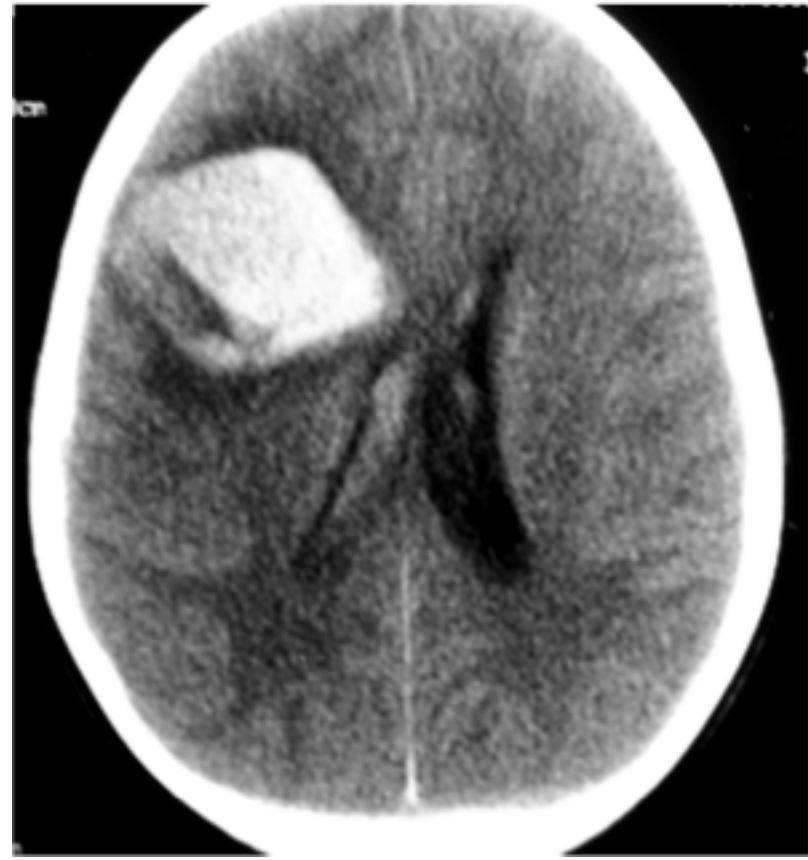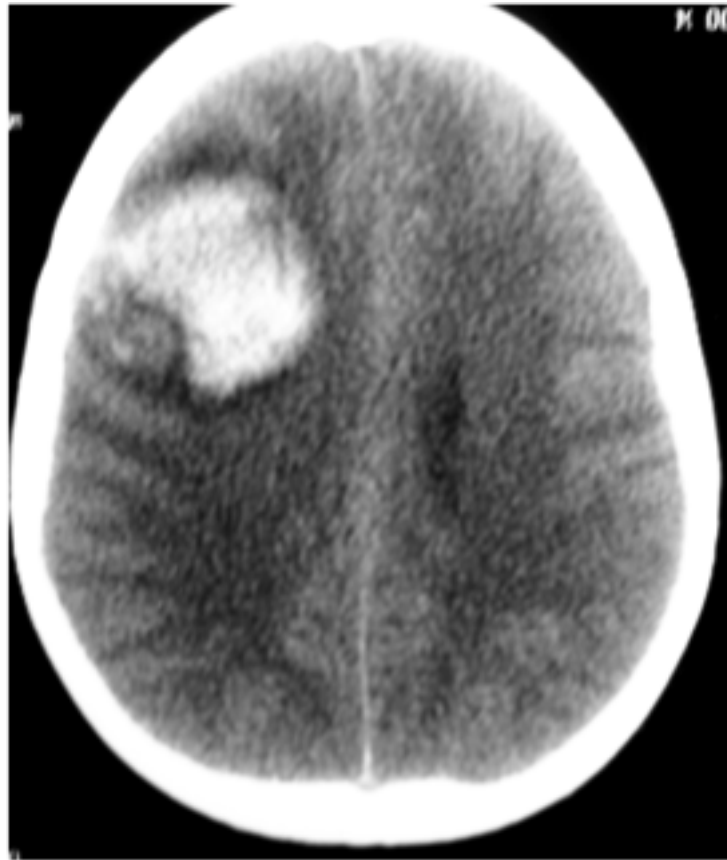





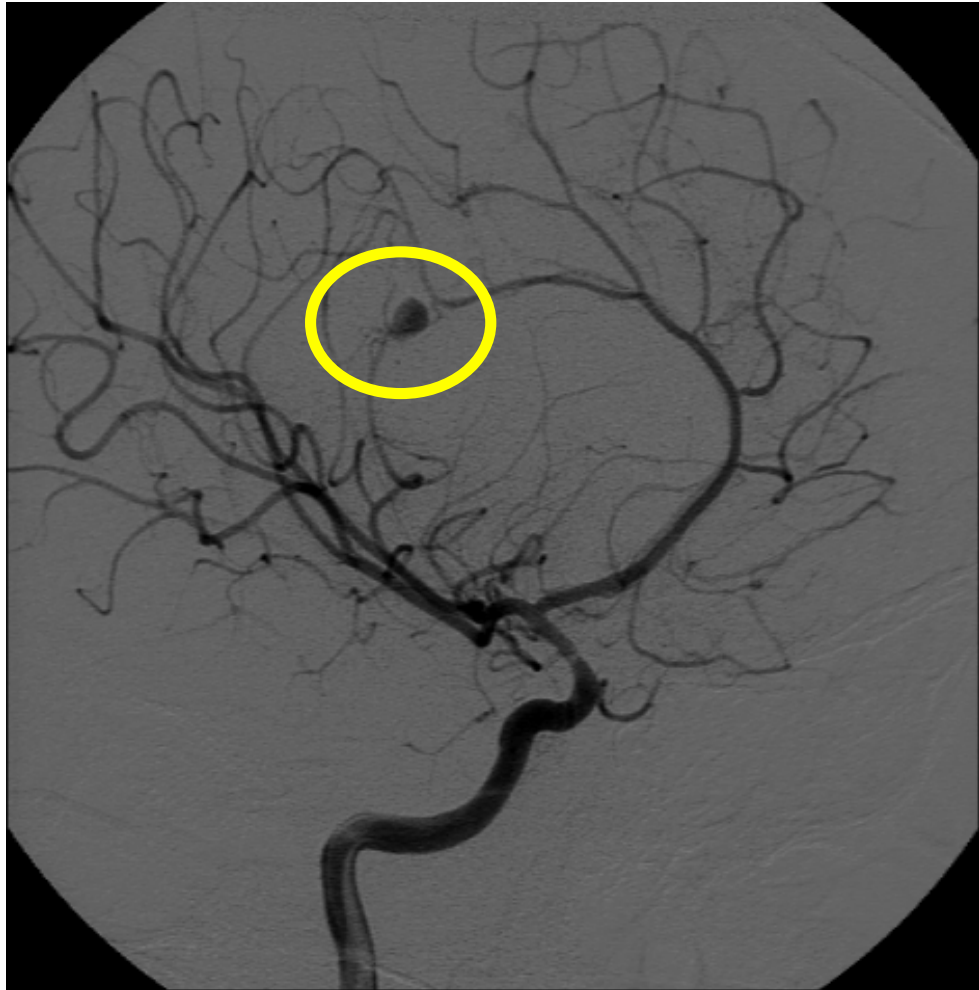
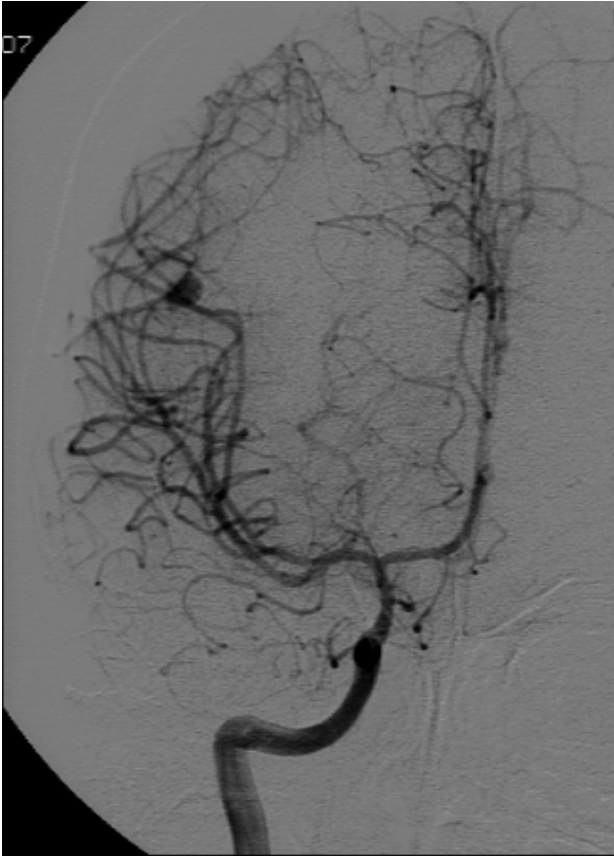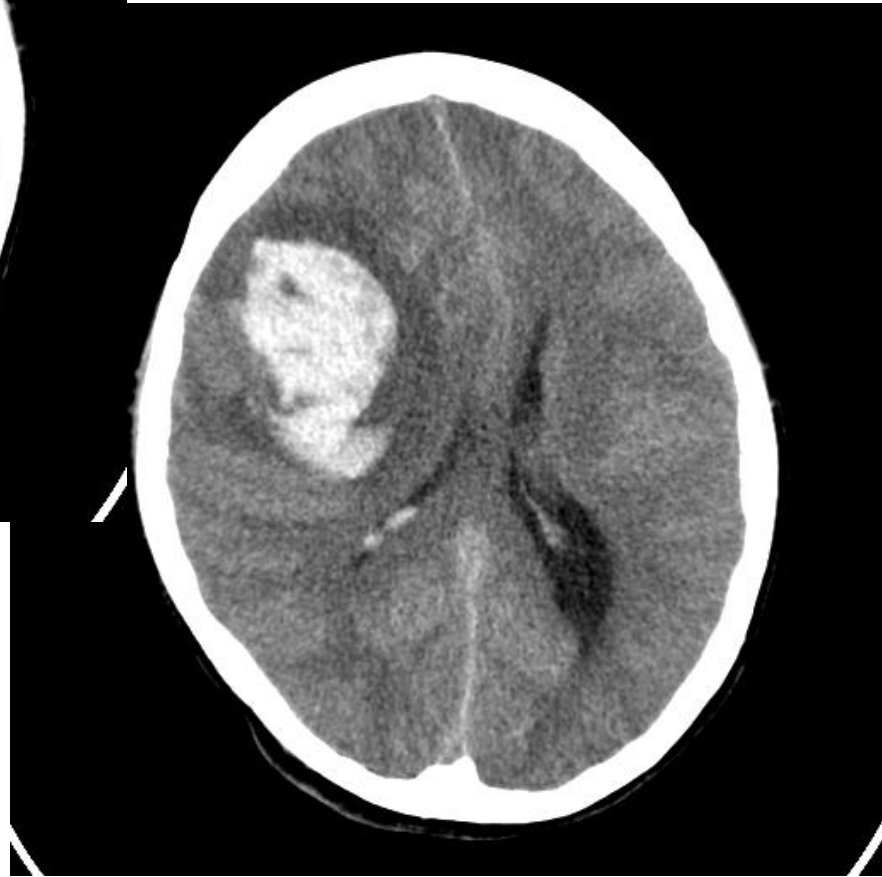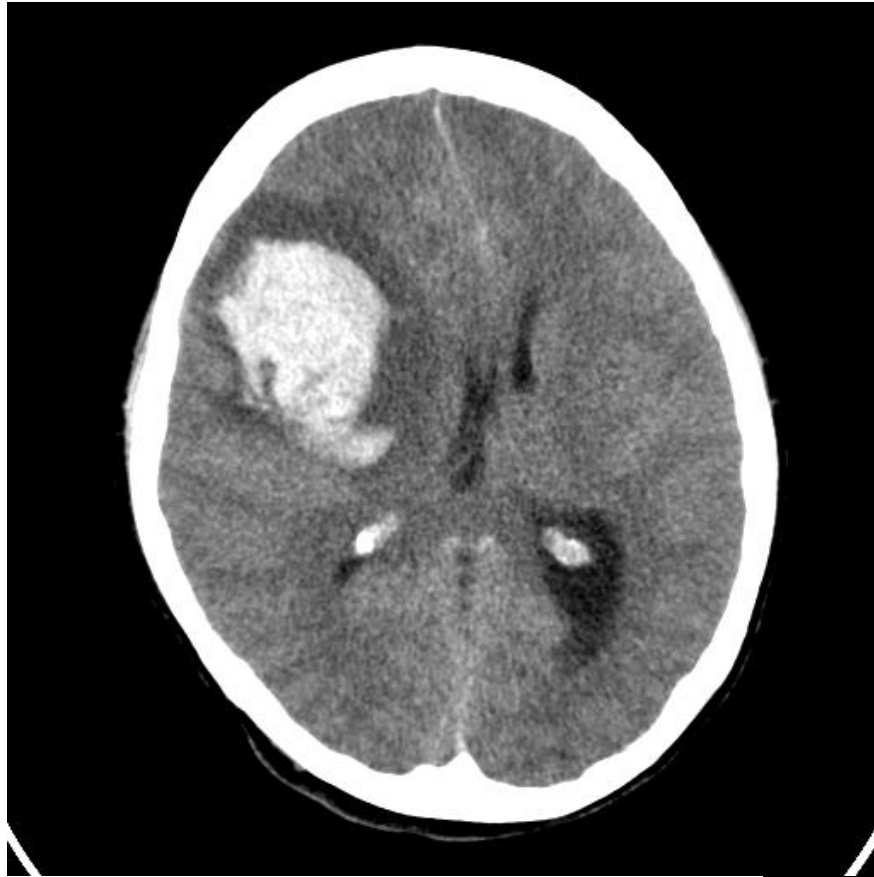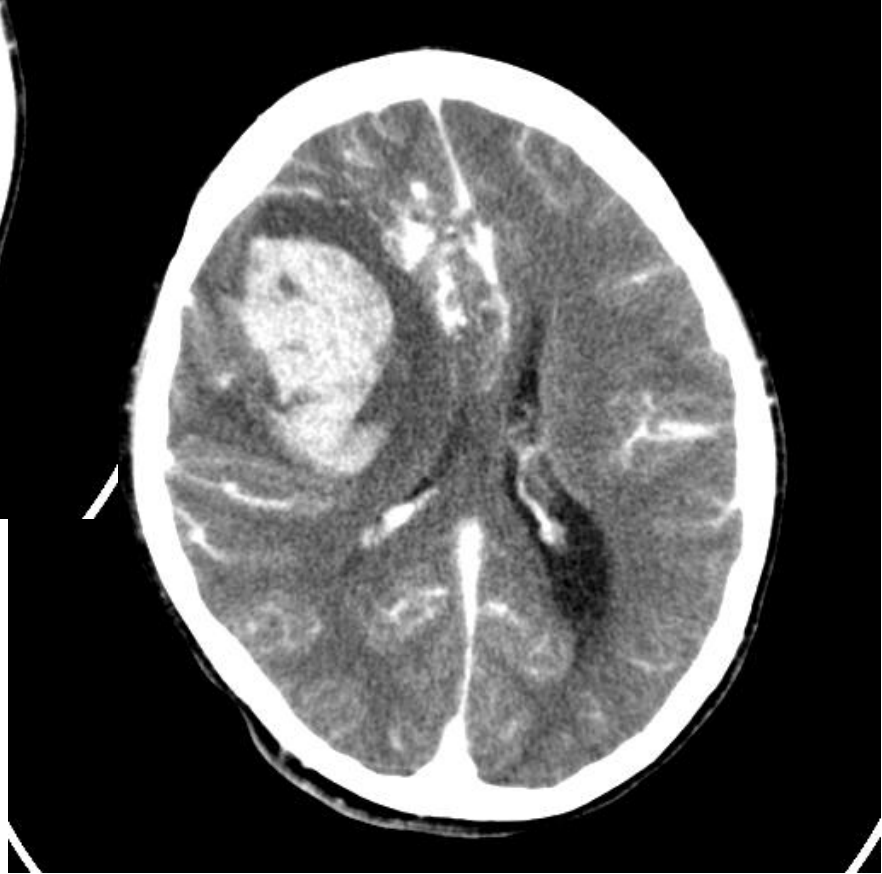
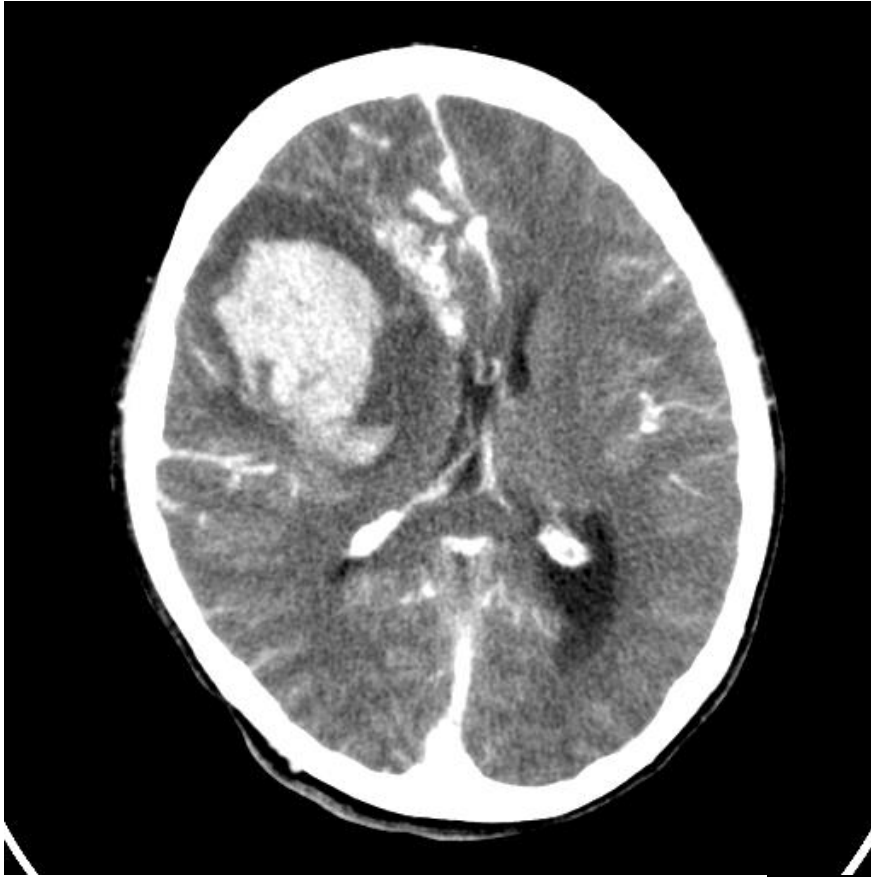Edema



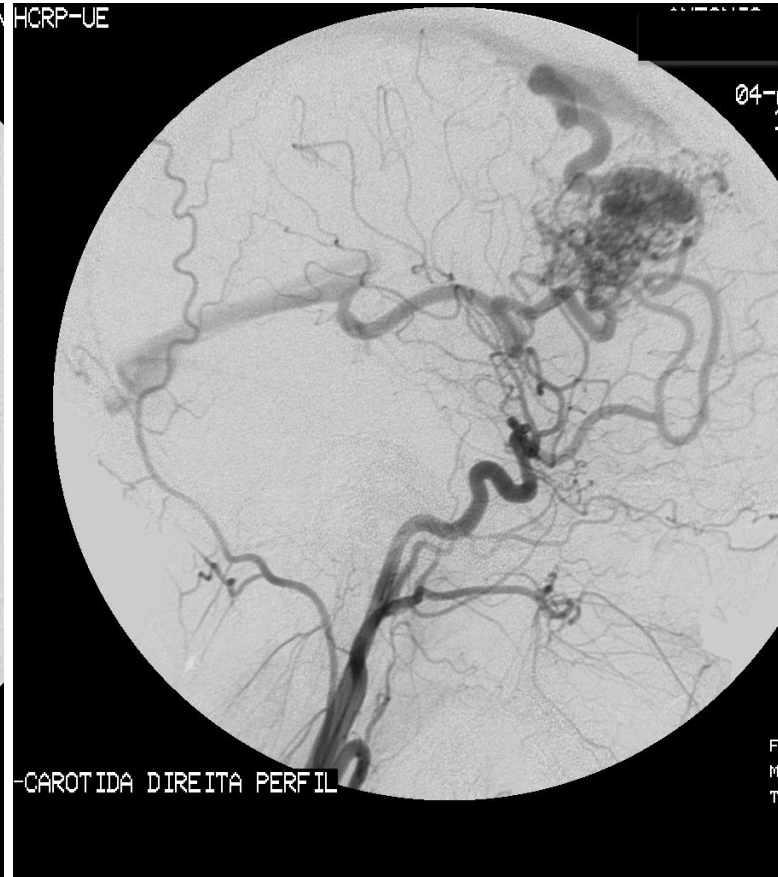
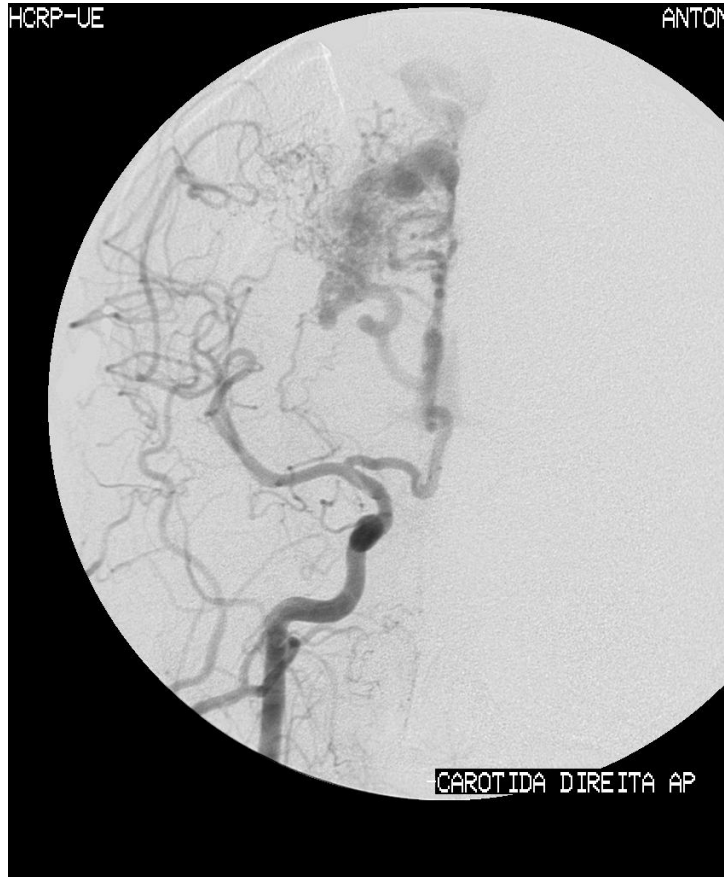

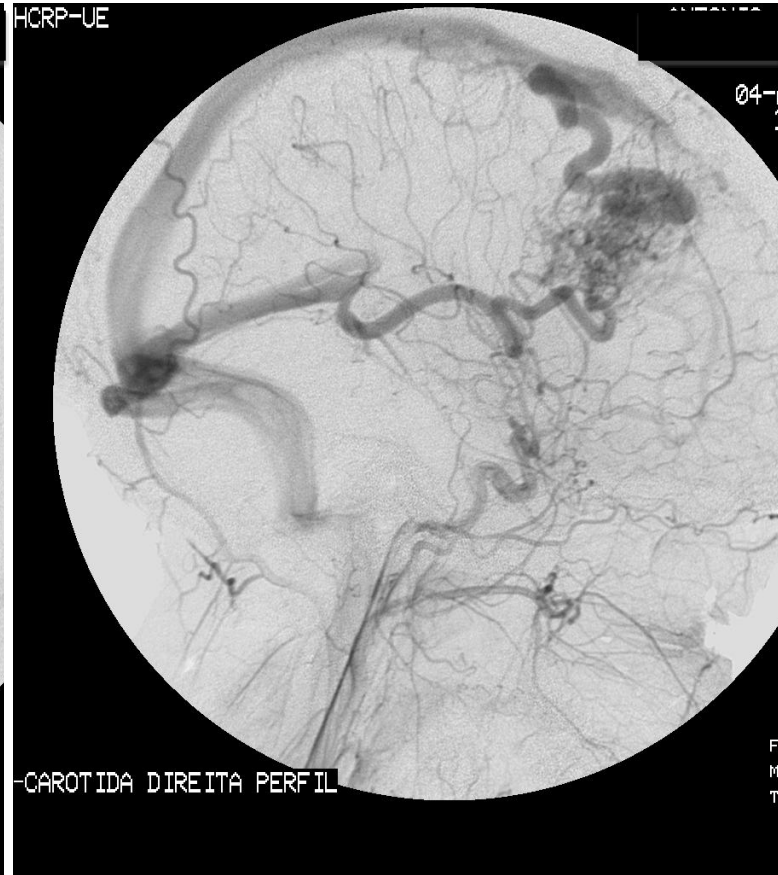

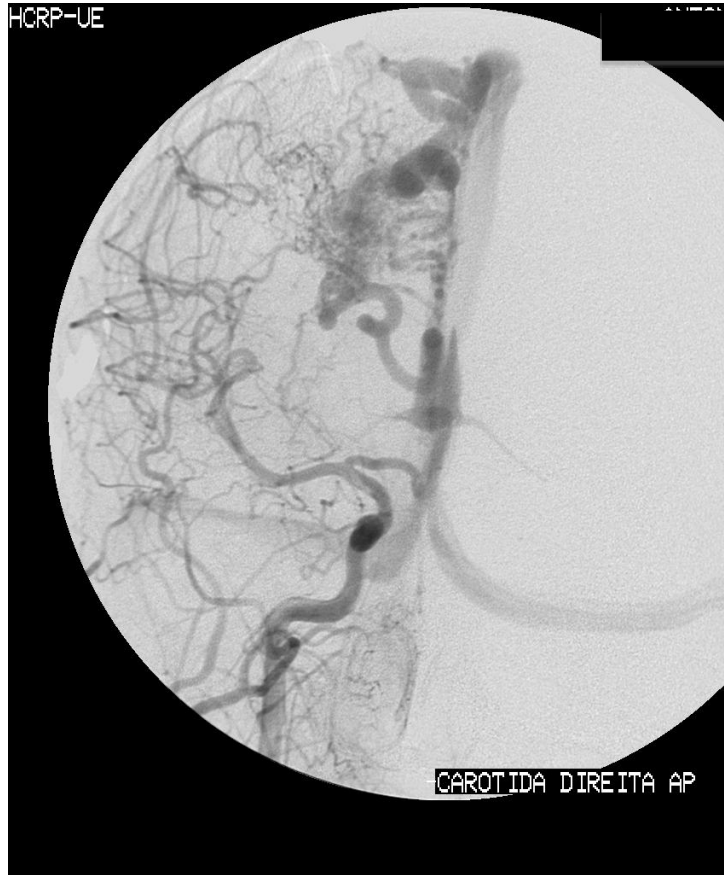


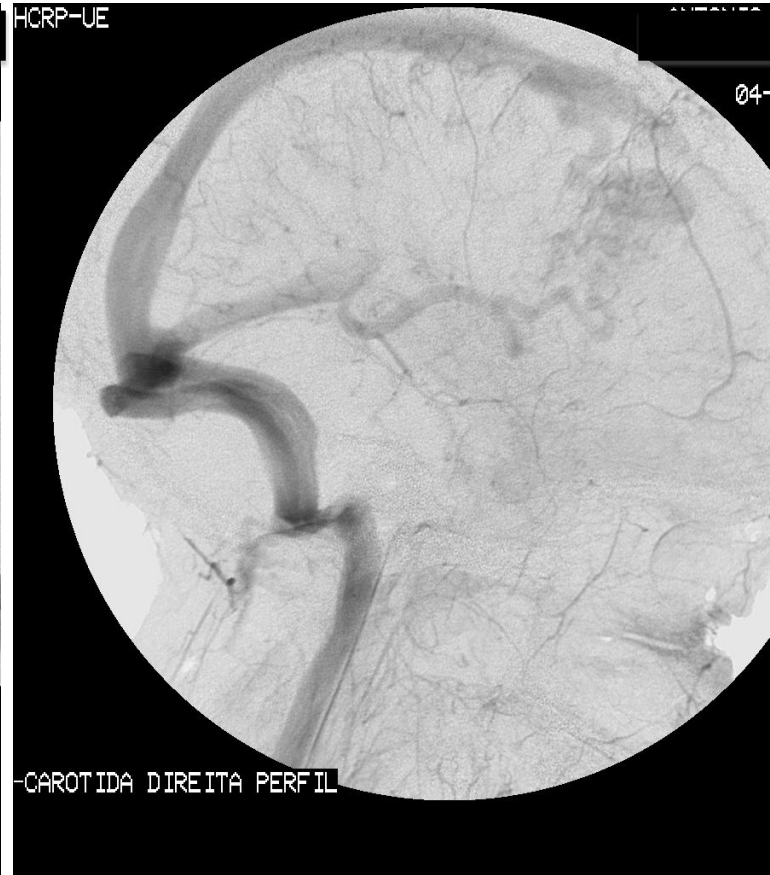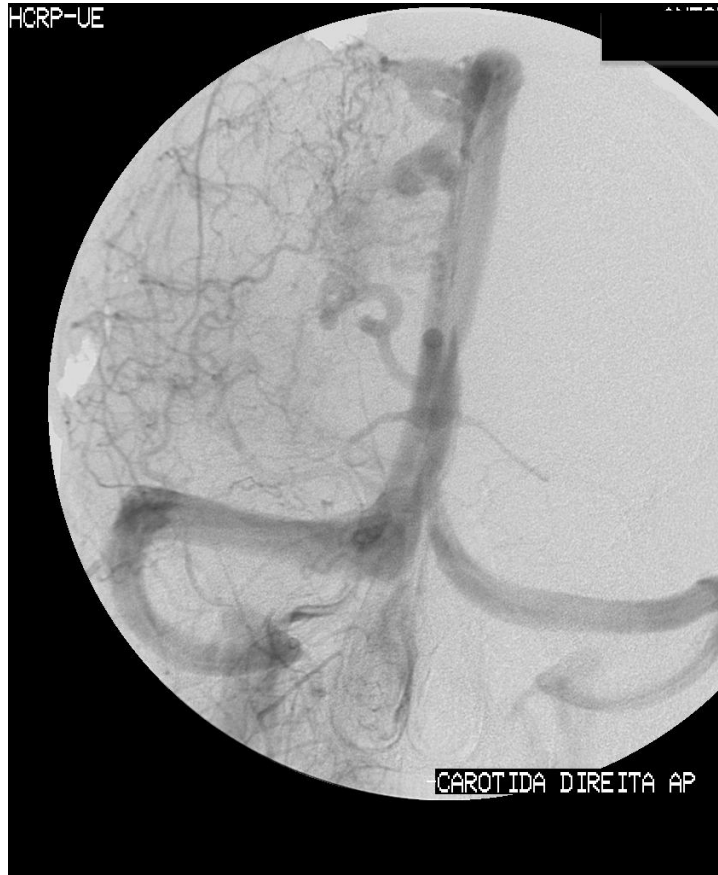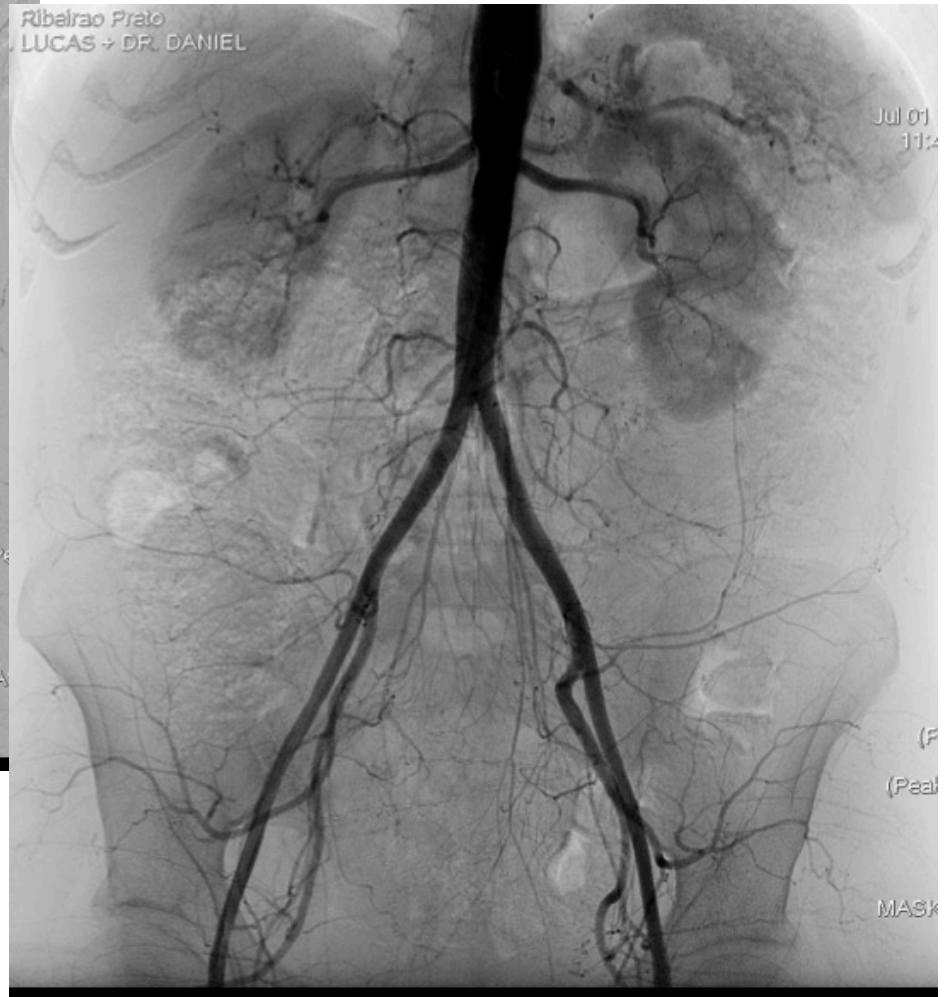




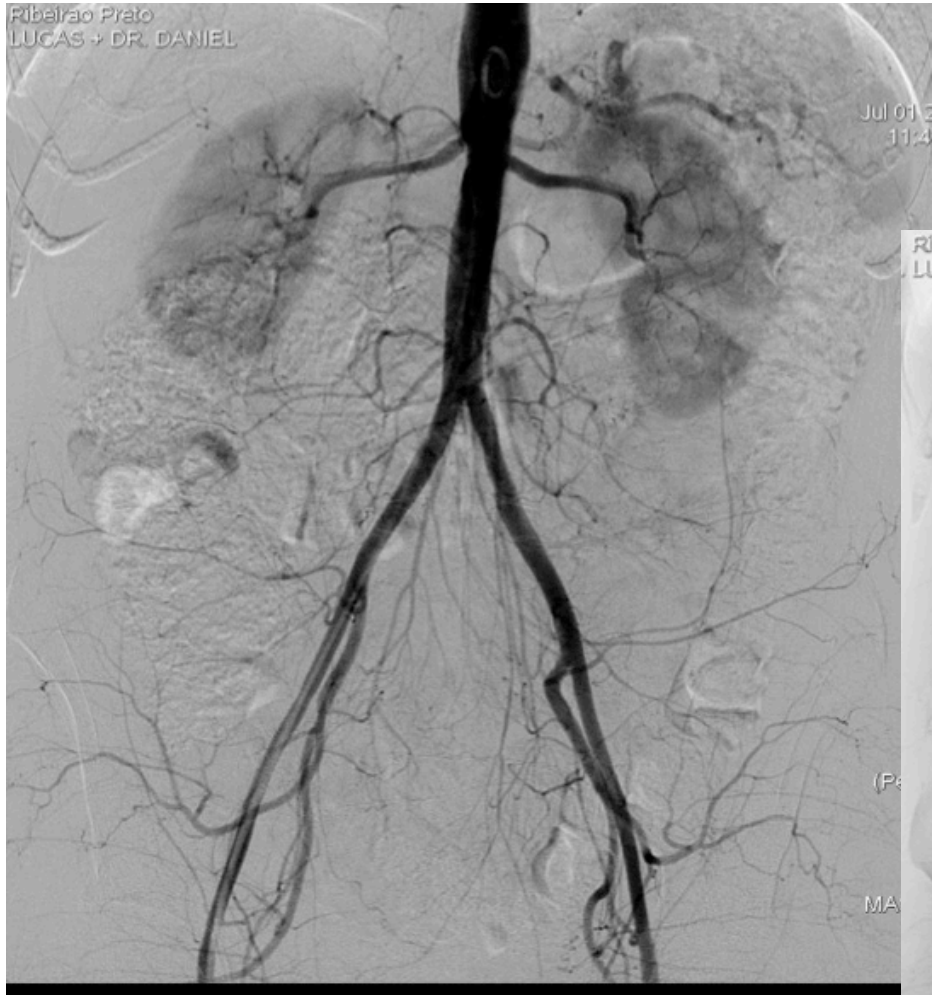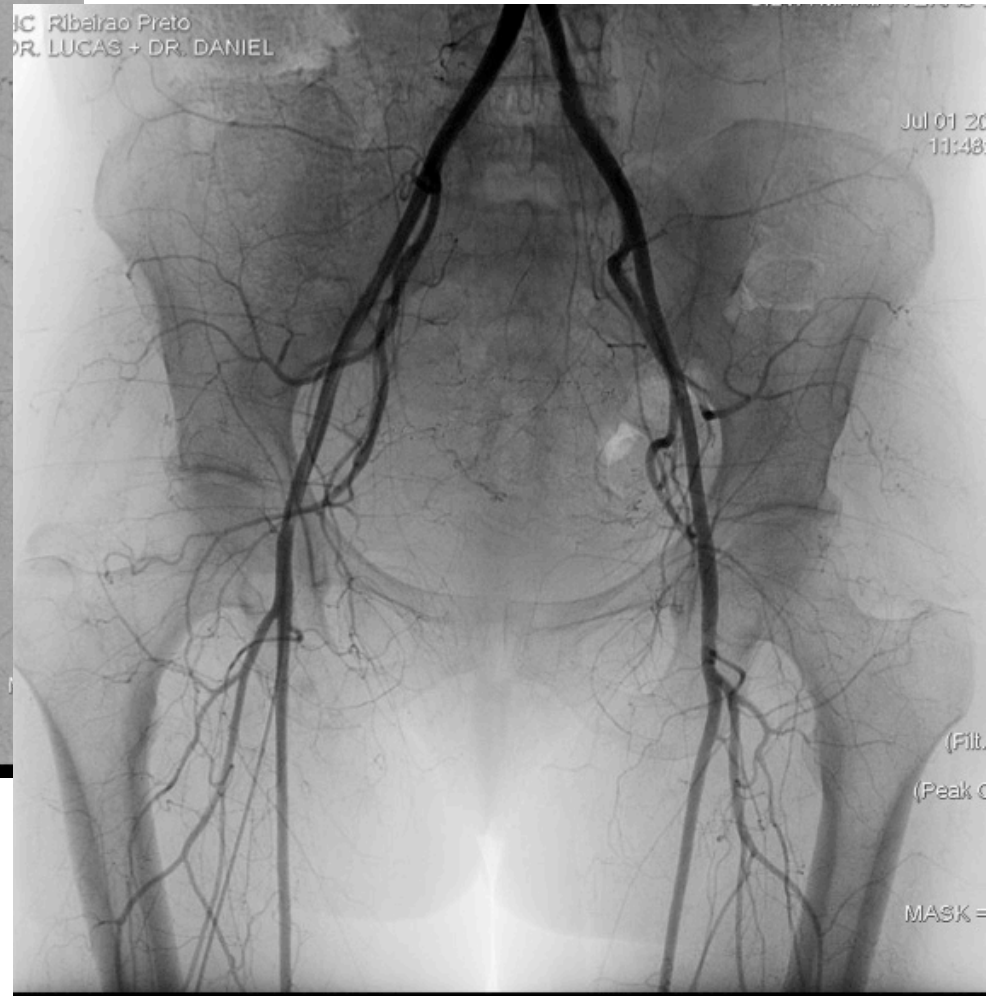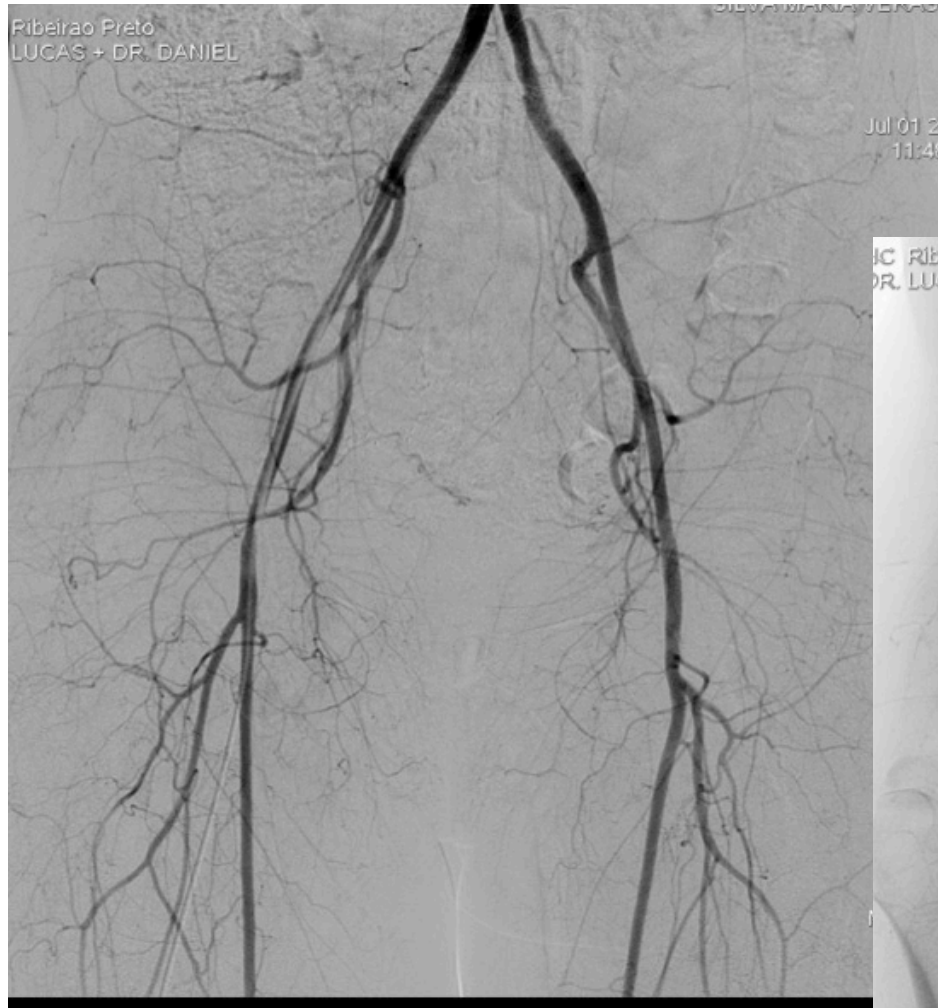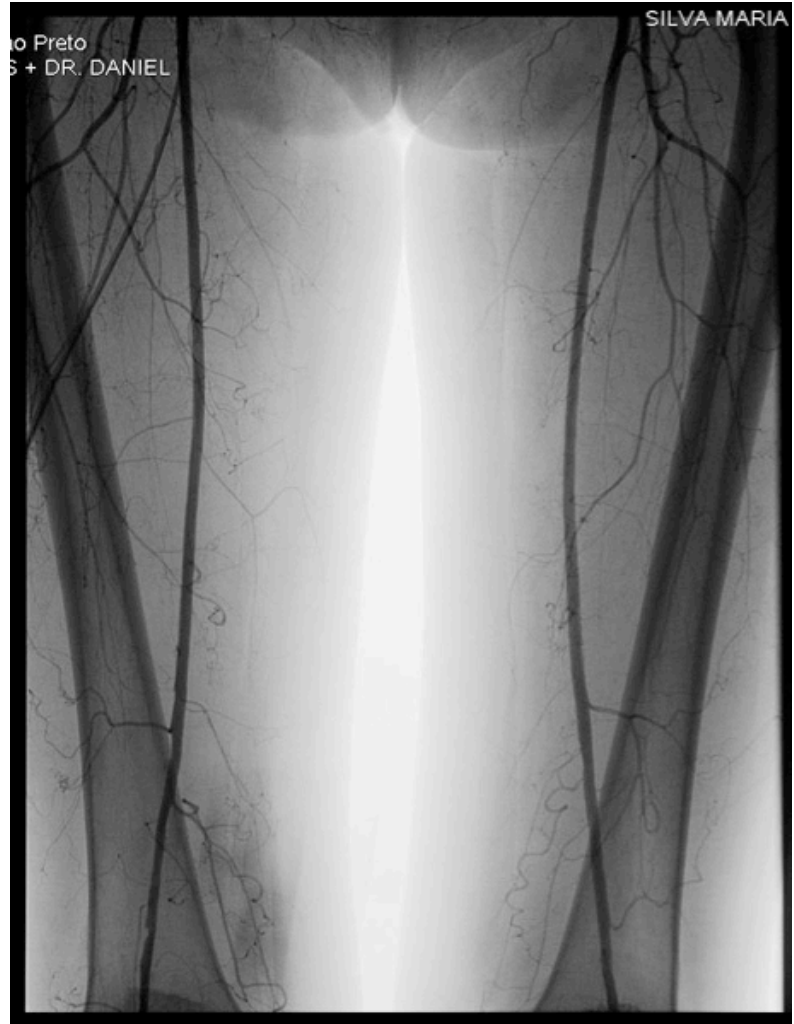







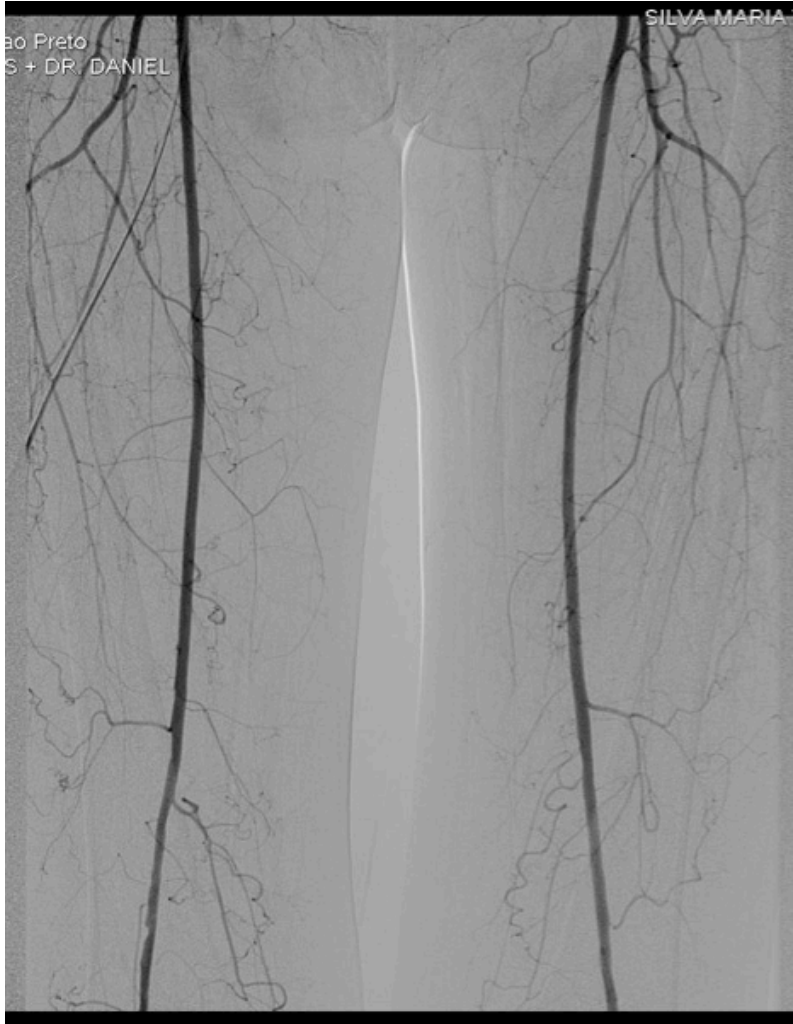




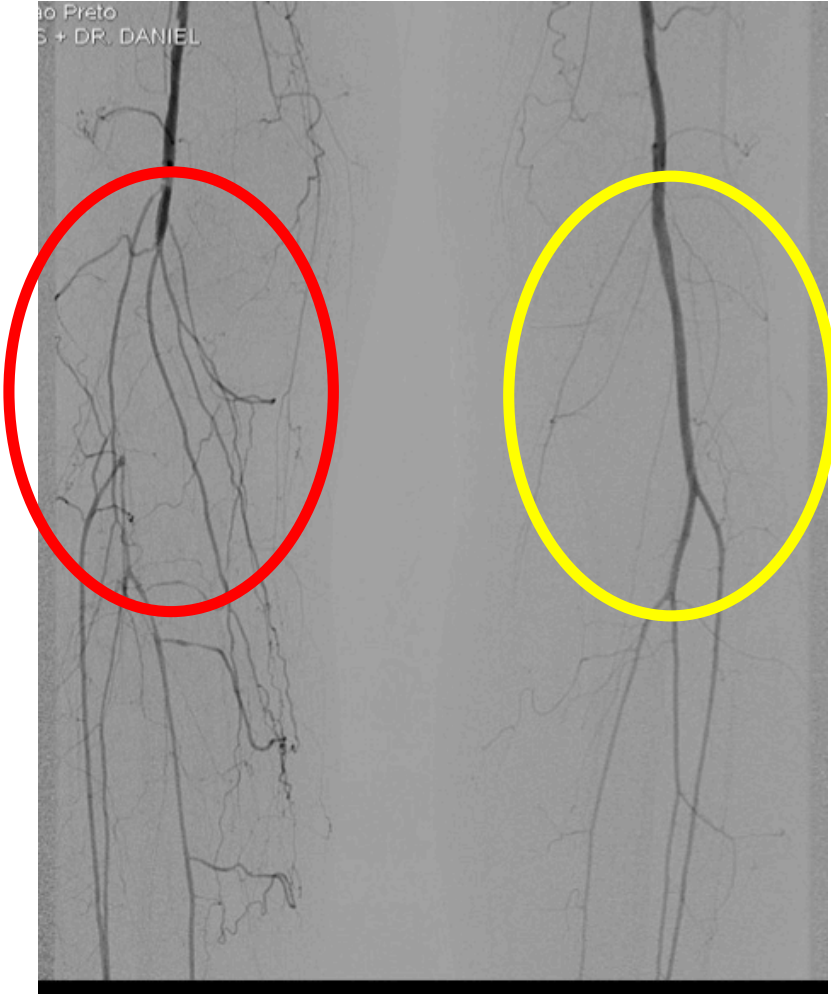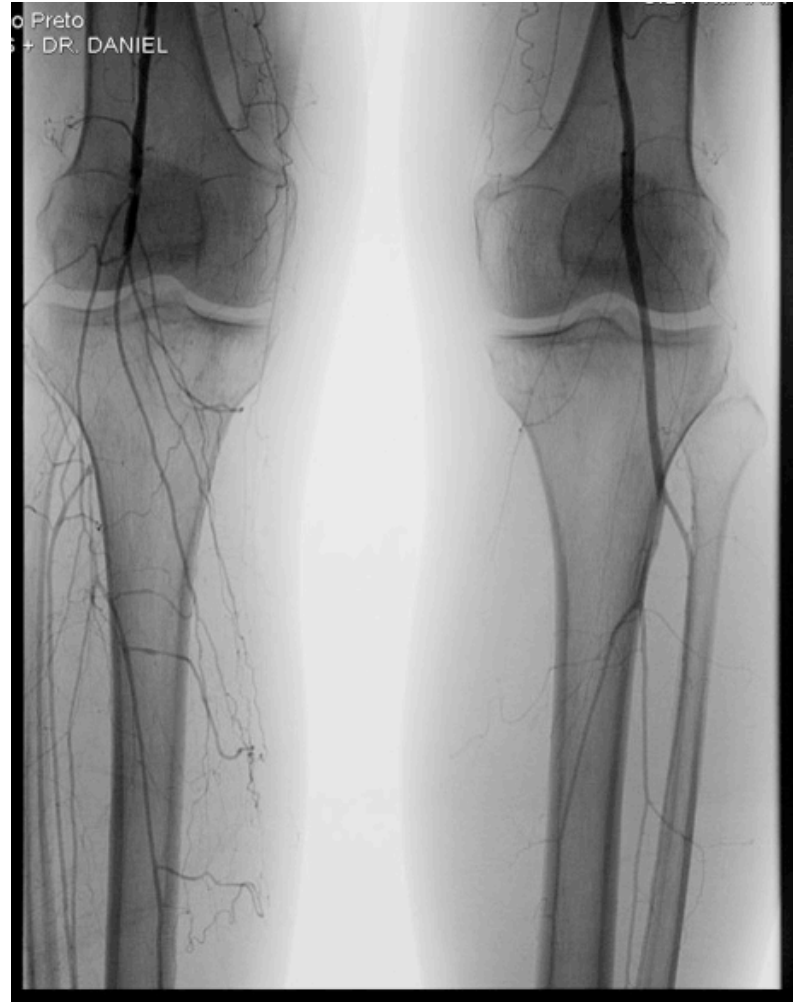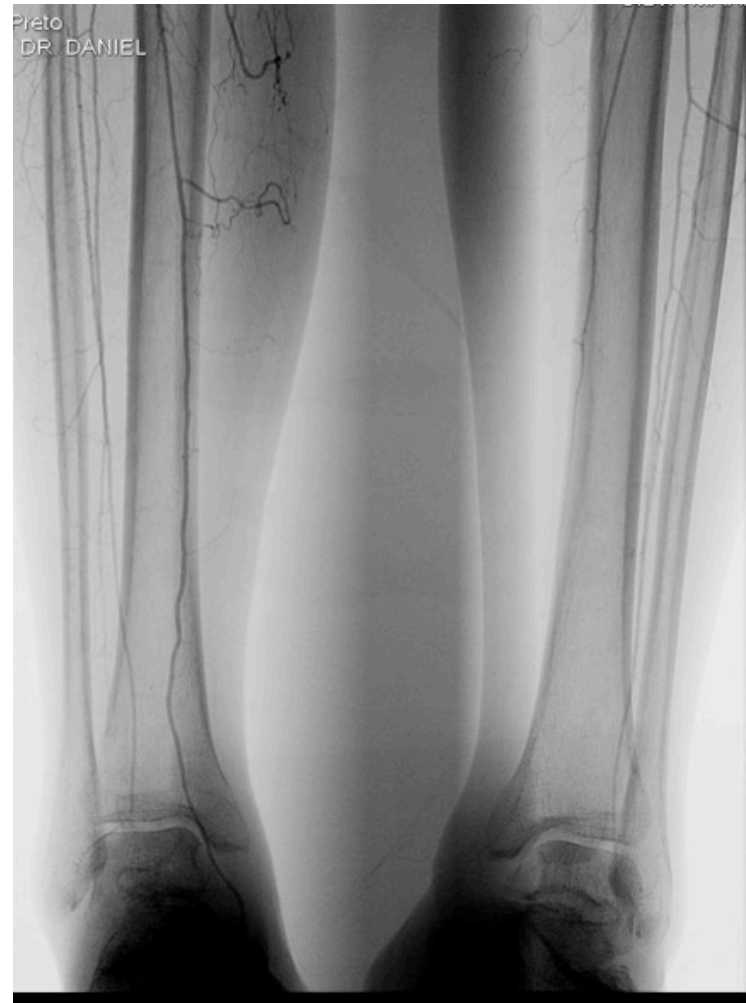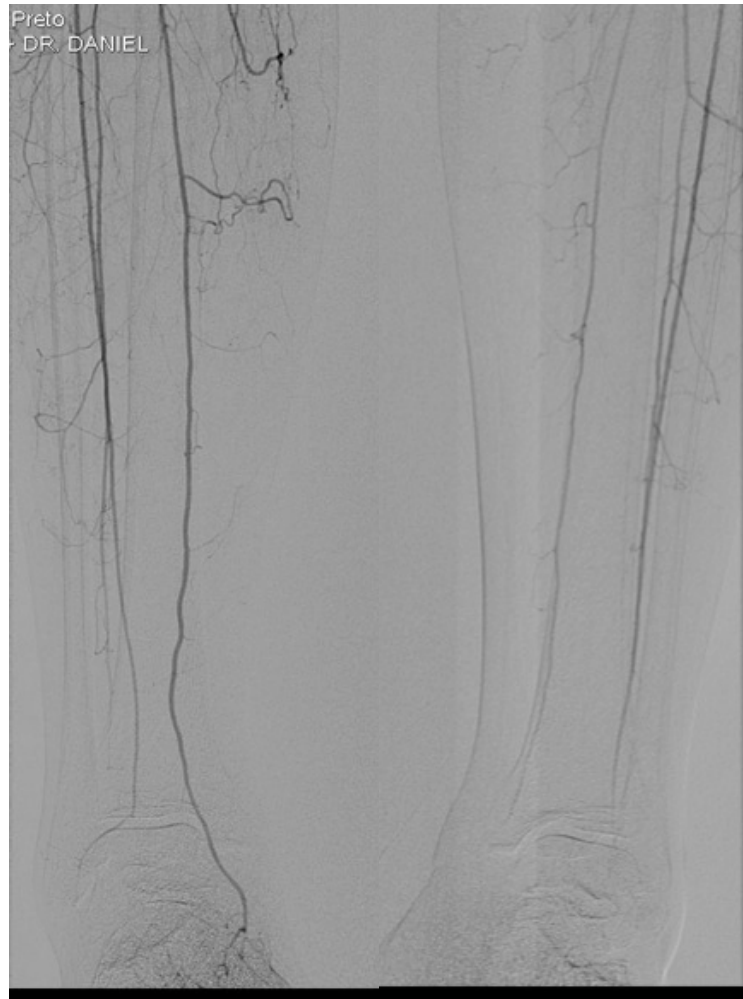


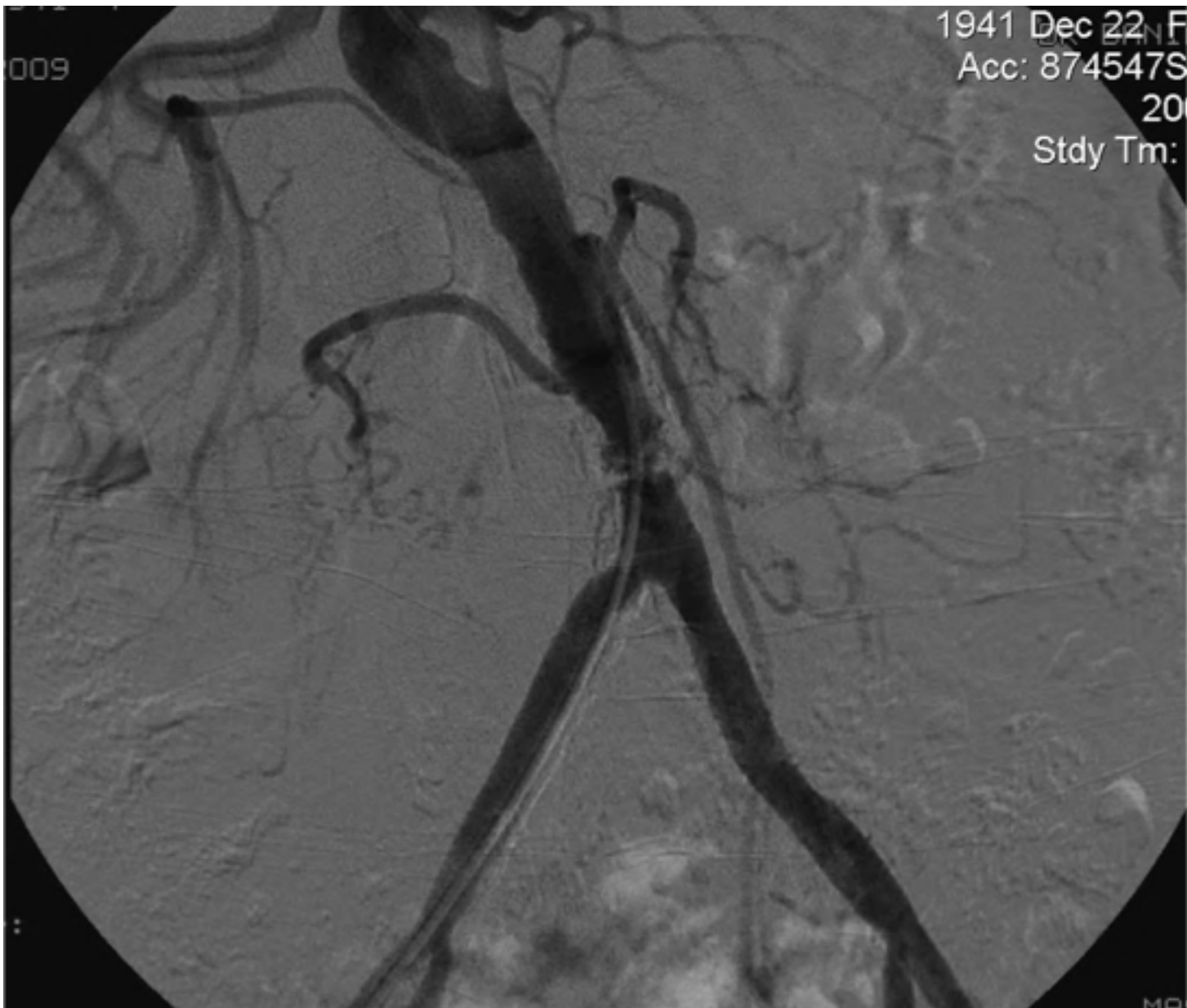ao Preto  
S + DR. DANIEL



o Preto  
S + DR. DANIEL







1941 Dec 22 F

Acc: 874547S

20

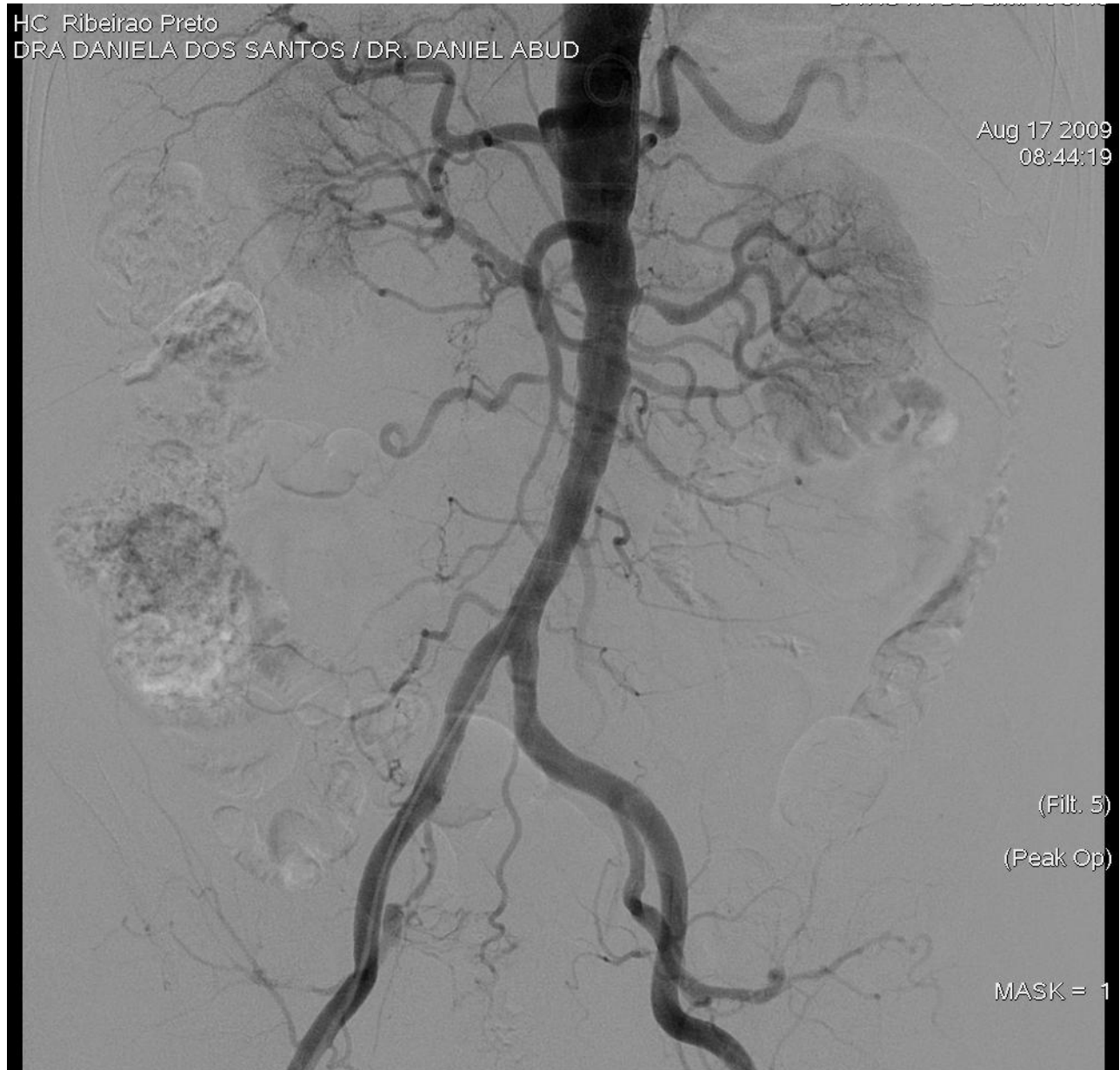
Study Tm:

009

MD

HC Ribeirao Preto  
DRA DANIELA DOS SANTOS / DR. DANIEL ABUD

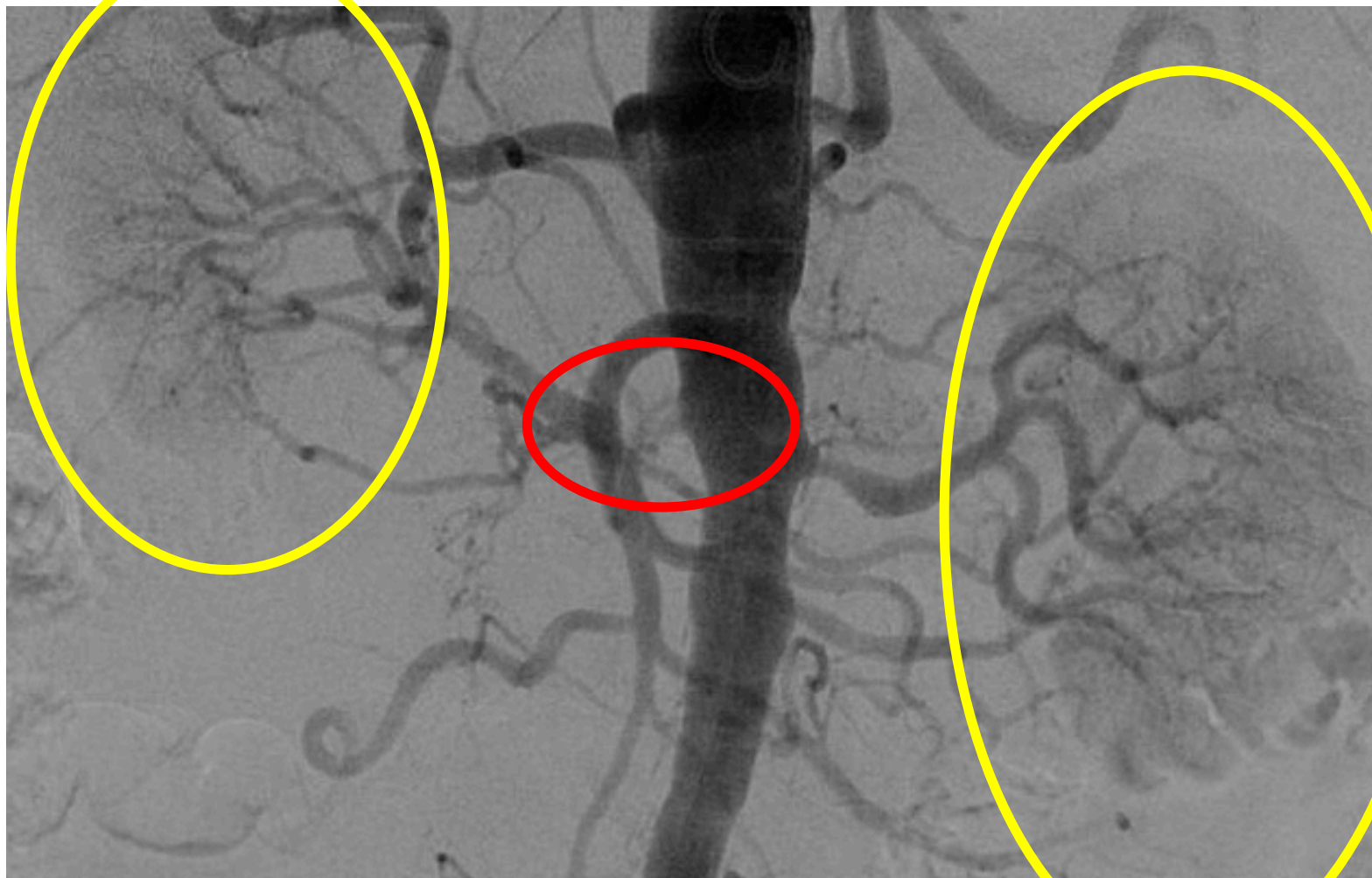Aug 17 2009  
08:44:19



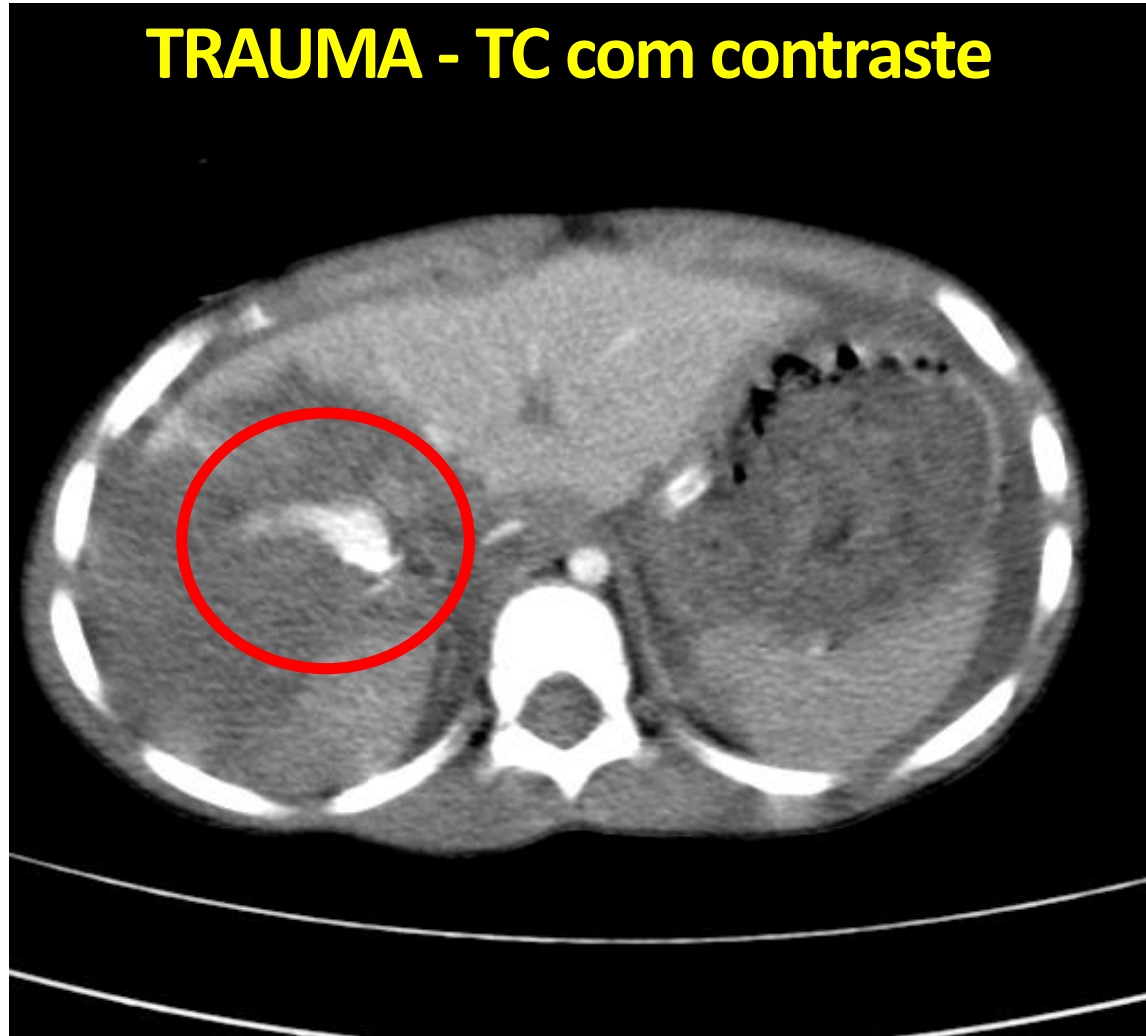
(Filt. 5)

(Peak Op)

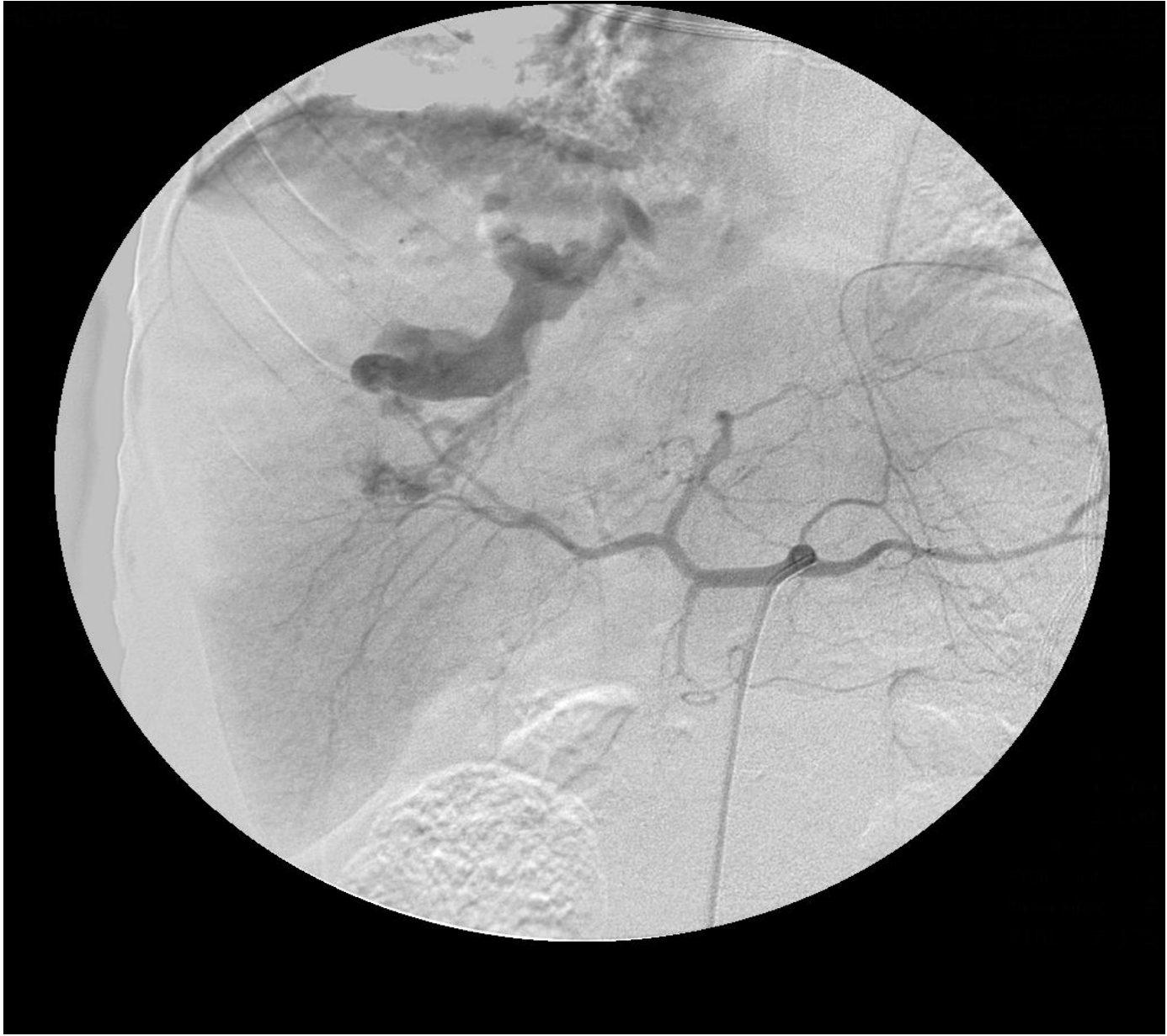
MASK = 1



**TRAUMA - TC com contraste**

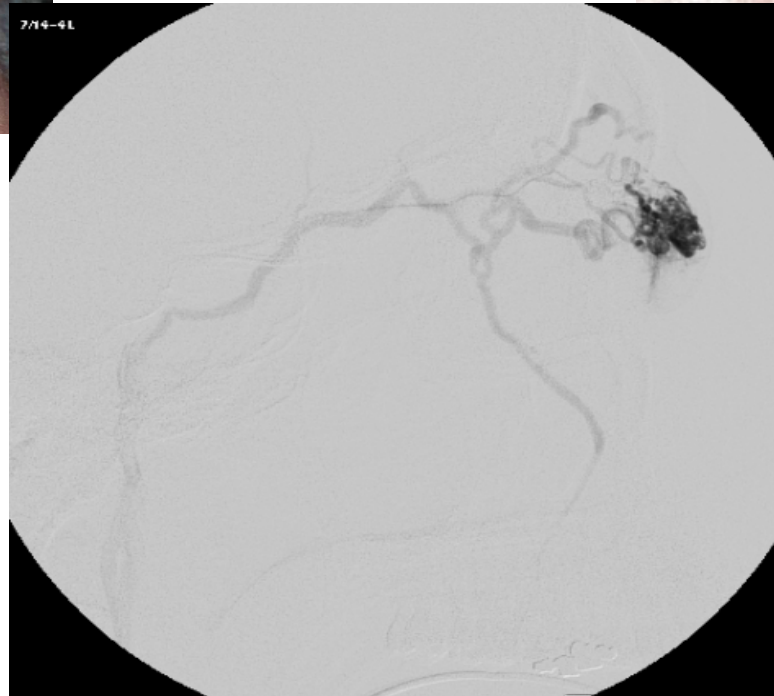
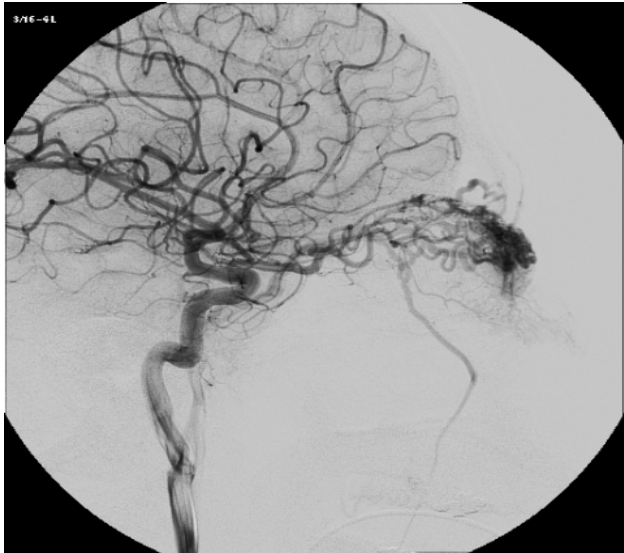
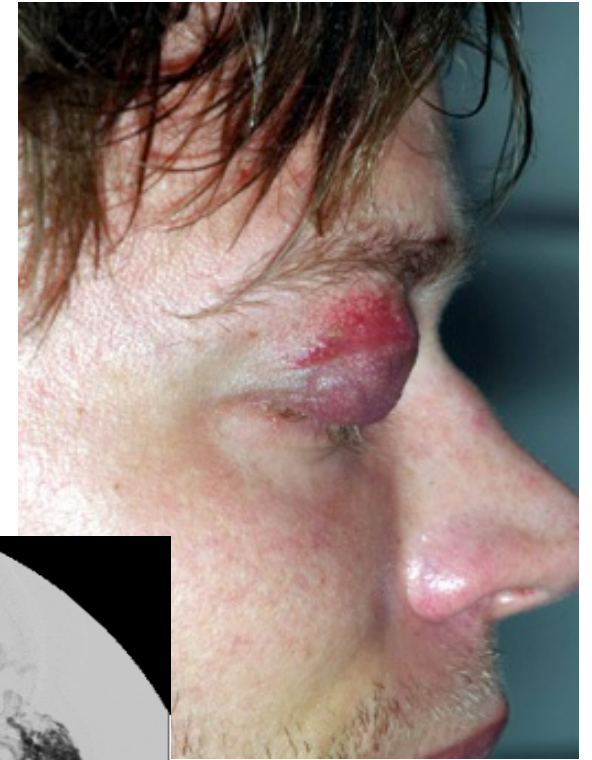
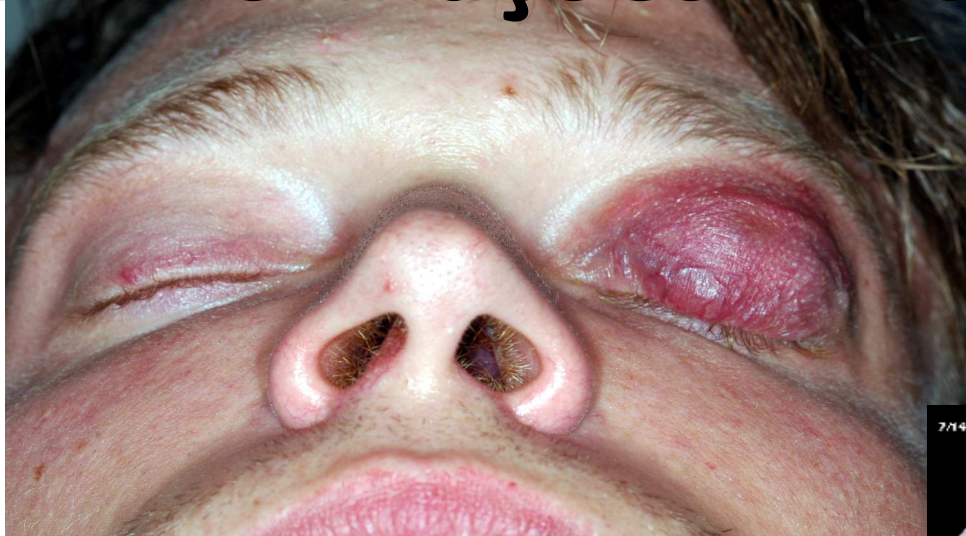





# Malformações Vasculares

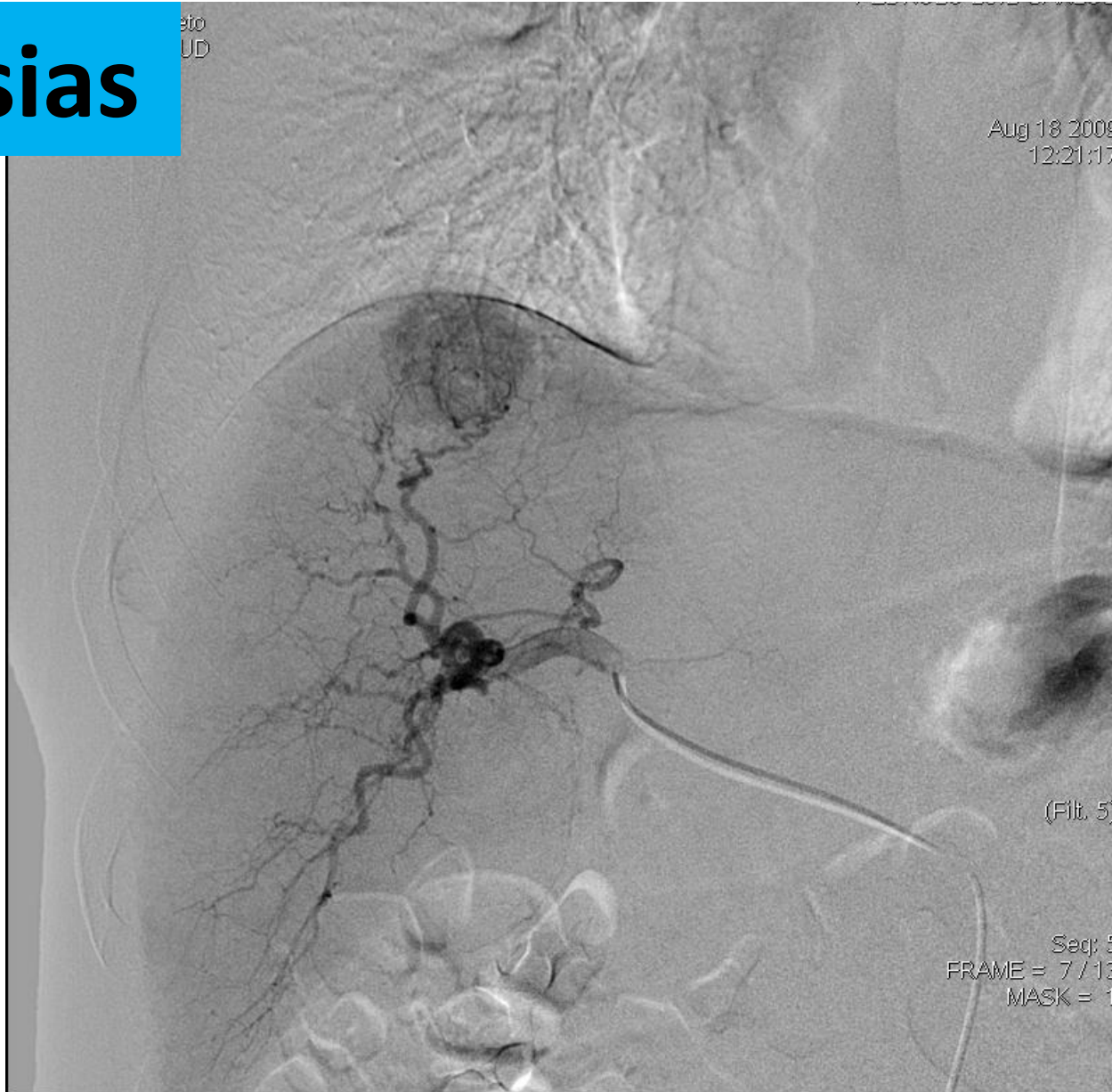



# Neoplasias

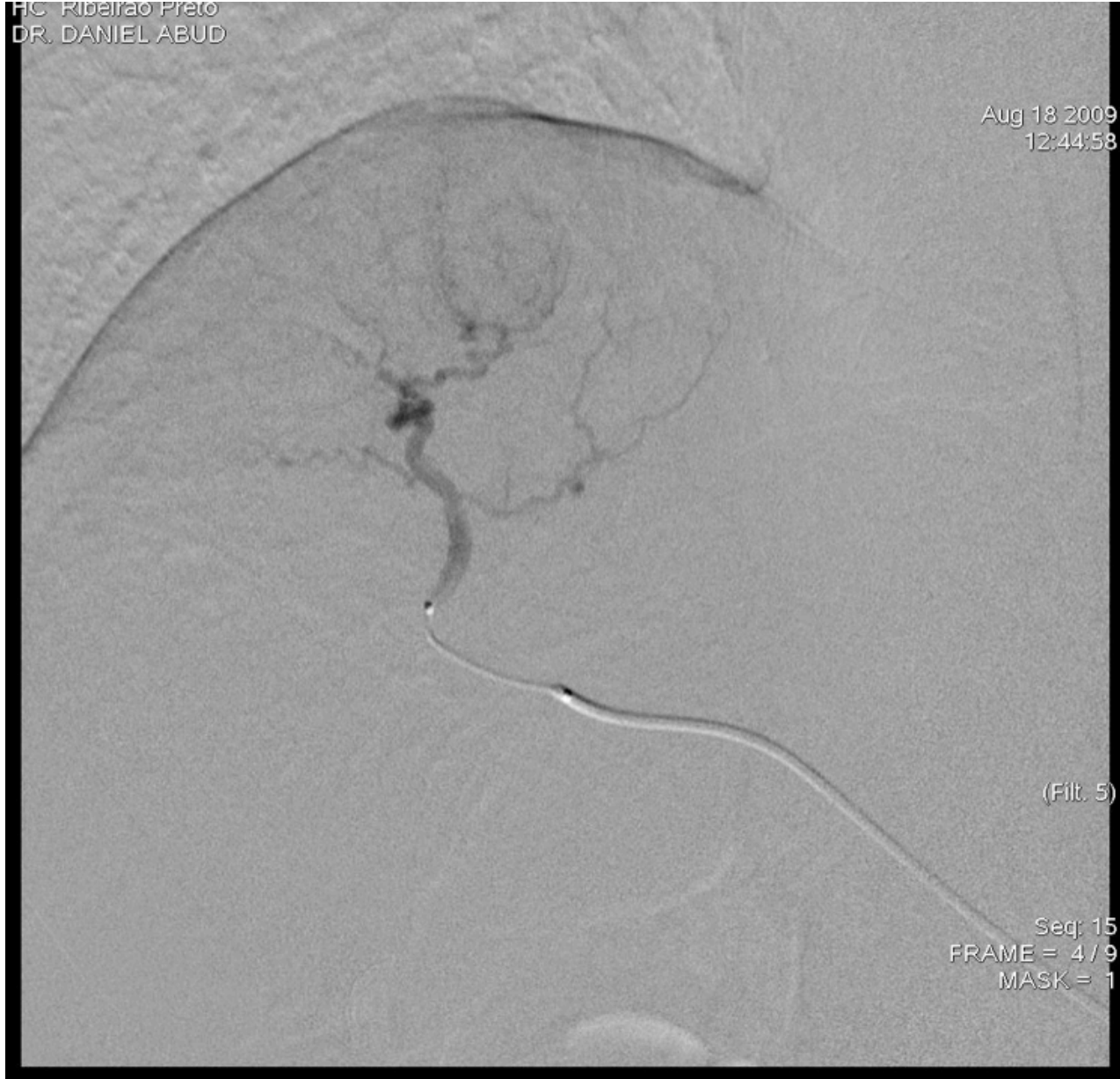eto  
UD

Aug 18 2009  
12:21:17



HC. Ribeirão Preto  
DR. DANIEL ABUD

Aug 18 2009  
12:44:58



(Filt. 5)

Seq: 15  
FRAME = 4 / 9  
MASK = 1

# Complicações Locais

- Trombose ou espasmo
- Sangramento prolongado
- Hematoma
- Fístula A-V
- Aneurisma e pseudoaneurisma
- Dor acentuada pós exame



# Complicações

Puncture site	
Hematoma requiring transfusion, surgery, or delayed discharge	< 3%
Occlusion	< 0,5%
Pseudoaneurysm	< 0,5%
Arteriovenous fistula	< 0,1%
Contrast extravasation	< 1 %
Nonpuncture site	
Distal emboli	< 0,5%
Dissection or occlusion of selected vessel	< 2%

# Complicações Neurológicas

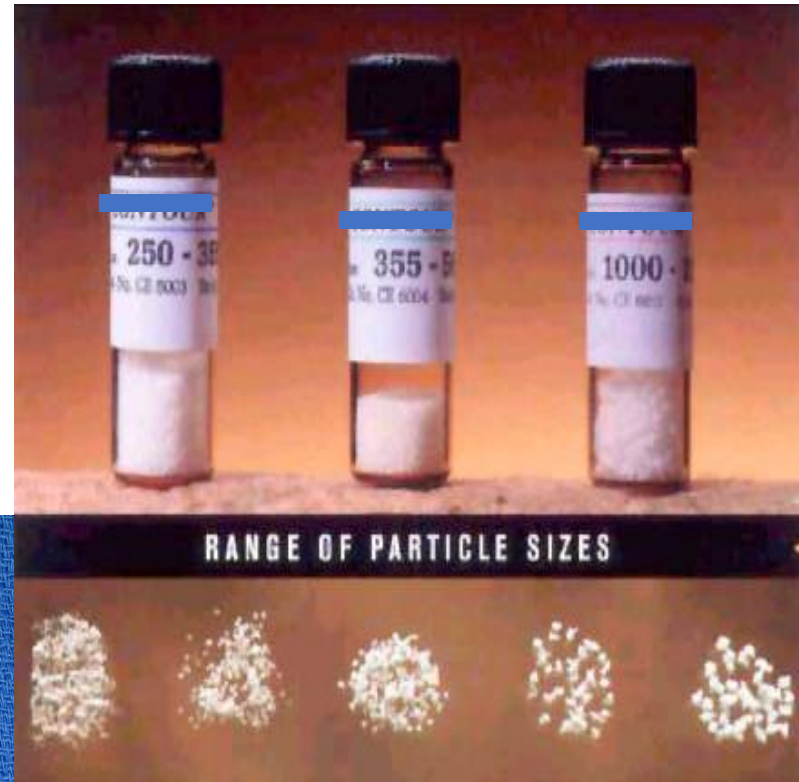
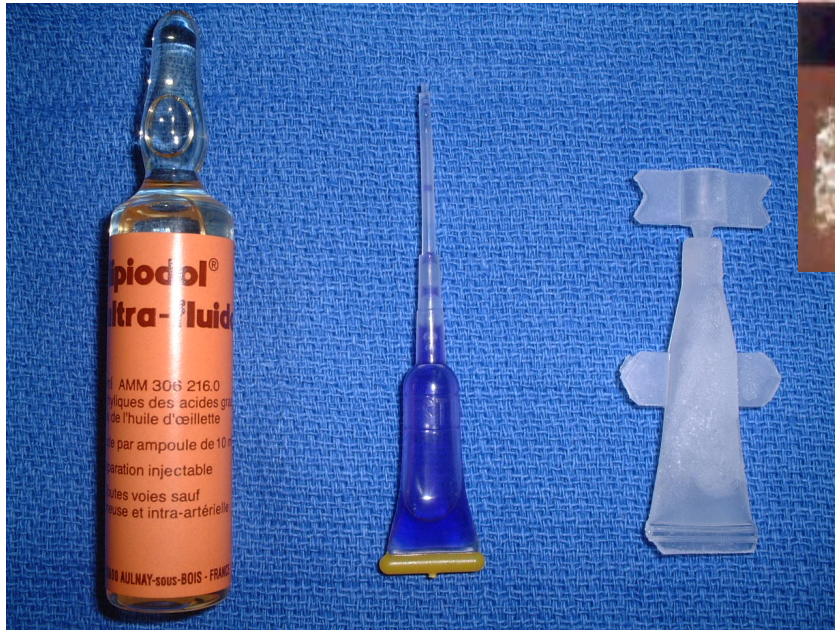exames seletivos de carótidas e vertebrais

- déficit neurológico transitório ou permanente
- amnésia global transitória
- distúrbio de consciência
  - menor que 0,5% em hospitais com equipe treinada



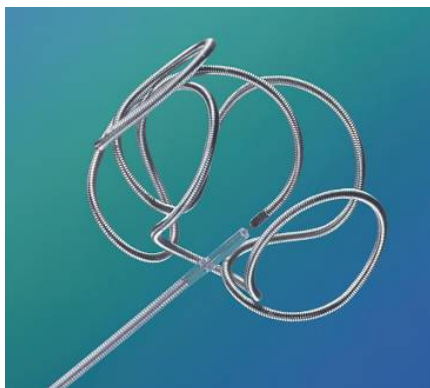
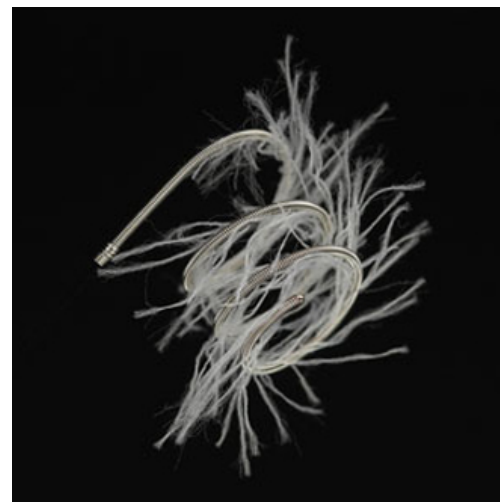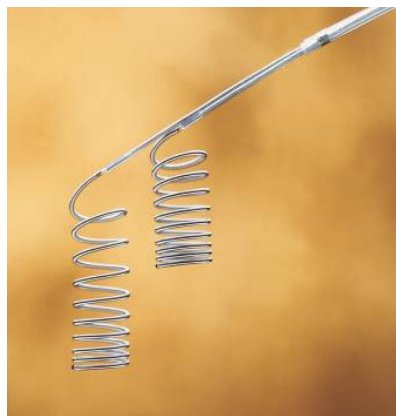## Conclusões

- A angiografia atual é um método de alta sensibilidade e especificidade, com baixo índice de complicações
- Apesar do rápido desenvolvimento dos métodos não-invasivos (USG,TC,RM), ainda é o padrão ouro na maioria das patologias vasculares
- A técnica angiográfica é o caminho para os inúmeros procedimentos terapêuticos endovasculares


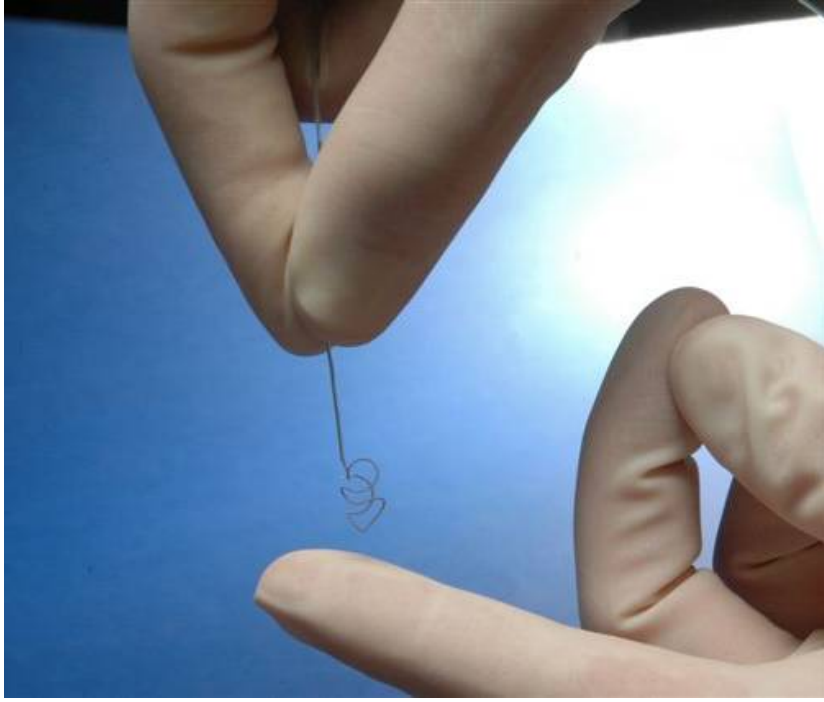


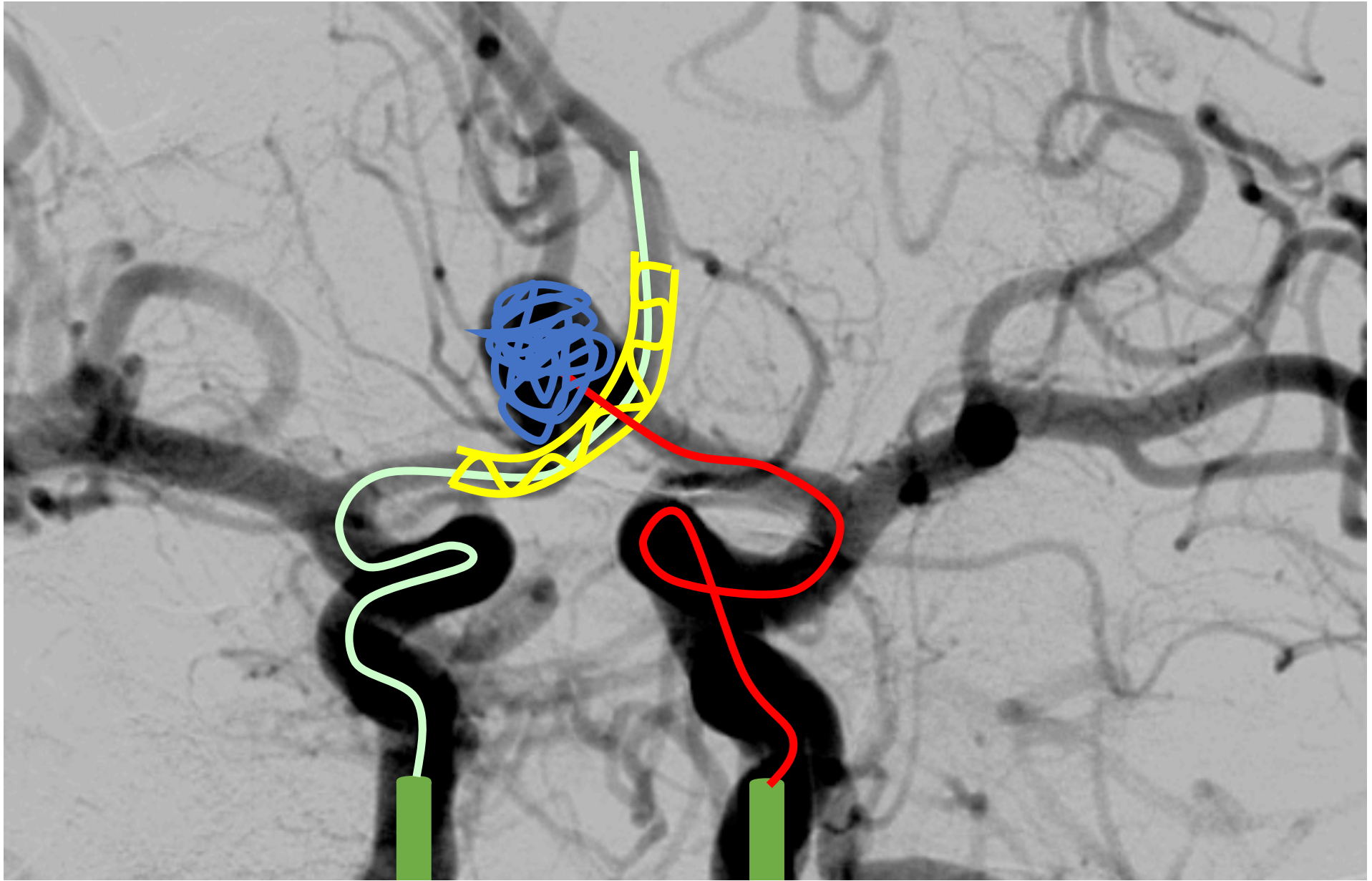

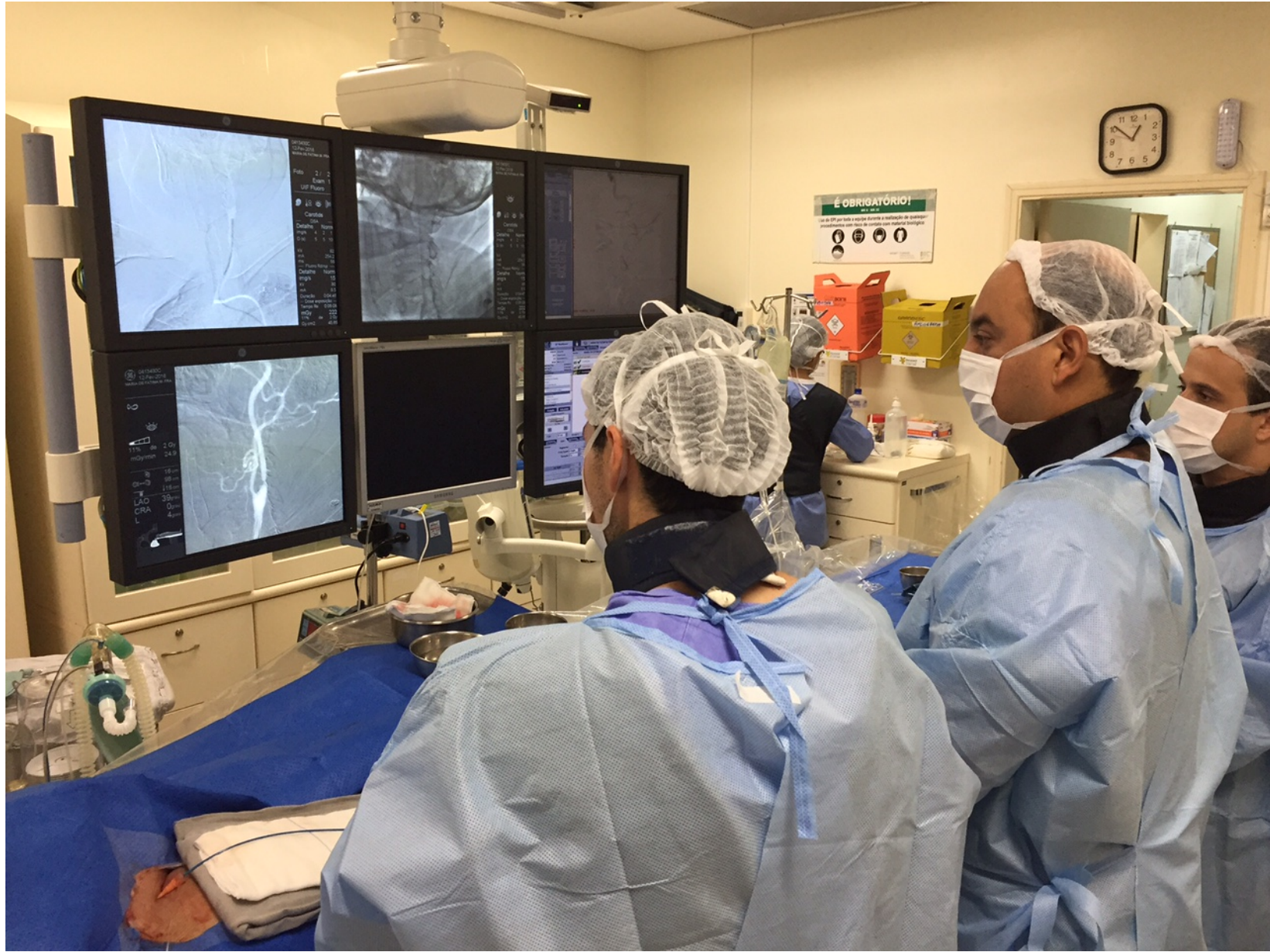
# Micromolas













# Radiologia Intervencionista

- Evolução do material, equipamento e das técnicas

