

Faculdade de Medicina de Ribeirão Preto

FMRP – USP

RCG 381 – Noções Básicas de Diagnóstico  
por Imagem

**Medicina Nuclear:  
Instrumental e Formação  
da Imagem**

Prof. Dr. Lauro Wichert Ana

# Introdução

---

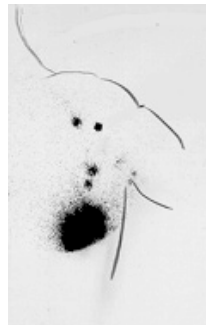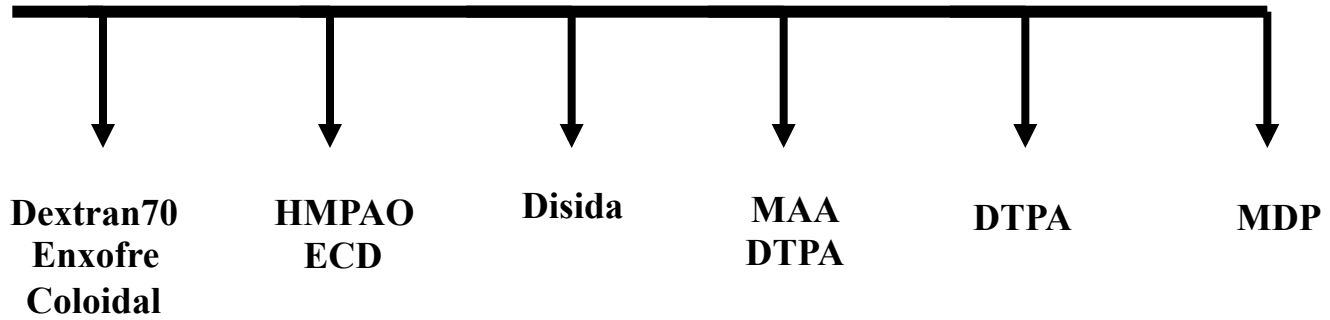
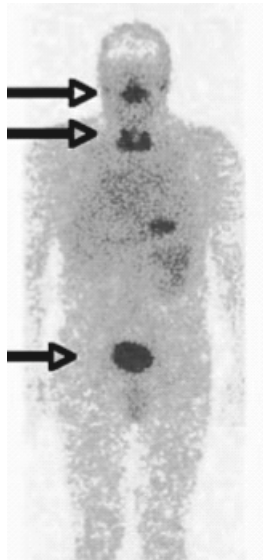
- O que é Medicina Nuclear?
- Quais são as 3 finalidades principais?
- Qual a matéria prima da MN?
- O que a MN nos diz sobre o o corpo humano?
- Existem Limitações?

Tecnécio-99m

# Radionuclídeo + Fármaco



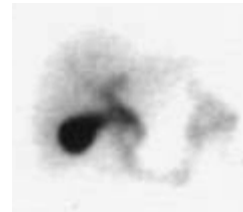
Puro



Linfo-  
Cintilografia



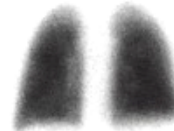
SPECT  
Cerebral



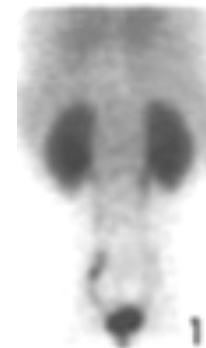Função  
Hepato  
Biliar



Ventilação



Perfusão



Função  
Renal



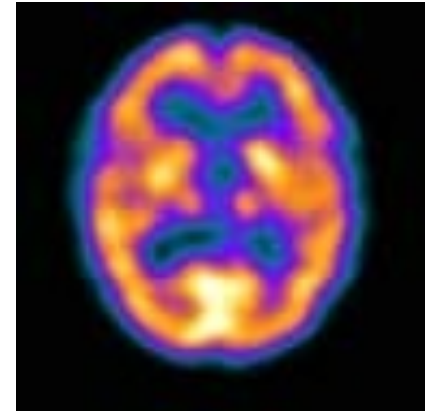
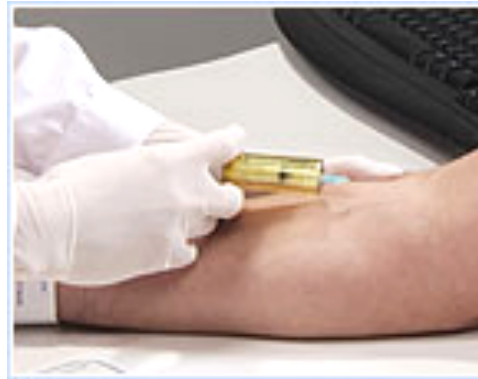Metab.  
Ósseo

*Qual é a mensagem?*

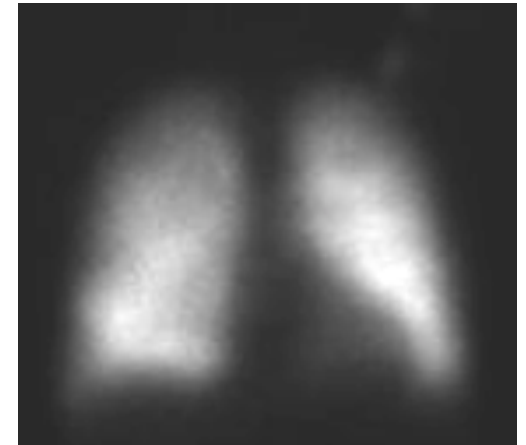
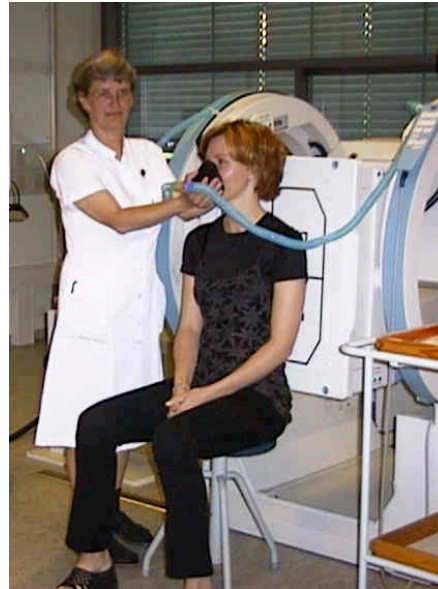
# Medicina Nuclear

## ■ Vias de Administração:

■ *Injeção*  
*Intravenosa*



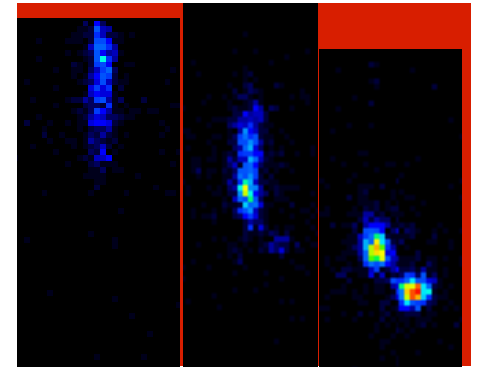
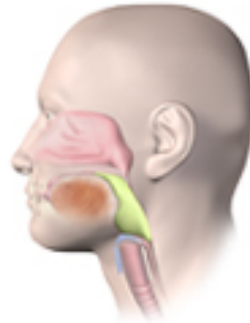
■ *Inalação*



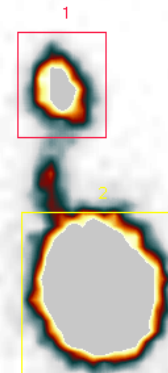
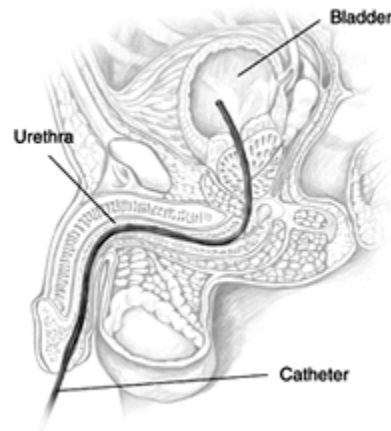
# Medicina Nuclear

## ■ Vias de Administração:

### ■ *Deglutição*



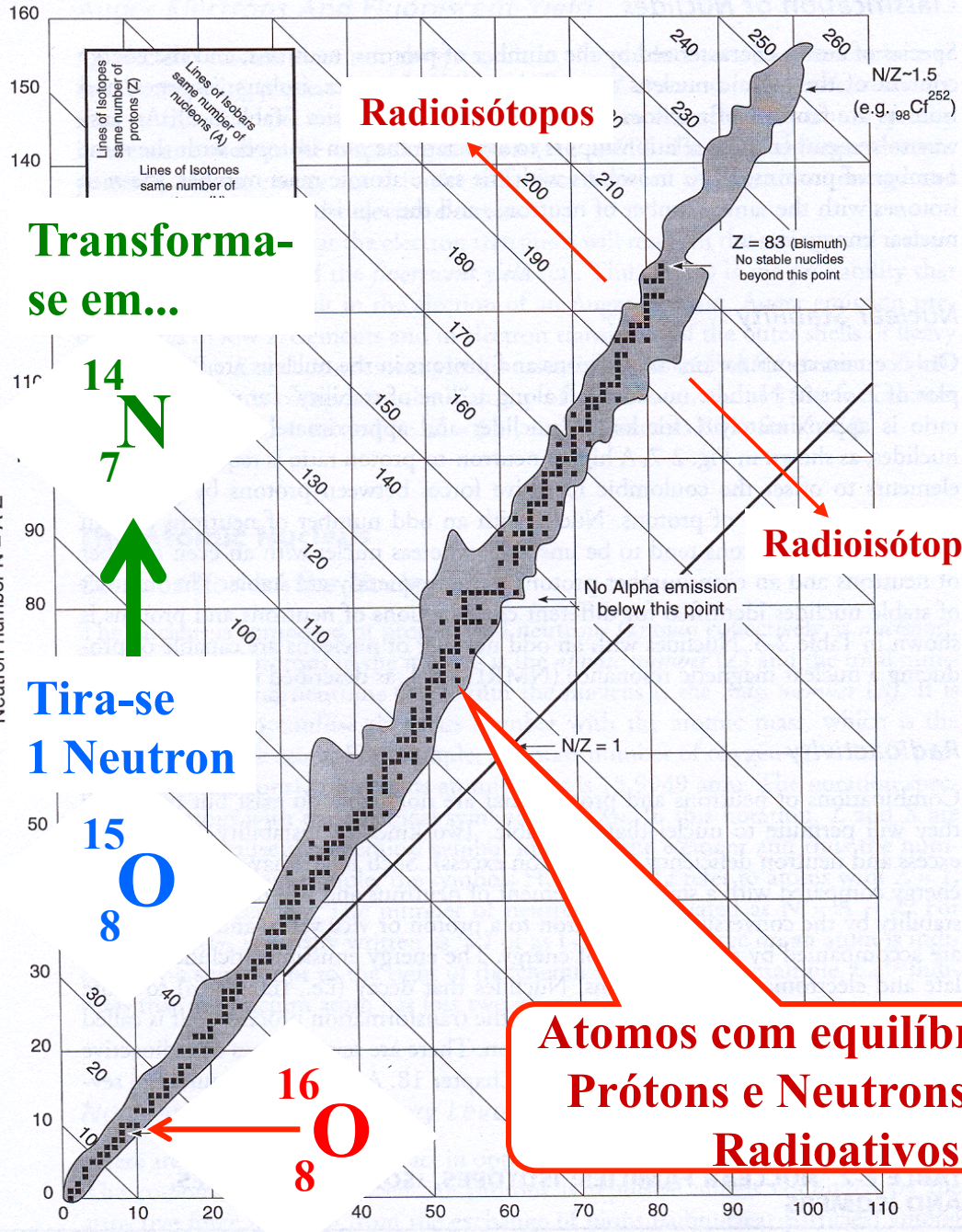
### ■ *Sondagem*





# Quais são as Bases Físicas da Medicina Nuclear

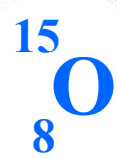





**Transforma-se em...**



**Tira-se 1 Neutron**



**Neutrons**



**Átomos com equilíbrio entre Prótons e Neutrons = Não Radioativos**

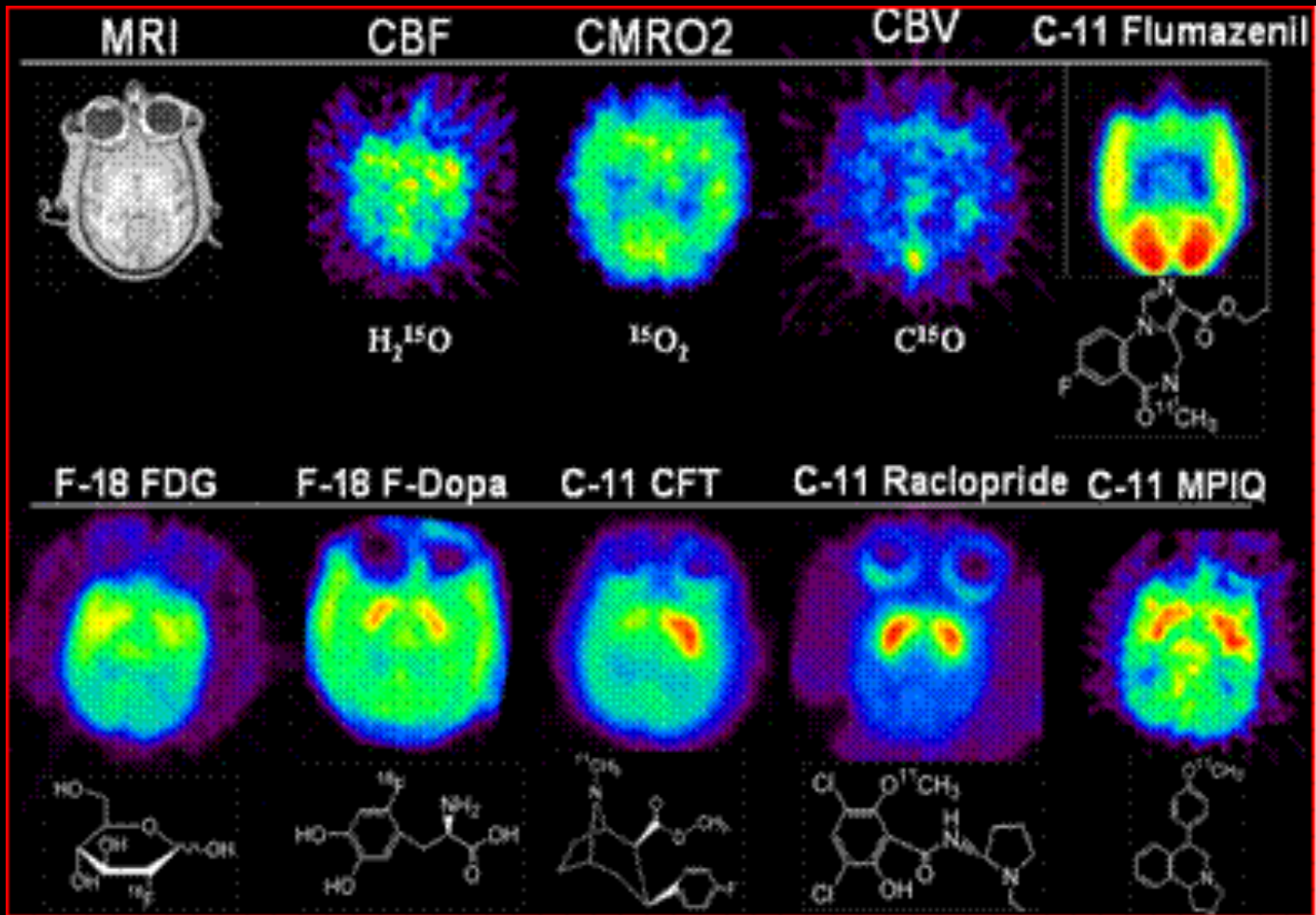
Proton number Z



**Prótons**



# Aplicações em Neurociências



# Radiação

---

- Quando um átomo encontra-se instável (excitado), o que ele faz para alcançar a sua estabilidade nuclear?

**Emite Radiação**

**DECAIMENTO RADIOATIVO**

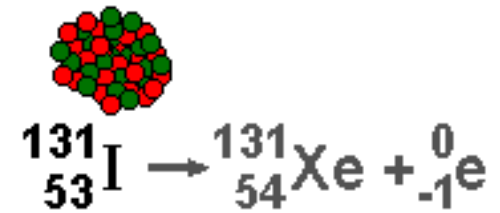
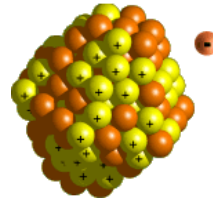
# Definições

---

- **Radiação:** É a emissão e propagação de partículas ou ondas originadas sejam de substâncias radioativas, fontes de ondas eletromagnéticas ou sonoras e que viajam através do espaço e da matéria.
- **Radioatividade:** É a propriedade de determinados elementos químicos de produzir radiação.

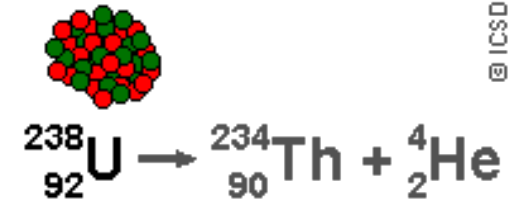
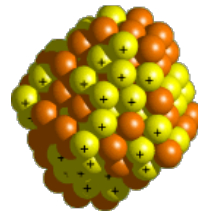
# Decaimento Radioativo

- Decaimento Beta  
(Transição Isobárica)



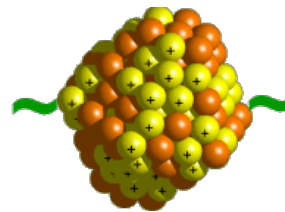
© ICSD

- Decaimento Alfa

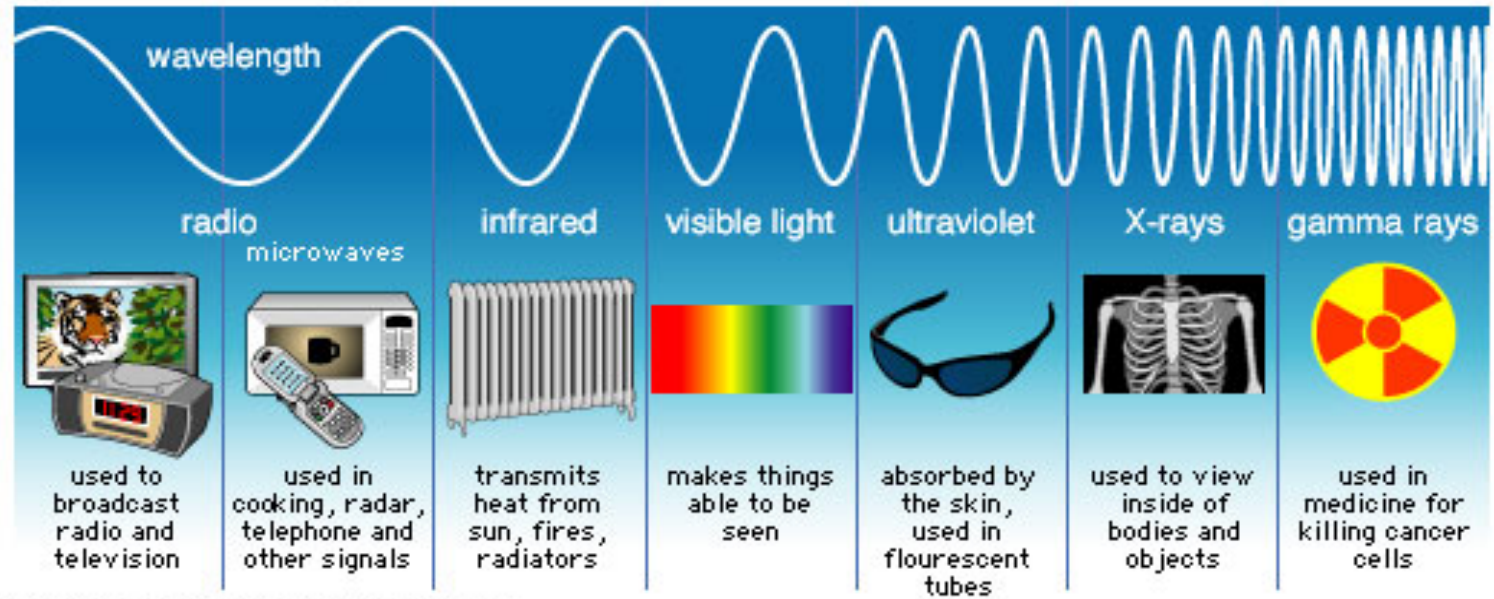


© ICSD

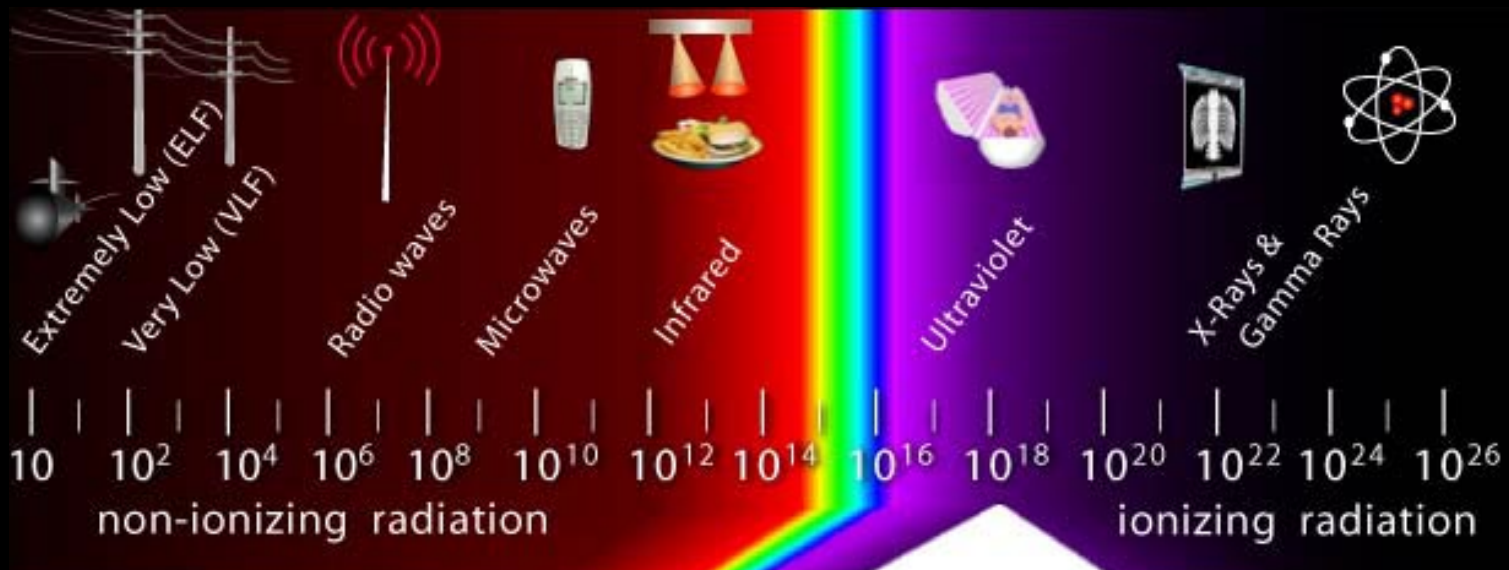
- Decaimento Gama  
(Transição Isobárica)



# Types of Electromagnetic Radiation



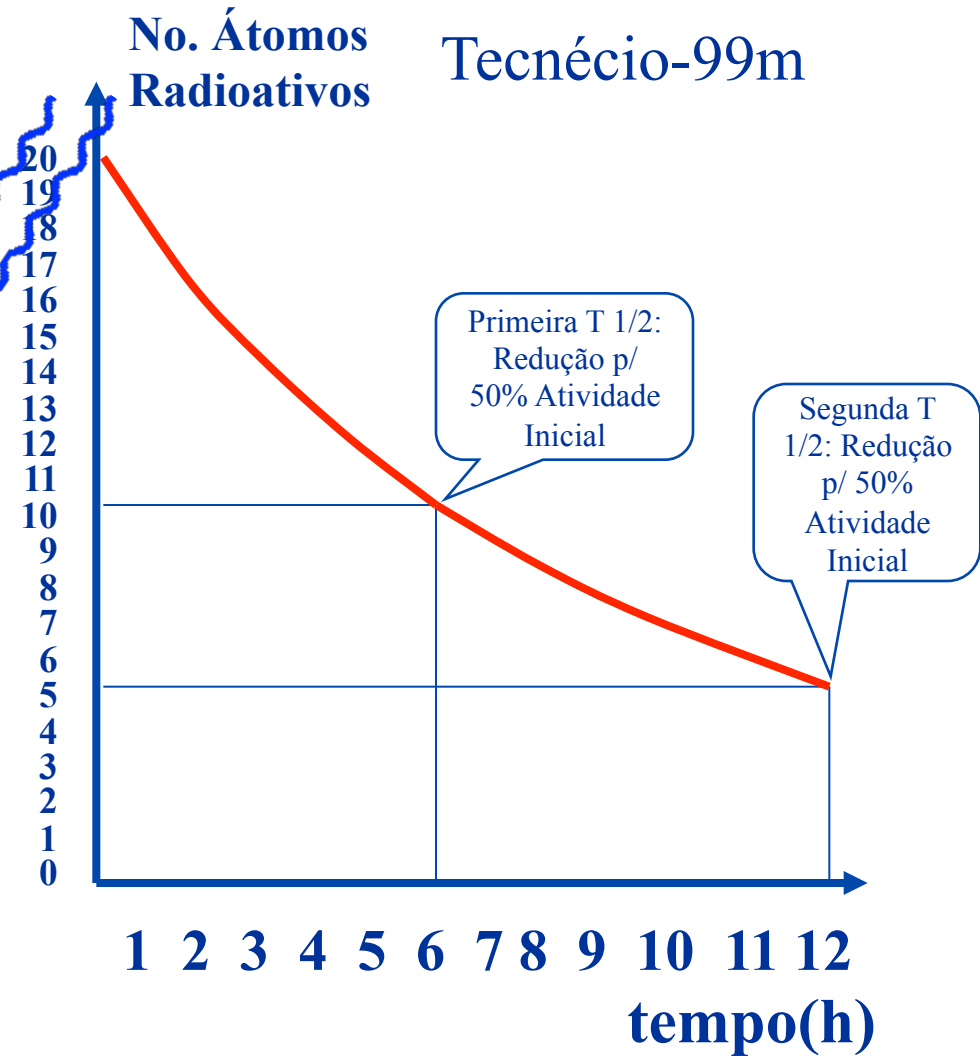
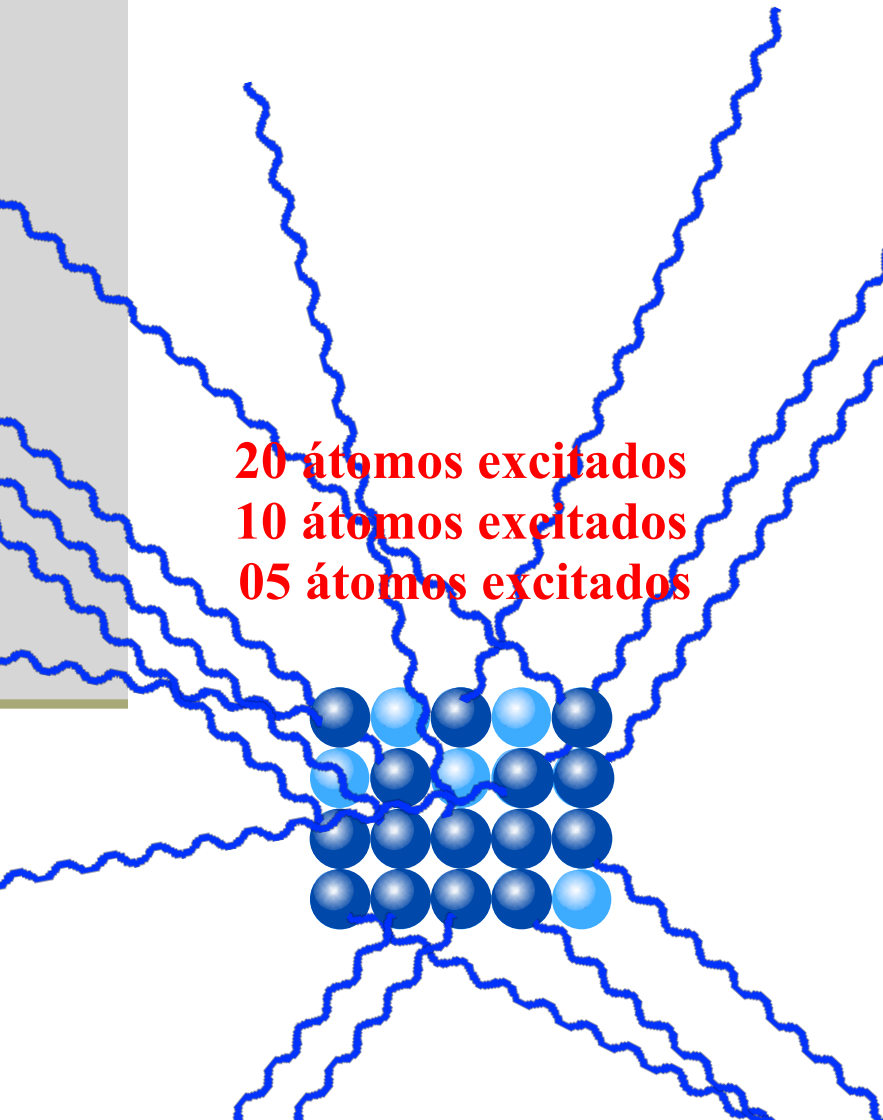
© 2006 Encyclopædia Britannica, Inc.



Não Ionizante

Ionizante

# Decaimento Radioativo




# Aplicações Médicas

---

- Partículas Alfa e Beta = Terapêutica
- Radiação Gama = Imagem

Tecnécio-99m  
Iodo-131  
Tálio-201  
Gálio-67  
Samário-153  
Flúor-18



# Radiação

---

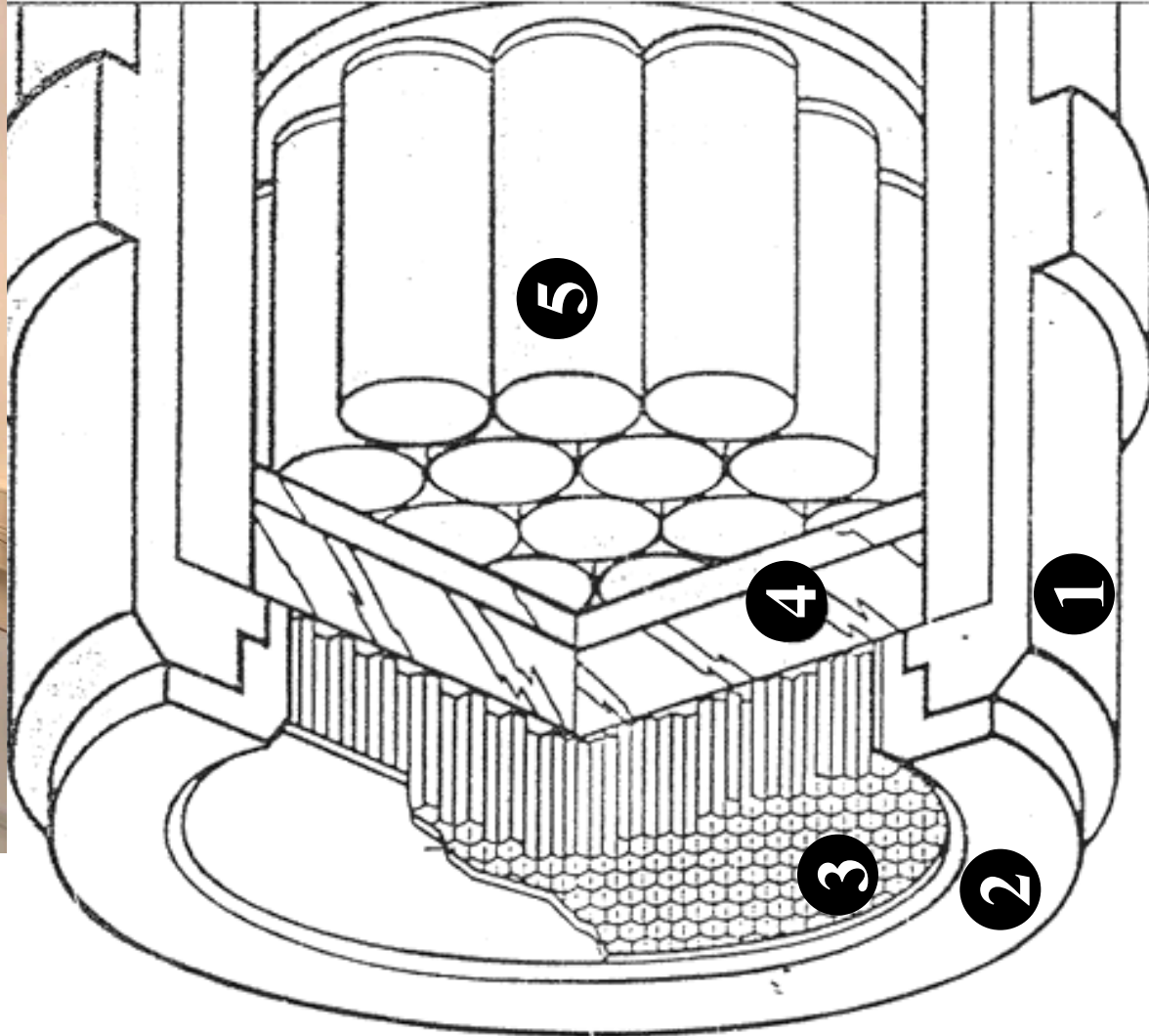
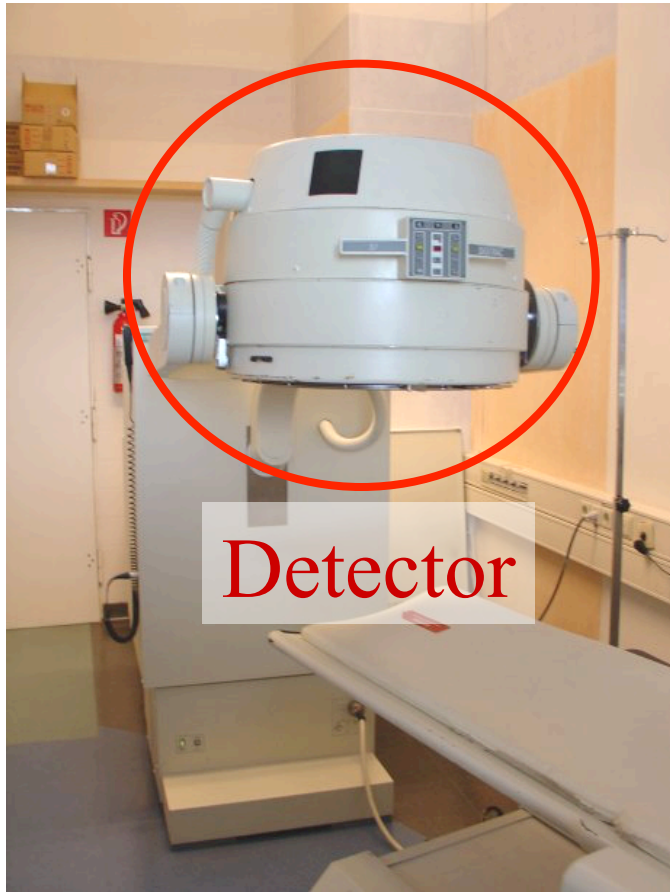- Mas como detectar a radiação gama?

**Através de Detectores de  
Radiação**



# Gama Câmeras e Formação da Imagem

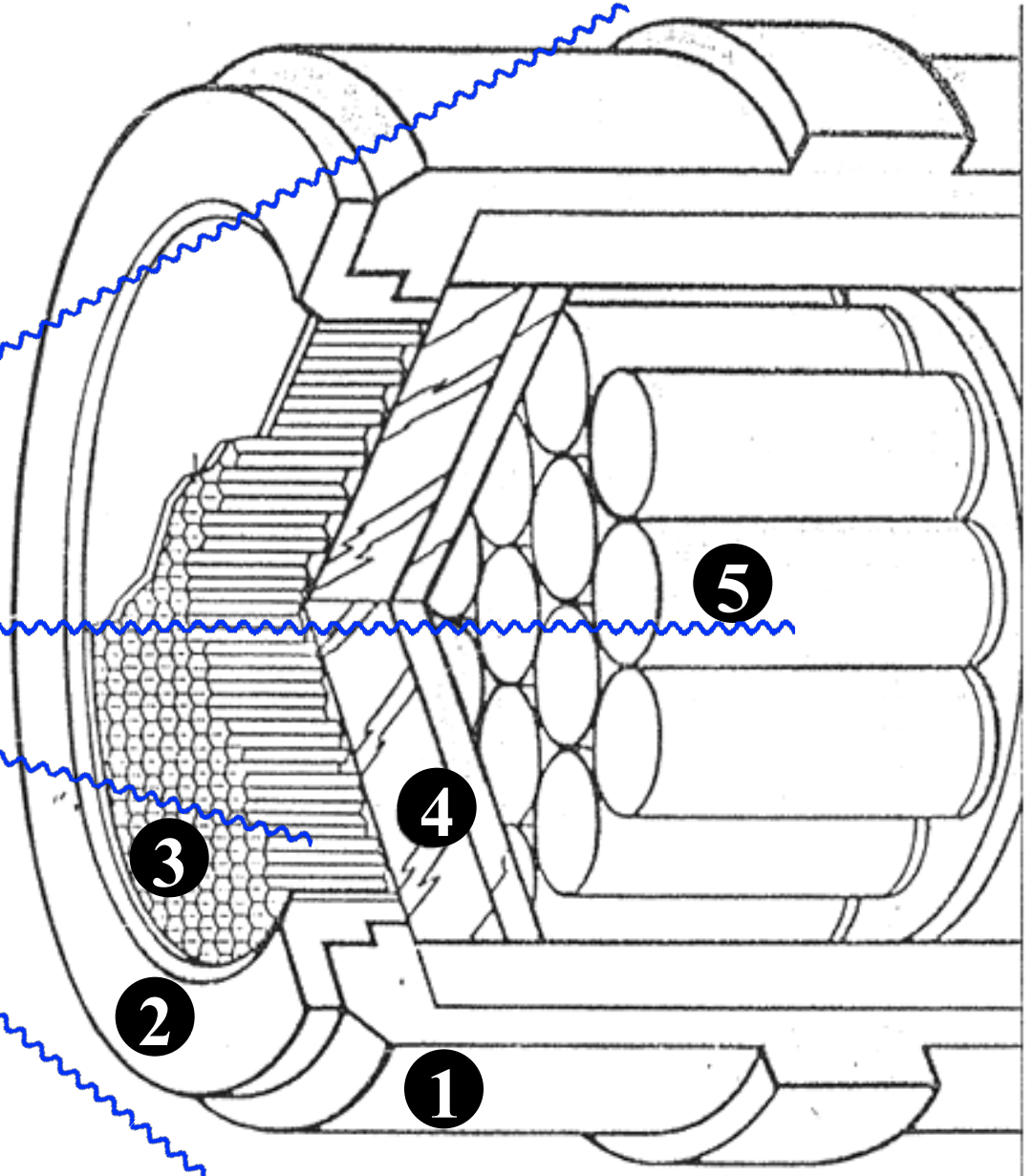
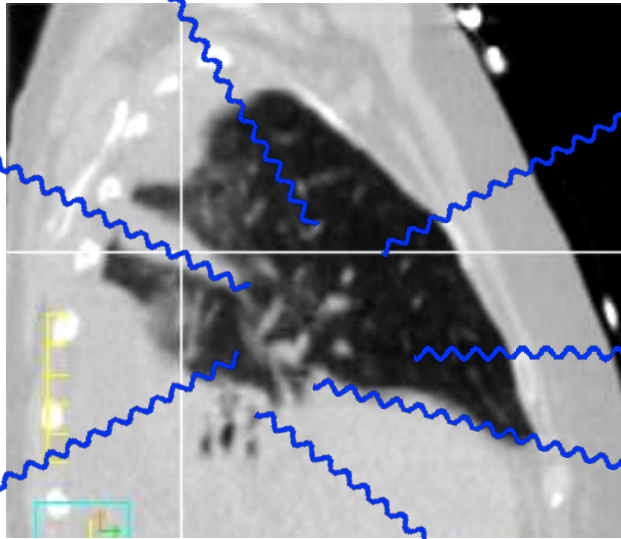
# Gama-Câmara



1. Invólucro
2. Blindagem
3. Colimador
4. Cristal NaI(Tl)
5. Fotomultiplicadora

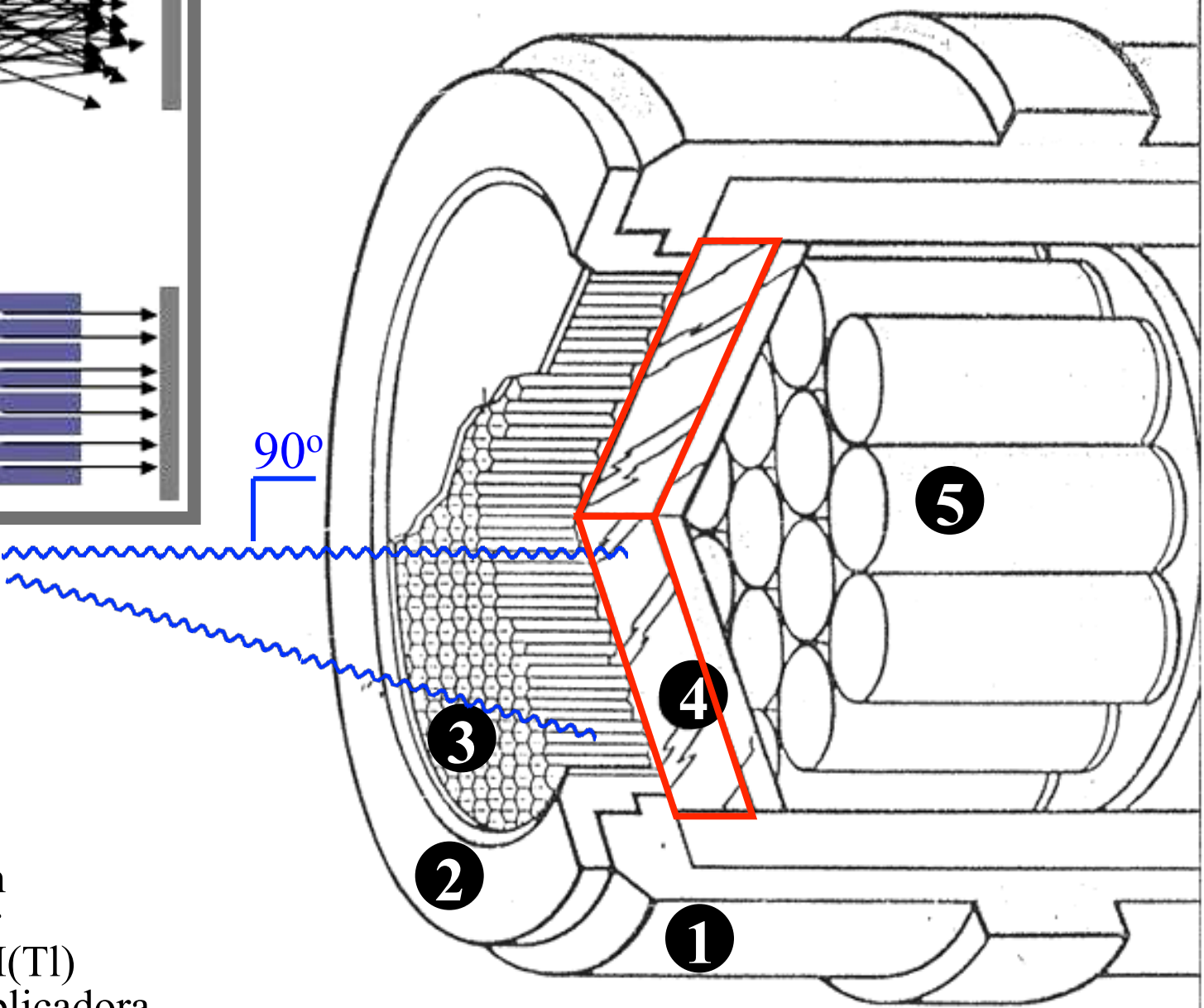
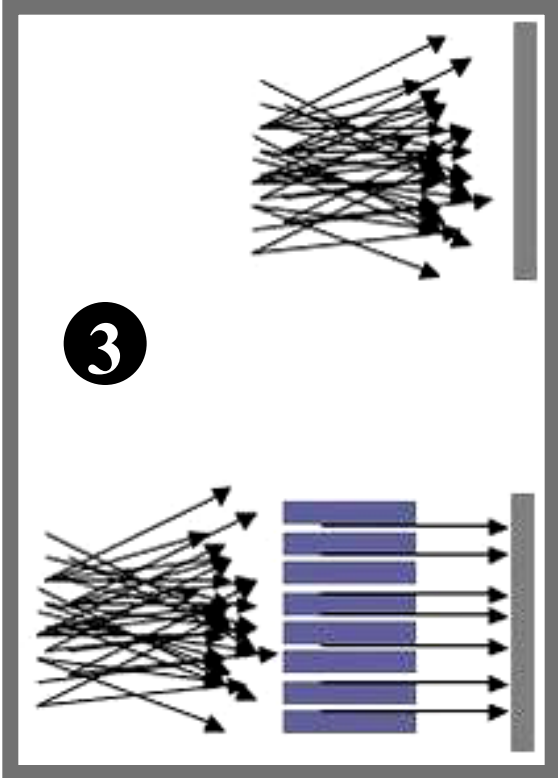
# Órgão Alvo

# Detector



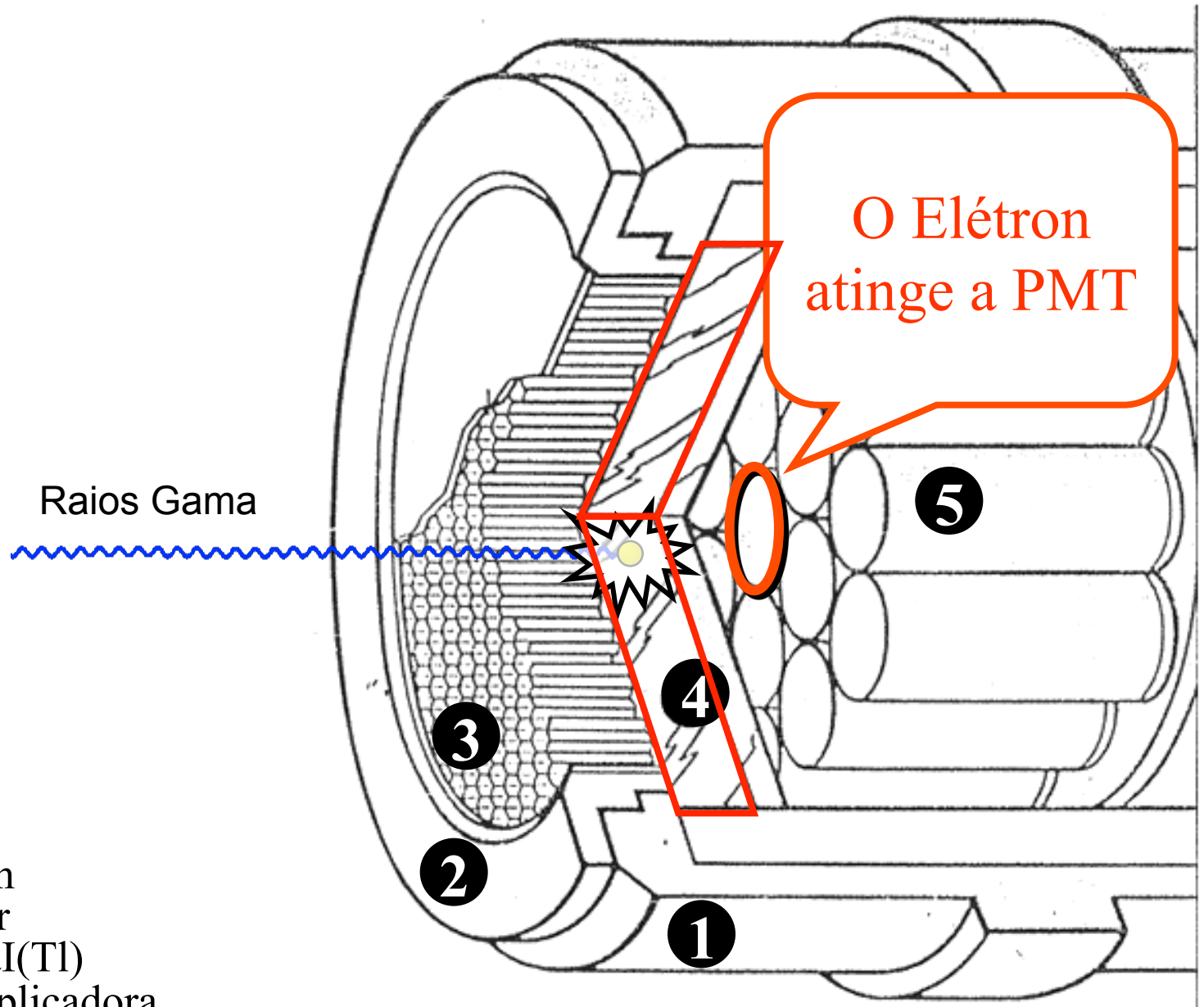
1. Invólucro
2. Blindagem
3. Colimador
4. Cristal NaI(Tl)
5. Fotomultiplicadora

# Detector




- 1. Invólucro
- 2. Blindagem
- 3. Colimador
- 4. Cristal NaI(Tl)
- 5. Fotomultiplicadora

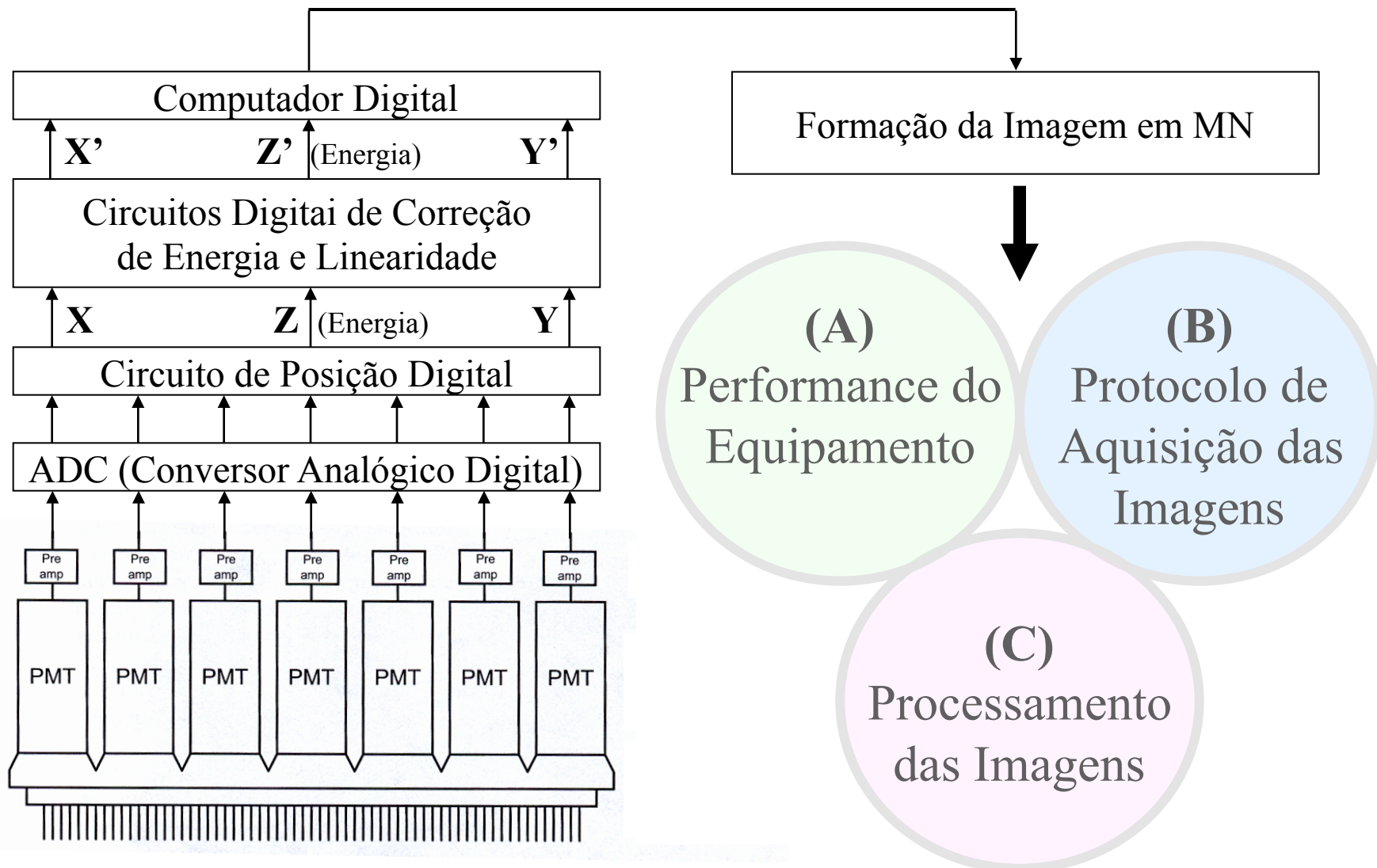
# Detector



# Fotomultiplicadoras (PMT)

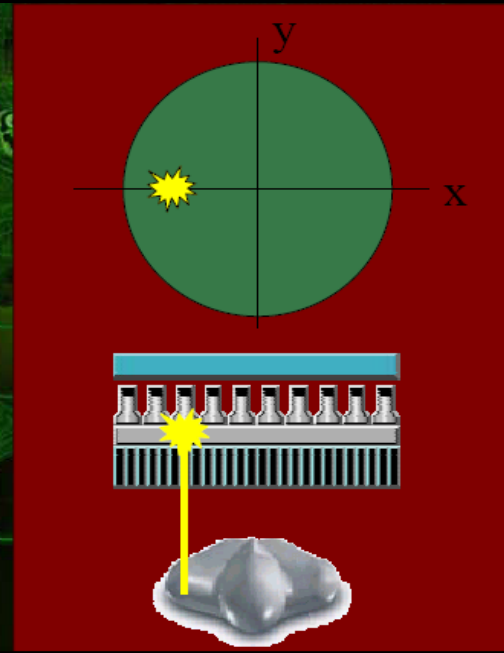


# Dos Raios Gama à Imagem em MN



# Protocolo de Aquisição

<b>0</b>	<b>0</b>	<b>0</b>
<b>1</b>	<b>0</b>	<b>0</b>
<b>0</b>	<b>0</b>	<b>0</b>





Matriz de  
Aquisição  
**3 x 3**



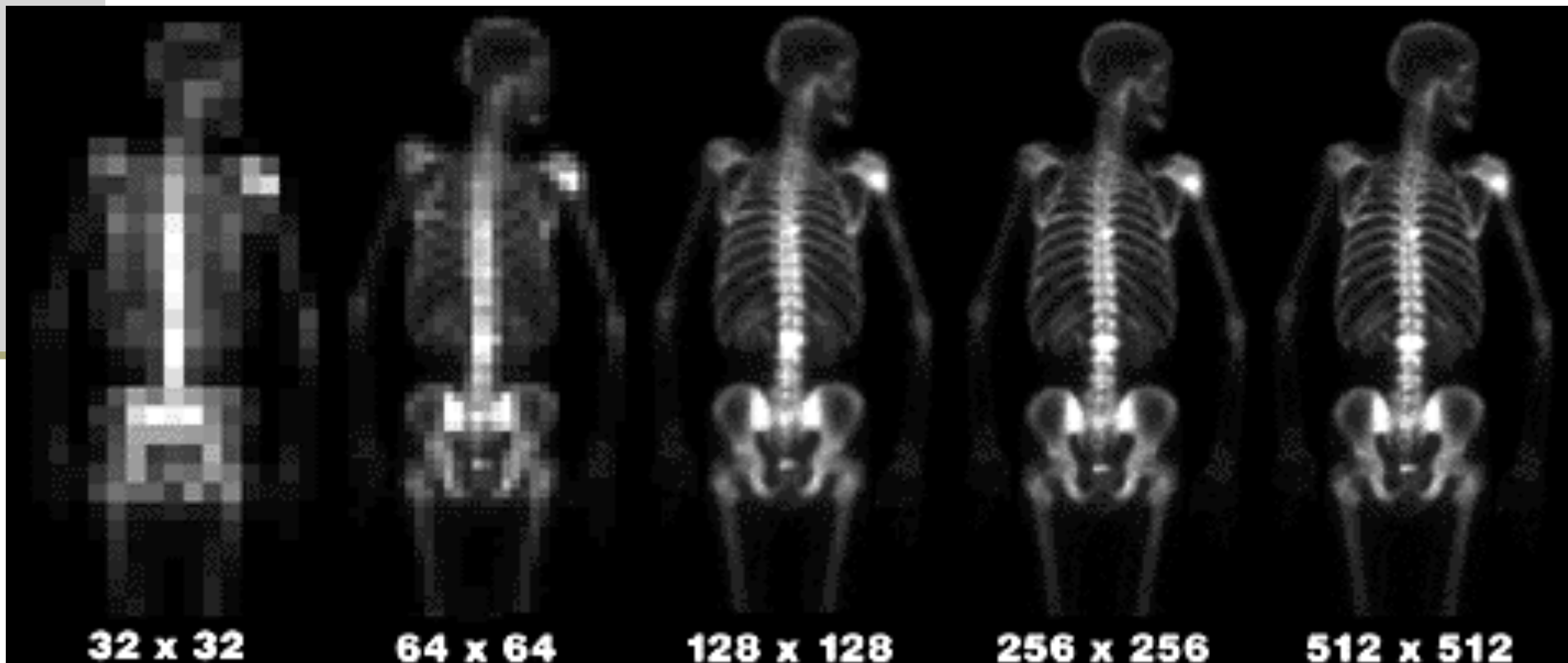
# Protocolo de Aquisição

## ■ Matrizes de Aquisição



# Método de Imagem em MN

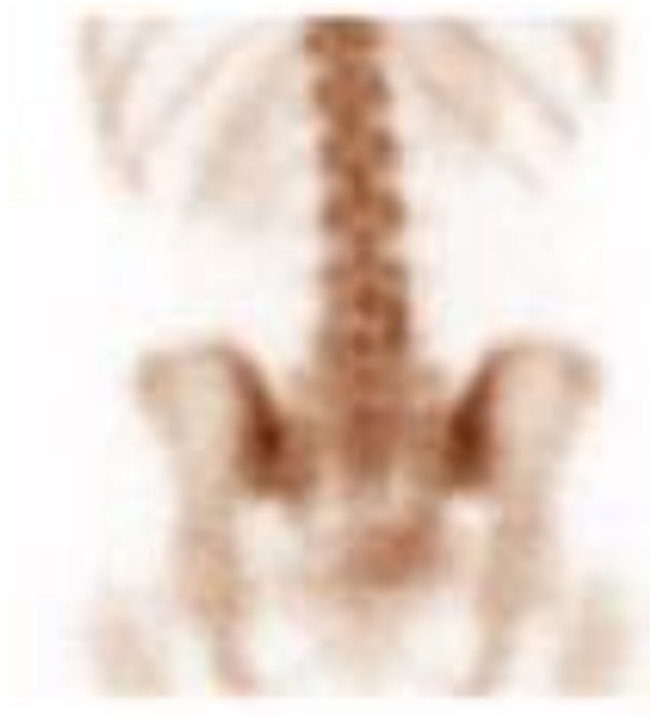## ■ Matrizes de Aquisição



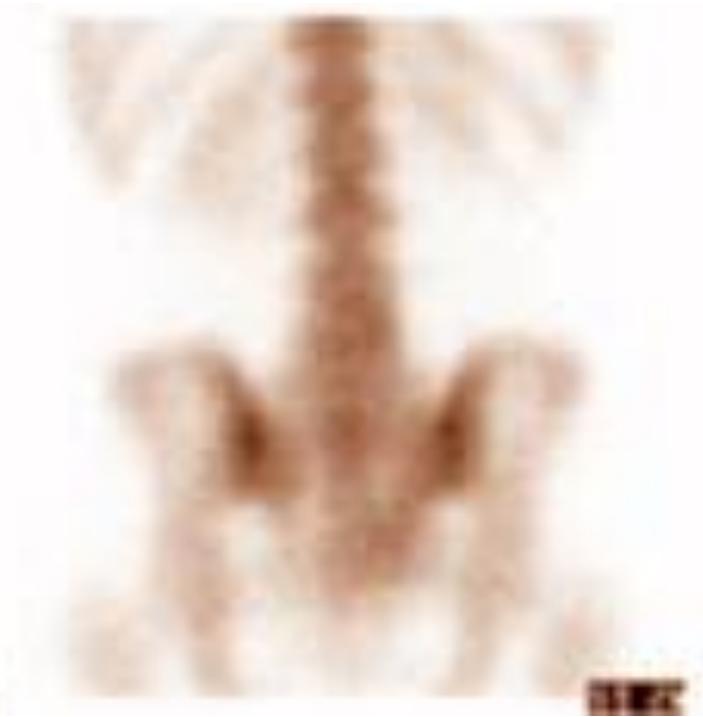# Método de Imagem em MN

---

- Distância do órgão-alvo até o detector.



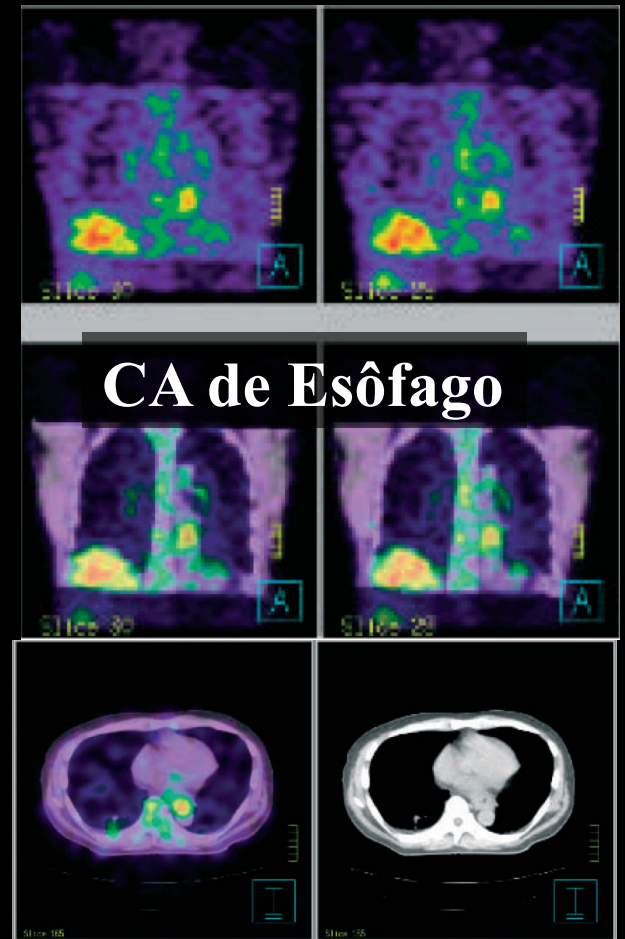
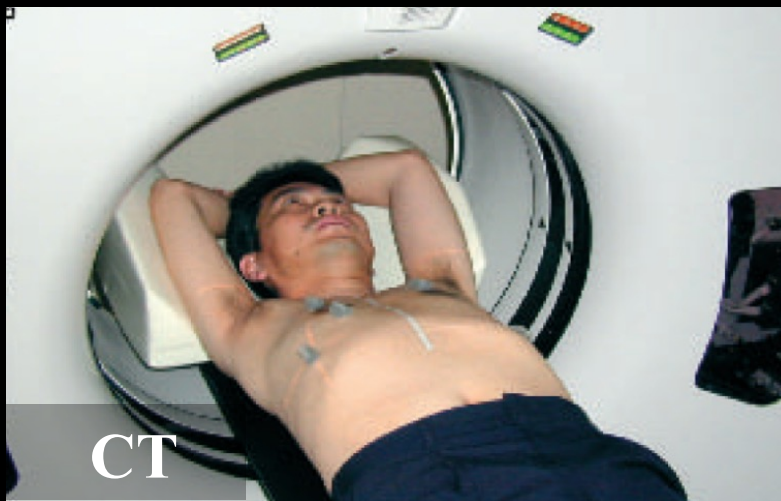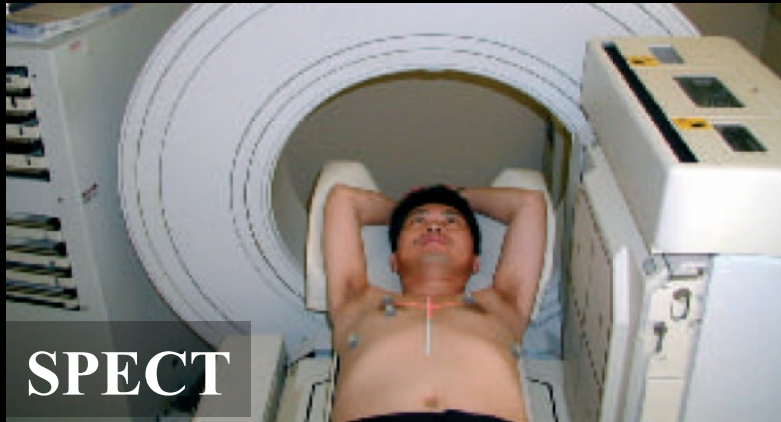**5 cm**



**15 cm**

# Detectores de Radiação

## ■ Gama-Câmaras: SPECT / CT

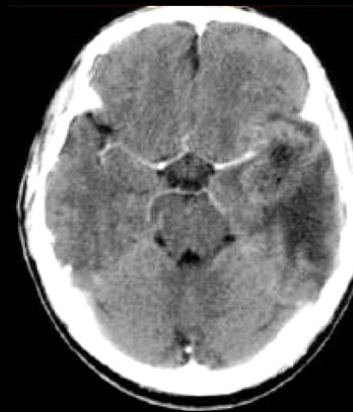
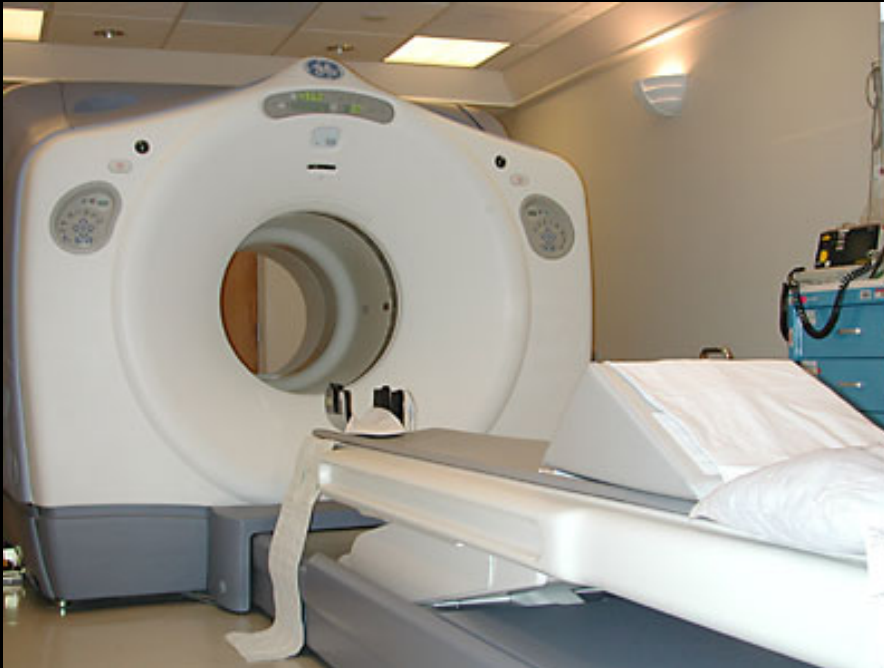
# Detectores de Radiação

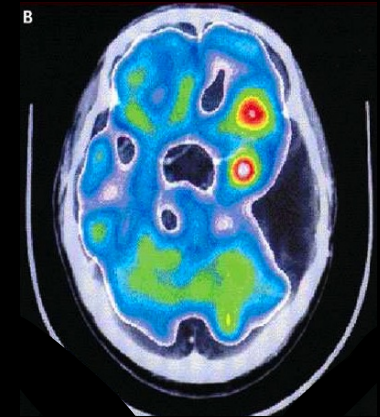
## ■ PET / CT Glioblastoma de Grau Intermediário

Paciente previamente tratado com Neurocirurgia, Quimioterapia e Radioterapia.

Apresenta aumento da [radiofármaco] nas margens da área tratada.



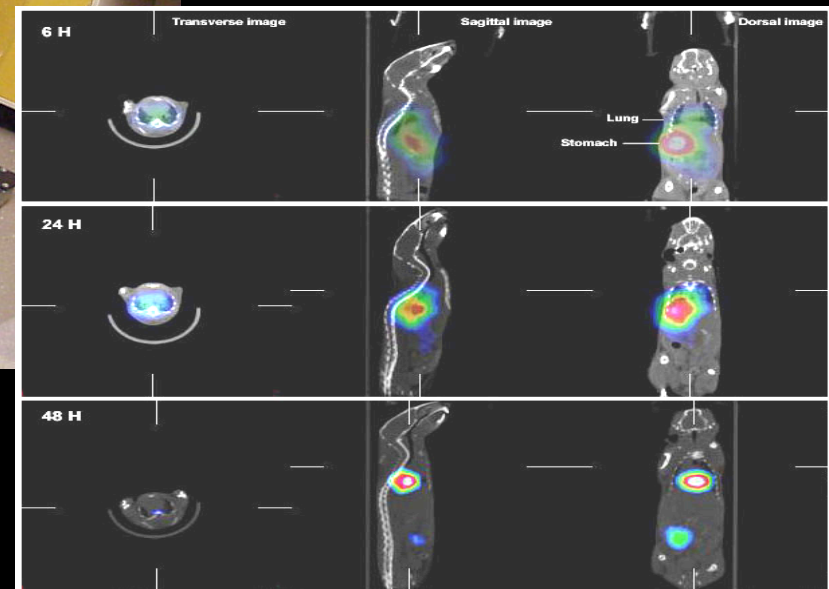
CT, Contraste



PET, F-18 FDG

# Detectores de Radiação

## ■ MicroSPECT/CT



# Medicina Nuclear: Indicações e Exemplos Clínicos

# Estudos Fisiológicos em...

---

- **Pneumologia**

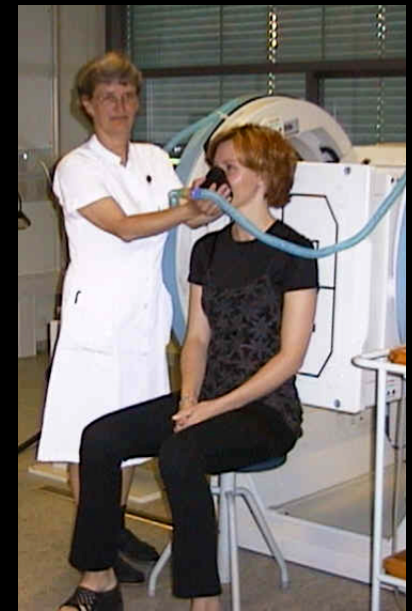


# Estudos Fisiológicos

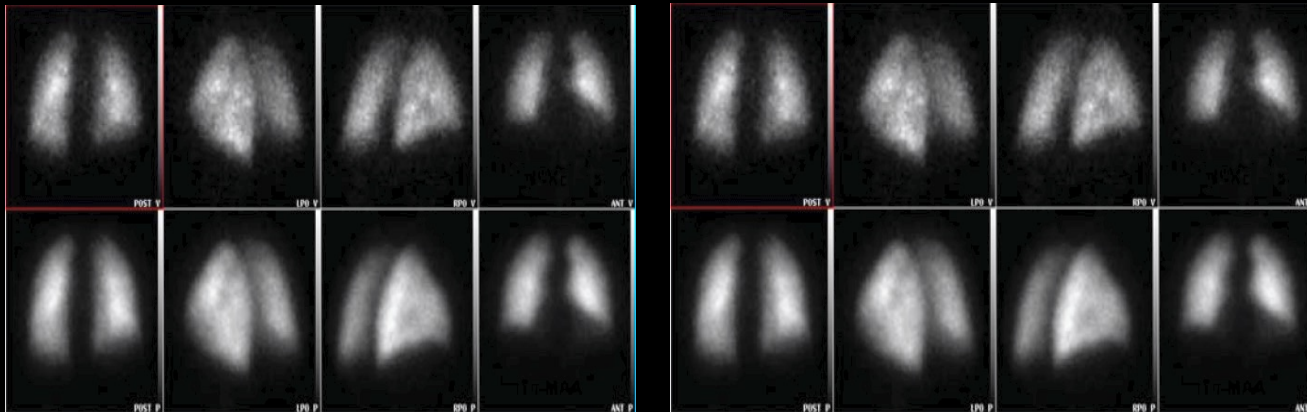
- Qual função está sendo estudada?

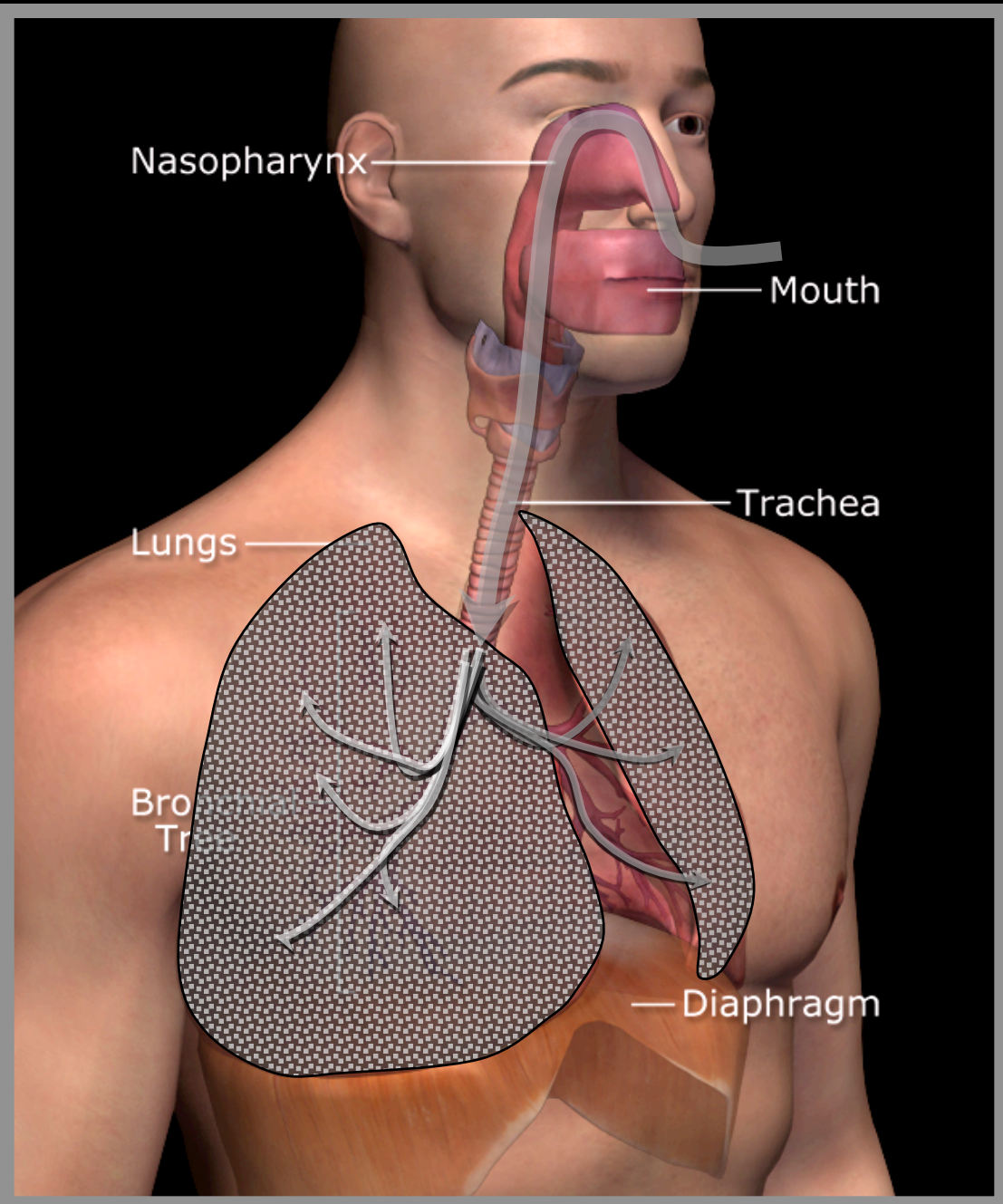
$^{99m}\text{Tc}$  - DTPA  
Ventilação (V)

$^{99m}\text{Tc}$  - MAA  
Perfusão (Q)




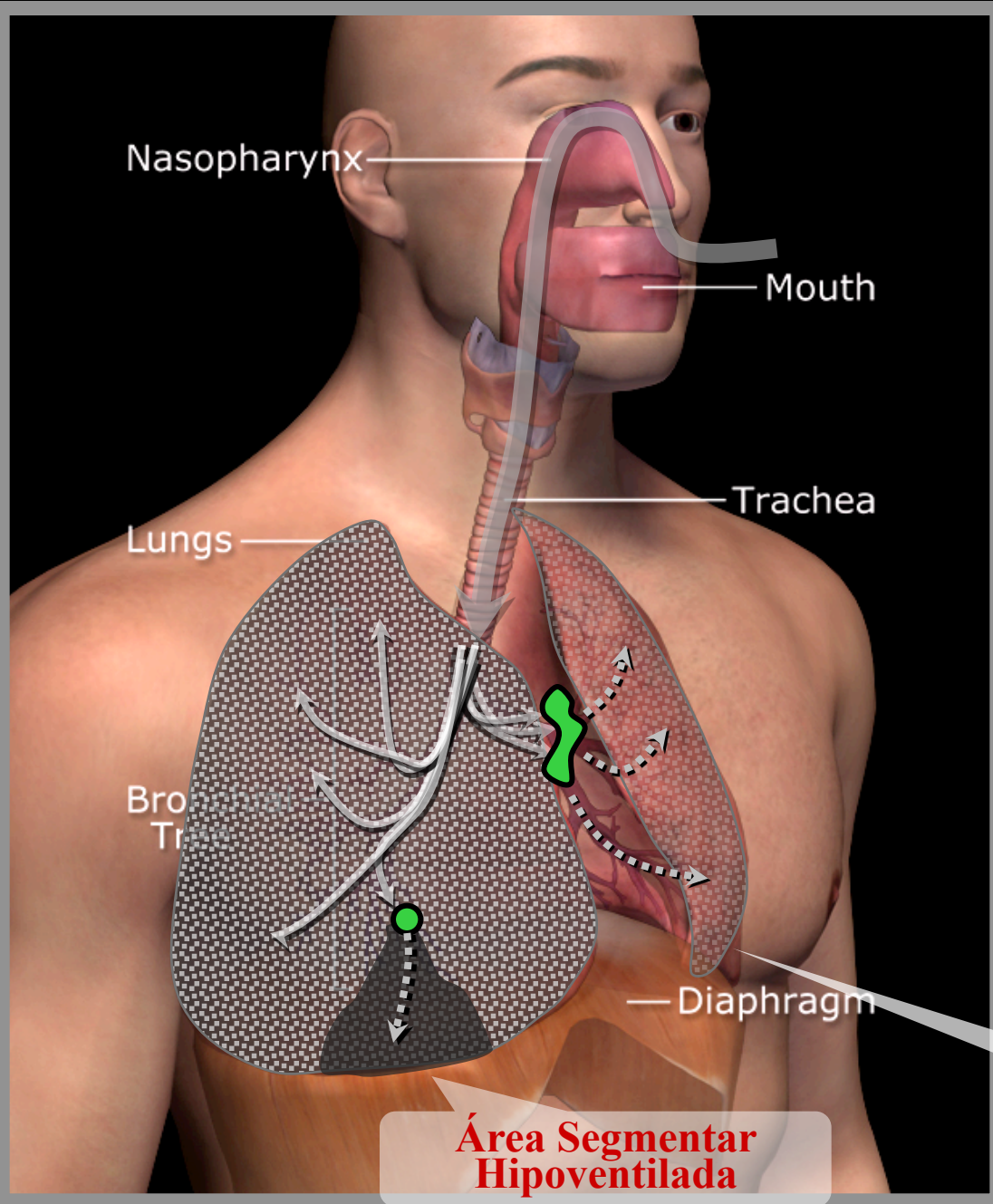
Inalação






# VENTILAÇÃO Pulmonar Normal

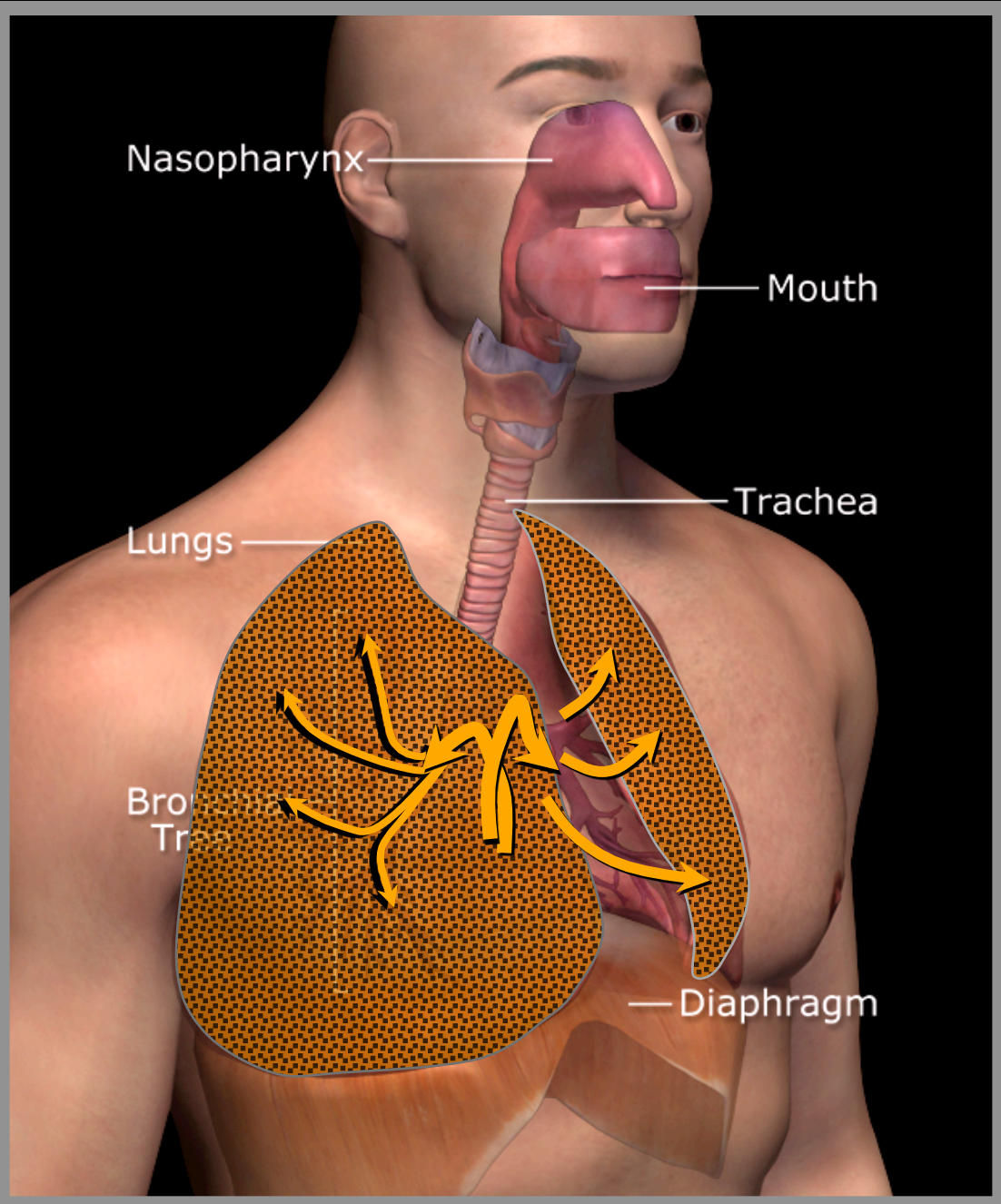





**VENTILAÇÃO**  
Defeito Segmentar P.D.  
+  
Defeito em todo P.E.



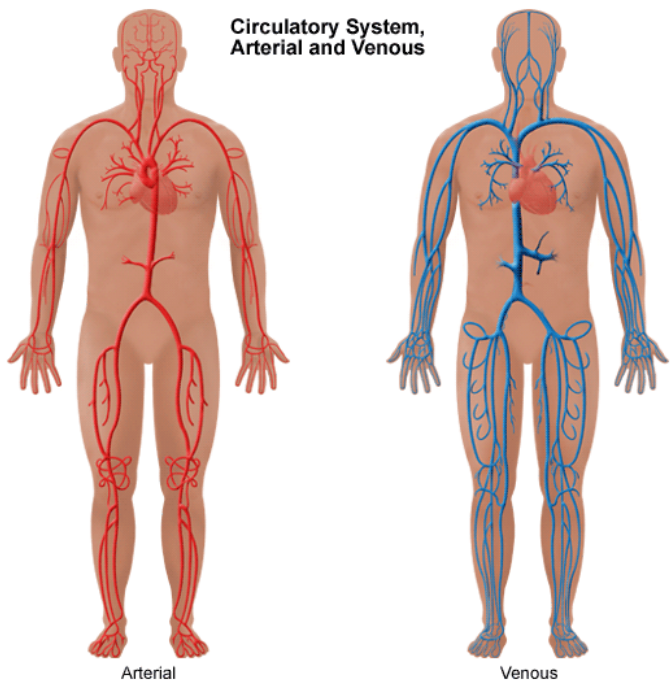
**Todo o Pulmão E Hipoventilado**



# PERFUSÃO Pulmonar Normal



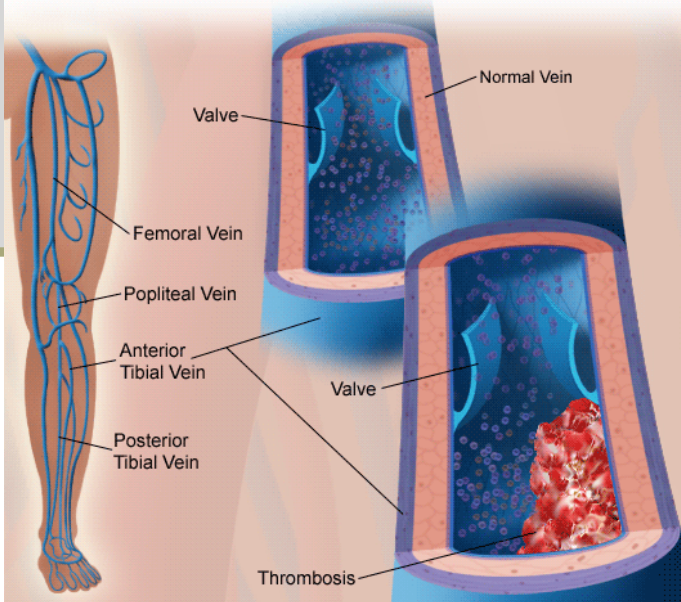
**Circulatory System,  
Arterial and Venous**



Arterial

Venous

**Deep Vein Thrombosis (DVT) of the Leg**



Valve

Normal Vein

Femoral Vein

Popliteal Vein

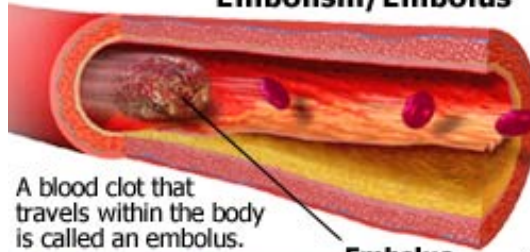
Anterior Tibial Vein

Posterior Tibial Vein

Valve

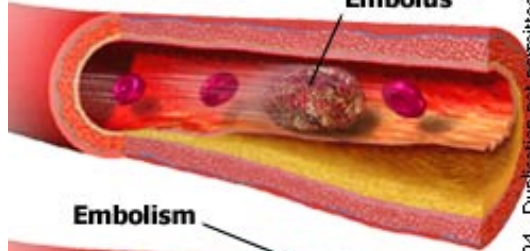
Thrombosis

**Embolism/Embolus**

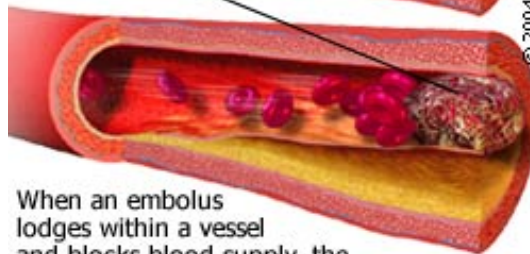


A blood clot that travels within the body is called an embolus.

Embolus

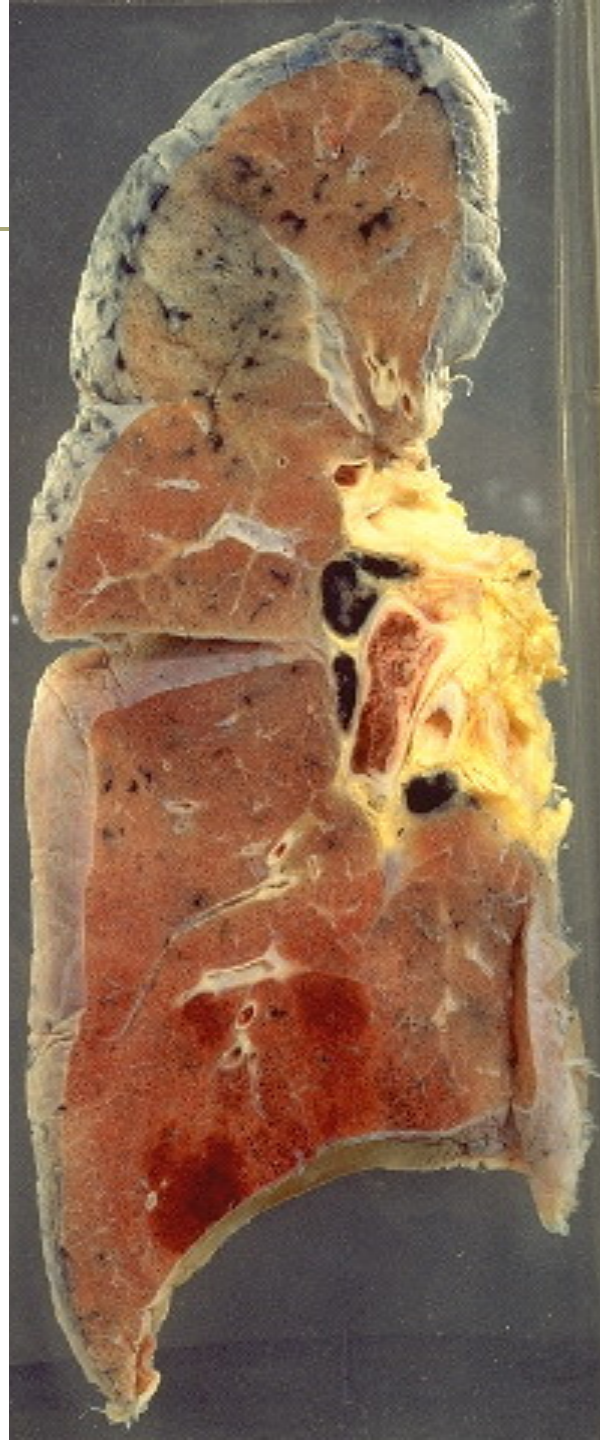

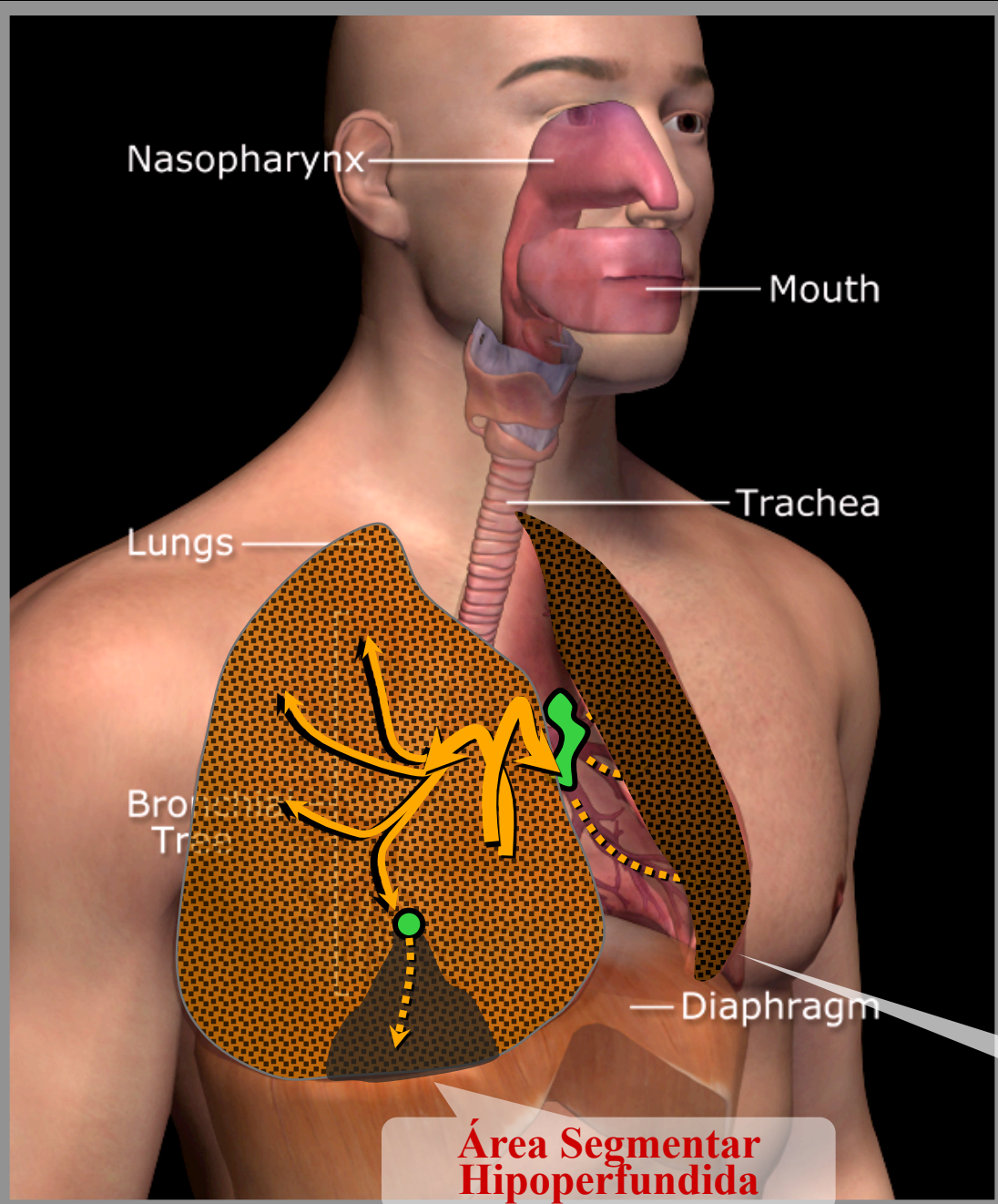
Embolism




When an embolus lodges within a vessel and blocks blood supply, the condition is called an embolism.

© 2004 - Duplication not permitted





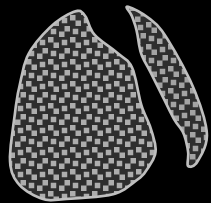
**PERFUSÃO**  
Defeito Segmentar P.D.  
+  
Defeito em todo P.E.



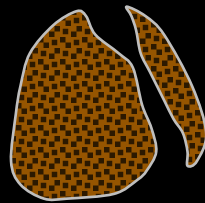
# Cintilografia V/Q Pulmonar

Vent

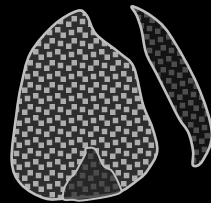
Perf




+




= Diagnóstico: **Aparentemente Normal**




+



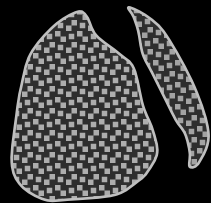
= **Defeito Concordante**: Infartos Prévios, Pneumonia Consolidada. Não TEP.




+



= **Defeito Não-Concordante**: Afeta mais a Ventilação. Pneumonias iniciais.



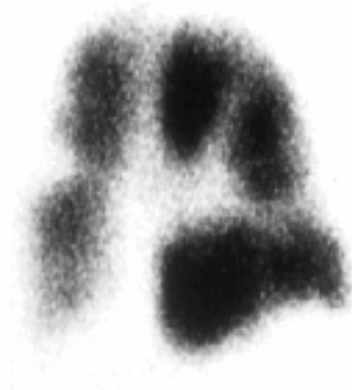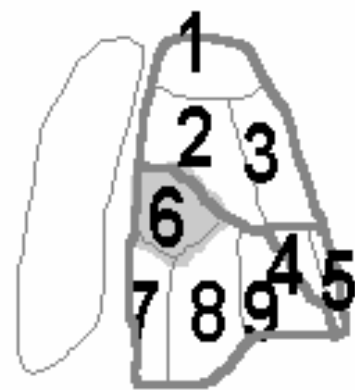
+



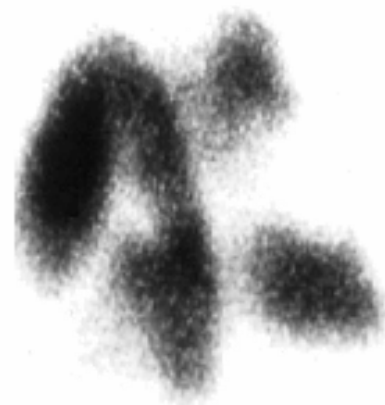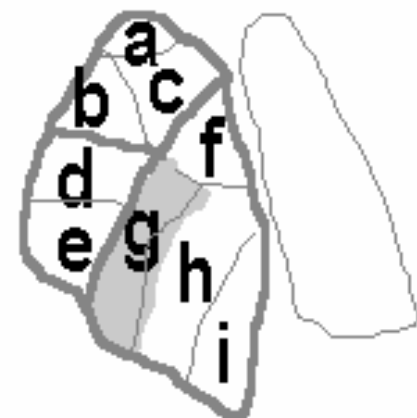= **Defeito Não-Concordante**: Afeta mais a Perfusão → TEP.

**Q**

**V**



**RPO**



**LPO**



# Estudos Fisiológicos em...

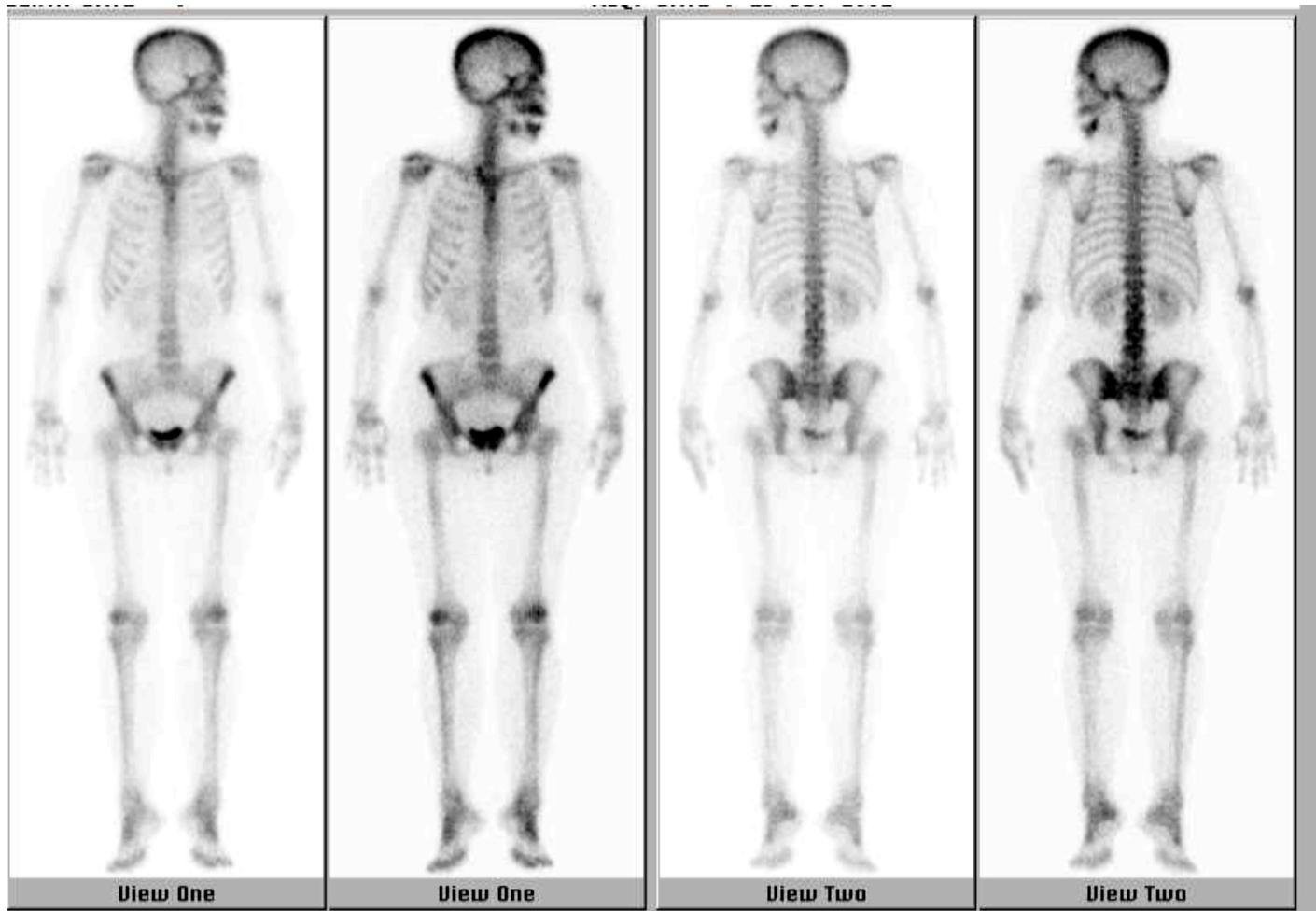
---

- Pneumologia
- **Oncologia e Ortopedia**

# Estudos Fisiológicos

$^{99m}\text{Tc}$ -MDP

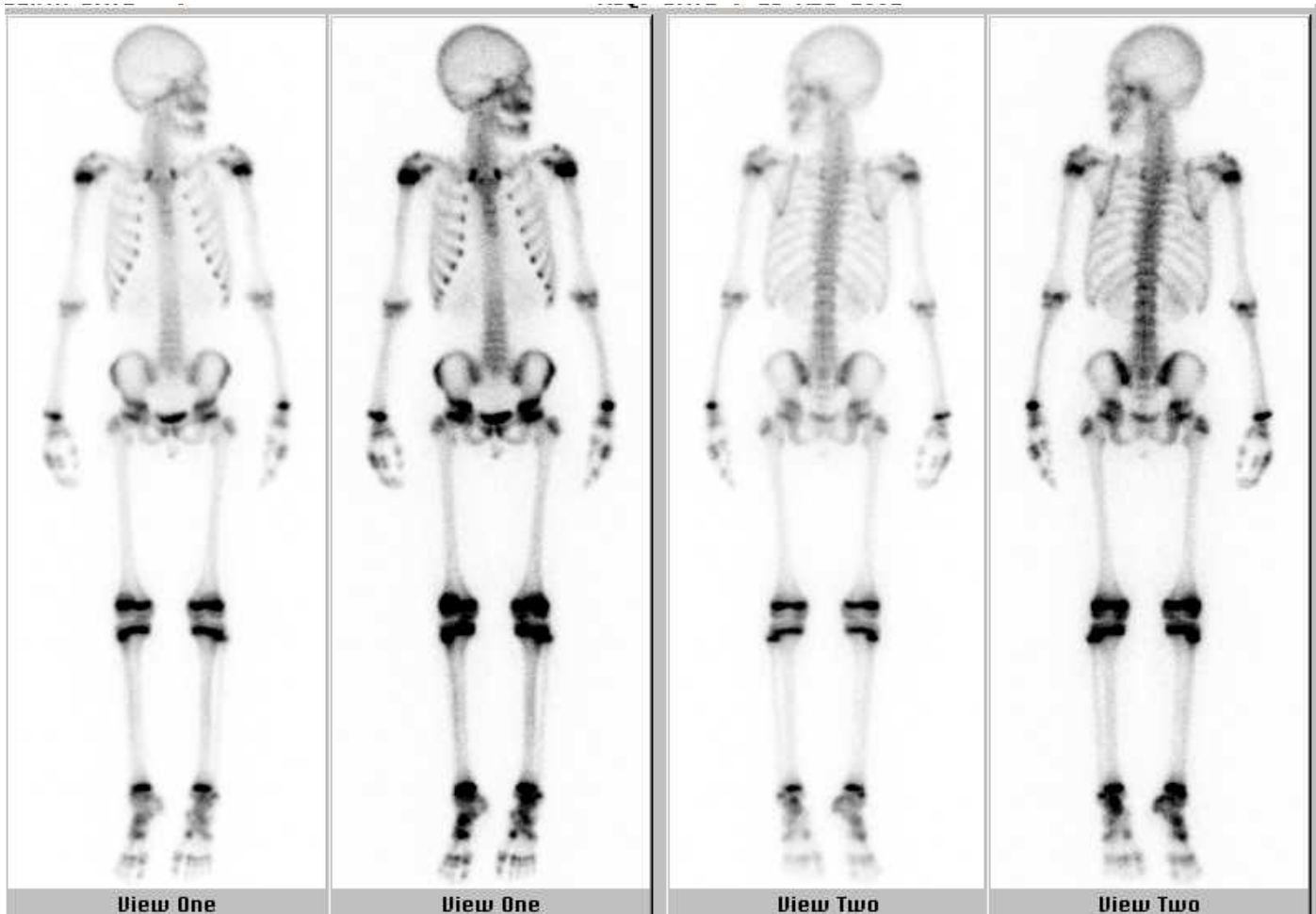
- Qual função está sendo estudada?



# Estudos Fisiológicos

$^{99m}\text{Tc}$ -MDP

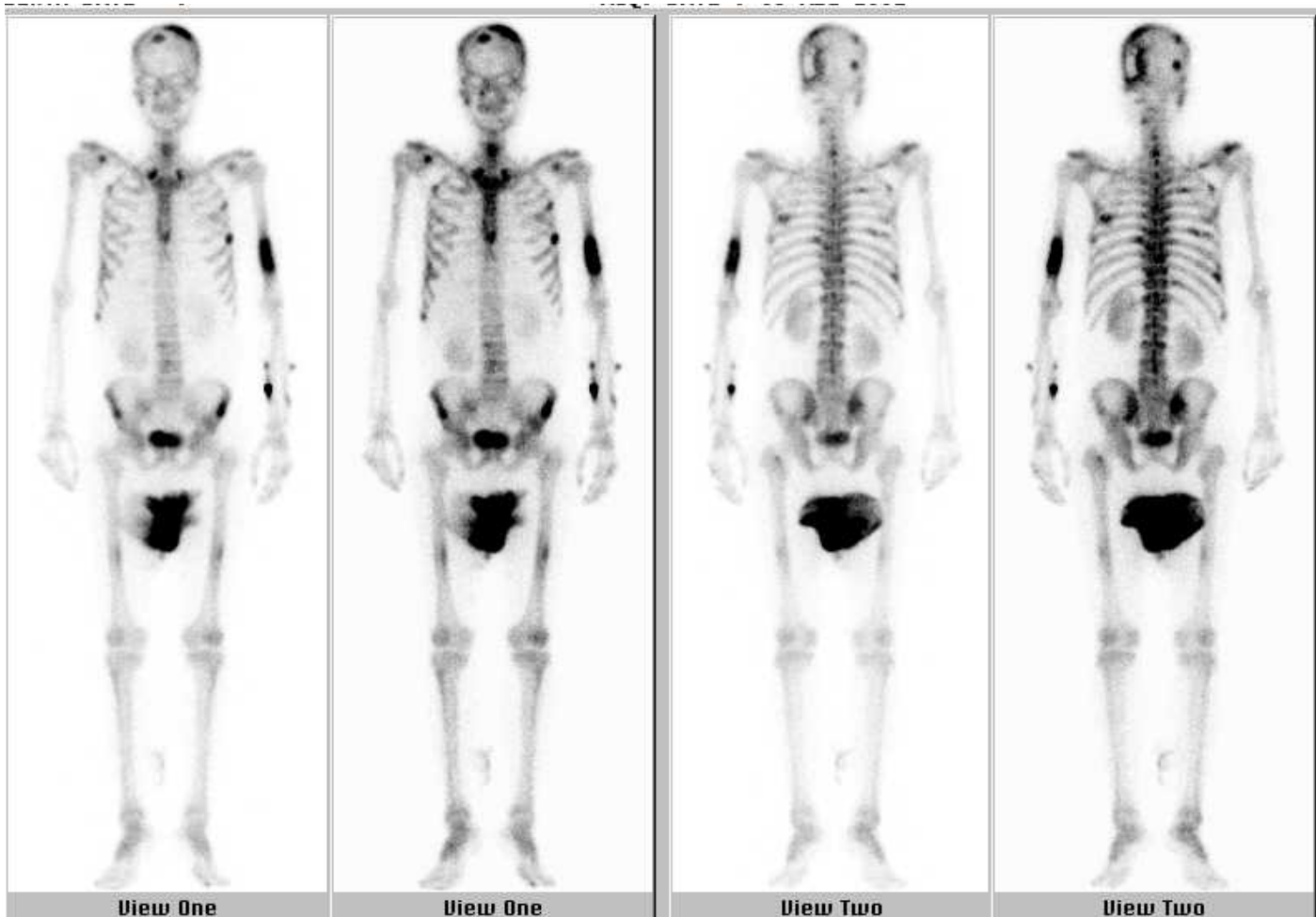
- Qual função está sendo estudada?



# Estudos Fisiológicos

$^{99m}\text{Tc}$ -MDP

- Qual a anormalidade observada?



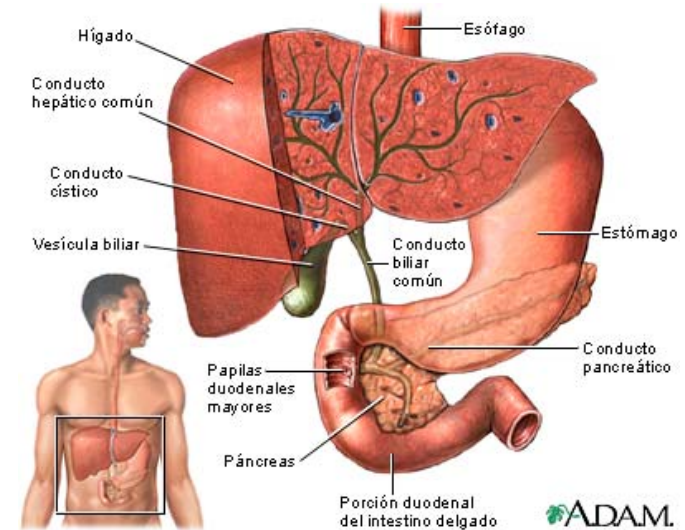
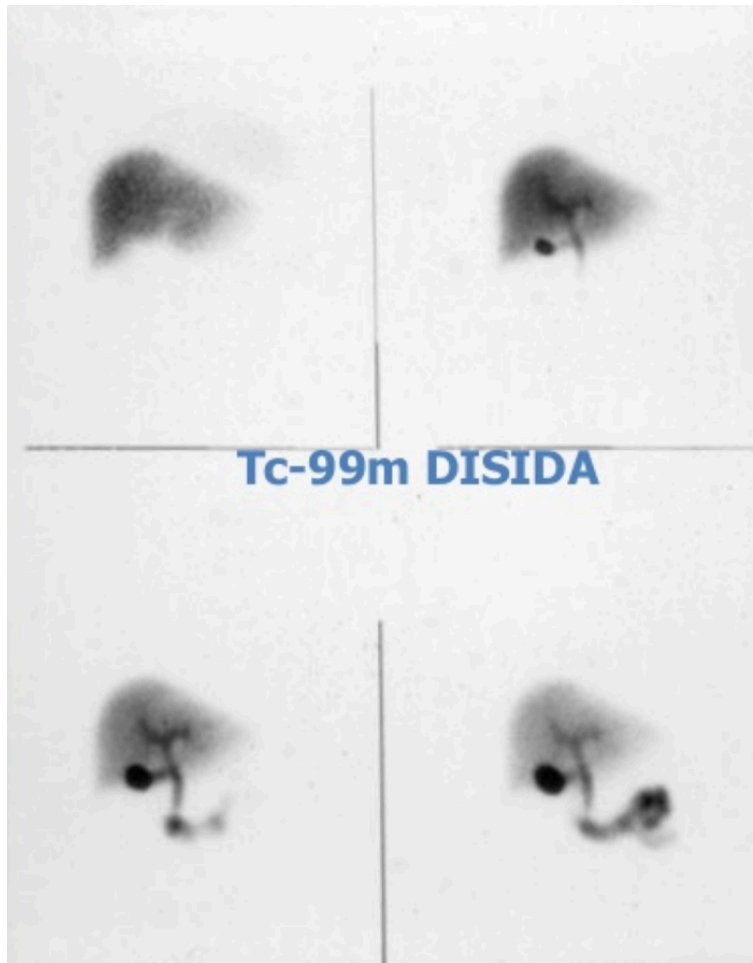
# Estudos Fisiológicos em...

---

- Pneumologia
- Oncologia e Ortopedia
- **Gastroenterologia**

# Estudos Fisiológicos $^{99m}\text{Tc}$ -DISIDA

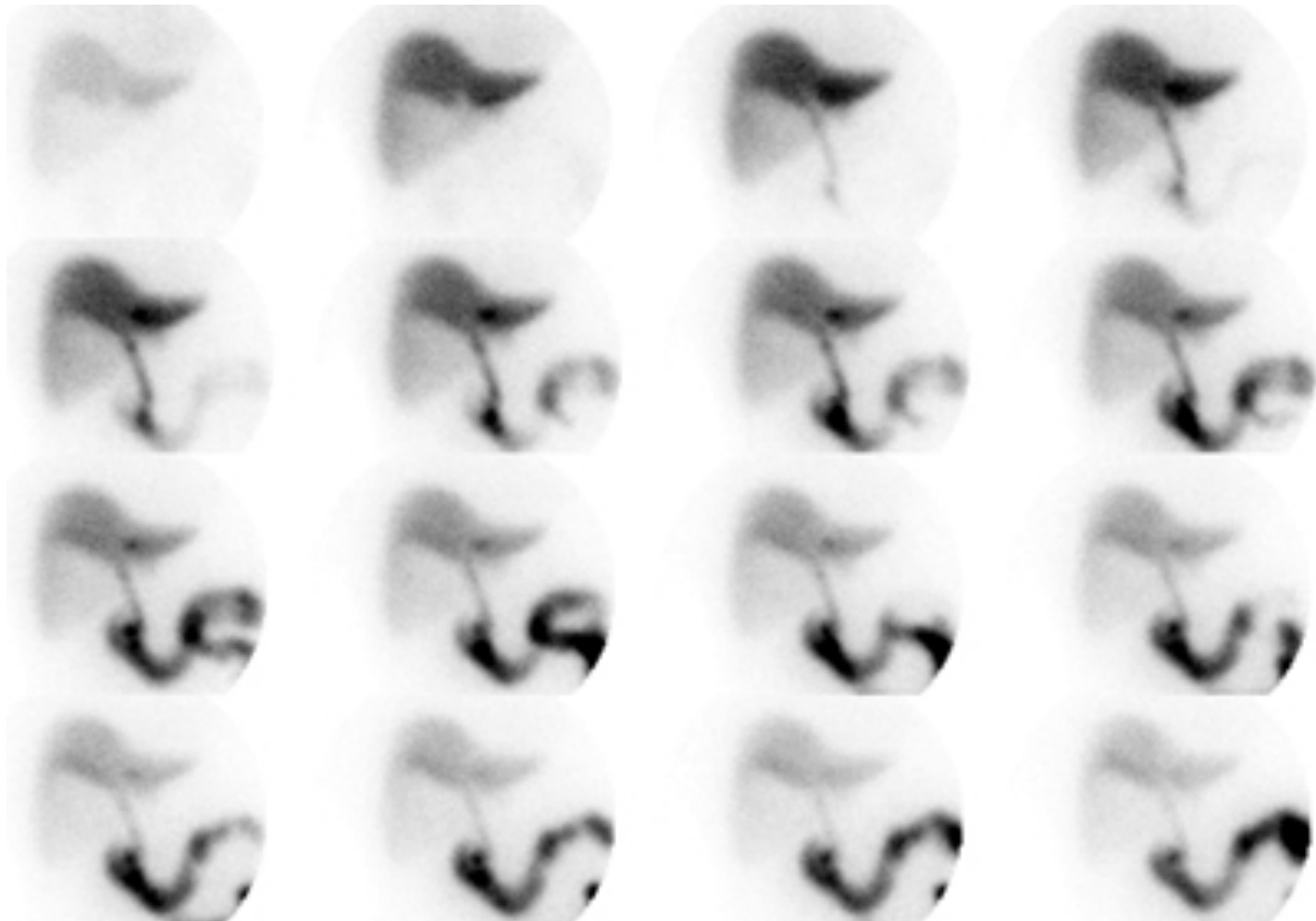
- Qual função está sendo estudada?



- Função Hepato-Biliar
- Função da Vesícula Biliar
- Patência das Vias Biliares

# Estudos Fisiológicos <sup>99m</sup>Tc-DISIDA

- Qual a anormalidade observada?



# Estudos Fisiológicos em...

---

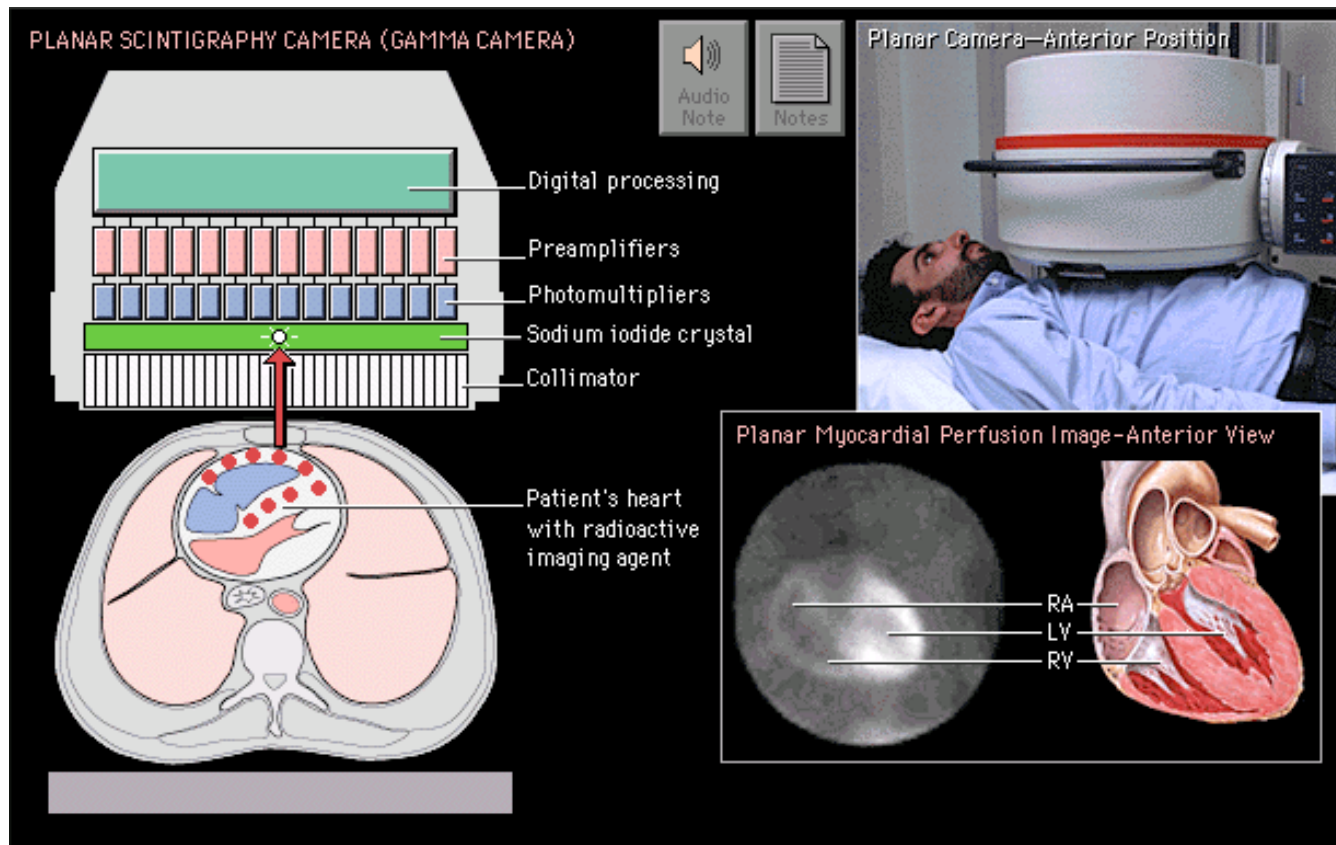
- Pneumologia
- Oncologia e Ortopedia
- Gastroenterologia
- **Cardiologia**



# Estudos Fisiológicos

$^{99m}\text{Tc}$ -SESTAMIBI

- Qual função está sendo estudada?



# Estudios Fisiológicos

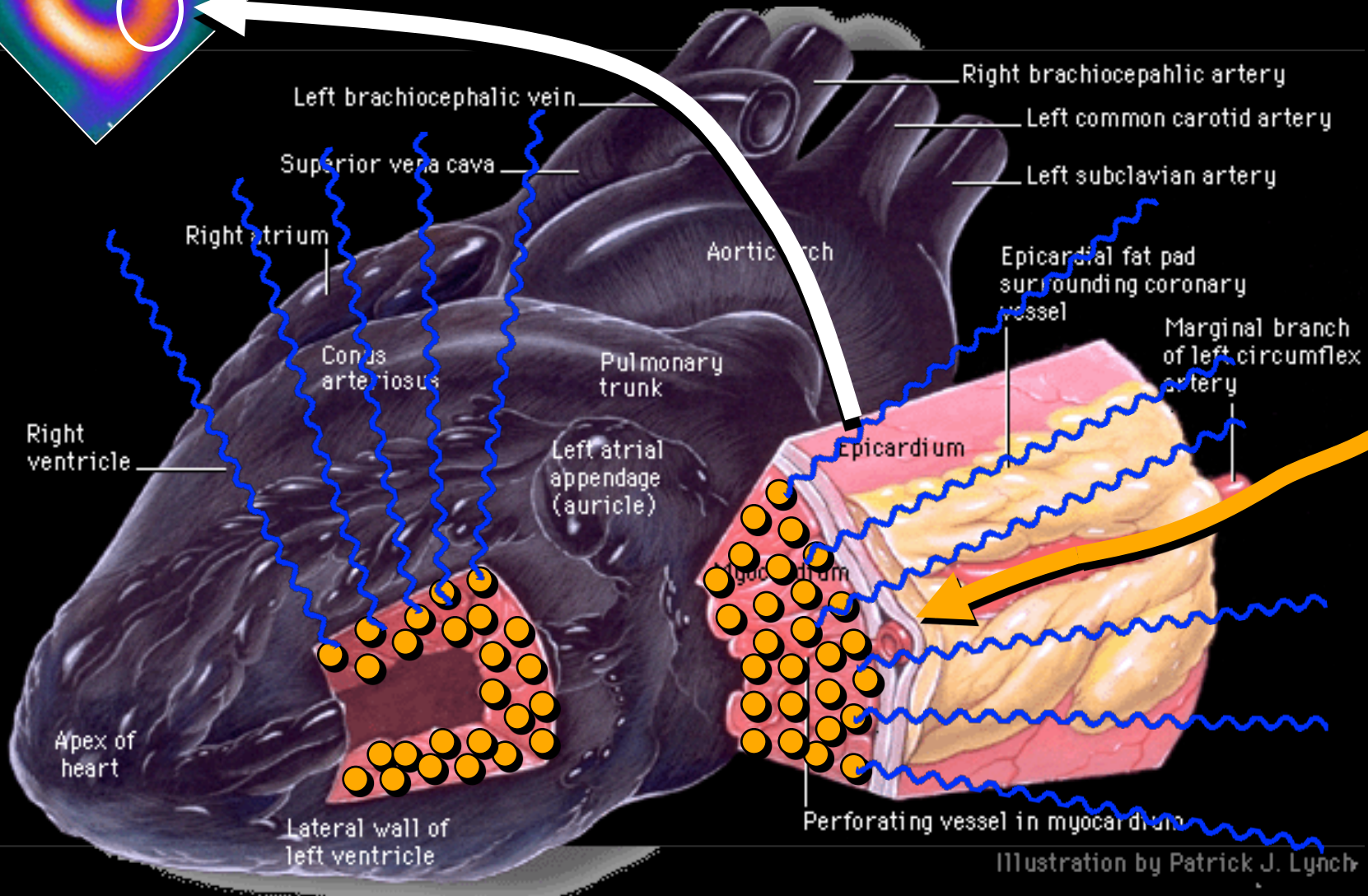
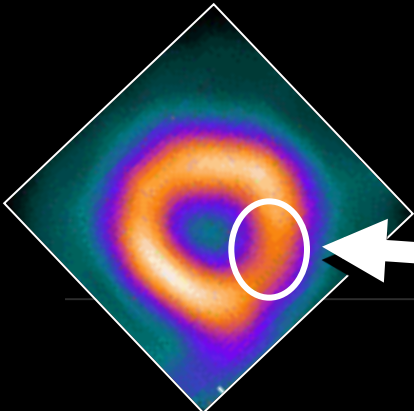


Illustration by Patrick J. Lynch

# Estudios Fisiológicos

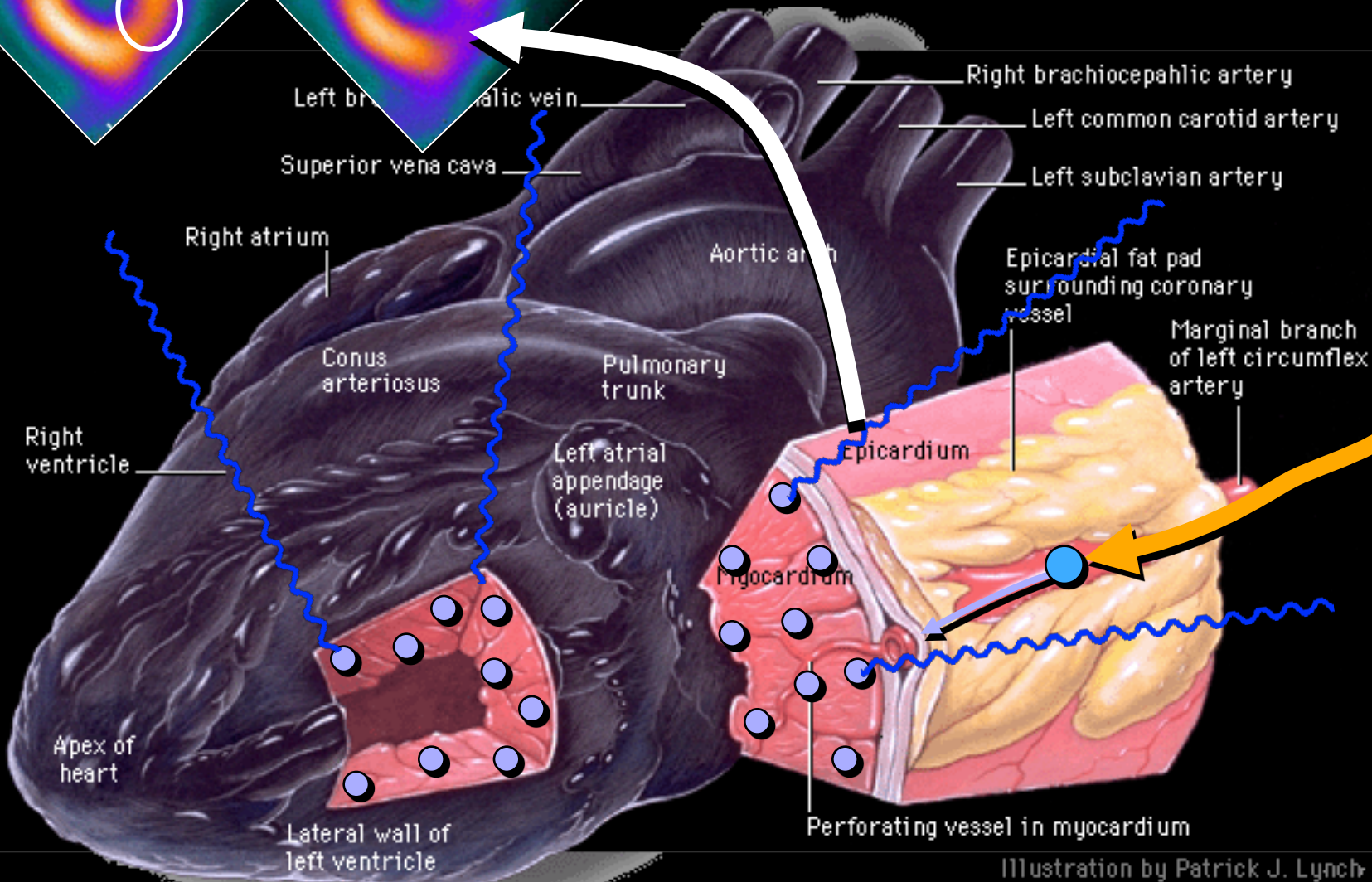


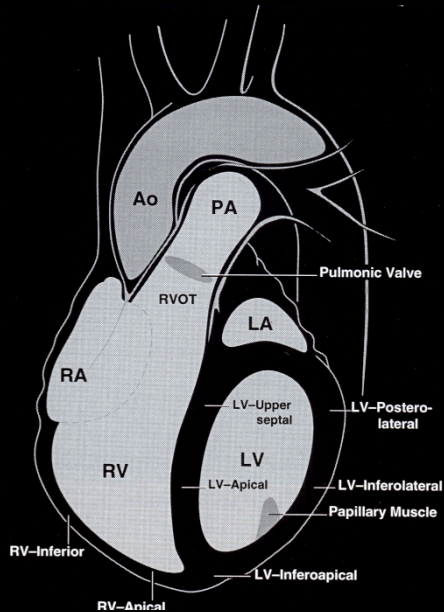
Illustration by Patrick J. Lynch

# Estudos Fisiológicos

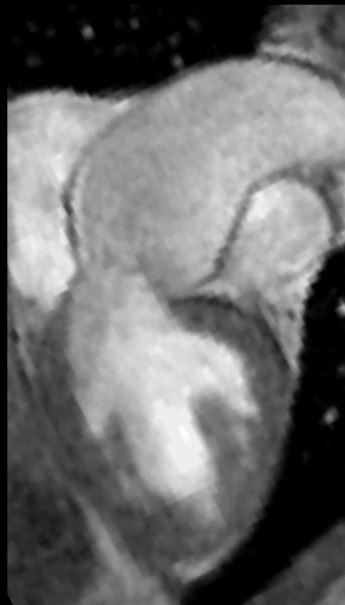
$^{99m}\text{Tc}$ -PIROFOSFATO

■ Qual função está sendo estudada?

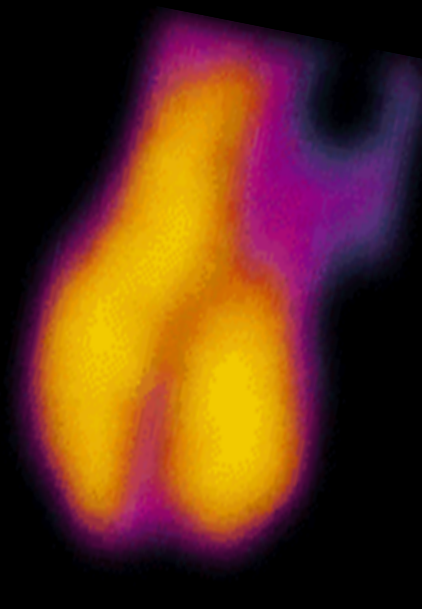Anatomia Normal



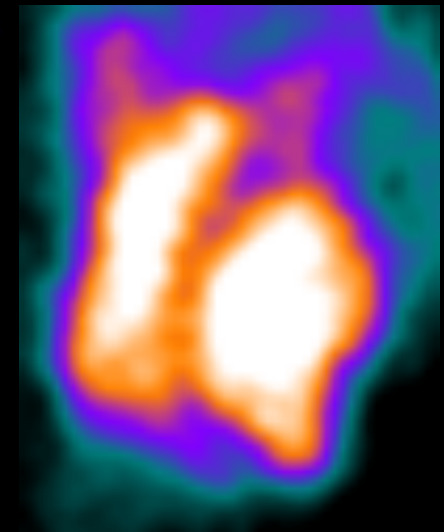
Motilidade Normal (RM)




Motilidade Normal



Discinesia Apical (Aneurisma)



# Marcação de Hemácias com Tecnécio<sup>99m</sup>



# Ventriculografia Radioisotópica

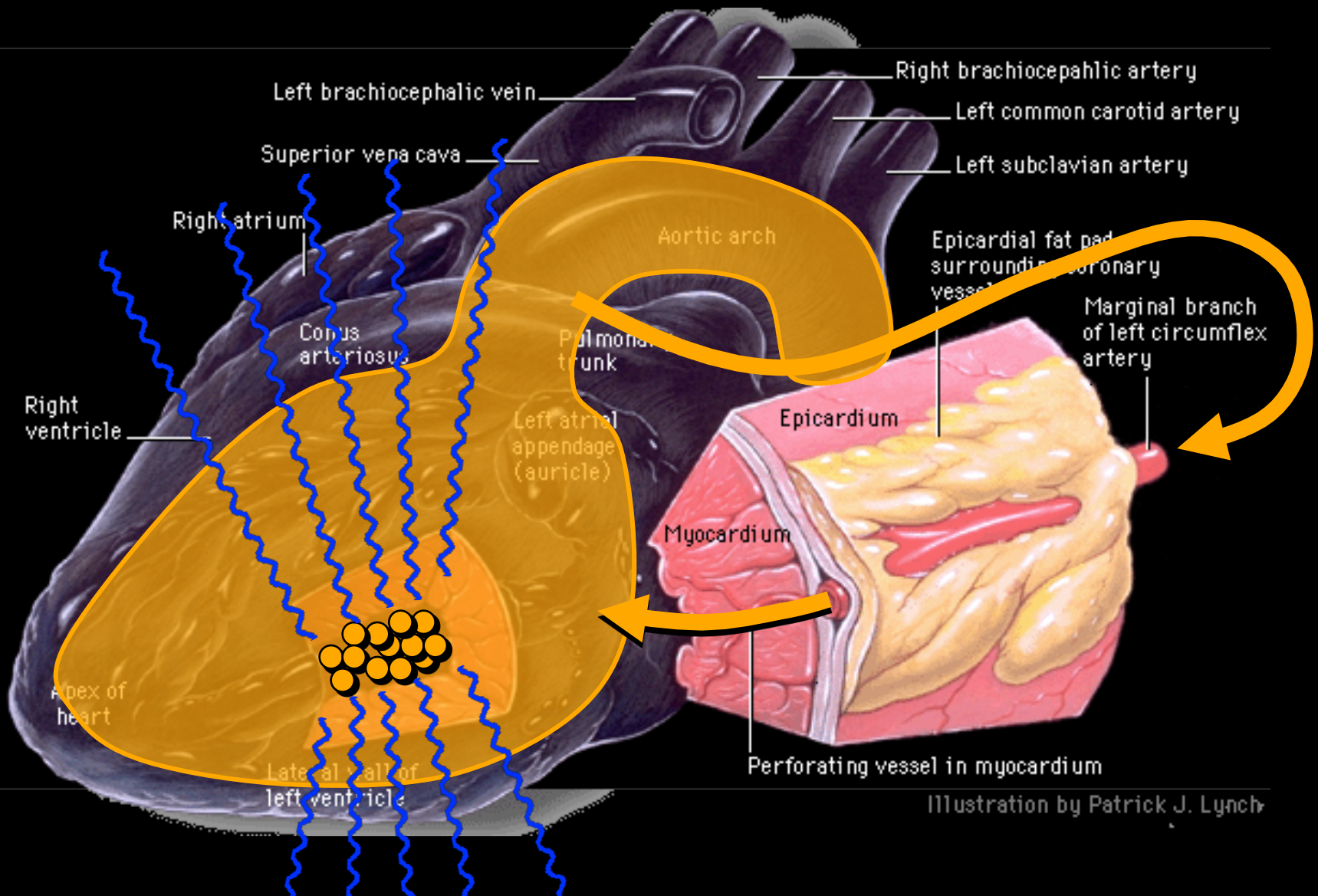
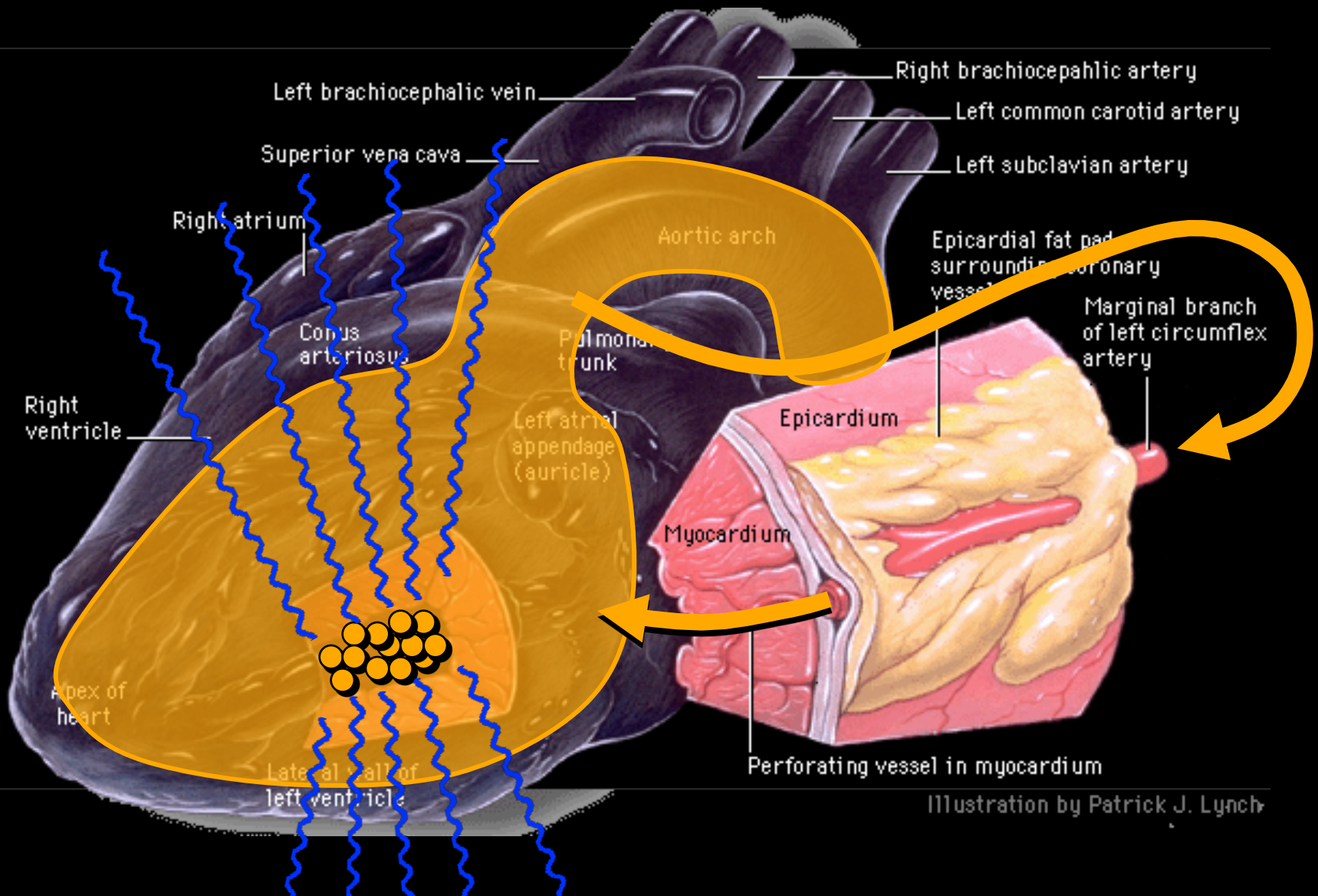


Illustration by Patrick J. Lynch

# Ventriculografia Radioisotópica



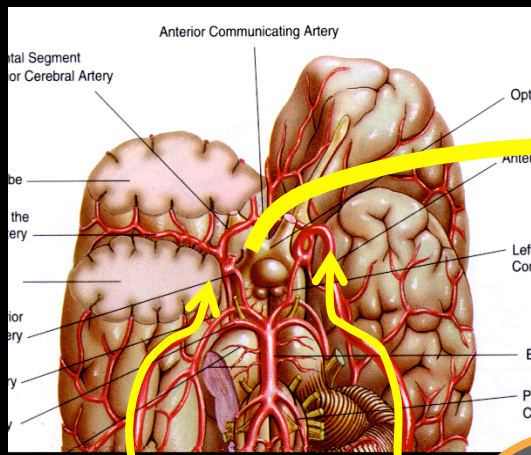
# Estudos Fisiológicos em...

---

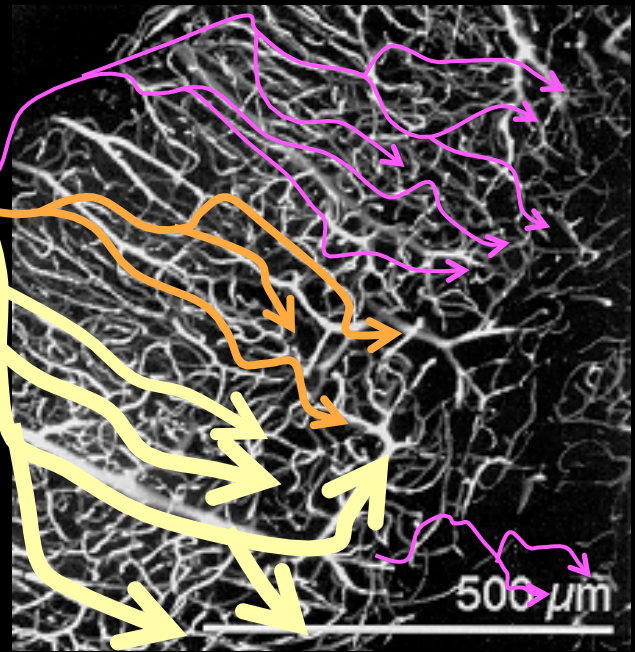
- Pneumologia
- Oncologia e Ortopedia
- Gastroenterologia
- Cardiologia
- **Neurologia e Psiquiatria**



2



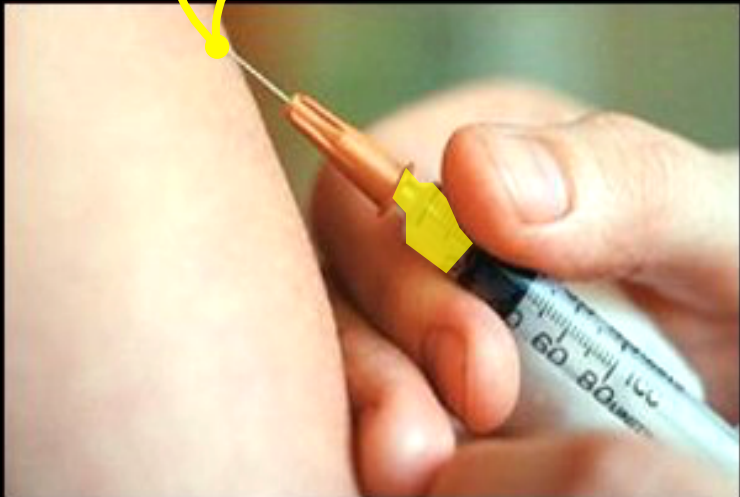3



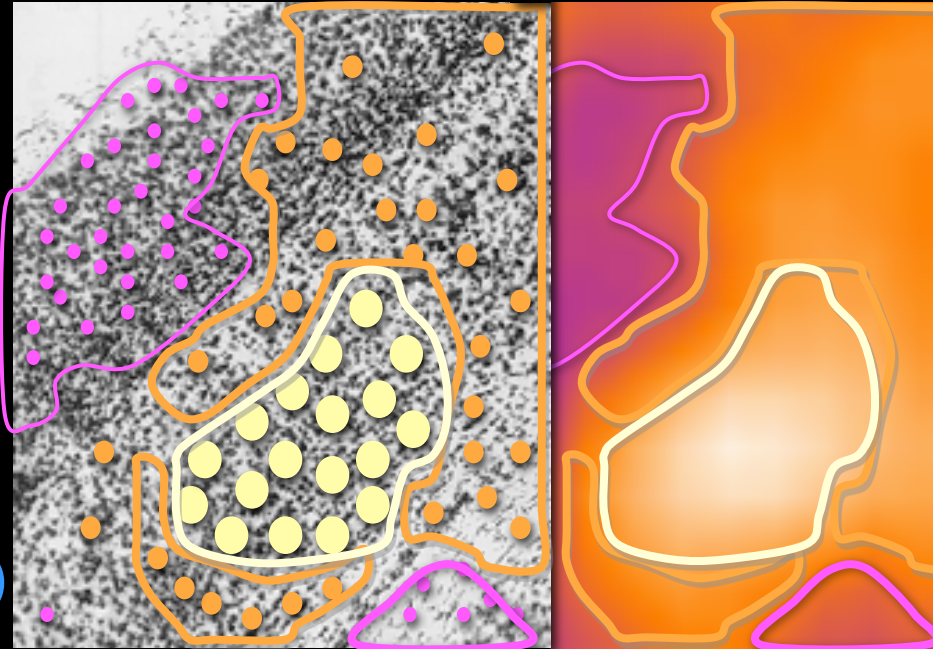
FSC 750ml/min  
Vol. = 120ml

20% DC

1

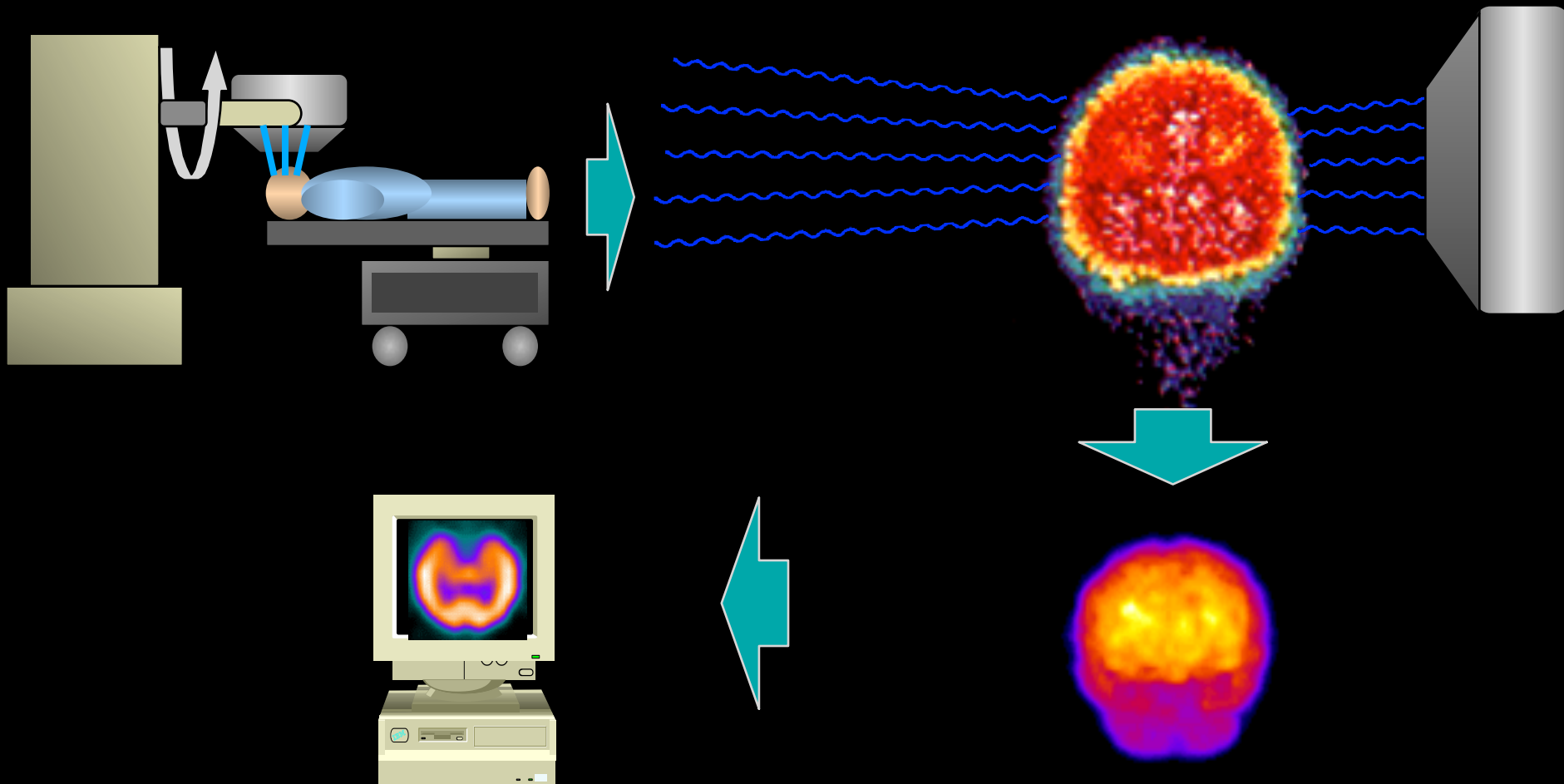


4

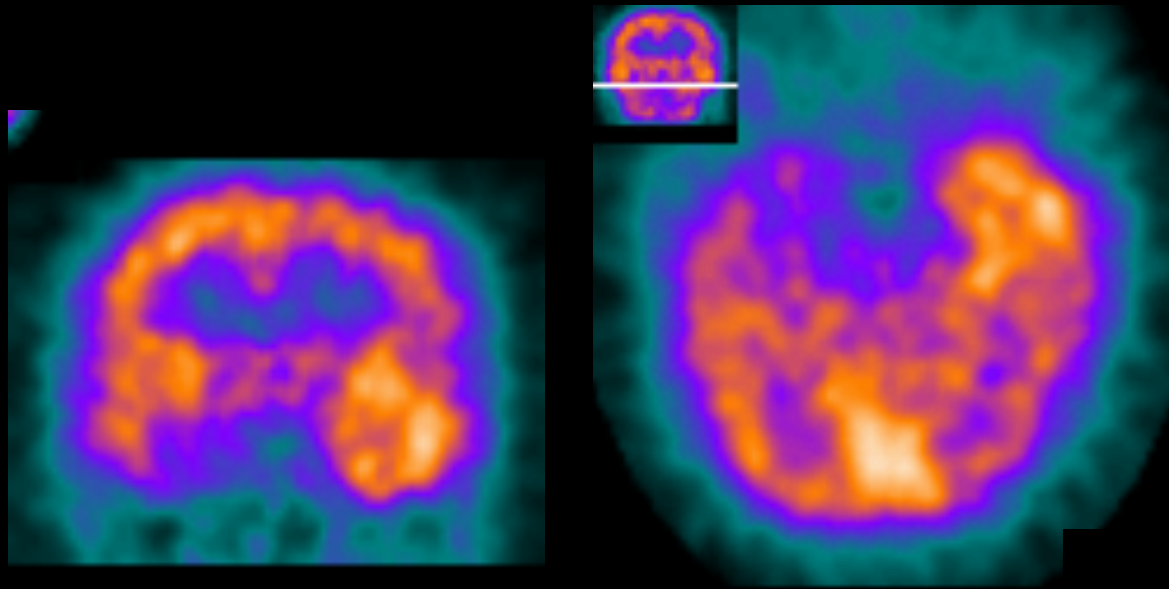


# Estudos Fisiológicos

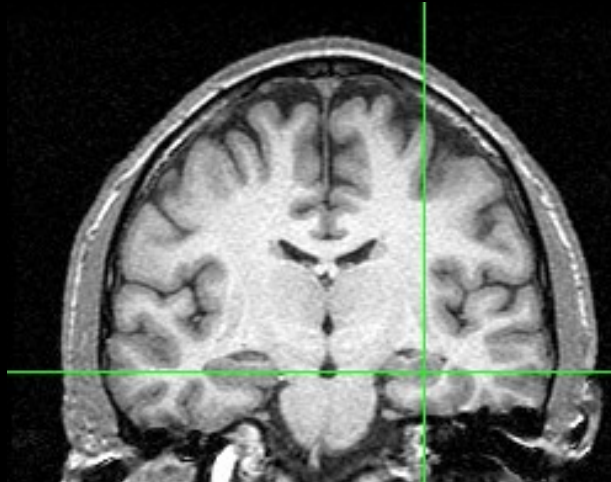
- Qual função está sendo estudada?



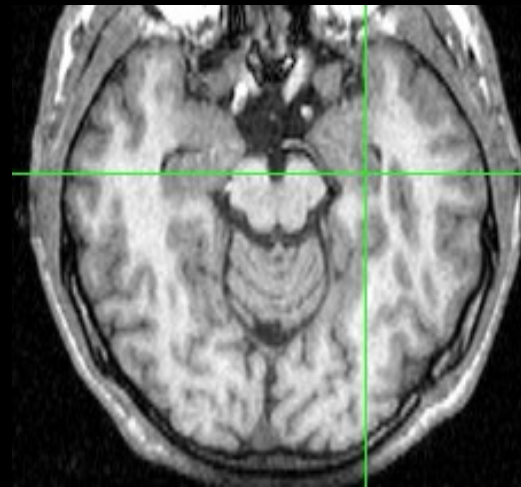
# SPECT Crítico

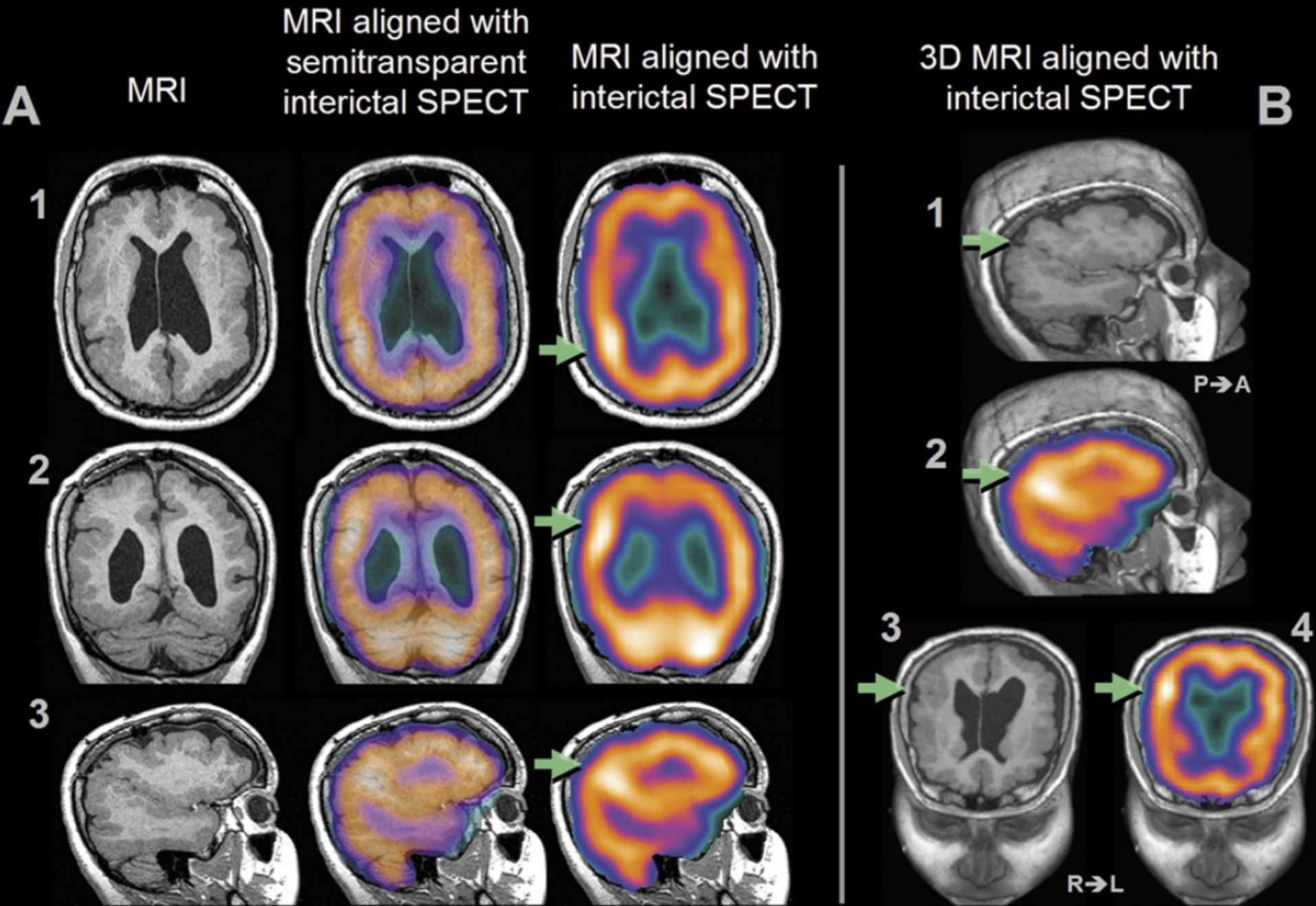


**D**



**E**





# Conclusões

LWICHERT@FMRP.USP.BR