

## Treatment-Induced Cortical Reorganization After Stroke in Humans

Joachim Liepert, MD; Heike Bauder, PhD; Wolfgang H.R. Miltner, PhD;  
Edward Taub, PhD; Cornelius Weiller, MD

**Background and Purpose**—Injury-induced cortical reorganization is a widely recognized phenomenon. In contrast, there is almost no information on treatment-induced plastic changes in the human brain. The aim of the present study was to evaluate reorganization in the motor cortex of stroke patients that was induced with an efficacious rehabilitation treatment.

**Methods**—We used focal transcranial magnetic stimulation to map the cortical motor output area of a hand muscle on both sides in 13 stroke patients in the chronic stage of their illness before and after a 12-day-period of constraint-induced movement therapy.

**Results**—Before treatment, the cortical representation area of the affected hand muscle was significantly smaller than the contralateral side. After treatment, the muscle output area size in the affected hemisphere was significantly enlarged, corresponding to a greatly improved motor performance of the paretic limb. Shifts of the center of the output map in the affected hemisphere suggested the recruitment of adjacent brain areas. In follow-up examinations up to 6 months after treatment, motor performance remained at a high level, whereas the cortical area sizes in the 2 hemispheres became almost identical, representing a return of the balance of excitability between the 2 hemispheres toward a normal condition.

**Conclusions**—This is the first demonstration in humans of a long-term alteration in brain function associated with a therapy-induced improvement in the rehabilitation of movement after neurological injury. (*Stroke*. 2000;31:1210-1216.)

**Key Words:** plasticity, neuronal ■ transcranial magnetic stimulation ■ reorganization ■ physical therapy ■ stroke

Research with animals has led to the discovery that cortical reorganization occurs after injury to the nervous system.<sup>1-3</sup> Spontaneously occurring cortical reorganization phenomena that result from nervous system damage or conditions that involve abnormal sensory input have been shown to be associated with pathological states in humans; these include phantom limb pain,<sup>4</sup> tinnitus,<sup>5</sup> and focal hand dystonia.<sup>6</sup> After motor stroke, a complex pattern of reorganization has been described.<sup>7-20</sup> In the subacute stage after a stroke, a reduction in motor cortex excitability and a decrease in the cortical representation area of paretic muscles have been found to occur.<sup>17,19</sup> This may represent a disadvantageous reorganization associated with an impaired motor function and could be due to the damage of neuronal structures or could reflect the disuse of the affected limb.<sup>21,22</sup> In addition to injury-related cortical reorganization, there is a second kind of process, use-dependent cortical reorganization, that results from the increased use of body parts in behaviorally relevant tasks and leads to an enhancement of the representation of those body parts in the cerebral cor-

tex.<sup>21,23-26</sup> It is possible that this process could be used to remediate pathological symptoms through the reversal or elimination of disadvantageous cortical reorganization produced with nervous system damage.

Constraint-induced movement therapy (CI therapy) has been shown in controlled studies to be efficacious in chronic stroke patients.<sup>27</sup> At this stage of their illness, these patients are presumed to have a stable motor deficit.<sup>28-30</sup> Moreover, the short duration of CI therapy (12 days) further minimizes the possibility that spontaneous recovery of function could give the appearance of a treatment effect. CI therapy stems jointly from basic research in neuroscience with monkeys with somatosensory deafferentation of a single forelimb and from behavioral psychology.<sup>31,32</sup> The effective therapeutic factor in this treatment<sup>33,34</sup> appears to be the massing or concentration of practice in use of the extremity affected by a stroke for many hours a day during a period of consecutive weeks. This therapy has been found to produce a substantial long-term improvement in the amount of use of an affected upper extremity that transfers into the real world environ-

Received December 21, 1999; final revision received March 9, 2000; accepted March 9, 2000.

From the Departments of Neurology (J.L., C.W.) and Biological and Clinical Psychology (H.B., W.H.R.M.), Friedrich-Schiller-University of Jena, Jena, Germany; and Department of Psychology (E.T.), University of Alabama at Birmingham and Physical Medicine Service, Birmingham VA Medical Center.

Correspondence to Priv-Doz Dr J. Liepert, Neurologische Klinik der Friedrich Schiller Universität, Philosophenweg 3, D-07743 Jena, Germany. E-mail liepert@neuro.uni-jena.de

© 2000 American Heart Association, Inc.

Stroke is available at <http://www.strokeaha.org>

ment.<sup>34–38</sup> It is possible that CI therapy might produce its therapeutic effect through the induction of a use-dependent cortical reorganization that counteracts adverse brain function changes and enhances recovery-associated plastic changes that occur in the human brain after stroke.<sup>7–9,17–19</sup>

The main goal of the present study was not to evaluate the clinical effects of CI therapy or to compare this treatment with other physiotherapeutic approaches but rather to use CI therapy as a model to assess therapy-induced plasticity in stroke patients. Therefore, we did not introduce a control group. However, we did use a control procedure (ie, 2 complete pretreatment test batteries separated by the same length of time required by the intervention), and placebo controls have been used in other CI therapy research.<sup>34,38</sup>

We used focal transcranial magnetic stimulation (TMS) to assess plastic alterations that may have been induced by CI therapy. TMS involves the noninvasive mapping of motor regions of the brain to determine the cortical representation areas of muscles with the use of a focused magnetic field to stimulate loci in motor areas from points on the scalp. It has been used to assess the amount of reorganization of motor representations consequent to injury of the peripheral and central nervous systems and after various conditions of use.<sup>17–19,39–55</sup> The amplitude-weighted center of the TMS map of a hand muscle corresponds closely to the hand area within the primary motor cortex as determined with anatomic and functional MRI (fMRI) studies.<sup>56–59</sup> In contrast to typical fMRI or positron emission tomography (PET) experiments in stroke patients, TMS mapping is performance independent and therefore ideally suited for longitudinal studies as in rehabilitation of stroke, where motor ability may change markedly. Preliminary results from a limited sample of patients had indicated that motor cortex reorganization occurs immediately after CI therapy.<sup>60</sup> In contrast to this earlier study, we performed TMS mappings and evaluations of motor functions in parallel at several time points before and after CI therapy to investigate the stability of the baseline and to determine short- and long-term effects of the therapy on the functional organization of the primary motor area of the brain in relation to clinical recovery.

## Subjects and Methods

Thirteen patients (10 men; mean age  $56.7 \pm 10.3$  years, age range 33 to 73 years; duration of hemiparesis  $4.9 \pm 4.7$  years [mean  $\pm$  SD], range 0.5 to 17 years) with chronic stroke ( $>6$  months) were studied. Eleven of the subjects had a right-sided paresis; 3 had cortical lesions (2 ischemic and 1 hemorrhagic in origin), and 10 had lacunar subcortical lesions that involved the internal capsule. Informed consent for participation in the study was obtained from all patients. The study was approved by the local ethics committee.

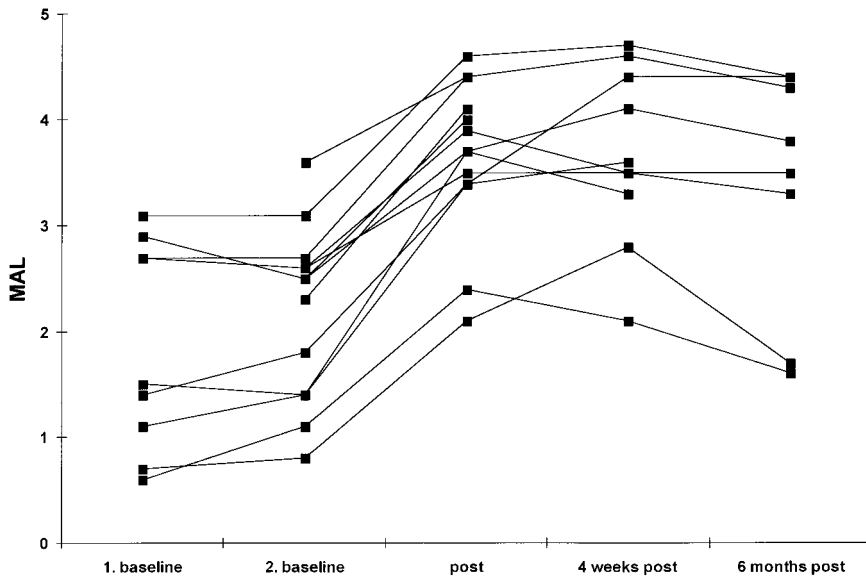
Functional inclusion criteria were (1) the ability to extend  $\geq 20^\circ$  at the wrist and  $10^\circ$  at the fingers and (2) sufficient stability to walk when the less-affected arm is immobilized. Exclusion criteria were (1) serious uncontrolled medical conditions, (2) global aphasia or cognitive impairments that might interfere with understanding instructions for motor testing, (3) anything in the head that contained metal, (4) pregnancy, (5) epilepsy, and (6) cardiac pacemaker.

Each subject received 12 days of CI therapy preceded and followed by periods in which electrophysiological, neurological, and behavioral testing was conducted. For CI therapy, subjects agreed to wear a resting hand splint secured in a sling that prevented use of the nonparetic upper extremity for a target of 90% of waking hours. This

arrangement induced greatly increased use of the paretic arm. In addition, on the 8 weekdays during the treatment period, the subjects came into the laboratory and received 6 hours per day of training in use of the affected arm in a variety of tasks according to a behavioral technique termed “shaping.”<sup>61</sup> The shaping was designed to produce intensive use of the more-affected extremity while at the same time improving the quality of movement. Treatment efficacy was evaluated with the motor activity log (MAL),<sup>34</sup> which tracked arm use in 20 common and important activities of daily living (ADL) performed outside the laboratory (1) for the week before the subject’s visit to the laboratory 2 weeks before the beginning of treatment, (2) for the week before the beginning of treatment, (3) 1 day after treatment, and (4) 4 weeks and (5) 6 months after the end of treatment (follow-up). The MAL has exhibited excellent intertest reliability for chronic stroke patients across a 2-week interval equal in length to the treatment period when no treatment was provided<sup>37</sup> and when a placebo treatment was administered.<sup>36</sup> Further details of the intervention and testing are available elsewhere.<sup>34,37</sup> We mapped the cortical output area of the abductor pollicis brevis (APB) muscle of the more-affected and less-affected hands with TMS on the same day as the MAL was administered 1 day before treatment and 1 day and 4 weeks after treatment. (Two subjects died before the 4-week posttreatment testing could be carried out, and 1 subject had to be excluded at this time because of the intervening occurrence of an epileptic seizure.) As a control procedure, to confirm the stability of the electrophysiological and behavioral measures, 10 subjects were tested 2 weeks before the beginning of treatment. This is the same temporal interval that separates the second pretreatment and posttreatment tests and therefore controls for such nonspecific effects as expectancy of improved extremity function, initial contact with experimenters, and increased attention to use of the affected upper extremity. During the period between the testing 2 weeks and 1 day before treatment, there was no contact between patients and the project. Eight subjects have been tested 6 months after treatment to date.

For magnetic stimulation, we used a figure-8 coil (The Magstim Company) kept in an anteroposterior position with the grip pointing backward. The coil was moved systematically over the skull in steps of 1 cm to identify all scalp positions whose stimulation produced an EMG response in APB muscle. “Motor threshold” was defined as the minimal intensity of stimulation capable of inducing motor evoked potentials (MEPs) of  $>0.05$  mV in at least 5 of 10 trials. Five transcranial magnetic pulses with an intensity 10% above the individual motor threshold were applied over each position to be tested. Both hemispheres were studied consecutively in a pseudo-random order. MEPs were recorded with surface electrodes from the contralateral and the ipsilateral APB muscle, respectively (Viking IV; Nicolet).

The subjects were seated comfortably in a chair with hands resting in their laps and wore a tight-fitting cap with a coordinate system (distances of 1 cm) indicated on it. They were provided with information about their muscular tension through auditory signals presented over a speaker that were proportional to the amount of prestimulation EMG activity recorded from APB muscle. The instruction was to relax the target muscle completely during the TMS mapping. Three parameters were used for analysis of the neurophysiological data: (1) size of the cortical motor output map, defined as the number of positions whose stimulation evoked MEPs of  $>0.05$  mV, (2) motor thresholds, expressed as a percentage of the maximal stimulator output intensity, and (3) location of the amplitude-weighted center of gravity (CoG) of the motor output map. A detailed description of the calculation of the CoG is given elsewhere.<sup>62</sup> Changes in all parameters were calculated for the more-affected and less-affected hemispheres. The investigator who performed the TMS mapping (J.L.) was blinded for the motor treatment outcome data. The experimenter who evaluated the motor function (H.B.) was blinded for the TMS mapping data. The behavioral and electrophysiological data were analyzed with repeated measures ANOVAs, followed by Tukey’s tests. Bonferroni-corrected paired *t* tests were used to compare the motor output area size of the affected



**Figure 1.** MAL scores 2 weeks and 1 day before treatment and 1 day, 4 weeks, and 6 months after treatment for each patient.

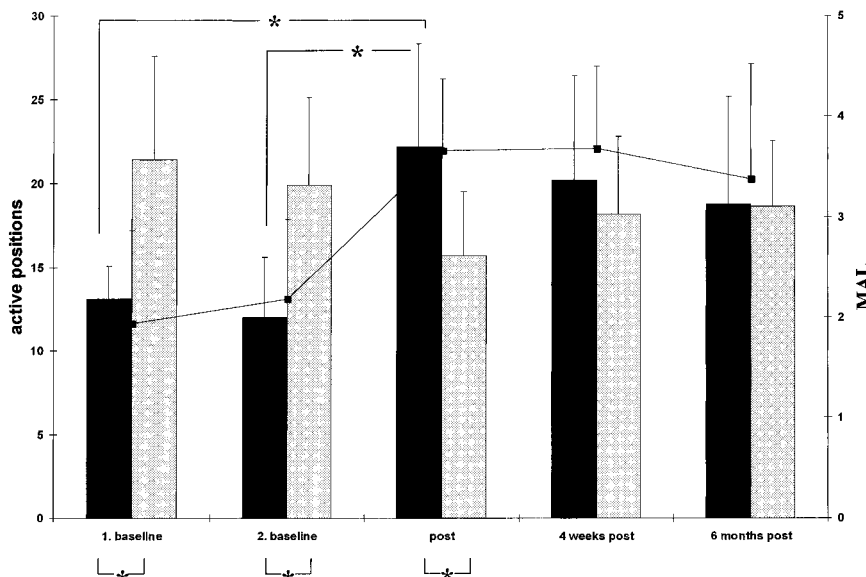
and the unaffected hemisphere at each measurement day.  $P < 0.05$  was used as the criterion for statistical significance.

**Results**

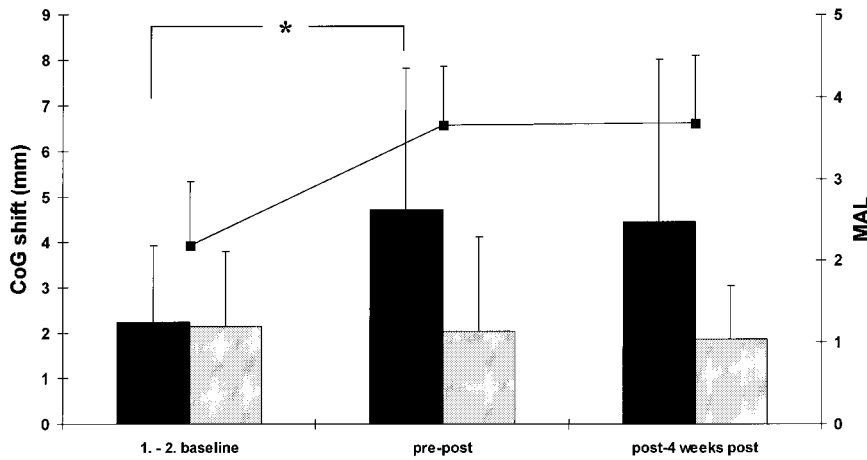
The MAL data are presented in Figure 1. CI therapy produced a significant and large improvement in motor functions from 1 day before treatment to 1 day after treatment ( $t_{12} = -12.781$ ,  $P < 0.0001$ ). The MAL scores at 2 weeks and 1 day before treatment were not significantly different from each other. The treatment gain persisted undiminished in follow-up. Four weeks after treatment, the MAL scores were not significantly different from the scores at 1 day after treatment ( $t_9 = -1.026$ , NS). A separate analysis for just the 8 subjects for whom there were 6-month follow-up data indicated that, again, the change from day 1 before treatment to the first day after treatment was significant ( $F_{4,20} = 31.4$ ,  $P < 0.001$ ,  $\epsilon = 0.336$ ) and that the change remained undiminished 4 weeks and 6 months after treatment. The subjects scored a mean of 2.2 on the MAL 1 day before treatment and a mean of 3.7 at 1 day

after treatment. To provide an idea of the nature of the treatment change, a score of 2 indicates slight use; 3, half as much use as before stroke, and 4, three fourths as much use as before stroke. The effect size was 1.5; in the meta-analysis literature, effect sizes of  $>0.8$  are considered large.<sup>63</sup> Clinical and electrophysiological results were very similar in patients with cortical and subcortical strokes ( $P > 0.1$ ), so the data from both groups were combined.

The TMS mapping data 1 day after treatment paralleled the behavioral results. Figure 2 indicates that the area of the cortex that yielded a response of the paretic hand muscle to stimulation of the contralateral hemisphere showed a massive increase from 1 day before treatment to 1 day after treatment. One day before treatment, there were 40% fewer active positions in the infarcted hemisphere than in the noninfarcted hemisphere ( $P < 0.001$ ). By the first day after treatment, this relationship had reversed, with 37.5% more active positions in the infarcted hemisphere than in the noninfarcted hemisphere. The number of active positions in the infarcted



**Figure 2.** Number of active TMS positions in the infarcted (black bars) and noninfarcted (gray bars) hemisphere 2 weeks and 1 day pretreatment and 1 day, 4 weeks, and 6 months after treatment. ■, Corresponding MAL data for the paretic limb. \* $P < 0.05$



**Figure 3.** Differences in the location of the center of the cortical motor output map (CoG) in comparisons of the 2 pretreatment baseline conditions with each other, pretreatment with posttreatment, and posttreatment with 4-weeks posttreatment. Shifts of CoG location in the infarcted (black bars) and noninfarcted (gray bars) hemisphere were tabulated independent of lateromedial direction. ■, Corresponding MAL data for the paretic limb at the second baseline, posttreatment, and 4-week posttreatment time points. \* $P < 0.05$

hemisphere had nearly doubled from before to after treatment (12 to 22 active positions;  $P = 0.002$ ). At the same time, the number of active positions in the noninfarcted hemisphere was nonsignificantly reduced. Four weeks after treatment, the motor output map of the affected side was still significantly larger than before therapy ( $P = 0.036$ ). There was a small, nonsignificant decrease in the number of infarcted hemisphere active positions and a similarly small increase in noninfarcted hemisphere active positions. The result of these 2 opposite changes was to normalize hemispheric responsivity, making the number of active positions on the 2 sides of the brain nearly equal (ie, approaching the condition in normal subjects). Six months after treatment, the trend toward normalization observed 4 weeks after therapy was even more evident. The TMS data obtained 2 weeks before treatment and, after a 2-week nontreatment interval, at 1 day before treatment (Figure 2) showed a close correspondence.

The amplitude-weighted center of activation sites or CoG showed almost identical results in both hemispheres on comparison of the 2 baseline measurements (Figure 3) (mean displacement 2 mm). These small shifts could be due to technical limitations of the method<sup>62,64</sup> or could indicate spontaneous fluctuations of the location of the center of the representation map. The CoG showed a significantly larger shift in the mediolateral dimension in the infarcted hemisphere than in the noninfarcted from 1 day before to 1 day after treatment (Figure 3,  $P < 0.01$ ). Nine of the shifts were in the lateral direction, whereas 4 of the shifts were medial. No significant changes were observed in the anteroposterior direction. Between 1 day after treatment and 4 weeks after treatment, further displacements of the CoG in the infarcted hemisphere were observed that showed a trend toward statistical significance: in 7 patients, the CoG moved medially; in 2, it remained in the same position; and in 1, a lateral shift occurred.

The motor threshold was elevated over the affected hemisphere and remained very similar at the different times throughout the experiment (infarcted hemisphere: before treatment  $-55.3 \pm 13.7$ , after treatment  $-54.7 \pm 13.5$ , 4 weeks after treatment  $-53.7 \pm 12.8$ ; noninfarcted hemisphere: before treatment  $-45.7 \pm 10.3$ , after treatment  $-44.9 \pm 10.1$ , 4 weeks after treatment  $-44.8 \pm 10.3$  [values indicate a percent-

age of the maximal stimulator output intensity]). We did not observe any MEPs when stimulating the ipsilateral cortex on either the more- or the less-affected side.

## Discussion

The most salient result of the present study is the almost doubling of the excitable cortex, yielding responses of a muscle in the more-affected hand of patients with chronic stroke after CI therapy. This result is paralleled by the large improvement produced by this intervention in the same subjects in the amount of use of the more-affected extremity in the real world setting. The behavioral and electrophysiological changes were consistent across individuals, with both being observed in each patient.

The comparison of the results of the 2 baseline measurements before therapy yielded a good reproduction of the MAL and TMS mapping data, with both indicating stability of motor performance in the patients and a good reproducibility of the TMS mapping and providing a control for certain nonspecific effects. The stability of both parameters is of importance for the interpretation of the posttreatment results in that it indicates the clinical and electrophysiological changes observed after CI therapy cannot be attributed to spontaneous recovery.

The decreased cortical representation area of the paretic muscle of the more-affected hand before therapy reflects a reduced excitability of the motor cortex in the more-affected hemisphere. This is probably due, at least in part, to a reduced use of the paretic hand before therapy or may be the result of the infarct itself.<sup>7</sup> The complete reversal of this abnormally small excitable cortical area for the APB muscle in subjects whose stroke had occurred a mean of 4.9 years earlier took place during the very short period of 12 days. The mechanism of this massive cortical reorganization probably reflects either an increase in the excitability of neurons already involved in the innervation of more-affected hand movements or an increase in excitable neuronal tissue in the infarcted hemisphere, or both. The short time course of 12 days makes the formation of new anatomic connections by means of sprouting as a major mechanism unlikely because clear evidence of axonal growth has not been found until months after a lesion occurred.<sup>65</sup> A more likely mechanism is a reduction in

activity of local inhibitory interneurons, thus unmasking preexisting excitatory connections.<sup>66</sup> An alternate and possibly complementary mechanism would be the enhancement of the synaptic strength of existing synaptic connections.<sup>67</sup> Regardless of the mechanism, rehabilitation appears to lead to a recruitment of a large number of neurons in the innervation of movements of the stroke-affected extremity adjacent to those involved before therapy. This hypothesis is further supported by larger shifts of the CoGs in the infarcted hemisphere. These CoG dislocations suggest that in addition to the enlargement of excitable cortical areas, a new maximum had developed adjacent to the former one. A similar finding was reported in adult monkeys that had received a unilateral lesion of the motor cortex during infancy: a relatively complete hand representation was found to occupy a new territory, medial to the old lesion.<sup>68</sup> In another intracortical microstimulation study, Nudo et al<sup>69</sup> demonstrated in adult squirrel monkeys that received a surgically induced ischemic infarct in a cortical area that controlled the movements of a hand that training of the more-affected limb and partial restraint of the less-affected extremity resulted in both improved motor functioning and cortical reorganization. The intervention was similar to the CI therapy approach that had been used previously.<sup>31,32,34</sup> The present study demonstrates that CI therapy has a parallel effect in humans after stroke. Similarly, in recovered stroke patients, a large lateral extension of the brain area that is active during finger movements was found.<sup>7</sup> Our results suggest that a reorganization occurred on a cortical level. However, the results do not permit exclusion of the possibility that additional plastic changes occurred on a subcortical or spinal level.

Some PET and fMRI studies in recovered stroke patients have suggested that plastic changes take place in the ipsilateral, noninfarcted hemisphere that might contribute to the restitution of motor function.<sup>7-10,12,70</sup> In our study, MEPS could not be evoked with ipsilateral brain stimulation; therefore, no evidence for an involvement of the motor cortex ipsilateral to the paretic arm was found in this subgroup of patients. This does not exclude the possibility of an additional ipsilateral cortical reorganization because different factors (eg, submaximal intensity of the magnetic stimulator output, recordings from relaxed muscles, selection of patients, passive response to stimulation rather than active movement) could be responsible for our result.

It is interesting that at 4 weeks and 6 months after treatment, the number of active positions in the 2 hemispheres were almost identical. This represents a return of the balance of area of excitability in the innervation of muscular activity between the 2 hemispheres toward what is, in effect, a normal condition after a temporary, therapy-induced hyperexcitability. Because the MAL data remained unchanged, the TMS data could indicate that with continued increased use of the more-affected upper extremity for 6 months after treatment, there was an improvement in effective connectivity of the neuronal networks involved in the motor performance. Such a plastic change, presumably involving an increase in synaptic efficiency, would permit the reduction in the excitability of the neuronal connections without a deterioration of function.<sup>20</sup> A similar reduction in excitability along with an

increased effective connectivity associated with repeated exposure to identical stimuli in associative learning was reported by Büchel et al.<sup>71</sup> Pascual-Leone et al<sup>40</sup> demonstrated that gaining explicit knowledge of a task also reduced motor cortex excitability. An analogous process might have occurred here as the patients became adjusted with time to the newly acquired increased use of the more-affected extremity. Another explanation of our results could be that brain areas that are not accessible by focal TMS took over the execution of motor functions, thus allowing a reduction in the excitability of the primary motor cortex. This possibility could be addressed experimentally with fMRI techniques. Before treatment, the representation area of the nonparetic muscle in the unaffected hemisphere was significantly larger than the motor representation of the paretic muscle in the infarcted hemisphere. This area in the unaffected hemisphere decreased nonsignificantly after therapy. Several factors might have contributed to these changes. Before treatment, an increase in unaffected hand use, which was required to compensate for the greatly decreased use of the paretic hand in everyday life, could have resulted in relative large cortical representations. During and after therapy, the nonparetic hand was used less frequently than before therapy. Similar to results obtained in an immobilization study,<sup>44</sup> this reduced use might have produced a shrinkage of the representation area. An alternate explanation could be a transhemispheric cross-talk between the 2 primary motor cortices (M1), mediated through transcallosal fibers. In normal subjects, TMS over 1 M1 was found to reduce the excitability of the contralateral M1.<sup>72</sup> This interhemispheric inhibition may still be operative in stroke patients with intact transcallosal connections.<sup>73</sup> Thus, a therapy-associated enhanced activation of M1 in the affected hemisphere could induce an increased inhibition of the contralateral M1.

CI therapy is predicated on the demonstration in deafferented monkeys<sup>31,32</sup> after neurological injury that the nonuse of an affected extremity can be due to a learning phenomenon that involves a conditioned suppression of movement. CI therapy is considered to be effective because it increases the motivation to use the extremity and thereby overcomes the "learned nonuse." (This formulation has been described in detail elsewhere.<sup>31,32,36</sup>) The current results indicate that the intervention, which involves massed and sustained practice of functional arm movements, also produces a massive use-dependent cortical reorganization that may provide the basis for the long-term persistence of the treatment effect for the 6 months studied in this experiment and for the 2 years reported in other research.<sup>25</sup> Other examples of use-dependent cortical plasticity, resulting from the increased use of body parts in behaviorally relevant tasks, have been described in animals<sup>21,23,24</sup> and humans.<sup>7,25,26,39-42</sup>

One of the aims of neuroscience has been to generate effective new rehabilitation strategies that would give pragmatic importance to this area of basic research. Moreover, if a central nervous system correlate of such a therapy could be found, a new vista would be opened in which further improvements in rehabilitation might be produced through manipulation of that correlate. The present study addresses both of these objectives.

## Acknowledgments

This work was supported by a grant from the Kuratorium ZNS (Bonn) (Dr Miltner), by a grant from the BMBF Mednet (Drs Weiller and Liepert), by the DFG and the EU (Dr Weiller), and by grant B95-975R from the Rehabilitation Research and Development Service, US Department of Veterans Affairs (Dr Taub). We thank Monika Sommer for her help in providing treatment and Dr C. Dettmers for his assistance in the neurological examinations.

## References

- Merzenich MM, Nelson RJ, Stryker MP, Cynader MS, Shoppmann A, Zook JM. Somatosensory cortical map changes following digit amputation in adult monkeys. *J Comp Neurol*. 1984;224:591–605.
- Kaas J, Florence SL, Jain N. Reorganization of sensory systems of primates after injury. *Neuroscientist*. 1997;3:123–130.
- Pons TP, Garraghty PE, Ommaya AK, Kaas JH, Taub E, Mishkin M. Massive cortical reorganization after sensory deafferentation in adult macaques. *Science*. 1991;252:1857–1860.
- Flor H, Elbert T, Knecht S, Wienbruch C, Pantev C, Birbaumer N, Larbig W, Taub E. Phantom-limb pain as a perceptual correlate of cortical reorganization following arm amputation. *Nature*. 1995;375:482–484.
- Mühlnickel W, Elbert T, Taub E, Flor H. Reorganization of auditory cortex in tinnitus. *Proc Natl Acad Sci U S A*. 1998;95:10340–10343.
- Elbert T, Candia V, Altenmüller E, Rau H, Sterr A, Rockstroh B, Pantev C, Taub E. Alteration of digital representations in somatosensory cortex in focal hand dystonia. *Neuroreport*. 1998;9:3571–3575.
- Weiller C, Chollet F, Friston KJ, Wise RJS, Frackowiak RSJ. Functional reorganization of the brain in recovery from striatocapsular infarction in man. *Ann Neurol*. 1992;31:463–472.
- Weiller C, Ramsay SC, Wise RJS, Friston KJ, Frackowiak RSJ. Individual patterns of functional reorganization in the human cerebral cortex after capsular infarction. *Ann Neurol*. 1993;33:181–189.
- Dettmers C, Stephan KM, Lemon RN, Frackowiak RSJ. Reorganization of the executive motor system after stroke. *Cerebrovasc Dis*. 1997;7:187–200.
- Cramer SC, Nelles G, Benson RR, Kaplan JD, Parker RA, Kwong KK, Kennedy DN, Finklestein SP, Rosen BR. A functional MRI study of subjects recovered from hemiparetic stroke. *Stroke*. 1997;28:2518–2527.
- Cao Y, D'Olhaberriague L, Vikingstad EM, Levine SR, Welch KM. Pilot study of functional MRI to assess cerebral activation of motor function after poststroke hemiparesis. *Stroke*. 1998;29:112–122.
- Seitz RJ, Hoflich P, Binkowski F, Tellmann L, Herzog H, Freund HJ. Role of the premotor cortex in recovery from middle cerebral artery infarction. *Arch Neurol*. 1998;55:1081–1088.
- Binkowski F, Seitz RJ, Arnold S, Classen J, Bnecke R, Freund HJ. Thalamic metabolism and corticospinal tract integrity determine motor recovery in stroke. *Ann Neurol*. 1996;39:460–470.
- Seitz RJ, Azari NP, Knorr U, Binkowski F, Herzog H, Freund HJ. The role of diaschisis in stroke recovery. *Stroke*. 1999;30:1844–1850.
- Infeld B, Davis SM, Lichtenstein M, Mitchell PJ, Hopper JL. Crossed cerebellar diaschisis and brain recovery after stroke. *Stroke*. 1995;26:90–95.
- Palmer E, Ashby P, Hajek VE. Ipsilateral fast corticospinal pathways do not account for recovery in stroke. *Ann Neurol*. 1992;32:519–525.
- Cicinelli P, Traversa R, Rossini PM. Post-stroke reorganization of brain motor output to the hand: a 2–4 month follow-up with focal magnetic transcranial stimulation. *Electroencephalogr Clin Neurophysiol*. 1997;105:438–450.
- Rossini PM, Caltagirone C, Castriota-Scanderbeg A, Cicinelli P, Del Gratta C, Demartin M, Pizzella V, Traversa R, Romani GL. Hand motor cortical area reorganization in stroke: a study with fMRI, MEG and TCS maps. *Neuroreport*. 1998;9:2141–2146.
- Traversa R, Cicinelli P, Bassi A, Rossini PM, Bernardi G. Mapping of motor cortical reorganization after stroke. *Stroke*. 1997;28:110–117.
- Weiller C, Rijntjes M. Learning, plasticity, and recovery in the central nervous system. *Exp Brain Res*. 1999;128:134–138.
- Nudo RJ, Milliken GW, Jenkins WM, Merzenich MM. Use-dependent alterations of movement representations in primary motor cortex of adult squirrel monkeys. *J Neurosci*. 1996;16:785–807.
- Nudo RJ, Milliken GW. Reorganization of movement representations in primary motor cortex following focal ischemic infarcts in adult squirrel monkeys. *J Neurophysiol*. 1996;75:2144–2149.
- Jenkins WM, Merzenich MM, Ochs MT, Allard T, Guic-Robles E. Functional reorganization of primary somatosensory cortex in adult owl monkeys after behaviorally controlled tactile stimulation. *J Neurophysiol*. 1990;3:82–104.
- Recanzone GH, Merzenich MM, Jenkins WM. Frequency discrimination training engaging a restricted skin surface results in an emergence of a cutaneous response zone in cortical area 3a. *J Neurophysiol*. 1992;65:1057–1070.
- Elbert T, Pantev C, Wienbruch C, Rockstroh B, Taub E. Increased cortical representation of the fingers of the left hand in string players. *Science*. 1995;270:305–307.
- Sterr A, Müller MM, Elbert T, Rockstroh B, Pantev C, Taub E. Changed perceptions in Braille readers. *Nature*. 1998;391:134–135.
- Duncan PW. Synthesis of intervention trials to improve motor recovery following stroke. *Top Stroke Rehabil*. 1997;3:1–20.
- Twitchell TE. The restoration of motor function following hemiplegia in man. *Brain*. 1951;74:443–480.
- Bard G, Hirschberg GG. Recovery of voluntary movement in upper extremity following hemiplegia. *Arch Phys Med Rehab*. 1965;46:567–572.
- Parker VM, Wade DT, Langton HR. Loss of arm function after stroke: measurement, frequency, and recovery. *Int Rehab Med*. 1986;8:69–73.
- Taub E. Somatosensory deafferentation research with monkeys: implications for rehabilitation medicine. In: Ince LP, ed. *Behavioral Psychology in Rehabilitation Medicine: Clinical Applications*. New York, NY: Williams & Wilkins; 1980:371–401.
- Taub E. Movement in nonhuman primates deprived of somatosensory feedback. *Exerc Sports Sci Rev*. 1977;4:335–374.
- Wolf SL, Lecraw DE, Barton LA, Jann BB. Forced use of hemiplegic upper extremities to reverse the effect of learned nonuse among chronic stroke and head-injured patients. *Exp Neurol*. 1989;104:125–132.
- Taub E, Miller NE, Novack TA, Cook EW III, Fleming WC, Nepomuceno CS, Connell JS, Crago JE. Technique to improve chronic motor deficit after stroke. *Arch Phys Med Rehab*. 1993;74:347–354.
- Taub E, Pidikiti RD, DeLuca SC, Crago JE. Effects of motor restriction on an unimpaired upper extremity and training on improving functional tasks and altering brain behaviors. In: Toole JF, Good DC, eds., *Imaging in Neurologic Rehabilitation*. New York, NY: Demos Vermande; 1996:133–154.
- Taub E, Crago JE, Uswatte G. Constraint-induced movement therapy. A new approach to treatment in physical rehabilitation. *Rehab Psychol*. 1998;43:152–170.
- Miltner WHR, Bauder H, Sommer M, Dettmers C, Taub E. Effects of constraint-induced movement therapy on patients with chronic motor deficits after stroke: a replication. *Stroke*. 1999;30:586–592.
- Taub E, Uswatte G, Pidikiti RD. Constraint-induced movement therapy. A new family of techniques with broad application to physical rehabilitation—a clinical review. *J Rehab Res Dev*. 1999;36:237–251.
- Pascual-Leone A, Dang N, Cohen LG, Brasil-Neto JP, Cammarota A, Hallett M. Modulation of muscle responses evoked by transcranial magnetic stimulation during the acquisition of new fine motor skills. *J Neurophysiol*. 1995;74:1037–1045.
- Pascual-Leone A, Grafman J, Hallett M. Modulation of cortical motor output maps during development of implicit and explicit knowledge. *Science*. 1994;263:1287–1289.
- Pascual-Leone A, Cammarota A, Wassermann E. M, Brasil-Neto JP, Cohen LG, Hallett M. Modulation of motor cortical outputs to the reading hand of Braille readers. *Ann Neurol*. 1993;34:33–37.
- Pascual-Leone A, Wassermann EM, Sadato N, Hallett M. The role of reading activity on the modulation of motor cortical outputs to the reading hand in Braille readers. *Ann Neurol*. 1995;38:910–915.
- Pascual-Leone A, Peris M, Tormos JM, Pascual-Leone Pascual A, Catala MD. Reorganization of human cortical motor output maps following traumatic forearm amputation. *Neuroreport*. 1996;7:2068–2070.
- Liepert J, Tegenthoff M, Malin J-P. Changes of cortical motor area size during immobilization. *Electroencephalogr Clin Neurophysiol*. 1995;97:382–386.
- Cohen LG, Bandinelli S, Findley TW, Hallett M. Motor reorganization after upper limb amputation in man. *Brain*. 1991;114:615–627.
- Ridding MC, Rothwell JC. Reorganisation in human motor cortex. *Can J Physiol Pharmacol*. 1995;73:218–222.
- Rijntjes M, Tegenthoff M, Liepert J, Leonhardt G, Kotterba S, Müller S, Kiebel S, Malin J-P, Diener H-C, Weiller C. Cortical reorganization in patients with facial palsy. *Ann Neurol*. 1997;41:621–630.
- Mano Y, Nakamuro T, Tamura R, Takayanagi T, Kawanishi K, Tamai S, Mayer RF. Central motor reorganization after anastomosis of the muscu-

- locutaneous and intercostal nerves following cervical root avulsion. *Ann Neurol*. 1995;38:15–20.
49. Rossini PM, Rossi S, Tecchio F, Pasqualetti P, Finazzi-Agro A, Sabato A. Focal brain stimulation in healthy humans: motor maps changes following partial hand sensory deprivation. *Neurosci Lett*. 1996;214:191–195.
  50. Topka H, Cohen LG, Cole RA, Hallett M. Reorganization of corticospinal pathways following spinal cord injury. *Neurology*. 1991;41:1276–1283.
  51. Brasil-Neto JP, Cohen LG, Pascual-Leone A, Jabir FK, Wall RT, Hallett M. Rapid reversible modulation of human cortical motor outputs after transient deafferentation of the forearm: a study with transcranial magnetic stimulation. *Neurology*. 1992;42:1302–1306.
  52. Brasil-Neto JP, Valls-Solé J, Pascual-Leone A, Cammarota A, Amassian VE, Cracco R, Maccabee P, Cracco J, Hallett M, Cohen LG. Rapid modulation of human cortical motor outputs following ischaemic nerve block. *Brain*. 1993;116:511–525.
  53. Fuhr P, Cohen LG, Dang N, Findley TW, Haghghi S, Oro J, Hallett M. Physiological analysis of motor reorganization following lower limb amputation. *Electroencephalogr Clin Neurophysiol*. 1992;85:53–60.
  54. Levy WJ Jr, Amassian VE, Traad M, Cadwell J. Focal magnetic coil stimulation reveals motor cortical system reorganized in humans after traumatic quadriplegia. *Brain Res*. 1990;510:130–134.
  55. Bymes ML, Thickbroom GW, Phillips BA, Wilson SA, Mastaglia FL. Physiological studies of the corticomotor projection to the hand after subcortical stroke. *Clin Neurophysiol*. 1999;110:487–498.
  56. Borojerdj B, Foltys H, Krings T, Spetzger U, Thron A, Töpper R. Localization of the motor hand area using transcranial magnetic stimulation and functional magnetic resonance imaging. *Clin Neurophysiol*. 1999;110:699–704.
  57. Krings T, Buchbinder BR, Bulter WE, Chiappa KH, Jiang HJ, Cosgrove GR, Rosen BR. Functional magnetic resonance imaging and transcranial magnetic stimulation: complementary approaches in the evaluation of cortical motor function. *Neurology*. 1997;48:1406–1416.
  58. Bastings EP, Gage HD, Greenberg JP, Hammond G, Hernandez L, Santago P, Hamilton CA, Moody DM, Singh KD, Ricci PE, Pons TP, Good DC. Co-registration of cortical magnetic stimulation and functional magnetic resonance imaging. *Neuroreport*. 1998;9:1941–1946.
  59. Singh KD, Hamdy S, Aziz Q, Thompson DG. Topographic mapping of trans-cranial magnetic stimulation data on surface rendered MR images of the brain. *Electroencephalogr Clin Neurophysiol*. 1997;105:345–351.
  60. Liepert J, Miltner WHR, Bauder H, Sommer M, Dettmers C, Taub E, Weiller C. Motor cortex plasticity during constraint-induced movement therapy in stroke patients. *Neurosci Lett*. 1998;250:5–8.
  61. Taub E, Crago JE, Burgio LD, Groomes TE, Cook EW III, DeLuca SC, Miller NE. An operant approach to rehabilitation medicine: overcoming learned nonuse by shaping. *J Exp Anal Behav*. 1994;61:281–293.
  62. Liepert J, Terborg C, Weiller C. Motor plasticity induced by synchronized thumb and foot movements. *Exp Brain Res*. 1999;125:435–439.
  63. Cohen J. *Statistical Power Analysis in the Behavioral Sciences*. New York, NY: Academic Press; 1997.
  64. Miranda PC, de Carvalho M, Conceicao I, Luis MLS, Ducla-Soares E. A new method for reproducible coil positioning in transcranial magnetic stimulation mapping. *Electroencephalogr Clin Neurophysiol*. 1997;105:116–123.
  65. Darian-Smith C, Gilbert CD. Topographic reorganization in the striate cortex of the adult cat and monkey is cortically mediated. *J Neurosci*. 1995;15:1631–1647.
  66. Jacobs KM, Donoghue JP. Reshaping the cortical motor map by unmasking latent intracortical connections. *Science*. 1991;251:944–947.
  67. Hebb DO. *Organization of Behaviour*. New York, NY: Wiley; 1949.
  68. Rouiller EM, Yu XH, Moret V, Tempini A, Wiesendanger M, Liang F. Dexterity in adult monkeys following early lesion of the motor cortical hand area: the role of cortex adjacent to the lesion. *Eur J Neurosci*. 1998;10:729–740.
  69. Nudo RJ, Wise BM, SiFuentes F, Milliken GW. Neural substrates for the effects of rehabilitative training on motor recovery after ischemic infarct. *Science*. 1996;272:1791–1794.
  70. Chollet F, DiPiero V, Wise RJ, Brooks DJ, Dolan RJ, Frackowiak RS. The functional anatomy of motor recovery after stroke in humans: a study with positron emission tomography. *Ann Neurol*. 1991;29:63–71.
  71. Büchel C, Coull JT, Friston KJ. The predictive value of changes in effective connectivity for human learning. *Science*. 1999;283:1538–1541.
  72. Ferbert A, Priori A, Rothwell JC, Day BL, Colebatch JG, Marsden CD. Interhemispheric inhibition of the human motor cortex. *J Physiol*. 1992;453:525–546.
  73. Borojerdj B, Diefenbach K, Ferbert A. Transcallosal inhibition in cortical and subcortical cerebral vascular lesions. *J Neurol Sci*. 1996;144:160–170.