

# SEMIOLOGIA



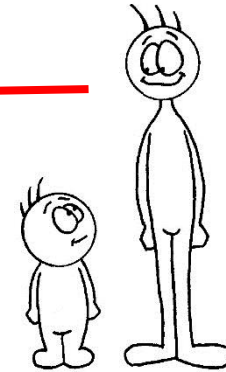
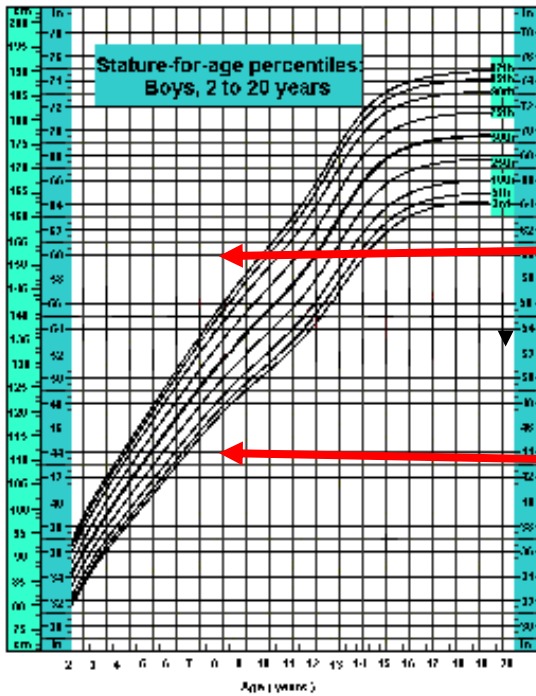
**Profa. Dra. Ester Silveira Ramos**  
**[esramos@rge.fmrp.usp.br](mailto:esramos@rge.fmrp.usp.br)**

**Alterações “maiores”**

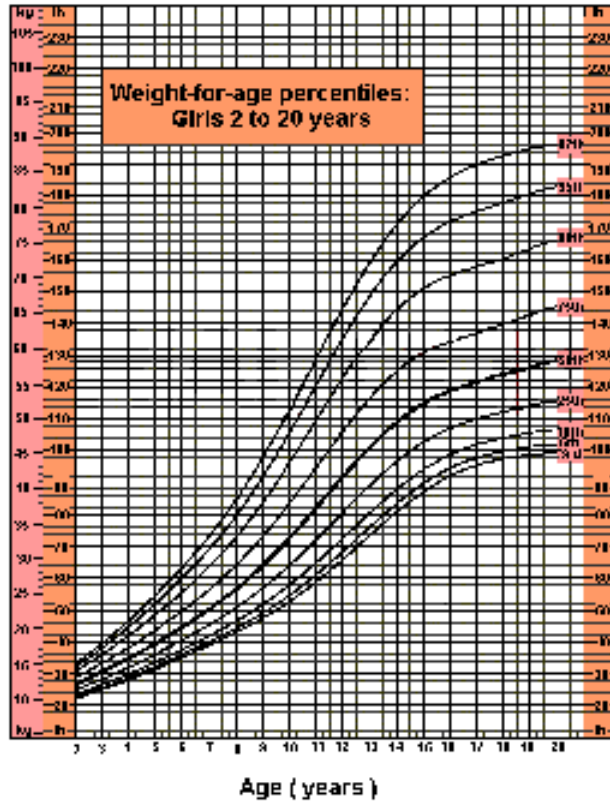
**Alterações “menores”**

**3 ou + menores, procurar maior**

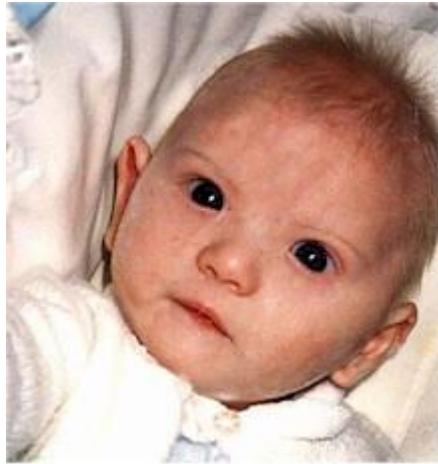# Estatura



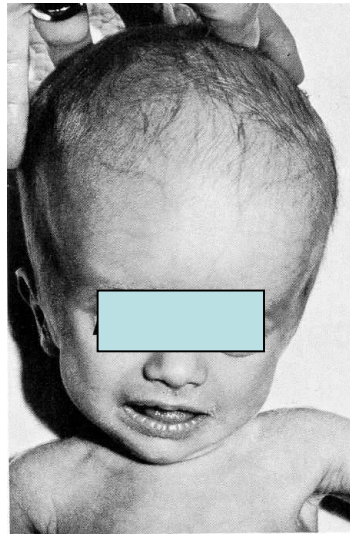
# Peso



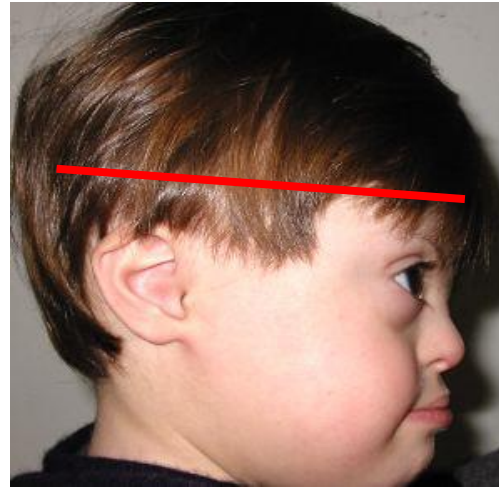
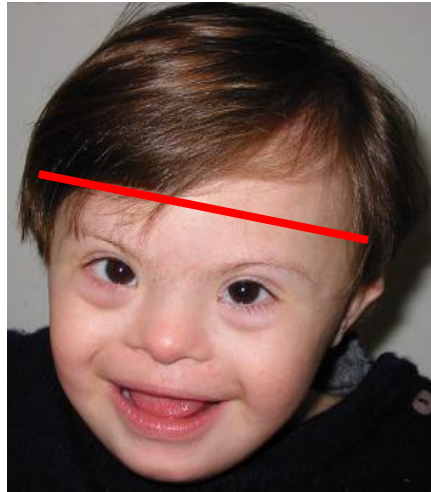# Microcefalia



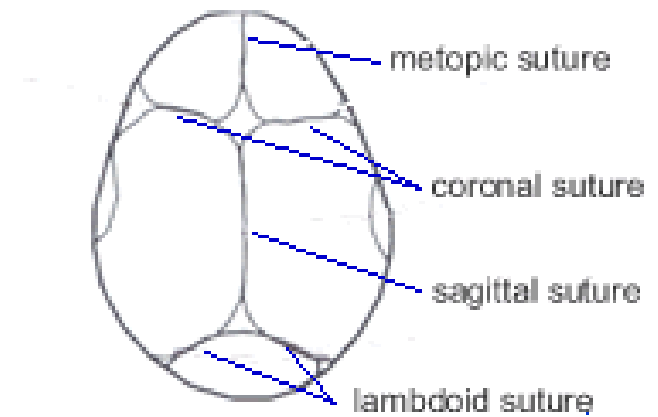
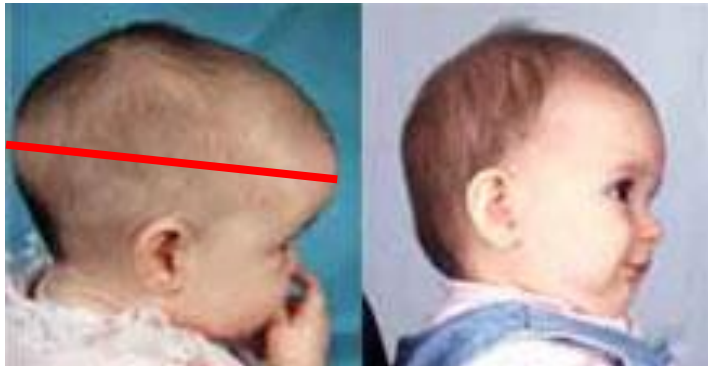# Macrocefalia



# Braquicefalia



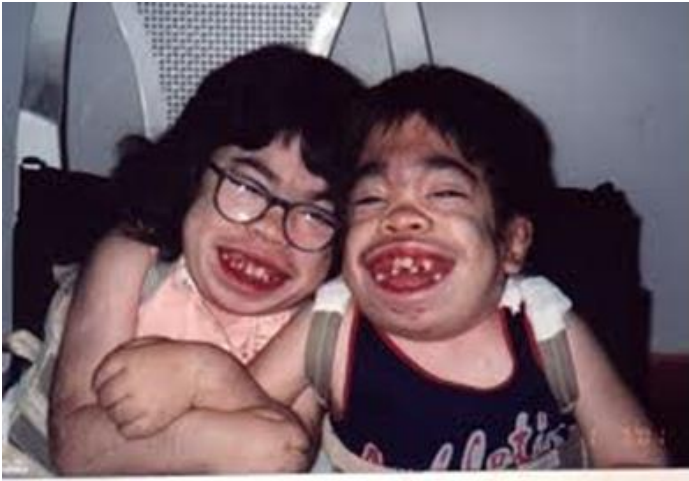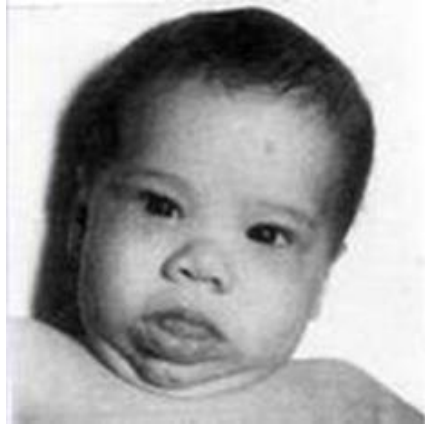# Dolicocefalia



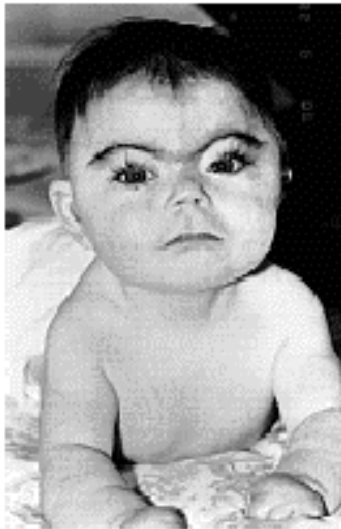**Cranial sutures**



# Face

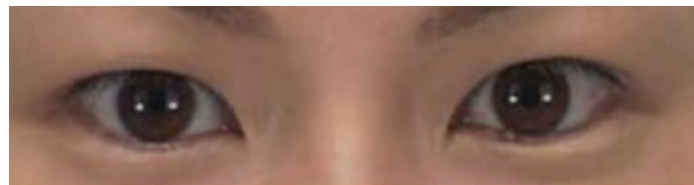
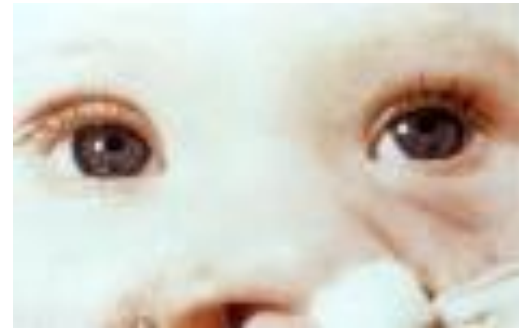
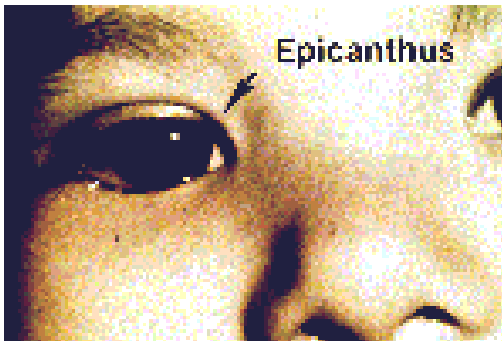# Sinofre

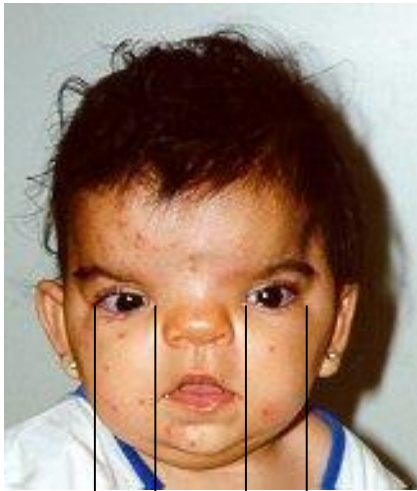

SÍNDROME DE CORNELIA DE LANGE

# Epicanto

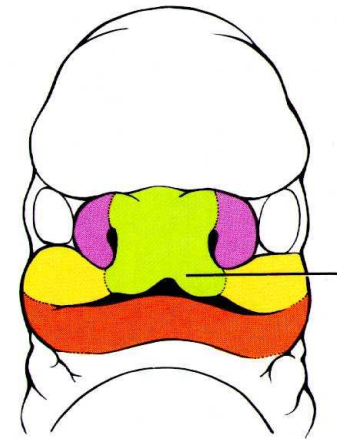
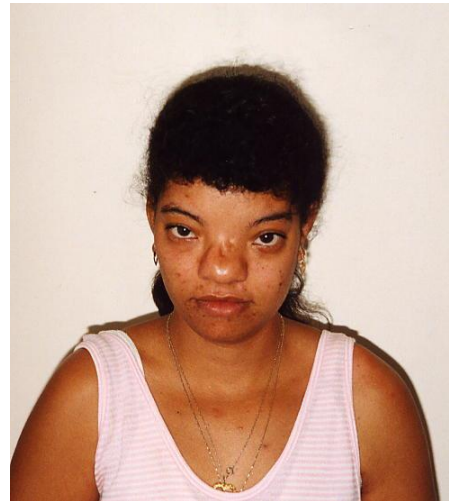

# Hipertelorismo (DII e DIE aumentadas)



DII

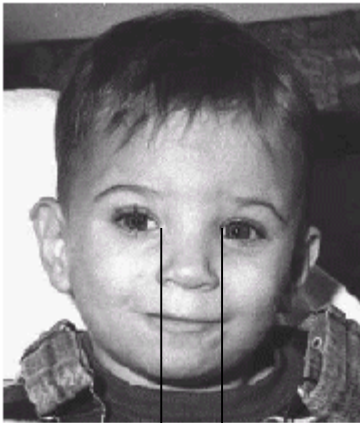
DIE



DDI= distância intercantal interna

DIE= distância intercanta externa

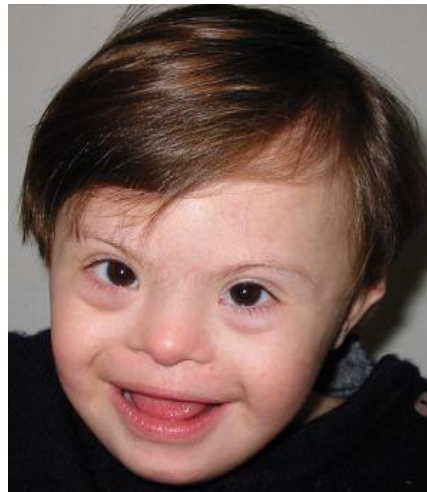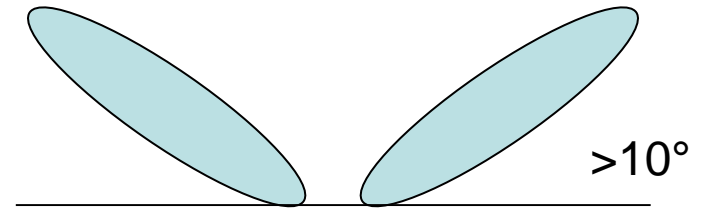
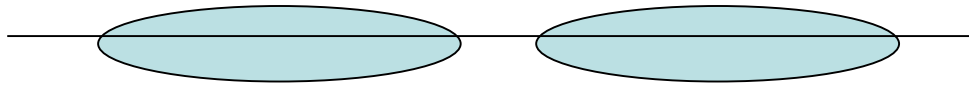
# Telecanto



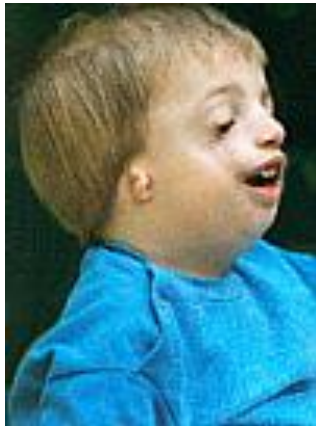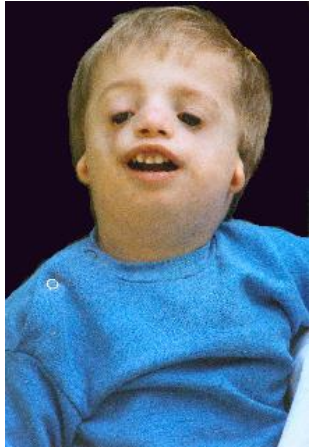DII aumentada



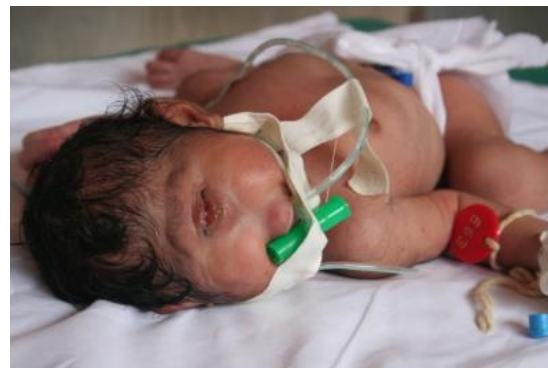
# Fendas oblíquas para cima



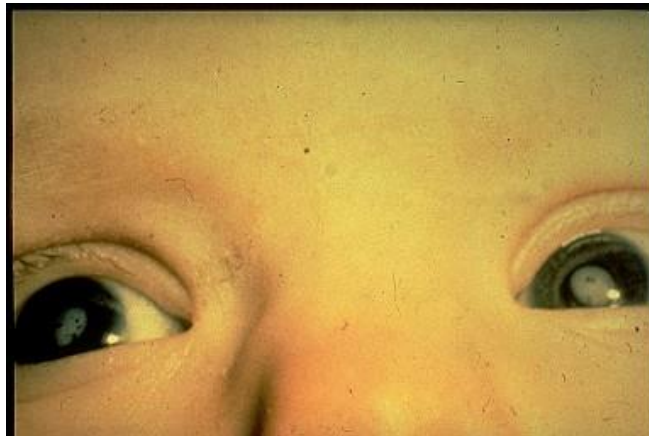# Fendas oblíquas para baixo



# Ciclopia







Catarata


# Nariz



raiz



ponte  
dorso



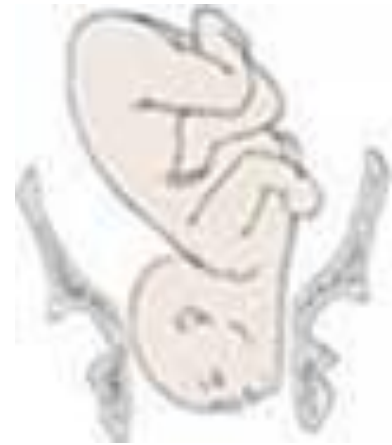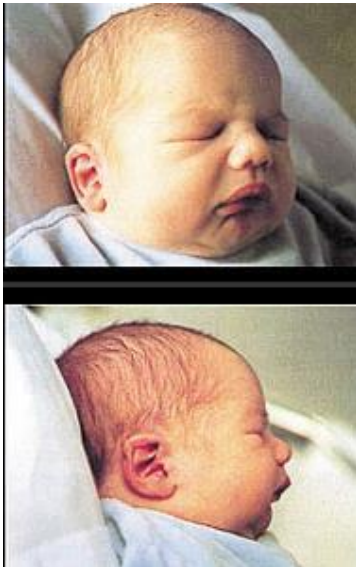base



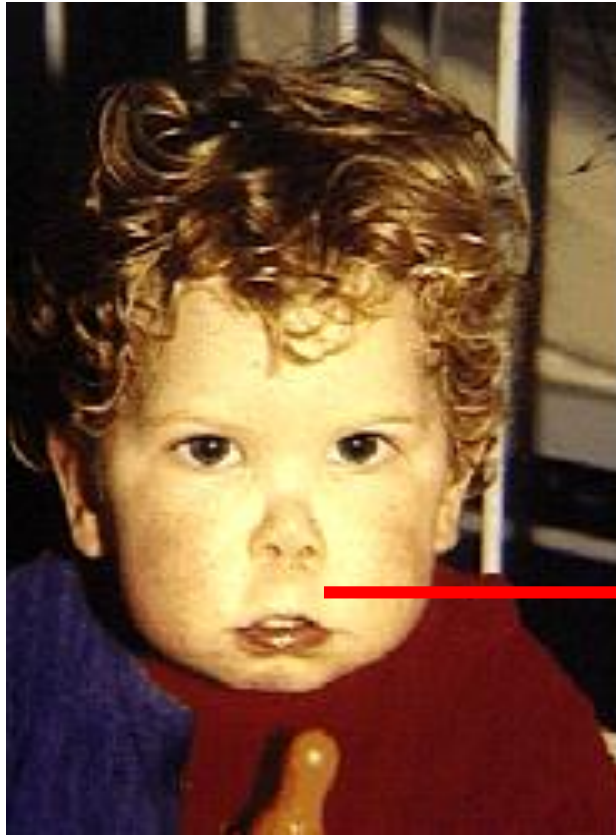columela



# Micro/Retrognatia

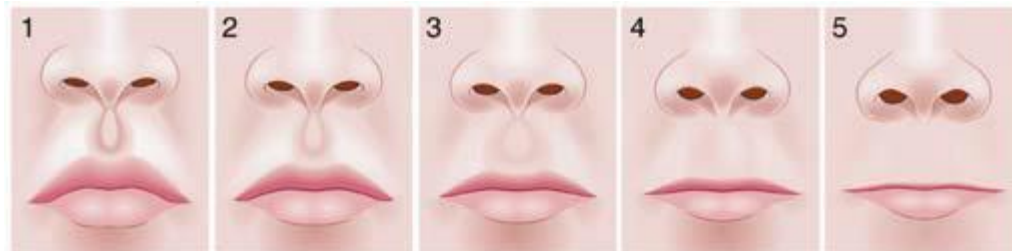
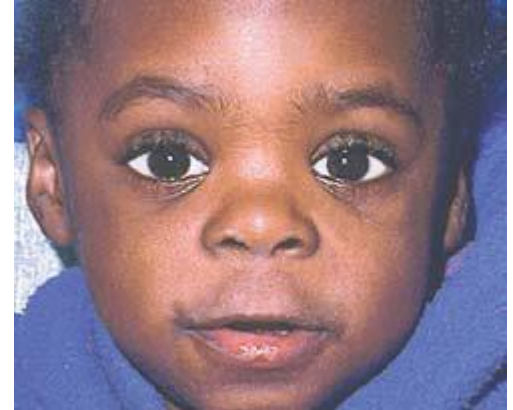
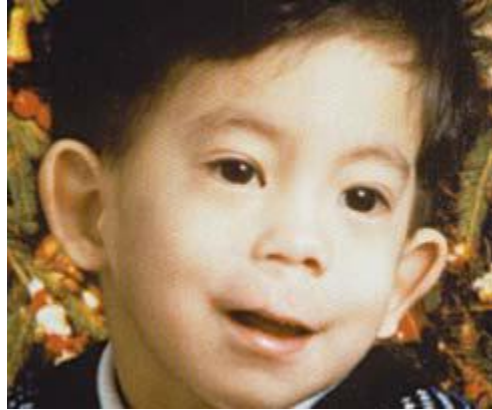
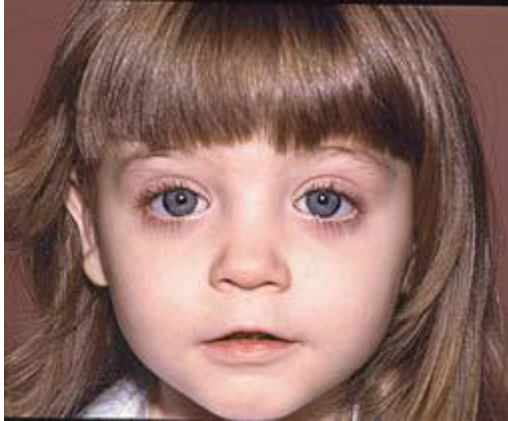Deformidade - apresentação

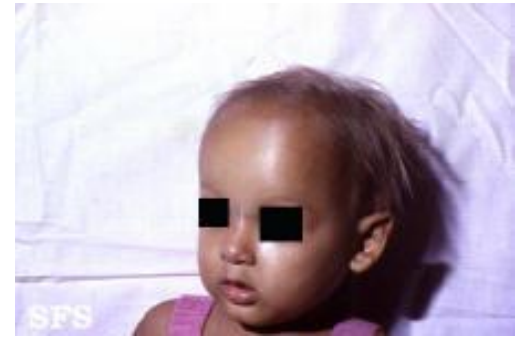
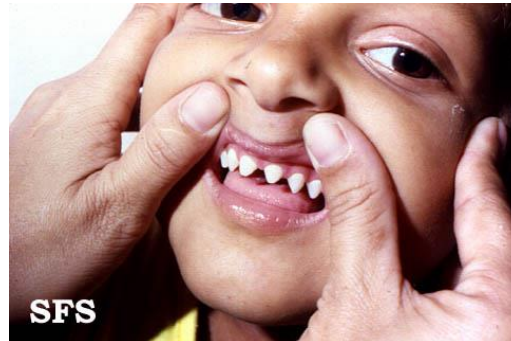
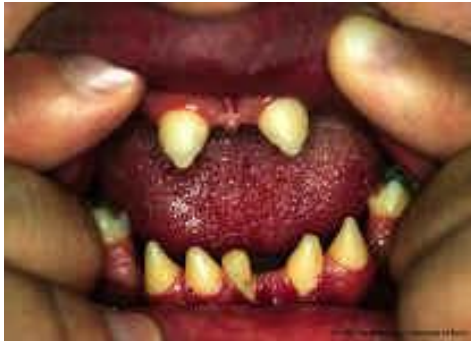Filtro  
nasolabial

# SAF



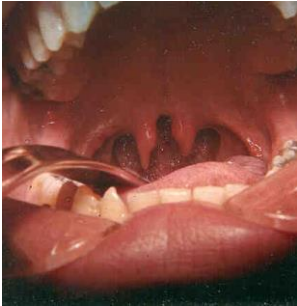# Dentes Conóides



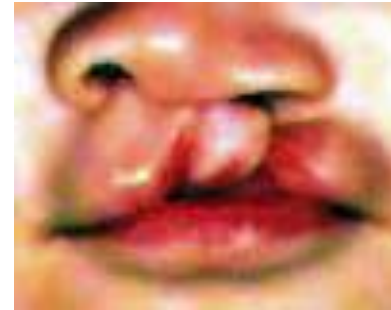Displasia ectodérmica

# Macroglossia

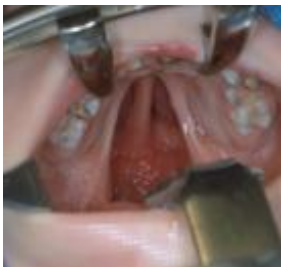# Fendas



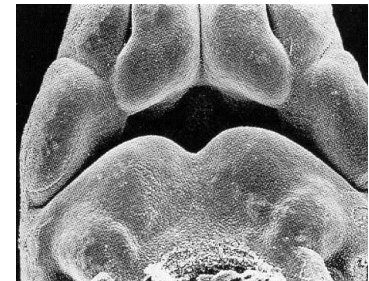
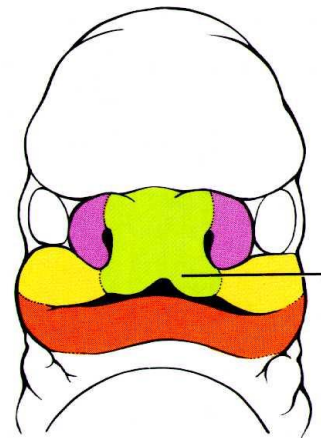
Úvula Bífida



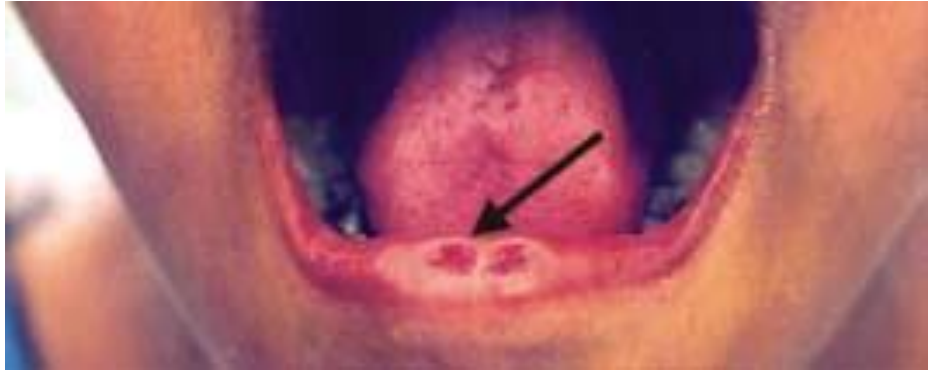
Fenda Labial



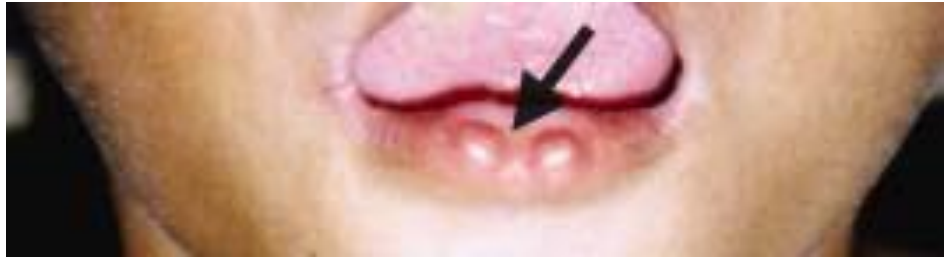Fenda Palatina





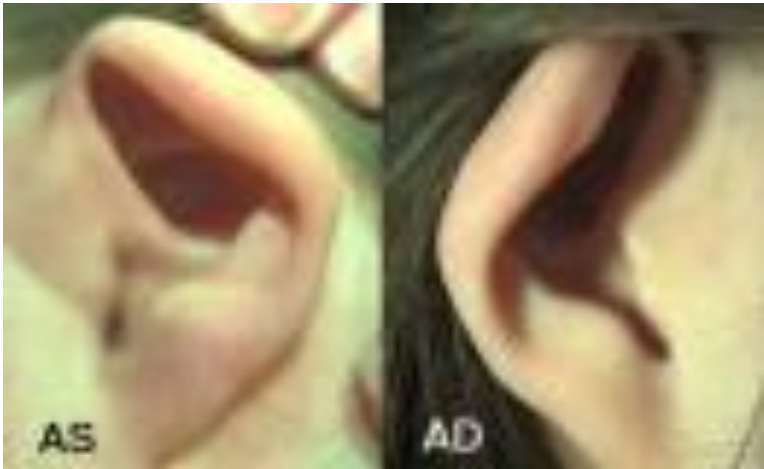
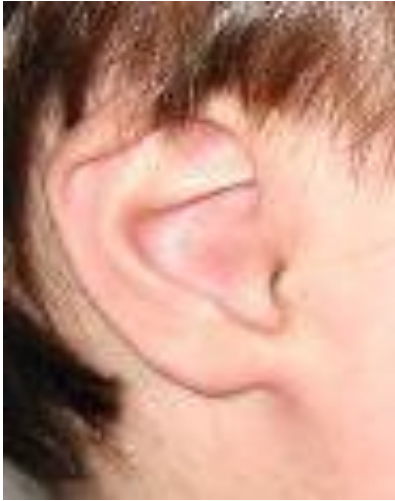
Fenda +

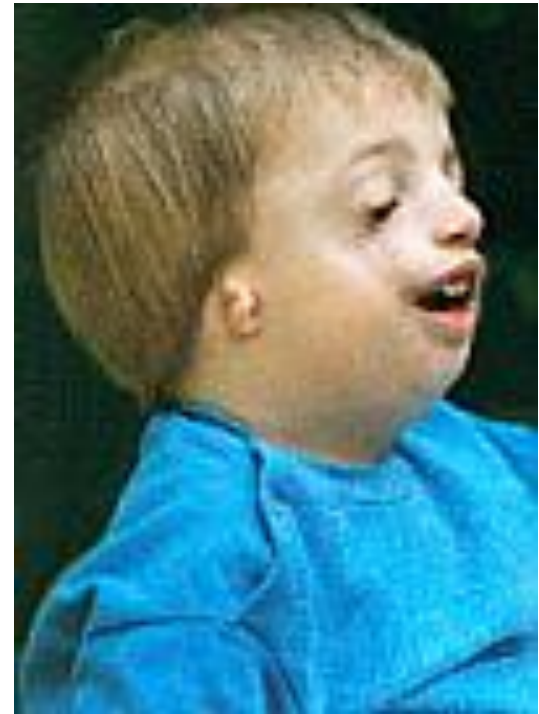
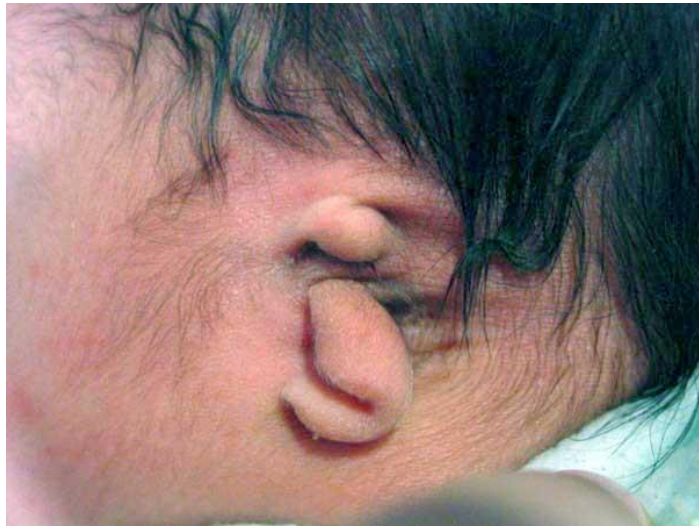
= Síndrome de Van der Woude

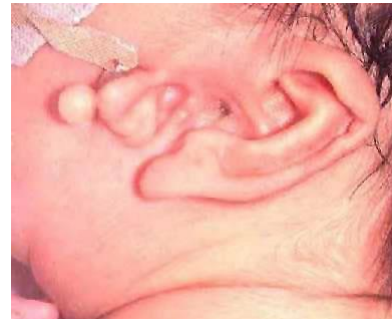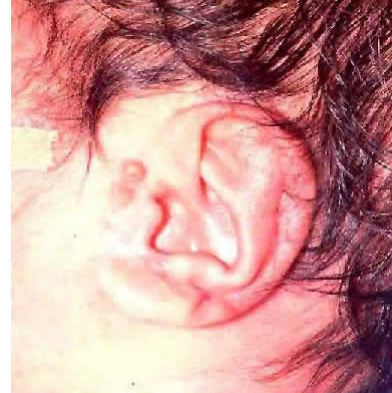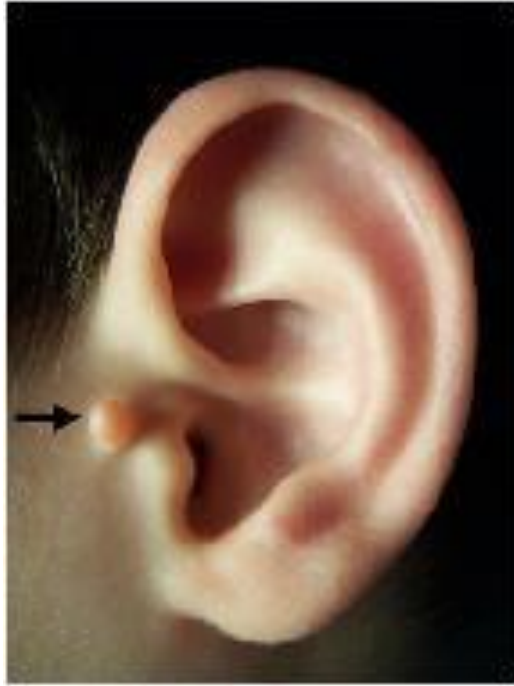# Orelha



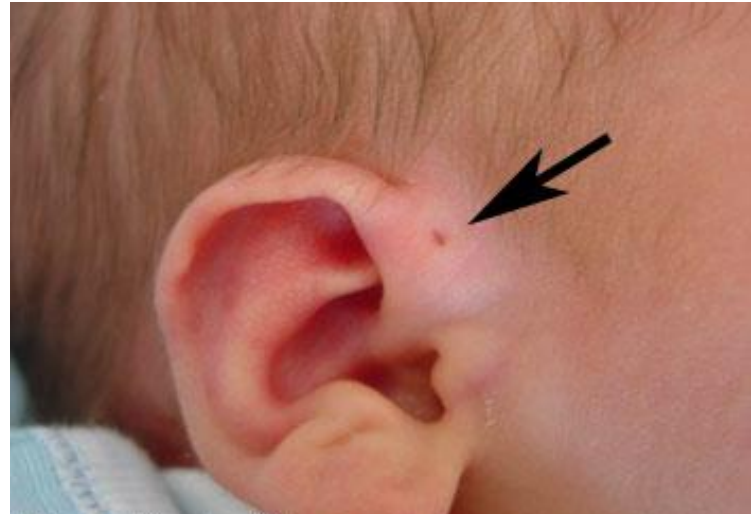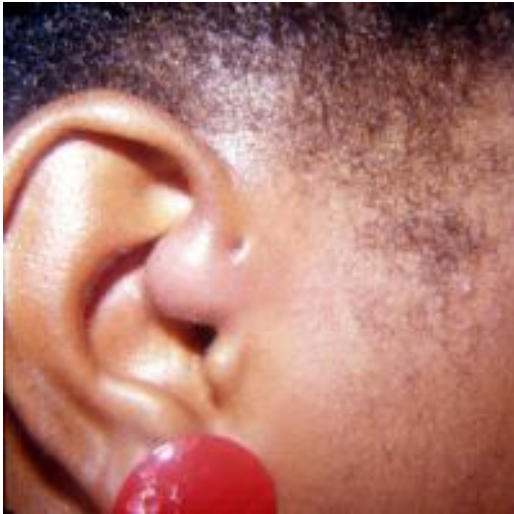# Microtia



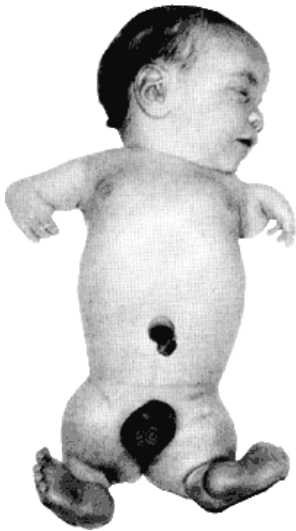# Apêndice pré-auricular



# Fístula/ “Pit” pré-auricular

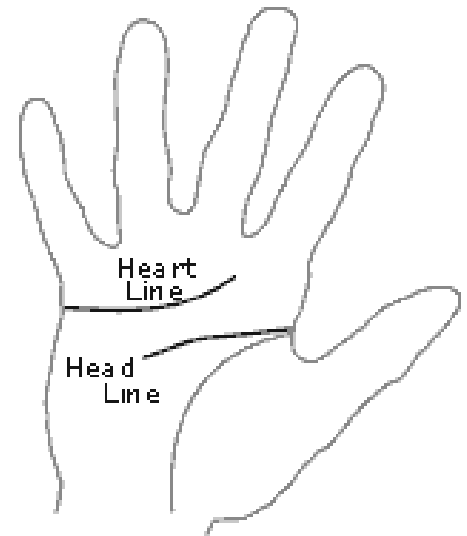
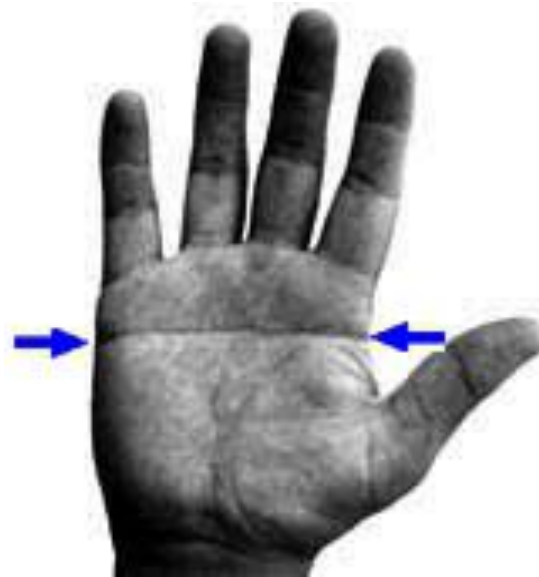
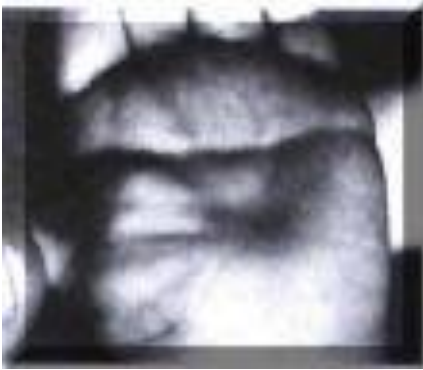

# Membros - Melia



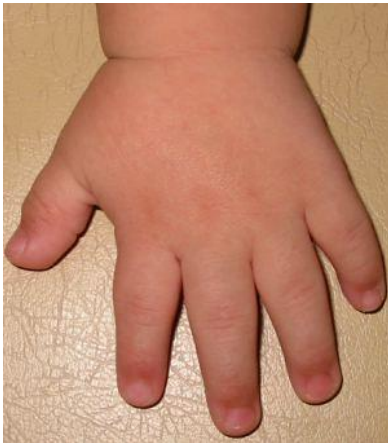Focomelia - Talidomida

# Mão - Quiro

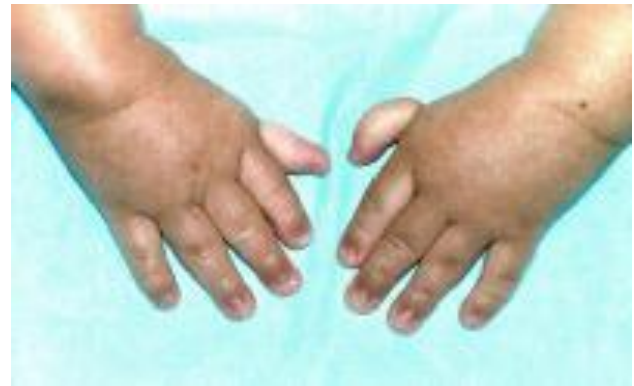

Prega palmar única (simiesca)

# Quirodáctilos



Braquidactilia  
Clinodactilia



Hipoplasia radial

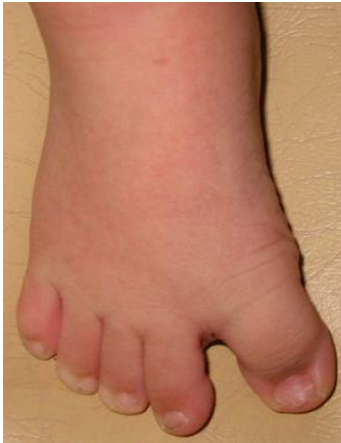

# Aracnodactilia

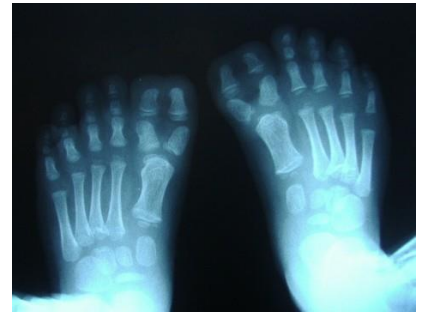
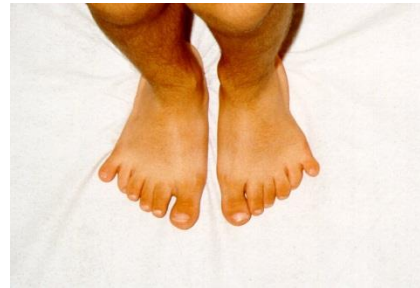
Frouxidão ligamentar

# Pododáctilos



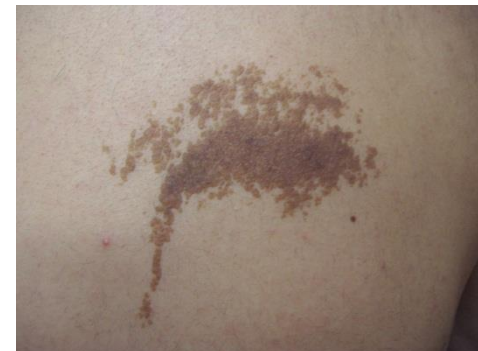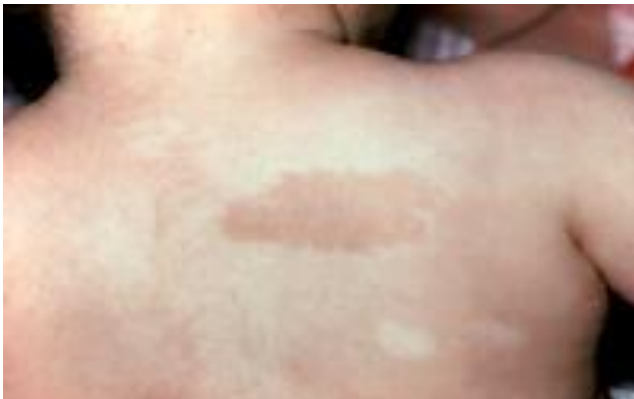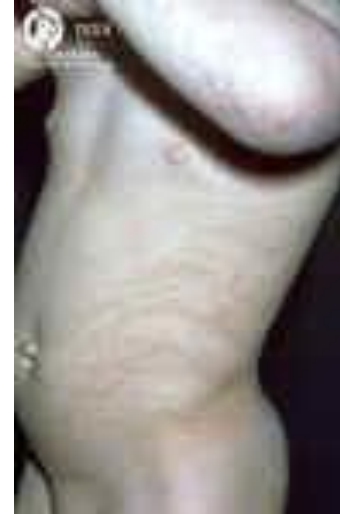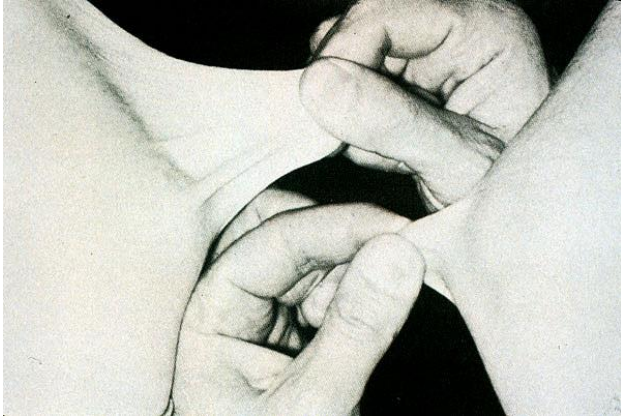Braquidactilia  
Aumento da distância  
entre o 1º e o 2º  
artelhos



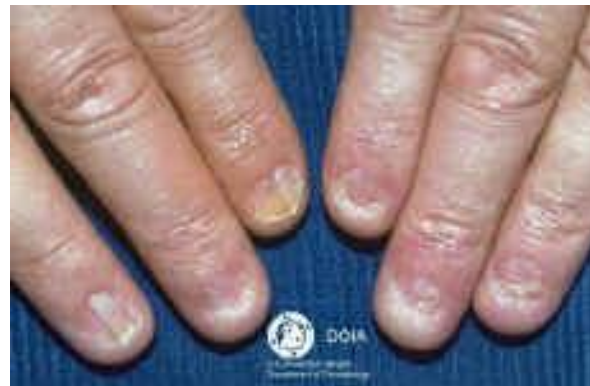Polidactilia

# Sindactylia

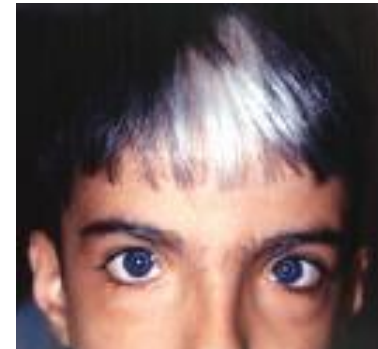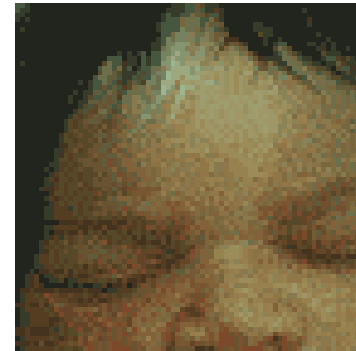# Pele



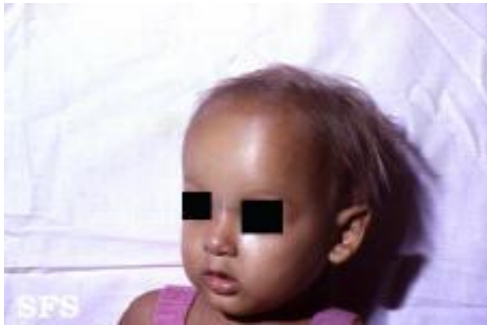# Unhas



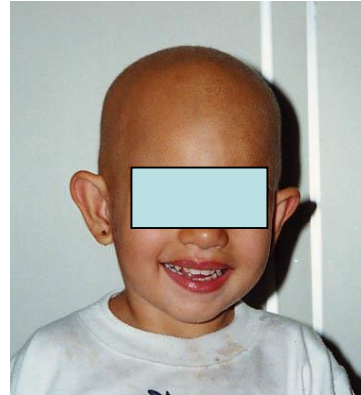# Cabelo/pelo



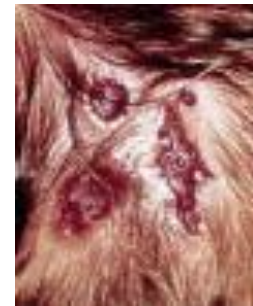# Cabelo/pelo



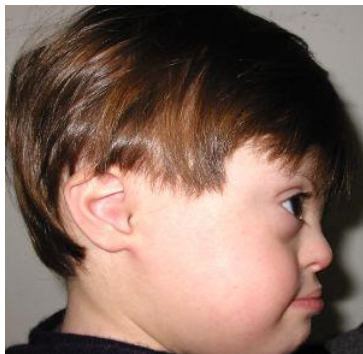Displasia ectodérmica



Alopecia



Trissomia 13



S. Down



S. Ambras