Journal of
Oral Pathology & Medicine

doi: 10.1111/j.1600-0714.2010.00898.x

J Oral Pathol Med (2010) 39: 715–721
© 2010 John Wiley & Sons A/S · All rights reserved
wileyonlinelibrary.com/journal/jop

Amylase and cyclic amp receptor protein expression in human diabetic parotid glands

Monica Piras[1], Arthur R. Hand[2], Maija I. Mednieks[3], Marco Piludu[1]

[1]*Department of Cytomorphology, University of Cagliari, Cittadella Universitaria di Monserrato, Monserrato (CA), Italy;*
[2]*Departments of Craniofacial Sciences and Cell Biology, University of Connecticut Health Center, Farmington, CT, USA;*
[3]*Department of Oral Health and Diagnostic Sciences, University of Connecticut Health Center, Farmington, CT, USA*

BACKGROUND: Salivary dysfunction and oral disorders have been described in both type 1 and type 2 diabetes mellitus. However, the cellular and molecular consequences of diabetes on oral tissues remain to be ascertained. The purpose of this investigation was to study, by means of electron microscopy, the morphologic and molecular changes that occur in salivary glands during diabetes.
METHODS: Biopsy samples of parotid glands were excised from non-diabetic and diabetic (type 1 and type 2) consenting patients and processed by standard methods for routine morphology and electron microscopic immunogold labeling. Specific antibodies were used to determine and quantify the expression of secretory proteins (alphaamylase and the regulatory subunit of type II protein kinase A).
RESULTS: Morphologic changes in the diabetic samples included increased numbers of secretory granules, and alterations in internal granule structure. Quantitative analysis of immunogold labeling showed that labeling densities were variable among the parotid gland samples. In type 1 diabetes amylase expression was greater than in non-diabetic glands, whereas in type 2 diabetes it was not significantly changed. Expression of type II regulatory subunits was slightly, although not significantly, increased in acinar secretory granules of type 1 diabetic samples and was unchanged in type 2 diabetic samples.
CONCLUSIONS: Our data show that diabetes elicits specific changes in secretory protein expression in human salivary glands, thus contributing to the altered oral environment and oral disease associated with diabetes.
J Oral Pathol Med (2010) **39**: 715–721

Keywords: diabetes; electron microscopy; human; immunocytochemistry; salivary glands

Correspondence: Marco Piludu, Dipartimento di Citomorfologia, Università di Cagliari, Cittadella Universitaria di Monserrato, 09042 Monserrato (CA), Italy. Tel: +39 070 675 4003, E-mail: mpiludu@unica.it
Accepted for publication February 24, 2010

Introduction

Many of the organic molecules present in human saliva such as histatins, mucins and lysozyme have antimicrobial properties, representing part of an innate host defense system that regulates oral growth and colonization by a number of pathogenic microbes (1). Therefore, the maintenance of normal salivary flow and composition is very important for the health of the oral environment.

Significant changes occur in human salivary gland function during diabetes mellitus (DM) (2). They include salivary gland enlargement (3–5) and alterations in salivary flow rates and composition (6–8). It has been reported that type 2 DM is associated with xerostomia and the resulting oral complications, which may include increases in mucosal abnormalities, infections, caries risk and incidence and severity of periodontal disease (9–12). Accumulating evidence linking periodontal disease with cardiovascular pathology and other systemic conditions (13, 14) points to additional risks for patients with diabetic oral complications. In effect, the reduction in saliva secretion plays a negative role in dental health and in the mechanisms of oral defense (15).

Periodontal diseases, along with neuropathy, retinopathy and micro- and macrovascular diseases, represent common complications that are involved in altering systemic physiology in diabetic patients. Periodontal disease is correlated with accumulation of dental plaque and calculus that harbor bacteria and virulence factors. The ensuing host inflammatory response results in the destruction of periodontal tissue and resorption of alveolar bone around the teeth (16). People with diabetes have a high probability of developing periodontal disease compared to non-diabetic individuals (16, 17). The mechanisms and the relationships that are common to DM and periodontitis are not yet clear.

The oral cavity mirrors the state of systemic health more frequently than any other part of the body. For example, increased superficial oral infections with yeast have been associated with DM. *Candida albicans*, normally present in the oral microflora, rarely causes

infections without predisposing factors (18). On the other hand, the incidence of candidiasis increases in relation to some factors, such as DM. Poor glycemic control increases oral candidal infection in diabetic patients and candidal growth rate is higher in type 1 than in type 2 DM (19).

Significant changes in salivary gland structure and secretory protein expression occur in experimental diabetes. These include the formation of autophagic vacuoles and crystalloids and the accumulation of lipid in the acinar cells, increased deposition of basement membrane, decreased expression of alpha amylase (α-amylase), parotid secretory protein (PSP) and proline-rich proteins (PRPs), and increased expression of salivary peroxidase (20–25). However, little comparable information on diabetic human salivary glands is available. Therefore, the present study was designed to determine changes in the salivary glands from diabetic patients compared to non-diabetic patients by means of electron microscopic procedures. We have examined the expression of α-amylase and cyclic AMP receptor proteins (cARP) in parotid glands from both type 1 and type 2 diabetic patients. The role and the importance of salivary α-amylase have been thoroughly investigated. It is mainly involved in the production of maltose and maltotriose from starches, and impairment of amylase activity during DM has been reported previously (26, 27). The regulatory (R) subunits of protein kinase A (PKA), cyclic AMP receptor proteins, previously were well-characterized in animal models (28–30), localized to human salivary parenchyma (31), and secreted into the saliva of rats and humans (32–34). Recent findings have revealed changes in cARP distribution and synthesis in a variety of tissues and conditions (35, 36). Previous studies on animal models of experimental diabetes have shown alterations in the secretion of this protein into saliva (23, 24).

Characterization of the structural changes and distribution of these proteins in diabetic salivary glands could lead to a better understanding of the molecular mechanisms involved in these processes, the development of new diagnostic procedures and, possibly, supplemental therapies in the treatment of DM.

Materials and methods

Sample collection and preparation

Samples of human salivary glands were obtained from 20 consenting patients (aged 42–68 years) of both sexes undergoing surgery at the Otorhinolaryngology Clinic, University of Cagliari. All procedures were carried out with informed consent, according to International Guidelines and were approved by the Institutional Ethics Committee on Human Experimentation at the ASL 8 (Azienda Sanitaria Locale No. 8) of Cagliari. The specimens used in this study were excised from parotid glands of 4 patients affected by type I DM, from parotid glands of 5 patients affected by type II DM and from parotid glands of 11 non-diabetic patients, used as controls.

The samples were cut into small pieces (1–2 mm), fixed in a mixture of 1% formaldehyde and 1.25% glutaraldehyde in 0.1 M cacodylate buffer, pH 7.2, for 3 h and processed by standard methods for embedding in Epon resin. After fixation the samples were washed several times with the same buffer, and stored at 4°C in a mixture of sucrose in 0.1 M cacodylate buffer. Samples for electron microscopic morphological analysis were post-fixed in 2% osmium tetroxide for 1 h at 4°C and treated with an aqueous solution of 0.25% uranyl acetate overnight at 4°C. After infiltration with Epon resin, the specimens were transferred to gelatin capsules or flat polyethylene molds filled with fresh resin and placed in a polymerization chamber at 40°C. The thin sections were collected on copper grids, stained with uranyl acetate and bismuth subnitrate and examined and photographed in a JEOL 100S transmission electron microscope (TEM).

Immunocytochemistry

For immunogold labeling, osmium postfixation and uranyl acetate treatment were omitted. Thin sections were collected on Formvar-coated mesh nickel grids, floated section-side down on phosphate-buffered saline (PBS) for 5 min, and transferred to small drops (30 μl) of PBS containing 1% bovine serum albumin (BSA) and 5% normal goat serum (NGS) for 30 min at room temperature to block non-specific binding of antibodies. The sections were incubated overnight at 4°C with a rabbit polyclonal antibody specific for human amylase (SIGMA-Aldrich), or with anti-cARP primary antibody (23). Incubation with the primary antibodies was performed in a humidified chamber. One percent BSA and 5% normal goat serum were included in the incubation medium in order to protect the antibodies. After rinsing with PBS, the grids were incubated for 60 min at room temperature with the secondary antibody, gold-labeled goat anti-rabbit IgG (Auroprobe EM, Amersham International PLC, Little Chalfont, UK), diluted 1:50 in 1% BSA–PBS.

The grids were washed with PBS and distilled water, stained with uranyl acetate and bismuth subnitrate, and observed and photographed in the TEM.

Appropriate controls were performed in order to establish the specificity of the labeling. They included: (i) omission of the primary antibodies from the labeling sequence, and (ii) substitution of pre-immune or non-immune serum for the primary antibody.

Quantitative analysis

A total of five to seven micrographs of salivary gland tissue from each of 20 individuals were used for quantitative analyses. Micrographs were taken at an initial magnification of 3500–7000 × and enlarged 2 times. Quantification was carried out by counting gold particles in subcellular compartments using a grid overlay method (31). Mean labeling densities, expressed as gold particles/μm^2 ± standard error (SEM), were calculated and analyzed using the statistical functions in Microsoft Excel. *T*-tests and single factor ANOVA functions in EXCEL were used to compare labeling densities among diabetic and non-diabetic samples.

Results

Ultrastructure and morphology

The morphology and the ultrastructure of parotid glands from non-diabetic individuals confirmed the findings of previous studies (37). The acinar cells of the secretory endpieces showed the presence of a well developed Golgi complex and prominent endoplasmic reticulum. Their cytoplasm was usually filled by a consistent number of secretory granules, characterized by the presence of a bipartite structure consisting of a moderately dense main portion and a dense core contained within it (Fig. 1a).

Morphologic changes of the glandular parenchyma in the diabetic samples included alterations in internal granule structure of parotid gland samples from type 1 diabetic patients, often characterized by the presence of several irregular dense areas (Fig. 1b). The ultrastructure of acinar cells in parotid glands from type 2 diabetic patients revealed an increased number of secretory granules with contents of lower electron density (Fig. 1c). The structure of mitochondria in acinar and ductal cells did not display significant alterations in either type 1 or type 2 DM patients. No significant differences in the number of lysosomes or lipid droplets were detected in diabetic samples when compared to non-diabetic individuals.

Immunohistochemical analysis

α-Amylase localization

Labeling of thin sections with polyclonal anti α-amylase antibody revealed specific reactivity in all serous components of all parotid glands examined in this study.

When compared to non-diabetic samples (Fig. 2a), type 2 diabetic parotid samples (Fig. 2d) showed no differences in the localization of α-amylase. Generally, α-amylase was associated with the Golgi complex and with cisternae of rough endoplasmic reticulum in acinar cells. The secretory granules represented the main site of α-amylase localization. Mitochondria and nuclei appeared devoid of labeling.

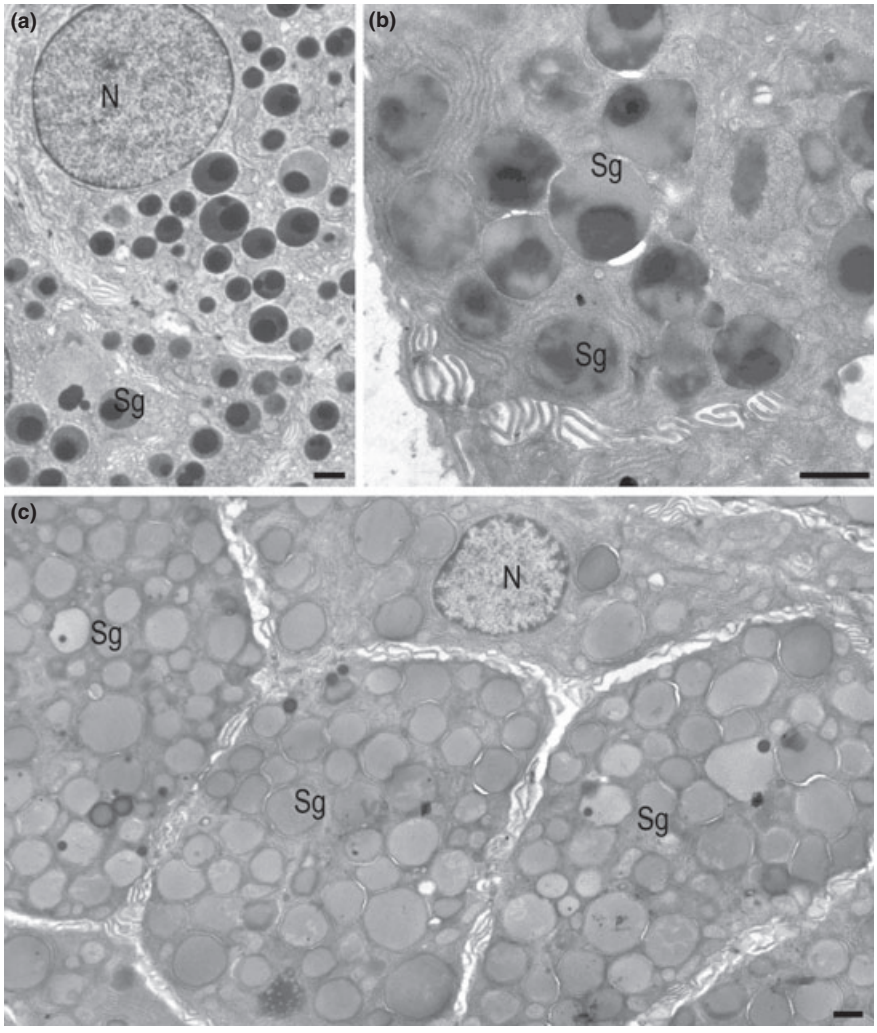

Figure 1 Parotid tissue sections from a non-diabetic patient (Panel a), from a type 1 diabetic patient (Panel b), and from a type 2 diabetic patient (Panel c), displaying portions of serous acinar cells. The secretory granules (Sg) in type 1 DM often contain several irregular dense areas. In type 2 DM, the cells are filled with granules of lower electron density. N = nucleus. Bars = 1 μm.

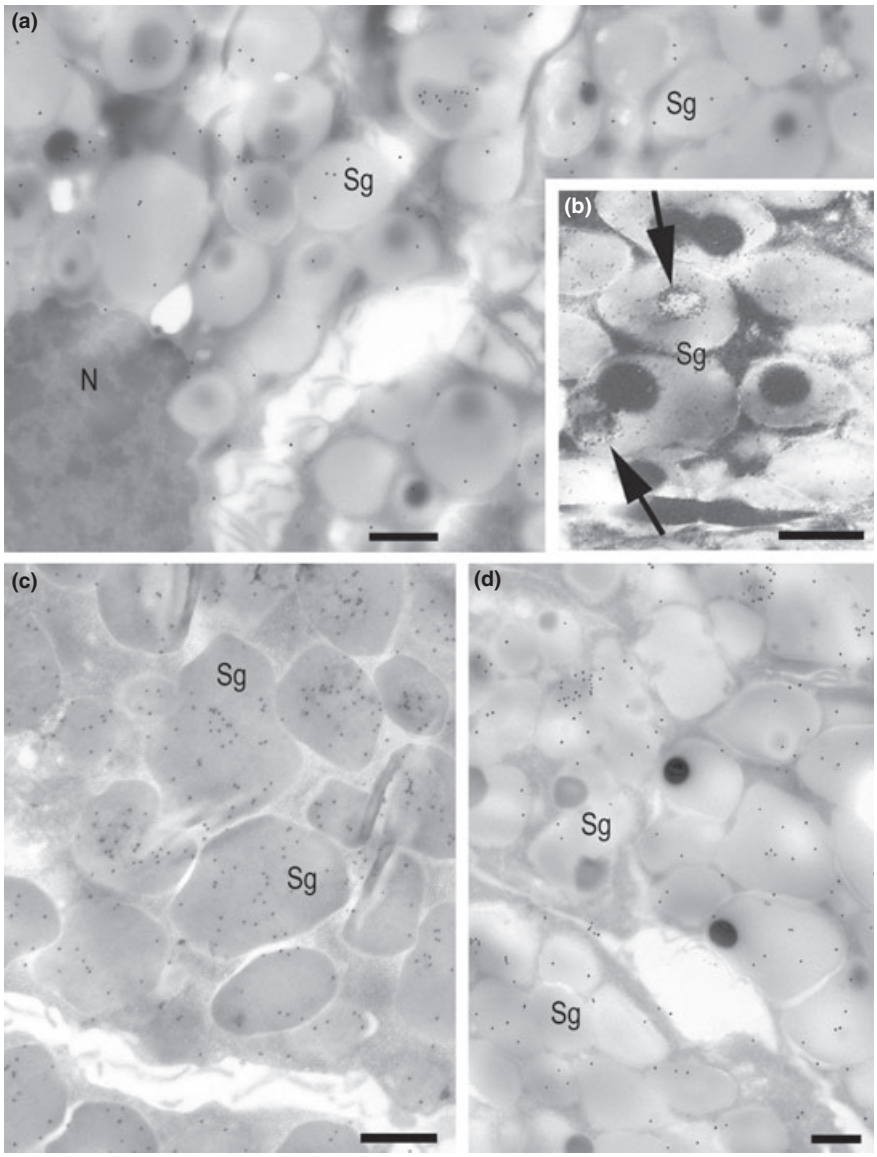

Figure 2 Immunocytochemical labeling of human parotid with anti α-amylase antibody. Panel a: electron microscopic image of non-diabetic parotid. Panels b and c: parotid tissue sections from a type 1 diabetic patient. Panel d: parotid tissue section from a type 2 diabetic patient. Labeling is restricted to secretion granules and appears increased in type 1 DM compared to normal controls and not significantly changed in type 2 DM. In parotid tissue sections from a type 1 diabetic patient gold labeling was often seen concentrated as circular shaped clusters (arrows, panel b). Secretory granules (Sg). N = nucleus. Bars = 1 μm.

Secretory granules of parotid samples of patients with type 1 DM, however, showed a variable labeling pattern (Fig. 2b and c). They represented the main site of gold particle deposition with distinct dense areas of the granule contents often displaying different intensities of α-amylase reactivity (Fig. 2b): (i) dense cores that were usually unlabeled; (ii) moderately dense areas where most of the gold labeling was often seen concentrated as circular clusters; and (iii) a peripheral lucent region with little labeling (Fig. 2b). In samples from non-diabetic patients, labeling was uniformly distributed in the moderately dense regions of secretory granules (Fig. 2a).

Quantitative analysis of gold particle densities of α-amylase showed significant changes in parotid serous cells of type 1 DM patients (Fig. 2), where α-amylase expression was greater than in non-diabetic controls (Table 1). In parotid gland samples from type 2 DM patients, α-amylase labeling appeared to be not significantly changed when compared to non-diabetic samples (Fig. 2) (Table 1).

cARP expression

Thin sections of serous acinar cells of parotid glands of type 1 and type 2 diabetic patients and of non-diabetic patients exhibited similar patterns of cARP localization (Fig. 3). In the cytoplasm, labeling was associated with the endoplasmic reticulum and Golgi complex, whereas secretory granules displayed the main site of gold labeling.

Table 1 Immunogold labeling densities of human parotid granules for α-amylase and cARP (Gold particles/μm^2)

Sample	*Amylase*	*cARP*
Non-diabetic	3.27 ± 0.63 (5)	2.35 ± 0.39 (8)
DM1	10.27 ± 0.67 (8)*	3.18 ± 0.64 (9)
DM2	2.83 ± 0.41 (16)	2.64 ± 0.44 (14)

Values are mean ± standard error (*n*).
*Significantly different from non-diabetic ($P < 0.001$).

Quantitative analysis of gold particle labeling densities showed that parotid cARP expression was slightly, but not significantly, increased in acinar secretory granules of type 1 DM samples compared to non-diabetic glands and not significantly changed in type 2 DM samples (Table 1). Mitochondrial and nuclear labeling densities were not significantly different from those treated with preimmune serum.

Discussion

Previous studies have described changes in the composition of saliva as well as in salivary gland function in both type I and type II DM, which impact on the maintenance of oral health (8, 9, 38, 39). Contradictory findings were reported frequently: in some cases, the salivary protein composition in diabetic subjects and non-diabetic controls was reported to be similar (39), in other cases, protein concentrations were found to be significantly lower (40), and in still others an increase in overall concentration of proteins were reported in diabetes (41). Thus, despite abundant data regarding disorders in salivary gland function in DM, disagreement still exists among published studies. Salivary epidermal growth factor concentration was decreased in diabetic patients (6), and higher concentrations of lactoferrin and lysozyme were found in type 2 DM compared to non-diabetic individuals (9).

The secretory granules of human salivary gland serous cells exhibit characteristic substructures, typically consisting of a dense core or spherule, a region of intermediate density, and a less dense, sometimes fibrillo-granular, matrix (37, 42, 43). The ultrastructural analyses we performed in the type 1 diabetic parotid samples showed alterations in the substructure of their secretory granules, whereas the granules of the type 2 diabetic samples exhibited less remarkable changes. The immunohistochemical analyses of amylase distribution within secretory granules of acinar cells of the type 1 diabetic parotid samples revealed significant changes. Secretory granules represented the main site of labeling and were characterized by the presence of distinct dense areas of the granule contents displaying different intensities of amylase reactivity. In the normal samples as well as in the type 2 diabetic samples, labeling was uniformly distributed in the moderately dense regions of the secretory granules. Previous studies have shown that the distribution of several secretory proteins within granules varies among the different granule regions and among the different glands (44–46). Our results are consistent with these earlier studies, and suggest that type I DM appears to affect the amylase secretory processes in at least two ways: by increasing amylase

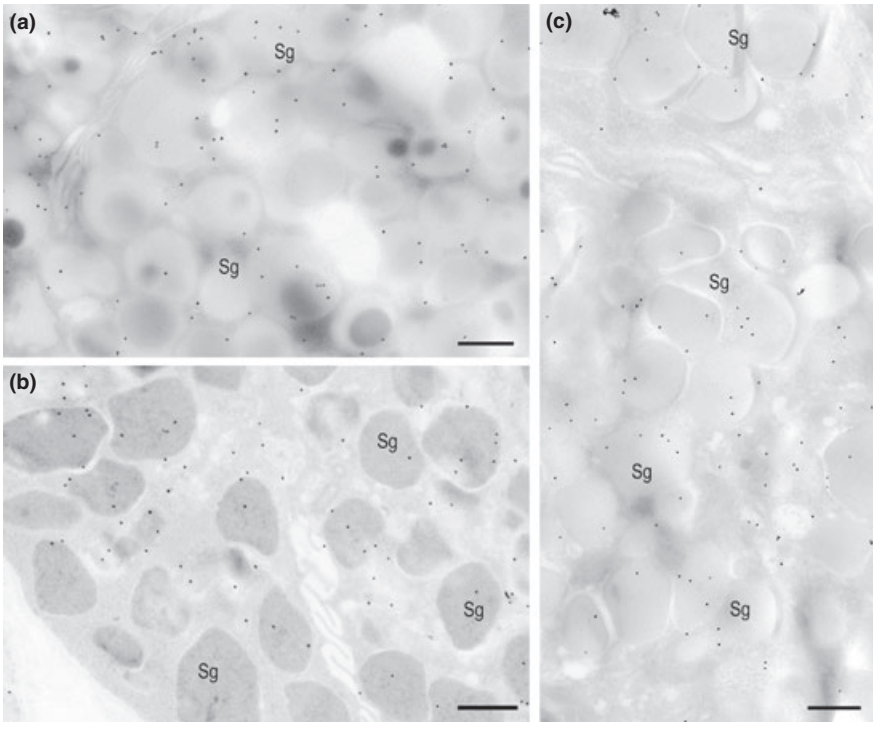

Figure 3 Immunocytochemical labeling of human parotid with anti cARP. Panel a: electron microscopic image of non-diabetic parotid. Panel b: parotid tissue section from a type 1 diabetic patient. Panel c: parotid tissue section from a type 2 diabetic patient. Labeling densities within secretory granules are not significantly changed from non-diabetic controls. Secretory granules (Sg). N = nucleus. Bars = 1 μm.

production, as discussed below, and by altering amylase packaging processes within secretory granules.

Quantitative electron microscopic immunogold labeling of salivary amylase expression showed a significant change in human salivary glands during type 1 DM. Data on amylase expression revealed that the labeling density (gold particles/μm^2) in the secretory granules of parotid glands from type 1 DM patients was higher than that of non-diabetic patients. The salivary samples used in these studies were excised from insulin-treated type 1 DM patients constantly monitored for glycemia. The long-term insulin treatment may account for the increased expression of amylase in these patients. It is well known that insulin can affect gene expression (47) in many tissues. Studies in experimental diabetes have shown that salivary amylase protein (20, 23) and mRNA levels (48) decreased in the rat parotid, and were restored by insulin treatment. Moreover, pancreatic amylase expression is strictly insulin-dependent; in the diabetic pancreas, amylase protein and mRNA levels are only 1% of those present in non-diabetic samples (49, 50). Submandibular epidermal growth factor protein and mRNA levels (51) and kallikrein-like protease activity (52) are significantly reduced by hypoinsulinemia in mice. Rat parotid PRPs and PSP also were decreased in diabetes (23).

In agreement with previous data (53), amylase expression was not significantly changed in type 2 DM with respect to non-diabetic patients. Although the mechanisms that lead to impairment in salivary protein secretion during diabetes still remain unknown, these results suggest that different molecular events occur in the synthesis and secretion process of amylase in type 1 DM compared to type 2 DM. However, considerable discrepancies have been reported regarding amylase expression in type 2 DM patients. Higher concentrations of amylase in saliva of these individuals, compared to control groups were reported by Dodds and Dodds (26). In part, the different approaches used in these studies may account for the observed differences. These earlier investigations were carried out by quantification of salivary amylase activity in the saliva of diabetic patients compared to non-diabetic patients, whereas the immunohistochemical method used in our study was able to detect and to quantify amylase protein expression in the salivary parenchyma. These differences in amylase concentrations also could reflect differences in the disease stage of the type 2 DM patients examined in these studies.

Our results showed no changes in the expression or localization of cARP in parotid glands of type 2 DM patients, compared to non-diabetic patients. Also, in the parotid samples of type 1 DM patients, where amylase expression was altered, cARP expression was not significantly different from non-diabetic patients. Although labeling of rat parotid secretory granules for cARP was unchanged in experimental diabetes, insulin treatment resulted in a significant decrease in granule labeling (23). In contrast, nuclear and cytoplasmic labeling for cARP were decreased in diabetic animals, and partially restored by insulin treatment. Differences in cARP expression between diabetic humans and rats may reflect differences in the nature of the disease, differences in the levels of insulin in human diabetes versus the rat model, or differences in the PKA/cARP system. Taken together, these results suggest that during diabetes, specific molecular changes can occur in the secretion process in salivary glands, and perhaps in other tissues.

Our data indicate that DM elicits highly specific changes in secretory protein expression in human salivary gland cells and tissues and suggest that, as the protein expression sequence and DM changes become established, the findings may translate to clinical applications for diagnosis and staging of DM, possibly using saliva as a testing fluid.

References

1. Mori M, Takeuchi H, Sato M, Sumitomo S. Antimicrobial peptides in saliva and salivary glands: their roles in the oral defense system. *Oral Med Pathol* 2006; **11**: 1–17.
2. Murrah VA. Diabetes mellitus and associated oral manifestations: a review. *J Oral Pathol* 1985; **14**: 271–81.
3. Davidson D, Leibel BS, Berris B. Asymptomatic parotid gland enlargement in diabetes mellitus. *Ann Int Med* 1969; **70**: 31–8.
4. Donath K, Seifert G. Ultrastructural studies of the parotid glands in sialadenosis. *Virchows Archiv (Pathol Anat)* 1975; **365**: 119–35.
5. Satoh M, Yoshihara T. Clinical and ultracytochemical investigation of sialadenosis. *Acta Otolaryngol* 2004; **553**(Suppl): 122–7.
6. Oxford GE, Tayari L, Barfoot MD, Peck AB, Tanaka Y, Humphreys-Beher MG. Salivary EGF levels reduced in diabetic patients. *J Diabetes Complications* 2000; **14**: 140–45.
7. Chavez EM, Borrell LN, Taylor GW, Ship JA. A longitudinal analysis of salivary flow in control subjects and older adults with type 2 diabetes. *Oral Surg Oral Med Oral Pathol Oral Radiol Endod* 2001; **91** Suppl. (2): 166–73.
8. Moore PA, Guggenheimer J, Etzel KR, Weyant RJ, Orchard T. Type 1 diabetes mellitus, xerostomia, and salivary flow rates. *Oral Surg Oral Med Oral Pathol Oral Radiol Endod* 2001; **92** Suppl. (3): 281–91.
9. Dodds MWJ, Yeh C-K, Johnson DA. Salivary alterations in type 2 (non-insulin-dependent) diabetes mellitus and hypertension. *Community Dent Oral Epidemiol* 2000; **28**: 373–81.
10. Dodds MWJ, Johnson DA, Yeh C-K. Health benefits of saliva: a review. *J Dentistry* 2005; **33**: 223–33.
11. Iacopino AM. Periodontitis and diabetes interrelationships: role of inflammation. *Ann Periodontol* 2001; **6**: 125–37.
12. Mealey B. Diabetes and periodontal disease. *J Periodontol* 1999; **70**: 935–49.
13. Löe H, Genco RJ. Oral complications in diabetes. Diabetes in America, 2nd edn, 1995; NIH Publications No. 95-1468.
14. Genco RJ, Grossi SG, Ho A, Nishimura F, Murayama Y. A proposed model linking inflammation to obesity, diabetes, and periodontal infections. *J Periodontol* 2005; **76**: 2075–84.
15. Ben-Aryeh H, Serouya R, Kanter Y, Szargel R, Laufer D. Oral health and salivary composition in diabetic patients. *J Diabetes Complications* 1993; **7**: 57–62.
16. Southerland JH, Taylor GW, Offenbacher S. Diabetes and periodontal infection: making the connection. *Clin Diabetes* 2005; **23**: 171–8.

17. Vernillo AT. Dental considerations for the treatment of patients with diabetes mellitus. *J Am Dent Assoc* 2003; **134**: 24S–33S.
18. Soysa NS, Samaranayake LP, Ellepola ANB. Diabetes mellitus as a contributory factor in oral candidosis. *Diabet Med* 2005; **23**: 455–59.
19. Guggenheimer J, Moore A, Rossie K, et al. Insulin-dependent diabetes mellitus and oral soft tissue pathologies: II. Prevalence and characteristics of Candida and Candidal lesions. *Oral Surg Oral Med Oral Pathol Oral Radiol Endod* 2000; **89**: 570–6.
20. Anderson LC. Effects of alloxan diabetes on rat parotid gland and saliva. *Am J Physiol* 1983; **245**: G431–7.
21. Hand AR, Weiss RE. Effects of streptozotocin-induced diabetes on the rat parotid gland. *Lab Invest* 1984; **51**: 429–40.
22. Anderson LC, Garrett JR. Lipid accumulation in the major salivary glands of streptozotocin-diabetic rats. *Arch Oral Biol* 1986; **31**: 469–75.
23. Anderson LC, Suleiman AH, Garrett JR. Morphological effects of diabetes on the granular ducts and acini of the rat submandibular gland. *Microsc Res Tech* 1994; **27**: 61–70.
24. Szczepanski A, Mednieks MI, Hand AR. Expression and distribution of parotid secretory proteins in experimental diabetes. *Eur J Morphol* 1998; **36**(Suppl): 240–6.
25. Mednieks MI, Szczepanski A, Clark B, Hand AR. Protein expression in salivary glands of rats with streptozotocin diabetes. *Int J Exp Pathol* 2009; **90**: 412–22.
26. Dodds MW, Dodds AP. Effects of glycemic control on saliva flow rates and protein composition in non-insulin-dependent diabetes mellitus. *Oral Surg Oral Med Oral Pathol Oral Radiol Endod* 1997; **83**: 465–70.
27. Varletzidis E, Ikkos D, Paleologou G, Pantazopoulos P, Miras K, Adamopoulos G. Salivary amylase activity in diabetes mellitus. *Panminerva Med* 1978; **20**: 255–62.
28. Hand AR, Mednieks MI. Regulatory subunits of cyclic AMP-dependent protein kinase: presence in granules and secretion by exocrine and endocrine cells. *J Cell Sci* 1989; **93**: 675–81.
29. Mednieks MI, Jungmann RA, Hand AR. Ultrastructural immunocytochemical localization of cyclic AMP-dependent protein kinase regulatory subunits in rat parotid acinar cells. *Eur J Cell Biol* 1987; **44**: 308–17.
30. Mednieks MI, Jungmann RA, Fischler C, Hand AR. Immunogold localization of the type II regulatory subunit of cyclic AMP-dependent protein kinase. Monoclonal antibody characterization and RII distribution in rat parotid cells. *J Histochem Cytochem* 1989; **37**: 339–46.
31. Piludu M, Mednieks MI, Hand AR. Cyclic AMP-receptor proteins in human salivary glands. *Eur J Morphol* 2002; **40**: 219–25.
32. Mednieks MI, Hand AR. Cyclic AMP binding proteins in saliva. *Experientia* 1984; **40**: 945–7.
33. Mednieks MI, Epstein PM, Hachisu R, Hand AR, Esquire RG. Cyclic AMP-reactive proteins in human saliva. *Arch Oral Biol* 1994; **39**: 869–75.
34. Sivakumar TP, Hand AR, Mednieks MI. Secretory proteins in the saliva of children. *J Oral Sci* 2009; **51**: 573–80.
35. Mednieks MI, Hand AR, Grindeland RE. Cyclic AMP-receptor responses to hypergravity. *Aviat Space Environ Med* 1998; **69**: 28–36.
36. Mednieks M, Lin M, Hand AR. Immunocytochemical analysis of cyclic AMP receptor proteins in the developing rat parotid gland. *Arch Oral Biol* 2008; **53**: 429–36.
37. Riva A, Riva-Testa F. Fine structure of acinar cells of human parotid gland. *Anat Rec* 1973; **176**: 149–65.
38. Markopoulos AK, Balazi M. Histopathological and immunohistochemical features of the labial salivary glands in children with type I diabetes. *J Diabetes Complications* 1998; **12**: 39–42.
39. Harrison R, Bowen WH. Flow rate and organic constituents of whole saliva in insulin-dependent diabetic children and adolescents. *Pediatr Dent* 1987; **9**: 287–90.
40. Streckfus CF, Marcus S, Welsh S, Brown RS, Cherry-Peppers G. Parotid function and composition of parotid saliva among elderly edentulous African-American diabetics. *J Oral Pathol Med* 1994; **23**: 277–9.
41. Ben-Aryeh H, Cohen M, Kanter Y, Szargel R, Laufer D. Salivary composition in diabetic patients. *J Diabet Complications* 1988; **2**: 96–9.
42. Tandler B, Erlandson RA. Ultrastructure of the human submaxillary gland. IV. Serous granules. *Am J Anat* 1972; **135**: 419–34.
43. Tandler B, Phillips CJ. Structure of serous cells in salivary glands. *Microsc Res Technol* 1993; **26**: 32–48.
44. Takano K, Bogert M, Malamud D, Lally E, Hand AR. Differential distribution of salivary agglutinin and amylase in the Golgi apparatus and secretory granules of human salivary gland acinar cells. *Anat Rec* 1991; **230**: 307–18.
45. Piludu M, Rayment SA, Liu B, et al. Electron microscopic immunogold localization of salivary mucins MG1 and MG2 in human submandibular and sublingual glands. *J Histochem Cytochem* 2003; **51**: 69–79.
46. Ahmad M, Piludu M, Oppenheim FG, Helmerhorst EJ, Hand AR. Immunocytochemical localization of histatins in human salivary glands. *J Histochem Cytochem* 2004; **52**: 361–70.
47. O'Brien RM, Granner DK. Regulation of gene expression by insulin. *Physiol Rev* 1996; **76**: 1109–61.
48. Kim SK, Cuzzort LM, McKean RK, Allen ED. Effects of diabetes and insulin on alpha-amylase messenger RNA levels in rat parotid glands. *J Dent Res* 1990; **69**: 1500–4.
49. Korc M, Owerbach D, Quinto C, Rutter WJ. Pancreatic islet acinar cell interaction: Amylase messenger RNA levels are determined by insulin. *Science* 1981; **213**: 351–3.
50. Osborn L, Rosenberg MP, Keller SA, Meisler MH. Tissue-specific and insulin-dependent expression of a pancreatic amylase gene in transgenic mice. *Mol Cell Biol* 1987; **7**: 326–34.
51. Kasayama S, Ohba Y, Oka T. Epidermal growth factor deficiency associated with diabetes mellitus. *Proc Natl Acad Sci USA* 1989; **86**: 7644–8.
52. Chan KM, Chao J, Proctor GB, Garrett JR, Shori DK, Anderson LC. Tissue kallikrein and tonin levels in submandibular glands of STZ-induced diabetic rats and the effects of insulin. *Diabetes* 1993; **42**: 113–7.
53. Newrick PG, Bowman C, Green D, et al. Parotid salivary secretion in diabetic autonomic neuropathy. *J Diabetes Complications* 1991; **5**: 35–7.

Acknowledgements

We are grateful to Mr. A. Cadau for his excellent technical assistance. This investigation was supported by the University of Cagliari, NIH grant DE10105, the University of Connecticut Health Center and by Fondazione Banco di Sardegna.