

Figura 1. Trauma de orelha.

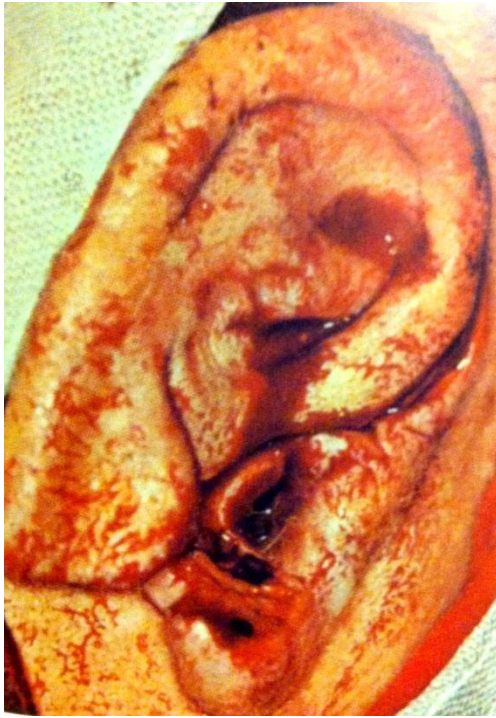


Figura2. Oto-Hematoma.

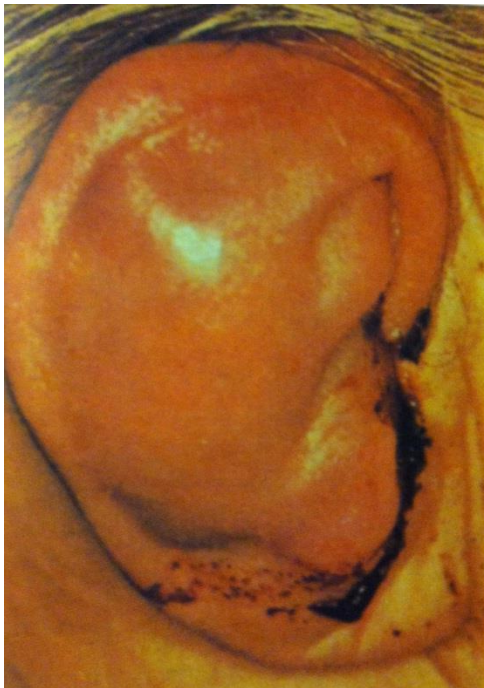


Figura 3. Otoscopia de otite externa fúngica.

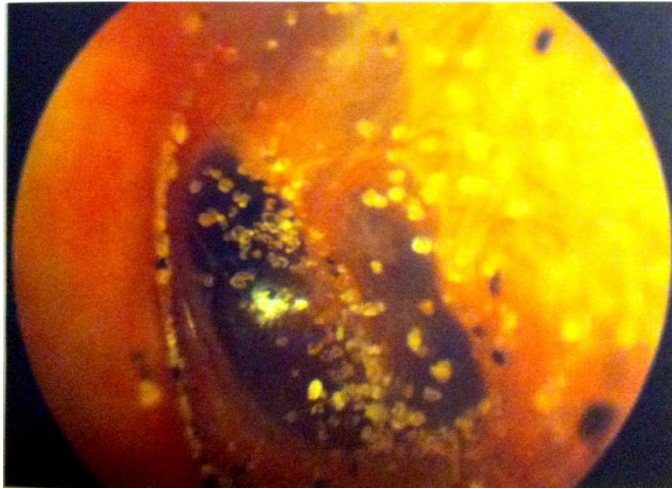


Figura 4. Otoscopia de otite externa localizada.

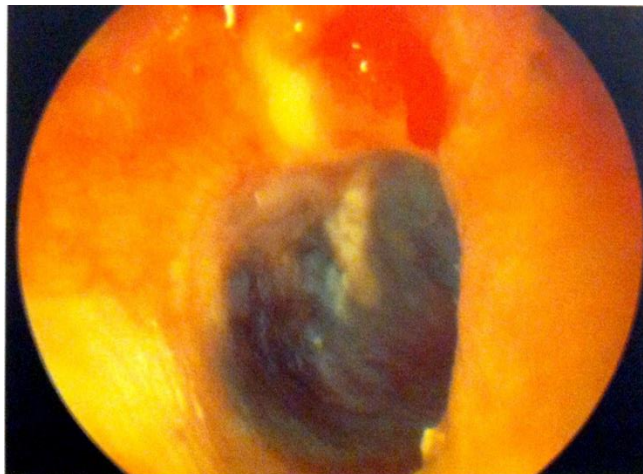

Figura 5. Otoscopia de otite externa difusa.

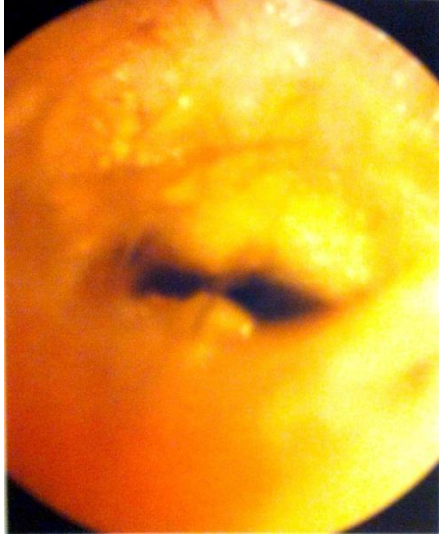


Figura 6. Paciente com otite externa maligna.

