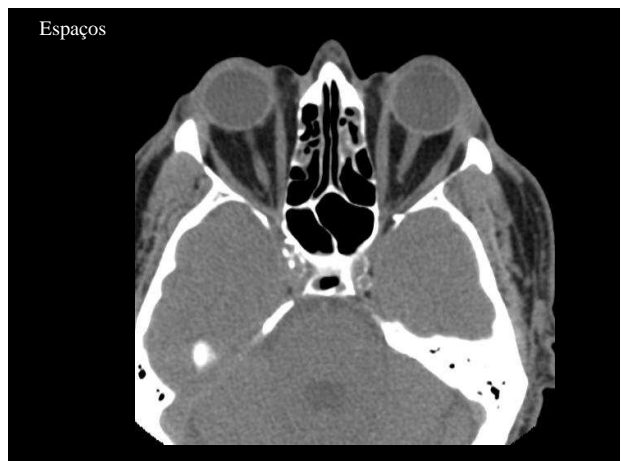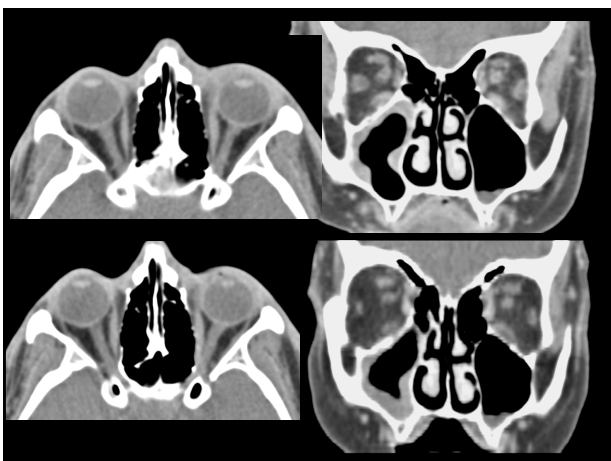
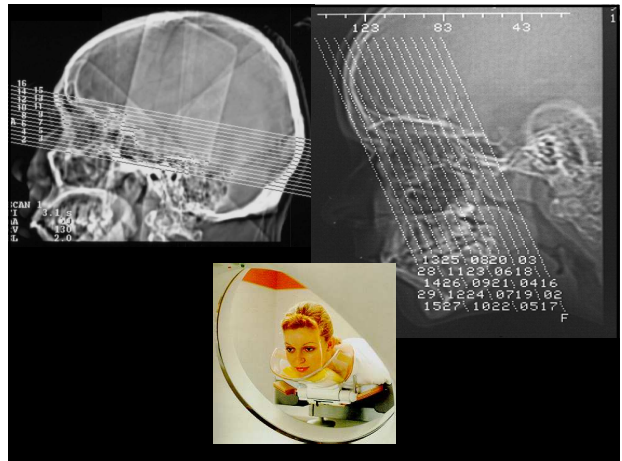
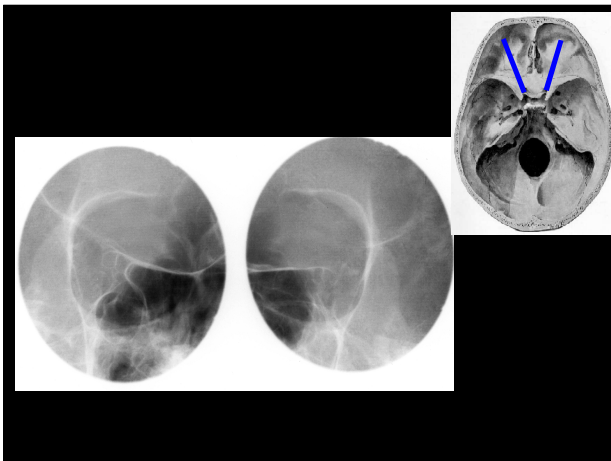
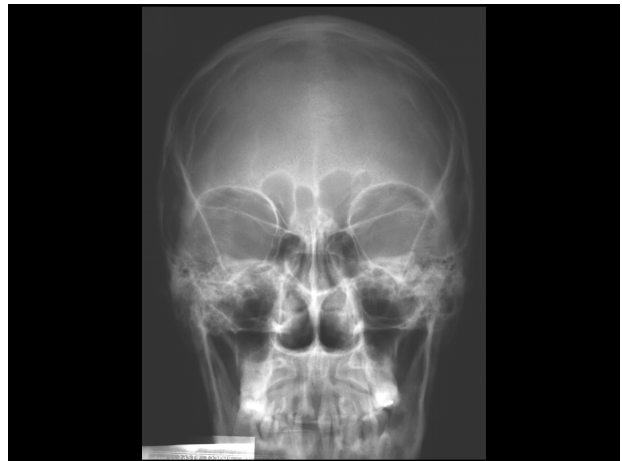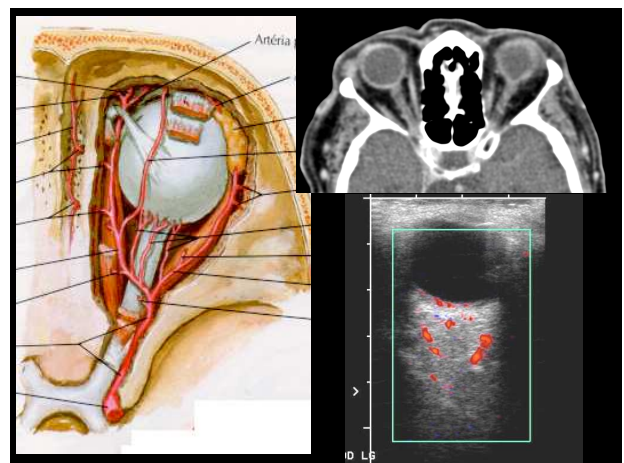
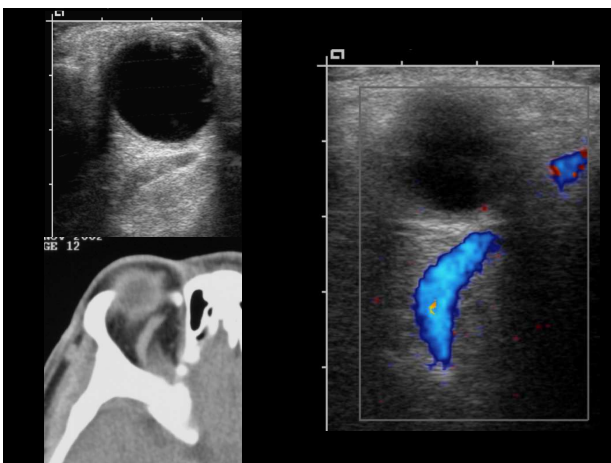
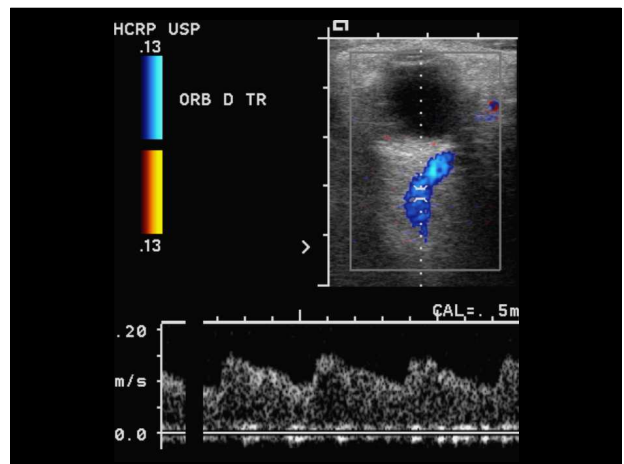
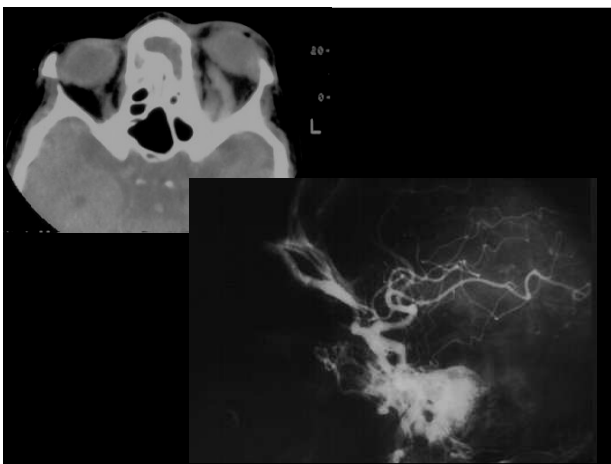
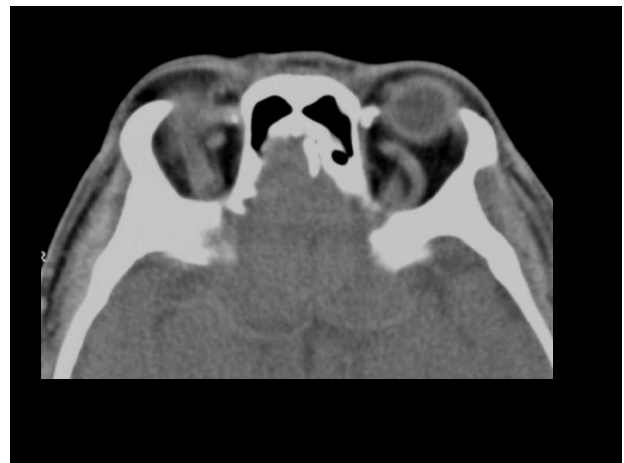
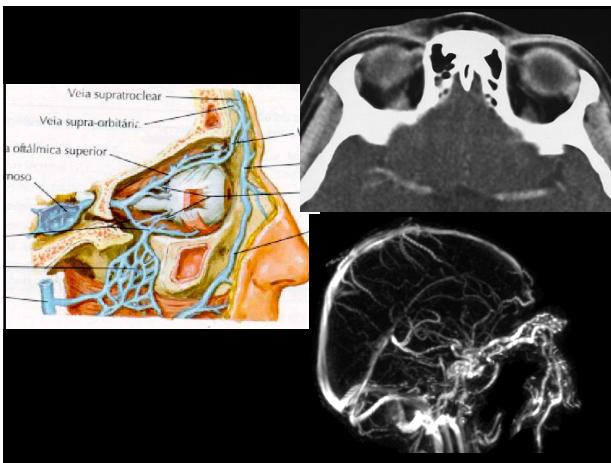
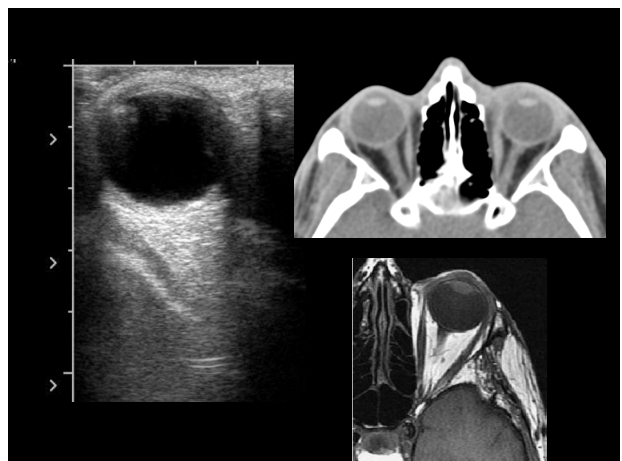
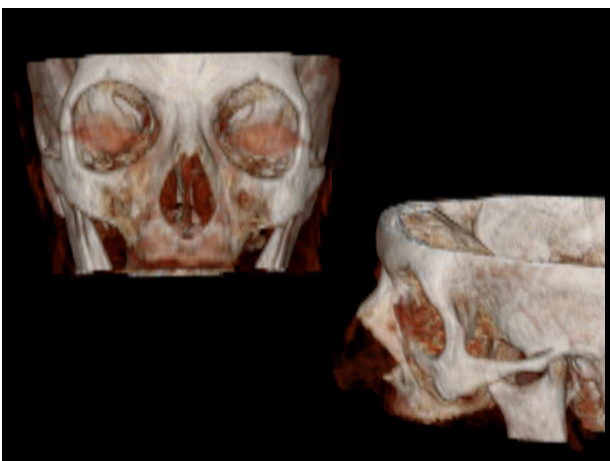
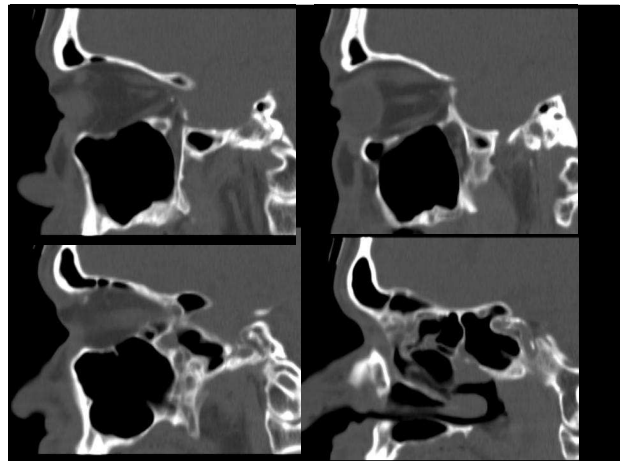
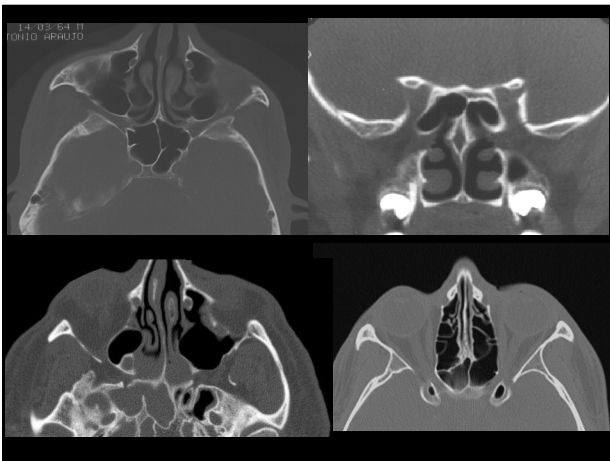
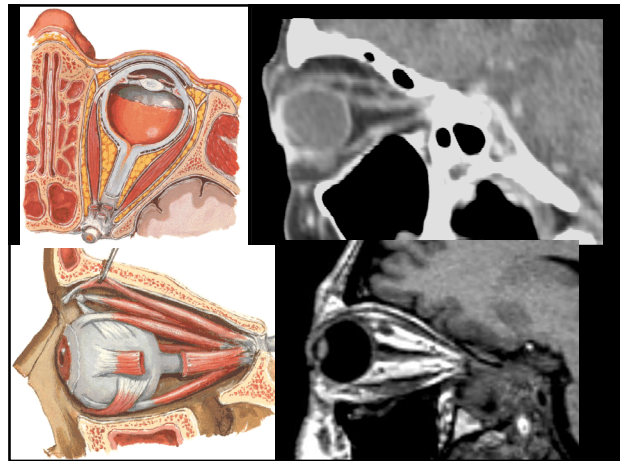


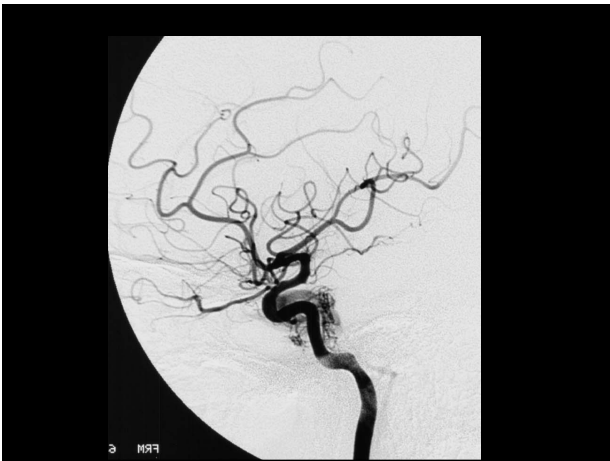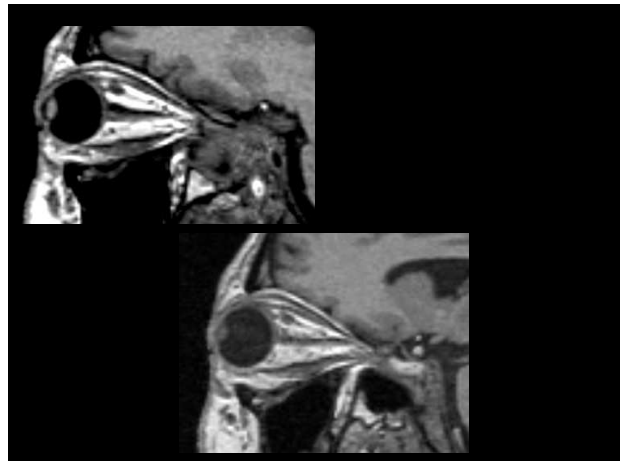
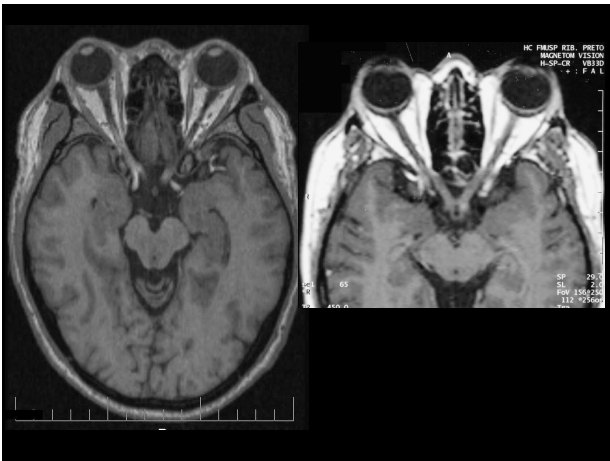
Diagnóstico por imagem em oftalmologia

Antonio Carlos Santos
Centro de Imagens - HCRP-FMRP-USP



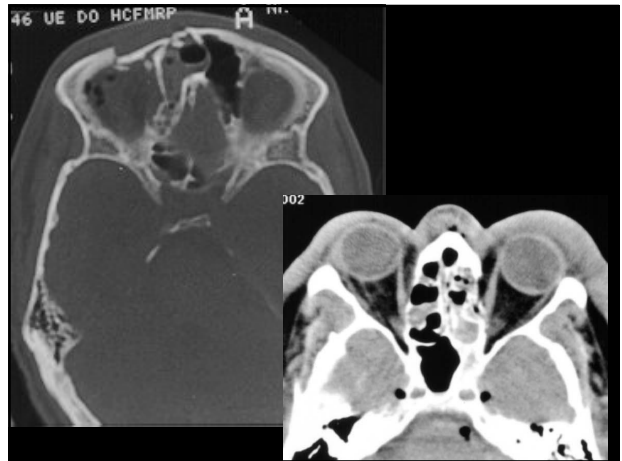




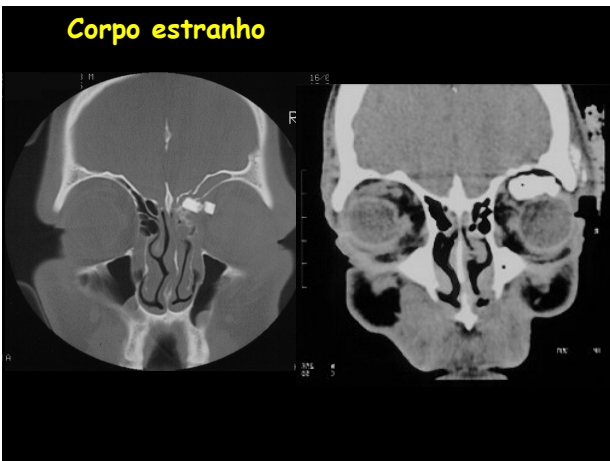

Exemplos de patologias

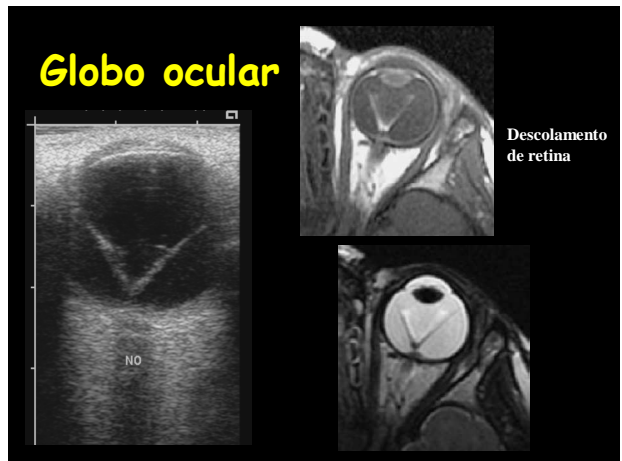
- Trauma
- Processos inflamatórios e infecciosos
- Processos expansivos e Neoplasias
- Lesões vasculares



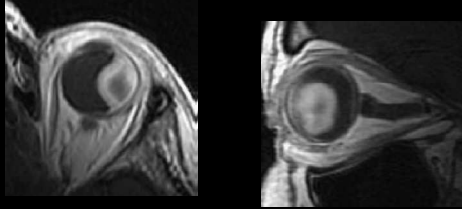
Corpo estranho



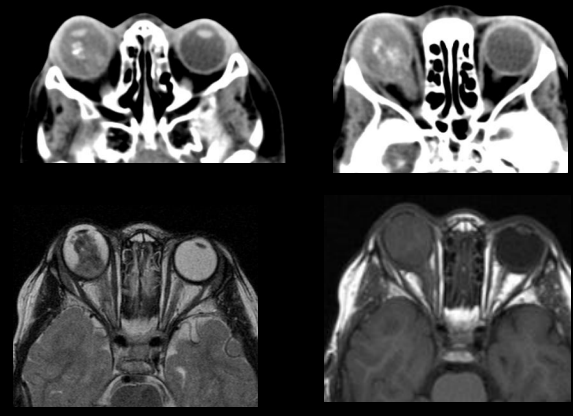
Globo ocular



hemorragia



Neoplasia de globo ocular: retinoblastoma



Neoplasia de globo ocular: retinoblastoma

